Print ISSN: 2321-6379
Online ISSN: 2321-595X

Case Report

Silence Becomes Violent – An Unnatural Event in Cerebral Arachnoid Cyst

Bhavanam Hanuma Srinivas[1,2], A S K Ahamed Sharief[3], Bommisetty Trinath Kumar[4], N V Sundara Chary[5]

[1]Senior Consultant Neurosurgeon, Department of Neurosurgery, Amaravathi Institute of Medical Sciences, Guntur, Pradesh, Andhra Pradesh, India, [2]Assistant Professor, Department of Neurosurgery, Guntur Medical College, Guntur, Andhra Pradesh, India, [3]Junior Consultant, Department of Neurosurgery, Amaravathi Institute of Medical Sciences, Guntur, Andhra Pradesh, India, [4]Senior Consultant, Department of Anaesthesia, Amaravathi Institute of Medical Sciences, Guntur, Andhra Pradesh, India, [5]Senior Consultant, Department of Neurology, Amaravathi Institute of Medical Sciences, Guntur, Andhra Pradesh, India

Abstract

Intracranial arachnoid cysts are usually accounts for 1% of the intracranial mass lesions. Their most frequent location is the middle cranial fossa. Most are asymptomatic or present with headache, convulsions, and hemorrhage. We herein report a clinical case, radiology, and discussion of previously asymptomatic middle cranial fossa arachnoid cyst in a 9-year-old male child who presented with raised intracranial features following a trivial trauma.

Key words: Arachnoid, Rupture, Subdural

INTRODUCTION

Intracranial arachnoid cysts are usually had indolent course, they account for 1% of the intracranial mass lesions.[1] Arachnoid cysts are common childhood developmental anomalies, their most frequent location is the middle fossa.[2] They are benign lesions and may be associated with complications such as subdural hematoma, subdural hygroma, and intracystic hemorrhage. Minor head injury is known to result in subdural hygroma or hematoma due to rupture of arachnoid cyst; however, spontaneous rupture of arachnoid cyst may occur rarely.[2] They are more common in males as compared to females.[3] In children, they are frequently associated with seizures and cranial deformity.[4,5] Rupture of arachnoid cyst causing subdural hygroma is very rare, with few case reports.

CASE REPORT

A 9-year-old, previously healthy boy, is presenting to the emergency department of a tertiary care hospital with the complaints of severe left hemicranial headache and multiple episodes of vomiting for past 2 days. There was no history of loss of consciousness, seizures. The child had H/O trivial trauma 2 weeks back. No significant past medical or surgical history. He achieved all developmental milestones normally. On examination vital data normal, he was drowsy on examination with the GCS 14/15. Power was 5/5 on both sides, all cranial nerves were intact, and no sensory loss was observed. There were no meningeal signs, but there was left side papilledema. His blood investigations, including blood glucose, full blood count, serum creatinine, and electrolytes, were normal. Magnetic resonance imaging (MRI) brain done which showed left middle cranial fossa cyst with left frontotemporoparietal, extra-axial collection of CSF-like intensity (T1 hypo, and T2 hyper) compatible with arachnoid cyst [Figures 1 and 2]. Left pterional craniotomy, evacuation of subdural hygroma, fenestration of cyst into suprasellar cistern, and marsupialization of the cyst were performed [Figure 3]. The patient developed pseudomeningocele, which was managed with lumbar CSF drainage for 4 days and was discharged without any deficits. The post-operative imaging showed resolution of the subdural hygroma.

Access this article online

www.ijss-sn.com

Month of Submission : 06-2020
Month of Peer Review : 07-2020
Month of Acceptance : 07-2020
Month of Publishing : 08-2020

DISCUSSION

Arachnoid cysts are CSF collections between the two layers of arachnoid membrane and are usually benign

Corresponding Author: Dr. Bhavanam Hanuma Srinivas, Flat No 5, Venkatasambasiva Residency, Chandramouli Nagar 7/2, Guntur - 522 007, Andhra Pradesh, India.

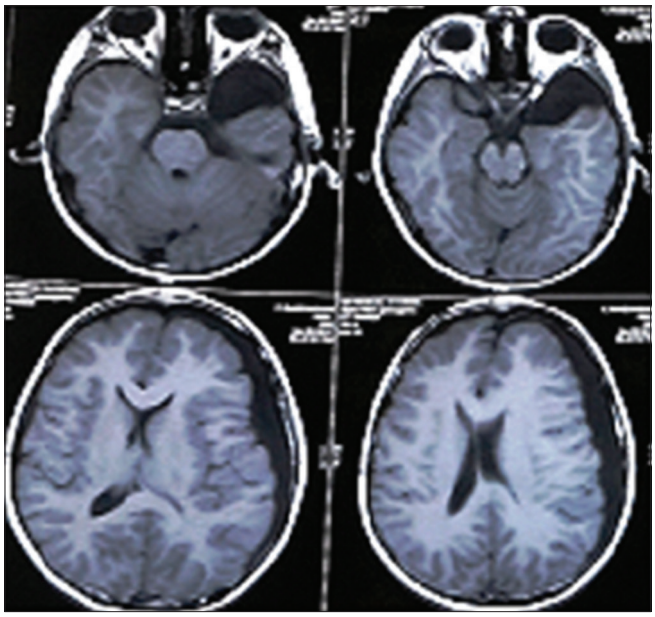

Figure 1: Magnetic resonance imaging brain T1W image showing subdural hypointensity in the left frontotemporal region and left middle cranial fossa suggestive of arachnoid cyst with subdural hygroma and mass effect

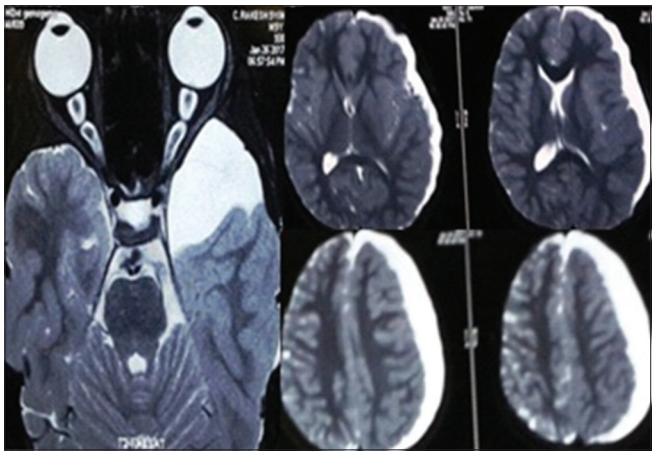

Figure 2: Magnetic resonance imaging brain T2 W image showing subdural hyperintensity in the left frontotemporal region and left middle cranial fossa suggestive of arachnoid cyst with subdural hygroma and mass effect

lesions. About 1% of intracranial space occupying lesions are arachnoid cysts. They usually grow slowly and occasionally disappear without treatment.[6] Arachnoid cysts complicated, with cystic expansion, intracystic hemorrhage, subdural hematoma, and subdural hygroma, are usually symptomatic. Their association with subdural hygroma is rare.[7,8] In 1924, first time Naffziger described, the possible mechanism of subdural hygroma formation, according to which a tear in the arachnoid membrane resulting in one-way valve mechanism with accumulation of CSF is thought to be responsible for subdural hygromas.[9,10] Tears of outer cyst membrane are the main cause of subdural

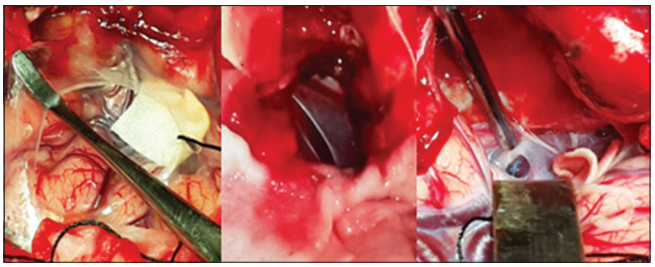

Figure 3: Intraoperative image showing left FTP area, slit like tear between left middle cranial fossa and FTP area, after marsupialization opening of cyst into suprasellar cisterns

hygroma in arachnoid cyst patients. The rupture is either spontaneous or traumatic in origin. Raised intracranial pressure with Valsalva maneuver is another possible cause of cyst rupture leading to hygroma. Most of the cases present with symptoms of raised intracranial pressure such as nausea, vomiting, headache, and rarely 6th cranial nerve palsy. Parsch *et al.* reported subdural hemorrhage in 2.43% and subdural hygroma in 0.46% of patients with arachnoid cyst reported on MRI. Mild head injury is the most common cause of arachnoid cyst rupture; however, rarely do they rupture spontaneously. Gradual increase in size of hygroma is due to the continuous transudation of cerebrospinal fluid in the ruptured cyst. CSF itself is less expansive and compressive than blood due to its low osmotic and hydrostatic pressure. Patients with arachnoid cyst may have complications by subdural hematoma as they are predisposed to it. Various management options of cerebral arachnoid cysts have been described in the literature. Surgical treatment of symptomatic cysts is generally acceptable. Craniotomy and fenestration of cyst, subdural evacuation, and CSF diversion are procedures performed in arachnoid cyst rupture depending on the size, location, and clinical presentation. For asymptomatic arachnoid cysts, prophylactic surgical treatment is not recommended.

CONCLUSIONS

Traumatic subdural hygroma should be suspected in symptomatic arachnoid cyst patients with any history of trivial head injury. MRI brain is investigation of choice. Features of raised intracranial pressure warrant for surgical treatment.

REFERENCES

1. Rajesh A, Bramhaprasad V, Purohit AK. Traumatic rupture of arachnoid cyst with subdural hygroma. J Pediatr Neurosci 2012;7:33-5.
2. Albuquerque FC, Giannotta SL. Arachnoid cyst rupture producing subdural hygroma and intracranial hypertension: Case reports. Neurosurgery 1997;41:951-6.
3. Sener RN. Arachnoid cysts associated with post-traumatic and spontaneous

rupture into the subdural space. Comput Med Imaging Graph 1997;21:341-4.
4. Choux M, Raybaud C, Pinsard N, Hassoun J, Gambarelli D. Intracranial supratentorial cysts in children excluding tumor and parasitic cysts. Childs Brain 1978;4:15-32.
5. Parsch CS, Krauss J, Hofmann E, Meixensberger J, Roosen K. Arachnoid cysts associated with subdural hematomas and hygromas: Analysis of 16 cases, long-term follow-up, and review of the literature. Neurosurgery 1997;40:483-90.
6. Dodd RL, Barnes PD, Huhn SL. Spontaneous resolution of a prepontine arachnoid cyst: Case report and review of the literature. Pediatr Neurosurg 2002;37:152-7.
7. Poirrier AM, Ngosso-Tetanye I, Mouchamps M, Misson JP. Spontaneous arachnoid cyst rupture in a previously asymptomatic child: A case report. Eur J Paediatr Neurol 2004;8:247-51.
8. Cakir E, Kayhankuzeyli, Sayin OC, Peksoylu B, Karaarslan G. Arachnoid cyst rupture with subdural hygroma: Case report and literature review. Neurocirugia (Astur) 2004;15:72-5.
9. Naffziger HC. Subdural fluid accumulations following head injury. J Am Med Assoc 1924;82:1751-2.
10. Çokluk C, Şenel A, Çelik F, Ergür H. Spontaneous disappearance of two asymptomatic arachnoid cysts in two different locations. Minim Invasive Neurosurg 2003;46:110-2.

How to cite this article: Srinivas BH, Sharief AS, Kumar BT, Chary NV. Silence Becomes Violent – An Unnatural Event in Cerebral Arachnoid Cyst. Int J Sci Stud 2020;8(5):1-3.

Source of Support: Nil, **Conflicts of Interest:** None declared.