Print ISSN: 2321-6379
Online ISSN: 2321-595X

Case Report

# Interesting Internal Hernia: A Rare Case Report of Intestinal Obstruction

**B R Sathya Krishna[1], Sravan Kumar Yelagandula[2]**

[1]Senior Surgeon, Department of General Surgery, St Marthas Hospital, Bengaluru, Karnataka, India, [2]Senior Registrar, Department of General Surgery, St Marthas Hospital, Bengaluru, Karnataka, India

## Abstract

Internal hernias are a relatively uncommon condition and also a rare type of intestinal obstruction. Many types of internal hernias have been described, among which paraduodenal hernias are considered to be most common. Internal hernias are very challenging to diagnose clinically and may be missed in the emergency room because of their non-specific signs and symptoms. These hernias may present as a surgical emergency as they progress to intestinal strangulation and ischemia if their diagnosis is delayed. Hence, accurate preoperative diagnosis is crucial for appropriate management. Many a times these hernias are found intraoperatively as a surprise. Herein, we report a 43-year-old patient, who was preoperatively diagnosed with a left paraduodenal hernia with the help of contrast-enhanced computed tomography abdomen and pelvis and underwent a laparotomy in an emergency setting. The jejunum and ileum were entrapped (bowel was viable) and were seen herniating through the foramen of Landzert - left paraduodenal space. Once the hernial contents had been reduced, non-absorbable sutures were used to obliterate the defect. Post-operative period was uneventful and the patient was discharged on POD 3.

**Key words:** Foramen of landzert, Internal hernia, Multidetector computed tomography, Paraduodenal hernia

## INTRODUCTION

Internal hernias are defined as protrusion of abdominal viscera through an opening within the peritoneal cavity, although all are not intraperitoneal. They can be congenital or acquired.[1] Paraduodenal hernias are one among many internal hernias. They are rare congenital hernias accounting for <2% of all intestinal obstructions, and most frequently involve the jejunum.[2] Left paraduodenal hernias are most common among them and result from abnormal rotation of midgut and failure of peritoneal fusion.[2] They usually present with acute abdominal pain, chronic digestive disorders, or variable symptoms; and can even remain silent. This non-specific presentation leads to delay in diagnosis often making internal hernias an incidental intraoperative finding.[3] Therefore, whenever the possibility of an internal hernia is considered, a rapid higher imaging is necessary to aid in early diagnosis and prompt intervention.

Access this article online

www.ijss-sn.com

Month of Submission : 07-2021
Month of Peer Review : 08-2021
Month of Acceptance : 08-2021
Month of Publishing : 09-2021

Multidetector computed tomography (MDCT), with its wide availability, has become first-line imaging technique in such patients.[3] Timely surgical intervention minimizes the mortality and morbidity associated with this hernia.

## CASE REPORT

A 43-year-old male presented to the emergency department with complaints of diffuse pain abdomen on and off for 1 month, aggravating with food intake. The pain was sudden in onset, of colicky type, gradually progressive in nature, and would relieve spontaneously. Occasionally, it was followed by non-bilious vomiting, containing food particles. Patient was admitted in a local hospital twice in the past 1 month for similar complaints where ultrasound and endoscopy were done and were normal. He had no history of previous surgeries and was not on any regular medications. On physical examination, the patient had tachycardia – 102 bpm and was dehydrated. Other vitals such as blood pressure and urine output were normal. There was no icterus. On examination, there was a diffuse mass noted in the left upper quadrant of the abdomen, not well defined, firm in consistency, tender, but there was no guarding. No hepatosplenomegaly. The rest of the abdomen was soft. Laboratory studies revealed total counts of 11,400, with other parameters

**Corresponding Author:** Dr. B R Sathya Krishna, 242, WCR, 2 stage Mahalakshmipuram, Bangalore - 560 086, Karnataka, India.


**Figure 1: X-ray abdomen erect and supine done on admission**

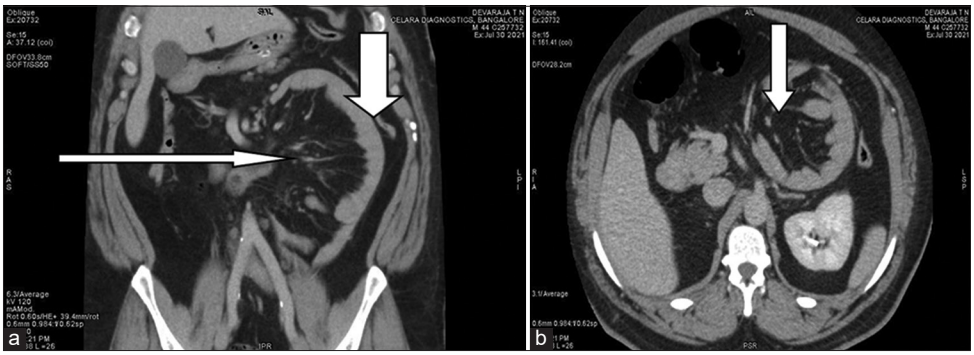


**Figure 2: (a and b) Contrast-enhanced computed tomography images of abdomen showing bowel loops herniating through a defect in left paraduodenal region in left hyochondrium upto left lumbar region (arrow marks). Crowding of small bowel loops within the sac**

being normal. X-ray of the abdomen erect and supine was normal [Figure 1]. Since the patient was hemodynamically stable, contrast-enhanced computed tomography (CECT) abdomen and pelvis were done [Figure 2] which revealed left paraduodenal hernia with entrapped small bowel loops and features suggestive of obstruction. Hence, patient was taken up for emergency exploratory laparotomy. Operative findings revealed a defect in the left paraduodenal space (foramen of landzert) with jejunal and ileal loops trapped in it [Figure 3]. Bowel appeared viable. After reducing the bowel from defect, the paraduodenal space was closed by approximating the mesocolon fold to the base of mesentery taking care not to injure the inferior mesenteric vein [Figure 4]. Pos-toperative period was uneventful. CECT repeated post-operatively showed normal bowel loops without any herniation [Figure 5]. The patient tolerated soft diet on POD 1, moved his bowel on POD 2, and was discharged on POD 3 in stable condition.

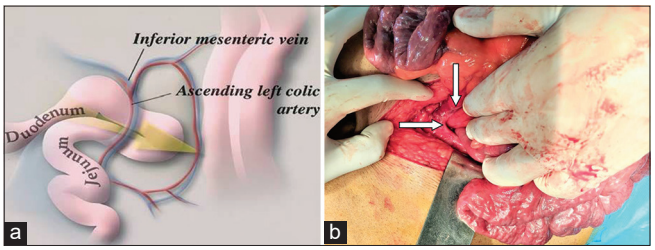


**Figure 3: (a and b) Intraoperative photograph showing left paraduodenal hernia with small bowel loops herniating through foramen of Landzert. Contents being reduced. Bowel looks viable**

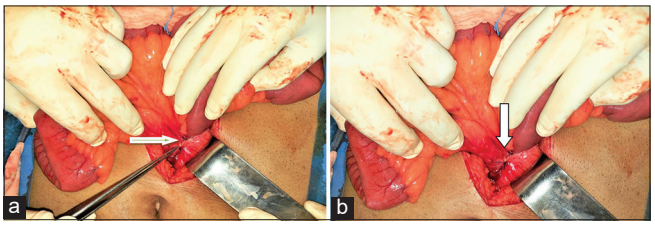


**Figure 4: (a and b) Defect closed with non absorbable suture after reducing the contents**

## DISCUSSION

Internal hernias are either congenital or acquired, among which acquired are more common. Congenital internal hernias are classified by Gharemani into Paraduodenal (30–50%), Foramen of Winslow, pericaecal, intersigmoid, and paravesical.[2]

**Figure 5: (a and b) Post operative computed tomography images showing no herniation**

Paraduodenal hernia, also known as mesocolic hernia, was first described in an autopsy by Neubauer in 1786. Later, an accurate scientific description of the condition was provided by Treitz in 1857, who considered it a retroperitoneal protrusion of abdominal viscera. The classification of hernia into the distinct left and right types was made by Jonnesco in 1889.[4]

In 1923, Andrews postulated that paradudodenal hernias result from an embryological error during the midgut rotation. The mesentery fails to fuse with the parietal peritoneum of the posterior abdominal wall in the early weeks of development, that is, after the return of the herniated bowel loops into the abdominal cavity. This creates a potential space of herniation behind the mesocolon. Therefore, they are termed as mesocolic hernias.[4]

Left paraduodenal hernia, which arises from the fossa of Landzert, comprises <2% of all hernias and is about 3 times more common than its right counterpart (Waldeyer's hernia). It occurs through a defect in the left portion of the transverse mesocolon that gives way to retroperitoneal herniation of the small intestine (usually proximal jejunum). The fossa of Landzert is located to the left of the fourth part of the duodenum, posterior to the inferior mesenteric vein, and ascending branch of a left colic artery, where they form the congenital defect.[5]

Majority of presentations occur between the 4th or 5th decade with a mean age of 38.5 years.[6] Symptoms vary from being asymptomatic which are found incidentally during intraop or may present with symptoms such as diffuse pain abdomen, vomiting, and other features of obstruction and gangrenous bowel. Sometimes symptoms may mimic peptic ulcer disease or any biliary disease for which patient may be receiving unnecessary interventions.

MDCT has become the investigation of choice in detecting internal hernias.[5] Although ultrasonography of the abdomen, barium enhanced studies are other imaging modalities that can also be used.

The lifetime risk of incarceration or strangulation is over 50% with a mortality risk of 20–50%, if left untreated.[5] The principles of surgery in the treatment of paraduodenal hernia include reduction of the hernia content, resection of the necrotic intestinal segment if present and repair of the hernial orifice by the closure of the defect.

The treatment of the paraduodenal hernia is surgery. It may be carried out by either a conventional open approach or laparoscopic approach. In our case, we performed exploratory laparotomy, and contents were reduced. Many recent studies that have compared open to laparoscopic approach showed that the laparoscopic approach has better results in terms of less post-operative stay, pain, wound infections, and postop ileus.[6,7]

## CONCLUSION

Paraduodenal hernia is a relatively rare cause of acute abdomen. Establishing a clinical diagnosis is challenging and is delayed owing to its variable signs and symptoms. Although it is a rare condition, it can cause high morbidity and mortality if left untreated. Internal hernia as the differential diagnosis has to be kept in mind, particularly in those who have not undergone previous abdominal surgery. With the advent of MDCT, early diagnosis of internal hernias has been made relatively easier. Early surgical intervention is necessary to avoid associated morbidity and mortality.

## REFERENCES


1. Doishita S, Takeshita T, Uchima Y, Kawasaki M, Shimono T, Yamashita A, *et al*. Internal hernias in the era of multidetector CT: Correlation of imaging and surgical findings. Radiographics 2015;36:88-106.
2. Kar S, Mohapatra V, Rath PK. A rare type of primary internal hernia causing small intestinal obstruction. Case Rep Surg 2016;2016:3540794.
3. Monica ML, Antonella M, Gloria A, Diletta C, Nicola M. Internal hernias: A difficult diagnostic challenge. Review of CT signs and clinical findings. Acta Biomed 2019;90:20-37.
4. Kadhem S, Ali MH, Al-Dera FH, Alzayer NA, Alyagoub HM. Left paraduodenal hernia: Case report of rare cause of recurrent abdominal pain.

Cureus 2020;12:e7156.
5. Hassani KI, Aggouri Y, Laalim SA, Toughrai I, Mazaz K. Left paraduodenal hernia: A rare cause of acute abdomen. Pan Afr Med J 2014;17:230.
6. Shadhu K, Ramlagun D, Ping X. Para-duodenal hernia: A report of five cases and review of literature. BMC Surg 2018;18:32.
7. Jeong GA, Cho GS, Kim HC, Shin EJ, Song OP, *et al*. Laparoscopic repair of paraduodenal hernia: Comparison with conventional open repair. Surg Laparosc Endosc Percuan Tech 2008;18:611-5.

**How to cite this article:** Krishna BRS, Yelagandula SK. Interesting Internal Hernia: A Rare Case Report of Intestinal Obstruction. Int J Sci Stud 2021;9(6):1-4.

**Source of Support:** Nil, **Conflicts of Interest:** None declared.