Print ISSN: 2321-6379
Online ISSN: 2321-595X

Case Report

An Interesting Case of Solitary Human Muscular Cysticercosis with Elastography Findings

Aishwarya Jeyakumar[1], Vignesh Gadupudi[2], P M Venkata Sai[3]

[1]Junior Resident, [2]Senior Resident, [3]Professor, Department of Radio-Diagnosis, Sri Ramachandra Institute of Higher Education and Research, Chennai, Tamil Nadu, India

Abstract

Context: Cysticercosis is an infection caused by the larval form of the parasite *Taenia solium*. High-resolution ultrasonography was done on Mindray Resona 7 machine with linear probe at 12 MHz frequency and we diagnosed as cysticercosis with surrounding inflammation in the right adductor magnus muscle of thigh.

Case Report: A female patient in her 20's presented with a painful swelling on the inner aspect of her right thigh. On ultrasonography, there was a well-defined isolated cystic lesion of size 3.3 × 2.5 cm with a hyperechoic speck within in intramuscular plane of adductor magnus muscle. Shear wave elastography was also performed and muscular cysticercosis was confirmed. She was treated conservatively with albendazole and steroids, which led to complete resolution of the swelling.

Conclusion: Lesions in intramuscular plane can be diagnosed on high-resolution sonography combined with elastography confidently. This reduces the expenditure cost for the patient.

Key words: Cysticercosis, Elastography, High-resolution ultrasound, Intramuscular, Medical management, Non-invasive

INRODUCTION

Cysticercosis is very common in Indian communities with poor sanitary facilities and poor hygiene. It is also commonly seen in pork eaters. There are two-way a human can get infected, the first being by eating contaminated pork meat. Second is by eating food or water contaminated by feces containing eggs of tis parasite. History taking is crucial for every patient, as it could help us narrow down the differentials. Furthermore, since this disease is prevalent in India, we should be able to treat the patient with the least number of investigative methods. Here, we are trying to emphasize the importance of ultrasonography along with elastography is diagnosing neurocysticercosis as it is non-invasive and non-ionizing method.

Access this article online

www.ijss-sn.com

Month of Submission : 10 - 2022
Month of Peer Review : 11 - 2022
Month of Acceptance : 11 - 2022
Month of Publishing : 12 - 2022

CASE DESCRIPTION

A female patient in her 20's, non-vegetarian, residing in a low socioeconomic status, presented clinically with a painful swelling in the inner aspect of her right upper thigh for the past 2 months. On clinical examination, her vitals were stable and on local examination, a swelling measuring 3 × 4 cm was noted in the upper posteromedial aspect of her right thigh. No discoloration of the skin or surrounding tissues noted. The swelling was soft and mildly tender on palpation. There was no associated neurological or ocular involvement.

Baseline blood investigations, renal and liver functions tests showed values within the normal range. As a part of radiological investigations, ultrasound (USG) of upper right thigh [Figure 1] was performed using MINDRAY RESONA 7 high end USG machine with linear transducer of 12 Mhz, which showed a well-defined hypoechoic area measuring 3.5 × 1.9 × 3 cm in the adductor magnus muscular plane of posteromedial aspect of the right inner thigh [Figure 2]. A well-defined cystic area [Figure 3] measuring 3.3 × 2.5 cm with hyperechoic speck [Figure 4] was seen within the lesion in the periphery. No peripheral or internal vascularity was noted. The lesion was seen placed along the muscle fibers of the adductor magnus muscle.

Corresponding Author: Vignesh Gadupudi, Sri Ramachandra Institute of Higher Education of Research, Chennai, Tamil Nadu, India.

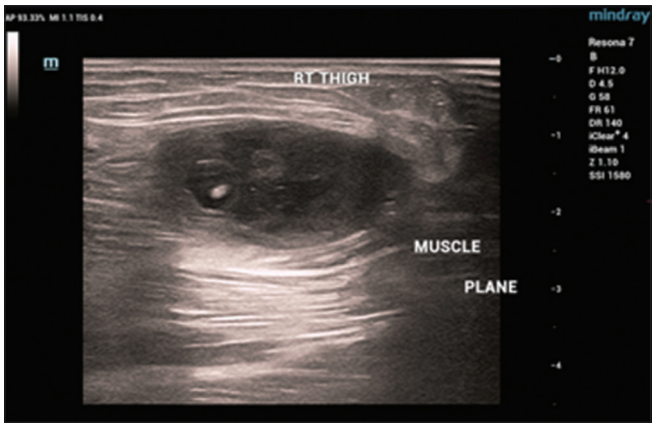

Figure 1: Encapsulated hypoechoic lesion with central echogenic nodule showing "cyst with dot sign" in the intramuscular plane

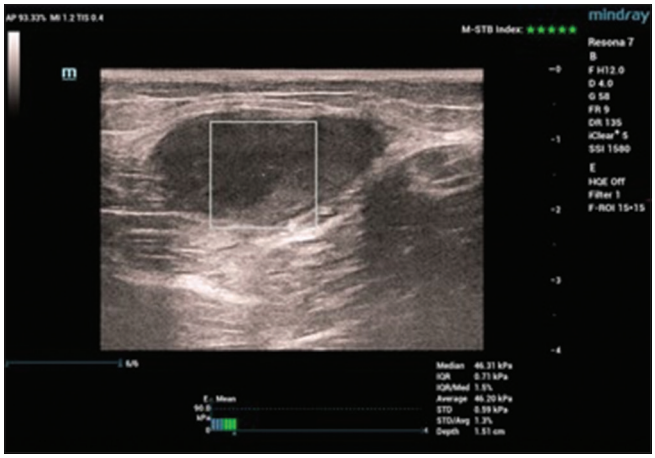

Figure 2: Elastography findings of the larger hypoechoic lesion

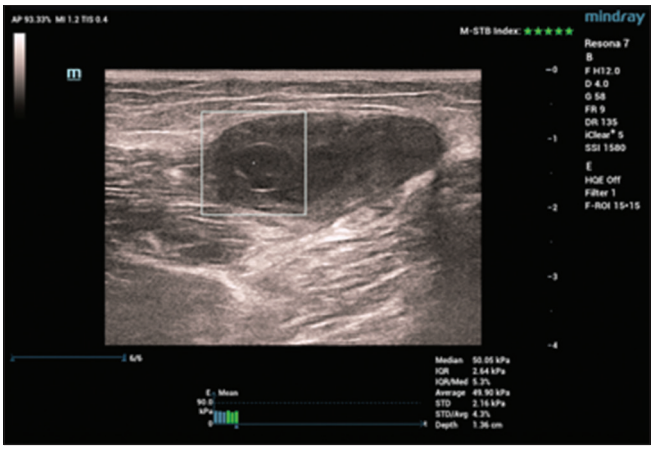

Figure 3: Elastography findings of the cystic lesion

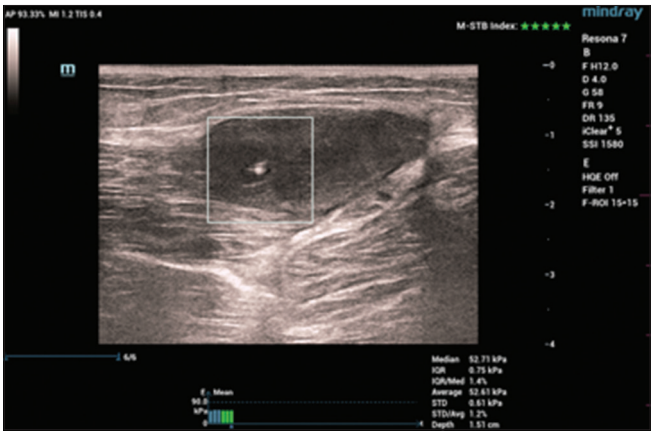

Figure 4: Elastography findings of the hyperechoic scolex

Shear wave elastography (sound touch quantification [STQ]) was performed on this lesion. To weaken artificial stiffness, transducer was put on the surface of lesion vertically as gently as possible. Patients were asked to hold their breath for several seconds to acquire stable sound touch elastography (STE) images.

2D and 3D shear wave by supersonic mindray has come out with its unique STQ option which was used to analyze this lesion. We have used in this study STQ this tool which give us MEAN, MAX, MIN, SD, DEPTH OF ROI CENTRE, MEDIAN, IQR, IQR/MED, and AVERAGE of the selected region of interest. [Table 1] In view of location of the lesion in muscle and along the muscle fibers along with a small rounded cystic area containing speck of hyperechoic area in the center, diagnosis of cysticercosis of muscle plane in adductor muscle was made [Figure 1]. Now, we can safely say that the surrounding hypoechoic area is suggestive of the inflammatory change in the adjacent muscle, and the peripheral lesion placed within it was the encysted larvae, whereas the hyperechoic speck was the scolex of the parasite. Further, investigations were not necessary but if doubtful, biopsy would be confirmatory in such cases. However, due to financial affordability issues, we did not advise her such investigations.

Table 1: Elastography findings comparison between hypoechoic lesion, cyst, scolex and adjacent muscle

STQ values	Hypoechoic lesion [Figure 2]	Cyst [Figure 3]	Scolex [Figure 4]	Muscle nearby
Median	46.31 kPa	50.05 kPa	52.71 kPa	35.8 kPA
IQR	0.71 kPa	2.64 kPa	0.75 kPa	2.14 kPa
IQR/MED (%)	1.5	5.3	1.4	6.0
Average	46.20 kPa	49.90 kPa	52.61 kPa	35.31 kPa
STD	0.59 kPa	2.16 kPa	0.61 kPa	1.78 kPa
STD/Avg (%)	1.3	4.3	1.2	5.0
Depth	1.51 cm	1.36 cm	1.51 cm	2.52 cm

Cysticercosis should always be kept as a differential diagnosis in all kinds of intramuscular or subcutaneous swellings in endemic regions. High-resolution ultrasonography has helped us in narrowing down our differential diagnosis. There are various differential diagnoses as listed below and how we ruled them out are described below:

1. Lipomas are hyperechoic lesions with no evidence of cystic changes
2. Neurofibromas are hypoechoic lesions adjacent to the nerve, which is proximally and distally visualized
3. Schwannoma is hypoechoic lesions seen eccentric to the nerve.

Fortunately, she responded well to medical treatment with tablet Albendazole 200 mg BD × 14 days and a course of steroids leading to complete resolution of the swelling. There was objective evidence of improvement with reduction in the pain and size of the swelling.

After 3 weeks of conservative treatment, on clinical follow-up, pain and tenderness had completely disappeared and patient was asymptomatic. On follow-up sonography, there was no evidence of phlegmon or cysticercosis in medial aspect of upper thigh. No appearance of new crops of cysticerci was noted.

DISCUSSION

Cysticercosis is an infection caused by the larval form of the tapeworm *Taenia solium*, from the cestode family. It is highly prevalent in India, Africa, China, and South America. However, due to increased travel and a mixture of immigrants, this disease is spreading to non-endemic parts of the world as well. This infection thrives in communities with poor sanitary facilities, overcrowding, poor personal hygiene, and places, where pigs are reared commonly.

Human beings are the definitive hosts and pigs are the intermediate hosts for the parasite *T, solium*. When the human being ingests contaminated water/food which contains the *T. solium* eggs or, when he is already infected with the gravid worm within the intestine (due to consumption of infected pork meat), the regurgitated eggs due to reverse peristalsis release oncopsheres within the small intestine which pierces and penetrates the mucosal wall using hooks and suckers, spread through blood stream to form encysted larvae in various parts of the body. This encysted larva from of the parasite is known as cysticercus cellulosae. As it ages the cyst becomes leaky, producing inflammatory reaction in the tissue surrounding it, and usually, the patient presents with symptoms in this stage.[1] In our case, the patient presented with a painful swelling in the inner aspect of her right thigh.

There are only few reported cases of the muscular cysticercosis diagnosed on USG.

In the muscular form, four types manifestations have been described.[2]

1. Myalgic type which has two subcategories
   a. The hyperechoic structure within the cystic lesion corresponds to the scolex. No inflammatory changes as the living parasite evades immune recognition
   b. Death of the larva causes the membrane to become leaky, causing inflammatory changes in the tissue surrounding it.
2. Abscess-like type: The next stage is when there is very minimal fluid within the partially collapse cysts and scolex is not seen within as it might have escaped from the cyst
3. Calcified cyst: Retracted cysts with calcified capsule and scolex is noted
4. Pseudo hypertrophic type: The cysticercosis cyst containing the scolex is noted within and irregular large collection of exudative fluid within the muscle.

Our case falls under the pseudo hypertrophic type of cysticercosis [Figure 1]. Usually, based on the three most common regions affected in the body, we have neurocysticercosis, ocular, and muscular cysticercosis.[3] The cysts are surrounded by a fibrous capsule except in the eye and ventricles of the brain. The larvae evoke a cellular reaction starting with infiltration of neutrophils, eosinophils, lymphocytes, plasma cells, and, at times, giant cells. This is followed by fibrosis and death of the larva with eventual calcification. The clinical features depend on the site affected.

Now let's discuss about elastography, which is an added advantage to the conventional USG.

Elastography in other words is known as palpation imaging. Over the past two decades, various elasticity imaging approaches have been introduced rampantly by radiologists because when combined with conventional USG techniques, this adds mechanical information of the tissue examined and helps in better diagnosis.

The most popular type of elastography was strain imaging for a long period of time, where higher strain corresponded to softer medium. However, the con was it varied according to the pressure used by the examiner. Hence, it took a rather long period of time to get accustomed to reliable images.

To overcome this limitation, shear wave elastography was introduced which helped in quantification of tissue stiffness. Just like palpation, elastography aims to characterize tissue stiffness. Physical palpation is replaced by point of shear wave quantification (VTQ by Siemens), 2d and 3d shear wave by supersonic mindray has come out with natural touch elastography and Mindray`s unique shear wave STE.

Shear wave elastography of mindray Resona 7 offers two imaging approaches: STE and STQ.[4]

STE technology will provide 2D color imaging of tissue stiffness information and display elastic distribution of the lesion.

The other approach on mindray Resona 7 is STQ which directly performs quantitative measurement on tissue stiffness in the ROI. This is a new approach to display real-time stiffness image of the region of interest, with better penetration and lesser noise. This uses ultrawide beam tracking imaging.

Based on the ultrawide beam tracking imaging platform, STE/STQ can reach a shear wave elastography speed of up to 10 KHz per frame, which allows super-fast detection of all necessary shear wave information in the ROI. Using better focused USG beams, STE/STQ boasts, in addition to an ultra-high frame rate, an excellent penetration capability, which ensures better elasticity images and measurement results.

We have used in this study STQ this tool give us MEAN, MAX, MIN, SD, DEPTH of ROI CENTRE, MEDIAN, IQR, IQR/MED, and AVERAGE of the selected region of interest. Elasticity bar given below easily evaluate the stability of STQ among multiple frames. Hence, we ask the patient to hold their thigh to have maximum stability of the images as possible. The height of each bar represents the mean value of young's modulus of whole ROI in each frame. Elastography has the advantages of real time 2-D shear wave, better penetration, more accurate quantification, lesser acoustic power for longer transducer life, and reduced radiation.

Normal relaxed muscle appears as an inhomogenous mosaic of intermediate or increased stiffness with scattered softer areas, especially at the periphery or near boundaries.

In inflammatory myopathies, USG elastography can show changes in muscle elasticity in correlation with elevated serum markers (increased stiffness due to fibrosis or as reduced stiffness, secondary to fatty infiltration).

The scolex will be harder as compared to the cyst or the lesion. As the elastography hardness increases, the firmness of the tissue increases.

Thinking about other radiological investigations, plain radiographs are not very helpful until the cysts have degenerated and calcify to become radio opaque. On the other hand, Computed tomography is only useful in neurocysticercosis but not much beneficial in the musculoskeletal cysticercosis.

High-resolution USG has become relatively inexpensive and is a readily available and reliable diagnostic modality for the diagnosis of intramuscular cysticercosis. There are many reports, in which cysticercosis had been accurately diagnosed by USG without the requirement of invasive techniques such as fineneedle aspiration cytology and biopsy. This is a huge achievement in the field of radiology.

Looking into the therapeutic options, waitful watching, surgical, or medical management is based on multiple factors, including symptoms and the location, number, stage, and size of cysts. Isolated solitary intramuscular cysticercosis requires no specific treatment unless it is symptomatic. Excision is the best method whenever possible. However, it may be required in case of intramuscular cysticercosis if there is neurovascular compromise due to growth of the cyst. Medical treatment should be considered if the site or number of the lesions makes surgical excision unfeasible. Concomitant intestinal taeniasis which is found in 25% of the cases should be investigated and treated as well. Antiparasitic therapy such as praziquantel and albendazole can be used to medically manage, and corticosteroids can be added to reduce the inflammatory reaction. Medical management can alone to be curative, such as in our patient. Praziquantel (50 mg/kg/day for 3 weeks) is considered the preferred treatment. Even albendazole (10–15 mg/kg/day for 2 weeks) can be effective as well.

Prophylactically, the critical thermal point of cysticercus is 56°C for 5 min; hence, we should not consume undercooked pork. Lifestyle changes, socioeconomic improvement, maintenance of clean personal habits and general sanitary measures, education to people about the disease, and anthelminthic therapy are important in reducing the prevalence of the *T. solium* larval diseases.

For control of cysticercosis, prevention of fecal contamination of soil, proper disposal of sewage, and avoidance of eating raw vegetables grown in polluted soil are useful measures.

Lots of recent publications and researched have shown the potential utility of the use of vaccines in pigs, but its widespread use is not yet a reality.[5]

Although solitary intramuscular cysticercosis is rare, the diagnosis should be kept in mind in patients presenting with an intramuscular or a subcutaneous mass, especially in endemic areas. USG and magnetic resonance imaging are useful non-invasive diagnostic modalities to clinch the diagnosis. Only symptomatic cysts require treatment. Both surgery and medical management have been found to yield good results, and thus, the treatment may be individualized.

CONCLUSION

High-resolution sonography, being non-invasive and non-ionizing, plays an important role in establishing the diagnosis in patients with muscular cysticercosis. Using elastography techniques, like in our case, of shear wave elastography, we can characterize tissue stiffness, complimenting B-mode imaging findings, which confirm the diagnosis of intramuscular cysticercosis. Therefore, we conclude that intramuscular cystic swellings can be diagnosed on high-resolution sonography along with great confidence without any need of FNAC/biopsy leading to easier management of the disease in patient at affordable rates. There is a huge scope in the future to apply elastography in various musculoskeletal studies to confirm B-mode USG findings.

ACKNOWLEDGMENT

Nil.

REFERENCES

1. Singal R, Mittal A, Gupta S, Gupta R, Sahu P, Gupta A. Intramuscular cysticercosis diagnosed on ultrasonography in thigh: A rare case report. N Am J Med Sci 2010;2:162-4.
2. Asrani A, Morani A. Primary sonographic diagnosis of disseminated muscular cysticercosis. J Ultrasound Med 2004;23:1245-8.
3. Vijayaraghavan SB. Sonographic appearances in cysticercosis. J Ultrasound Med 2004;23:423-7.
4. Huang L, Ma M, Du Z, Liu Z, Gong X. Quantitative evaluation of tissue stiffness around lesion by sound touch elastography in the diagnosis of benign and malignant breast lesions. PLoS One 2019;14:e0219943.
5. Meena D, Gupta M, Jain VK, Arya RK. Isolated intramuscular cysticercosis: Clinicopathological features, diagnosis and management-a review. J Clin Orthop Trauma 2016;7(Suppl 2):243-9.

How to cite this article: Jeyakumar A, Gadupudi V, Sai PMV. An Interesting Case of Solitary Human Muscular Cysticercosis with Elastography Findings. Int J Sci Stud 2022;10(9):10-14.

Source of Support: Nil, **Conflicts of Interest:** None declared.