Print ISSN: 2321-6379
Online ISSN: 2321-595X

Case Report

# Giant Cell Tumor of Distal Femur Treated with Resection Arthrodesis and Custom Made Intramedullary Nail Along with Tibia Slide and Fibula Graft: A Case Report and Review of Literature

**Anuj Kumar Lal[1], Niyati Srivastava[2], Sanjay Gupta[3]**

[1]Speciality Registrar, Department of Trauma and Orthopaedics, Ysbyty Gwynedd, Bangor, North Wales, [2]Senior House Officer, Department of Renal medicine, Ysbyty, Gwynedd, Bangor Wales, [3]HOD, Department of Orthopaedic Surgery, SRMSIMS, Bareilly, Uttar Pradesh, India

## Abstract

**Introduction:** Giant cell tumor of the bone has been defined by the World Health Organization as a locally malignant tumor. The surgical treatment varies from a simple intralesional curettage to wide/*en block* resection. The surgical challenge faced is preventing recurrence of the lesion and at the same time providing with a painless functional limb.

**Case Report:** We report a giant cell tumor (GCT) of the distal femur in a 32-year-old female who underwent resection arthrodesis with the help of a custom-made interlocking nail with tibia slide graft and fibula strut graft.

**Discussion:** The aim in surgical treatment of GCT of bone should be to prevent recurrence. Recurrence rate with wide resection has been reported as low as 0–5%. Chances of revision surgery in a young patient with endoprosthetic reconstruction are higher than with arthrodesis.

**Conclusion:** Arthrodesis provides a painless, stable, and functional limb after *en block* resection.

**Key words:** Giant cell tumor, Wide resection, Arthrodesis

## INTRODUCTION

Giant cell tumor (GCT) of the bone is a locally aggressive benign osteolytic tumor which was first described by Cooper and Travers in 1818.[1] The incidence of GCT of bone varies considerably between Western and Asian population, being 3–8% in former group and nearly 20% in the later group.[2] It accounts for 5% of primary bone tumors and 15% of benign bone tumors.[3] GCT is an epiphyseal long bone tumor and has more predilection for distal femur, proximal tibia, and distal radius. It is an osteolytic lesion and histologically shows osteoclast-like giant cells interspersed with vascular stroma.[4] It is seen in age group of 20–40 years and predominantly in males, with a male-to-female ratio of 1.27–1.77:1.[5] GCT was classified clinic-radiologically both by Enneking and later by Campanacci *et al.* These classifications were designed to define the extent of surgery for complete tumor excision.[6] Treatment, thus, includes intralesional curettage, extended curettage with adjuvants and high-speed burr and wide resection. Recurrence rate with wide resection is lower (0–5%) as compared to curettage alone (25–50%).[6] Bone tumors have been treated in the past with resection arthrodesis and have been declined after newer joint preserving options have been available. Arthrodesis was indicated when an extensive resection was required, and joint surfaces could not be preserved, but limb was neurologically intact.[7]

We report a case of a 32-year-old female with obesity who was diagnosed with GCT of the bone and treated with resection arthrodesis with a custom-made intramedullary nail and tibia slide and fibula grafts. The evidence base and clinical details are discussed.[8]

Access this article online

www.ijss-sn.com

Month of Submission : 01-2022
Month of Peer Review : 01-2022
Month of Acceptance : 02-2022
Month of Publishing : 03-2022

**Corresponding Author:** Dr. Anuj Kumar Lal, Department of Trauma and Orthopaedics, Ysbyty Gwynedd, Bangor, North Wales

## CASE PRESENTATION

A 32-year-old female presented to the outpatient clinic with complains of pain and swelling over the left knee. The pain has been present since a year and was controlled with non-steroidal anti-inflammatory medications, but she found it increasingly difficult to walk since 2 months. She had no medical comorbidities; however, she was moderately obese with a BMI of 32. Clinical examination revealed a globular swelling over the distal thigh. There was tenderness on palpation around distal femur and joint line. Overlying skin was normal. Range of motion of the left knee was painful and restricted. There was no neurovascular deficit. Radiographs of her left knee [Figure 1] showed an osteolytic lesion of the left distal femur with cortical break and extension into soft-tissue posteromedially. She also underwent magnetic resonance imaging [Figure 2] which showed the soft-tissue extension. Further, confirmation was made after core needle biopsy. The tumor was graded according to Campanacci Grade as Stage III GCT with radiological and histological evidence. The surgical options, including wide resection and endoprosthetic reconstruction and resection arthrodesis, were considered. The surgical options were discussed in detail with the patient. Although endoprosthetic reconstruction would give a more functional joint, the patient wanted to resume fieldwork in farm which involves heavy physical labor. Hence, taking her BMI and occupation into consideration, the decision was made to proceed with resection arthrodesis. Wide resection of the tumor was performed [Figure 3]. Bone gap was measured to be 10 cm, and tibia graft was calculated as double of the bone gap plus 3 cm to make up for the joint space and prevent limb shortening. Tibia graft was taken along with non-vascular fibula strut graft from the same side. Custom-made interlock nail was introduced through the piriform fossa and extended distally into the tibia and locked with proximal and distal screws. Tibial graft was slided over the defect along with the fibula graft and stabilized with locking plate anterolaterally. Graft was covered with overlying vastus after drain insertion. Post-operative immobilization was obtained with knee immobilizer. Histology of resected specimen showed features suggestive of high-grade GCT. Radiograph of the limb was taken on 2nd post-operative day [Figure 4]. Post-operative period was uneventful, and the patient was advised to remain non-weight-bearing for 3 months. The patient underwent physiotherapy from 1st post-operative day and started mobilizing with help of walker on 2nd post-operative day. Partial weight-bearing was initiated after 12 weeks and full weight-bearing after 6 months. The patient was able to return to work in 8 months from the surgery, she was followed up to 3 years and showed no recurrence or complications.


**Figure 1: Radiograph of the left knee showing lytic bone lesion involving the distal femur with characteristic soap bubble appearance with break in cortical continuity posteromedially**

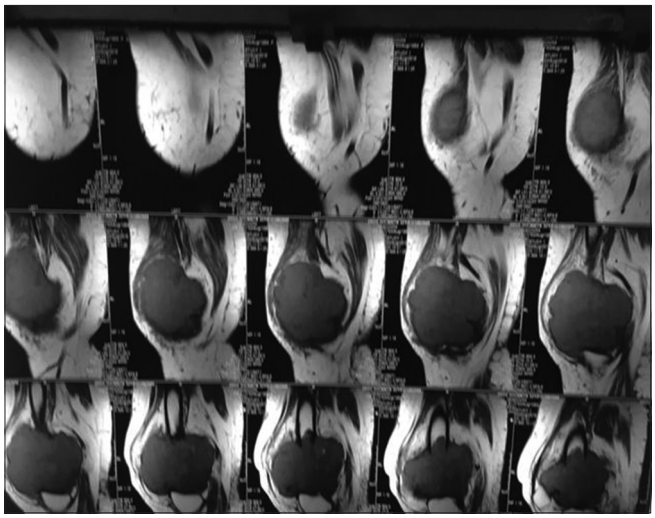

**Figure 2: MRI left distal femur**

## DISCUSSION

Giant cell tumor is an aggressive benign bone tumor with higher incidence in the third decade of life. These tumors have been known to have high local recurrence rates.[4] Klenke *et al*., in a review of 118 GCT patients, concluded that age at diagnosis was the predictor of recurrence rates regardless of status of the lesion and the surgical modality taken to treat it.[3] In another study by Kivioja *et al*., they concluded that age and surgical margins are prognostic factors of local recurrence.[9] According to a large multicentric study on GCT of bone done in China, it was found that GCT around the knee was found more commonly in men. They also found the recurrence rate of GCT to be higher in patients between 20 and 39 years of age and those treated with intralesional curettage.[10] The GCT of the bone is associated with 1–4% benign pulmonary metastases. In spite of GCT being a benign tumor, it can cause significant destruction of bone and

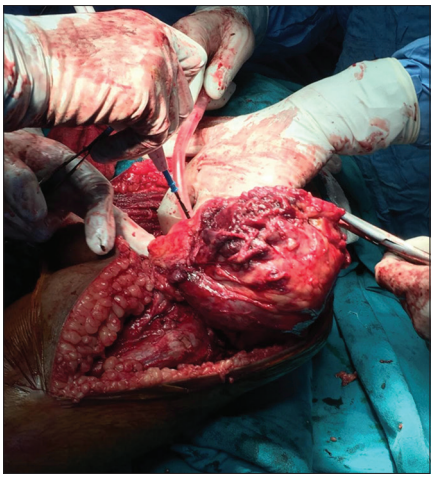

**Figure 3: Intraoperative photograph after *en block* resection of the lesion from distal femur along with muscular attachments**


**Figure 4: Post-operative X-rays showing interlocking nail *in situ* with autologous bone graft reinforced with locking compression plate**

could present as a challenge to surgeons specially in pre-articular areas. The aim of the surgeon is to completely excise the tumor, preserve limb function, and prevent any local recurrence.[11]

Campanacci graded these lesions on the basis of their radiological appearance. Grade III was designated to those lesions which had permeated growth and soft-tissue extension without any reactive bone shells limiting the lesion.[12]

The primary aim while treating a primary bone tumor should always be complete surgical removal of the lesion. Preservation of limb function and planning of reconstructive procedures is secondary and changes should be made according to the demands of tumor excision.[13] Surgical resection is the standard surgical treatment for GCT of bone. Intralesional curettage is favored in cases, where the lesion is benign and is Grade I/II. *En block*/wide resection has been advocated as the modality of treatment, as the recurrence rate is low and the recurrence-free survival rate has been reported between 84% and 100%.[13] Although *en-block* resection provides the best cure for GCT, joint reconstruction poses as a challenge to the surgeon and thus irrespective of the lesion being primary or recurrent , reconstruction of the joint surface is important.[14] This can be achieved with either megaprosthesis joint replacement or biological reconstruction.[15] The ideal reconstruction after an *en block* resection is still a matter of debate. Wide surgical resection is indicated when there is extensive bone destruction, recurrence or when the reconstruction is difficult to do after intralesional curettage.[16] The recurrence rate with wide (*en block*) resection is as low as 0–5%. Prosser *et al*. found that the recurrence rate of the 137 patients who had curettage alone varied with Campanacci grades, being only 7 % in patients of Grades I and II, but 29% in Grade III patients.[6] Chen *et al*. concluded that as knee joint is a weight-bearing joint, the amount of subchondral bone involved by the lesion is a valuable prognostic factor and found that the mean area of articular surface involvement in patients who underwent resection was 68.2%.[17]

Knee arthrodesis in tumor excision is mainly indicated when after resection of tumor joint surface cannot be preserved. Reconstructions by arthrodesis have declined, as a variety of techniques involving expandable endoprosthesis and biological reconstruction by freezing, autoclaving or irradiation, are present to preserve the function of the joint. Endoprosthesis reconstruction incurs high cost, which requires good muscular reconstruction.[18] In a young patient with a good remaining life span, endoprosthesis reconstruction will require multiple surgeries as the implant life will be significantly shorter than the patient's life span.[19] Ahmed *et al*., in his case report, desarthodesed a knee after 40 years of arthrodesis with patient having a functional painless limb for 39 years after arthrodesis for GCT of distal femur.[20] Gitelis *et al*. compared the results of *en bloc* resection of GCT ($n$ = 20) and intralesional excision with adjunctive local insertion of methyl methacrylate or phenol ($n$ = 20). They reported only one recurrence in the intralesional surgery group. There were no recurrences in the patients who had an *en bloc* resection. [21] Tuteja *et al*. showed the advantages of using a dual autologous vascular fibular graft along with knee arthrodesis after resection of GCT and found that they showed good union at recipient site and lesser complications in filling femoral defects. He

concluded that resection arthrodesis with dual fibular graft offers limb reconstruction as an alternative to amputation, providing a stable and functional limb in aggressive and recurrent GCT around the knee joint.[22] Campanacci and Costa reported 92% union rate in 26 patients treated with resection of GCT around the knee and stabilized with long intramedullary nail. They reported infection as the main complication occurring in five of their patients.[23]

In our case, we aimed at giving the patient a stable joint that would allow her to return to her occupation at the earliest. Endoprosthetic replacements require lifestyle modifications as well as prospects of the patient undergoing multiple surgeries are also high. In addition with obesity and high physical labor involved, there are high chances of early wear and revision. We believe that although endoprosthetic replacement is an attractive option, tumor grading, patient's occupation, socioeconomic status, and post-operative expectations that must be considered. Arthrodesis was considered due to the above reasons and has shown to give satisfactory functional outcome in up to 3-year follow-up.

## CONCLUSION

Stage III GCT has higher incidence of recurrence and *en block* resection is advised to prevent recurrence. Resection arthrodesis with intramedullary nail and autologous bone graft provides a painless and functional limb and allows the patient to perform strenuous activities.

## REFERENCES


1. Cooper A, Travers B. Surgical Essays. London: Cox & Son, Longman & Co.; 1818. p. 195.
2. Thomas DM, Skubitz T. Giant-cell tumour of bone. Curr Opin Oncol 2009;21:338-44.
3. Klenke FM, Wenger DE, Inwards CY, Rose PS, Sim FH. Giant cell tumor of bone: Risk factors for recurrence. Clin Orthop Relat Res 2011;469:591-9.
4. Rigollino AV, Fernando TS, Tanaka MH, Souza MM. Giant cell tumor locally advanced around the knee: Treatment and literature review. Rev Bras Ortop 2017;52:473-8.
5. Hu Y, Zhao L, Zhang H, Yu X, Wang Z, Ye Z, *et al*. Sex differences in the recurrence rate and risk factors for primary giant cell tumors around the knee in China. Sci Rep 2016;6:28173.
6. Prosser G, Baloch K, Tillman R, Carter S, Grimer R. Does Curettage without adjuvant therapy provide low recurrence rates in giant-cell tumors of bone? Clin Orthop Relat Res 2005;435:211–8.
7. Wang H, Wan N, Hu Y. Giant cell tumor of bone: A new evaluating system is necessary. Int Orthop 2012;36:2521-7.
8. Conway J, Mont M, Bezwada H. Current concepts review: Arthrodesis of the knee. J Bone Joint Surg Am 2004;86:835-48.
9. Kivioja AH, Blomqvist C, Hietaniemi K, Trovik C, Walloe A, Bauer HC, *et al*. Cement is recommended in intralesional surgery of giant cell tumors: A scandinavian sarcoma group study of 294 patients followed for a median time of 5 years. Acta Orthop 2008;79:86-93.
10. Hu P, Zhao L, Zhang H, Yu X, Wang Z, Ye Z, *et al*. Recurrence rates and risk factors for primary giant cell tumors around the knee: A multicentre retrospective study in China. Sci Rep 2016;6:36332.
11. Jamshidi K, Karimi A, Mirzaei A. Epidemiologic characteristics, clinical behaviour and outcome of the giant cell tumor of the bone: A restrospective single-center study. Arch Bone Jt Surg 2019;7:538-44.
12. Campanacci M, Capanna R, Fabbri N, Bettelli G. Curettage of giant cell tumor of bone. Reconstruction with subchondral grafts and cement. Chir Organi Mov 1990;75 Suppl 1:212-3.
13. Kocher MS, Gebhardt MC, Mankin HJ. Reconstruction of the distal aspect of the radius with use of an osteoarticular allograft after excision of a skeletal tumor. J Bone Joint Surg Am 1998;80:407-19.
14. Lausten GS, Jensen PK, Schiodt T, Lund B. Local recurrences in giant cell tumour of bone. Long-term follow up of 31 cases. Int Orthop 1996;20:172-6.
15. Saini R, Bali K, Bachhal V, Mootha AK, Dhillon MS, *et al*. En bloc excision and autogenous fibular reconstruction for aggressive giant cell tumor of distal radius: A report of 12 cases and review of literature. J Orthop Surg Res 2011;6:14.
16. van der Heijden L, Dijkstra PD, van de Sande MA, Kroep JR, Nout RA, *et al*. The clinical approach toward giant cell tumor of bone. Oncologist 2014;19:550-61.
17. Chen TH, Su YP, Chen WM. Giant cell tumors of the knee: Sub-chondral bone integrity affects the outcome. Int Orthop 2005;29:30-4.
18. Xu SF, Yu XC, Xu M, Fu Z. Inactivated autograft-prosthesis composite have a role for Grade III giant cell tumor of bone around the knee. BMC Musculoskelet Disord 2013 14:319.
19. Shalaby S, Shalaby H, Bassiony A. Limb salvage for osteosarcoma of the distal tibia with resection arthrodesis, autogenous fibular graft and Ilizarov external fixator. J Bone Joint Surg Br 2006;88:1642-6.
20. Abdelaal AH, Yamamoto N, Hayashi K. Ten-year follow-up of desarthrodesis of the knee joint 41 years after original arthrodesis for a bone tumor. Case Rep Orthop 2015;2015:308127.
21. Gitelis S, Mallin BA, Piasecki P, Turner F. Intralesional excision compared with en bloc resection for giant-cell tumors of bone. J Bone Joint Surg Am 1993;75:1648-55
22. Tuteja S, Kale S, Chaudhari P, Dhar SB. Recurrent GCT of distal femur treated with resection arthrodesis with non-vascularized bilateral fibular graft and a custom-made interlock nail.J Orthop Case Rep 2016;6:16-8.
23. Campanacci M, Costa P. Autogenous bone grafts and arthrodesis in twenty-six cases. Clin Ortop 1979;61.


**How to cite this article:** Lal AK, Srivastava N, Gupta S. Giant Cell Tumor of Distal Femur Treated with Resection Arthrodesis and Custom Made Intramedullary Nail Along with Tibia Slide and Fibula Graft: A Case Report and Review of Literature. Int J Sci Stud 2022;9(12):7-10.

**Source of Support:** Nil, **Conflicts of Interest:** None declared.