Print ISSN: 2321-6379
Online ISSN: 2321-595X
DOI: 10.17354/ijss/2018/330

Original Article

Histopathological Study of Neoplastic and Non-neoplastic Lesions of the Ovary in Sanjay Gandhi Memorial Hospital/Gandhi Memorial Hospital, Rewa, Madhya Pradesh, India

Ajay Kumar Gupta[1], Sanghmitra Singh[2], Uday Raj Singh[3]

[1] PG Student, Department of Pathology, Shyam Shah Medical College, Rewa, Madhya Pradesh, India, [2] Assistant Professor, Department of Obstetrics and Gynaecology, Shyam Shah Medical College, Rewa, Madhya Pradesh, India, [3] Professor, Department of Pathology, Shyam Shah Medical College, Rewa Madhya Pradesh, India

Abstract

Introduction: Tumors of the ovary are common forms of neoplasms in women. In the developed world, ovarian carcinoma is the fourth or fifth most common cause of death from all cancers in women, and 7% of patients with these tumors present with advanced stage disease. Ovarian cancers account for 6% of all cancers in females. 80% are benign and these occur mostly in young women between the ages of 20 and 45 years. Malignant tumors are common in older women between the ages of 40 and 65 years.

Aims: This study aims to the incidence of different histological types of ovarian lesions, histomorphological features, categorize ovarian lesions into neoplastic and non-neoplastic group, and correlate incidence of neoplastic and non-neoplastic lesion with particular age group and parity.

Materials and Methods: The study was conducted on approximate 50 patients of ovaries received these include surgically resected ovaries, either as part of total abdominal hysterectomy with bilateral salpingo-oophorectomy or as a clinically diagnosed ovarian lesions from Shyam Shah Medical College and Sanjay Gandhi Memorial Hospital, Rewa, Madhya Pradesh, from the duration of April 2017 to march 2018.

Results: The total number of ovarian lesions studied during the study period was 50 cases, among them, 15 (30%) cases were non-neoplastic and remaining 35 (70%) cases were neoplastic. The most common non-neoplastic lesion seen was follicular cyst 6 (40%) cases followed by corpus luteal cyst 4 (26.66%) cases. Among the 35 neoplastic ovarian lesions, 26 (74.28%) cases were benign, 1 (2.85%) case was at borderline, and 8 (22.85%) cases were malignant. In benign ovarian neoplasm, most commonly lesion were serous cystadenoma 17 (48.57%) cases followed by benign cystic teratoma 4 (11.42%) cases. In malignant cases, the most common lesion were serous cystadenocarcinoma 3 (8.57%) cases followed by mucinous cystadenocarcinoma 2 (5.71%) cases. Overall, ovarian lesions were more common in age group of 20–39 years followed by 40–59 years. The youngest patient was 9 years old and the oldest patient was 69 years old. The malignant tumors were more common in nulliparous women (33.33%) than benign neoplasm (15.38%). Of total 35 neoplastic ovarian lesions, 32 (91.42%) cases were unilateral and 3 (8.57%) cases were bilateral.

Conclusion: The histological type of ovarian tumor correlates with the prognosis of the tumor. Serum CA-125 screening along with annual pelvic examination after 35 years of age in women along with transvaginal ultrasonography can be used as regular screening methods to evaluate early detection of ovarian cancer. An accurate histopathological diagnosis combines with clinical staging will help in rendering prompt and appropriate treatment to the patients.

Key word: Histopathology, Incidence, Neoplastic ovarian lesions, Non-neoplastic lesions, Ovarian tumor

Access this article online

www.ijss-sn.com

Month of Submission : 00-0000
Month of Peer Review : 00-0000
Month of Acceptance : 00-0000
Month of Publishing : 00-0000

AQ1

INTRODUCTION

Tumors of the ovary are common forms of neoplasms in women.[1] In the developed world, ovarian carcinoma is the fourth or fifth most common cause of death from all cancers in women, and the primary cause of death from gynecological malignancies; 7% of patients with these

Corresponding Author: Ajay Kumar Gupta, Department of Pathology, Shyam Shah Medical College, Rewa, Madhya Pradesh – 486001, India. Phone: +91-8770298552. E-mail: dr.gupta.ajay17@gmail.com

tumors present with advanced stage disease.[2] Ovarian tumor and non-neoplastic lesions present a great challenge to gynecological oncologist. Certain non-neoplastic lesions of the ovary frequently form a pelvic mass and potentially mimic an ovarian neoplasm.

The most important clinical feature in ovarian tumor is the age of the patient. One of the eight ovarian tumors in patients <45 years of age is malignant; by contrast, in older women, the proportion is one to three. The single most common ovarian tumor, the mature cystic teratoma (dermoid cyst) is encountered at all ages, like most tumors in the sex cord-stromal category.[3] Ovarian cancers account for 6% of all cancers in females. 80% are benign and these occur mostly in young women between the ages of 20 and 45 years. Malignant tumors are common in older women between the ages of 40–65 years.[4] Classification of ovarian tumors is primarily morphological. It is based on that the ovary containing four major types of tissue: [4] Surface, coelomic or germinal epithelium, germ cells, sex cord and ovarian stroma, specialized, and non-specific.

The treatment for ovarian neoplasms depends on the grade and stage of the tumor at presentation. Treatment modalities include cystectomy or oophorectomy, salpingo-oophorectomy, hysterectomy, chemotherapy, and/or radiotherapy.[5] This study shows the patterns of ovarian lesions with regard to age, parity, origin, risk factors, clinical presentation, and histopathological classification.

Aims and Objectives

This study aims to the incidence of different histological types of ovarian lesions, histomorphological features, categorize ovarian lesions into neoplastic and non-neoplastic group, and correlate incidence of neoplastic and non-neoplastic lesion with particular age group and parity.

MATERIALS AND METHODS

The study was conducted on approximate 50 patients of ovaries received these include surgically resected ovaries, either as part of total abdominal hysterectomy with bilateral salpingo-oophorectomy or as a clinically diagnosed ovarian lesions from Shyam Shah Medical College and Sanjay Gandhi Memorial Hospital, Rewa, Madhya Pradesh, from the duration of April 2017 to march 2018. All sections were routinely processed under standardized conditions for paraffin embedding and then cut into 5 μ or thinner as needed and stained with hematoxylin and eosin (H and E) stain using standard procedure. For classification of ovarian lesion, the World Health Organization (WHO) was being used. Statistical tools, incidence, and percentage were calculated.

Inclusion Criteria

All the specimens of ovarian lesion (neoplastic and non-neoplastic) sent to the Department of Pathology, shyam shah medical college, rewa, were included in the study. Hysterectomy specimen with ovarian lesion was also be included in the study.

Exclusion Criteria

Decomposed and poorly and improperly fixed specimens.

All the specimens received at the Department of Pathology, Shyam Shah Medical College, Rewa, were procedure fixation → grossing → dehydration → wax impregnation → blocking section cutting and followed by H and E section.

Data collection of the histopathological slides of patients included in the study was retrieved and reviewed by me and experienced histopathologist to confirm ovarian neoplasm diagnosis, determine the histopathological type of the tumor, and classify the ON using the WHO classification. Data analysis for quantitative data mean, standard deviation, etc., was obtained and for qualitative data, proportion will be obtained and analyzed using statistical software or MS Excel.

RESULTS

The present study of 50 cases of the ovarian lesions, 35 cases were neoplastic. The neoplastic lesion comprised 26/35 (74.28%) benign, 1/35 (2.85%) borderline, and 8/35 (22.85%) malignant tumors (Table 1).

Table 2 shows that in non-neoplastic lesions, follicular cyst was the most common lesion 6/15 (40%), followed by corpus luteal cyst 4/15 (26.66%), hemorrhagic cyst (20%), endometriosis (6.66%), and inclusion cyst (6.66%) (Table 2).

Table 1: Distribution of benign, borderline, and malignant neoplasm

Ovarian neoplasm	Number of cases (%)
Benign	26 (74.28)
Borderline	01 (2.85)
Malignant	08 (22.85)
Total	35 (100)

Table 2: Distribution of various types of the non-neoplastic ovarian lesions

Non-neoplastic ovarian lesion	Number of cases (%)
Follicular cyst	6 (40.0)
Corpus luteal cyst	4 (26.66)
Hemorrhagic cyst	3 (20.00)
Inclusion cyst	1 (6.66)
Endometriosis	1 (6.66)
Total	15 (100.0)

Table 3 shows that neoplastic tumors were divided into four groups, namely, surface epithelial tumors, germ cell tumors, sex cord-stromal tumors, and metastatic tumor. Surface epithelial tumors were maximum in number 26/35 (74.28%), followed by germ cell tumors 5/35 (14.28), sex cord-stromal tumors 3/35 (8.57%), and metastatic tumor 1/35 (2.85%).

Table 4 shows that in non-neoplastic lesions, the most common histopathological pattern was follicular cyst 6/15 (40%), followed by corpus luteal cyst 4/15 (26.66%), hemorrhagic cyst 3/15 (20%), inclusion cyst 1/15 (6.6%), and endometriosis 1/15 (6.6%).

Tables 5 and 6 show that in neoplastic lesion, the most common histological class is surface epithelial tumors 26/35 (74.28%) followed by germ cell tumors 5/35 (14.28%). Among all the benign lesions (n = 26), serous cystadenoma is the most common 17/26 (65.38%) while the benign cystic teratoma (dermoid cyst) is the second most common 4/26 (15.38%). On the other hand, among all the malignant lesions (n = 8), serous cystadenocarcinoma is the most common 3/8 (37.50%) followed by mucinous cystadenocarcinoma 2/8 (25.00%).

In germ cell tumor, the most common benign tumor was dermoid cyst and most common malignant tumor was dysgerminoma. In sex cord-stromal, the most common benign tumor was fibroma and most common malignant tumor was granulosa cell tumor. Under metastatic group, one case of Krukenberg tumor comprising 2.85% of all ovarian tumor was reported.

Table 7 shows that non-neoplastic lesions were common in parity 2 and parity 4 patients.

Table 3: Distribution of various types of the neoplastic ovarian lesions

Classes of ovarian tumor	Number of cases (%)
Surface epithelial-stromal tumor	26 (74.28)
Germ cell tumor	05 (14.28)
Sex cord-stromal tumor	03 (8.57)
Metastatic tumor	01 (2.85)
Total	35 (100.0)

Table 4: Histopathological patterns of the non-neoplastic lesions of ovary

Histopathological patterns	Number of cases (%)
Follicular cyst	6 (40.0)
Corpus luteal cyst	4 (26.66)
Hemorrhagic cyst	3 (20.0)
Inclusion cyst	1 (6.6)
Endometriosis	1 (6.6)
Total	15 (100.0)

In neoplastic lesions, benign lesions were common in parity 2 and parity 3 followed by nulliparous patients.

Borderline neoplasm was common in nulliparous patient.

Malignant neoplasm was most common in nulliparous patients followed by parity 2 patients.

In the present study, it was observed that malignant tumors were more common in nulliparous women (33.33%) than benign neoplasm (15.38%). Figure-3 in neoplastic lesions of ovary most common clinical presentation was lump in abdomen 19/35 (54.28%) followed by pain in abdomen 12/35 (34.28%), GIT complaints 2/35 (5.71%), loss of weight/appetite 1/35 (2.85) and ascites 1/35 (2.85%).

Non-neoplastic Lesions of Ovary

- Follicular cyst - six cases of follicular cyst were studied. Microscopically, the cyst wall of all cases was lined by outer layer of thick theca interna cells. A single inner layer of granulosa cells were resting on a thick theca layer.
- Corpus luteal cyst - four cases of luteal cyst were studied. Microscopically, the cyst wall is composed of an inner connective tissue layer, a middle layer of large luteinized granulosa cells, and an outer layer of small luteinized theca interna cells.
- Hemorrhagic cyst - three cases of hemorrhagic cysts were studied. Cyst filled with hemorrhagic material and lined by single layer of cells.
- Inclusion cyst - one case of inclusion cyst was studied. Cyst being formed through invagination of the surface epithelium. Microscopically, they were lined by columnar cells.
- Endometriosis - one case of endometriosis was studied. Microscopically, they were composed of endometrial

Table 5: Histopathological patterns of the neoplastic lesions of ovary

Histopathological patterns	Number of cases (%)
Surface epithelial-stromal tumor	26 (74.28)
A Serous tumor	
Serous cystadenoma	17 (48.57)
Borderline serous cystadenoma	1 (2.85)
Serous cystadenocarcinoma	3 (8.57)
B Mucinous tumor	
Mucinous cystadenoma	3 (8.57)
Mucinous cystadenocarcinoma	2 (5.71)
Germ cell tumor	5 (14.28)
Benign cystic teratoma	4 (11.42)
Dysgerminoma	1 (2.85)
Sex cord-stromal tumor	3 (8.57)
Granulosa cell tumor	1 (2.85)
Fibroma	2 (5.71
Other	1 (2.85)
Metastatic tumor	1 (2.85)

Table 6: Frequency of different classes of the neoplastic ovarian tumor (*n*=35)

Histological classes of ovarian tumors	Benign tumors (*n*=26)	Borderline tumors (*n*=1)	Malignant tumors (*n*=8)	Total (%)
Surface epithelial tumor	Serous cystadenoma (17) mucinous cystadenoma (03)	Borderline serous cystadenoma (01)	Serous cystadenocarcinoma (03) mucinous cyst adenocarcinoma (02)	26 (74.28)
Germ cell tumor	Benign cystic teratoma (04)	-	Dysgerminoma (01)	05 (14.28)
Sex cord-stromal tumor	Fibroma (02)	-	Granulosa cell tumor (01)	03 (8.57)
Metastatic tumor	-	-	Krukenberg tumor (01)	01 (2.85)
Total	26	01	08	35 (100)

Table 7: Distribution of ovarian masses in marital status and parity of patients with both non-neoplastic and neoplastic ovarian masses

Marital status and parity	Non-neoplastic	Benign neoplasm	Borderline neoplasm	Malignant neoplasm	Total
	n (%)	*n* (%)	*n* (%)	*n* (%)	*n* (%)
Unmarried	1 (6.66)	1 (3.84)	-	-	2 (4.0)
Nulliparous	-	4 (15.38)	1 (100.0)	3 (37.50)	8 (16.0)
Parity 1	3 (20.1)	1 (3.84)	-	1 (12.50)	5 (10.0)
Parity 2	4 (26.66)	9 (34.61)	-	2 (25.00)	15 (30.0)
Parity 3	3 (20.0)	5 (19.23)	-	1 (12.50)	9 (18.0)
Parity 4	4 (26.66)	3 (11.53)	-	1 (12.50)	8 (16.0)
Parity 5 and above	-	3 (11.53)	-	-	3 (6.0)
Total	15 (100.0)	26 (100.0)	1 (100.0)	8 (100.0)	50 (100.0)

glands, endometrial stroma, and accumulation of hemosiderin-laden macrophages and hemorrhagic foci also seen.

Neoplastic lesions of Ovary

- Serous cystadenoma - 17 cases of serous cystadenoma were studied. Gross findings - outer surface of all the cases was showing dilated veins. On cut, they were filled with serous fluid. Wall was variably thickened of all cases.
- Microscopically, the cyst was lined by single layer of columnar epithelium. In some cases, cyst was lined by single layer of flattened/cuboidal epithelium.
- Serous papillary cystadenoma - one case also reveals stromal papillae with single layer of columnar epithelium.
- Borderline serous cystadenoma - one case was studied. Microscopically, they were showing cyst wall lined by columnar epithelium. Epithelium was showing stratification (4–5 layers) and mild nuclear atypia and minimum mitotic activity. No stromal invasion was seen.
- Serous cystadenocarcinoma - three cases were studied. Microscopically, they were showing marked nuclear atypia, including pleomorphism, atypical mitotic figures, and multinucleation. They were also showing epithelial stratification, complex papillary architecture, branching papillary fronds, and destructive stromal invasion.
- Mucinous cystadenoma - three cases were studied. Microscopically, the cyst was lined by single layer of mucin filled columnar epithelial cells with basally located nuclei. Stromal element minimal between cyst wall.

Mucinous cystadenocarcinoma - two cases were studied.

- Microscopically, they were showing sheets, papillae, and trabeculae of tumors cells having round to oval pleomorphic nuclei, vesicular chromatin, and scanty amount of eosinophilic cytoplasm. Tumor cells embedded in mucinous background. In between tumor cells, there are bands of fibrocollagenous tissue separated by tumor cells in lobules.

Benign cystic teratoma - four cases were studied.

- Microscopically, they were showing areas of hemorrhage along with islands of sebaceous glands, shafts of hair follicles, and areas of chondroid differentiation.
- One case was showing sheets and nests of endoderm, mesoderm, and ectoderm mainly composed of thyroid follicles, respiratory epithelium, cartilage, neuroepithelium, shafts of hair follicles, and sebaceous glands with focal areas of squamous differentiation and keratin pearl formation.

Dysgerminoma - one case was studied.

- Microscopically, section was showing large areas of hemorrhage with distortion of architecture. However,

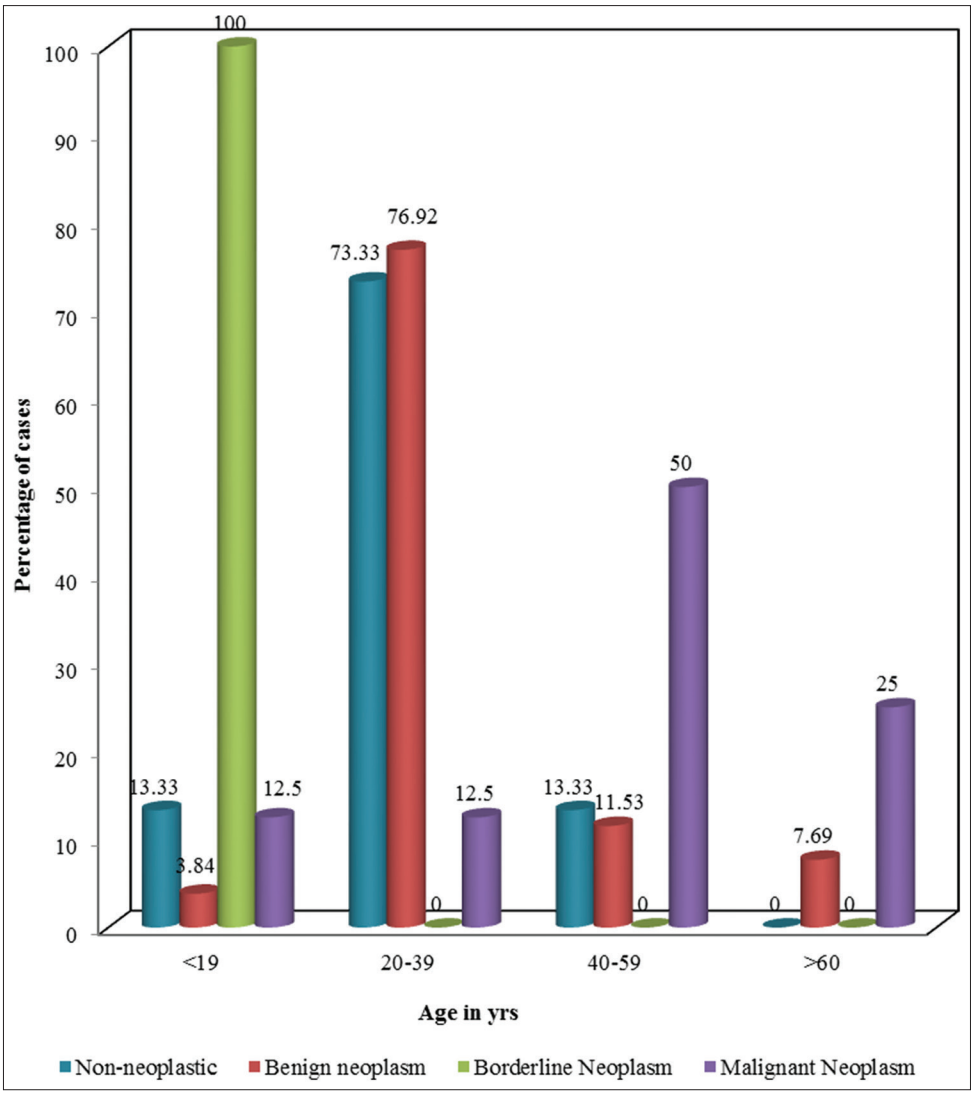

Figure 1: Ovarian masses in various age groups of patients with both non-neoplastic and neoplastic ovarian masses

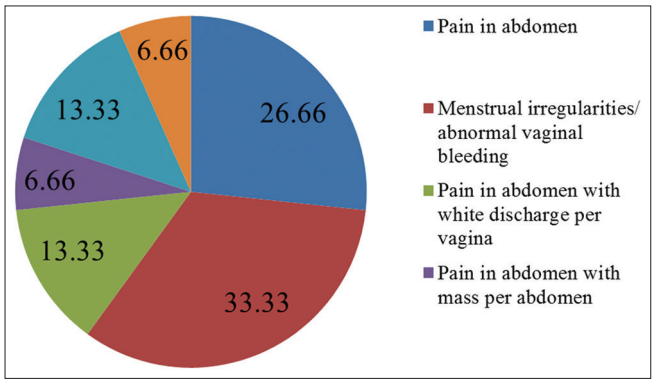

Figure 2: Clinical presentation of non-neoplastic cases

areas reveal few round cells having clear to eosinophilic cytoplasm with round or flattened nuclei. Occasional syncytiotrophoblastic cells are also seen.

Fibroma - two cases were studied.

- Microscopically, they were composed of spindle-shaped cells with uniform, bland nuclei, and scanty cytoplasm. The cells were arranged in fascicles or a storiform pattern.

Granulosa cell tumor - one case was studied.

- Microscopically, section was showing solid sheets of tumor cell having polygonal enlarged pleomorphic, hyperchromatic nuclei with scanty cytoplasm, and Call-Exner bodies. At few places, mitotic figures were also evident. Section was also showing areas of necrotic material and hemorrhage.

Metastatic tumor (Krukenberg tumor) - one case was studied

- Microscopically, section was showing highly fibrous stroma diffusely infiltrated signet ring cells containing abundant mucin.

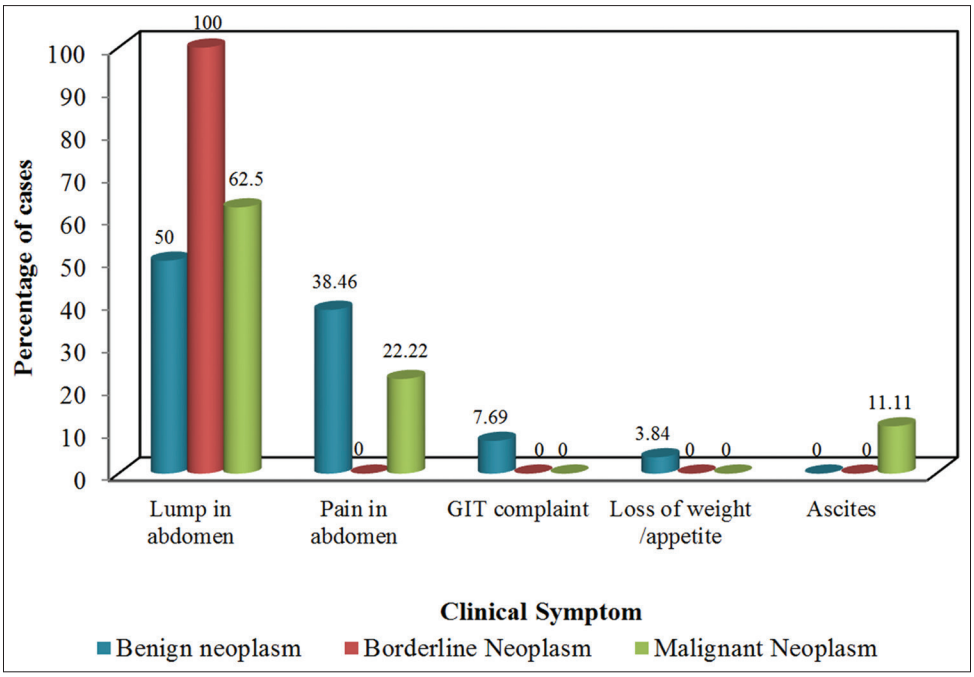

Figure 3: Clinical presentation in neoplastic ovarian masses

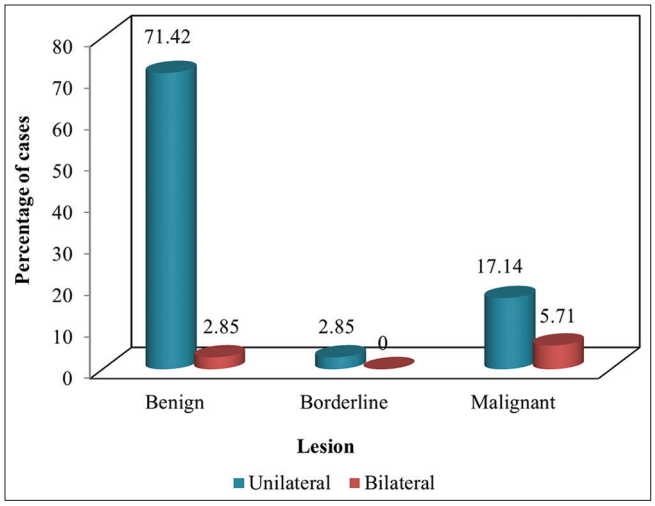

Figure 4: Laterality of ovarian neoplastic lesions

DISCUSSION

Ovarian cancer is the second leading cause of mortality among all gynecological cancers.[6] Due to similar clinical presentations, there is confusion in the diagnosis of non-neoplastic and neoplastic lesions of ovary although it is diagnosed as a mass or cystic lesion on ultrasonography (USG) and, hence, removed prophylactically in routine oophorectomies and hysterectomies.[7] In the current study, 50 ovarian lesions of non-neoplastic and neoplastic origins were evaluated to find out incidence, age, parity, marital status, clinical, and histopathological features. Kreuzer *et al.*[8] reported 82 (40.39%) non-neoplastic lesions of 203 ovarian lesions and Martínez-Onsurbe *et al.*[9] reported 55 (41.67%) non-neoplastic lesions of 132 ovarian lesions. Incidence reported in our study regarding non-neoplastic lesions was lower and concurring with the above studies. The non-neoplastic lesions such as follicular or corpus luteum cysts are the commonly encountered conditions.[10] Figure -1 In neoplastic lesions benign tumours were more common in age group of 20-39 year, borderline tumours was more common in age group of <19 year while malignant tumours were more common in age group of 40-59 years. In the current study, 14 cystic lesions were reported of which follicular 6 (42.85%), corpus luteum 4 (28.57%), three hemorrhagic cyst, and one inclusion cyst. Incidence of these cysts was accordance with to Kreuzer *et al.*[8] (55% follicular cyst and 45% corpus luteal cyst) and Martínez-Onsurbe *et al.*[9] (55% follicular cyst and 45% corpus luteal cyst). Gupta *et al.*[11] reported follicular and corpus luteal cyst (80.2%). In the present study, the incidence was 93.32%, which was higher than this study. Endometriosis is common condition found in women of reproductive age. The most common location of endometriosis is the ovary and posterior cul-de-sac.[12] In our study, one case (6.66%) was reported. This finding was higher than to Gupta *et al.*[11] (2.9%), Carey and Kirk,[13] and Clement *et al.*[14] Al-Fozan and Tulandi[12] in a study conducted for 6 years reported 340 lesions, of which 155 (45.59%) were ovarian endometriosis. In clinically suspected ovarian pathology cases, the most common clinical symptoms were menstrual irregularities/abnormal vaginal bleeding in 5 cases (33.33%), pain in abdomen in 4 cases (26.66%), pain in abdomen with white discharge per vagina in 2 cases (13.33%), and mass per abdomen only

in 2 cases Figure - 2 (13.33%). These findings were similar to van Winter *et al.*[15] study.

- In the present study, 35 neoplastic lesions were diagnosed. The most common were benign tumors 26 cases (74.28%) followed by malignant tumor 8 cases (22.85%) and borderline malignancy 1 case (2.85%) (Table 1).
- In the present study, maximum numbers of cases were in the 3rd–4th decade of life. The present study is in concordance with Pilli *et al.*[16] and Ramachandra *et al.*[17] where the incidence of ovarian neoplastic lesions was more common in 20–39 years of age group. Tushar *et al.*[18] reported high incidence of ovarian tumors in 40–59 years age group.
- There is inverse relationship between ovarian cancer risk and parity. Parous women are at significantly lower risk than nulliparous women. In our study, the incidence of nulliparity (16%) is comparable with Misra *et al.* (16.00%) and Madan *et al.* (14.54%).[19-21]
- Based on histomorphological features, the incidence of surface epithelial tumors was most common (74.28%), followed by germ cell tumors (14.28%), sex cord-stromal tumors (8.57%), and metastatic (2.85%). Similar observations were seen in other studies (Table 3).
- In benign and malignant ovarian neoplasm, lump in abdomen was the most common complaint, followed pain in abdomen, gastrointestinal disturbances with loss of weigh/appetite, and ascites. These findings were in accordance with other studies.
- The present study is concordant with studies by Gupta *et al.*[22] and Misra *et al.*[23] and with Nucci *et al.*[5] which showed high incidence of malignant tumor having more number of tumors with solid and mixed consistency. Majority of the benign lesions (68.57%) in the present study were cystic in consistency. Moreover, majority of malignant lesions (14.28%) were having mixed consistency. This result is concordant with studies by Gupta *et al.*[21] and Misra *et al.*[23]
- In the present study, of total 35 neoplastic ovarian lesions, 32 cases were unilateral and three cases were bilateral. The present study is concordant with studies by Goldzieher *et al.* [24] Mushtaq *et al.*[25] and Couto *et al.*[26] Tushar *et al.*[18] reported more number of bilateral tumors compared to the present study. Most of the benign tumors (71.42%) were unilateral and most of malignant tumors (17.14%) were also unilateral tumors. This result is concordant with studies by Misra *et al.*[23] and Prabhakar *et al.*[27]
- Ovarian cancers are called as "silent killer" as in most of the primary ovarian tumor, they remain asymptomatic until the advanced stage Figure 4[28]. Out of total 35 neoplatic ovarian lesions, 32 cases were unilateral and 3 cases were bilateral.

CONCLUSION

Effective therapeutic management of ovarian malignant tumors continues to be a challenge to the oncologist. An accurate histopathological diagnosis combines with clinical staging will help in rendering prompt and appropriate treatment to the patients.

The histological type of ovarian tumor correlates with the prognosis of the tumor. Serum CA-125 screening along with annual pelvic examination after 35 years of age in women along with transvaginal USG can be used as regular screening methods to evaluate early detection of ovarian cancer.

RECOMMENDATIONS

- Further, in-depth studies are highly recommended to be carried out for more evaluation of risk factors and to find out the causes for the high rate of the disease in this country. For unnecessary removal of the ovary, frozen section is recommended.
- Screening policy for ovarian cancer should be established for early detections.
- Improvement of the cancer reporting and registration. Detailed histopathological reporting, grading and staging.

REFERENCES

1. Crum PC, Kumar V, Abbas KA, Fousto N. The Female Genital Tract: Ovarian Tumour in Pathological Basis of Diseases. In: Robbin C, Cotran S, editor. 7th ed. China: Elsevier Saunders; 2005. p. 1092-104.
2. Al-nafussi A. Ovarian epithelial tumors common problems in diagnosis. Curr Diagn Pathol 2004;10:473-99.
3. Clement EP, Young HR. Ovarian surface epithelial-stromal tumors. In: Sternberg Diagnostic Surgical Pathology. 5th ed. China: Lippincott William, and Wilkins; 2010. p. 2278-305.
4. Rosai J. Female reproductive system, classification of ovarian tumours. In: Rosai and Ackerman Surgical Pathology. 9th ed. China: Elsevier; 2004. p. 1659-709.
5. Nucci RM, Oliva E. Surface Epithetical Stromal Tumour of the Ovary: Gynecologicopathology. 1st ed. China: Elsevier Churchill Livingstone; 2009. p. 393-607.
6. Modugno F. Ovarian cancer and polymorphisms in the androgen and progesterone receptor genes: A huge review. Am J Epidemiol 2004;159:319-35.
7. Kurman RJ, Norris HJ. Malignant germ cell tumours of the ovary. Hum Pathol 1977;8:551-64.
8. Kreuzer GF, Paradowski T, Wurche KD, Flenker H. Neoplastic or nonneoplastic ovarian cyst? The role of cytology. Acta Cytol 1995;39:882-6.
9. Martínez-Onsurbe P, Villaespesa AR, Anquela JM, Ruiz PL. Aspiration cytology of 147 adnexal cysts with histologic correlation. Acta Cytol 2001;45:941-7.
10. Malaviya AK. Non neoplastic cysts of ovary-unusual presentations. Indian J Pathol Microbiol 2001;44:211-45.
11. Gupta N, Bisht D, Agarwal AK, Sharma VK. Retrospective and prospective study of ovarian tumours and tumour-like lesions. Indian J Pathol Microbiol 2007;50:525-7.
12. Al-Fozan H, Tulandi T. Left lateral predisposition of endometriosis and

endometrioma. Obstet Gynecol 2003;101:164-6.
13. Carey M, Kirk ME. Necrotic pseudoxanthomatous nodules of the omentum and peritoneum: A peculiar reaction to endometriotic cyst contents. Obstet Gynecol 1993;82:650-2.
14. Clement PB, Young RH, Scully RE. Necrotic pseudoxanthomatous nodules of ovary and peritoneum in endometriosis. Am J Surg Pathol 1988;12:390-7.
15. van Winter JT, Simmons PS, Podratz KC. Surgically treated adnexal masses in infancy, childhood, and adolescence. Am J Obstet Gynecol 1994;170:1780-6.
16. Pilli GS, Suneeta KP, Dhaded AV, Yenni VV. Ovarian tumours: A study of 282 cases. J Indian Med Assoc 2002;100:420, 423-4, 447.
17. Ramachandra G, Harilal KR, Chinnamma K, Thangavelu H. Ovarian neoplasms-a study of 903 cases. J Obstet Gynecol India 1972;22:309-315.
18. Tushar K, Asanranthi K, Mohapatra PC. Intraoperative cytology of ovarian tumours. J Obstet Gynecol India 2005;55:345-9.
19. Madan A, Tyagi SP, Mohsin S. Incidence of ovarian tumours at Aligarh with particular reference to histopathological typing. J Obstet Gynecol India 1978;8:827-32.
20. Risch HA, Marrett LD, Howe GR. Parity, contraception, infertility, and the risk of epithelial ovarian cancer. Am J Epidemiol 1994;140:585-97.
21. Misra RK, Sharma SP, Gupta U, Gaur R, Mishra SD. Pattern of ovarian neoplasm in eastern UP. J Obstet Gynecol India 1991;30:242-6.
22. Gupta SC, Singh PA, Mehrotra TN, Agarwal R. Testicular granulosa cell tumor, adult type. Indian J Pathol Microbiol 1986;29:354-62.
23. Misra RK, Sharma SP, Gupta U, Gaur R, Misra SD. Pattern of ovarian neoplasm in eastern U.P. J Obstet Gynaecol 1990;41:242-6.
24. Goldzieher JW, Green JA. The polycystic ovary. I. Clinical and histologic features. J Clin Endocrinol Metab 1962;22:325-38.
25. Mushtaq M. Percutaneous ultrasound guided aspiration of ovarian cyst. J Surg Pak 2001;6:10-1.
26. Couto F, Nadkarni NS, Rebello MJ. Ovarian tumours in goa-a clinicopathological study. J Obstet Gynaecol India 1993;43:408-12.
27. Prabhakar BR, Maingi K. Ovarian tumours-prevalence in Punjab. Indian J Pathol Microbiol 1989;32:276-81.
28. Berek JS, Natarajan S. Ovarian and fallopian tube cancer. In: Berek JS, editor. Berek and Novak's Gynecology. 14th ed. New Delhi: Wolters Kluwer Health (India) Private Limited; 2007. p. 1457-547.

How to cite this article: Gupta AK, Singh S, Singh UR. Histopathological Study of Neoplastic and Non-neoplastic Lesions of the Ovary in Sanjay Gandhi Memorial Hospital/Gandhi Memorial Hospital, Rewa, Madhya Pradesh, India. Int J Sci Stud 2018;6(9):21-28.

Source of Support: Nil, **Conflict of Interest:** None declared.