

Thoracoscopy and its Role in Evaluating Undiagnosed Pleural Effusions

Venkateswara Reddy Tummuru¹, Ramya Reddy Mallipeddi², ANV Koteswara Rao³, Pradyut Waghray⁴, P Sowmya Reddy⁵

¹Assistant Professor, Department of Tuberculosis and Respiratory Diseases, SVS Medical College and Hospital, Mahabubnagar, Telangana, India, ²Post Graduate, Department of Tuberculosis and Respiratory Diseases, SVS Medical College and Hospital, Mahabubnagar, Telangana, India, ³Professor, Department of Tuberculosis and Respiratory Diseases, SVS Medical College and Hospital, Mahabubnagar, Telangana, India, ⁴Professor and HOD, Department of Tuberculosis and Respiratory Diseases, SVS Medical College and Hospital, Mahabubnagar, Telangana, India, ⁵Consultant Pulmonologist, Department of Pulmonology, St. Theresa Hospital, Hyderabad, Telangana, India

Abstract

Introduction: Definition of undiagnosed pleural effusion was considered as the failure to achieve an etiologic diagnosis by initial pleural fluid microbiological, biochemical analysis, and at least three pleural fluid cytologies negative for malignant cells or other definite causes. Medical thoracoscopy also referred to as pleuroscopy is an endoscopic evaluation of the pleural space. Thoracoscopy was mainly used in the etiological diagnosis of pleural effusions and therapeutic procedures such as pleurodesis and adhesiolysis. In around 20%–30% of cases, etiology remains unclear and in this context, thoracoscopy becomes an important investigation modality.

Materials and Methods: It is a prospective, interventional study taken up as a pilot project by the Department of Pulmonary Medicine of SVS Medical College and Hospital, Mahabubnagar, Telangana, India. A total of 30 patients were satisfying the inclusion criteria and were further studied for their thoracoscopic and histopathological findings from January 2018 to November 2018.

Results: A total of 30 patients out of whom 19 patients were male (63.3%) and 11 patients (36.6%) were female. The most common respiratory symptom was shortness of breath in 18 patients (60%) and cough in 12 patients (40%). Out of the total 30 cases, 23 (76.66%) were malignant and 7 (23.33%) were diagnosed to be having tuberculosis (benign). According to the histopathological diagnosis, 20 (66.6%) had metastatic adenocarcinoma, 7 (23.3%) had tuberculosis and malignant lymphoma, and metastatic squamous cell carcinoma and sarcoma were detected in 1 (3.3%) patient. According to thoracoscopic findings, 13 (43.3%) patients had mass lesion, 12 (40%) patients had nodule, 3 (6.6%) patients had adhesions, and 2 (10%) patients had plaques. Majority of the mass lesions 11 (36.66%) were metastatic adenocarcinomas and majority of nodules 5 (16.66%) were diagnosed as tuberculous lesions.

Key words: Histopathology, Pleural effusion, Thoracoscopy

INTRODUCTION

Medical thoracoscopy also referred to as pleuroscopy is an endoscopic evaluation of the pleural space. It is minimally invasive procedure invented in 1910 by

Hans Christian Jacobus who is regarded as “Father of Thoracoscopy.”^[1] Thoracoscopy was mainly used in the etiological diagnosis of pleural effusions and therapeutic procedures such as pleurodesis and adhesiolysis. In around 20%–30% of cases, etiology remains unclear and in this context, thoracoscopy becomes an important investigation modality.^[2] Thoracoscopy, mainly rigid thoracoscopy, is useful to get large tissues where we can go for relevant investigations.

Thoracoscopy-guided biopsy and adhesiolysis today is a minimally invasive procedure performed by interventional pulmonologists. Results are excellent and

Access this article online



www.ijss-sn.com

Month of Submission : 04-2019
Month of Peer Review : 05-2019
Month of Acceptance : 05-2019
Month of Publishing : 06-2019

Corresponding Author: Dr. P Sowmya Reddy , Ground Floor, Plot 99, Nandagiri Hills, R. No. - 69, Jubilee Hills, Hyderabad - 500 033, Telangana, India.

severe complications are extremely rare. Thoracoscopy is a valuable tool as the pleural space can be visualized and representative sample can be picked.

Histopathology is the microscopic examination of the tissue to study the manifestations and type of disease. The tissue for histopathological examination is obtained after surgery or biopsy or autopsy. Later, it is sent for laboratory for confirmation by the pathologist. This is the gold standard investigation for confirmation. Whenever there is difficulty in confirming the diagnosis, histopathological examination remains the standard procedure of choice.

Definition of undiagnosed pleural effusion was considered as the failure to achieve an etiologic diagnosis by initial pleural fluid microbiological, biochemical analysis and at least three pleural fluid cytologies negative for malignant cells or other definite causes.^[3]

In Indian scenario, there are fewer studies that have been done on the role of thoracoscopy in cases of undiagnosed pleural effusion.^[4-6] This study was taken up to find out the thoracoscopic gross appearance in undiagnosed exudative pleural effusion cases and its final histopathological diagnosis.

MATERIALS AND METHODS

It is a prospective, interventional study taken up as a pilot project by the Department of Pulmonary Medicine

Table 1: Types of cases according to gender

Type of cases	Male (%)	Female (%)	Total (%)
Malignancy	14 (46.66)	09 (30)	23 (76.66)
Tuberculosis	05 (16.66)	02 (6.66)	07 (23.33)
Total cases	19 (63.33)	11 (36.66)	30 (100)

Table 2: Histopathological diagnosis of cases

Histopathological diagnosis	Frequency (%)
Metastatic adenocarcinoma	20 (66.6)
Malignant lymphoma	1 (3.3)
Metastatic squamous cell carcinoma	1 (3.3)
Sarcoma	1 (3.3)
Tuberculosis	7 (23.3)

Table 3: Thoracoscopic findings and histopathological diagnosis

Histopathological diagnosis	Mass lesion (%)	Nodule (%)	Plaque (%)	Adhesion (%)
Metastatic adenocarcinoma (n=20)	11 (55)	5 (25)	2 (10)	2 (10)
Malignant lymphoma (n=1)	0	1 (100)	0	0
Metastatic squamous cell carcinoma (n=1)	0	1 (100)	0	0
Sarcoma (n=1)	1 (100)	0	0	0
Tuberculosis (n=7)	1 (14.2)	5 (71.5)	0	1 (14.2)
Total (n=30)	13 (43.3)	12 (40)	2 (6.6)	3 (10)

of SVS Medical College and Hospital, Mahabubnagar, Telangana, India. All the enrolled cases of exudative pleural effusion which satisfy the inclusive criteria were taken into the study from January 2018 to November 2018. A total of 30 patients were satisfying the inclusion criteria and were further studied for their thoracoscopic and histopathological findings. The study was started after taking the approval of the Institutional Ethics Committee, SVS Medical College and Hospital, Mahabubnagar, Telangana, India.

The inclusion criteria include any case of exudative pleural effusions of age 45–75 years, which remained undiagnosed after initial and repeated biochemical, cytological analysis of pleural fluid and who have given the consent for participating in the study.

The exclusion criteria included the pleural effusions where microbiological or cytological or biochemical confirmation of diagnosis has been achieved. The patients who are unfit for the procedure, those who are suffering from bleeding diathesis, and those who are not willing to participate in the study were excluded from the study.

The patient underwent complete physical examination with written informed consent after detailed clinical history was taken. All the necessary baseline investigations were done including prothrombin time to assess the fitness of the patient. Radiological investigations included chest X-ray, contrast-enhanced computed tomography chest, and ultrasound chest.

For thoracoscopic procedure, the patient should be nil by mouth for at least 6 h before the procedure. During the procedure, the patient is asked to lie down in the lateral decubitus position with the affected side facing upward. Locoregional anesthesia is given on the desired site of affected side. Throughout the procedure, conscious sedation with benzodiazepine and opioid was given and blood pressure, oxygenation, and pulse were monitored.

Incision was given at the desired site and pleural cavity was entered with blunt dissection. A trocar and cannula were introduced along with rigid thoracoscope. Inspection of

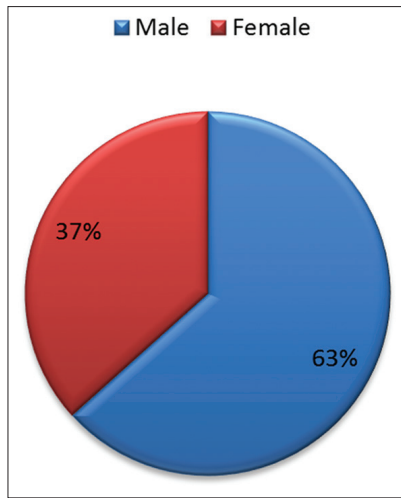


Figure 1: Distribution of the study population according to gender

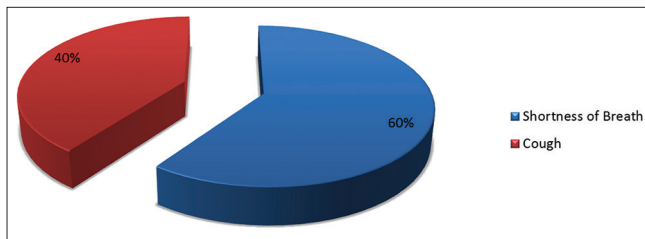


Figure 2: Distribution of the study population according to symptoms

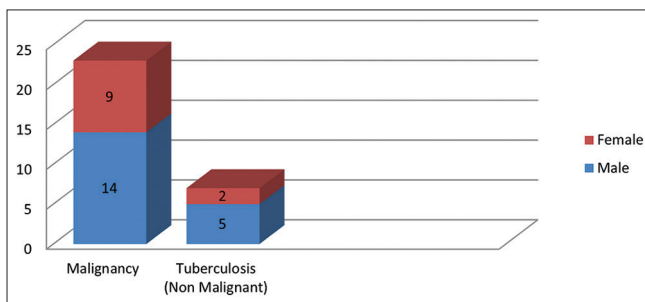


Figure 3: Types of cases according to gender

the pleural cavity was done and at selected sites, pleural biopsies were also taken simultaneously. The findings of thoracoscopy were recorded and the biopsy specimen was sent for histopathological examination. Adhesiolysis was also in patients in whom adhesions were present. Six to 10 biopsies are taken with pinch and peel method from the mass lesions, nodules, and plaques. Chest tube was inserted and connected to underwater seal and secured with suture. Biopsies were also sent for CBNAAT and acid-fast bacilli culture.

The data were entered using Microsoft Excel and analyzed using Microsoft Excel and Epi info software. Univariate analysis was done.

RESULTS

A total of 30 patients out of whom 19 patients were male (63.3%) and 11 patients (36.6%) were female. The most common respiratory symptom was shortness of breath in 18 patients (60%) and cough in 12 patients (40%). Out of the total 30 cases, 23 (76.66%) were malignant and 7 (23.33%) were diagnosed to be having tuberculosis (benign). Malignancy was present in 14 (46.66%) male patients and 9 (30%) female patients. Tuberculosis was diagnosed in 5 (16.66%) male patients and 2 (6.66%) female patients.

According to the histopathological diagnosis, 20 (66.6%) had metastatic adenocarcinoma, 7 (23.3%) had tuberculosis and malignant lymphoma, and metastatic squamous cell carcinoma and sarcoma were detected in 1 (3.3%) patient each.

According to thoracoscopic findings, 13 (43.3%) patients had mass lesion, 12 (40%) patients had nodule, 3 (6.6%) patients had adhesions, and 2 (10%) patients had plaques. Majority of the mass lesions 11 (36.66%) were metastatic adenocarcinomas and majority of nodules 5 (16.66%) were diagnosed as tuberculous lesions.

Of seven patients diagnosed to be tuberculosis, all were AFB positive and their histopathological examination suggested tuberculosis. Six were CBNAAT positive.

DISCUSSION

This prospective, interventional study was taken up as a pilot project by the Department of Pulmonary Medicine of SVS Medical College and Hospital, Mahabubnagar, Telangana, India.

In our study, majority of the patients were male and the most common symptom of presentation was shortness of breath. These findings are in concurrence with the study conducted by Patil *et al.*,^[3] where the majority of the cases were male and presented with shortness of breath. In a study done by Yousef *et al.*,^[7] male and female patients were in equal number and dyspnea was the presenting feature in all of them.

In this study, histology revealed that majority (76.66%) of the cases of undiagnosed exudative pleural effusion are malignant. These findings are in line with the study conducted by Patil *et al.*^[3] and Prabhu and Narasimhan,^[6] where majority of the patients were diagnosed with malignancy on histopathological examination. Other studies also reported that majority of the histopathological findings as malignancies.^[4,5,8,9]

In this study, mass lesions and nodules were the most common thoracoscopic findings. However, in the study

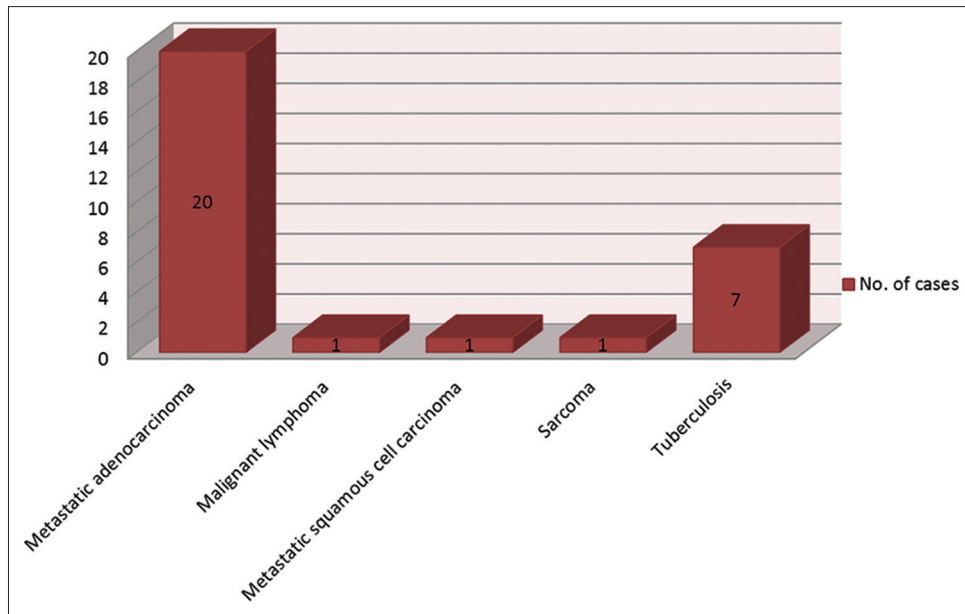


Figure 4: Histopathological diagnosis of cases

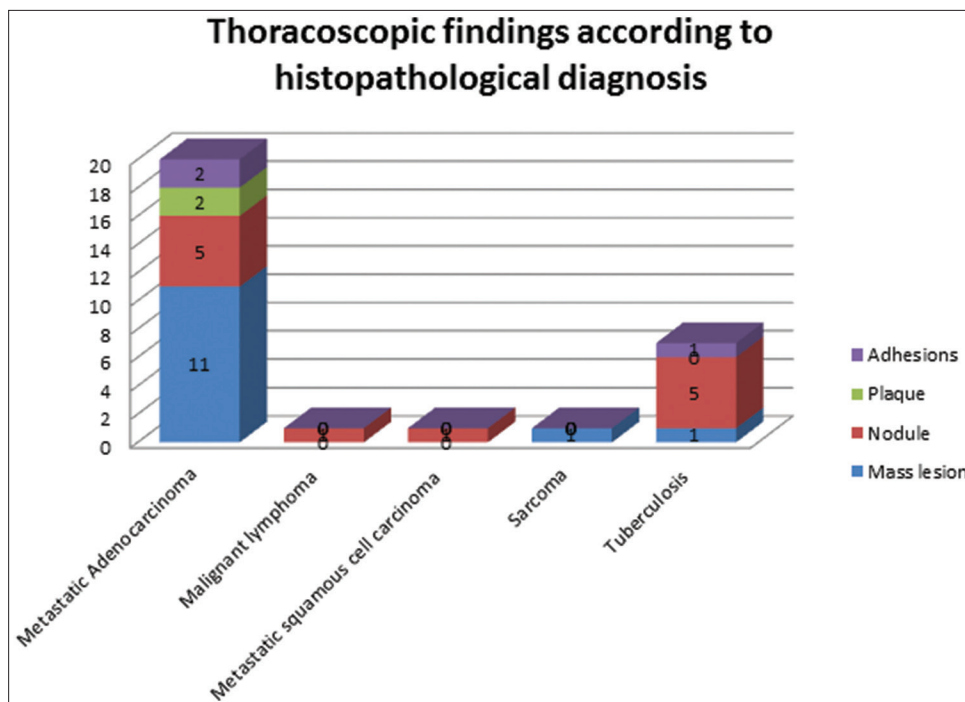


Figure 5

conducted by Yousef *et al.*,^[7] almost 75% of them presented as nodules.

In this study, metastatic adenocarcinoma was the most common histopathological finding. This finding of our study is in concurrence with the study done by Patil *et al.*^[3]

The complications after the procedure were nil. However, in the study conducted by Prabhu and Narasimhan,^[6] 5%

of them had minor complications such as subcutaneous emphysema and prolonged air leak. Similarly, in the studies conducted by Menzies and Charbonneau,^[10] Blanc *et al.*,^[11] Munavvar *et al.*,^[12] and Law *et al.*^[13] reported minor complications after the procedures.

CONCLUSION

- In this study, adenocarcinoma (66.6%) is most common

- In this study, mass lesions were the most common gross finding in patients who were diagnosed with adenocarcinoma.

REFERENCES

1. Jacobaeus HC. Fiberoptic laparoscopy and thoracoscopy. *Beitr Klin Tuberk* 1913;25:1-170.
2. Light RW. Clinical practice. Pleural effusion. *N Engl J Med* 2002;346:1971-7.
3. Patil CB, Dixit R, Gupta R, Gupta N, Indushekar V. Thoracoscopic evaluation of 129 cases having undiagnosed exudative pleural effusions. *Lung India* 2016;33:502-6.
4. Mootha VK, Agarwal R, Singh N, Aggarwal AN, Gupta D, Jindal SK, *et al.* Medical thoracoscopy for undiagnosed pleural effusions: Experience from a tertiary care hospital in north India. *Indian J Chest Dis Allied Sci* 2011; 53:21-4.
5. Dhanya TS, Ravindran C. Medical thoracoscopy minimally invasive diagnostic tool for a trained pulmonologist. *Calicut Med J* 2009;7:e4.
6. Prabhu VG, Narasimhan R. The role of pleuroscopy in undiagnosed exudative pleural effusion. *Lung India* 2012;29:128-30.
7. Yousef AI, Morsi AF, El-Shabrawy M, El Shahaat HA. The role of medical thoracoscopy in the diagnosis of exudative pleural effusion at the chest department of Zagazig university hospitals. *Egypt J Bronchol* 2016; 10:225-31.
8. Hucker J, Bhatnagar NK, al-Jilaihawi AN, Forrester-Wood CP. Thoracoscopy in the diagnosis and management of recurrent pleural effusions. *Ann Thorac Surg* 1991;52:1145-7.
9. Hansen M, Faurschou P, Clementsen P. Medical thoracoscopy, results and complications in 146 patients: A retrospective study. *Respir Med* 1998; 92:228-32.
10. Menzies R, Charbonneau M. Thoracoscopy for the diagnosis of pleural disease. *Ann Intern Med* 1991;114:271-6.
11. Blanc FX, Atassi K, Bignon J, Housset B. Diagnostic value of medical thoracoscopy in pleural disease: A 6-year retrospective study. *Chest* 2002; 121:1677-83.
12. Munavvar M, Khan MA, Edwards J, Waqaruddin Z, Mills J. The autoclavable semirigid thoracoscope: The way forward in pleural disease? *Eur Respir J* 2007;29:571-4.
13. Law WL, Chan J, Lee S, Ng CK, Lo CK, Ng WK, *et al.* Pleuroscopy: Our initial experience in Hong Kong. *Hong Kong Med J* 2008;14:178-84.

How to cite this article: Tummuru VR, Mallipeddi RR, Rao AK, Waghay P, Reddy PS. Thoracoscopy and Its Role in Evaluating Undiagnosed Pleural Effusions. *Int J Sci Stud* 2019;7(3):19-23.

Source of Support: Nil, **Conflict of Interest:** None declared.