Print ISSN: 2321-6379
Online ISSN: 2321-595X

Original Article

Role of Ultrasound in the Evaluation of Paediatric Rickets and its Association with Radiograph: A Cross-sectional Study

Hemangini Thakkar[1], Rajaram Sharma[2], Padma Badhe[3], Prateek Joshi[2], Diksha Rewal[4], Tapendra Tiwari[2], Saurabh Goyal[2]

[1]Professor and Head, Department of Radiodiagnosis, Seth Gordhandas Sunderdas Medical College and King Edward Memorial Hospital, Mumbai, Maharashtra, India, [2]Assistant Professor, Department of Radiodiagnosis, Pacific Institute of Medical Sciences, Udaipur, Rajasthan, India, [3]Professor, Department of Radiodiagnosis, Seth Gordhandas Sunderdas Medical College and King Edward Memorial Hospital, Mumbai, Maharashtra, India, [4]Senior Resident, Department of Transfusion Medicine, RNT Medical College, Udaipur, Rajasthan, India

Abstract

Introduction: Traditionally radiograph is used to diagnose rickets; however similar findings can also be seen on ultrasonography (USG) of the wrist joint and knee joint, such as widening of growth plates, frayed and cupped paintbrush metaphyses, bowing deformities, fractures, and pseudo-fractures.

Aim: The aim of the study is to evaluate the usefulness and diagnostic accuracy of USG for rickets as an isolated modality and in comparison with a radiograph.

Methodology: A cross-sectional study was conducted over a period of 10 months in the Department of Radiology. Thirty biochemically proven rickets patients and ten controls participants were assessed with bilateral wrist, knee, and trans-abdominal USG and compared to the latest radiograph for the following parameters: (1) Combined thickness of growth plate and unossified part of metaphysis was measured where it was maximum in both wrists and knee joints. (2) Presence or absence of cupping of physeal disc was assessed. (3) Metaphysis was evaluated for the presence of fraying and splaying. (4) If the unsharpness of cortex was present or not in the evaluated bones. The sensitivity, specificity, positive and negative predictive values (NPVs) of the above-mentioned variables were calculated for an USG and radiograph. Association between these was calculated.

Results: Sensitivity on radiograph for cupping, fraying, splaying, and unsharpness were 80%, 86.67%, 80%, and 10%, whereas on USG were 0%, 100%, 90%, and 10%, respectively. The specificity for these features were 100% on radiograph as well as USG. The positive predictive value of radiograph for these were 100%, while the for USG it was 0 for the cupping and 100% for rests of the features. The NPV for cupping, fraying, splaying, and unsharpness were 62.5%, 71.42%, 62.5%, and 27.02%, while on USG were 25%, 100%, 76.92%, and 27.02%, respectively.

Conclusions: USG is more sensitive in detecting rickets as compared to the radiograph. USG showed increase in the combined thickness of growth plate and unossified part of metaphysis more accurately than the radiograph. USG also depicted the fraying and splaying of metaphysis and unsharpness of the cortex in a greater number of cases as compared to the radiograph.

Key words: Bone, Growth plate, Musculoskeletal

Access this article online

IJSS

www.ijss-sn.com

Month of Submission : 10-2021
Month of Peer Review : 11-2021
Month of Acceptance : 11-2021
Month of Publishing : 12-2021

INTRODUCTION

Rickets is known as a defect in mineralization of bones before the closure of epiphysis in immature skeleton due to impaired metabolism of Vitamin D, Calcium or Phosphorus, causing fractures, and deformities.[1] Rickets is one of the most frequent diseases affecting childhood

Corresponding Author: Dr. Rajaram Sharma, Department of Radio-diagnosis, Pacific Institute of Medical Sciences, Udaipur, Rajasthan, India.

in developing countries. The commonest cause is Vitamin D deficiency, but lack of adequate dietary Calcium may also lead to rickets.[2] Although it can occur in adults, most cases occur in children suffering from severe malnutrition.

Ongoing back to the historical perspective, Greek physician Soranus of Ephesus had first reported deformation of the bones in infants in the first and second centuries AD. Diagnosis of rickets is established by clinical features (bony pain and muscle spasms, knock-knees, frontal bossing, soft skull, rickety rosary, i.e., costochondral swelling, Harrison's groove, widening of the wrist), radiological findings, and laboratory values. The biochemical analysis will show hypocalcemia, hypophosphatemia; serum elevated levels of alkaline phosphatize, and parathormone along with hyper aminoaciduria.[3-5]

Features on the radiograph include-Generalized osteopenia, coarse trabecular changes (cortical irregularity of the shaft), widening of the growth plate, frayed (irregularity of metaphysis) and cupped paintbrush metaphyses, absent zone of provisional calcification, bowing deformities, fractures, decreased bone length, scoliosis, and pseudo-fractures.[4,6]

Musculoskeletal ultrasonography (USG) is an emerging field of imaging. USG is a valuable and well-founded technique in musculoskeletal pathologies. Its role in imaging is continuing to evolve with the recognition of further clinical applications and improved USG technology. It is now a well-established first-line imaging modality in Europe to diagnose musculoskeletal pathologies and is rapidly gaining popularity in other parts of the world.[6,7]

The objectives of the study were to detect standard radiograph findings on USG of wrist and knee joints and evaluation of sensitivity, specificity, positive predictive value, and negative predictive value (NPV) of USG and radiograph for rickets using measurements of the thickness of the physeal plate and unossified part of epiphysis and metaphysic and observing for the cupping, fraying and splaying of the metaphysis.

USG was also evaluated if it can an idea about underlying etiology. However, it was not compared to radiograph, as radiograph cannot give an idea about underlying etiology. The statistical analysis was done using Graphpad prism software for various variables, and the association between the attributes was calculated.

SUBJECTS AND METHODS

It was a cross-sectional study conducted over a period of 10 months (From January 2018 to October 2018) in the Department of Radiology, Seth GS Medical College and KEM hospital, Mumbai, Maharashtra, India.

Inclusion Criteria

1. Newly biochemically proven rickets cases of age between 1 and 10 years
2. Already diagnosed cases, now on treatment were included
3. Patients having registration in our institute either as outdoor patients or indoor patients
4. Controls were the participants of age between 1 and 10 years who are not having rickets at present or had it in the past. Radiographs of the control were done for some other reasons such as trauma (however, no fracture) or skeletal survey for various other reasons such as bone age estimation in hypothyroidism. Controls were not subjected to additional radiographs from our side
5. Patient with the latest available digital radiograph of both wrist joint and knee joints (radiograph of within a week's duration).

Exclusion Criteria

1. Patient, not willing for the study
2. Patients where rickets was a clinical suspicion only.

Of all the participants referred to us over a period of 10 months, the patients meeting the inclusion criteria were evaluated.

This was a pilot study. The number of patients has been decided arbitrarily, keeping in mind a sufficient number of patients be included to evaluate the role of USG in the diagnosis of rickets with radiograph correlation. On the basis of this study, a larger sample size can be studied in the future. The sample size was 40 participants, including 30 rickets patients and ten controls.

Study Procedure

All participants (cases and controls) were scanned on Philips HD 11×E using a 5–12 MHz linear transducer and curvilinear transducer having color Doppler and spectral capabilities. All patients were assessed with bilateral wrists, knees, and trans-abdominal USG (for cases only).

The examination procedure was explained to the patient and relatives. With the patient lying down comfortably in a supine position, USG gel was spread over the wrist, knee, flank, right hypochondrium, and neck on the right side than on the left side in the same sequence. The transducer, held in the examiner's right hand, was moved across the joint from the top downwards and from right to left till the requisite structures were studied. Grayscale images were obtained. The depth and focus of the transducer were adjusted according to each patient.

The patient was kept in a supine position, and a rolled towel was placed behind the knee to achieve an approximately 10–15° of knee flexion for the USG scan.[7] USG of the wrist was performed in the supine position in the neutral orientation.[7]

Perpendicular maximum distance between the lateral or the medial most ends of the metaphysis to the ossified end of the epiphysis in both the knees and wrists was measured [Figures 1-4].

Routine USG examination included a complete morphological examination of wrist and knee joints, kidneys, liver, and parathyroid glands. During each examination, epiphyseal width measurement was obtained at the point of maximum width. Subjective assessment for the depth of disc cupping and structural abnormalities of joints in rickets were also assessed. All these findings were compared to the latest available radiograph (not older than a week) [Figure 5].

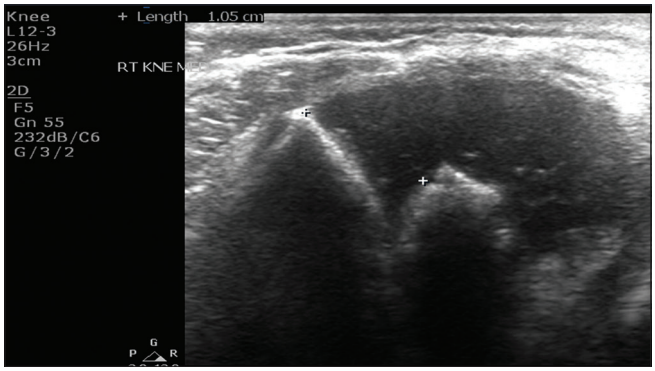

Figure 1: Greyscale ultrasound image of the right knee, showing femoral growth plate measurement at its maximum diameter at medial condyle. The hypoechoic part between the + sign is the growth plate or physeal plate

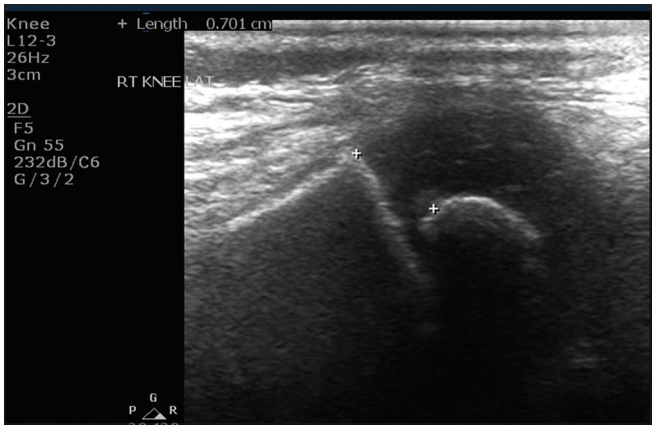

Figure 2: Greyscale ultrasound image of the right knee, showing femoral growth plate measurement at its maximum diameter at lateral condyle. The hypoechoic part between the + sign is the growth plate or physeal plate

USG for both kidneys was done to look for medullary and cortical calcinosis, of the liver to look for biliary atresia and cirrhosis, and of the parathyroid gland to look for enlargement or adenoma. (For cases only; not for controls).

The following parameters were evaluated:

1. Combined thickness of growth plate and unossified part of epiphysis and metaphysis where it is maximum in both wrists and both knee joints
2. Cupping of physeal disc and metaphysis - Present or not on radiograph and on USG. Cupping was defined as a concave radio-lucent margin in the metaphysis. It was a subjective assessment, and no actual measurements were done for this criterion

Figure 3: Greyscale ultrasound image of right wrist, showing radius growth plate measurement at its maximum diameter at the styloid process. The hypoechoic part between the + sign is the growth plate or physeal plate

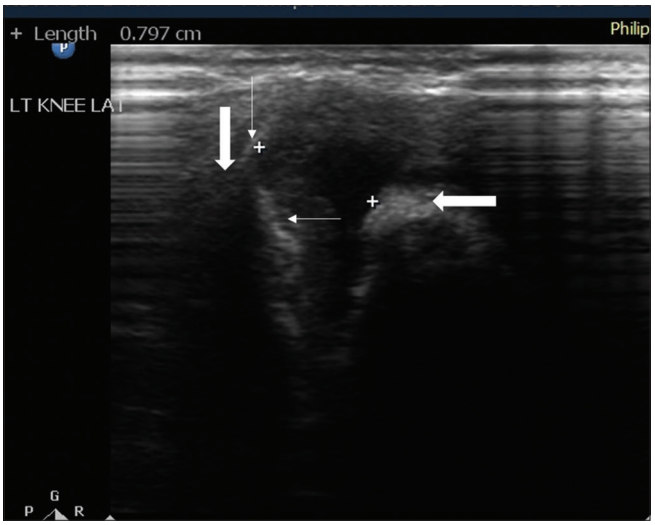

Figure 4: Greyscale ultrasound image of the left knee, showing splaying (thin vertical white arrow) and fraying (thin horizontal white arrow). There is a widening of growth seen. Cortical irregularity is also seen on both the epiphyseal (thick horizontal white arrow) and metaphyseal side (thick vertical white arrow)

3. In metaphysis, if
   - Fraying present or not
   - Splaying present or not
4. Unsharpness of cortex of both radius and femur. (Subjective criteria).

All these parameters were compared and analyzed with a previously available radiograph (not older than a week). In the case of asymmetry in involvement, joint with more severely involvement was used to compare the outcome. Any amount of fraying or splaying was considered abnormal.

The radiologist interpreting the radiograph and the radiologist doing USG were experienced (faculty members of the department), trained, and were blinded to each other's interpretation.

The data obtained from the study were tabulated in the excel sheet and the calculation was done using Graphpad prism and Statistical Package for the Social Sciences software. The frequency variables for attributes and *P*-value were calculated a $P < 0.01$ was considered significant.

Figure 5: Anteroposterior radiograph of the left knee joint shows all typical features of rickets, i.e., growth plate widening, cupping, fraying and splaying of the metaphysis. There is coarsening of the trabeculae, and generalized osteopenia was noted. This image shows how the maximum diameter of the growth plate is taken on both the medial and lateral sides

RESULTS

The study included 30 rickets patients (14 males and 16 females) and ten normal participants as controls (five males and five females), and the *P*-value for the efficacy of USG in the diagnosis of rickets was calculated. Data obtained from the study is analyzed for age distribution, sex distribution to calculate sensitivity, specificity, positive and NPV of USG with radiograph correlation.

The radiograph demonstrated standard features, i.e., generalized osteopenia, coarse trabecular changes, widened growth plates, frayed and cupped paintbrush metaphyses, absent zone of provisional calcification, bowing deformities, fractures, decreased bone length, scoliosis, and pseudo-fractures. The USG on the other hand precisely illustrated widening of growth plates, frayed and cupped paintbrush metaphyses, fractures, and pseudo-fractures.

For cupping, fraying splaying and unsharpness of cortex the radiograph had sensitivity of 80%, 86.67%, 80% and 10%, while USG had 0%, 100%, 90% and 10%, respectively. The positive predictive value of radiograph for cupping, fraying splaying and unsharpness of cortex was 100% for each parameter, while for USG it was 0 for the cupping and 100% for rests of the evaluated features. The specificity for these features was 100% on both USG in this study. The NPV of radiograph for cupping, fraying splaying and unsharpness of cortex were 62.5%, 71.42%, 62.5% and 27.02% while on USG these were 25%,100%, 76.92% and 27.02% respectively [Tables 1-3].

Three out of the 30 rickets patients are having associated medullary nephrocalcinosis on USG, a finding which favors the diagnosis of Vitamin-D resistant renal rickets, thus assisting in evaluation of underlying etiology for the disease. Rest 27 cases had a normal USG of the kidneys. *P*-value was calculated for the thickness of physeal plate and unossified part of epiphysis and metaphysis at medial femoral condyle (on the medial side) on USG (tpmu) in rickets patients versus thickness of physeal plate and unossified part of epiphysis and metaphysis at medial femoral condyle (on the medial side) on a radiograph in rickets patients (tpmx) using Graphpad prism software (unpaired *t*-test). It was found to be <0.01, which is significant.

P-value was calculated for the thickness of physeal plate and unossified part of epiphysis and metaphysis at lateral femoral condyle (on lateral side) on USG (tplu) in rickets patients versus thickness of physeal plate and unossified part of epiphysis and metaphysis at lateral femoral condyle

Table 1: Contingency table for evaluated imaging features of rickets on radiograph and ultrasound

Feature	Number of cases in which the radiograph showed the finding	Number of cases in which the ultrasound showed the finding
Cupping	24	0
Fraying	26	30
Splaying	24	27
Unsharpness of cortex	3	3

Table 2: Calculated parameters for various rickets features on radiograph

Feature	Sensitivity (%)	PPV (%)	Specificity (%)	NPV (%)
Cupping	80	100	100	62.50
Fraying	86.67	100	100	71.42
Splaying	80	100	100	62.50
Unsharpness (Irregularity)	10	100	100	27.02

PPV: Positive predictive value, NPV: Negative predictive value

Table 3: Calculated parameters for various rickets features on ultrasound

Feature	Sensitivity (%)	PPV (%)	Specificity (%)	NPV (%)
Cupping	0	0	100	25
Fraying	100	100	100	100
Splaying	90	100	100	76.92
Unsharpness (Irregularity)	10	100	100	27.02

PPV: Positive predictive value, NPV: Negative predictive value

(on lateral side) on a radiograph in rickets patients (tprx) using Graphpad prism software (unpaired *t*-test). It was found to be <0.01, which is significant.

P-value was calculated for the thickness of physeal plate and unossified part of epiphysis and metaphysis of the radius of the right hand at styloid process on USG (tpru) in rickets patients and thickness of physeal plate and unossified part of epiphysis and metaphysis of the radius of the right hand at styloid process on a radiograph in rickets patients (tprx) using Graphpad prism software (unpaired *t*-test). It was found to be <0.01, which is significant.

This study suggests that USG has better chances of picking up the widening of growth plate, as it has consistently shown higher values for thickness of physeal plate and unossified part of epiphysis and metaphysis as compared to the radiograph. Rests of the statistical analysis details are provided in Table 4 below.

Table 4: Statistical calculation using Graphpad Prism for the cases-

Statistical variable	Tpmx	Tpmu	Tplx	Tplu	Tprx	Tpru
Number of values	30	30	30	30	4	4
Minimum	4.400	5.700	2.800	3.700	1.800	2.100
25% Percentile	7.400	8.475	4.600	6.150	1.975	2.300
Median	8.550	9.700	5.250	6.800	2.900	3.300
75% Percentile	9.200	11.28	6.275	7.525	4.425	5.125
Maximum	12.40	17.50	10.70	12.60	4.800	5.600
Mean	8.397	9.940	5.610	6.997	3.100	3.575
Std. Deviation	1.555	2.214	1.455	1.565	1.288	1.500
Std. Error of Mean	0.2838	0.4041	0.2656	0.2858	0.6442	0.7499
Lower 95% CI of mean	7.816	9.113	5.067	6.412	1.050	1.189
Upper 95% CI of mean	8.977	10.77	6.153	7.581	5.150	5.961

DISCUSSION

Rickets is a deforming and debilitating disease of the growing pediatric population in developing countries. As a traditionally established practice, the radiograph is the commonly prescribed imaging modality for rickets patients to date. As advancements are going on in biochemical testing and in treatment, soon, there will be an imaging modality that is more sensitive and specific for diagnosing rickets. Radiation protection in the pediatric group is a growing concern of the era. Musculoskeletal USG has evolved according to the need of the changing and developing clinical practices. USG is a radiation-free and yet reasonably cheaper alternative.

However, there is no literature available about USG in the imaging of rickets or its correlation with a radiograph. We propose that additional such studies should be done on this topic to arrive at a consensus.

Limitations and Future Recommendations

The limitations of the study are smaller sample size and inter-observer variability. As this was a pilot study only, purposefully, we omitted a few of the rickets features.

The same findings can be applied to adult rickets or osteomalacia; however, some differences will be there because the growth plate is fused till the adulthood. We have taken an initial step in this vast field of scope, which requires further investigation and applicability.

CONCLUSIONS

USG is more sensitive in detecting growth plate widening, fraying and splaying of the metaphysis. However, radiograph has an overhand in detecting cupping of metaphysis and deformities evaluation. Overall, USG is more sensitive in detecting rickets compared to the radiograph. We hope this pilot study will encourage further research in the subject, and over time some new guidelines will be made.

ACKNOWLEDGMENTS

Nil.

ETHICS APPROVAL AND CONSENT TO PARTICIPATE

Approval was taken from the institutional ethics committee before the start of the study. Written informed consent from the parents of the participants and assent from participants were obtained.

CONSENT FOR PUBLICATION

Not applicable.

REFERENCES

1. Munns CF, Shaw N, Kiely M, Specker BL, Thacher TD, Ozono K, *et al*. Global consensus recommendations on prevention and management of nutritional rickets. J Clin Endocrinol Metab 2016;101:394-415.
2. Ruangkit C, Suwannachat S, Wantanakorn P, Sethaphanich N, Assawawiroonhakarn S, Dumrongwongsiri O. Vitamin D status in full-term exclusively breastfed infants versus full-term breastfed infants receiving Vitamin D supplementation in Thailand: A randomized controlled trial. BMC Pediatr 2021;21:378.
3. Tan ML, Abrams SA, Osborn DA. Vitamin D supplementation for term breastfed infants to prevent Vitamin D deficiency and improve bone health. Cochrane Database Syst Rev 2020;12:CD013046.
4. Calder AD. Radiology of osteogenesis imperfecta, rickets and other bony fragility states. Endocr Dev 2015;28:56-71.
5. Klauser AS, Tagliafico A, Allen GM, Boutry N, Campbell R, Court-Payen M, *et al*. Clinical indications for musculoskeletal ultrasound: A Delphi-based consensus paper of the European society of musculoskeletal radiology. Eur Radiol 2012;22:1140-8.
6. Henderson RE, Walker BF, Young KJ. The accuracy of diagnostic ultrasound imaging for musculoskeletal soft tissue pathology of the extremities: A comprehensive review of the literature. Chiropr Man Therap 2015;23:31.
7. Özçakar L, Kara M, Chang KV, Ulaşlı AM, Hung CY, Tekin L, *et al*. EURO-MUSCULUS/USPRM basic scanning protocols for wrist and hand. Eur J Phys Rehabil Med 2015;51:479-84.

How to cite this article: Thakkar H, Sharma R, Badhe P, Joshi P, Rewal D, Tiwari T, Goyal S. Role of Ultrasound in the Evaluation of Paediatric Rickets and its Association with Radiograph: A Cross-sectional Study. Int J Sci Stud 2021;9(9):20-25.

Source of Support: Nil, **Conflicts of Interest:** None declared.