Print ISSN: 2321-6379
Online ISSN: 2321-595X

Original Article

A Study on the Morphometric Profile of Glenoid Part of Human Scapula

R Sivachidambaram[1], T H Dilipkumar[2]

[1]Assistant Professor, Department of Anatomy, Government Medical College, Pudukkottai, Tamil Nadu, India, [2]Assistant Professor, Department of Anatomy, Madras Medical College, Chennai, Tamil Nadu, India

Abstract

Introduction: Shoulder instability is a challenging part for an orthopedic surgeon to diagnose and treat due to various anatomical and pathological changes which occur in the glenoid cavity of scapula. In shoulder arthroplasty, the prosthesis of glenoid component of scapula is used to treat conditions such as complete glenoid erosion and severe glenoid fracture. Therefore, we aimed to establish the morphometric and morphological features of glenoid cavity of scapulae harvested from a sample of population of Tamil Nadu.

Aims and Objectives: The aim of the study is to establish the morphometric profile of glenoid part of human scapula present in the Department of Anatomy, Government Medical College, Pudukkottai.

Materials and Methods: We studied 65 dry scapulae (30 right, and 35 left) from the Department of Anatomy, Government Medical College, Pudukkottai, Tamil Nadu. Vertical diameter of the glenoid cavity, transverse diameter of the lower half, and upper half of the glenoid cavity were measured. The shape of the glenoid cavity and the incidence of distinct glenoid notch were also noted.

Results: The mean vertical diameter of glenoid cavity was 3.63 ± 0.3 cm on the right and 3.58 ± 0.3 cm on left side. The mean transverse diameter of lower half of glenoid cavity was 2.52 ± 0.3 cm on the right and 2.50 ± 0.3cm on the left side. The mean transverse diameter of the upper half of glenoid cavity was 1.93 ± 0.2 cm on the right and 1.91 ± 0.3 cm on the left side. Pear-shaped glenoid cavity was noted in 56% of scapula, oval shape was seen in 29%, while inverted comma shape was observed in 15% of scapula.

Conclusion: Knowledge of morphometry and morphology of glenoid cavity of scapula helps design the glenoid component of scapula for arthroplastic procedure. Knowledge of variation in normal anatomy of glenoid fossa is necessary to diagnose and treat the conditions such as glenoid erosion, Bankart lesion, and osteochondral defects.

Key words: Bankart lesion, Glenoid cavity, Glenoid notch, Shoulder instability

INTRODUCTION

The scapula is a flat triangular bone present on the posterolateral aspect of the thorax. The glenoid cavity is a fossa present in the lateral part of the scapula, which provides a shallow socket for the head of the humerus to articulate.[1] Such a shallow fossa makes the shoulder joint, the most frequently dislocating joint in the body. Depending on the presence of a glenoid notch in its anterior margin, the shape of the glenoid cavity takes an inverted comma shape or a pear shape or an oval shape.[2]

In anterior shoulder dislocation, patients with distinct glenoid notch are more prone for anterior glenoidlabral tear (Bankart lesion), due to the non-attachment of labrum in the notch.[3] Hence, the present study noted the incidence of distinct glenoid notch and the various shapes of glenoid cavity in the Tamil Nadu population. Glenoid erosion is considered to be one of the most important causes for recurrent shoulder instability.[4] To diagnose the percentage of erosion, the normal morphometric parameters of the glenoid cavity are needed.

Fracture of glenoid is also quite common in acute trauma of the shoulder joint.[5] To manage it, the prosthesis of glenoid component of the scapula is needed.[6] In the

Access this article online

www.ijss-sn.com

Month of Submission : 02-2022
Month of Peer Review : 03-2022
Month of Acceptance : 03-2022
Month of Publishing : 04-2022

Corresponding Author: Dr. R Sivachidambaram No.A3, A-Block, 1st Floor, Teaching Staff Doctors Quarters, Government Medical College Hospital, Mullur Village, Pudukkottai - 622 004, Tamil Nadu, India

view of above consideration, we aimed to establish the morphometric and morphological parameters of glenoid cavity of the scapula in Tamil Nadu population.

Aims and objectives

The aim of the study is to establish the morphometric profile of glenoid part of human scapula present in the Department of Anatomy, Government Medical College, Pudukkottai.

MATERIALS AND METHODS

The study was done on 65 dry unpaired scapulae (30 right, and 35 left) of unknown sex from the Department of Anatomy, Government Medical College, Pudukkottai, Tamil Nadu. Damaged bones were excluded from this study. The following parameters were measured.

As shown in Figure 1, the vertical diameter of the glenoid cavity was measured by taking the maximum distance from the supraglenoid tubercle to the inferior margin of the glenoid cavity, the transverse diameter of the lower half of the glenoid cavity was measured by taking the maximum distance between the anterior margin and the posterior margin of the glenoid cavity and transverse diameter of the upper half of the glenoid cavity was measured by taking the anteroposterior diameter of the upper half of the glenoid cavity at the midpoint between the superior margin and the midpoint of vertical length of the glenoid cavity of the scapula. All the above parameters were measured with the digital caliper. The bones were examined for the various shapes of the glenoid cavity, as shown in Figure 2. The incidence of distinct glenoid notch, as shown in Figure 3, was also noted in our study. Statistical analyses such as mean, standard deviation, and the range were calculated using IBM SPSS statistical software (version 22.0) - IBM, New York, USA.

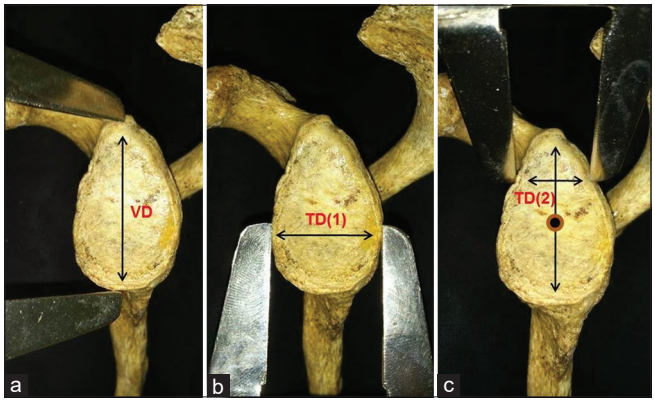

Figure 1: Diameters of glenoid cavity of scapula (a) vertical diameter of the glenoid cavity (VD), (b) transverse diameter of the lower half of the glenoid cavity (TD 1), and (c) transverse diameter of upper half of the glenoid cavity (TD 2)

RESULTS

As given in Table 1, the mean vertical diameter of the glenoid cavity on the right side was 3.63 ± 0.3 cm and it was 3.58 ± 0.3 cm on the left side. The mean transverse diameter of the lower half of the glenoid cavity on the right side was 2.52 ± 0.3 cm and it was 2.50 ± 0.3 cm on the left side. The mean transverse diameter of the upper half of the glenoid cavity on the right side was 1.93 ± 0.2 cm and it was1.91 ± 0.3 cm on the left side. As given in Table 2, out of 65 glenoid cavities examined, pear-shaped glenoid cavities were noted in 56%, oval shape was seen in 29%, and inverted comma shape in 15% of the bones. Distinct glenoid notch was noted in 17% of the scapula studied, as shown in Table 3.

DISCUSSION

The various anatomical and pathological changes in the glenoid cavity of the scapula make it more prone for shoulder instability and recurrent dislocation of the

Figure 2: Shapes of glenoid cavity of scapula (a) inverted comma shape, (b) pear shape, and (c) oval shape

Figure 3: Distinct glenoid notch (GN) of scapula

Table 1: Morphometric parameters of the right and left glenoid cavities of scapula

Parameters (cm)	Mean±SD		Range	
	Right	Left	Right	Left
Vertical diameter	3.63±0.3	3.58±0.3	3–4.2	3–4.1
Transverse diameter (1)	2.52±0.3	2.50±0.3	2–3.3	2–3.2
Transverse diameter (2)	1.93±0.2	1.91±0.3	1.5–2.4	1.3–2.4

SD: Standard deviation

Table 2: Incidence of various shapes of glenoid cavity of scapula

Shape of the glenoid	Right side (%)	Left side (%)	Overall occurrence (%)
Inverted comma	20	14	15
Pear	53	54	56
Oval	27	32	29

Table 3: Incidence of distinct glenoid notch in scapula

Feature	Right side	Left side	Percentage
Distinct glenoid notch	7/65	4/65	17

shoulder joint. Among this, glenoid erosion is considered to be the major cause for shoulder instability due to its high risk of recurrence even after surgical repair. Hence, early diagnosis and the treatment of glenoid erosion are needed, which depends on the percentage of bone eroded versus normal joint surface area of the glenoid cavity, the width and the height of the glenoid cavity.[7]

According to Mamatha *et al.*[8] the mean vertical diameter of the glenoid cavity on the right side was 3.36 cm and it was 3.40 cm on the left side, the mean transverse diameter of the lower half of the glenoid cavity on the right side was 2.33 cm and it was 2.30 cm on the left side, and the mean transverse diameter of the upper half of the glenoid cavity on the right side was 1.62 cm and it was 1.57 cm on the left side. All these morphometric parameters were similar to our study values, as shown in Table 1. Our study results were similar to previous studies done by Rajput, Kavita and Jaskaran and Maman *et al.*[9-11]

Prescher and Klümpen,[2] in 1996, noted that the percentage of the glenoid cavity with both distinct and indistinct glenoid notch (inverted comma and pear shape) was 55%. However, in our study, it was found to be present in 69% of the bones studied.

As shown in Figure 3, the glenoid notch is a small depression present in the anterior rim of the glenoid cavity which alters the shape of the glenoid cavity as inverted comma, pear shape, and oval shape. The exact reason for the presence of the glenoid notch was not known. It could be suggested that the pressure on the anterior margin of the glenoid cavity by the tendon of subscapularis muscle leads to the formation of the notch. Frazer,[12] in 1958, suggested that the scapular part and the coracoid part of the glenoid cavity were marked by the glenoid notch. Prescher and Klümpen [13] suggested that the glenoid labrum was not attached to the margin of the glenoid cavity at the glenoid notch, but bridged it.

Bankart,[14,15] in 1923, and Adams, in 1948,[16] observed that labral tears and avulsion of the labrum occur at the anterior margin of the glenoid cavity (Bankart lesion) in a patient with recurrent dislocation. The nonattachment of the labrum in the glenoid notch could make the shoulder joint less resistant to dislocating forces and was found to be the predisposing factor for Bankart lesions. This lesion is an important cause for recurrent shoulder instability. In the present study, the incidence of glenoid notch in both right and left scapulae was 70%. Out of this, distinct glenoid notch was noted only in 17% of the bone studied. Hence, the normal non-attachment of the glenoid labrum at the glenoid notch must not be diagnosed as a Bankart lesion.

CONCLUSION

The morphometric and morphological parameters of the glenoid cavity observed in the present study will help the orthopedic surgeons to decide the proper size of the glenoid component of the scapula in shoulder arthroplasty. In shoulder instability cases, these morphometric parameters are helpful for the radiologist to diagnose and categorize the degree of glenoid erosion which helps in better surgical planning of the glenoid repair to prevent recurrent instability. The knowledge of various shapes of glenoid cavity and the incidence of glenoid notch noted in the present study are important for evaluating the pathological conditions such as osseous Bankart lesion and glenoid erosion in the shoulder instability.

REFERENCES

1. Standarding S. Gray's Anatomy. The Anatomical Basis of Clinical Practice. 41th ed. London: Elsevier Churchill Livingstone; 2016. p. 803, 813.
2. Prescher A, Klümpen T. The glenoid notch and its relation to the shape of the glenoid cavity of the scapula. J Anat 1997;190:457-60.
3. Rhee YG, Cho NS, Cho SH. Traumatic anterior dislocation of the shoulder: Factors affecting the progress of the traumatic anterior dislocation. Clin Orthop Surg 2009;1:188-93.
4. Ikemoto RY, Murachovsky J, Nascimento LG, Bueno RS, de Oliveira LH, Fujiki EN, *et al.* A new method to evaluate glenoid erosion in instable shoulder. Int Arch Med 2013;6:42.
5. Ideberg R, Grevsten S, Larsson S. Epidemiology of scapular fractures. Incidence and classification of 338 fractures. Acta Orthop Scand 1995;66:395-7.
6. Kligman M, Roffman M. Glenoid fracture: Conservative treatment versus surgical treatment. J South Orthop Assoc 1998;7:1-5.

7. Sugaya H, Moriishi J, Dohi M, Kon Y, Tsuchiya A. Glenoid rim morphology in recurrent anterior glenohumeral instability. J Bone Joint Surg Am 2003;85:878-84.
8. Mamatha T, Pai SR, Murlimanju BV, Kalthur SG, Pai MM, Kumar B. Morphometry of glenoid cavity. Online J Health Allied Scs 2011;10:7.
9. Rajput HB, *et al*. A study of morphological patterns of glenoid cavity of scapula. Natl J Med Res 2012;2:504-7.
10. Kavita P, Jaskaran S. Morphology of coracoid process and glenoid cavity in adult human scapulae. Int J Anal Pharm Biomed Sci 2013;2:19-22.
11. Maman AS, Lachat JJ, Zamarioli A, Homem JM, Thomazini, JA. Morphologic aspects of the articular face of the glenoid cavity in the human scapulae: Preliminar outcomes. J Morphol Sci 2008;25:157-214.
12. Frazer JE. The Anatomy of the Human Skeleton. 5th ed. London: Churchill; 1958.
13. Prescher A, Klümpen T. Does the area of the glenoid cavity of the scapula show sexual dimorphism? J Anat 1995;186:223-6.
14. Bankart AS. Recurrent or habitual dislocation of the shoulder-joint. Br Med J 1923;2:1132-3.
15. Bankart AS. The pathology and treatment of recurrent dislocations of the shoulder joint. Br J Surg 1938;26:23-9.
16. Adams JC. Recurrent dislocation of the shoulder. J Bone Joint Surg Br 1948;30B:26-38.

How to cite this article: Sivachidambaram R, Dilipkumar TH. A Study on the Morphometric Profile of Glenoid Part of Human Scapula. Int J Sci Stud 2022;10(1):45-48.

Source of Support: Nil, **Conflicts of Interest:** None declared.