

A Study of 25 Diagnosed Cases of Abdominal Tuberculosis – A Review Article

Nilesh Punjabhai Sondarva¹, Kishan D Shah², Sudhir G Mehta³

¹Resident, Department of General Surgery, MP Shah Medical College, Jamnagar, Gujarat, India, ²Associate Professor, Department of General Surgery, MP Shah Medical College, Jamnagar, Gujarat, India, ³Professor and Head, Department of General Surgery, MP Shah Medical College, Jamnagar, Gujarat, India

Abstract

Background: The objective of this study is to evaluate diagnosed cases of abdominal tuberculosis (TB) in terms of incidence, manifestation in different age groups, clinical presentations, treatment received (conservative or surgical), lesions found intraoperatively, and its outcome on follow-ups.

Methods: It is a retrospective study with 25 cases of abdominal TB treated at Guru Gobind Singh Hospital, Jamnagar, during the period of 2005–2007. Detailed history, physical examination, necessary investigations such as complete blood counts, ESR, urine examination, sputum examination, and radiological investigations were prescribed in all cases. Barium study, Mantoux test, ascitic fluid examination, and computed tomography scan abdomen were carried out when indicated. Tissue or biopsy materials were histologically examined. Results were analyzed with patient's health status.

Results: In 25 case series of abdominal TB, the average age of presentation was between 10 and 40 years with definite male predominance (male:female = 3:2). Most of the patients belonged to low socioeconomic class which, in turn, reflects overcrowding, undernourishment, bad sanitation, and poor hygiene in living conditions. In our study, ESR was raised in more than 90% of patients. Abdominal pain was the most common presenting symptom followed by anorexia, fever, and vomiting. About 25% of patients were having TB foci in lung either active or healed lesion. Uncorrected anemia, malnutrition, and pulmonary TB were all contributory to poor prognosis and prolonged morbidity. Anti-TB drugs gave most satisfactory results in our patients.

Conclusions: Koch's abdomen is a clinical entity with varied clinical presentation. It is very common in tropics and may present with complications. Most of the patients are cured with conservative treatment and anti-TB drugs. Surgery is required in case of complications only. No drug-resistant cases have been found in this study. Investigations have played major role in confirmation of disease.

Key words: Abdominal tuberculosis, Intestinal resections, Koch's abdomen, Stricture plasty

INTRODUCTION

Tuberculosis (TB) has become a big health issue, especially in developing countries like India, where illiteracy, poverty, overcrowding, lack of basic living facilities, large families, poor sanitation, and malnutrition are prevalent.^[1] Approximately one-third of the world population is infected with TB and about 3 million die each year from this

disease.^[2] Therefore, the World Health Organization has raised a global concern and declared as the most important communicable disease worldwide.^[3] It is a chronic granulomatous disease caused by *Mycobacterium tuberculosis* and the reservoir of infection in humans with active TB. Pulmonary TB is the most common form and it primarily involves the lung, but any part of the body can be involved by the disease.^[4,5] Abdominal TB constitutes a major public health problem in developing countries and associated with significant morbidity and mortality.^[6] It is the sixth most frequent site for the extrapulmonary involvement and it can involve any part of the gastrointestinal tract, peritoneum, and hepatobiliary system. Approximately 1–3% of total TB cases are extrapulmonary,^[7,8] while abdominal TB accounts for 11%–16%.^[9] However, in HIV-positive patients, the

Access this article online



www.ijss-sn.com

Month of Submission : 07-2019
Month of Peer Review : 08-2019
Month of Acceptance : 08-2019
Month of Publishing : 09-2019

Corresponding Author: Dr. Nilesh Punjabhai Sondarva, F/303, Nilkanth Greens, Behind Delhi Public School, Kalali Road, Vadodara - 390 012, Gujarat, India.

incidence of extrapulmonary TB is up to 50%. The modes of infection of abdominal TB include hematogenous spread from a primary lung focus that reactivates later or miliary TB, spread through lymphatics from infected nodes, ingestion of bacilli either from the sputum or from infected sources such as milk products, or by direct spread from adjacent organs.^[10] The most common site of predilection is the ileocecal region, attributed to the minimal digestive activity, relatively increased physiological stasis, higher rate of fluid and electrolyte absorption, and more lymphoid tissue at this site.^[11,12] Peritoneal involvement may occur due to spread of the bacilli from mesenteric lymph node. However, one-third of cases show abdominal lymph node and peritoneal TB without any evidence of gastrointestinal involvement.^[13] Abdominal TB is characterized by different modes of presentations, namely, chronic, acute, and acute on chronic, or it may be an incidental finding at laparotomy for other diseases;^[14] the clinical presentation depends on the site and type of involvement. It usually runs an indolent course and presents late with complications, especially acute or subacute intestinal obstruction due to mass (tuberculoma) or stricture formation in small gut and ileocecal region or gut perforation, leading to peritonitis.^[15] Whereas intestinal (enteric) TB exists in one of the three main forms, i.e. ulcerative, hypertrophic or ulcerohypertrophic causing fibrous strictures, while peritoneal involvement (TB peritonitis) exists in four main forms, namely, ascitic, loculated (encysted), plastic (fibrous), and purulent forms.^[16,17] The lymph nodes in the small bowel mesentery and the retroperitoneum are commonly involved, and these may caseate and calcify. Disseminated abdominal TB involving the gastrointestinal tract, peritoneum, lymph nodes, and solid viscera has also been described.^[17] The diagnosis of abdominal TB in initial stages is difficult as the clinical features are vague, diverse and there is no specific diagnostic test. It remains a considerable diagnostic challenge, especially in the absence of pulmonary infection, as the disease can mimic various gastrointestinal disorders, particularly the inflammatory bowel disease, colonic malignancy, or other gastrointestinal infections. The most common complication of intestinal TB is intestinal obstruction attributed to strictures or by adhesions. In India, approximately 3–20% of all cases of bowel obstruction are due to the TB.^[18,19] One of the serious complications of abdominal TB is perforation, causing high morbidity and mortality and it accounts for 5–9% of small intestinal perforations.^[20] Surgical intervention is reserved only for complications such as obstruction, perforation, fistula, or a mass which does not resolve with medical therapy. In most cases, a trial of medical therapy should be undertaken before surgical intervention.^[21] Mortality rate has come down to 3% from 20% to 50% after introduction of antitubercular chemotherapy and multidrug treatment. Surgical management of abdominal

TB (intestinal TB) has changed considerably from bypass operations, hemicolectomies to conservative resections, and stricturoplasties.^[22] This study aims at a fresh look in to abdominal TB and at a better understanding of its clinical manifestations, diagnostic modalities, management, and its complications.

METHODS

The study was conducted at Guru Gobind Singh Hospital, M. P. Shah Medical College, Jamnagar, Gujarat, India, during May 2005–May 2007. This study had included 25 confirmed cases of abdominal TB.

Detailed history, physical examination, and most of the investigations such as complete blood counts, erythrocyte sedimentation rate (ESR), sputum examination, and radiological investigations (X-ray chest, X-ray abdomen, and ultrasound of abdomen) were done in all cases.

Barium meal, barium enema, Mantoux test, and ascitic fluid examination were carried out when indicated.

In all cases, histopathological examination of biopsy material was done when biopsy was performed. Culture and guinea-pig inoculation could not be done due to inadequate facility.

In follow-up, all relevant medical data were inquired and recorded. Results of treatment given were analyzed and necessary corrections were made.

RESULTS

In this study, of 25 patients, 96% were Hindus and 4% were Muslims which indicate majority of Hindu people living in this region [Table 1]. In addition, majority of people (72%) belonged to low-income group (annual income <10,000 INR/year) while 28% of people were from middle-income group (annual income between 10,000 and 20,000 in a year) [Table 2]. No age is bar to abdominal TB but, in our study, minimum and maximum age of patients were 9 years and 60 years, respectively.

The most common age groups affected with abdominal TB were 10–39 years which account for 64%. In total, 68% of males (17 of 25) and 32% of females (8 of 25) were affected with disease [Table 3] which bring the male-to-female ratio around 3:2.

In our study, 68% of patients presented with chronic complaints while 32% presented with acute complaints (duration of symptoms within 15 days) [Table 4]. The most

common acute presentation was intestinal obstruction in our study.

In all patients, abdominal pain (100%) was the main presenting complaints followed by anorexia (96%), fever (60%), vomiting (52%), constipation (40%), loss of weight (40%), abdominal distension (24%), and diarrhea (16%) in descending orders. The least common complaints were lump in abdomen accounts for 8% only in this study [Table 5].

The most common intraoperative procedure was release of adhesions/bands among small intestines (36%) followed by stricturoplasty (22%) and intestinal resection and anastomosis (18%). Meanwhile, the least common procedures were perforation closure and right hemicolectomy both had 4% of recurrence in this study [Figure 1].

Table 1: Race and religion distribution

| Religions | Numbers | Percentage |
|-----------|---------|------------|
| Hindus | 24 | 96 |
| Muslims | 1 | 4 |
| Total | 25 | 100 |

Table 2: Income group-wise distribution

| Income groups | Numbers | Percentage |
|---------------|---------|------------|
| Low income | 18 | 72 |
| Middle income | 7 | 28 |
| High income | 0 | 0 |
| Total | 25 | 100 |

Table 3: Age group-wise distribution

| Age groups in years | Males | Females | Total | Percentage |
|---------------------|-------|---------|-------|------------|
| 0–9 | 1 | 0 | 1 | 4 |
| 10–19 | 3 | 3 | 6 | 24 |
| 20–29 | 3 | 3 | 6 | 24 |
| 30–39 | 4 | 0 | 4 | 16 |
| 40–49 | 4 | 1 | 5 | 20 |
| 50–59 | 1 | 1 | 2 | 8 |
| 60–69 | 1 | 0 | 1 | 4 |
| Total | 17 | 8 | 25 | 100 |

Table 4: Acute versus chronic presentation

| Presentation | Numbers | Percentage |
|--------------|---------|------------|
| Chronic | 17 | 68 |
| Acute | 8 | 32 |
| Obstruction | 4 | 16 |
| Perforation | 1 | 4 |
| Peritonitis | 1 | 4 |
| RIF lump | 2 | 8 |

RIF: Right iliac fossa

The prominent histopathological findings in descending order of frequency were hyperplastic lesions in small bowels (32%), mesenteric lymph nodal disease (24%) (caseation necrosis and giant cells presence), stricturous lesions in small bowels (20%), and peritoneal surface miliary lesions (16%). The least frequent findings were ulcerative bowel lesions and dense serosal adhesions with same recurrence of 4% [Figure 2].

In this study, tuberculous infections to intraabdominal organs with the highest degree of involvement is seen with small intestines(32%), followed by mesenteric lymph nodes (24%), appendix with ileocecal junction (20%), peritoneal surface (16%) and large intestines (8%) in decreasing order of frequency. We have not encountered any cases with involvement of stomach, duodenum, rectum, and anal canal [Table 6].

DISCUSSION

In our series, in all cases, tissues were sent for histopathological examination and positive histology was obtained in all cases whether in the form of presence of tubercle bacilli in 60% of cases while caseation necrosis/ giant cell in remaining 40% of cases.

In our series, no post-operative death has occurred. Two patients had post-operative wound infections. One patient developed diarrhea after conservative ileocecal resection. Post-operative fecal fistula was not found in a case.

Table 5: Signs and symptoms of distribution

| Signs and symptoms | Presence of symptoms (of 25 cases) | Percentage |
|----------------------|------------------------------------|------------|
| Abdominal pain | 25 | 100 |
| Anorexia | 24 | 96 |
| Fever | 15 | 60 |
| Vomiting | 13 | 52 |
| Constipation | 10 | 40 |
| Loss of weight | 10 | 40 |
| Abdominal distension | 6 | 24 |
| Diarrhea | 4 | 16 |
| Lump in abdomen | 2 | 8 |

Table 6: Site of lesions

| Anatomical site | Number of cases | Percentage |
|---------------------------------|-----------------|------------|
| Stomach and duodenum | 0 | 0 |
| Small intestines | 8 | 32 |
| Appendix and ileocecal junction | 5 | 20 |
| Large intestines | 2 | 8 |
| Peritoneal tubercles | 4 | 16 |
| Mesenteric lymph nodes | 6 | 24 |
| Rectum and anal canal | 0 | 0 |

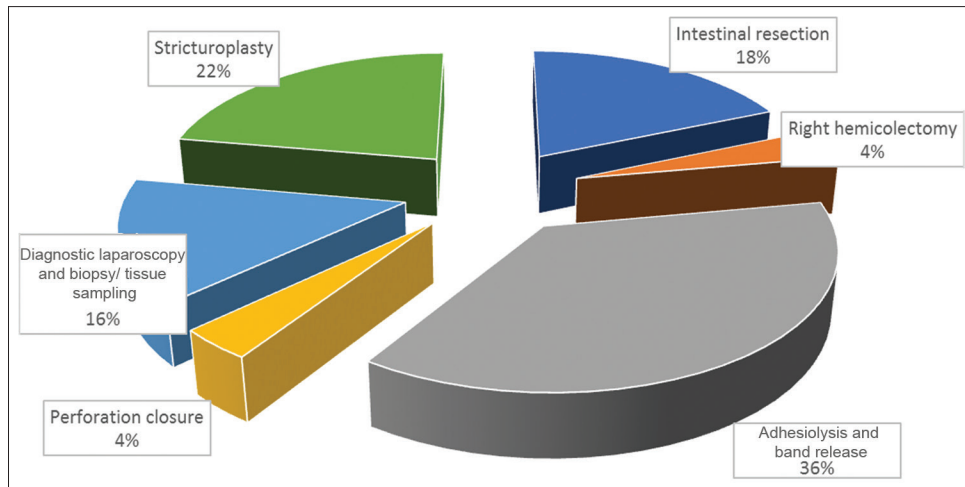


Figure 1: Types of operative procedures

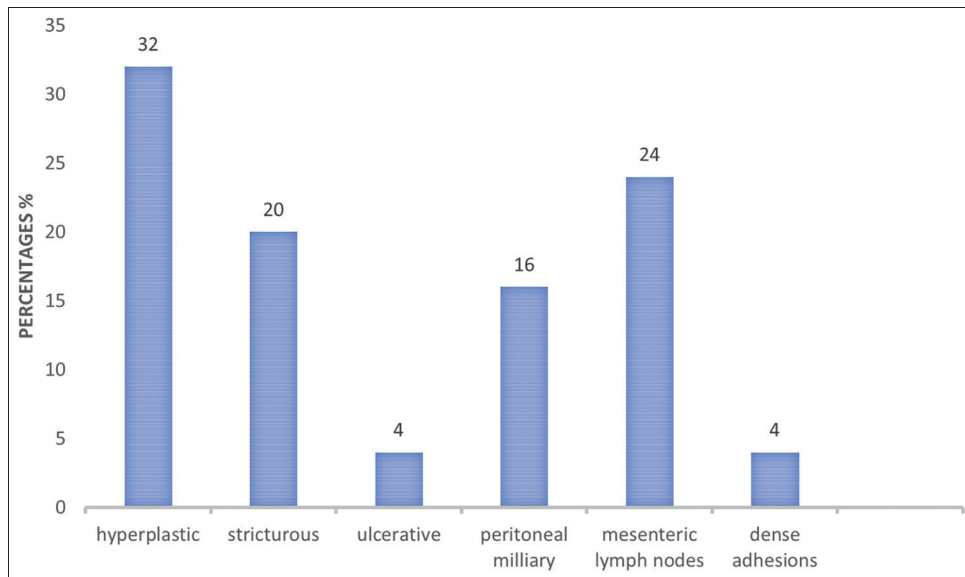


Figure 2: Types of lesions

Follow-up was done in all cases. Follow-up schedule was like, every 15 days visit for initial 3 months, then every month for a year. In follow-up visit, patients were inquired about symptoms, any post-operative complaints, duration, and regularity of AKT. Any change in weight, appetite, and general condition were noted along with hemoglobin and ESR values.

Patient conditions were classified under the following headings:

- Well = No complaints
- Improved = Overall improvement in symptoms, weight gain, good appetite, good and general conditions but some vague, inconstant abdominal symptoms revealed only when interrogated carefully
- Not improved = Little benefit from operation.

In our series, 20 patients became well accounts for 80% while 5 patients (20%) were improved with treatment. In our series, there was not any patient with no improvement.

CONCLUSIONS

Koch's abdomen is a clinical entity with varied clinical presentations. It is widely prevalent in developing country like India and most often present with complications. It's quite crucial for clinicians to rule out Koch's abdomen from other conditions who can mimic with it. Most of the patients are cured with conservative treatment with anti-TB drugs. Surgery is required in case of complications occurred. No drug resistance has been found in this study.

Investigations play a major role in establishing the diagnosis and treating the patients.

ACKNOWLEDGMENT

I reckon great efforts of my PG teacher Dr. Kishan D Shah and our Departmental Head, Professor in General Surgery, Dr. Sudhir G Mehta for guiding me in this study with utmost knowledge sharing and great help to accomplish this study. I also acknowledge our surgical unit operative and ward staff for managing patients, tirelessly. Needless to say, our patients who had put faith in our surgical team and giving us the opportunity to serve them and finally, my parents and my wife, for their motivation and mental support to bring this case study to the forum. I also acknowledge all my seniors, reviewers, and critics for their timeless guidance and support in my career.

REFERENCES

1. Kumar V, Abbas AK, Fausto N, Mitchell RN. Robbins Basic Pathology. 8th ed. Philadelphia, PA: Saunders Elsevier; 2007. p. 516-22.
2. World Health Organization. Tuberculosis Fact Sheet No. 104. Geneva: World Health Organization; 2010.
3. Konstantinos A. Testing for tuberculosis. *Aust Prescr* 2010;33:12-8.
4. Park K, editor. Park's Textbook of Preventive and Social Medicine. 19th ed. India: M/S Banarasidas Bhanot; 2007. p. 768.
5. Kapoor VK. Abdominal tuberculosis: The Indian contribution. *Indian J Gastroenterol* 1998;17:141-7.
6. Wadhwa N, Agarwal S, Mishra K. Reappraisal of abdominal tuberculosis. *J Indian Med Assoc* 2004;102:31-2.
7. Shukla S, Kumar K. Spectrum of clinical presentation of abdominal tuberculosis and its surgical management. *Int Surg J* 2018;5:1482-7.
8. Mandell GL, Bennett JE, Raphael D. Mandell, Douglas, and Bennett's Principles and Practice of Infectious Diseases. 7th ed. Philadelphia, PA: Churchill Livingstone/Elsevier; 2010. p. 839-43.
9. Gibson PG, Abramson M. Evidence-based Respiratory Medicine. Oxford: Blackwell; 2005. p. 321.
10. Behera D. Textbook of Pulmonary Medicine. 2nd ed. New Delhi: Jaypee Brothers Medical Publisher; 2010. p. 457.
11. Bhansali SK. Abdominal tuberculosis. Experiences with 300 cases. *Am J Gastroenterol* 1977;67:324-37.
12. Paustian FF, Marshall JB. Intestinal tuberculosis. In: Berk JE, editor. *Bockus Gastroenterology*. 4th ed. Philadelphia, PA: WB Saunders; 1985. p. 2018-36.
13. Hoon JR, Dockerty MB, Pemberton Jde J. Ileocecal tuberculosis including a comparison of this disease with nonspecific regional enterocolitis and noncaseous tuberculated enterocolitis. *Int Abstr Surg* 1950;91:417-40.
14. Vimlesh K, Seth SK. Essentials of Tuberculosis in Children. 3rd ed. New Delhi: Jaypee Brothers Medical Publishers; 2006. p. 249.
15. Thomson A, Miles A. Manual of Surgery. New York: Kaplan Publishing; 2008. p. 75.
16. Jindal SK. Textbook of Pulmonary and Critical Care Medicine. New Delhi: Jaypee Brothers Medical Publishers; 2011. p. 549.
17. Golden MP, Vikram HR. Extrapulmonary tuberculosis: An overview. *Am Fam Physician* 2005;72:1761-8.
18. Bhansali SK, Sethna JR. Intestinal obstruction: A clinical analysis of 348 cases. *Indian J Surg* 1970;32:57-70.
19. Tandon RK, Sarin SK, Bose SL, Berry M, Tandon BN. A clinico-radiological reappraisal of intestinal tuberculosis – changing profile? *Gastroenterol Jpn* 1986;21:17-22.
20. Talwar S, Talwar R, Prasad P. Tuberculous perforations of the small intestine. *Int J Clin Pract* 1999;53:514-8.
21. World Health Organization. Global Tuberculosis Control 2012. Geneva: World Health Organization; 2012. Available from: http://www.who.int/tb/publications/global_report/en/index.html. [Last accessed on 2011 Apr 11].
22. Marshall JB. Tuberculosis of the gastrointestinal tract and peritoneum. *Am J Gastroenterol* 1993;88:989-99.

How to cite this article: Sondarva NP, Shah KD, Mehta SG. A Study of 25 Diagnosed Cases of Abdominal Tuberculosis – A Review Article. *Int J Sci Stud* 2019;7(6):50-54.

Source of Support: Nil, **Conflict of Interest:** None declared.