Print ISSN: 2321-6379
Online ISSN: 2321-595X

Original Article

Role of Cross-sectional Imaging in Biliary Tract Malignancies in Therapeutic Decision-making

Prashant Yadav[1], Salil Pandey[2], A Suresh[3], Madan Mohan Babu[4], Rajan Aggarwal[5]

[1]3rd Year Post Graduate Student, Department of Radiodiagnosis, Vydehi Institute of Medical Sciences and Research Centre, Bengaluru, Karnataka, India, [2]Associate Professor, Department of Radiodiagnosis, Vydehi Institute of Medical Sciences and Research Centre, Bengaluru, Karnataka, India, [3]Professor and Head, Department of Radiodiagnosis, Vydehi Institute of Medical Sciences and Research Centre, Bengaluru, Karnataka, India, [4]Professor, Department of Radiodiagnosis, Vydehi Institute of Medical Sciences and Research Centre, Whitefield, Bangalore, India, [5]2nd Year Post Graduate Student, Department of Radiodiagnosis, Vydehi Institute of Medical Sciences and Research Centre, Bengaluru, Karnataka, India

Abstract

Introduction: Role of cross-sectional imaging in biliary tract malignancies in therapeutic decision-making plays an very important role.

Materials and Methods: Ethical committee clearance and informed consent were taken from 57 patients of suspected biliary tract malignancies who underwent Triphasic computed tomography (CT) and in whom these malignancies were histopathologically confirmed. Based on imaging findings and clinical parameters, the tumors were deemed operable and non-operable by experienced radiologists and operating oncosurgeons. In operable cases, the CT findings were compared with the intraoperative findings and the correlation was studied. Inoperable tumors were considered for palliative stenting with either endoscopic retrograde cholangiopancreatography (ERCP) or percutaneous transhepatic biliary drainage (PTBD). A prediction of feasibility or non-feasibility for successful ERCP was done based on imaging findings. A reasonable follow-up of the patients was done following surgery, ERCP, or PTBD to ascertain the effectiveness of these measures on the overall patient's outcome.

Results: We found that the CT findings were accurate in predicting operability in patients with biliary tract malignancies and CT findings correlated with intraoperative findings in majority of the operable cases. CT had sensitivity of 81.25%, specificity of 100%, positive predictive value (PPV) of 100%, negative predictive value (NPV) of 93.18%, and diagnostic accuracy of 94.74% in predicting operability. We also observed that the accuracy of CT in predicting feasibility or non-feasibility of successful ERCP-guided stenting was satisfactory in cases of non-operable tumors. CT had sensitivity of 71.43%, specificity of 84.62%, PPV of 90.91%, NPV of 57.89%, and diagnostic accuracy of 75.61% in predicting ERCP feasibility.

Conclusion: CT imaging findings were very helpful in deciding operability and non-operability in cases with hepatobiliary malignancies. CT imaging findings were further very useful in deciding feasibility of ERCP-guided stenting in non-operable tumors. Overall, cross-sectional imaging played a key role in imaging of patients with hepatobiliary malignancies in deciding the best therapeutic options for the patients.

Key words: Computed tomography, Gallbladder, Reduced dose, Standard dose, Ultrasonography

INTRODUCTION

Cancers of the biliary tract are one of most common malignancies of hepatobiliary system being second most common after hepatocellular carcinoma. Cancers of the biliary tract can be seen to occur in any part of biliary tree. Accurate pre-operative assessment of these tumors by the radiologist is of paramount importance, since the entire therapeutic management is dependent on it. Unnecessary major surgeries can be avoided if non-operability factors can be accurately identified and these patients can be diverted to other palliative therapeutic options which are more suitable in these advanced stages.

Our study also aims to assess suitability for endoscopic retrograde cholangiopancreatography (ERCP) or percutaneous transhepatic biliary drainage (PTBD) in non-operable tumors and assess, whether it is possible to predict non-feasibility of

Access this article online

www.ijss-sn.com

Month of Submission : 04-2022
Month of Peer Review : 05-2022
Month of Acceptance : 05-2022
Month of Publishing : 06-2022

Corresponding Author: Dr. Prashant Yadav, C-0315, Divyasree Republic of Whitefield Apartments, Bengaluru, Karnataka, India.

ERCP in certain situations. This can be helpful in avoiding unnecessary procedures and proceeding directly to the relevant therapeutic option, minimizing patient discomfort.

MATERIALS AND METHODS

- The ethical committee of VIMS and RC gave the ethical clearance and informed consent was obtained from all the patients
- The study population included 57 patients with obstructive jaundice with suspected biliary tract malignancies and in whom these malignancies were histopathologically confirmed
- Triphasic CT was performed on all the patients with Siemens Somatom Definition AS 128 slice multi-detector CT scanner with 5 mm collimation and a gantry speed of 0.05 s and pitch of 1.2 s, 120kvP, and 345 effective mAs [Figure 1]. First, a non-contrast axial cuts were obtained; thereafter, contrast was administered (Omnipaque (Iohexol) – 350 mg I/ml), typical doses of 1.5 mg/kg (60–90 ml) through pressure injector (Imaxeon, SW version – 1.5–0.12) using smart prep software (RCU manager) [Figures 2 and 3] and arterial, venous, and delayed phase were obtained. The typical scan parameters involved 5 mm and 1 mm slice thickness, coronal, axial, and sagittal reconstruction, with 120 MA and 60-80 Kvp
- The CT examinations were analyzed on dedicated work stations, this included Aquarius systems or Syngovia dedicated work station.

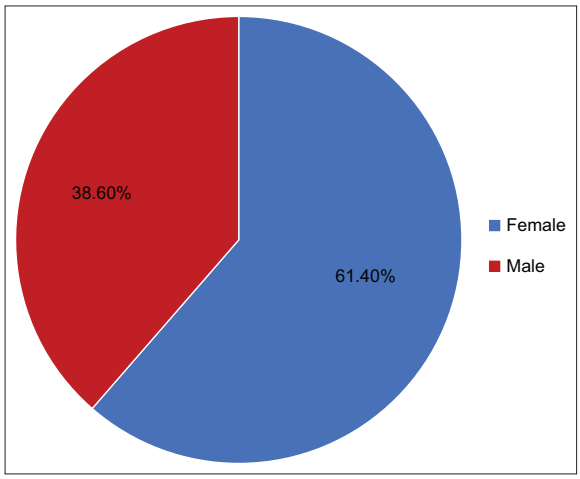

Figure 1: Siemens Somatom Definition AS 128 slice Multi-detector CT scanner – Pie diagram showing sex distribution of subjects

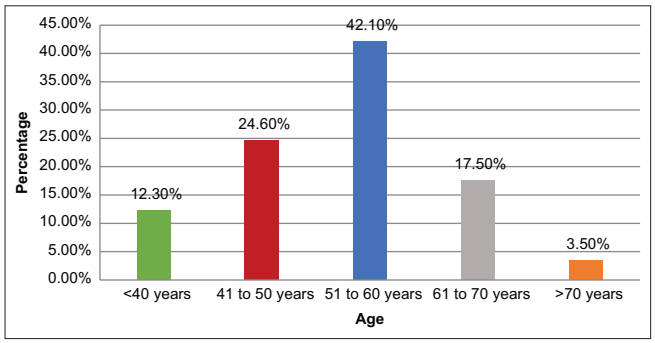

Figure 2: Smart prep software (RCU manager) – Bar diagram showing Age distribution of subjects

Inclusion Criteria

All patients with obstructive jaundice who present for CT imaging in department of radiology with suspected biliary tract malignancies and in whom these malignancies were ultimately confirmed.

Exclusion Criteria

The following criteria were excluded from the study:

- Cases in whom histopathological confirmation could not be done or in whom it is repeatedly negative
- Cases which were not ready for any further treatment following imaging diagnosis
- Patients without obstructive jaundice
- Patient allergic to contrast media
- Patients with high creatinine value secondary to renal failure.

The following details were analyzed:[1-4]

1. The size and location of the lesion
2. Level of biliary obstruction
3. Type of block: The block was classified according to Bismuth Corlette classification into type I, II, IIIa, IIIb, and IV
4. Extent of involvement of liver parenchyma
5. Involvement of adjacent structures or organs
6. Vessel encasement or abutment (to be mentioned in degrees)
7. Presence of locoregional or distant lymph nodal involvement

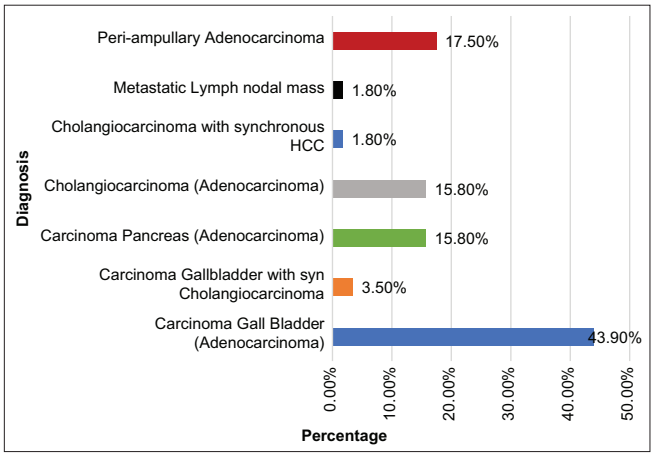

Figure 3: Pressure injector (Imaxeon, SW version – 1.5-0.12) – Bar diagram showing diagnosis distribution

8. Presence of peritoneal deposits
9. Presence of any distant metastases or metastatic lesions within the liver.

Histopathological confirmation of malignancy was obtained in all patients. Operability was assessed jointly by experienced radiologists and operating oncosurgeons in a multidisciplinary team meeting taking into the account the imaging findings and the other clinical parameters.[5-8]

In presence of following parameters, the tumor was deemed inoperable -

- Presence of metastatic lesions within or outside liver
- Presence of metastatic lymph nodes apart from locoregional lymph nodes in porta hepatis or Para duodenal region
- Type IV block with tumor extending into intrahepatic segmental ducts
- Encasement of hepatic artery: Minor degrees of abutment were considered equivocal and an operative exploration will be needed in such cases
- Encasement or obstruction of portal vein (minimal focal abutment is not a contraindication)
- Extensive contiguous infiltration of liver parenchyma with involvement of two or more segments precluding liver resection due to inadequate liver FLR
- An advanced block such as type IIIa or IIIb was considered inoperable in case of certain patient's factors such as – advanced age with poor performance status in presence of inadequate FLR precluding an extensive liver resection or in non-compliant patients who are unwilling for an extensive liver resection.

Based on above criteria, the lesions were classified as operable or inoperable. In operable cases, the findings on CT were compared with the intraoperative findings and the correlation was studied.[9,10]

Inoperable tumors were considered for palliative stenting with either ERCP or PTBD. A prediction of feasibility or non-feasibility for successful ERCP was done based on imaging findings. A non-feasibility or failure of ERCP was predicted based on following imaging findings:

- Type IV Block
- Large bulky tumor masses which will preclude endoscopic passage of guide wire through the lesions. This was based on size criteria and any bulky lesion greater than 2 cm in the region of the biliary tract was a contraindication
- Extensive duodenal stenosis or anatomical distortion of duodenal or ampullary region by lesions which will preclude passage of endoscope
- Irrespective of the predictivity of feasibility, all patients were first subjected to ERCP and the success and failure of ERCP was observed. Correlation was done of the predictivity from cross-sectional imaging and the outcome from ERCP.

A reasonable follow-up of the patients was done following surgery, ERCP, or PTBD to ascertain the effectiveness of these measures on the overall patient's outcome.

Statistical Analysis

Data were entered into Microsoft Excel data sheet and were analyzed using SPSS 22 version software. Categorical data were represented in the form of frequencies and proportions. Chi-square test was used as test of significance for qualitative data. Continuous data were represented as mean and standard deviation. *P*-value (Probability that the result is true) of <0.05 was considered as statistically significant after assuming all the rules of statistical tests. Statistical software: Microsoft Excel and SPSS version 22 (IBM SPSS Statistics, Somers NY, USA) were used to analyze data.[11-13]

RESULTS

A total of 57 patients who presented with obstructive jaundice and underwent triphasic CT scanning and in whom malignant causes of biliary obstruction were ultimately proved by histopathology were analyzed.

This included 22 males and 35 females [Figure 1]. The age range of the patients was from 30 to 79 years and mean age was 54. The age range in male patients was 30–79 and in female patients from 39 to 71 years and the mean age of male patients was 51 and of female patients was 54 [Figure 4]. The average duration of symptoms was of 2 months and ranged from 2 weeks to 1 year.

The chief complaints of the patients were pain abdomen, yellowish discoloration of sclera, loss of weight, and loss of appetite. The deranged LFTs were noted in all patients and the serum total bilirubin levels ranged from 1.5 to 26.5 and mean was 14. There was conjugated hyperbilirubinemia in all patients with raised direct bilirubin. There were associated liver enzyme derangements (AST/ALT/ALP) in all patients.

The size and location of the lesion are detailed in Figure 3. Liver parenchymal infiltration by the lesions was seen in eight patients, this was mainly by carcinoma of gallbladder in seven cases or mass forming cholangiocarcinoma in one case. A case of HCC was arising from the liver parenchyma itself and secondarily infiltrating the common bile duct (CBD). The segments involved by the tumors were mainly V and IV in seven cases with tumor extending into segment

VII as well in one case. With respect to involvement of adjacent structures or organs, there was additional infiltration of duodenum by carcinoma of head/uncinate process of pancreas in five cases and an infiltration from the adjacent duodenal bulb into the biliary system in three cases.

There was complete hepatic artery encasement in eight cases, partial hepatic artery encasement (< 180°) in three cases, superior mesenteric artery encasement in four cases, superior mesenteric vein encasement in three cases and significant portal vein encasement (more than 180°) in twelve cases. The vascular encasement was maximum in cases with carcinoma of head/uncinate process of while periampullary carcinomas had minimal vascular involvements.

The presence of locoregional lymph nodal involvement defined as enlarged nodes (more than 5 mm in short axis) in the porta hepatis, paraduodenal, or precaval region which were present in 22 cases. A distant nodal metastatic disease (defined as enlarged nodes, more than 5 mm in short axis in para-aortic regions or beyond) was noted in 25 cases. All these distant nodes were evaluated using CT-guided fine-needle aspiration cytology (FNAC) and proven to be containing metastatic deposits. There was presence of peritoneal deposits, noted as containing small enhancing nodules or frank omental thickening or caking in nine cases. There was presence of liver metastases in 11 cases and distant metastases (involving bones or lungs) in one case [Figure 5].

The type of block seen is detailed in Figure 4. The malignant etiology responsible for the lesions is highlighted in table. The details of histopathological confirmation obtained are enlisted in Figure 6. After detailed analysis of the imaging features and the histopathogical confirmation, the operability was discussed in a multidisciplinary team consisting of operating surgical oncologists specializing in liver resections and hepatobiliary surgeries. Based on the criteria listed above, 16 tumors were considered operable and 41 tumors were inoperable [Figure 7]. The details of factors which rendered the tumors inoperable either present alone or in combination are listed in Figures 7 and 8.

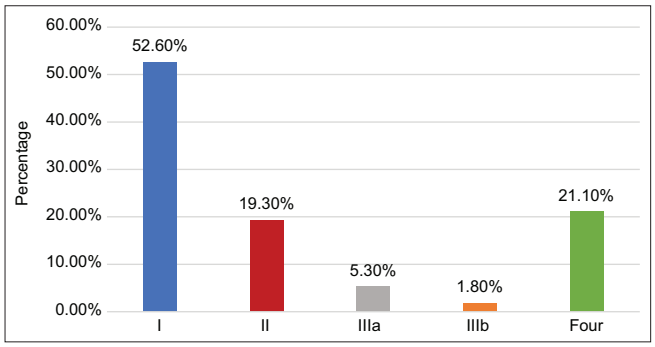

Figure 4: Bar diagram showing type of block

For the tumors considered operable, a comparison of intraoperative findings was done with the CT findings. The CT findings were accurate in predicting operability in 13 cases and correlated. There was non-correlation noted in three cases [Figure 9]. Overall, the predictive value of CT in predicting operative feasibility for hepatobiliary tumors was found to be as detailed in [Figure 10]. In the study, type of block, vascular involvement, and distant metastasis in imaging determined operability.

Parameter	Estimate (%)	Lower–Upper 95% CIs
Sensitivity	81.25	56.99, 93.41
Specificity	100	91.43, 100
Positive predictive value	100	77.19, 100
Negative predictive value	93.18	81.77, 97.65
Diagnostic accuracy	94.74	85.63, 98.19

CT had sensitivity of 81.25%, specificity of 100%, positive predictive value (PPV) of 100%, negative predictive value

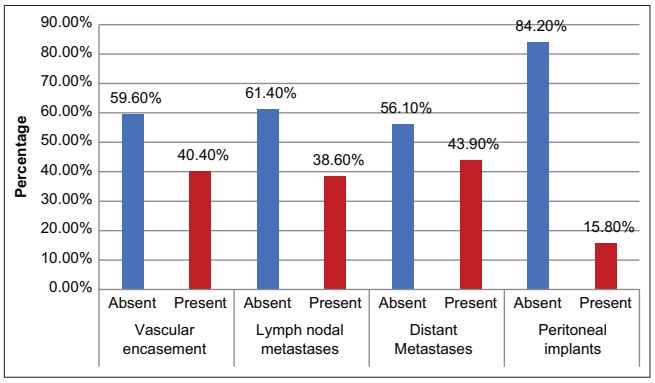

Figure 5: Bar diagram showing imaging findings

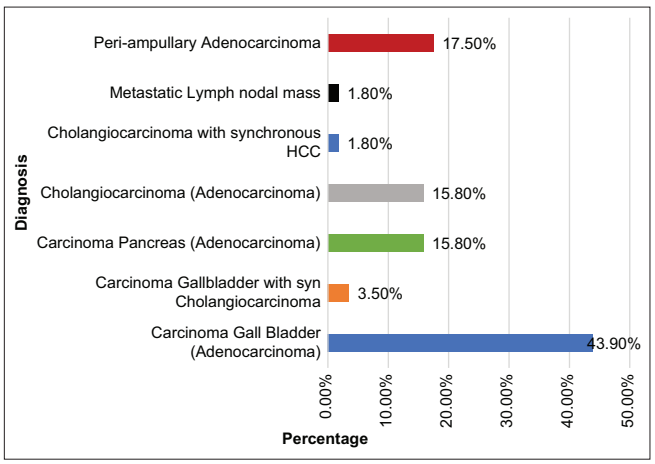

Figure 6: Bar diagram showing tissue diagnosis (HPE) distribution

(NPV) of 93.18%, and diagnostic accuracy of 94.74% in predicting operability. The major factors for non-operability were advanced level of block, presence of metastatic disease, or vascular encasements precluding resections.

Of the non-operable cases, 40 cases were considered for a palliative biliary stenting through either ERCP or PTBD. One case was not considered for any stenting as their performance status was too low to tolerate such procedures and a best supportive care plan was considered for them.

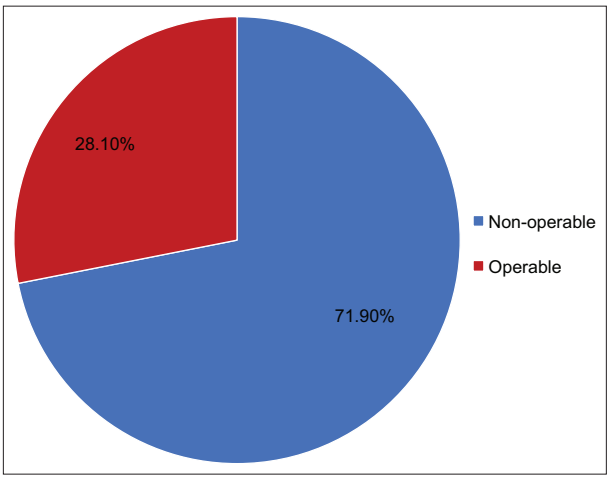

Figure 7: Pie diagram showing operability distribution

Based on the CT criteria listed above, a feasibility of ERCP was predicted in 22 cases, while ERCP was considered non-feasible in 19 cases. Of the cases, in which ERCP was considered feasible based on CT features, a successful ERCP could be performed in 20 cases, while ERCP was unsuccessful in two cases. In the cases, in which ERCP was considered not feasible based on CT criteria, the ERCP failed in 11 cases, while it was successful in eight cases [Figure 11].

Overall, the accuracy of CT in predicting successful ERCP-guided retrograde cannulation across stricture and a successful stenting is detailed in Figure 12. In cases of failed ERCP, the patients underwent PTBD and stenting and a PTBD was successful in all cases with successful negotiation of guide wire across the stricture, followed by balloon angioplasty and metallic stenting. CT had sensitivity of 71.43%, specificity of 84.62%, PPV of 90.91%, NPV of 57.89%, and diagnostic accuracy of 75.61% in predicting ERCP feasibility.

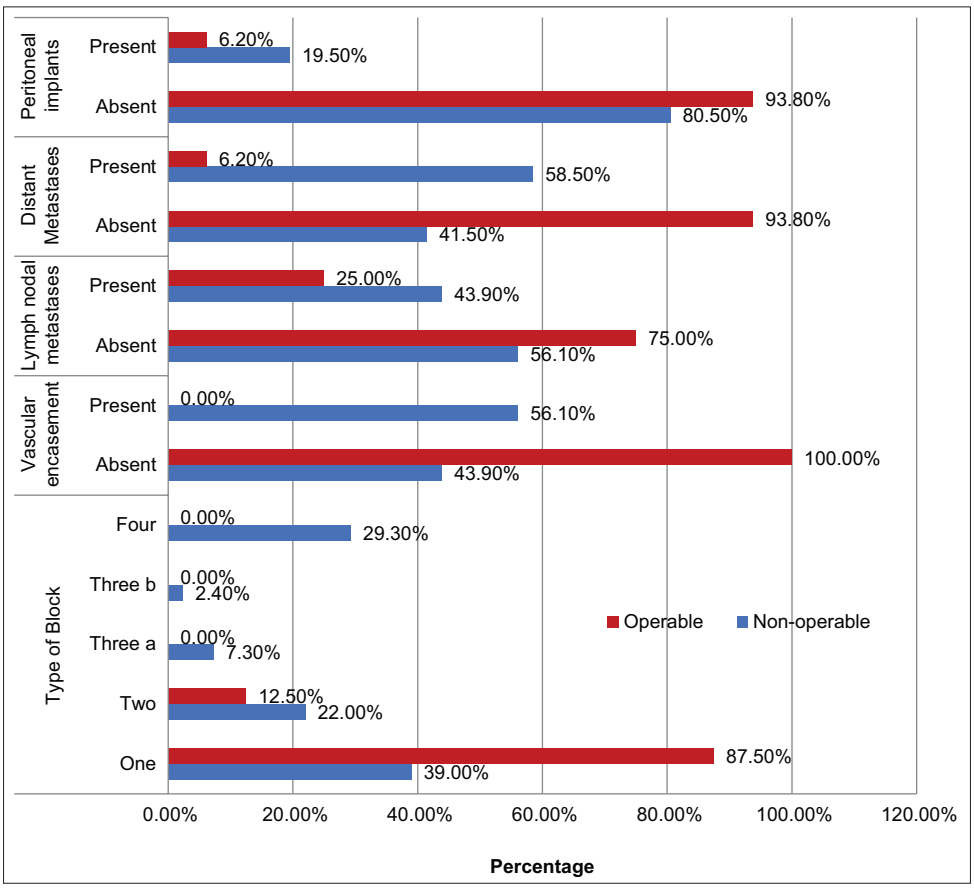

Figure 8: Bar diagram showing criteria's on cross-sectional imaging, which determine operability and non-operability of biliary tumors

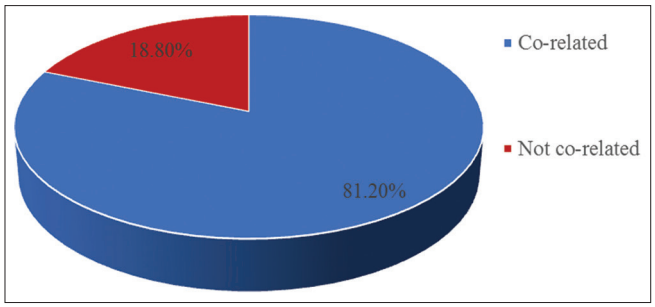

Figure 9: Bar diagram showing correlation of computed tomography findings with operability

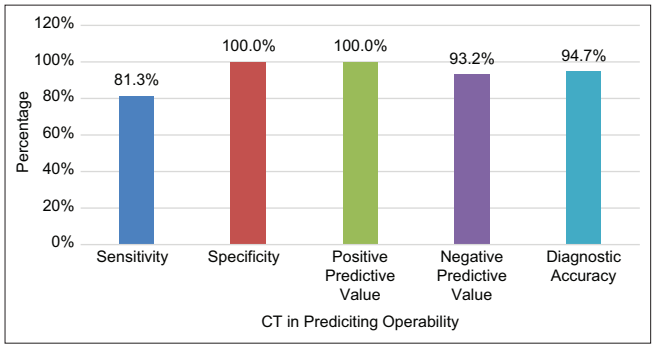

Figure 10: Bar diagram showing comparison of computed tomography findings with operability

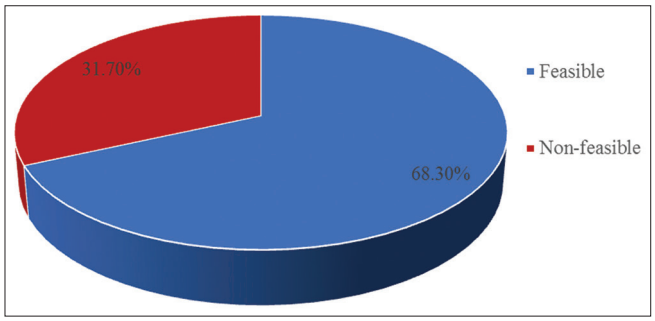

Figure 11: Pie diagram showing endoscopic retrograde cholangiopancreatography feasibility distribution among non-operable subjects

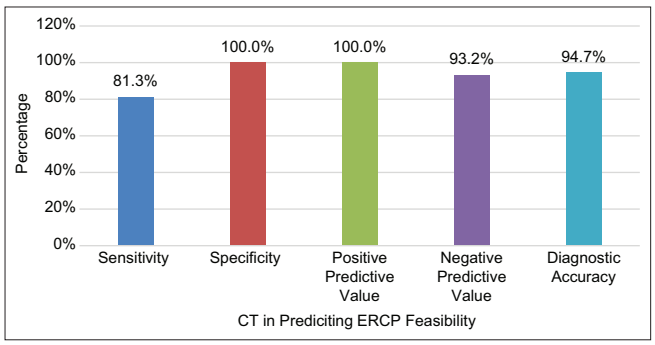

Figure 12: Bar diagram showing comparison of computed tomography findings with endoscopic retrograde cholangiopancreatography feasibility

ILLUSTRATIVE CASES

Case 1

Cholangiocarcinoma.

CT findings

There was obstruction at the biliary confluence with extension across the confluence into the right and left hepatic ducts suggestive of type IV block [Figures 13 and 14]. There was extensive obstruction on the right side with extension up to the third order biliary branches. The obstruction on the left was lesser with extension up to the secondary confluence. There was associated mild atrophy of the right lobe of liver.

MRCP findings

Suggests dilated IHBR and hepatic ducts with obstruction at the region of common duct- likely by soft-tissue stricture. Since the lesions were stricturous, but there was extensive type IV block; hence, a ultrasound (USG)-guided FNAC from the stricturous lesions causing ductal separation in the right lobe was done.

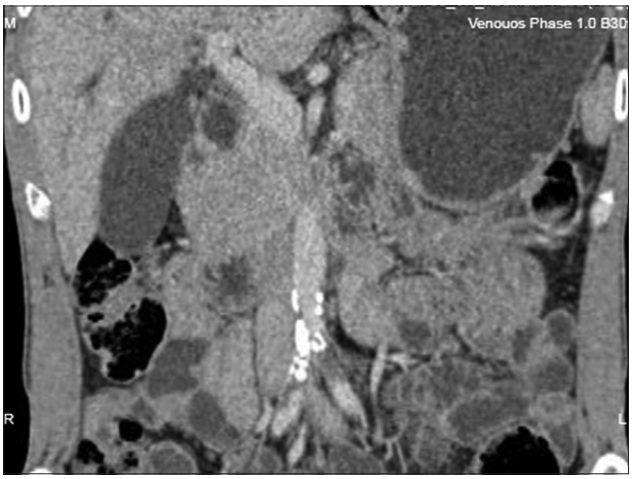

Figure 13: Type IV block

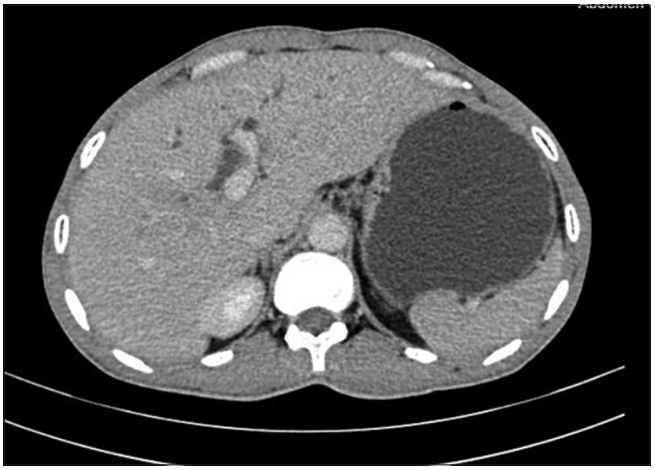

Figure 14: Type IV block

USG-guided FNAC (HPE report)

Adenocarcinoma and suggestive of cholangiocarcinoma.

Operability

The lesion was considered inoperable due to advanced type IV block. ERCP was considered not feasible due to type IV block. Plan was palliative stenting.

ERCP was not successful and failed and wire could not be negotiated across the stricture. The patient underwent PTBD and biliary stenting. The left PTBD was done and a metallic stent was placed across the stricture, since the right lobe was atrophic due to segmental blocks and most of the drainage was from the left lobe [Figure 15]. Post-stenting results were excellent with subsidence of jaundice and excellent results were noted up to a follow-up period of 6 months.

Case 2

Carcinoma Gallbladder.

CT findings

Necrotic mass arising from fundus of gallbladder with extension into subcapsular region and adjacent omental and pericolic fat stranding. The lesion shows indistinct fat planes with hepatic flexure and is causing Type I Block [Figures 16 and 17].

USG-guided biopsy (HPE)

Adenocarcinoma and carcinoma gallbladder.

Operability

Tumor was deemed operable.

Name of procedure

Radical Cholecystectomy.

Operative details

Tumor gallbladder involving segment IVb and V of liver.

Case 3

Carcinoma head of Pancreas.

CT findings

Multicystic well-defined lesion with enhancing internal septations within involving the head of pancreas with extensions, lesion is seen compressing 1st and 2nd part of duodenum, and focally abutting right kidney and gallbladder, superiorly lesion is abutting the left renal vein and causing mild compression of IVC type I block [Figures 18 and 19].

Intraoperative surgical specimen (HPE report)

Adenocarcinoma and carcinoma head of pancreas.

Operability

Operable.

Figure 16: Hypervascular enhancing gallbladder mass

Figure 15: Stent in place

Figure 17: Infiltration in segment IV b and V of liver

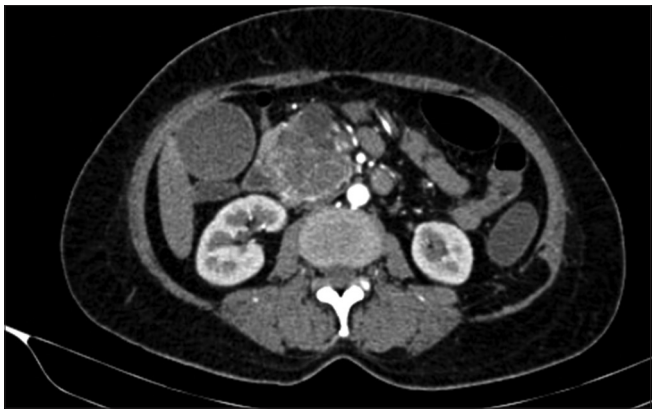

Figure 18: Enhancing lesion involving the head of pancreas

Figure 19: Type I block

Operative findings

Operative findings showed bulky nodular lesion in the head of pancreas with solid and cystic components causing type I block.Operative findings correlated with the CT findings.

DISCUSSION

Our study analyses the cross-sectional imaging findings in a large subset of patient population presenting with obstructive jaundice due to malignant causes. Obstructive jaundice due to malignant biliary obstruction is an important and common presentation in tertiary care referral cancer center such as ours and this study helped us to gain insights into different facets of this important clinical entity with regard to its imaging, which ultimately plays a crucial role in the entire subsequent patient management.

CONCLUSION

Our study aimed to evaluate the role of the role of cross-sectional imaging in biliary tract malignancies in therapeutic decision-making. With the study group of 57 patients with suspected, biliary tract malignancies undergoing triphasic CT scanning and the malignancies confirmed histopathologically. We observed that triphasic CT imaging was very accurate in deciding operability and non-operability in biliary tract malignancies and was also very useful in predicting feasibility or non-feasibility of successful ECRP-guided stenting in non-operable tumors.

Our goal of the study to assess the role of cross-sectional imaging in biliary tract malignancies was achieved. We found that triphasic CT imaging played a very key role in in deciding the best therapeutic management options for the patients.

ACKNOWLEGDMENT

First, I would like to express my profound gratitude to my institute and its management; Vydehi Institute of Medical Sciences and Research Center and our Director, Mrs. Kalpaja DA for providing me the opportunity and the necessary facilities for this research. My sincere thanks to Dr. Salil Pandey, MD for the continuous support of my study and related research, for his patience, motivation, and immense knowledge. My heart full thanks to my head of the department Dr. Prof. Suresh. A, MD for allowing me to utilize the services of the department at timely basis and giving me opportunity to carry out my tasks. I would also like to thank the rest of my department staff, for their insightful comments and encouragement, but also for the hard questions which incented me to widen my research from various perspectives. In addition, I thank my Assistant Professors, Senior Residents, seniors, colleagues, and juniors for the stimulating discussions and advice throughout the years. Last but not the least, my deepest gratitude and ardent thanks to my family: My parents, Mrs. Pushpa and Mr. Achal Singh Yadav, and my brother Rahul Yadav and Abhinav Yadav, for their wise counsel, unrelenting attention and sympathetic ear throughout Dr. Prashant Yadav.

REFERENCES

1. Freeny PC. Computed tomography in the diagnosis and staging of cholangiocarcinoma and pancreatic carcino. Ann Oncol 1999;10 Suppl 4:12-7.
2. Halefoglu AM. Magnetic resonance cholangiopancreatography: A useful tool in the evaluation of pancreatic and biliary disorders. World J Gastroenterol 2007;13:2529-34.
3. Hennedige TF, Neo WT, Venkatesh SK. Imaging of malignancies of the biliary tract-an update. Cancer Imaging 2014;14:14.
4. Han JK, Choi BI, Kim AY, An SK, Lee JW, Kim TK, *et al.* Cholangiocarcinoma: Pictorial essay of CT and cholangiographic findings. Radiographics 2002;22:173-87.
5. Mahajan MS, Moorthy S, Karumathil SP, Rajeshkannan R, Pothera R. Hilar cholangiocarcinoma: Cross sectional evaluation of disease Spectrum. Indian J Radiol Imaging 2015;25:184-92.

6. Wang J, Bo X, Shi X, Suo T, Xin Y, Nan L, *et al.* Modified staging classification of gallbladder carcinoma on the basis of the 8th edition of the American joint commission on cancer (AJCC) staging system. Eur J Surg Oncol 2020;46:527-33.
7. Buck JL, Elsayed AM. Ampullary tumors: Radiologic-pathologic correlation. Radiographics 1993;13:193-212.
8. Cloyd JM. Staging for ampullary carcinoma: Is less actually more? Ann Surg Oncol 2019;26:1598-600.
9. Al-Hawary MM, Francis IR, Chari ST, Fishman EK, Hough DM, Lu DS, *et al*. Pancreatic ductal adenocarcinoma radiology reporting template: Consensus statement of the society of abdominal radiology and the American pancreatic association. Gastroenterology 2014;146:291-304.e1.
10. Ruys AT, Busch OR, Rauws EA, Gouma DJ, Van Gulik TM. Prognostic impact of preoperative imaging parameters on resectability of hilar cholangiocarcinoma. HPB Surg 2013;2013:657309.
11. Dakhale GN, Hiware SK, Shinde AT, Mahatme MS. Basic biostatistics for post-graduate students. Indian J Pharmacol 2012;44:435-42.
12. Sunder Rao PS, Richard J. An Introduction to Biostatistics: A Manual for Students in Health Sciences. 4th ed. New Delhi: Prentice Hall of India; 2006. p. 86-160.
13. Elenbaas RM, Elenbaas JK, Cuddy PG. Evaluating the medical literature. Part II: Statistical analysis. Ann Emerg Med 1983;12:610-20.

How to cite this article: Yadav P, Pandey S, Suresh A, Babu MM, Aggarwal R. Role of Cross-sectional Imaging in Biliary Tract Malignancies in Therapeutic Decision-making. Int J Sci Stud 2022;10(3):44-52.

Source of Support: Nil, **Conflicts of Interest:** None declared.