Print ISSN: 2321-6379
Online ISSN: 2321-595X

Original Article

Cytology, Histology, and Imaging Correlation in the Plethora of Thyroid Lesions from a Tertiary Care Center

K Gayathri[1], B Archana[1], Priya Palanisamy[2], S Rajendiran[1]

[1]Department of Pathology, Sri Ramachandra Institute of Higher Education and Research, Chennai, Tamil Nadu, India, [2]Senior Resident, Department of Radiology and Imaging Sciences, Sri Ramachandra Institute of Higher Education and Research, Chennai, Tamil Nadu, India

ABSTRACT

Introduction: Fine needle aspiration cytology (FNAC) has a pivotal role in evaluating the lesions of the thyroid. Although FNAC has distinct advantages, it has limitations too. This study was done to correlate the FNAC findings of thyroid lesions with thyroid imaging reporting and data systems classification on ultrasound and histopathological findings. We also evaluated the discordant cases and analyzed them.

Materials and Methods: Our study is a retrospective analysis of 179 cases of thyroid nodules over a period of 3 years from April 2016 to April 2019. The FNAC findings were reviewed. These data were compared with the histopathological and imaging findings and analyzed.

Results: Cytohistological correlation was done in 179 cases, 94 benign cases and 85 malignant lesions. The mean age of presentation of discordant cases was 43.2 years with male:female ratio of 1:3.8. Concordance was noted in 84% cases and discordance was noted in 15.6%, respectively. Reasons of discordance included sampling error in 11 (6.1%) cases, cystic nature of the lesion in 12 (6.7%) cases, and interpretation error/nature of the lesion in 5 (2.8%) cases. The sensitivity and specificity of FNAC was 58.3% and 100%, respectively. The positive predictive value was 100% and negative predictive value was 71.5%. Accuracy of FNAC in differentiating benign from malignant thyroid lesion was 79.6%.

Conclusion: FNAC of thyroid nodules provides the most accurate pre-operative diagnosis. It is a minimally invasive procedure and hence considered as a gold standard diagnostic tool in the evaluation of thyroid nodules. Nature of the disease, experience of the cytopathologist, and the understanding of certain limitations determine its diagnostic utility. Thus, the Bethesda system of reporting thyroid cytology should be meticulously followed to minimize these errors and a repeat FNAC asked for in discordant cases after a multidisciplinary team conference.

Key words: Bethesda system, Fine needle aspiration cytology, Follicular lesions, Papillary carcinoma, Thyroid lesions

INTRODUCTION

The incidence of clinically apparent thyroid swellings in the general population is 4–5%.[1] Thyroid lesions can present as a diffuse enlargement, solitary or multiple nodules. Fine needle aspiration cytology (FNAC) is a simple, safe, reliable, and cost-effective tool with a high degree of sensitivity and specificity for detecting malignancies.[2] It is considered the first line of investigation in the clinical evaluation of thyroid nodules. However, limitations of FNAC include technical factors (skills of the performing expert, inadequate sampling) and pathological factors (cystic lesions). We studied the spectrum of thyroid lesions and analyzed the cytohistological and histology-imaging discordance.

Access this article online

IJSS

www.ijss-sn.com

Month of Submission : 09-2020
Month of Peer Review : 09-2020
Month of Acceptance : 10-2020
Month of Publishing : 11-2020

OBJECTIVE

The objective of the study was as follows:

1. To study the spectrum of thyroid lesions
2. To correlate the FNAC findings with histopathology of excised specimens

Corresponding Author: Dr. B Archana, Department of Pathology, Sri Ramachandra Institute of Higher Education and Research, Chennai, Tamil Nadu, India.

3. To study the imaging and pathological discordance in thyroid lesions.

MATERIALS AND METHODS

Our study is a retrospective analysis of 179 cases of thyroid nodules over a period of 3 years from April 2016 to 2019 from a tertiary care hospital. Ethical clearance was obtained (IEC No: CSP-MED/19/JAN/49/04). FNAC and histopathology slides were reviewed, double-blinded and reported by two independent observers. These data were documented and analyzed. Imaging findings were also reviewed and documented.

Inclusion Criteria

All patients who presented with thyroid swellings, irrespective of age, and who have undergone FNAC followed by surgery were included in the study. Exclusion criteria – patients in whom either one (FNAC/histopathology/Imaging findings) was not available were excluded from the study.

RESULTS

A total of 179 patients were included in the study, of which 142 were females and 37 were males with a male:female ratio of 1:3.8. Age of the patients ranged from 19 to 71 years, with a mean age of 43 years. Mode of the clinical presentation was either a nodule or a diffuse enlargement in front of the neck. Thyroid imaging reporting and data systems (TIRADS) classification was followed according to The American College of Radiology (ACR) to determine the risk of cancer in thyroid nodules.[3] According to the ACR classification, TIRADS 1 – Normal thyroid gland; TIRADS 2 – Benign lesion; TIRADS 3 – Probably benign lesions; TIRADS 4 – Suspicious lesions; TIRADS 5 – Probably malignant lesions; and TIRADS 6 – Biopsy proven malignancy.

Total thyroidectomy was performed for 87 cases, right hemithyroidectomy for 47 cases, and left hemithyroidectomy for 45 cases. By histopathology, 94(52%) cases were benign and 85 (47.4%) cases were malignant. Cytohistology correlation was seen in 151 (84%) cases and non-correlation was observed in 28 (15.6%) cases [Table 1]. Reasons for discordance were mainly due to inadequate sampling and cystic nature of the lesion.

Cytohistology correlation along with the radiological analysis was done for all the 28 cases of discordance. The mean age of presentation of discordant cases was 43.2 years with male:female ratio of 1:4.6. Out of 28 discordant cases, only 3 cases (10.7%) had undergone ultrasonogram (USG)-guided FNAC. On imaging, TIRADS 3 and 4 categories had the maximum discordance [Table 2]. Most malignant cases were misdiagnosed as Bethesda II category. Reasons of discordance included sampling error in 11 cases (6.1%), cystic nature of the lesion in 12 cases (6.7%), and interpretation error/nature of the lesion 5 cases (2.8%). Among the discordant cases, follicular lesions were noted in 16 cases (57.1%), papillary carcinoma in 9 cases (32.1%), papillary microcarcinoma in 2 cases (7.1%), and medullary carcinoma in 1 case (3.5%).

Table 1: Clinicopathological profile of the thyroid lesions

1. Bethesda category diagnosis	Number of cases	Percentage
II Benign	103	57.5
III Atypia of undetermined significance	5	2.7
IV Follicular neoplasm	6	3.3
V Suspicious for malignancy	17	9.4
VI Malignant	24	13.4
Suboptimal	7	3.9
2. Histopathology diagnosis	**Number of cases**	**Percentage**
Benign	85	57
Malignant	64	42
3. Age distribution	**Number of cases**	**Percentage**
<20 years	2	1
21–40 years	78	44
41–60 years	85	47
>60 years	14	8
4. Sex	**Number of cases**	**Percentage**
Males	37 cases	20
Females	142 cases	72

Below are three selected cases of discordance with valuable learning points.

Case 1 – 50 years female presented with a swelling in front of the neck, a TIRADS 3 lesion measuring 3.5 cm × 2.7 cm × 5.4 cm was noted on imaging. Ultrasound of the thyroid showed a well-defined wider than taller mixed solid cystic nodule with few macrocalcifications and increased internal vascularity. Nine milliliters of colloid were obtained. FNAC showed thyroid follicular epithelial cells in a background of thick and thin colloid, Bethesda II category. Final histopathological diagnosis was given as medullary carcinoma of the thyroid [Figure 1].

Case 2 – 36 years female presented with a solitary nodule, a TIRADS 3 lesion with cystic changes measuring 4.3 cm × 2.4 cm × 3.6 cm was noted on imaging. Ultrasound showed an ill-defined mixed solid cystic wider than taller nodule in the left lobe of thyroid with a macrocalcification. FNAC suggested a Bethesda II category lesion. Histopathological diagnosis was papillary carcinoma of thyroid, classic type [Figure 2].

Table 2: Analysis of discordant cases

Discordant cases number	Female	Male	Mean age	Sampling error	Cystic nature of the lesion	Others (Interpretation error)	TIRADS classification	Bethesda category
28	23	5	43.2	11 (6.1%)	12 (6.7%)	5 (2.8%)	TIRADS 3: (12/28) 42% TIRADS 4: (16/28) 57%	All cases belonged to Bethesda II category

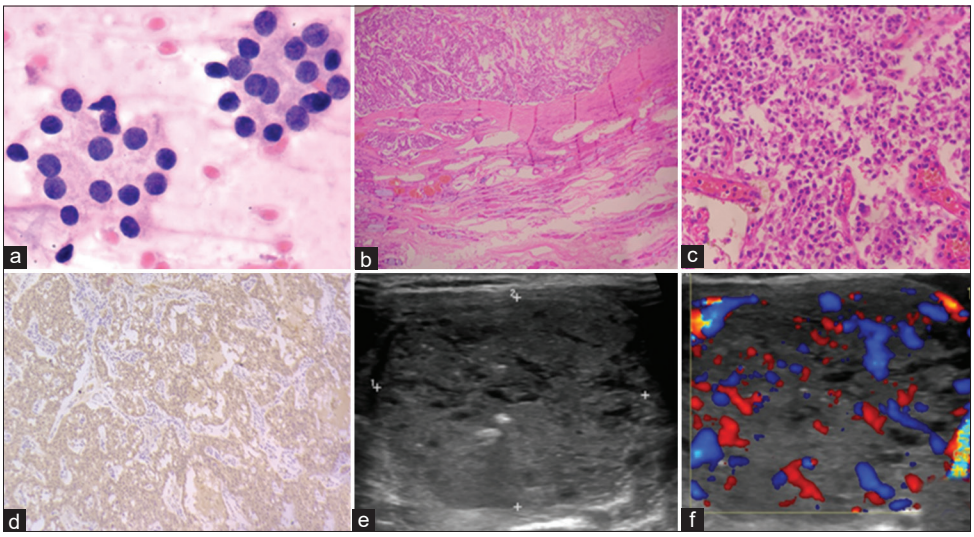

Figure 1: (a) ×40, fine needle aspiration cytology shows thyroid follicular epithelial cells in a background of thick and thin colloid. (b) H&E, ×4 shows sheets of tumor cells. (c) H&E, ×40 shows round, plasmacytoid cells in nests with fine stippled chromatin separated by capillaries. (d) IHC, ×4, synaptophysin positivity noted. (E and F) High-frequency ultrasound of thyroid shows a well-defined wider than taller mixed solid cystic nodule in the left of thyroid with few macrocalcifications and increased internal vascularity

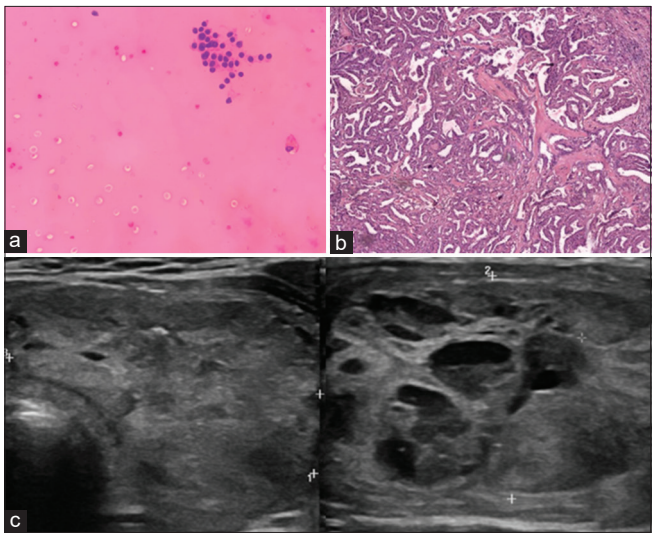

Figure 2: (a) ×10, fine needle aspiration cytology shows scattered thyroid follicular cells with cyst macrophages in background colloid. (b) H&E, ×10, tumor cells arranged in papillary pattern with nuclear features of papillary carcinoma. (c) Ultrasound of thyroid shows an ill-defined, mixed solid cystic wider than taller nodule in the left lobe of thyroid with a macrocalcification

Case 3 – 28 years male presented with a solitary nodule in the front of the neck. A TIRADS 3 lesion was noted with a cystic area within the nodule measuring 3.4 cm × 2 cm × 3 cm. Ultrasound showed a tall well-defined hypoechoic wider than taller solid nodule in the right lobe of thyroid with increased internal vascularity and no calcifications. FNAC showed thyroid follicular cells with few showing Hurthle cell change and hemorrhage, suggesting a Bethesda II category lesion. Histopathological diagnosis was given as follicular variant of papillary thyroid carcinoma (PTC) [Figure 3].

Statistical analysis was done using SPSS software. The sensitivity and specificity of FNAC in diagnosing malignancy was 58.3% and 100%, respectively. Positive predictive value was 100% and negative predictive value was 71.5%. Accuracy of FNAC in differentiating benign from malignant thyroid lesion was 79.6%.

For radiologically evaluated TIRADS category, the sensitivity and specificity was 59.7% and 100%, respectively. Positive predictive value was 100% and negative predictive value was 72.4%. Accuracy of TIRADS in differentiating benign from malignant thyroid lesions was 80.4%.

DISCUSSION

It is well-known that thyroid lesions are most common in middle-age females, similar to the observation in

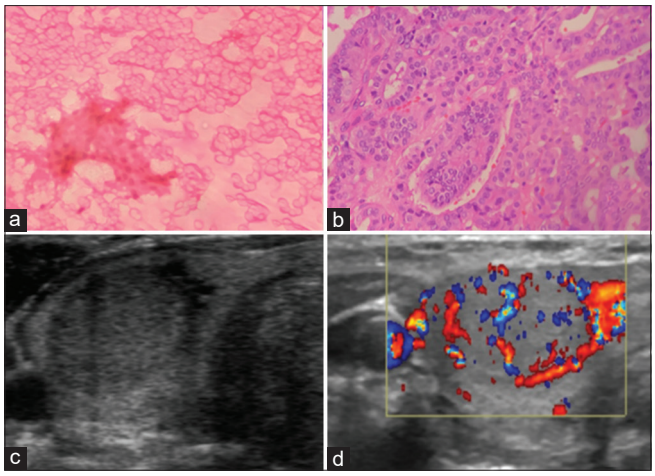

Figure 3: (a) ×10, fine needle aspiration cytology shows scant thyroid follicular cells with few showing Hurthle cell change in a background of hemorrhage. (b) H&E, ×40, microfollicles with tumor cells showing nuclear features of papillary thyroid carcinoma. (c and d) Ultrasound shows a tall well-defined hypoechoic wider than taller solid nodule in the right lobe of thyroid with increased internal vascularity and no calcifications

our study.[3] Thyroid lesions usually present with an asymptomatic swelling in the anterior part of the neck. It can present as a solitary nodule, multinodular or as a diffuse swelling. The vast majority of these nodules are non-neoplastic lesions or benign neoplasms.[3] The general protocol for the investigation of a thyroid nodule includes clinical examination, imaging modalities such as ultrasound, biochemical analysis including thyroid function tests with antibodies levels followed by FNAC diagnosis using The Bethesda system of reporting. In the case of a Bethesda IV category, surgical lobectomy is performed, Bethesda V category lesions are managed with a near-total thyroidectomy and Bethesda VI category lesions are managed with total thyroidectomy with or without neck dissection.[4]

FNAC of thyroid lesions is a safe, cost-effective, minimally invasive, simple out-patient procedure, hence considered as a gold standard for pre-operative assessment of patients with thyroid nodules.

TIRADS has been proposed for risk stratification of thyroid nodules. TIRADS 3 are probably benign nodules with a risk of malignancy of <5%. The risk of malignancy in TIRADS 4a (undetermined) and 4b (suspicious) is 5–10% and 10–80%, respectively.[5]

Reasons for discordance are mainly because of the error in sampling and the nature of the lesion (43%)[6] which is associated with an adverse outcome in patients with thyroid cancer and ultimately, it determines the treatment.

The diagnosis of follicular patterned lesions can be challenging in FNAC because of the overlapping features between benign and malignant lesions and is hence, considered to be a grey zone. Follicular spectrum of thyroid lesions includes follicular adenoma, follicular carcinoma, and follicular variant of PTC. The sole criteria for the diagnosis of follicular carcinoma are the demonstration of capsular or vascular invasion. Follicular carcinoma can be divided into minimally invasive (capsular invasion only) and angioinvasive carcinoma. Hence, the capsule has to be all embedded for accurate diagnosis in histopathology.[7] One more pitfall is that benign follicular nodules cannot be distinguished in FNAC from follicular carcinomas because the criteria to distinguish them are based upon histological evidence of capsular or vascular invasion which cannot be assessed in cytology.[8-10]

Adequacy in FNAC is based on cellularity criteria (6 clusters of 10 cells or 10 clusters of 6 cells).[4,11] Aspirates that contain only cystic fluid and erythrocytes are considered inadequate.

Sampling error may be the reason for discordance in papillary carcinoma and microcarcinoma. The occurrence of a cystic change with underlying malignancy in thyroid lesions is a common diagnostic pitfall in FNAC.[12-14] PTCs tend to undergo hemorrhagic and degenerative changes. Sampling of this area will result in a lesser number of cells and false interpretation of it to be a benign cyst.[15-17] Any recurrent cystic lesion should raise a strong suspicion for malignancy and should be treated accordingly. In such cases, USG-guided FNAC is suggested to accurately locate the lesion for a better diagnostic yield. The term papillary microcarcinoma is used when it is found incidentally and it measures <1 cm in diameter as defined by the World Health Organization.[18-20] There is a high chance of it being missed in FNAC because of the small size of the lesion. Non-invasive follicular thyroid neoplasm with papillary-like nuclear features (NIFTP) is an encapsulated or clearly delimited, non-invasive neoplasm with a follicular growth pattern and nuclear features of PTC. It is considered as a premalignant lesion in patients with RAS mutation. The diagnosis of NIFTP is made after complete resection of the lesion by the defined criteria.[21]

The reason for the false-positive diagnosis is the presence of diagnostic features of PTC even in benign conditions of thyroid such as adenomatoid nodule and Hashimoto's thyroiditis. Benign thyroid nodules with papillary hyperplasia can pose a diagnostic challenge not only in cytology but also in histopathology as it mimics classical PTC.[16,20]

In the current study, 3.9% aspirates were reported as inadequate compared to the study done by Nandedkar *et al*. which showed inadequate/nondiagnostic category in 26 cases (4.29% of total cases).[22]

Utility of core needle biopsy compared to FNAC is still debatable and results have been inconclusive. While its distinct advantages include identifying the architectural pattern and performing ancillary techniques; however, disadvantages include invasiveness of the technique with a risk of complications as well as failure to differentiate between follicular lesions.[23,24]

ACR TIRADS (TI-RADS) was established in 2017 based on the US features of thyroid nodules into five categories – Composition, echogenicity, shape, margins, and presence of echogenic foci. Each of these features was assigned individual points from 0 to 3 and the nodule's total point determines its risk of malignancy (TR1 – benign, TR2 – not suspicious, TR3 – mildly suspicious, TR4 – moderately suspicious, and TR5 – high suspicious). Depending on the diameter and the TR category of the nodules, further recommendations like the need for FNA biopsy short-term follow-up or no further action is recommended.[23] In our study, of the 28 cases that were discordant 12 cases were given TIRADS-3 and 16 cases were given TIRADS-4 on USG which were predominantly solid cystic lesions and subsequently advised for a cytology correlation due to their ultrasound features suspicious for malignancy. Except 3 patients, all other 25 discordant cases underwent FNAC without image guidance which resulted in sampling error and inadequate sample owing to the cystic nature of these nodules. Moreover, all these 28 discordant nodules which labeled as suspicious TIRADS-3/4 lesions on USG were malignant on histology.

CONCLUSION

Histopathological evaluation of thyroid nodules provides the most accurate method of diagnosis. FNAC is considered only as a screening tool and particular attention should be given to minimize the false positive and negative diagnosis. The Bethesda system of reporting should be followed to minimize these errors. Occurrence of cystic change in thyroid lesions is a common diagnostic pitfall in cytology. Hence, the possibility of neoplastic etiology should be considered in cystic lesions and these cases require USG-guided FNAC to ensure cellular adequacy, thus, preventing a sampling error. In suspicious cases, repeat FNAC/core biopsy is suggested for a confirmatory diagnosis. A benign FNAC diagnosis should be followed up with excision in case of imaging and pathology discordance. A multidisciplinary team discussion involving the surgeon, oncologist, radiologist, and pathologist is warranted in discordant cases for planning and instituting optimal management.

REFERENCES

1. Dean DS, Gharib H. Epidemiology of thyroid nodules. Best Pract Res Clin Endocrinol Metab 2008;22:901-11.
2. Sinna EA, Ezzat N. Diagnostic accuracy of fine needle aspiration cytology in thyroid lesions. J Egypt Natl Canc Inst 2012;24:63-70.
3. Robbins SL. The Endocrine System: Thyroid Gland in Pathologic Basis of Disease. Philadelphia, PA: WB Saunders; 1974. p. 1326-30.
4. Cibas ES, Ali SZ. The Bethesda system for reporting thyroid cytopathology. Thyroid 2009;11:1159-65.
5. Franklin NT, Middleton WD, Grant EG. Thyroid imaging reporting and data system (TI-RADS): A user's guide. Radiology 2018;287:29-36.
6. Raja BN, Rani GS, Kumar VN. Utility of fine needle aspiration cytology (FNAC) as a screening tool in diagnosis of thyroid lesion in correlation with histopathology-a 4 years study. Int J Med Biomed Stud 2019;3:286-9.
7. Mijović T, Rochon L, Gologan O, Hier MP, Black MJ, *et al.* Fine-needle aspiration biopsies in the management of indeterminate follicular and hurthle cell thyroid lesions. Otolaryngol Head Neck Surg 2009;140:715-9.
8. Canberk Ş, Firat P, Schmitt F. Pitfalls in the cytological assessment of thyroid nodules. Turk Patoloji Derg 2015;31 Suppl 1:18-33.
9. Kakudo K, editor. Thyroid FNA Cytology: Differential Diagnoses and Pitfalls. Berlin, Germany: Springer; 2019.
10. Guhamallick M, Sengupta S, Bhattacharya N, Basu N, Roy S, Ghosh A, *et al*. Cytodiagnosis of thyroid lesions-usefulness and pitfalls: A study of 288 cases. J Cytol 2008;2:6.
11. Renshaw AA. Evidence-based criteria for adequacy in thyroid fine-needle aspiration. Am J Clin Pathol 2002;118:518-21.
12. Sukumaran R, Kattoor J, Pillai KR, Ramadas PT, Nayak N, Somanathan T, *et al*. Fine needle aspiration cytology of thyroid lesions and its correlation with histopathology in a series of 248 patients. Indian J Surg Oncol 2014;5:237-41.
13. Sharma R, Mathur DR. Diagnostic accuracy of fine needle aspiration cytology (FNAC) of the thyroid gland lesions. Int J Health Sci Res 2012;2:1-7.
14. Bamanikar S, Soraisaham P, Jadhav S, Kumar H, Jadhav P, Bamanikar A. Cyto-histology and clinical correlation of thyroid gland lesions: A 3 year study in a tertiary hospital. Clin Cancer Investig J 2014;3:208-12.
15. Shere SK, Kulkarni AS, Phulgirkar PP, Anjum S, Patil SP, Bindu R. Correlation of fine needle aspiration cytology with histopathology in diagnosis of thyroid lesions. J Evol Med Dent Sci 2013;2:4826-31.
16. Poonam P. Diagnostic utility of FNAC in thyroid lesions and their histological correlation-a case study. IAIM 2018;5:7-13.
17. Bagga PK, Mahajan NC. Fine needle aspiration cytology of thyroid swellings: How useful and accurate is it?. Indian J Cancer 2010;47:437.
18. Sharma C. An analysis of trends of incidence and cytohistological correlation of papillary carcinoma of the thyroid gland with evaluation of discordant cases. J Cytol 2016;33:192-8.
19. Prajapati J, Chag S, Mehta D. Diagnostic accuracy and efficacy of fine needle aspiration cytology of thyroid lesions and its cyto-histopathological correlation. Int J Pathol 2018;6:64-8.
20. Bakhos R, Selvaggi SM, DeJong S, Gordon DL, Pitale SU, Herrmann M, *et al*. Fine-needle aspiration of the thyroid: Rate and causes of cytohistopathologic discordance. Diagn Cytopathol 2000;23:233-7.
21. Baloch ZW, Seethala RR, Faquin WC, Papotti MG, Basolo F, Fadda G, *et al*. Noninvasive follicular thyroid neoplasm with papillary-like nuclear features (NIFTP): A changing paradigm in thyroid surgical pathology and implications for thyroid cytopathology. Cancer Cytopathol 2016;124:616-20.
22. Nandedkar SS, Dixit M, Malukani K, Varma AV, Gambhir S, *et al*. Evaluation of thyroid lesions by fine-needle aspiration cytology according to Bethesda system and its histopathological correlation. Int J Appl Basic

Med Res 2018;8:76-82.
23. Pantanowitz L, Thompson LD, Jing X, Rossi ED. Is thyroid core needle biopsy a valid compliment to fine needle aspiration? J Am Soc Cytopathol 2020;9:383-8.
24. Tessler FN, Middleton WD, Grant EG, Hoang JK, Berland LL, Teefey SA, *et al*. ACR thyroid imaging, reporting and data system (TI-RADS): White paper of the ACR TI-RADS committee. J Am Coll Radiol 2017;14:587-95.

How to cite this article: Gayathri K, Archana B, Palanisamy P, Rajendiran S. Cytology, Histology, and Imaging Correlation in the Plethora of Thyroid Lesions from A Tertiary Care Center. Int J Sci Stud 2020;8(8):68-73.

Source of Support: Nil, **Conflicts of Interest:** None declared.