Print ISSN: 2321-6379
Online ISSN: 2321-595X

Original Article

Comparison of 2D Mammogram and Digital Breast Tomosynthesis for Precise BI-RADS Classification – A Tertiary Care Hospital Experience

H Lalchhanhimi[1], Bhawna Dev[2], Suresh Varadharajan[3], P M Venkata Sai[2], Paarthipan Natarajan[4], Jai Prakash Srinivasan[3], Aprajita Mehta[5]

[1]Scholar, Department of Radiology and Imaging Sciences, Sri Ramachandra Institute of Higher Education and Research, Chennai, Tamil Nadu, India, [2]Professor, Department of Radiology and Imaging Sciences, Sri Ramachandra Institute of Higher Education and Research, Chennai, Tamil Nadu, India, [3]Associate Professor, Department of Community Medicine, Sri Ramachandra Institute of Higher Education and Research, Chennai, Tamil Nadu, India, [4]Professor, Department of Radiology, Saveetha Medical College and Hospital, Chennai, Tamil Nadu, India, [5]Consultant Radiologist, Fortis Memorial Research Institute, Gurgaon, Haryana, India

Abstract

Introduction: Breast cancer is one of the leading cancers that occur in women worldwide. Thus, its early detection and treatment plays a crucial role in determining the survival rate of women and increases their chance of beating the disease. Mammogram has always been considered to be the primary and gold standard for screening and diagnosis of breast cancer. This study was designed to compare 2D mammogram and Digital Breast Tomosynthesis (DBT) findings and provide accurate Breast Imaging Reporting and Database system (BI-RADS) scoring of breast lesions. A precise BI-RADS classification is a requisite so as to reduce additional tests or invasive procedures subjecting the patients to further stress and discomfort.

Materials and methods: A sample size of 1000 patients were included in the study. The 2D mammogram and DBT images were evaluated and reported separately using the American College of Radiology (ACR) Breast Imaging Reporting and Database system (BI-RADS) Fifth edition classification.

Results: The sensitivity and specificity of 2D mammogram was calculated to be 85.33% and 94.05% respectively, whereas for DBT it was found to be 92% and 98.08% respectively.

Conclusion: From our study, we found that DBT increases the detection of lesions and aids in diagnostic accuracy.

Key words: 2D digital mammogram, 3D digital breast tomosynthesis, Breast cancer, Dense breast, Mammography

INTRODUCTION

Breast cancer is the cancer most common to occur in women. There have been a number of strategies and initiated projects that have been started to increase the awareness and improve screening for breast cancer. It is calculated to constitute roughly about 21% of all cancers in women worldwide.[1] A mammogram examination plays a major role in early detection, diagnosis and prompt treatment of breast cancer, increasing the chances of survival and their chance of beating the disease.[2][3] Mammography remains the gold standard and the most widely utilized tool for early detection and diagnosis of breast cancer.[4][5] It has been found that implementation of mammography has been able to reduce mortality rate of breast cancer as much as 50%.[4] Cancer projections are especially useful in the developing countries like India where the major cause of morbidity and mortality is highest in Indian metropolitan cities.[7]

Digital breast tomosynthesis (DBT) is an evolving diagnostic technology used in breast imaging to evaluate compressed breast tissue.[8][9] The most important advantage of DBT is the ability to eliminate superimposed tissue allowing better visualization of breast parenchyma, thereby reducing false-positive screening recalls while

Access this article online

www.ijss-sn.com

Month of Submission : 12-2021
Month of Peer Review : 01-2022
Month of Acceptance : 01-2022
Month of Publishing : 02-2022

Corresponding Author: Dr. Bhawna Dev, Department of Radiology and Imaging Sciences, Sri Ramachandra Institute of Higher Education and Research, Chennai, Tamil Nadu, India.

simultaneously increasing the cancer detection rate.[10][11] In DBT technology, the breast is positioned in a method similar to that used in routine digital mammography, but the image acquisition is done in a series of low-dose exposures at preset intervals, each from a different angle which results in a series of projection images.[8] DBT is, thus, considered to enable better characterization of breast cancer due to improved sensitivity and specificity compared with digital 2D mammography as it helps in clarifying areas of overlapping tissue.[8][12]

Aims and Objectives

The aim of the study is:

- To characterize the true nature of lesions on tomosynthesis and reduce the false-positive results
- To establish the role of tomosynthesis in distinguishing false-positive lesions such as
  - Summation shadows
  - Asymmetries
  - Architectural distortion
- Impact of tomosynthesis on BIRADS categorization reducing the recall rates.

MATERIALS AND METHODS

Patients' Selection and Inclusion Criteria

An observational study was conducted in patients who presented themselves for a mammographic examination (either diagnostic or screening) at Sri Ramachandra Medical Centre, Chennai, which is a tertiary care hospital over the period of 2017–2018. No specific exclusion criteria were set for the examination. A total of 1000 patients was included in the study and their data was used for further analysis.

A detailed history including chief complaints, previous medical/surgical history, menstrual history, and family history was collected from all patients and a thorough physical examination of the breasts performed. A digital X-ray mammogram along with DBT consisting of standard craniocaudal and mediolateral oblique projections was done for bilateral breasts using Fuji Amulet Innovality 200 mA. The mammographic images were evaluated and reported using the American College of Radiology (ACR) breast imaging reporting and database system (BI-RADS) fifth edition classification. Only lesions which were given above a BI-RADS 3 grading were taken for biopsy for further confirmation with histopathology.

OBSERVATION AND RESULTS

A total number of 1000 patients were evaluated for the study, both diagnostic and screening. All mammograms were studied in 2D and 3D (DBT) mode simultaneously using 12 megapixel dedicated monitor. Out of these, 417 patients (41.7%) came for routine screening without complaints whereas 583 patients (58.3%) were for diagnostic purpose. 46 patients had a positive family history of breast cancer, whereas the remaining 954 patients had none.

The largest number of patients, that is, 363 (36.3%) were between the ages of 40 and 50; 319 (31.9%) between 50 and 60 years; whereas 176 (17.6%) were patients aged <40 years; and 141 (14.1%) were above 60 years, respectively. The breast density patterns were analyzed and it was observed that maximum number of patients fell in ACR density pattern B (79%) followed by category C (12%).

Out of the 417 patients that came for routine mammogram screening with no specific complaints, 20 patients turned out to have malignant findings; whereas of the 583 that came for diagnosis, 528 had benign findings and 55 patients had malignancy. For the assessment of 2D and DBT images, ACR BI-RADS was used to standardize and categorize reports and evaluate the mammogram images.

From our study analysis, cases which had concordant reports, BI-RADS 2D and DBT are as follows:

- 248 cases showed normal study in both 2D and DBT and were categorized as BI-RADS 1 making them concordant
- 317 cases showed BI-RADS 2 readings in both 2D and DBT
- 90 lesions were concordant as BI-RADS 3 probably benign lesions both on 2D and DBT
- 22 lesions were classified as BI-RADS 4A in both 2D and DBT
- Five lesions were categorized as BI-RADS 4C in both 2D and DBT
- 38 cases showed BI-RADS 5 reading both in 2D and DBT and were concordant [Figures 1-7].

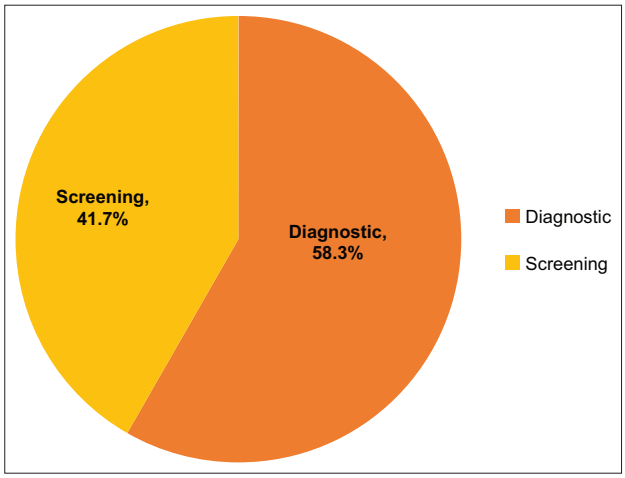

Figure 1: Distribution of screening and diagnostic mammograms (*n* = 1000)

The lesions/findings which had different interpretations on 2D and DBT were evaluated in detail and categorized as follows:

Category 1 – Lesions Which Were Seen Only on Tomosynthesis and Not Seen on 2D Mammogram

There were 195 lesions seen only on DBT and not seen on 2D mammogram. Of these, 172 lesions were of non-specific benign findings such as subcentimetric cysts/nodules, lipoma, and dilated ducts that were seen only on DBT and categorized as BI-RADS 2 which were not visible in the 2D mammograms. Twenty-three lesions were labeled as BI-RADS 3, probably benign lesions on DBT. On ultrasound, 15 of these lesions were single solid oval circumscribed lesions <1.5 cm in size; the rest of them, that is, six lesions, were complicated cysts. Two lesions were proved to be sclerosing adenosis on histopathology after being labeled as BI-RADS 4A on tomosynthesis.

Illustrative Case Number 1: Lesion which was not seen on 2D mammogram and picked up only on Tomosynthesis [Figure 8].

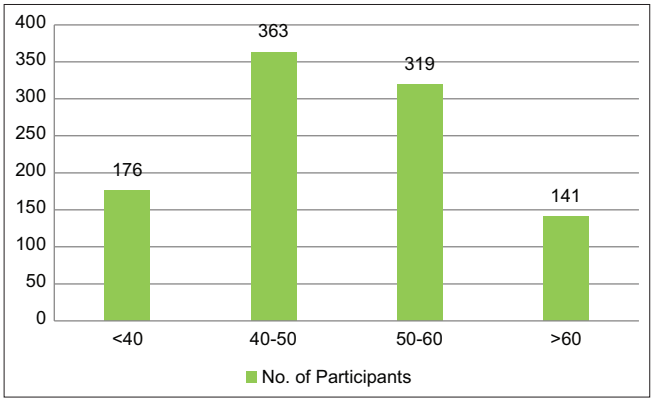

Figure 2: Distribution of participants by age group (*n* = 1000)

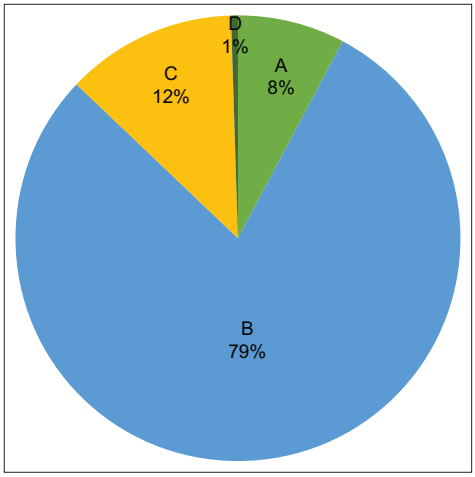

Figure 3: American College of Radiology density pattern (*n* = 1000)

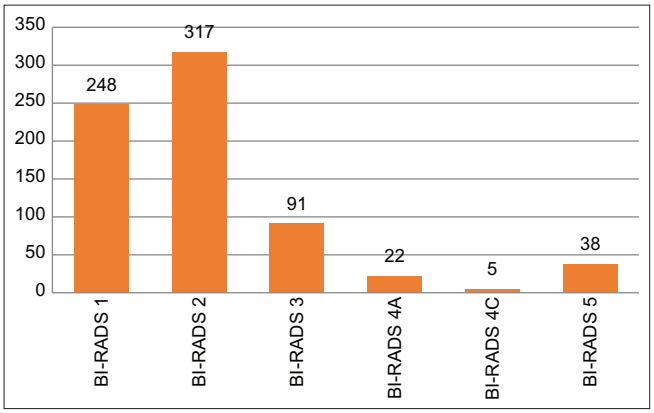

Figure 4: Concordant interpretations on both 2D and digital breast tomosynthesis

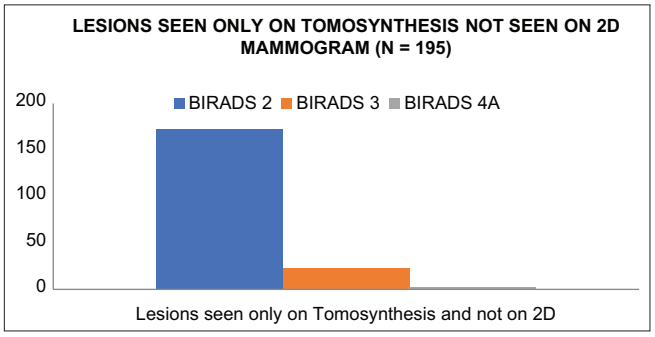

Figure 5: Category 1 – lesions which were seen only on tomosynthesis and not seen on a 2D mammogram

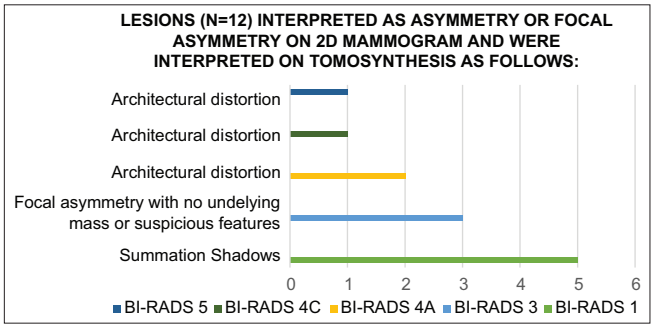

Figure 6: Category 2 – lesions/findings that were interpreted as asymmetry or focal asymmetry on a 2D mammogram

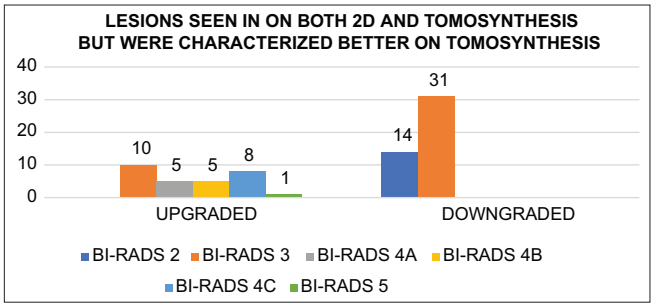

Figure 7: Category 3 – lesions seen in on both 2D and tomosynthesis but were characterized better on tomosynthesis

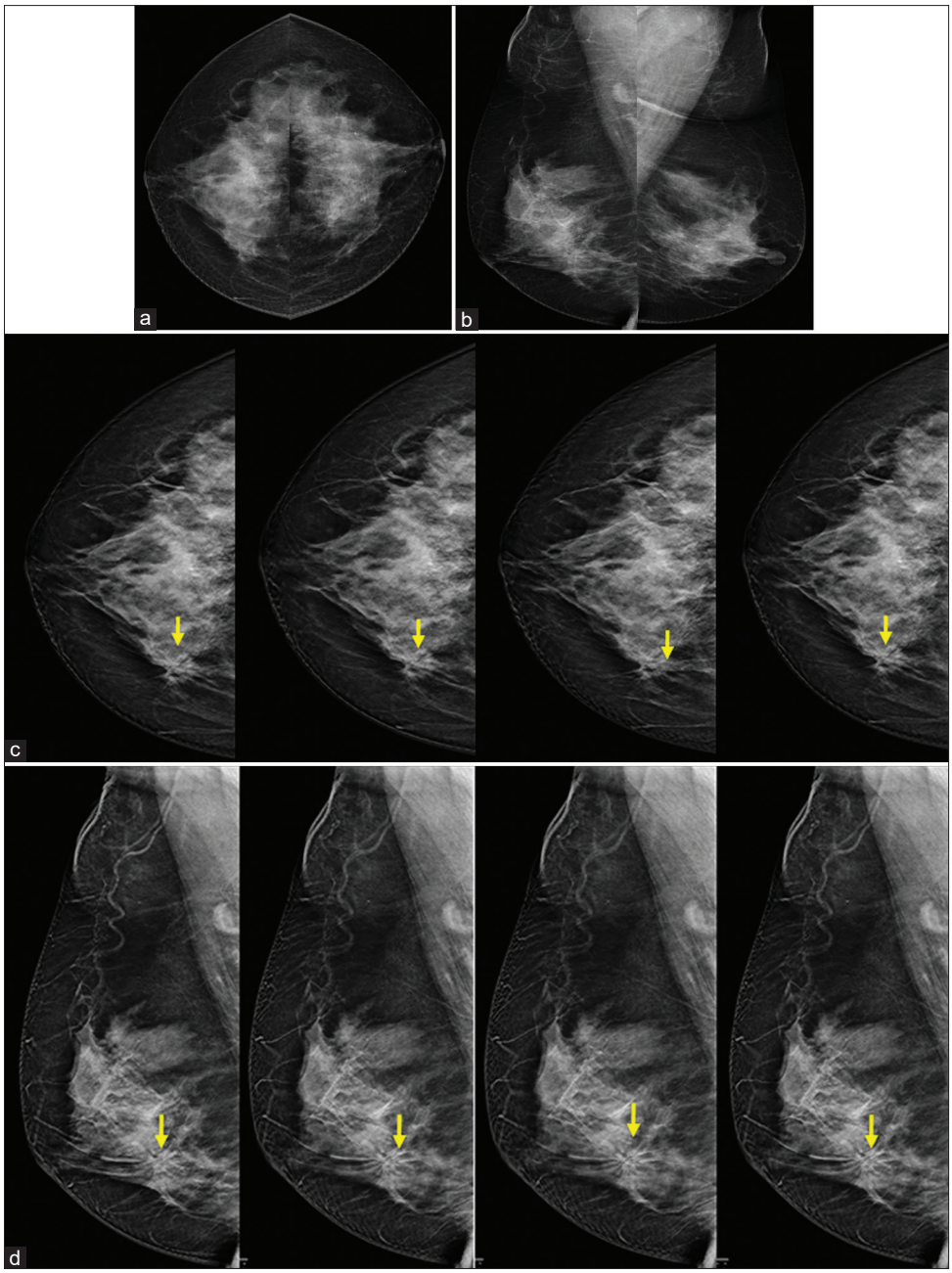

Figure 8: (a and b) Do not show any lesions in both craniocaudal (CC) and mediolateral oblique (MLO) view and was marked as a normal study, (c and d) a spiculated lesion in the lower inner quadrant in the right CC and right MLO view detectable only on tomosynthesis

Category 2 – Lesions/Findings That Were Interpreted as Asymmetry or Focal Asymmetry on 2D Mammogram

There were 12 such cases which were interpreted as asymmetry or focal asymmetry on 2D mammogram. Out of these, two cases proved to be real architectural distortion and were given BI-RADS 4A; one case as BI-RADS 4C; and one as BI-RADS 5 grading on tomosynthesis. Five cases were found to be summation shadows on tomosynthesis where the breast tissue was seen spanning out and hence were graded as BI-RADS 1 or 2. The remaining three cases showed focal asymmetry in the respective areas with no underlying mass or without any suspicious features and were thus classified as BI-RADS 3 in DBT and advised for follow-up.

Illustrative Case Number 2: Finding that was interpreted as focal asymmetry on 2D mammogram confirmed to be a normal study on Tomosynthesis [Figure 9].

Illustrative Case Number 3: Finding that was interpreted as focal asymmetry on 2D mammogram that was proven to be true architectural distortion on tomosynthesis [Figure 10].

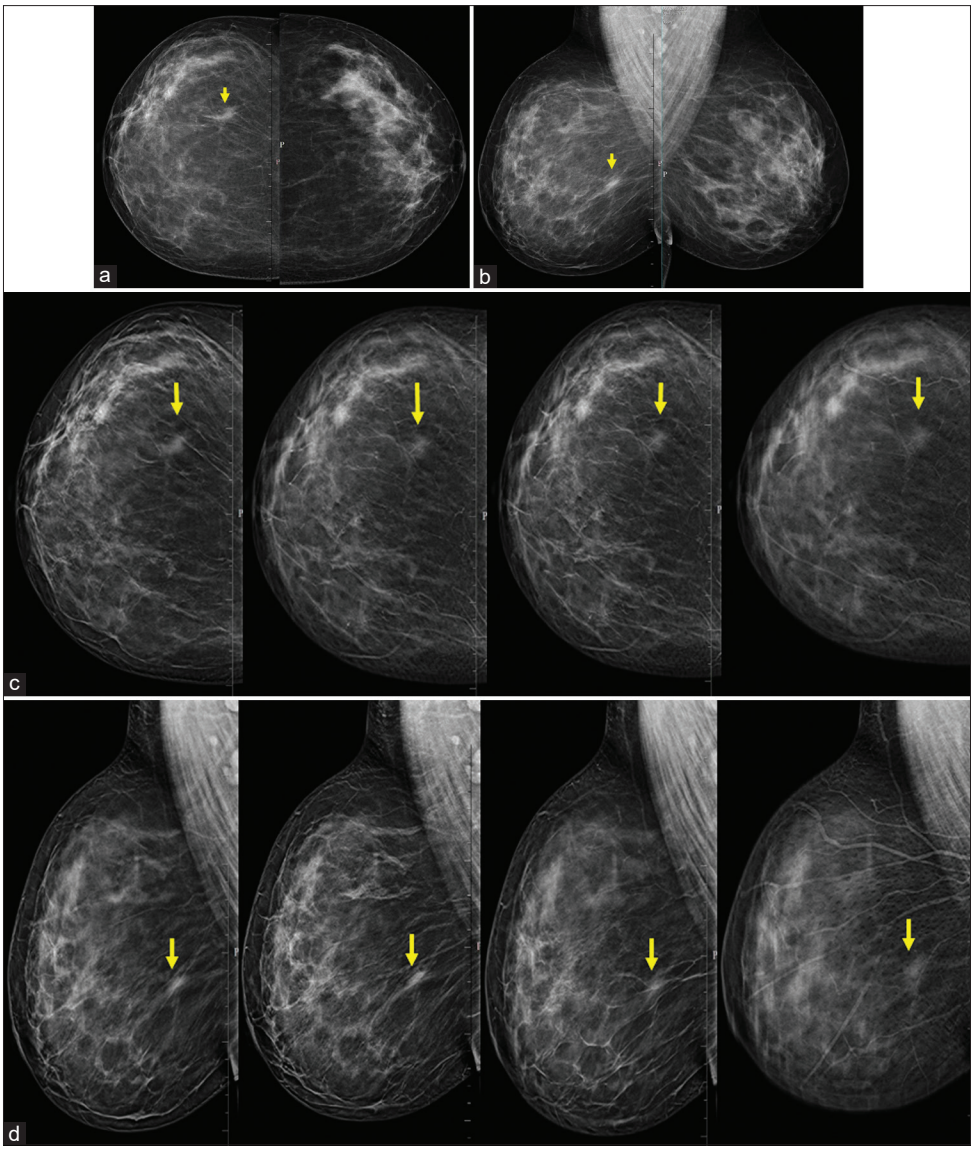

Figure 9: (a and b) Focal asymmetry in the lower outer quadrant (yellow arrow) of the left craniocaudal (CC) and left mediolateral oblique (MLO) view in 2D mammogram images, (c and d) the focal asymmetry to be gradually spanning out (yellow arrow) and showing normal breast parenchyma on both CC and MLO projections on tomosynthesis images

Category 3 – Lesions Seen Both in 2D and Tomosynthesis But Were Characterized Better on Tomosynthesis

In regard to shape and margin definition leading to accurate BI-RADS classification, five of the cases that were considered to be BI-RADS 3, probably benign lesions in 2D, whose lobulated margins were seen better in DBT, were subsequently categorized as BI-RADS 4A. From the 10 cases that were given BI-RADS 4A, five were upgraded to BI-RADS 4B and the other five were all upgraded to BI-RADS 4C on DBT. Three lesions reported as BI-RADS 4B in 2D mammogram were also upgraded as BI-RADS 4C on DBT. One lesion that was labeled as BI-RADS 4A in 2D mammogram was upgraded as a BI-RADS 5 highly suspicious lesion on DBT. In all the above cases, the margins and shapes were better interpreted on DBT. Ten cases which were interpreted as benign cysts/nodules and given BI-RADS 2 on 2D mammogram were upgraded to BI-RADS 3, probably benign lesions as they were found to be real circumscribed lesions on DBT.

There were 31 cases where the lesions had no defined border on 2D mammogram and were graded as BI-RADS 4A suspicious lesions that were subsequently downgraded to BI-RADS 3, probably benign lesions as their circumscribed borders were seen in DBT. Fourteen cases where BI-RADS 3 grading was given to lesions in 2D mammogram were also downgraded to BI-RADS 2 as they were found to be benign cysts/nodules on DBT.

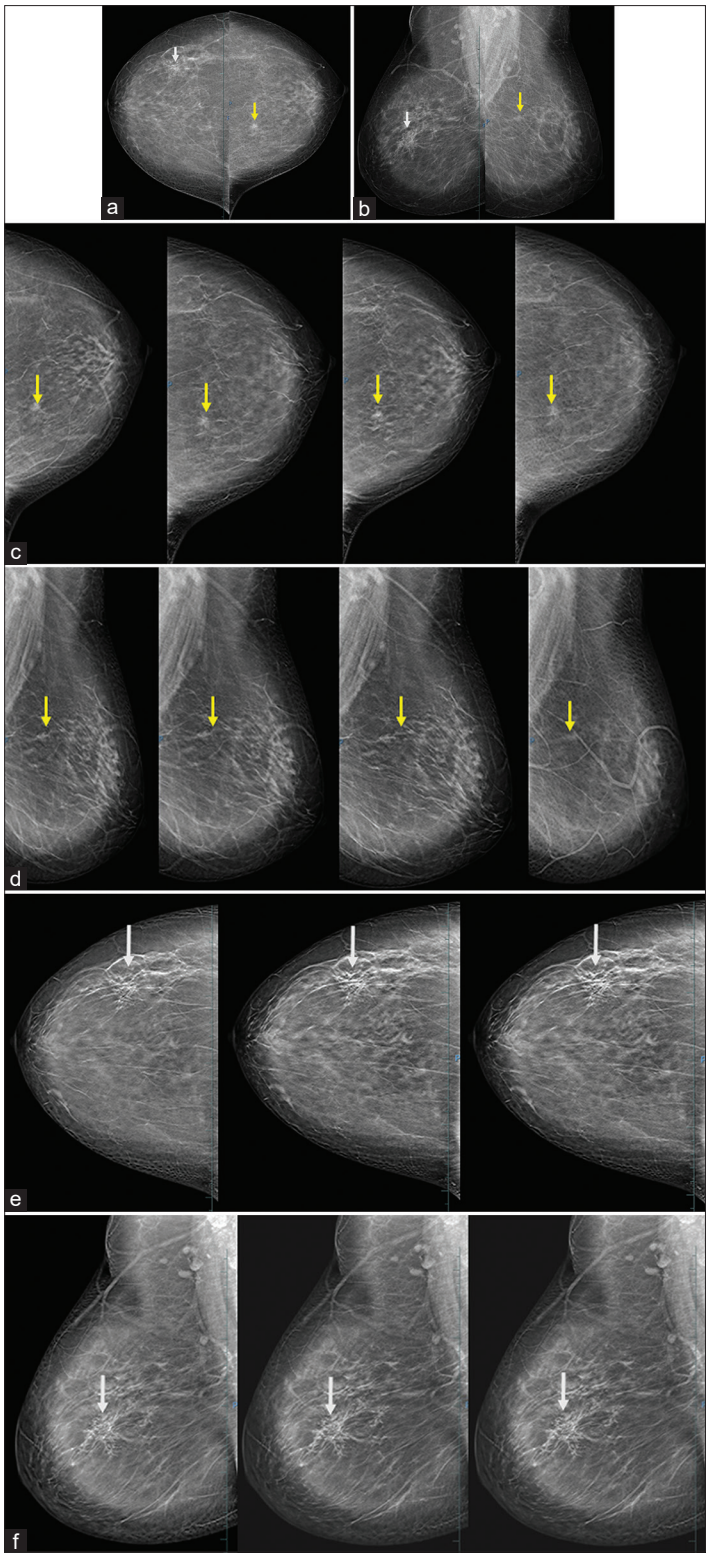

Figure 10: (a and b) Focal asymmetry in the upper outer quadrant (white arrow) of the right craniocaudal view and a focal density in the upper inner quadrant of the left craniocaudal view (yellow arrow) in 2D mammogram images, (c and d) the focal density in the right breast (yellow arrow) to span out in tomosynthesis images proving it to be a summation shadow, (e and f) focal asymmetry in the upper outer quadrant of the left breast on 2D, seen as a true architectural distortion on digital breast tomosynthesis slices. Core biopsy performed showed it to be an invasive ductal carcinoma

Illustrative Case Number 4: Lesion seen both in 2D and Tomosynthesis were characterized better on Tomosynthesis

The sensitivity and specificity of 2D mammogram was calculated to be 85.33% and 94.05%, respectively,

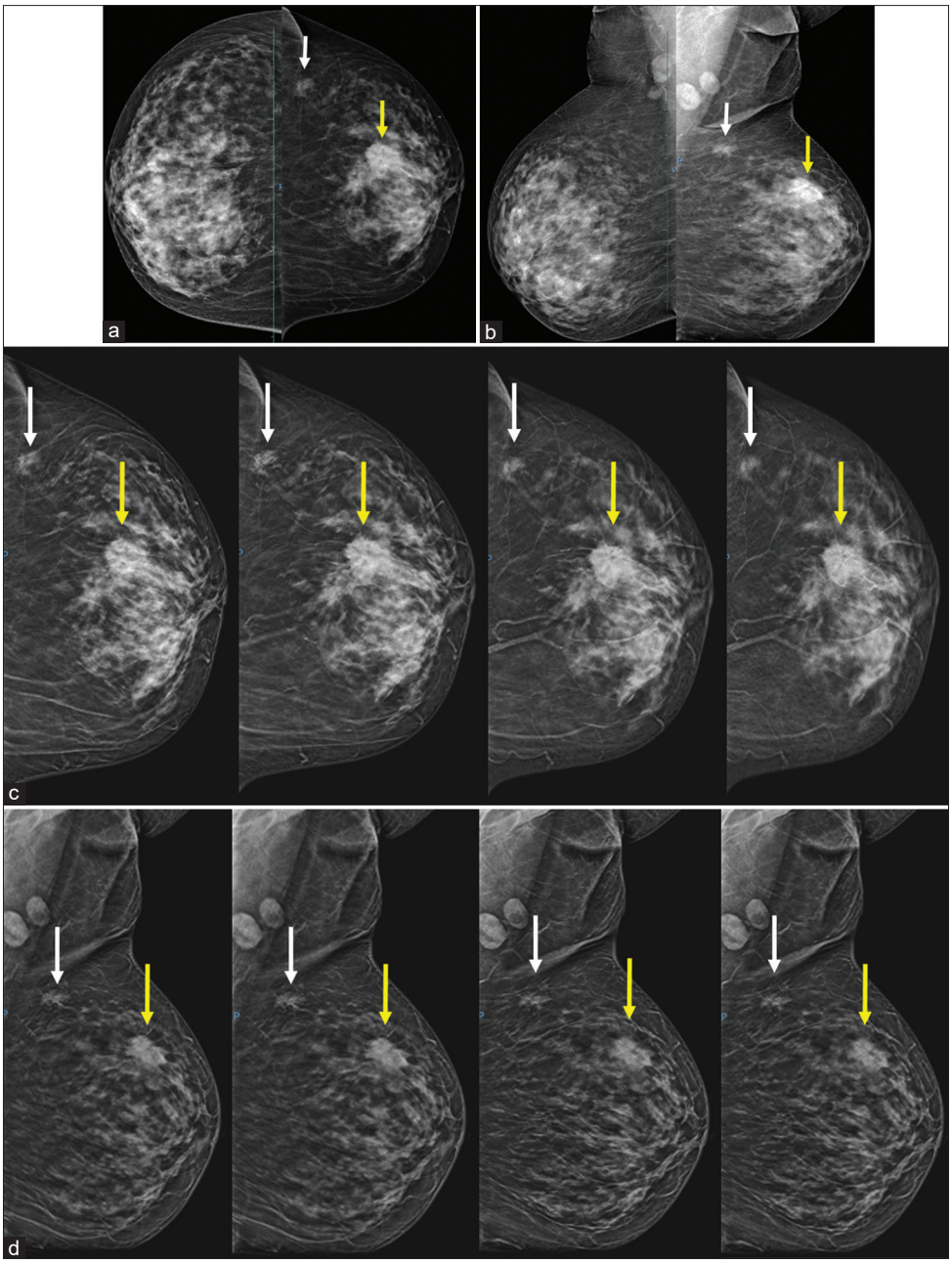

Figure 11: (a and b) A high-density lesion (yellow arrow) as well as an asymmetry (white arrow) in the upper outer quadrant of the right breast in both right craniocaudal and right mediolateral oblique view of 2D mammogram images, (c and d) the spiculated, irregular margins, and extent of the high-density suspicious lesion (yellow arrow) better. In addition, the asymmetry near the axilla is also seen as a true architectural distortion representing a suspicious finding. Core biopsy done for both lesions proved it to be invasive lobular carcinoma

whereas for DBT, it was found to be 92% and 98.08%, respectively.

DISCUSSION

There have been multiple studies that were conducted to show the improved performance of DBT in improving BI-RADS classification. Our study was designed to compare the clinical performance of 2D mammography with DBT for better detection of lesions and in differentiating real asymmetry from summation shadows. A total number of 1000 were taken in for the study either for diagnostic or screening mammograms.

A study was carried out by Caumo *et al*.[13] which stated that DBT significantly improved the detection outcome and decreased the recall rate of patients comparing to 2D synthetic mammogram. It helps specifically better

in categorization of lesions in high-density breasts. In our study, we also found that DBT was more helpful in categorizing lesion from breasts with high-density patterns, where the margins and shape of the lesions are appreciated better in DBT and lead to improved BI-RADS reporting.

A study carried out by Dhamija[14] found that DBT improves the cancer detection rate, reduces the false-positive rates and recall rates with better lesion characterization. In our study, we also found that DBT did help in distinguishing lesions better and avoided misdiagnosing benign findings as malignancy.

Lee *et al*.[15] carried out a study on density-based screening where they found that in comparison to screen-film mammography, digital mammography demonstrated higher accuracy for women with dense breasts and represented the primary screening modality of choice. They found that DBT improved cancer detection by reducing the effect of masking breast tissue. However, they also claimed that it subsequently increased biopsy rates as more lesions were being detected which otherwise would have possibly been overlooked in 2D mammogram, which, overall, was beneficial for the patient.[15] In our study, we found that DBT proved to be more effective not only in finding concealed lesions but also in determining better BI-RADS category as their shape and margins were better appreciated in DBT as compared to 2D mammograms.

CONCLUSION

From our study, we found that DBT has the potential to change conventional mammographic screening and diagnostic imaging with possible improvements in cancer detection, decreased call backs, and fewer positive biopsies. Tomosynthesis increases the detection of lesions, particularly in dense breasts, and aids in diagnostic accuracy. It helps to avoid false-positive cases of architectural distortion by differentiating between asymmetry and summation shadows. It depicts the morphology and margins of lesions more efficiently and thus leads to better categorization of lesions as compared to 2D mammograms.

REFERENCES

1. Yadav DP, Padmanabhan DV. Utility of whole breast ultrasound and digital tomosynthesis as an adjunct with mammography in dense breast to detect breast lesions. Int J Radiol Diagn Imaging 2019;2:112-8.
2. Males M, Mileta D, Grgic M. Digital Breast Tomosynthesis: A Technological Review. Proceeding Elmar International Symposium Electronics in Marine; 2011. p. 41-5.
3. Habel LA, Lipson JA, Achacoso N, Rothstein JH, Yaffe MJ, Liang RY, *et al*. Case-control study of mammographic density and breast cancer risk using processed digital mammograms. Breast Cancer Res 2016;18:1-7.
4. Sechopoulos I. A review of breast tomosynthesis. Part I. The image acquisition process. Med Phys 2013;40:1-12.
5. Niklason LT, Christian BT, Niklason LE, Kopans DB, Castleberry DE, Opsahl-Ong BH, *et al*. Digital tomosynthesis in breast imaging. Radiology 1997;205:399-406.
6. The American Cancer Society. American Society of Breast Disease Statement on Digital Breast Tomosynthesis. The American Cancer Society; 2014. p. 1-8.
7. Malvia S, Bagadi SA, Dubey US, Saxena S. Epidemiology of breast cancer in Indian women. Asia Pac J Clin Oncol 2017;13:289-95.
8. Nicholson BE, Rochman CM, Merchant JK, Harvey JA. Digital breast tomosynthesis in the diagnostic setting: Indications and clinical applications. Radiographics 2015;35:975-90.
9. Friedewald SM, Rafferty EA, Rose SL, Durand MA, Plecha DM, Greenberg JS, *et al*. Breast cancer screening using tomosynthesis in combination with digital mammography. JAMA 2014;311:2499-507.
10. Durand MA, Wang S, Hooley RJ, Raghu M, Philpotts LE. Tomosynthesis-detected architectural distortion: Management algorithm with radiologic-pathologic correlation. Radiographics 2016;36:311-21.
11. Walter SD. Mammographic screening: Case-control studies. Ann Oncol 2003;14:1190-2.
12. Kontos D, Ikejimba LC, Bakic PR, Troxel AB, Conant EF, Maidment AD. Analysis of parenchymal texture with digital breast tomosynthesis: Comparison with digital mammography and implications for cancer risk assessment. Radiology 2011;261:80-91.
13. Caumo F, Zorzi M, Brunelli S, Romanucci G, Rella R, Cugola L, *et al*. Digital breast tomosynthesis with synthesized two-dimensional images versus full-field digital mammography for population screening: Outcomes from the verona screening program. Radiology 2018;287:37-46.
14. Dhamija E. Digital breast tomosynthesis: An overview. Indian J Surg Oncol 2021;12:315-29.
15. Lee CI, Chen LE, Elmore JG. Risk-based breast cancer screening: Implications of breast density. Med Clin North Am 2017;101:725-41.

How to cite this article: Lalchhanhimi H, Dev B, Varadharajan S, Sai PMV, Natarajan P, Srinivasan JP, Mehta A. Comparison of 2D Mammogram and Digital Breast Tomosynthesis for Precise BI-RADS Classification – A Tertiary Care Hospital Experience. Int J Sci Stud 2022;9(11):70-77.

Source of Support: Nil, **Conflicts of Interest:** None declared.