

Meckel's Diverticulum: Still Formidable during Acute Abdominal Surgeries – An Observational Study

V Thirulogachandran¹, D Maruthupandian², G Karthick³

¹Senior Civil Surgeon, Department of General Surgery, Government Headquarters Hospital, Dindigul, Tamil Nadu, India, ²Emeritus Professor, Department of General Surgery, The Tamil Nadu Dr. MGR Medical University, Chennai, Tamil Nadu, India, ³Assistant Surgeon, Government Primary Health Centre, Sengurichi, Dindigul, Tamil Nadu, India

Abstract

Introduction: Meckel's diverticulum is a relatively common congenital diverticulum of ileum resulting from incomplete atrophy of the vitellointestinal duct in the embryo. Even though the majority of Meckel's diverticulum is asymptomatic, their potential to present with severe complications such as bleeding and perforation, intestinal obstruction has, nevertheless, caused much debate regarding whether a silent Meckel's should be pre-emptively resected when incidentally discovered during acute abdominal surgeries.

Aim: Our study aims to analyze the incidental finding of Meckel's diverticulum during acute abdominal surgeries and its surgical management.

Materials and Methods: This prospective observational study was conducted for the incidental findings of Meckel's diverticulum during acute abdominal surgeries. All the patients clinical, radiological, laboratory, and pathological findings were collected and the results were statistically analyzed and discussed.

Results: Out of 13 patients, 9 were males and 4 were females, based on age 10 years, patients had age below 40 years and 3 of them had above 40 years, based on clinical manifestations, 1 had perforative peritonitis, 1 had intestinal obstruction, 1 had acute diverticulitis, 1 had recurrent abdominal pain, and 9 were asymptomatic and incidentally found, among them 5 were found during appendectomy, 1 during gastrectomy, 1 during hernia surgery, 1 during traumatic Whipple's procedure, and 1 during gastrojejunostomy.

Conclusion: Symptomatic Meckel's diverticulum was associated with dreaded complications such as perforative peritonitis, intestinal obstruction, and diverticulitis with severe pain which made us conclude about even an asymptomatic Meckel's diverticulum found incidentally during acute abdominal surgeries need to be resected.

Key words: Intestinal obstruction, Meckel's diverticulum, Peritonitis

INTRODUCTION

Meckel's diverticulum was initially identified by Hildanus in 1598 and reported by Johann Friedrich Meckel, who established its embryological origin in 1809. It comprises the three layers of the intestinal wall and therefore is a true diverticulum that results from an incomplete obliteration

of the omphalomesenteric duct.^[1] The duct typically obliterates during the 7 months of gestation and failure of closure results in a diverticulum 98% of the time.^[2] It is the most prevalent congenital anomaly of the gastrointestinal tract, occurring in 2% of the population with 2:1 male predominance. Meckel's diverticulum arises from the anti-mesenteric border of the distal ileum, typically 40–100 cm from the ileocecal valve, with a typical length of 2 inches and diameter of 2 cm. Blood supply to this diverticulum comes from the omphalomesenteric artery. The prevalence of Meckel's diverticulum is increased in children born with major malformation of the umbilicus, alimentary tract, nervous system, or cardiovascular system, in descending order.^[3]

Access this article online



www.ijss-sn.com

Month of Submission : 01-2020
Month of Peer Review : 02-2020
Month of Acceptance : 03-2020
Month of Publishing : 03-2020

Corresponding Author: Dr. D Maruthupandian, Department of General Surgery, The Tamil Nadu Dr. MGR Medical University, Chennai, Tamil Nadu, India.

Patients are usually asymptomatic.^[4] Meckel's diverticulum involves a variety of complications such as intestinal obstruction, intussusceptions, ulceration, hemorrhage, vesico-diverticular fistulae, and rarely tumors.^[5-9]

Ectopic tissue is a common finding in Meckel's diverticulum, originally demonstrated gastric mucosa in the diverticula in 1907, and subsequently heterotopic mucosa has been described in up to 50% of Meckel's diverticula, with gastric, pancreatic, small bowel, and colonic types being the most common, as arranged in descending order.^[10,11]

Pre-operative diagnosis can be difficult. In adults, the diagnosis is usually made intraoperatively; therefore, pre-operative history, clinical findings, and supportive radiological imaging are essential to making a timely diagnosis. Less commonly, they are found on diagnostic imaging, including various modalities such as conventional radiography, contrast study using barium, and ultrasonogram. Therefore, contrast-enhanced computed tomography abdomen is the most sensitive diagnostic tool for making the diagnosis of Meckel's diverticulum and diverticulitis. A high index of suspicion is needed to diagnose a Meckel's diverticulum.

Surgical resection is the choice for symptomatic Meckel's diverticulum; this may include simple diverticulectomy or bowel resection. Diverticula with a broad base or those associated with complications such as hemorrhage are removed by bowel resection. Laparoscopic resection has also been reported in both the pediatric and adult population as a safe option.^[12,13] Symptomatic Meckel's diverticulum found incidentally during acute abdominal surgeries needs surgical resection.

Aim

The aim of our study is to analyze the incidental finding of Meckel's diverticulum during acute abdominal surgeries and its surgical management.

MATERIALS AND METHODS

This prospective observational study was conducted to analyze the incidental findings of Meckel's diverticulum during other acute abdominal surgeries under different study parameters such as sex, age distribution, clinical manifestations, histopathological findings, length of Meckel's diverticulum, and surgical management. Medical records were reviewed retrospectively, including clinical presentation at admission, laboratory values, performed pre-operative diagnostics, intraoperative findings, and histological results. All patients clinical, radiological, laboratory, and pathological findings were collected.

RESULTS

Out of 13 patients, 9 patients (69%) were males and 4 patients (31%) were females [Figure 1].

Out of 13 patients, 10 patients (77%) had age below 40 years and 3 patients (23%) had age above 41 years [Figure 2].

Out of 13 patients, 9 patients had incidental findings, 1 had perforative peritonitis, 1 had intestinal obstruction, 1 had acute diverticulitis, and 1 had recurrent abdominal pain [Table 1].

Out of 13 patients, 3 symptomatic patients (23%) managed by open surgical resection, 1 symptomatic patient (8%) by laparoscopic procedure, and 9 asymptomatic patients (69%) had no resection [Figure 3].

Out of 4 patients, 3 patients (75%) had length of Meckel's diverticulum of about 6 cm, and 1 patient (25%) had length of about 8 cm [Figures 3 and 4].

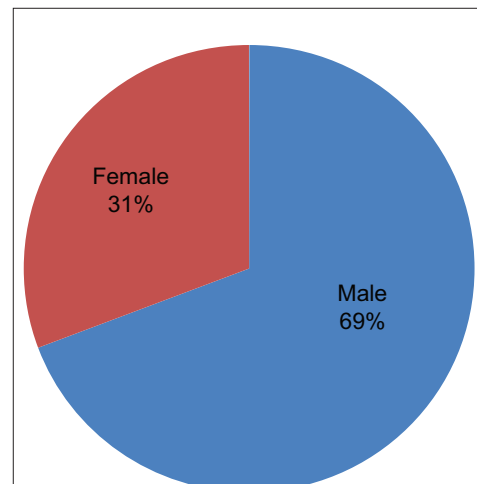


Figure 1: Sex distribution of Meckel's diverticulum

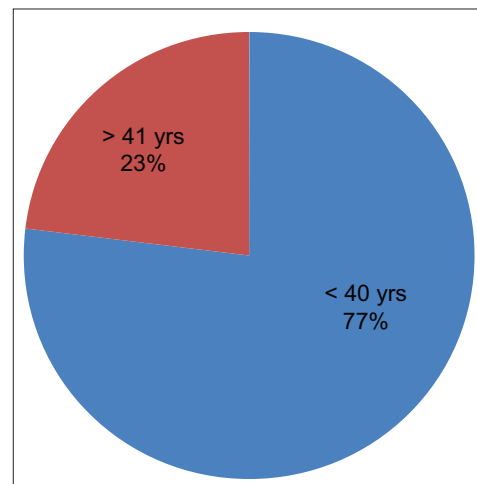


Figure 2: Age distribution of Meckel's diverticulum

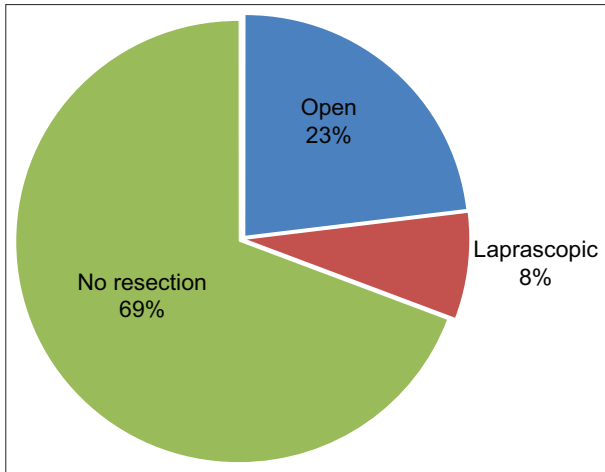


Figure 3: Surgical management of Meckel's diverticulum

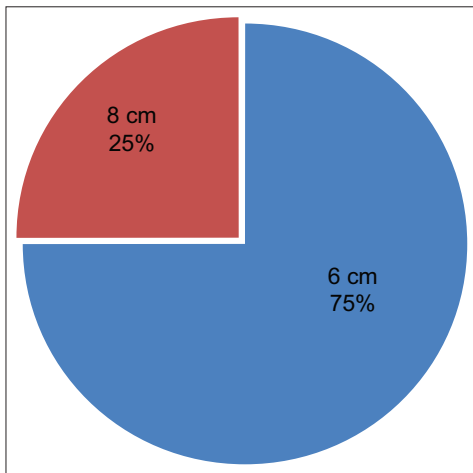


Figure 4: Size of Meckel's diverticulum

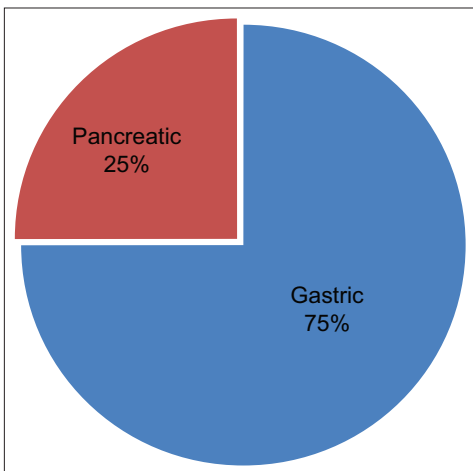


Figure 5: Histopathology of Meckel's diverticulum

Out of 4 patients with Meckel's diverticulum, 3 patients (75%) had the histopathological origin of gastric mucosa, and 1 patient (25%) had origin of pancreatic mucosa [Figure 5].

Table 1: Distribution of clinical manifestations

Clinical manifestations	No. of patients
Incidental findings	9
Perforative peritonitis	1
Intestinal obstruction	1
Acute diverticulitis	1
Recurrent abdominal pain	1

DISCUSSION

Meckel's diverticulum is more common in males than females, with male to female ratio ranging from 2:1 to 4:1. In our study, out of 13 patients, 9 patients (69%) were males and 4 patients (31%) were females. In our study, out of 13 patients, 3 patients (75%) had the histopathological origin of gastric mucosa, and 1 patients (25%) had origin of pancreatic mucosa.

Laparoscopy is not only a useful diagnostic method but also a therapeutic tool, especially in cases of bleeding Meckel diverticulum. It remains controversial whether all incidentally diagnosed Meckel diverticula should be resected. Some authors have promoted the removal of all asymptomatic Meckel diverticulum because of the high risk of subsequent complications and low risk associated with resection.^[12,13] Some authors have advocated resection only in selected cases of Meckel diverticulum, such as who are suspected of having ectopic gastric mucosa or forming adhesive bands.^[14,15] In our study, 4 patients who had symptomatic Meckel's diverticulum were removed and those 9 patients who had incidental finding of asymptomatic Meckel's diverticulum were not resected and kept under follow-up.

Many studies show that Meckel's diverticulum occurs mostly in children's or young adolescents. In our study, out of 13 patients, 10 patients (77%) had age below 40 years and 3 patients (23%) had age above 41 years.

CONCLUSION

Symptomatic Meckel's diverticulum was associated with dreaded complications such as perforative peritonitis, intestinal obstruction, and diverticulitis with severe pain which made us to conclude about even an asymptomatic Meckel's diverticulum found incidentally during acute abdominal surgeries need to be resected.

REFERENCES

1. St-Vil D, Brandt ML, Panic S, Bensoussan AL, Blanchard H. Meckel's diverticulum in children: A 20-year review. *J Pediatr Surg* 1991;26:1289-92.
2. Huang CC, Lai MW, Hwang FM, Yeh YC, Chen SY, Kong MS, *et al.* Diverse presentations in pediatric Meckel's diverticulum: A review of 100 cases. *Pediatr Neonatol* 2014;55:369-75.

3. Simms MH, Corkery JJ. Meckel's diverticulum: Its association with congenital malformation and the significance of atypical morphology. *Br J Surg* 1980;67:216-9.
4. Rattan KN, Singh J, Dalal P, Rattan A. Meckel's diverticulum in children: Our 12-year experience. *Afr J Paediatr Surg* 2016;13:170-4.
5. Dumper J, Mackenzie S, Mitchell P, Sutherland F, Quan ML, Mew D. Complications of Meckel's diverticula in adults. *Can J Surg* 2006;49:353-7.
6. Sagar J, Kumar V, Shah DK. Meckel's diverticulum: A systematic review. *J R Soc Med* 2006;99:501-5.
7. Sinha CK, Fishman J, Clarke SA. Neonatal Meckel's diverticulum: Spectrum of presentation. *Pediatr Emerg Care* 2009;25:348-9.
8. Leijonmarck CE, Bonman-Sandelin K, Frisell J, Räf L. Meckel's diverticulum in the adult. *Br J Surg* 1986;73:146-9.
9. Ymaguchi M, Takeuchi S, Awazu S. Meckel's diverticulum. Investigation of 600 patients in Japanese literature. *Am J Surg* 1978;136:247-9.
10. Weinstein EC, Cain JC, Remine WH. Meckel's diverticulum: 55 Years of clinical and surgical experience. *JAMA* 1962;182:251-3.
11. Deetz D. Perforations peritonitis von einem darmdivertikel mit magenschleimhautbau ausgehend. *Dtsch Z Chir* 1907;88:482-93.
12. Vane DW, West KW, Grosfeld JL. Vitelline duct anomalies. Experience with 217 childhood cases. *Arch Surg* 1987;122:542-7.
13. Pellerin D, Harouchi A, Delmas P. Meckel's diverticulum, revision of 250 children cases. *Ann Chir Infant* 1976;17:157-72.
14. Onen A, Çiğdem MK, Oztürk H, Otçu S, Dokucu AI. When to resect and when not to resect an asymptomatic Meckel's diverticulum: An ongoing challenge. *Pediatr Surg Int* 2003;19:57-61.
15. Felberbauer FX, Niederle B, Teleky B. The truth behind the 'rule of twos' the Meckel diverticulum revised. *Eur Surg* 2007;39:299-306.

How to cite this article: Thirulogachandran V, Maruthupandian S, Karthick G. Meckel's Diverticulum: Still Formidable during Acute Abdominal Surgeries – An Observational Study. *Int J Sci Stud* 2020;7(12):76-79.

Source of Support: Nil, **Conflicts of Interest:** None declared.