

Safety and Outcome of Laparoscopic Heller's Cardiomyotomy with Intraoperative Endoscopic Assessment and Dor's Fundoplication in Primary Achalasia Cardia: A Single-center Prospective Study

M Umamaheshwaran¹, A Shafique², R Selvasekaran³

¹Assistant Professor, Department of Surgical Gastroenterology, Tirunelveli Medical College, Tirunelveli, Tamil Nadu, India, ²Assistant Professor, Department of Medical Gastroenterology, Tirunelveli Medical College, Tirunelveli, Tamil Nadu, India, ³Associate Professor, Department of Medical Gastroenterology, Thoothukudi Medical College, Thoothukudi, Tamil Nadu, India

Abstract

Introduction: Achalasia cardia is a primary esophageal motility disorder of an unknown etiology, characterized by abnormal peristalsis of the esophageal body and the absence of relaxation of the lower esophageal sphincter. Laparoscopic Heller cardiomyotomy is the surgical procedure of choice for achalasia cardia.

Aim: The aim of the study was to the immediate safety and long-term efficacy of laparoscopic Heller's cardiomyotomy with intraoperative endoscopy and Dor's anterior partial fundoplication in patients with achalasia cardia.

Materials and Methods: In this prospective study, laparoscopic Heller's myotomy with intraoperative endoscopy and anterior Dor's fundoplication were performed in all achalasia cardia patients. Patients' demographic, clinical features such as dysphagia grade and Eckardt score, intraoperative, post-operative parameters, and response to treatment on follow-up were analyzed.

Results: In 14 patients, 10 were females (71%), the mean age was 37±14.96 years. Mean pre-operative modified Takita's dysphagia grade was 2.93±0.73. Endoscopic classic findings and barium swallow bird beak sign were diagnostic in all cases. Pre-operative Eckardt score was 8.93±1.44. Eckardt score at discharge was 0.43±0.51 and at 12th month was 0.21±0.43. On analysis, there was a significant improvement in pre-operative values of modified Takita's dysphagia grade and Eckardt score to normal values postoperatively ($P < 0.0001$) and the durable effect was persistently observed in 3rd and 6th, 9th, and 12th-month follow-up.

Conclusion: Laparoscopic Heller's myotomy with intraoperative endoscopy and Dor's fundoplication are safe and effective with significant improvement in post-operative Takita's dysphagia score and Eckardt score.

Key words: Achalasia cardia, Dor's fundoplication, Eckardt score, Laparoscopy Heller's myotomy

INTRODUCTION

Achalasia cardia, even though a rare disease, is the most common esophageal motility disorder with annual

incidence of around 1.6/100,000 persons and prevalence of around 10.8/100,000 persons.^[1] It is associated with abnormalities of esophageal peristalsis and lower esophageal sphincter (LES), causing failure of relaxation of hypertensive LES with swallowing. Classic symptoms of Achalasia cardia are dysphagia, regurgitation especially nasal regurgitation during sleep or supine posture, with recurrent aspiration episodes in chronic cases.^[2] It also causes retrosternal pain, vomiting, and weight loss in long-term cases. End-stage achalasia is defined by the esophageal diameter of more than 6 cm, deviation of long axis of the esophagus with associated sigmoid like

Access this article online



www.ijss-sn.com

Month of Submission : 01-2020
Month of Peer Review : 02-2020
Month of Acceptance : 03-2020
Month of Publishing : 03-2020

Corresponding Author: Dr. M Umamaheshwaran, Department of Surgical Gastroenterology, Tirunelveli Medical College, Tirunelveli, Tamil Nadu, India.

deformation.^[3] Dysphagia is graded by severity according to Takita's classification.^[4]

Table 1, retrosternal pain is mainly caused due to spastic, non-peristaltic, and nonfunctional contractions of the esophagus to propel the esophageal content into the stomach beyond the hypertensive LES. Weight loss is a long time effect due to either nutritional or development of malignancy in this background.

These classic four symptoms – dysphagia, regurgitation, retrosternal pain, and weight loss are included in a clinical Eckardt score.^[5] Each component is assigned a score from 0 to 3 based on the patient's self-reported response, resulting in a total score that can range from 0 to 12.^[5] Eckardt score is an exceptional tool for diagnosis and assessment of the efficacy of treatment during follow-up. Clinical and symptomatic success is defined by a score of 3 or less following a therapeutic intervention [Table 2]. Limitations are, this is a subjective assessment of the patient's symptoms. Objective confirmation of the efficacy of the intervention requires post-operative manometry and timed barium study with additional cost to the patient.

It is diagnosed with classic clinical symptoms, endoscopic findings, and barium swallow. Esophageal manometry with Chicago subtype Classification^[6] helps in pre-operative prognostication of treatment response and selection of intervention.^[7] Treatment of this condition is mainly palliative, relieving the obstruction at LES by dividing the hypertensive LES fibers. At present, available interventions are pharmacotherapy, endoscopic dilatation/botulinum toxin injection, laparoscopic Heller's cardiomyotomy (laparoscopic Heller's myotomy [LHM]), and per oral endoscopic myotomy (POEM).

Table 1: Modified Takita's dysphagia grading

Grade	Findings
I	Able to eat normally
II	Requires liquids with meals
III	Able to take only semisolid food
IV	Able to take only liquids
V	Able to swallow saliva but not liquids
VI	Complete dysphagia

Table 2: Eckardt score for symptomatic evaluation in achalasia

Score	Weight loss (kg)	Dysphagia	Retrosternal pain	Regurgitation
0	None	None	None	None
1	<5	Occasional	Occasional	Occasional
2	5–10	Daily	Daily	Daily
3	>10	Each meal	Each meal	Each meal

The purpose of this study is to evaluate the immediate safety and long-term efficacy of laparoscopic Heller's cardiomyotomy with intraoperative endoscopy and Dor's anterior partial fundoplication in patients with achalasia cardia.

The primary outcome of the study is the effective therapeutic response with a reduction in the dysphagia grade and Eckardt score at the follow-up assessment. Secondary outcomes included feasibility, rate of complications, and symptomatic relief.

MATERIALS AND METHODS

This is a prospective study of achalasia cardia patients diagnosed and treated between December 2017 and December 2018 in our institute by a single surgeon. Patients were regularly followed up, data were prospectively collected and analyzed for the safety and efficacy of the LHM intervention.

Inclusion Criteria

Diagnostic history, Eckardt score, upper endoscopy, high-resolution manometry, barium swallow study was included in the study.

After proper pre-operative evaluation and diagnosis, patients were given a detailed explanation of therapeutic options available such as pharmacologic, pneumatic dilation, surgery, and endoscopic (POEM) treatments. Those patients willing for surgical option and fit to undergo a major laparoscopic surgical procedure were included in this study. Unfit patients and those patients not willing for surgery were excluded from this study. Contrast computed tomography (CT) scan was performed in selected patients with severe weight loss, atypical findings, and advanced age at presentation.

Methodology

After general anesthesia, the patient was placed in a supine position strapped well, with legs apart using stirrups. Laparoscopic equipment placed at the head end of the patient. The surgeon stands between the patient's legs, with assistants standing at both sides of the patient. We use five ports, 10 mm left supraumbilical for the camera, 5 mm bilateral subcostal operating ports, 5 mm epigastric port for liver retraction, and 5 mm left lumbar port for assistance. Under reverse Trendelenburg position, dissection was limited to the anterolateral aspect of the abdominal esophagus and the diaphragmatic crura to prevent future reflux. The anterior vagal trunk was dissected and preserved. Heller's myotomy was started from the lower esophagus and extended for about 6 cm on the esophagus and gastric side for 1–2 cm by blunt technique with cautious and very minimal use of energy devices.

After completion of myotomy, intraoperative endoscopy was performed under laparoscopic vision, to ensure the adequacy and length of myotomy on both esophageal and gastric sides with the free unrestricted easy passage of endoscope across the LES. The myotomy site was immersed in saline and air leakage test was performed by insufflation of endoscopic air with direct visualizations by laparoscopy. After confirmation of the adequacy of myotomy and ruling out perforations, anterior partial Dor's fundoplication was performed by suturing the fundus of the stomach to both edges of myotomy and crura of the diaphragm.

Postoperatively gastrografen dye swallow study was routinely performed after 24 h for ruling out any leak and to confirm the free passage of dye across LES. Oral diet was started and the patient was discharged subsequently once they recover. Patients were followed weekly for the 1st month, 3rd, 6th, 9th months, and 1 year after surgery and dysphagia grade and Eckardt score obtained.

All data values are expressed as mean \pm SD. Comparisons between pre-operative and post-operative values of Eckardt score and variable parameters were analyzed by using paired sample *t*-test, $P < 0.05$ was considered statistically significant.

RESULTS

A total of 14 patients with achalasia cardia were included in this study with 10 females (71%) and 4 males (29%), respectively [Figure 1]. Patients were aged between 13 and 66 years with a mean of 37 ± 14.96 [Figure 2]. Three patients had diabetes and one patient had idiopathic thrombocytopenic purpura (ITP) as comorbidity.

The total duration of symptoms ranged from 6 to 72 months with a mean of 26.43 ± 16.57 . The most common symptom was dysphagia 73 months, Takita's grade 2 in 4 cases (28.6%), 3 in 7 cases (50.0%), and 4 in 3 cases (21.4%), respectively, followed by regurgitation [Figure 3]. The mean modified Takita's dysphagia score was 2.93 ± 0.73 . Retrosternal pain was present in most of the patients. Weight loss was observed in all patients which ranged between 4 and 12 kg with a mean of 7.64 ± 2.53 kg. Endoscopic classic findings and barium swallow bird beak sign were diagnostic in all cases [Figure 4]. Manometry was performed in all cases and Type 2 was present in 12 patients (85.72%) and Types 1 and 3 were present in one patients (7.14%) each. A contrast CT scan chest was done in 4 patients. The maximum diameter of esophagus ranged between 3.70 cm and 10.30 cm with mean value of 5.96 ± 2 cm. The sigmoid esophagus was present in 4 cases

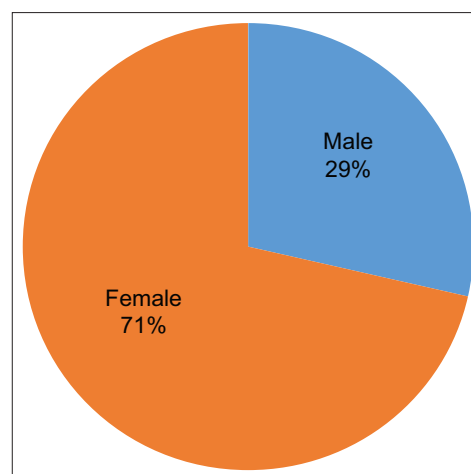


Figure 1: Distribution of gender

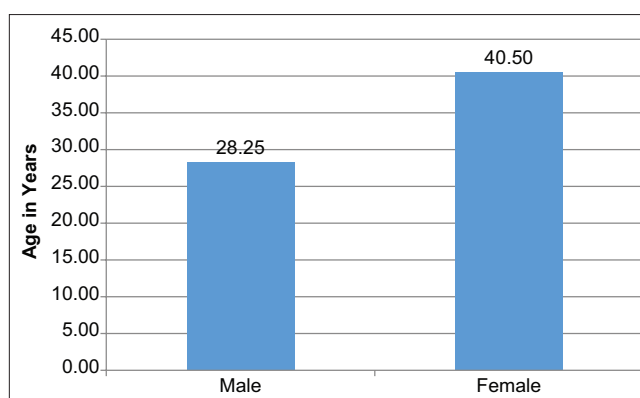


Figure 2: Distribution of age group

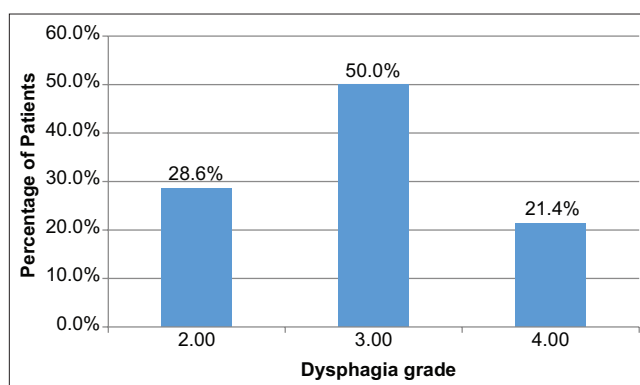


Figure 3: Distribution of dysphagia grade (Takita's)

(28.6%). Pre-operative Eckardt score ranged between 7 and 12 with mean value of 8.93 ± 1.44 .

All cases were performed by laparoscopic technique with no conversion. Intraoperative endoscopy was also performed in all cases to confirm the adequacy of myotomy and leak test was also done in all cases which were negative for any perforation. Extension of myotomy was needed in 5 cases (35.7%). Myotomy was extended on the gastric

Table 3: Distribution of study variables

Variables	Minimum	Maximum	Mean	Standard deviation
Age (years)	13.00	66.00	37.00	14.96
Duration of symptoms (months)	6.00	72.00	26.43	16.57
Weight loss (kg)	4.00	12.00	7.64	2.53
Maximum esophagus diameter (cm)	3.70	10.30	5.96	2.00
Duration of surgery (min)	90.00	150.00	111.07	19.53

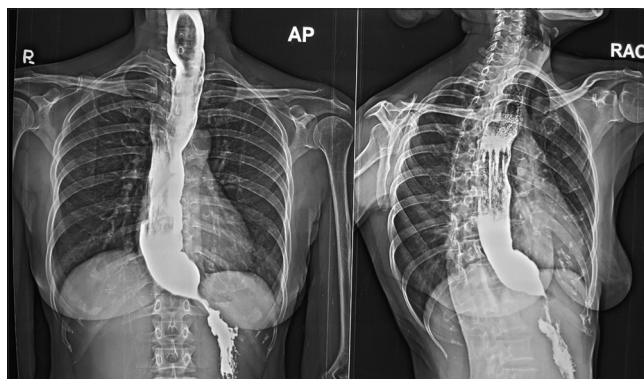
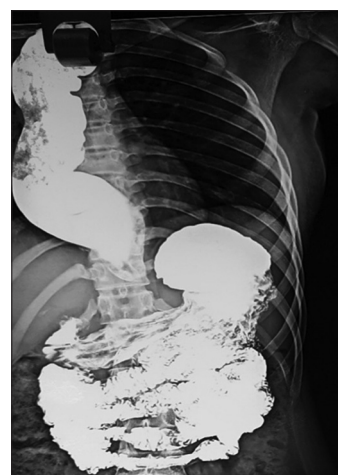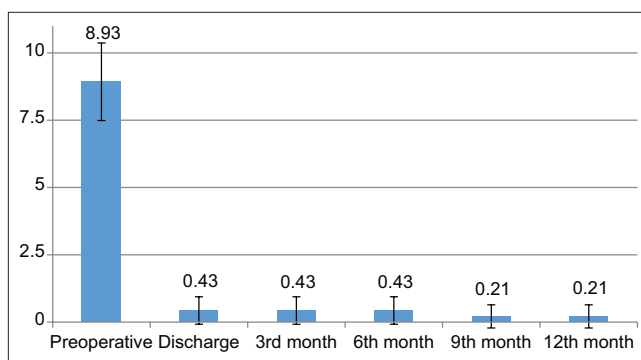
side in 3 cases and esophageal side in 2 cases. All patients underwent anterior Dor's fundoplication without division of short gastric vessels and mobilization of fundus of the stomach. Drains were placed in all cases.

Duration of surgery ranged between 90 and 150 min with a mean of 111.07 ± 19.53 . The only intraoperative complication was bleeding that occurred in one patient with ITP which was controlled without any adverse effect [Table 3].

Post-operative hospital stay ranged between 3 and 7 days with a mean of 3.78 ± 1.18 . Gastrografin dye swallow study was done in all patients after 24 h, which confirmed free passage of contrast across the LES and did not reveal any leak [Figure 5]. Oral intake was resumed in all cases between post-operative days 2–5 with a mean of 2.42 ± 0.85 . Only one patient with ITP developed a small hematoma in the post-operative period which was managed conservatively without any adverse effect, but necessitated delayed oral intake with resultant delayed discharge on the 7th day. All patients were discharged after removal of drain, between 3 and 7 days with a mean value of 3.78 ± 1.18 .

Postoperatively, dysphagia improved to modified Takita's dysphagia grade 1 (able to eat normally) in all patients and the effect was observed until 12 months on follow-up. None of the patients had vomiting or weight loss in post-operative follow-up. Only one patient had occasional episodes of retrosternal pain during 3rd- and 6th-month review. Occasional episodes of regurgitation were observed in 5 patients in 3rd- and 6th-month follow-up (in those patients with extended myotomy). At 1 year follow-up, only 2 patients had occasional regurgitation and none of the patients had dysphagia, vomiting, retrosternal pain, or weight loss. The mean Eckardt scores were 0.43 ± 0.51 at discharge and 0.21 ± 0.43 at the 12th month. On statistical analysis, there was no significant statistical difference noted between 3rd and 6th, 9th, and 12th-month Eckardt scores [Figure 6].

On analysis, there was a significant improvement in pre-operative values of modified Takita's dysphagia grade and Eckardt score to normal values postoperatively ($P < 0.0001$)

**Figure 4: Pre-operative barium swallow****Figure 5: Post-operative swallow study****Figure 6: Distribution of Eckardt score**

and the durable effect was persistently observed in 3rd and 6th, 9th, and 12th-month values.

DISCUSSION

Achalasia cardia is a rare motility disorder of the esophagus with specific clinical features and is diagnosed by classic endoscopic, barium swallow, and manometric findings. Symptoms were graded and classified as per Eckardt score. Treatment is mainly aimed at relieving the obstruction at hypertensive LES. Eckardt score is the best prognostic symptomatic assessment of functional recovery following intervention for Achalasia cardia.^[8] A post-operative score of <3 is the goal for good functional outcomes which should be durable in the long term. A post-operative score of >9 indicated failure of the intervention.^[8]

Of the available pharmacologic, endoscopic, and surgical treatment options – LHM is the gold standard intervention to treat this rare condition.^[9] Heller's cardiomyotomy is done by dividing hypertensive lower esophageal and gastric muscle fibers. LHM has the advantages of minimally invasive surgery such as enhanced magnified vision, minimal pain, and early post-operative recovery.

For better symptomatic improvement, myotomy is done for at least 5 cm on esophageal aspect and extended myotomy is done in selective cases. The gastric aspect of myotomy is performed for at least 1–2 cm. Since myotomy is done under direct magnified laparoscopic vision, mucosal injuries can be detected intraoperatively and repaired immediately. Post-myotomy intraoperative endoscopy is done in all cases to confirm the adequacy of myotomy and an air leak test is also performed to detect microperforations and repaired immediately. Since limited esophageal mobilization was done only on the anterolateral aspect, anterior Dor's fundoplication is done in all cases to cover the myotomy site and to prevent reflux in the future.

Previous studies on achalasia cardia showed that LHM provides excellent symptomatic relief, with efficacy rates from 88% to 95% which lasts for 6–10 years.^[10,11] It is recommended that the myotomy should extend for 4–5 cm in the distal esophagus and 2–3 cm into the gastric side.^[12] Main intraoperative complication is esophageal perforation; in approximately 6.9% of patients, maybe repaired immediately during the surgery.^[13,14] The most common post-operative side effect LHM is the development of reflux. Fundoplication can reduce the chance of developing GERD from 41.5% to 14.5%.^[13] Both Dor and Toupet fundoplication is equally effective in reducing the GERD risk after LHM.^[15]

Our present study included patients from all socioeconomic status and chronic symptoms of more than 6 months. All the patients were operated by a single surgeon at a single institute and uniform operative and post-operative protocol was followed in every patient. Sigmoid esophagus (end-stage achalasia) was present in 4 patients. Type 1 and Type 3 manometric types were present in one patient each. One patient had ITP which caused some intraoperative bleeding and was managed easily without any major complication.

Relief of dysphagia is the most important goal in the management of patients with achalasia, which is confirmed in our study [Figure 3]. All patients with a pre-operative Eckardt score of 7–12 had symptomatic improvement with a post-operative Eckardt score of 0–1, and the effect was persistent during follow-up up to 1 year which is statistically significant. The mean Eckardt scores significantly improved after LCM in all our patients. This successful effect was observed even in Type 1 and Type 3 manometric types. Our study also showed, even in four patients with end-stage sigmoid esophagus, LHM was safe and similarly effective in the long term.

Limitations of the Study

- Prospective observational study with no comparison
- Smaller sample size (rare disease)
- Non-randomized trial
- Shorter follow-up.

CONCLUSION

Achalasia cardia is a chronic esophageal motility disorder that impairs the patient's quality of life, work productivity, functional, and nutritional status. Laparoscopic Heller's cardiomyotomy is the gold standard surgical intervention of all the available interventions for primary achalasia cardia. Our present study confirmed the immediate safety and durable long-term benefits of LHM with intraoperative endoscopy and Dor's fundoplication. The same effect is observed even in Type 3 and severe cases with the sigmoid esophagus. A newer procedure like POEM is emerging as a safer alternative and its long-term effects should be compared with LHM in future studies.

REFERENCES

1. Sadowski DC, Ackah F, Jiang B, Svenson LW. Achalasia: Incidence, prevalence and survival. A population-based study. *Neurogastroenterol Motil* 2010;22:e256-61.
2. Fisichella PM, Raz D, Palazzo F, Niponmick I, Patti MG. Clinical, radiological, and manometric profile in 145 patients with untreated achalasia. *World J Surg* 2008;32:1974-9.
3. Panchanatheswaran K, Parshad R, Rohila J, Saraya A, Makharia GK, Sharma R. Laparoscopic Heller's cardiomyotomy: A viable treatment option for sigmoid oesophagus. *Interact Cardiovasc Thorac Surg* 2013;16:49-54.

4. Peters JH, Meester TR, Stein HJ. Surgical therapy for cancer of the esophagus and cardia. In: Castell DO, editor. *The Esophagus*. 2nd ed. New York: Little, Brown; 1995. p. 293-335.
5. Gockel I, Junginger T. The value of scoring achalasia: A comparison of current systems and the impact on treatment-the surgeon's viewpoint. *Am Surg* 2007;73:327-31.
6. Kahrilas PJ, Bredenoord AJ, Fox M, Gyawali CP, Roman S, Smout AJ, *et al.* The Chicago classification of esophageal motility disorders, v3.0. *Neurogastroenterol Motil* 2015;27:160-74.
7. Vaezi MF, Pandolfino JE, Vela MF. ACG clinical guideline: Diagnosis and management of achalasia. *Am J Gastroenterol* 2013;108:1238-49.
8. Ren Y, Tang X, Chen Y, Chen F, Zou Y, Deng Z, *et al.* Pre-treatment Eckardt score is a simple factor for predicting one-year peroral endoscopic myotomy failure in patients with achalasia. *Surg Endosc* 2017;31:3234-41.
9. Youssef Y, Richards WO, Sharp K, Holzman M, Sekhar N, Kaiser J, *et al.* Relief of dysphagia after laparoscopic Heller myotomy improves long-term quality of life. *J Gastrointest Surg* 2007;11:309-13.
10. Boeckxstaens GE, Annesse V, des Varannes SB, Chaussade S, Costantini M, Cuttitta A, *et al.* Pneumatic dilation versus laparoscopic Heller's myotomy for idiopathic achalasia. *N Engl J Med* 2011;364:1807-16.
11. Persson J, Johnsson E, Kostic S, Lundell L, Smedh U. Treatment of achalasia with laparoscopic myotomy or pneumatic dilatation: Long-term results of a prospective, randomized study. *World J Surg* 2015;39:713-20.
12. Triadafilopoulos G, Boeckxstaens GE, Gullo R, Patti MG, Pandolfino JE, Kahrilas PJ, *et al.* The Kagoshima consensus on esophageal achalasia. *Dis Esophagus* 2012;25:337-48.
13. Campos GM, Vittinghoff E, Rabl C, Takata M, Gadenstätter M, Lin F, *et al.* Endoscopic and surgical treatments for achalasia: A systematic review and meta-analysis. *Ann Surg* 2009;249:45-57.
14. Zaninotto G, Costantini M, Rizzetto C, Zanatta L, Guirroli E, Portale G, *et al.* Four hundred laparoscopic myotomies for esophageal achalasia: A single centre experience. *Ann Surg* 2008;248:986-93.
15. Rawlings A, Soper NJ, Oelschlager B, Swanstrom L, Matthews BD, Pellegrini C, *et al.* Laparoscopic dor versus toupet fundoplication following Heller myotomy for achalasia: Results of a multicenter, prospective, randomized-controlled trial. *Surg Endosc* 2012;26:18-26.

How to cite this article: Umamaheshwaran M, Shafique A, Selvasekaran R. Safety and Outcome of Laparoscopic Heller's Cardiomyotomy with Intraoperative Endoscopic Assessment and Dor's Fundoplication in Primary Achalasia Cardia: A Single Centre Prospective Study. *Int J Sci Stud* 2020;7(12):89-94.

Source of Support: Nil, **Conflicts of Interest:** None declared.