Print ISSN: 2321-6379
Online ISSN: 2321-595X

Original Article

Supraorbital Keyhole Approach for Anterior Circulation Aneurysms: An Institutional Experience

Narendra Singh[1], Manish Agrawal[2], Surendra Jain[3], Jasdeep Singh Khanuja[1], Shashi Kant Jain[4]

[1]Resident, Department of Neurosurgery, Swai Man Singh Medical College, Jaipur, Rajasthan, India, [2]Professor, Department of Neurosurgery, Swai Man Singh Medical College, Jaipur, Rajasthan, India, [3]Assistant Professor, Department of Neurosurgery, Swai Man Singh Medical College, Jaipur, Rajasthan, India, [4]Professor and Head, Department of Neurosurgery, Swai Man Singh Medical College, Jaipur, Rajasthan, India

Abstract

Background: Pterional approach is most accepted and most common approach for clipping of intracranial anterior circulation aneurysms. This approach imparts good exposure of anterior and middle skull base. However the Pterional approach has potential adverse effects, such as long operative time, excessive blood loss, long hospital stay, and temporal muscle atrophy. Supraorbital keyhole via eyebrow incision is a minimal invasive approach for anterior circulation aneurysm surgery. This approach has advantages of less operative time, less blood loss, less brain retraction, short hospital stay and no temporal muscle atrophy.

Objective: Objective of this study to emphasize the advantages and limitations of supra orbital key hole approach for anterior circulation aneurysm surgery based on our institutional experience.

Material and Methods: Between September 2017 and February 2020, total 16 patients with anterior circulation aneurysms were operated by suprorbital keyhole craniotomy approach. All patients included were ≥18 years of age with Subarachnoid hemorrhage grade 1, grade 2, grade 3 on modified fischer scale. Intra operative and postoperative parameter noted and analyzed over a period of 3 months follow up.

Results: There were good cosmetic results with less approach related complications. We achieved good recovery (4/5) on Glasgow outcome scale score 4 or 5 were achieved in 87.5% of the patients in follow period of 3 months.

Conclusion: Supra orbital key hole approach is not a standard approach for all kind of anterior circulation aneurysms, it can be applied for small sized aneurysms with SAH grade up to 3 on modified fischer scale. An thorough pre-op work up, experience, skilled hand are prerequisites for supra orbital keyhole approach in aneurysm surgery. Selection of this approach should be based on aneurysms morphology, size of aneurysm, grade of SAH, brain edema, and the surgeon's experience.

Key words: Anterior circulation aneurysm, Minimal invasive approach, Pterional craniotomy, Supraorbital keyhole surgery

INTRODUCTION

Various conventional approaches such as frontal and pterional approach are used to gain access anterior circulation aneurysms. These approaches impart excellent exposure to anterior and middle crania fossa. Major disadvantages of these approaches are such as long operative period, extensive brain retraction, more blood loss, long operative time, and poor cosmetic results. The evolution of these approaches from Dandy's frontotemporal "macrosurgical approach" to the supraorbital keyhole approach has served to provide satisfactory exposure to safely address different intracranial pathologies.[1] Keyhole approach for intracranial pathologies has shown how a evidently small incision can be sufficient for operating on tumors and aneurysms. The cosmetic results are considerably better in this approach.[2] The aim of "keyhole" surgery was not to achieve a small size incision and craniotomy for the purpose of a small opening. The goal of keyhole approach was to entitle adequate access to intracranial lesions while restricting trauma to adjacent tissue such as the skin, bone, dura, and brain.[3,4] Keyhole approach may not be suitable for all kind of lesions of the anterior skull base. There is a narrow viewing angle through this approach that may require frequent adjustment of the operating room table and microscope for adequate visualization of a given lesion. Illumination is often another problem as getting adequate light through

Access this article online

www.ijss-sn.com

Month of Submission : 04-2020
Month of Peer Review : 05-2020
Month of Acceptance : 06-2020
Month of Publishing : 06-2020

Corresponding Author: Manish Agrawal, Department of Neurosurgery, Swai Man Singh Medical College, Jaipur, Rajasthan, India.

such a small opening onto a deep-seated target areas.[2,5] In case of vascular lesions, a smaller opening in a blood-filled area can also make it burdensome to procure adequate vascular control without injury to neighboring structures.[6] Relative contraindications comprise the presence of a large frontal sinus, recent subarachnoid hemorrhage, and severe brain edema.[7,8] Almost all aneurysms of anterior circulation being amenable to clipping by supraorbital keyhole approach due to refinements in operative techniques. Supraorbital craniotomy approach has been shown to be efficacious and secure for anterior circulation aneurysms. This approach has many advantages such as less operative time, less retraction for brain, less blood loss, short hospital stay with good cosmetic outcome, and similar rate of complications related to the surgical treatment of anterior circulation aneurysms compared to conventional approaches.[5] Along with this rationale, we present our experience in clipping 16 anterior circulation aneurysms operated through supraorbital keyhole approach in a tertiary care hospital.

MATERIALS AND METHODS

Between September 2017 and February 2020, a total of 16 patients with anterior circulation aneurysms were operated by supraorbital keyhole craniotomy approach. All patients included were ≥18 years of age with subarachnoid hemorrhage Grade 1, Grade 2, and Grade 3 on modified Fisher scale computed tomography with anterior circulation aneurysm (anterior communicating, anterior cerebral artery aneurysm of A1, middle cerebral artery aneurysm M1 and M2 segment, and internal carotid artery bifurcation) on computed angiography brain [Figure 1]. In post-operative period, all patients underwent computed angiography.

Surgical Technique

The supraorbital keyhole approach executed in this study was delineated in detail by Perneczky *et al.*[4] The patient was placed in the supine position with head elevated 30° above the level of the heart and turned between 15° and 60° to the opposite side of intended site of incision. The degree of head rotation relies on the location of aneurysm. Extent of head rotation for the anterior communicating artery, middle cerebral artery, and internal cerebral artery was 40–60°, 15°, and 20–30°, respectively. The neck was slightly extended so that the zygomatic arch was the highest point. This position permits the gravity assisted self-retraction of the frontal lobe.

After sterilizing the surgical field, skin incision was made in the superior edge of the eyebrow or on the forehead crease just above the eyebrow, starting from the midpupillary line and extending laterally to just behind the frontal process of the zygomatic bone. The supraorbital nerve and artery, the frontal branches of the facial nerve, and the superficial temporal artery were always protected. Subcutaneous dissection was done from the supraorbital foramen to the frontozygomatic suture [Figure 1]. The temporalis fascia was incised close to its attachment at the anterior temporal line. Subperiosteal dissection of the temporalis muscle was done to expose the keyhole burr hole site. A burr hole was made on the superior temporal line, just above the frontal base. The craniotomy was performed using a high-speed drill. The medial-inferior edge of the craniotomy went around the level of the frontal base and the lateral edge to the sphenoid wing, at a width of 25–30 mm and a height of 15–25 mm [Figure 2]. A large frontal sinus is a relative contraindication to this approach. If the frontal sinus was entered inadvertently, it was exenterated by removing and cauterizing its mucosa and covered with a periosteal flap. The dura was opened in a semicircular fashion at frontal base. A traditional microsurgical technique was implemented with optimal illumination with an operative microscope. The arachnoid of the carotid cistern, the Sylvian fissure, and suprasellar cisterns were opened for cerebrospinal fluid (CSF) drainage, to create enough room for brain retraction and surgical manipulation. Lamina terminalis was sometimes opened to drain CSF. Water tight dural closure done at the end of surgery. Bone flap replaced and fixed with miniplates and screws. The

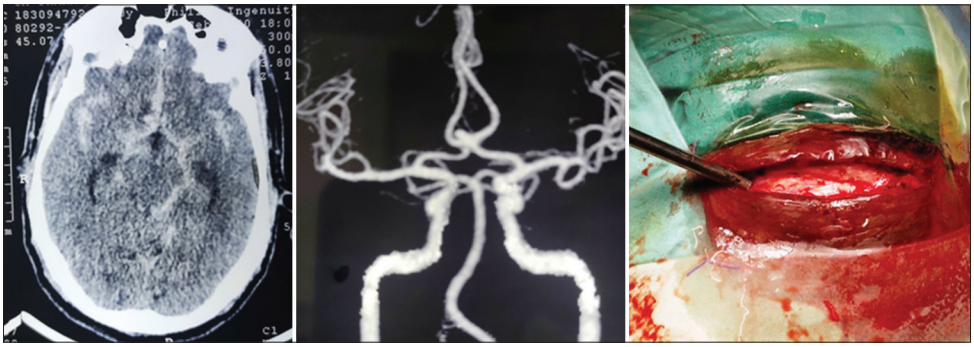

Figure 1: From left to right modified Fisher Grade 3 subarachnoid hemorrhage, second image shows Acom aneurysm, supraorbital skin incision, and dissection of subcutaneous tissue and frontalis muscle

Table 1: Pre-operative parameters

Age (years)	Sex	Hunt and Hess grade	Glasgow Coma Scale on admission	Modified Fisher grade of subarachnoid hemorrhage	Aneurysm location	Aneurysm size (mm)	Aneurysm shape
19	F	1	E4V5M6	1	Left ICA bifurcation	4.2 × 4.5	Saccular
55	M	2	E4V5M6	2	Acom	2.8 × 2.9	Saccular
43	F	2	E4V5M6	2	Acom	3.7 × 4.0	Saccular
45	M	2	E4V4M6	2	Acom and right ICA bifurcation	3.5 × 3.8 and 5.2 × 5.4	Saccular
55	F	2	E4V5M6	2	Acom	4.2 × 4.4	Bilobed
58	F	3	E4V2M5	2	Left ICA bifurcation	6.9 × 7.1	Saccular
45	F	2	E4V5M6	1	Acom and right MCA bifurcation	3.5 × 4.1 and 7.6 × 8.2	Saccular
46	M	3	E4V3M5	3	Acom	3.8 × 3.9	Saccular
57	F	2	E4V5M6	2	Acom	3.3 × 3.7	Multilobed
41	F	2	E4V5M6	1	Acom	4.1 × 4.3	Saccular
43	M	2	E4V5M6	1	Acom	4.0 × 4.2	Saccular
54	F	1	E4V5M6	2	Acom	3.6 × 3.7	Saccular
55	M	1	E4V5M5	1	Right ACA (A1 part)	5.7 × 5.9	Saccular
76	F	2	E4V5M6	2	Acom	3.5 × 3.8	Saccular
40	M	2	E4V5M6	1	Acom	3.3 × 3.6	Saccular
45	F	2	E4V5M6	2	Acom	4.4 × 4.5	Saccular

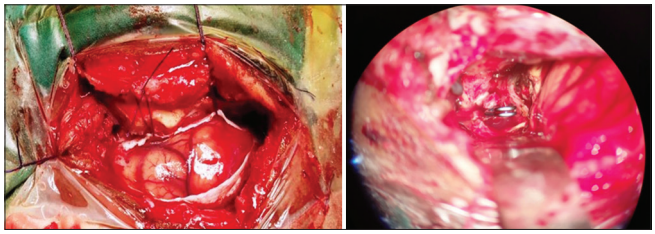

Figure 2: Left to right, brain edema after supraorbital keyhole craniotomy, microscopic view shows clipped Acom aneurysm

temporalis muscle and fascia were sutured back to the frontal pericranium. The surgical wound closed in layers. Skin incision closed with subcuticular sutures.

Data Collection

Pre-operative data collection included were age, sex, gender, clinical presentation, grading on Hunt and Hess scale, Glasgow Coma Scale on admission, subarachnoid hemorrhage grading on modified Fisher scale, and aneurysm morphology in form of size, shape, and direction.

Intraoperative data collection included were duration of surgery, violation of frontal sinus, and premature rupture of aneurysm before proximal control.

Post-operative data collection in follow-up period of 3 months included aneurysm clipping complete or incomplete, presence or absence of vasospasm, periorbital edema, surgical site infection, CSF leakage, numbness of supraorbital area, inability to raise eye brow, mucocele and depression of operated site, hospital stay, and outcome on Glasgow Outcome Scale.

DATA ANALYSIS AND RESULTS

Patients' age ranged from 19 to 76 years with a mean of 48.5 years. There were 10 (62.5%) females and 6 (37.5%) males. Sixteen patients were admitted after subarachnoid hemorrhage (SAH), 3 (18.7%) were in Grade 1, 11 (68.7%) in Grade 2, and 3 (18.7%) in Grade 3 on Hunt and Hiss scale. SAH grading on modified Fisher scale of patients was 6 (37.5%) in Grade 1, 9 (56.2%) in Grade 2, and 1 (6.25%) in Grade 3. There were total of 18 aneurysms in 16 patients at various locations (anterior communicating [72.2%], internal carotid bifurcation [16.6%], middle cerebral artery [5.5%], and proximal anterior cerebral artery [5.5]) and morphology. All aneurysms were ruptured. Size of aneurysm was ranged from 2.8 mm to 8.2 mm [Table 1]. All aneurysms clipped through supraorbital keyhole approach.

Duration of surgery (from skin incision to last skin suture) varied between 105 min (1 h 45 min) and 210 min (3 h 30 min). Average duration of surgery was 163 min (2 h 43 min). Inadvertent violation of frontal sinus was present only in two patients. Premature rupture of aneurysm before proximal control was present in two patients. Temporary clip used in 12 patients with average period of 4.8 min [Table 2].

Average drop in hematocrit was 4.14. Aneurysm occlusion was complete in all patients, Radiologically evident vasospasm was present in two patients. Transient periorbital edema was present in all patients. One patient developed subdural hygroma in post-operative period which treated with burr hole and suction evacuation. There was no surgical site infection. CSF leakage noted in two patients

which was managed conservatively. Transient numbness of supraorbital area was present in two patients and permanent numbness was present in one patient. Inability to raise eye brow transiently was present in two patients. Average hospital stay was 13 days. Post-operative Glasgow Coma Scale was 15/15 in 14 patients which was same as pre-operative period and E4VtM5 in two patients on discharge which was improved and gain consciousness. Good recovery was present in 87.5% on Glasgow Outcome Scale which was 5 in 12 patients and 4 in 2 patients. There were no mucocele formation and depression of operated site [Table 3].

Table 2: Intraoperative parameters

Violation of frontal sinus	Drop in hematocrit	Premature rupture of aneurysm	Duration of surgery (minutes)
No	2.52	No	178
No	5.58	No	155
No	4.08	No	168
No	2.45	No	125
No	3.98	No	136
No	4.10	Yes	210
No	4.25	No	131
No	6.21	Yes	206
No	4.41	No	178
Yes	4.33	No	128
No	4.23	No	170
No	5.10		200
Yes	2.98	No	105
No	3.70	No	188
No	4.24	No	148
No	4.15	No	185

DISCUSSION

The supraorbital keyhole craniotomy approach can be considered as a standard for clipping of different kinds of anterior circulation aneurysms. This approach has advantages such as small incision, small bone window compared to standard craniotomy with similar outcomes on Glasgow Outcome Scale, but requires prominent microneurosurgical techniques and instrumentation.[1] Good recovery GOS (4/5) achieved in 87.5% of patients on Glasgow Outcome Scale which was comparable to outcomes (76.6–82.6% in

Table 3: Post-operative parameters

GOS	Complete clipping of aneurysm	Surgical site infection	CSF leak	Hospital stay (days)	Numbness over supraorbital area	Inability to elevate eyebrow	Depression of surgical site
5	Yes	No	No	12	Absent	No	No
5	Yes	No	No	15	Absent	No	No
5	Yes	No	No	14	Absent	No	No
4	Yes	No	Yes	13	Transient	No	No
5	Yes	No	No	17	Absent	No	No
1	Yes	No	No	07	-	-	-
5	Yes	No	No	18	Absent	No	No
1	Yes	No	No	05	-	-	-
5	Yes	No	No	19	Absent	No	No
5	Yes	No	No	14	Transient	Transient	No
5	Yes	No	No	16	Absent	No	No
5	Yes	No	No	08	Absent	No	No
4	Yes	No	Yes	15	Transient	No	No
5	Yes	No	No	10	Permanent	No	No
5	Yes	No	No	11	Absent	No	No
5	Yes	No	No	17	Absent	No	No

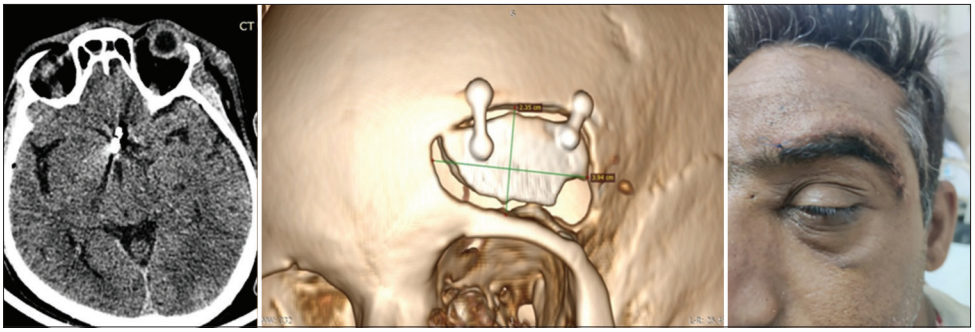

Figure 3: Left to right, NCCT head showing aneurysm clip *in situ*, 3D reconstruction shows post-supraorbital craniotomy defect with miniplates and screw, post-surgical scar mark in post-operative period

supraorbital craniotomy approach and 75–79.5 in pterional approach) in a study by Chalouhi *et al*.[9] One prevalent problem to this concept is the restricted access and scope for manipulation during aneurysm dissection which may lead to premature rupture of aneurysm. Premature ruptured rate was lower (12.5%) in our study as compared to Radonovic *et al*.[10] and Chalouhi *et al*.[9] (13.8%) in pterional craniotomy approach. The key to the problem is a thorough knowledge of microanatomy learned on cadavers. Average operative time was 163 min comparable to 150 min in a study of Won-Sang Cho *et al*.[11] Drop in hematocrit was 4.14 similar to Yuhee Kim *et al*.[12] Case selection is definitely important, as it is for one's ability to work in narrow, confined spaces. Evolution of tube shaft instruments has made this approach possible. Generous opening of arachnoid spaces, as well as Sylvian fissure, is imperative to achieve relaxation of the brain and corridor to the aneurysm location.[13] Dare *et al*. reported on the effective use of this approach in elective surgery of 10 aneurysms of the anterior circulation. The mean aneurysm size was 5.9 mm, with a range of 4–10 mm. They emphasized the advantage of this approach that incorporate minimal disruption and exposure of normal brain tissue, reduced frontal lobe retraction and an excellent post-operative cosmetic outcome.[6] In our study, we achieved similar outcome on Glasgow Outcome Score with good cosmetic results [Figure 3].

CONCLUSION

Supraorbital keyhole approach has many merits and also limitations compared to pterional approach. Supraorbital keyhole approach is not a standard approach for all kind of anterior circulation aneurysms, it can be safely applied for small-sized aneurysms with SAH grade up to 3 on modified Fisher scale with similar outcome on Glasgow Outcome Scale compared to pterional approach with good cosmetic results. A thorough pre-operative workup, experience, and skilled hand are prerequisites for supraorbital keyhole approach in aneurysm surgery. High-grade subarachnoid hemorrhage, brain edema, and giant aneurysm can limit the accessibility to aneurysm and may lead to premature rupture of aneurysm so selection of this approach should be based on aneurysms morphology, size of aneurysm, grade of SAH, brain edema, and the surgeon's experience.

REFERENCES

1. Reisch R, Perneczky A. Ten-year-experience with the supraorbital approach through an eyebrow skin incision. Neurosurgery 2005;57:242-55.
2. Mitchell P, Vindlacheruva RR, Mahmood K, Ashpole RD, Grivas A, Mendelow AD. Supraorbital eyebrow minicraniotomy for anterior circulation aneurysms. Surg Neurol 2005;63:47-51.
3. Perneczky A. Planning strategies for the suprasellar region: Philosophy of approaches. Neurosurgeon 1992;11:343-8.
4. Reisch R, Perneczky A, Filippi R. Surgical technique of the supraorbital key-hole craniotomy. Surg Neurol 2003;59:223-7.
5. Ormond DR, Hadjipanayis CG. The supraorbital keyhole craniotomy through an eyebrow incision: Its origins and evolution. Minim Invasive Surg 2013;2013:296469.
6. Dare AO, Landi MK, Lopes DK, Grand W. Eyebrow incision for combined orbital osteotomy and supraorbital minicraniotomy: Application to aneurysms of the anterior circulation. Technical note. J Neurosurg 2001;95:714-8.
7. Bhatoe HS. Transciliary supraorbital keyhole approach in the management of aneurysms of anterior circulation: Operative nuances. Neurol India 2009;57:599-606.
8. van Lindert E, Perneczky A, Fries G, Pierangeli E. The supraorbital keyhole approach to supratentorial aneurysms: Concept and technique. Surg Neurol 1998;49:481-9.
9. Chalouhi N, Jabbour P, Ibrahim I, Starke RM, Younes P, El Hage G, *et al*. Surgical treatment of ruptured anterior circulation aneurysms: Comparison of pterional and supraorbital keyhole approaches. Neurosurgery 2013;72:437-41.
10. Radovanovic I, Abou-Hamden A, Bacigaluppi S, Tymianski M. A safety, length of stay, and cost analysis of minimally invasive microsurgery for anterior circulation aneurysms. Acta Neurochir (Wien) 2014;156:493-503.
11. Cho WS, Kim JE, Kang H, Son YJ, Bang JS, Oh CW. Keyhole approach and neuroendoscopy for cerebral aneurysms. J Korean Neurosurg Soc 2017;60:275-81.
12. Kim Y, Yoo CJ, Park CW, Kim MJ, Choi DH, Kim YJ, *et al*. Modified supraorbital keyhole approach to anterior circulation aneurysms. J Cerebrovasc Endovasc Neurosurg 2016;18:5-11.
13. Veznedaroglu E, Benitez RP, Rosenwasser RH. Surgically treated aneurysms previously coiled: Lessons learnt. Neurosurgery 2004;54:300-3.

How to cite this article: Singh N, Agrawal M, Jain S, Khanuja JS, Jain SK. Supra Orbital Keyhole Approach for Anterior Circulation Aneurysms: An Institutional Experience. Int J Sci Stud 2020;8(3):76-80.

Source of Support: Nil, **Conflicts of Interest:** None declared.