

Retrocaval Ureter with Proximal Hydroureteronephrosis Presenting as Flank Pain in a Child: A Rare Case Report with Review of Literature

Mahendra Kumar Jangid¹, Reyaz Ahmad², Priya Jangid³, Sujeet K Pandre⁴, Gurpreet Kaur⁵

¹Assistant Professor, Department of Paediatric Surgery, All India Institute of Medical Science, Bhopal, Madhya Pradesh, India, ²Associate Professor, Department of Paediatric Surgery, All India Institute of Medical Science, Bhopal, Madhya Pradesh, India, ³Post Graduate Student, Department of Pathology, Jawahar Lal Nehru Medical College, Ajmer, Rajasthan India, ⁴Senior Resident, Department of Paediatric Surgery, All India Institute of Medical Science, Bhopal, Madhya Pradesh, India, ⁵Junior Resident, Department of Paediatric Surgery, All India Institute of Medical Science, Bhopal, Madhya Pradesh, India

Abstract

Retrocaval ureter also referred to as pre-ureteral vena cava or circumcaval ureter is a rare congenital anomaly with the ureter passing posterior to the inferior vena cava. Although it is a congenital anomaly, patients do not normally present with symptoms until the 3rd and 4th decades of life after a resulting hydronephrosis. We present the report of a 12-year-old male child with a history of right flank pain and associated right proximal hydroureteronephrosis. Diagnosis was confirmed with computerized tomography urography, and an open surgical repair was done for the anomaly. The case is discussed here along with review of recent literature.

Key words: Circumcaval ureter, Flank pain, Hydroureteronephrosis, Pre-ureteral vena cava retrocaval ureter

INTRODUCTION

Retrocaval ureter, also called circumcaval ureter or pre-ureteral vena cava, is a rare congenital anomaly in which ureter deviates medially passing behind the inferior vena cava (IVC) and winding around it before crossing anteriorly and laterally to resume its normal course distally.^[1] The condition usually becomes symptomatic in the 3rd or 4th decade of life due to hydronephrosis from kinking of the ureter, compression, or aperistaltic retrocaval segment.^[2] Most patients present with right flank pain, recurrent urinary tract infection (UTI), renal stones, and hydronephrosis. It is also one of the causes of pelviureteric junction obstruction. Retrocaval ureter may be asymptomatic and discovered during imaging or surgery for

unrelated pathology or at autopsy. Repair usually involves resection of the redundant retrocaval ureteral segment and reanastomosis.^[3] The surgical approach for this entity has shifted from open to laparoscopic and robotic surgery [Table 1].

CASE REPORT

A 12-year-old boy presented with right flank pain for 8 months, and the pain was dull and intermittent. There was no other history related to urinary tract symptoms such as hematuria, burning micturition, and retention. No abnormality was found on general and abdominal physical examination. Complete laboratory evaluation including urinalysis, complete blood picture, urea, creatinine, and electrolytes was within normal limits. On ultrasonography (USG), moderate hydronephrosis and upper hydroureter were found. Contrast computerized tomography (CT) urography of the abdomen revealed hydronephrosis and dilatation of the right proximal ureter up to the level of L3. The ureter was found to be coursing medially posterior to the IVC, at this level with

Access this article online



www.ijss-sn.com

Month of Submission : 04-2019
Month of Peer Review : 05-2019
Month of Acceptance : 05-2019
Month of Publishing : 06-2019

Corresponding Author: Dr. Mahendra Kumar Jangid, 20, Sarla Paradise, BDA Road, Awadhपुरi, Bhopal, Madhya Pradesh, India.

Table 1: Published reports of operative repair of retrocaval ureter

S. No.	Study	Period	No. of patient	Median age of diagnosis	Male/ female	Presentation	Diagnostic investigation	Type of retrocaval ureter	Treatment approach	Operation	DJ remove	Follow up
1	Fernando <i>et al.</i> ^[20] 2018	2018	1	14 years	Male	Incidental diagnosed during UDT evaluation	USG then IVP	Type I	Open, flank incision retroperitoneal approach	DJ stent ureteroenteric anastomosis	-	12-week DTPA scan
2	Agarwal <i>et al.</i> ^[21] 2018	2018	1	33 years	Female	Flank pain	USG then IVP CT, DTPA scan	Type I		Ureteroureterostomy		6 months
3	Tamhankar <i>et al.</i> ^[22] 2017	2013–2016	6	29.6 years (14–50 years)	All male	Flank pain	USG CE CT RCU, DTPA scan	Type I	Laparoscopic transperitoneal DJ stent	Ureteroureterostomy	6 weeks	1 year
4	Rehan <i>et al.</i> ^[23] 2017	2017	1	31 years	Female	Flank pain	USG DJ stenting CT, DTPA scan	Type I	Open subcostal incision	Open subcostal	6 weeks	6-month DTPA scan
5	Ahmed <i>et al.</i> ^[24] 2017	2010–2017	4	31.8 years (9–48 years)	2+2	Flank pain, hematuria-3 Incidental for APD	USG then IVP MRI	Type I Type II	Open subcostal incision-3	Pyeloureterostomy, ureteroureterostomy		
6	Shah <i>et al.</i> ^[25] 2016	2016	1	19 years	Male	Flank pain	USG, IVP, CT urography		Open conservative	Pyeloureterostomy with DJ stenting	6 weeks	2 months
7	Bhattacharjee <i>et al.</i> ^[26] 2016	2016	1	40 years	Male	Cyclic abdominal pain	USG, IVP, CT urography	Type I	Laparoscopic, transperitoneal	Ureteroenteric anastomosis with DJ stent	6 weeks	-
8	Pradnaybendre <i>et al.</i> ^[27] 2016	2016	1	5 years	Male	Flank pain	USG, DTPA, CT IVP		Open, right transverse incision	Ureteroenteric anastomosis with DJ stent	6 weeks	3 months
9	Tuncer <i>et al.</i> ^[28] 2016	2013–2016	3	17.66 (13–24 years)	Male-2 Female-1	Lumber pain, hematuria	USG, IVP	Type I	Open, flank incision	Ureteroenteric anastomosis with DJ stent	6 weeks	3-month IVP
10	Fidalgo <i>et al.</i> ^[29] 2016	2016	1	40 years	Male	Flank pain	USG, CT, MAG 3 scan		Laparoscopic transperitoneal	Pyeloureterostomy	6 weeks	3 months
11	Deepak Pankaj <i>et al.</i> ^[30] 2015	2015	1	27 years	Female	Right flank pain, burning micturition	USG, IVP then CT		Open lumbar abdominal approach	Ureteroenteric anastomosis with DJ stent	6 weeks	
12	Pradeep Kajal <i>et al.</i> ^[31] 2015	2015	1	6 years	Female	Right flank pain	USG, IVP, DTPA then CT		Open loin incision	Pyeloureteric anastomosis with DJ stent	3 weeks	
13	Ricciardulli <i>et al.</i> ^[32] 2015	2002–2013	27	28 years (21–39 years)	20+7	Flank pain-10, haematuria-7, UTI-6, Asympt. 4	USG, IVP then CT	Type I	Laparoscopic retroperitoneal approach	Ureteroureterostomy with DJ stent	4–6 weeks	12 months
14	Kamble <i>et al.</i> ^[33] 2014	2014	1	30 years	Male	Right flank pain, dysuria	USG, IVP	Type	Open lumbar incision	Ureteroenteric anastomosis with DJ stent	4 weeks	
15	Vs <i>et al.</i> ^[34] 2014	2014	1	45 years	Female	Right flank pain, dysuria	USG, IVP	Type I	Open loin incision retroperitoneal approach	Ureteroenteric anastomosis with DJ stent	6 weeks	

(Contd...)

Table 1: (Continued)

S. No.	Study	Period	No. of patient	Median age of diagnosis	Male/ female	Presentation	Diagnostic investigation	Type of retrocaval ureter	Treatment approach	Operation	DJ remove	Follow up
16	Bassiouny et al. ^[15] 2013	2012	2	Newborn	1+1	Antenatally detected hydronephrosis	USG, MCU, CT	Type I Type II	Open right subcostal approach conservative	Ureteroureterostomy		
17	Nayak et al. ^[55] 2012	2006–2009	5	27.8 years	4+1		IVU, CT, MRI		Robotic transperitoneal approach	Ureteroureterostomy-3, pyeloplastomy 2	6 weeks	12.5 months
18	Kye et al. ^[9] 2010		2	38 years (36,40 years)	1+1	Flank pain	USG, retrograde pyeloureterogram, CT	Type II	Open midline approach	Pyeloureterostomy with DJ stent	5 weeks	
19	Yarmohammadi et al. ^[10] 2006	1983–2005	13	23 years (12–27 years)	12+1	Pyelonephritis-7, flank pain-4, calcula-1, hematuria-1	USG, IVP, CT	Type I	Open subcostal retroperitoneal approach	Ureteroureterostomy		6 months with IVP
20	Iqba and Ansari ^[8] 2006	2006	1	35 years	Male	Flank pain	USG, IVP, CT		Open subcostal retroperitoneal approach	Ureteroureterostomy		6 months with IVP

CT: Computerized tomography, MRI: Magnetic resonance imaging, USG: Ultrasonography, IVP: Intravenous pyelogram, DTPA: Diethylenetriaminepentaacetic acid, MAG 3: Mercaptoacetyltriglycine, UDT: Undescended testis, MCU: Micturating Cystourethrogram

normal caliber distal to it. Findings were consistent with retrocaval ureter [Figure 1].

Right kidney and ureter were approached by midline vertical incision and medial mobilization of ascending colon done. On exploration, right proximal ureter and pelvis were dilated. Dilated proximal ureter was curved medially then posterior to IVC. Finally, curved anterolaterally to IVC and took a downward course [Figure 2]. Distal ureter was normal. Ureter was dissected and separated anteriorly from IVC and transected at U curved site of ureter. Ureter was anteriorized, spatulated, and an oblique ureteroureteral anastomosis was performed over DJ stent using 5/0 Vicryl [Figure 3]. The patient recovered uneventfully. The patient was allowed orally on post-operative day, catheter remove on post-operative day 2 and was discharged on post-operative day 5. DJ stent [Figure 4] was removed after 3 weeks. An USG done 3 months after surgery showed regression of hydronephrosis and hydroureter.

DISCUSSION

Retrocaval ureter is a rare congenital abnormality. It occurs in 1 in 1500 live births at autopsy,^[4] with an overall incidence of about 0.006–0.17%.^[5-7] It was first reported by Hochstetter in 1893.^[6] It is more common in males, with a male-to-female ratio between 3 and 4:1.^[8] In clinical practice, reported cases have also shown male preponderance [Table 1].^[5,9,10]

The anomaly is thought to occur because of the abnormal formation of infrarenal IVC from anteriorly located subcardinal instead of supracardinal veins which are located posteriorly.^[2] In normal circumstances, the infrarenal IVC originates from dorsally located supracardinal vein, but when it develops from ventrally located subcardinal vein, the ureter is trapped posteriorly leading to pre-ureteral vena cava.^[2] It mainly occurs on the right side but can be on the left side in patients with the very rare situs inversus, duplication of IVC, or persistent left subcardinal vein.^[11,12]

Associated anomalies with retrocaval ureter are reportedly up to 21% and are mainly related to the cardiovascular and urogenital systems (including duplication of IVC, situs inversus, horseshoe kidney, ureteral duplication ureteropelvic junction obstruction, congenital lack of the vas deferens, hypospadias, extra vertebra, diverticulum, anterior urethral calculus, kidney agenesis, syndactyly, intestinal malrotation, and Goldenhar syndrome).^[10-12] None of these anomalies was seen in our patients.

Although it is congenital in origin, most of the reported cases presented in the 3rd or 4th decade because of the

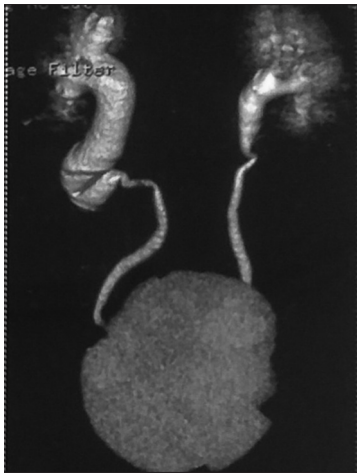

Figure 1: Pre-operative #D reconstructive image of computerized tomography urography reveals right retrocaval ureter with proximal dilated pelvis and proximal ureter

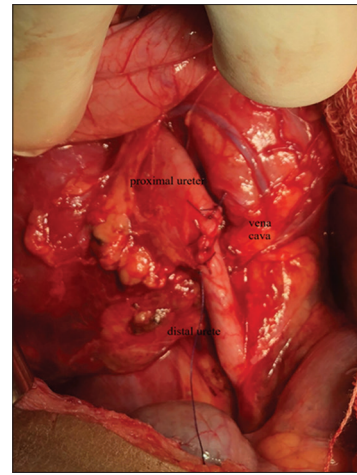


Figure 3: Operative picture of retrocaval ureter after correction as ureteroenteric anastomosis

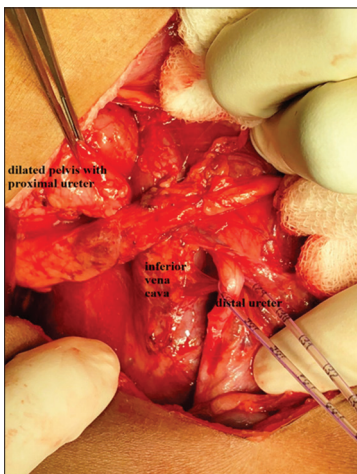

Figure 2: Intraoperative pic of retrocaval ureter with dilated pelvis and proximal ureter, vena cava, and distal ureter

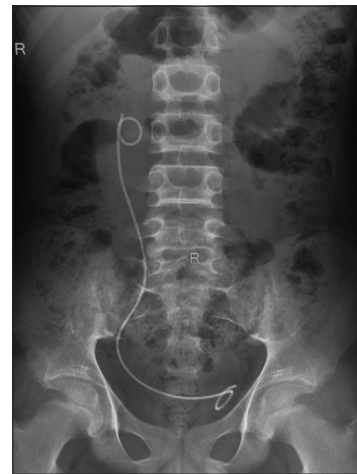

Figure 4: Post-operative kidney, ureter and bladder X-ray with DJ stent

gradual nature of the hydronephrosis. However, symptoms can occur earlier^[13,14] as in our case in which symptoms manifested at 12 years of age and also reported in neonatal period.^[15] Patients usually complain of right-sided flank pain and features of recurrent UTI, which typify the mode of presentation. In some cases, hematuria and renal stone may also be present. However, it should be noted that some cases remain asymptomatic and are only incidentally discovered during evaluation for unrelated disease conditions.

Bateson and Atkinson classified retrocaval ureter into two types based on radiological appearance and the site of narrowing of ureter in 1969.^[1] Type I has the typical S-shaped, “fish hook,” or “Shepherd crook” deformity and associated with extreme medial deviation in 50% of the cases at the level of third lumbar vertebral segment and moderate-to-severe hydronephrosis. This type accounts for

most of the symptomatic cases. Type II is associated with a more gentle curve appearing as J-shaped or “sickle”-shaped deformity with mild medial deviation at the level of renal pelvis, with mild or no hydronephrosis in 10% of the cases and most are asymptomatic.^[1]

Abdominal ultrasound can at best demonstrate the presence of hydronephrosis since it poorly delineates the ureter, while IVU readily demonstrates hydroureteronephrosis with upward curving and abrupt termination of the ureter and non-visualization of the middle and distal thirds of the ureter. Spiral CT is considered the investigation of choice compared to IVU because it can delineate both the ureter and IVC [Table 1]. Magnetic resonance imaging may be better than the CT as it can delineate the course of the entire ureter and is not associated with exposure to radiation as compared to IVU or CT.^[16] The diagnosis of retrocaval ureter can be confirmed pre-operatively with antegrade or retrograde pyelography. Diuretic

renography with diethylenetriaminepentaacetic acid or mercaptoacetyltriglycine can assess the level of obstruction and determine the best therapeutic modality [Table 1].^[13]

Asymptomatic patients and those with mild hydronephrosis and infection can be managed non-operatively and followed up subsequently, while surgical treatment is required in symptomatic patients or those with severe hydronephrosis. Treatment can be by open or laparoscopic approach.^[17] The first successful surgical correction was reported by Kimbrough in 1935.^[18] The procedure essentially involves division of the ureter with or without excision of the narrowed or aperistaltic segment, anteriorization, ureteroureterostomy, or dismembered pyeloplasty over a stent. Laparoscopic/robotic approach through transperitoneal or retroperitoneal route^[19] is less invasive and associated with less morbidity, less post-operative pain, early recovery, short hospital stay, and cosmetically acceptable scar [Table 1].^[19]

CONCLUSIONS

Retrocaval ureter is a congenital anomaly presenting clinically late, in the 3rd and 4th decades of life, and it is rarely noticed and presented in pediatric age groups (1st and 2nd decades of life). So treating clinician also keep suspicious of retrocaval ureter as differential diagnosis in child presented with flank pain with proximal hydroureteronephrosis. Imaging studies are sufficient for making an accurate diagnosis of a retrocaval ureter. Treatment is surgical, which allows for correction of the anomaly, with resolution of symptoms. Although retrocaval ureter can manage by minimally invasive surgery but it is emerging.

REFERENCES

- Bateson EM, Atkinson D. Circumcaval ureter: A new classification. *Clin Radiol* 1969;20:173-7.
- Carrion H, Gatewood J, Politano V, Morillo G, Lynne C. Retrocaval ureter: Report of 8 cases and the surgical management. *J Urol* 1979;121:514-7.
- Sumarac-Petronić Z, Petronić V. Retrocaval ureter-diagnosis and surgical management. *Helv Chir Acta* 1981;48:311-4.
- Heslin JE, Mamonas C. Retrocaval ureter: Report of four cases and review of literature. *J Urol* 1951;65:212-22.
- Huang KH, Chang SC, Huang CY, Pu YS, Huang JC. Retrocaval ureter: Report of 12 cases and literature review. *JTUA* 2005;164:163-7.
- Hochstetter F. Beiträge zur entwicklungsgeschichte des venensystems der amniten: II. Reptilien (Iacerta, tropidonotus). *Morphol Jahrb (Leipzig)* 1892-1893;19:428-501.
- Hyseni N, Llullaku S, Berisha M, Shefkiu A, Grajqevci S, Jashari H. Case presentation of preureteral vena cava and review of the literature. *Open J Urol* 2013;3:206-9.
- Iqbal M, Ansari MN. Retrocaval ureter with hydronephrosis. *J Pak Med Assoc* 2006;56:38-9.
- Kyei MY, Yeboah ED, Klufio GO, Mensah JE, Gepi-Atee S, Zakpaa L, *et al.* Retrocaval ureter: Two case reports. *Ghana Med J* 2011;45:177-80.
- Yarmohammadi A, Mohamadzadeh Rezaei M, Feizzadeh B, Ahmadnia H. Retrocaval ureter: A study of 13 cases. *Urol J* 2006;3:175-8.
- Rubinstein I, Cavalcanti AG, Canalini AF, Freitas MA, Accioly PM. Left retrocaval ureter associated with inferior vena caval duplication. *J Urol* 1999;162:1373-4.
- Watanabe M, Kawamura S, Nakada T, Ishii N, Hirano K, Numasawa K, *et al.* Left preureteral vena cava (retrocaval or circumcaval ureter) associated with partial situs inversus. *J Urol* 1991;145:1047-8.
- Méndez Gallart R, Vela Nieto D, Gómez Tellado M, Montero Sánchez M, País Piñeiro E, Candal Alonso J, *et al.* Retrocaval ureter in children: Surgical approach based on the obstructive pattern in the diuretic renogram with 99mTc DTPA. *Actas Urol Esp* 1998;22:789-92.
- Primus G, Kopp W. Retrocaval ureter a rare anomaly. *Int Urol Nephrol* 1986;18:277-82.
- Bassiouny IE, Abbas TO, Mosleh A. Retrocaval ureter: A report on two neonate. *Ann Pediatr Surg* 2013;9:40-4.
- Uthappa MC, Anthony D, Allen C. Case report: Retrocaval ureter: MR appearances. *Br J Radiol* 2002;75:177-9.
- Matsuda T, Yasumoto R, Tsujino T. Laparoscopic treatment of a retrocaval ureter. *Czech Med* 1986;9:15-22.
- Kimbrough JC. Surgical treatment of hydronephrosis. *J Urol* 1935;33:97-109.
- Mugiya S, Suzuki K, Ohhira T, Un-No T, Takayama T, Fujita K, *et al.* Retroperitoneoscopic treatment of a retrocaval ureter. *Int J Urol* 1999;6:419-22.
- Fernando MH, Jayarajah U, Arulanantham A, Goonewardena S, Wijewardena M. Retrocaval ureter associated with cryptorchidism: A case report and review of literature. *Clin Case Rep* 2018;6:1592-4.
- Agarwal S, Goel S, Sankhwar S, Garg G. Circumcaval ureter/retrocaval ureter. *BMJ Case Rep* 2018;2018:bcr-2018-225449.
- Tamhankar AS, Savalia AJ, Sawant AS, Pawar PW, Kasat GV, Patil SR, *et al.* Transperitoneal laparoscopic repair of retrocaval ureter: Our experience and review of literature. *Urol Ann* 2017;9:324-9.
- Rehan AM, Al-Ghamdi AS, Al-Saied G, Al-Qahtani SM. Retrocaval ureter as a cause of flank pain: Review of literature of surgical treatment. *Saudi Surg J* 2017;5:136-8.
- Ahmed M, Alhassan A, Sadiq MA, Lawal AT, Bello A, Maitama HY, *et al.* Variable presentation of retrocaval ureter: Report of four cases and review of literature. *Niger Postgrad Med J* 2017;24:126-9.
- Shah SM, Patel CK, Mehta SM, Gohil VB. Retrocaval circumcaval ureter: Rare congenital anomaly of ureter or inferior vena cava. *Natl J Med Res* 2016;6:105.
- Bhattacharjee S, Sanga S, Gupta P, George RA. Retrocaval ureter or preureteral vena cava: Lest we forget this rare cause of hydronephrosis. *Med J Armed Forces India* 2016;72:S77-S79.
- Bendre P, Nage A, D'souza FH. Retrocaval ureter a rare cause of hydronephrosis in children. *J Pediatr Neonatal Care* 2016;5:200.
- Murat T, Gökhan F, Alper K, Özgür Y, Erkin S, Aydın Ö, *et al.* A retrocaval ureter: A rare congenital anomaly. *J Kartal TR* 2016;27:138-41.
- Fidalgo N, Pinheiro H, Ferronha F, Morales J, Pinheiro LC. Minimally invasive approach of a retrocaval ureter. *Case Rep Urol* 2016;2016:5.
- Pankaj D, Prakash S, Singh T. Retrocaval ureter: A case report. *J Evol Med Dent Sci* 2015;4:2613-6.
- Kajal P, Rattan K, Sangwan V, Bhutani N. Retrocaval ureter presenting at 6 years of age in a girl child an extreme rarity. *Asian J Urol* 2015;20:1-3.
- Ricciardulli S, Ding Q, Zhang X. Retroperitoneal laparoscopic approach for retrocaval ureter: Our experience on 27 cases. *J Urol Res* 2015;2:1033.
- Kamble MA, Thawait AP, Kamble AT. Retrocaval ureter: A rare congenital anomaly presenting as renal colic with hematuria. *Int Surg J* 2014;1:21-4.
- Vs G, Nn H, Pd D, Nb M, Ss B. Retrocaval ureter: An innocent bystander. *J Clin Diagn Res* 2014;8:ND05-6.
- Nayak B, Dogra PN, Gupta NP. Robotic repair of retrocaval ureter: A case series. *Afr J Urol* 2012;18:135-7.

How to cite this article: Jangid MK, Ahmad R, Jangid P, Pandre SK, Kaur G. Retrocaval Ureter with Proximal Hydroureteronephrosis Presenting as Flank Pain in a Child: A Rare Case Report with Review of Literature. *Int J Sci Stud* 2019;7(3):106-110.

Source of Support: Nil, **Conflict of Interest:** None declared.