Print ISSN: 2321-6379
Online ISSN: 2321-595X

Case Report

A Case Report of Flexometallic Laryngeal Mask Airway Used in Tonsillectomy

T. Balaji[1], T. Rajaram Manoharan[2], A. L. Shanmuga Priya[3], J. Suresh[4]

[1]Senior Consultant, Department of Anesthesiology, Preethi Hospitals Private Limited, Uthangudi, Tamil Nadu, India, [2]HOD and Professor, Department of Anesthesiology, Preethi Hospitals Private Limited, Uthangudi, Tamil Nadu, India, [3]Senior Resident, Department of Anesthesiology, Preethi Hospitals Private Limited, Uthangudi, Tamil Nadu, India, [4]Junior Consultant, Department of Anesthesiology, Preethi Hospitals Private Limited, Uthangudi, Tamil Nadu, India

Abstract

Tonsils and adenoids are part of Waldeyer's ring of lymphoid tissue and are often sites of acute and chronic inflammation. Children are prone to recurrent adenotonsillitis, causing obstructive airway problems requiring the need for surgical removal. Airway problems are a major concern in adenotonsillectomy procedures. This is related both to the underlying clinical problem and the shared airway between the anesthesiologist and surgeon. Until recently, the airway is usually managed with either an endotracheal tube (ETT) or right angle endotracheal tube for this procedure. With the introduction of flexible laryngeal mask airway (FLMA), designed for use in head and neck, oral surgeries, these procedures can be done with a superior recovery profile and fewer bronchospasm incidences, laryngospasm, oropharyngeal trauma, than an ETT. The FLMA provides better protection of lower airway and esophagus from blood and secretions than the ETT. Herewith, we present a case of adenotonsillectomy done in a 10-year-old child using FLMA.

Key words: Adenotonsillectomy, Airway management, Flexible laryngeal mask airway, Laryngeal mask airway, Laryngospasm

INTRODUCTION

Airway management is one of the most important skills in anesthesiology, and inability to secure the airway can lead to catastrophic results. Before 1980, only the face mask and the endotracheal tube (ETT) were the available airway devices. Since then several supraglottic airway devices have been developed, of which the laryngeal mask airway (LMA) is the only time tested and widely used device, introduced by Dr Archie Brain. Supraglottic airway devices fill the gap between the face mask and the tracheal tube. The first supraglottic airway device, LMA–Classic, became available in 1988.[1] There are many LMA devices available now, some of which appear similar to the LMA family and others that work in a different concept. The LMA is designed to provide and maintain the seal around the laryngeal inlet. The most important feature of LMA is that they provide rapid control of the airway. They are faster and easier to insert than endotracheal intubation. LMA is commonly used in both adults and pediatrics patients. Over the years, they have earned an important place in difficult airway management.[2]

Many surgeries, particularly procedures performed on the oral and nasal cavities, require the anesthesiologist and surgeon to share access to the airway. Conventionally, special ETTs with a spiral coil built into them to increase the tube's flexibility and prevent kinking have been used to allow the surgeon to manipulate the ETTs during surgery to gain access to the operating field. To make an LMA specifically for head and neck procedures, a similar spiral coil was incorporated into the LMA's shaft, creating the flexible LMA (FLMA), introduced into clinical practice in 1994. The FLMA has since been used successfully in patients undergoing a variety of head and neck, oral surgeries.[3]

FLMA

The FLMA has the same parts as LMA classic [Figure 1]; it differs from LMA classic in having an airway tube flexible,

Access this article online

www.ijss-sn.com

Month of Submission : 12-2020
Month of Peer Review : 12-2020
Month of Acceptance : 01-2021
Month of Publishing : 02-2021

Corresponding Author: Balaji T, Department of Anesthesiology, Preethi Hospitals Private Limited, Uthangudi, Tamil Nadu, India.

wire-reinforced.[3] This tube is longer and narrower than the airway tube of LMA classic. It is available in the sizes shown in Table 1.

The cuff sizes are the same as that of LMA classic. A single-use version is also available. The sizes for the single-use version are the same as for the multiuse one.

Williams *et al.* (Br. J. Anaesth. 1993), 104 patients were allocated randomly to receive anesthesia for adenotonsillectomy through either a reinforced LMA or a tracheal tube. Airway maintenance and protection were assessed during and after surgery. The authors concluded that the reinforced laryngeal mask did not interfere with surgical access; it resisted compression and protected the lower airway from contamination with blood. In children, recovery was less eventful in the LMA group, with less airway obstruction ($P < 0.001$) and better airway acceptance ($P < 0.05$). The reinforced LMA provided a clear, secure airway until recovery of protective airway reflexes.[4]

Brimacombe *et al.* (Anaesth Analg 1999), the authors conducted a randomized, controlled, cross-over cadaver study to test the hypothesis that the efficacy of seal for ventilation and airway protection, anatomic position, and airway patency with the FLMA is altered by the application of a Boyle Davis gag. They also determined the airway sealing pressure at which the FLMA prevents aspiration when large volumes of fluid are placed above the cuff. Efficacy of seal for airway protection was determined by flooding the mouth with 55–135 mL of water, reducing intracuff pressure until aspiration was detected fiber optically and measuring airway sealing pressure at this intracuff pressure. The mean airway sealing pressure at which aspiration occurred when large volumes of fluid were placed above the cuff was 11 (7–15) cmH_2O. They conclude that the FLMA forms an effective seal for ventilation and protection of the airway that is unaffected by applying a mouth gag that provides surgical access to the oropharynx.[5]

A 10-year-old boy of weight 25 kg, belonging to American Society of Anesthesiologists I category with mouth opening of 4 cm was posted for tonsillectomy. The patient was pre-medicated with inj. midazolam 2 mg with inj. atropine 0.6 mg IM 20 min before induction. The patient was shifted to the operating room and monitors were connected; electrocardiography, non-invasive blood pressure, and pulse oximeter. Baseline values were re-corded. IV access was secured on the left forearm with 22G cannula. Intravenous fluid Ringer's lactate was started. Inj. fentanyl 50 mcg IV was given. The patient was induced with inj. propofol 60 mg, inj. atracurium 12.5 mg IV, mask ventilated with N_2O 66% with oxygen and sevoflurane 2% for 3 min.

A flexo metallic LMA of 2.5 sizes were used for the patient, based on weight. We used a malleable stylet to make the airway tube stiffer and to facilitate insertion. In this case, LMA was inserted using the standard technique with cuff fully deflated. Thirteen milliliter of air was used to inflate the cuff. Bilateral air entry was checked by auscultation. LMA secured was in the midline with adhesive plasters over the mandible, as shown in Figure 2. Sister Rose positioning required for tonsillectomy was done. Doughty's mouth gag with a groove for the air-way tube was applied after adequate lubrication. The distance between the angles of the mouth to the angle of mandible was used to predict the size of the blade. The airway tube, inflation system tubing was kept in the midline within the groove.

Table 1

Mask size	Weight	Cuff volume
2	10-20 kg	10 ml
2.5	20-30 kg	15 ml
3	30-50 kg	20 ml
4	50-70 kg	30 ml
5	70-100 kg	40 ml

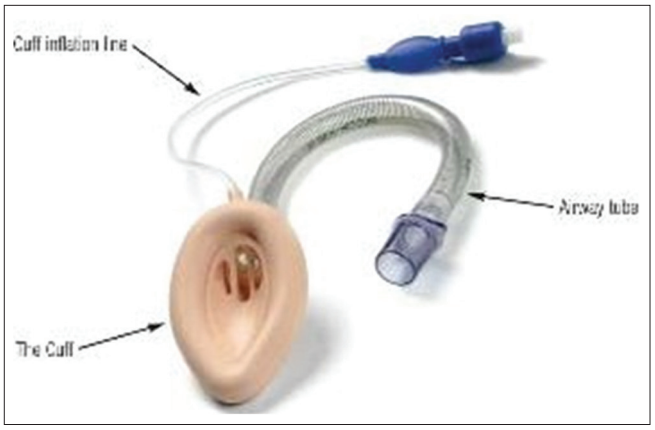

Figure 1: Laryngeal mask airway flexible device description

Figure 2: Laryngeal mask airway secured was in the midline with adhesive plaster

DEVICE FIXATION

Anesthesia maintained with N_2O/O_2 in the ratio of 66: 33% and sevoflurane 1%. Inj. atracurium was used intermittently to maintain muscle paralysis. During the intraoperative period, the patient was monitored continuously for hemodynamic disturbances, desaturation, and airway obstruction. The intraoperative period went uneventfully. At the end of the procedure, Doughty's mouth gag was removed with care after achieving adequate hemostasis. Thorough oral suctioning was done under vision. Both the tonsillar fossae were inspected for bleeding and retained cotton balls. The blood staining of LMA was seen only on the dorsal surface, and the laryngeal surface was free of blood. The patient was reversed with inj. neostigmine 1.25 mg and inj. glycopyrrolate 0.25 mg. The patient became conscious, obeyed verbal commands; muscle power was adequate, airway reflexes recovered fully. The LMA was removed. In the post-operative period, the patient was monitored with oxygen supplementation in the recovery room for 30 min. The post-operative period went uneventfully. The child was shifted to the post-operative ward.

DISCUSSION

FLMA is a safer alternative to the ETT in adenotonsillectomy procedure.[6] LMA has come into increasing use in anesthesia, particularly in outpatient surgeries. LMA can be inserted easily without requiring neuromuscular blockade and also allows spontaneous ventilation throughout the procedure. Introduction of LMA induces a less hemodynamic stress response. It is better tolerated in shallower depths of anesthesia.[7,8]

FLMA is a safer alternative to the ETT in adenotonsillectomy procedure.[6] LMA has come into increasing use in anesthesia, particularly in outpatient surgeries. LMA can be inserted easily without requiring neuromuscular blockade and also allows spontaneous ventilation throughout the procedure. Introduction of LMA induces a less hemodynamic stress response. It is better tolerated in shallower depths of anesthesia.[7] However, the presence of LMA in the mouth can obstruct the view of the surgical field. With the introduction of flexo metallic LMA's, this problem is solved and many studies have proved this.[4,5]

1. Sister rose to position leads to the collection of secretions in the oropharynx, easily suctioned out
2. As tonsillectomy is an elective procedure, these children have fasted overnight. Hence, the incidence of aspiration of gastric contents is less
3. LMA is better than the ETT in preventing aspiration of blood or secretions from above the vocal cords level, which is common in tonsillectomy
4. The position of tonsils allows for easy accessibility and complete visualization of the surgical area.

Hence, bleeding can be easily diagnosed and treated. The tonsillectomy procedure needs adequate surgical exposure, an adequate plane of anesthesia to prevent untoward movements, prevention of aspiration of blood from the oral cavity, an airway device that permits the circuit to be kept away from the surgical field, and also resists compression or kinking 9 FLMA has all the features necessary for the tonsillectomy procedure. Such as, the FLMA has a wire-reinforced, flexible airway tube that allows it to be positioned away from the surgical field.

Wire reinforced tube resists kinking and compression. Flexible LMA available in pediatric and adult sizes. Better protection of the airway from blood and secretions from above the trachea compared to an ETT [Figure 3].

There is a reduction in the incidence of post-operative nausea vomiting due to the prevention of blood from entering the esophagus. LMA better tolerated by the anesthetized spontaneously breathing patients than ETT. Good maintenance of LMA cuff stability even during head movement. All LMA benefits such as lesser drug requirement reduced coughing and bucking on emergence, minimal hemodynamic response, reduced intracranial, and intraocular pressures are present in the FLMA.

The disadvantages of using FLMA are, the wire reinforcement makes the FLMA more resistant to kinking and compression than the LMA Classic but does not prevent obstruction from biting. Airway obstruction and loss of seal have been reported when a Boyle Davis gag was used. This can usually be corrected by repositioning the gag. The FLMA is unsuitable for magnetic resonance imaging scanning if image quality in the region of the LMA is important.

The metallic rings will cause image distortion. The recommendations for optimal use of FLMA are,[9]

The Device Vice

a. FLMA pre-use tests should exclude any airway tubes with bite marks
b. The correct size of FLMA should be chosen

Figure 3: Prevention of aspiration of blood by laryngeal mask airway compared to endotracheal tube

c. Standard insertion technique with the mid-line placement of the airway tube and the pilot tube is advised.

Maintenance

a. Correct length of the blade
b. Lubrication of blade by a surgeon
c. Careful insertion of the blade by a surgeon [Figure 4]
d. Optimal head and neck positioning before opening of tonsillar gag [Figure 5].

Ventilation

a. Confirmation of ease of ventilation with open tonsillar gag

Figure 4: Insertion of the mouth gag

Figure 5: The optimal position of flexible laryngeal mask airway and mouth gag

b. Spontaneous or positive pressure ventilation
c. No part of the airway tube or cuff visible to the surgeon
d. Airway tube shielded if split blade during laser surgery.

Removal of Device

a. Careful tonsillar gag removal at the end of surgery by a surgeon
b. Laryngoscopy to check no further bleeding
c. Placement of bite block
d. Discontinuation of volatile agents to allow recovery.

If Problems Arise with Partial Obstruction Following the Opening of the Tonsillar Gag, Several Checks Can Be Made

a. Head and neck position
b. FLMA size. Tonsillar gag size
c. The slight tension on the airway tube to maintain a midline position as the blade is introduced by the surgeon, reducing the likelihood of any part of the tube becoming kinked or trapped between the blade and the teeth in particular
d. Try different blade size
e. Further adjustments to head and neck position
f. Change the FLMA size.

CONCLUSION

The use of the FLMA for adenotonsillectomy procedures is associated with a superior recovery profile; less airway soiling compared to uncuffed ETTs.

REFERENCES

1. Brain AI. The laryngeal mask-a new concept in airway management. Br J Anaesth 1983;55:801-5.
2. Benumof JL. Laryngeal mask airway and the ASA difficult airway algorithm. J Am Soc Anesthesiol 1996;84:686-99.
3. Bailey P, Brimacombe JR, Keller C. The flexible LMA: Literature considerations and practical guide. Int Anesthesiol Clin 1998;36:111-22.
4. Williams PJ, Bailey PM. Comparison of the reinforced laryngeal mask airway and tracheal intubation for adenotonsillectomy. Br J Anaesth 1993;70:30-3.
5. Brimacombe JR, Keller C, Gunkel AR, Puhringer F. The influence of the tonsillar gag on efficacy of seal, anatomic position, airway patency, and airway protection with the flexible laryngeal mask airway: A randomized, cross-over study of fresh adult cadavers. Anesth Analg 1999;89:181-6.
6. Webster AC, Morley-Forster PK, Dain S, Ganapathy S, Ruby R, Au A, *et al*. Anaesthesia for adenotonsillectomy: A comparison between tracheal intubation and the armoured laryngeal mask airway. Can J Anaesth 1993;40:1171-7.
7. Miller RD. Miller's Anesthesia. 6th ed. Philadelphia, PA: Elsevier, Churchill Livingstone; 2005. p. 1625-8.
8. Brain AI, Denman WT, Goudsouzian NG. Laryngeal Mask Airway Instruction Manual. San Diego, California: LMA North America Inc.; 1999.
9. Keller C, Brimacombe J, Keller K. Pressures exerted against the cervical vertebrae by the standard and intubating laryngeal mask airways: A randomized, controlled, cross-over study in fresh cadavers. Anesth Analg 1999;89:1296-300.

How to cite this article: Balaji T, Manoharan TR, Priya ALS, Suresh J. A Case Report of Flexometallic Laryngeal Mask Airway Used in Tonsillectomy. Int J Sci Stud 2021;8(11):10-13.

Source of Support: Nil, **Conflicts of Interest:** None declared.