

Clinical Review of Juvenile Nasopharyngeal Angiofibroma in Urban Tertiary Care Centre: A Retrospective Analysis

T Indra¹, R Muthu Kumar², G Sundar Krishnan³

¹Associate Professor, Department of ENT, Kilpauk Medical College, Chennai, Tamil Nadu, India, ²Director and Professor, Department of ENT, Upgraded Institute of Otorhinolaryngology Madras Medical College and Government General Hospital, Chennai, Tamil Nadu, India, ³Professor, Department of ENT, Upgraded Institute of Otorhinolaryngology Madras Medical College and Government General Hospital, Chennai, Tamil Nadu, India

Abstract

Introduction: The aim of this study was to review management, surgical approaches used, blood loss, complications, and recurrence rate of juvenile nasopharyngeal angiofibroma (JNA) in our institution during 2002–2005 period.

Materials and Methods: All patients referred for a JNA were included in the study. Medical files and imaging data were retrospectively analyzed. Surgical management was then evaluated consecutive patients operated on from April 2002 to June 2005. Case series with chart review. The study was conducted from data on patients operated from April 2002 to 2005 in Madras Medical College and Government General Hospital.

Results: A total of 42 patients were operated on, with a mean age of 16.8 years (range, 9–31 years). In the endoscopic approach blood loss was found to be <300 ml. With Weber Ferguson trans palatine extensive tumor with proptosis blood loss was >1000 ml embolization has reduced the intraoperative blood loss. Since they explored pterygopalatine fossa by removing posterior part of medial wall and posterior wall completely, recurrence was rare.

Conclusion: Progress in skull base anatomy, instrumentation, cameras, and surgical strategy allows for expansion of the indications for endoscopic removal of JNA. This approach may have a better outcome in terms of blood loss, hospital stay, and local sequelae. Still, an external approach should be considered only for selected cases due to a massive intracranial extension or optic nerve or internal carotid artery entrapment by the tumor.

Key words: Angiofibroma, Embolization maxillary swing, Endoscopic approach

INTRODUCTION

Juvenile nasopharyngeal angiofibroma (JNA) is a benign, locally aggressive tumor found commonly in young boys.^[1,2] The internal maxillary artery is the most common vascular source of JNAs followed by the ascending pharyngeal artery. Intracranial involvement has been reported to occur in 10–20% of all cases.^[3,4] Staging is based on anatomic tumor extension, and the Radkowski system of staging

is used most frequently. Over the years, surgical excision has remained standard treatment.^[5] Transnasal endoscopic resection is generally used in early stages, while advanced cases require craniofacial approaches.^[6] The available of pre-operative embolization has helped surgeons in reducing bleeding during surgery and improve outcomes of surgery.^[7] However, surgery alone in advanced stages has reported high recurrence rates especially if resection is not complete. The long-term morbidity associated with radiotherapy has remained a concern.^[8]

Aim

The aim of the study is as follows:

1. To study the age group presentations clinical features presentation in the study group.
2. To study the reference of computed tomography (CT)

Access this article online



www.ijss-sn.com

Month of Submission : 12-2018
Month of Peer Review : 01-2019
Month of Acceptance : 01-2019
Month of Publishing : 02-2019

Corresponding Author: Dr. T Indra, Department of ENT, Kilpauk Medical College, Chennai 10, Tamil Nadu, India. Phone: +91-9444359191. E-mail: indravinyagam@gmail.com

in JNA with regard to diagnosis extensions and bony involvement in the planning of surgical procedures.

- To study the complications.

MATERIALS AND METHODS

The study was conducted at the Upgraded Institute of Otorhinolaryngology Madras Medical College and Government General Hospital. 2002–2005 series of 42 patients of JNA present in outpatient department with nasal bleed. Detailed history, clinical findings of each patient noted. All patients DNE and CT with contrast - axial/coronal cuts findings noted. Carotid angiography and embolization of vessels were done in selected cases. The following data were gathered: Gender, age at the time of diagnosis, signs, and symptoms, diagnostic nasal endoscopic examination, surgical approach, need for transfusion, pre-operative embolization, complications, follow-up exams, recurrences, and reoperation. The Fisch (Fisch, 1983) criteria were applied to classify the tumors. Case pro forma prepared for the study.

RESULTS

From May 2002 to January 2005, 42 male patients (100%) underwent treatment for angiofibromas. The ages ranged from 11 years to 31 years, with a mean 16.8 years. 10 patients were between the age group 11 to 15, 21 patients between the age group 16 to 20 years, 11 patients between the age group 21 to 31. The most frequent signs and or symptoms were epistaxis 70%, and nasal block (92%), followed by nasal discharge 21%, bulging of the face (20%), and palate bulge 60%. All patients underwent nasal endoscopy and CT. No biopsies were carried out in these patients. Based on the tomographic findings and the Fisch classification, 15 patients (36%) were Stage I, 14 patients (33%) were Stage II, 10 patients (24%) were Stage III, and 3 patients (7%) were Stage IV [Figure 1]. All patients underwent surgery as follows:

Trans palatine approach in 9 patients, nasal endoscopic approach in 7 patients, le fort osteotomy approach in 1 patient, modified le fort in 2 patients and facial translocation in 1 patient.

A total of 32 patients required intraoperative blood transfusions, of which 12 patients had 4 units of transfusions, 10 patients did not require intraoperative blood transfusions, nasal packing was done in all patients at the end of surgery and removed 48–72 h later.

The majority of the patients had O + blood group, 25 patients [Table 1].

Only 2 patients had post-operative complications, such as an oroantral leak following a transpalatine approach, and lower turbinate, and septal synechiae after nasal endoscopic method; both complications were corrected with no additional morbidity. Nasal crusting was seen in 16. The recurrence rate was associated with the absence of pre-operative embolization and advanced tumor stage at the time of diagnosis.

DISCUSSION

Out of transnasal endoscopic surgery offered six cases had undergone trans palatal approach in the past. Moreover, one case transnasal endoscopic Stages were I, II, or III; hence, a transnasal endoscopic approach offers a good salvage technique for complete excision of these tumors. In the endoscopic method- recurrence was due to failure to remove the posterior wall of the maxilla. Facial translocation approach was used in one of the cases and the same patient underwent transpalatal approach twice in the past. After the facial translocation approach, there was no recurrence of the tumor. Since the approach offered access to middle cranial fossa complete tumor excision was done. A modification of facial translocation approach instead of osteotomy of the maxilla done, a maxillary swing procedure was used; hence, the morbidity associated was less.

Mean age of presentation

Martin/Ehrlich/Abels 1948	29 cases	16 years
Figi/david1950	51 cases	15 years
Shaheen 1930	58 cases	20 years
In our present study	2002–2005	18 years

Minimum age of presentation was 12 years. Maximum age was 31 years.

This shows that number of cases decrease in the post-adolescence period.

Nasal obstruction was the most common symptom of presentation 92%. Nasal bleeding in 70 % of the study group, protrusion of eyeball was present in 20% of the study group [Table 2].

Preoperative CT evaluation was done in all the cases which enabled to clearly delineate [Table 3]. The bony landmarks surrounding the tumor, intracranial extension, and extension into adjoining structures.

Introduction of conformal radiotherapy has evolved as a promising treatment approach for locally advanced cohorts of JNA.^[9] Carotid angiography was done in 3 patients internal maxillary artery was found to be the most common feeding vessel for the angiofibroma. Embolization of

Table 1: CT extension of tumor mass

CT extension of tumor mass	Number of patients
Confined to nasopharynx	15
Extending onto nasal cavity/sphenoid sinus	14
Extending into one or more of the following antrum, ethmoid sinus, pterygomaxillary, infratemporal orbit, cheek	10
Extending into the cranial cavity	3

CT: Computed tomography

Table 2: Surgical approaches used

Surgical approaches used	Number of patients
Transnasal	5
Trans palatine	19
Lateral rhinotomy	2
Modified LeFort	2
Fascial translocation	1
Trans nasal endoscopic	12

Table 3: Blood group

Blood group	Number of patients
A+	11
B+	4
AB+	1
O+	25
O-	1

feeding vessel was done in three cases. Gel foam was used as an embolizing agent. In addition, external carotid artery ligation was done in 8 cases, and external carotid artery plication was done in 4 cases. Intraoperative blood loss was <500 ml [Table 4]. In the endoscopic approach blood loss was found to be <200 ml. With Weber Ferguson transpalatine extensive tumor with proptosis blood loss was >1000 ml embolization has reduced the intraoperative blood loss since we explored pterygopalatine fossa completely in transnasal endoscopic approach by removal of the posterior part of the medial wall of the maxillary antrum and posterior wall of the maxillary antrum [Table 5]. Radiotherapy needs to be used only when surgery is not possible or in recurrent and residual lesions.^[10] The chances of leaving behind the tumor in the pterygopalatine fossa are very minimal, and hence, the recurrence is very rare.

CONCLUSION

Pre-operative selective arterial embolization was the best treatment for angiofibromas among the cases we reviewed; the cure rate was about 94% follow-up using CT makes it possible to establish the presence and extension of tumor recurrences or the absence of tumors. Surgery is the gold standard for treatment of JNA. Data reveal that during the past 15 years, there has been a marked shift toward

Table 4: Blood loss

Blood loss	Units	Number of patients
ml	Not given	10
350	1	6
700	2	12
1050	3	1
1400	4	11
1750	5	1

Table 5: Complications

Palatal gap	Synechae	Nasal crusting	Unightlyscar	Deafness
2	8	16	3	6

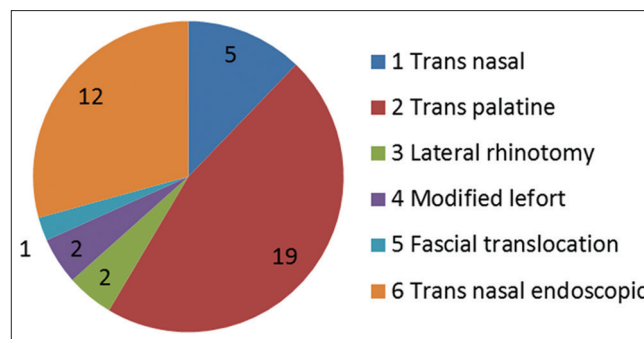


Figure 1: Number of patients

endonasal procedures while the tumor stages of the patients treated remained the same.^[11,12] Modern imaging techniques allow accurate diagnosis and staging of JNA. Recurrence of juvenile angiofibroma after surgical removal is commonly ranging from 20% to 30%.^[13] Some studies have found encouraging results in reducing recurrence by meticulously drilling out the pterygoid base, the pterygoid canal, and the basisphenoid.^[14] When a tumor extends intracranially and remains medial or inferomedial to the cavernous sinus, it is more readily removed through the anterior approach.^[15] Our experience and a review of the literature show that the surgical approach should be selected according to tumor stage. Progress in skull base anatomy, instrumentation, cameras, and surgical strategy allows for expansion of the indications for endoscopic removal of JNA. This approach may have a better outcome in terms of blood loss, hospital stay, and local sequelae. Still, an external approach should be considered only for selected cases due to a massive intracranial extension or optic nerve or internal carotid artery entrapment by the tumor.

ACKNOWLEDGMENTS

We wish to acknowledge the Dean, Director of Upgraded Institute of Otorhinolaryngology for their Cooperation, without which this study would not have been possible.

Such contribution is extremely important, as it allows scientific research to advance, thereby improving the quality of life of patients.

REFERENCES

1. Gullane PJ, Davidson J, O'Dwyer T, Forte V. Juvenile angiofibroma: A review of the literature and a case series report. *Laryngoscope* 1992;102:928-33.
2. Wiatrak BJ, Koopmann CF, Turrisi AT. Radiation therapy as an alternative to surgery in the management of intracranial juvenile nasopharyngeal angiofibroma. *Int J Pediatr Otorhinolaryngol* 1993;28:51-61.
3. Harwood AR, Cummings BJ, Fitzpatrick PJ. Radiotherapy for unusual tumors of the head and neck. *J Otolaryngol* 1984;13:391-4.
4. Jafek BW, Krekorian EA, Kirsch WM, Wood RP. Juvenile nasopharyngeal angiofibroma: Management of intracranial extension. *Head Neck Surg* 1979;2:119-28.
5. Leong SC. A systematic review of surgical outcomes for advanced juvenile nasopharyngeal angiofibroma with intracranial involvement. *Laryngoscope* 2013;123:1125-31.
6. Marshall AH, Bradley PJ. Management dilemmas in the treatment and follow-up of advanced juvenile nasopharyngeal angiofibroma. *ORL J Otorhinolaryngol Relat Spec* 2006;68:273-8.
7. Moulin G, Chagnaud C, Gras R, Gueguen E, Dessi P, Gaubert JY, *et al.* Juvenile nasopharyngeal angiofibroma: Comparison of blood loss during removal in embolized group versus nonembolized group. *Cardiovasc Intervent Radiol* 1995;18:158-61.
8. Lee JT, Chen P, Safa A, Juillard G, Calcaterra TC. The role of radiation in the treatment of advanced juvenile angiofibroma. *Laryngoscope* 2002;112:1213-20.
9. Beriwal S, Eidelman A, Micaily B. Three-dimensional conformal radiotherapy for treatment of extensive juvenile angiofibroma: Report on two cases. *ORL J Otorhinolaryngol Relat Spec* 2003;65:238-41.
10. Reddy KA, Mendenhall WM, Amdur RJ, Stringer SP, Cassisi NJ. Long-term results of radiation therapy for juvenile nasopharyngeal angiofibroma. *Am J Otolaryngol* 2001;22:172-5.
11. Carrau RL, Snyderman CH, Kassam AB, Jungreis CA. Endoscopic and endoscopic-assisted surgery for juvenile angiofibroma. *Laryngoscope* 2001;111:483-7.
12. Nicolai P, Berlucchi M, Tomenzoli D, Cappiello J, Trimarchi M, Maroldi R, *et al.* Endoscopic surgery for juvenile angiofibroma: When and how. *Laryngoscope* 2003;113:775-82.
13. Radkowski D, McGill T, Healy GB, Ohlms L, Jones DT. Angiofibroma. Changes in staging and treatment. *Arch Otolaryngol Head Neck Surg* 1996;122:122-9.
14. Howard DJ, Lloyd G, Lund V. Recurrence and its avoidance in juvenile angiofibroma. *Laryngoscope* 2001;111:1509-11.
15. Bales C, Kotapka M, Loevner LA, Al-Rawi M, Weinstein G, Hurst R, *et al.* Craniofacial resection of advanced juvenile nasopharyngeal angiofibroma. *Arch Otolaryngol Head Neck Surg* 2002;128:1071-8.

How to cite this article: Indra T, Kumar RM, Krishnan GS. Clinical Review of Juvenile Nasopharyngeal Angiofibroma in Urban Tertiary Care Centre: A Retrospective Analysis. *India. Int J Sci Stud* 2019;6(11):155-158.

Source of Support: Nil, **Conflict of Interest:** None declared.