Print ISSN: 2321-6379
Online ISSN: 2321-595X

Original Article

Analysis of the Treatment of Infected Non-union of Long Bones using Monolateral External Fixator

M Vijayanand Thambiah

Senior Civil Surgeon, Government Headquarters Hospital and DNB PG Teaching Institute, Cuddalore, Tamil Nadu, India

Abstract

Introduction: Infected non-union has been defined as a state of failure of union for 6–8 months with persistent infection at the fracture site. Infected non-union can develop after an open fracture after a previous open reduction and internal fixation or sequelae to chronic hematogenous osteomyelitis.

Aim: The aim of the study was to study the outcome of treatment of infected Nonunion of long bones using a Monolateral external fixator (The dynamic external fixation system and Rail fixation system) and reveal its real usefulness.

Materials and Methods: This is a prospective study conducted at Govt. Royapettah hospital and K.M.C., which consists of 21 cases of infected non-union with monolateral external fixator. The diagnosis was established by physical examination and investigations such as erythrocyte sedimentation, total and differential white blood cell count pus culture sensitivity and standard AP, and LATERAL X-rays. The results were divided into bony results and functional results, according to the classification of the Association for the study and application of the method of Ilizarov.

Results: Of the 21 patients, 11 (52%) patients developed infected non-union following open fracture and 10 patients (48%) developed infected non-union following previous implant surgeries for closed fractures. Sinus tract got cleared in all cases except 3 where the sinus tracts were multiple and there was no progression toward union in those cases. There was considerable delay in the consolidation phase in all cases. Out of 21 cases, 11 cases had pin tract infection (52.3%). For wound dehiscence in the post-operative period, a split skin graft cover was given in two cases.

Conclusion: The monolateral external fixation system is an effective and convenient method for treating infected non-union of long bones. This study could achieve a success rate of 86%, giving good encouraging results to most of our patients.

Key words: Distraction osteosynthesis, Infected non-union, Long bones, Monolateral external fixator

INTRODUCTION

Ununited fractures of long bones are a complex surgical problem and a chronic and debilitating condition. Infected non-union of long bones is a source of functional disability and can lead to economic hardship and loss of self-esteem. Infected non-union has been defined as a state of failure of union for 6 to 8 months with persistent infection at the fracture site.[1,2]

Access this article online

IJSS

www.ijss-sn.com

Month of Submission : 06-2021
Month of Peer Review : 07-2021
Month of Acceptance : 07-2021
Month of Publishing : 08-2021

Infected non-union can develop after an open fracture, a previous open reduction and internal fixation (ORIF), or sequelae to chronic hematogenous osteomyelitis. The incidence increases, especially in increasing high-velocity trauma, which is more frequently treated with internal fixation.

It is difficult to treat infected non-union[2-4] because of the following reasons.

1. Previous surgeries would have resulted in cicatrization of the soft tissue with an avascular environment around the fracture site
2. The sinus tract formation was leading on to the fracture site indicating dead bone or sequestrum inside
3. Necrosis of bone near the non-union site, to a considerable distance, due to thrombosis of blood vessels of Haversian canals

Corresponding Author: Dr. M Vijayanand Thambiah, Government Headquarters Hospital and DNB PG teaching Institute, Cuddalore, Tamil Nadu, India.

4. Prolonged immobilization, multiple surgeries with muscle fibrosis leading to a stiff joint/fracture disease
5. The microorganism may develop resistance to antibiotic therapy and poses a problem in controlling the disease.

Soft tissue loss with multiple sinuses[5,6] osteomyelitis, osteoporosis, complex deformities with limb length inequality, stiffness of the adjacent joints, and multi-drug resistant infection complicate treatment and recovery. These factors make an unfavorable milieu for fracture unions. Even after prolonged treatment and repeated surgeries to correct this problem, the outcome is unsure and amputation may be the only alternative left.

Hence, the treatment of non-union of long bones associated with infection is a formidable challenge to the orthopedic surgeon. Bone union is not usually obtained until the infection has been eradicated. The method is known as the distraction osteogenesis[6] simultaneously addresses deformity, shortening, loss of bone function, osteoporosis, and soft-tissue atrophy.

There are various modalities of treatment for infected non-union. In the past, several authors solved this problem by many methods where all the factors of non-union such as deformity, shortening, infection, and abnormal mobility were managed. The cornerstones for successful bone healing are biomechanical stability and biological vitality of the bone, as they provide an environment in which new bone can be formed. According to AO manual,[4] an external fixator is considered the standard fixation method in infected non-union. On the other hand, internal fixation is deferred in infected non-union for fear of persistence/recurrence of infection.

The dynamic external fixator system is a unilateral external fixator system. The frequent association of infection, bone defect, limb shortening, deformity, and soft tissue problems with atrophic non-union makes an external fixator attractive for skeletal stabilization.

Aim

The aim of the study was to study the outcome of treatment of infected Nonunion of long bones using a Monolateral external fixator (The dynamic external fixation system and Rail fixation system) and reveal its real usefulness.

MATERIALS AND METHODS

This is a prospective study conducted at Govt. Royapettah hospital and K.M.C. consist of 21 cases in the age range from 16 years to 65 years (with a mean age of 37.5 years.) treated at our institution from July 2003 to Feb 2006. Patients who were lost to follow-up were not included in this study. Our institution approved our treatment protocols and all patients gave written informed consent.

The diagnosis was established by physical examination and investigations such as erythrocyte sedimentation, total and differential white blood cell count pus culture sensitivity and standard AP, and LATERAL X-rays. History is taken from the patient, including the date of injury, detail of the original accident, and subsequent treatment. Special attention was focused on limb length measurements, range of motion of the joints, neuromuscular status, and distal vascularity.

Postoperatively, the limb is kept elevated to reduce the postoperative edema. Then, the ankle is splinted in a neutral position. Drain is removed after 48 h. Parenteral antibiotics were continued for 2 weeks postoperatively or till the subsidence of infection and then oral antibiotics were given for an additional 2 weeks. Joint motion exercises and non-weight bearing followed for 4 weeks and then partial weight-bearing was advised. Distraction was carried at the rate of 0.25 mm 4 times a day, which was started from the 7th postoperative day. A radiograph was taken every week during the initial period of distraction and at monthly intervals after that. On discharge, all patients were taught about pin site care, hygiene and the rhythm of distraction, where a lengthening procedure was carried out.

The patients were followed in the outpatient department, where clinical and radiological progress was assessed. The rate of distraction was altered based on the radiographic the appearance of the regenerate. In all cases, compression at the non-union site was maintained till union. Poor consolidation of the regenerate (two cases) was treated by encouraging weight-bearing and alternate compression –distraction (Accordion technique).[2] The distraction was stopped when sufficient gain of length has been achieved. The fixator was left in position for a further period to allow consolidation of callus. In two cases, in spite of successful docking and control of infection, there were no signs of radiological union; an iliac graft was applied at the docking site. Our criteria for radiological union[7] are the presence of bony consolidation in three out of four cortices in AP and Lateral X-rays. When this is achieved, the patient is examined clinically and the fixator is removed. After removing the fixator, the patient is advised to use a functional cast brace for the upper limb and crutches for the lower limb for 6 weeks. Then, the patient is gradually mobilized to full weight-bearing.

The results were divided into bony results and functional results, according to the classification of the Association for the study and application of the method of Ilizarov.

RESULTS

There were 18 males and three females in our study with a male to female ratio of 6:1.

12 patients had infected non-union of the femur, seven patients had infected non-union of the tibia and two patients had infected non-union of the humerus [Figure 1]. Of the 12 cases of the femur, five had infected non-union after ORIF with nail/pate for closed fractures, five had infected non-union, which occurred after open fractures and subsequent native treatment, and two had infected non-union following treatment of open fracture with AO external fixator system [Table 1].

Among the seven cases of the tibia, three patients had infected non-union after ORIF for closed fracture, and four infected non-union occurred after open fracture. Five patients had infected draining non-union and two had infected quiescent non-draining non-union [Figure 2]. Two patients with septic non-union of humerus resulted after ORIF with plating for closed fractures. Our follow-up period was from a maximum of 28 months to a minimum of 6 months (mean 16.8 months). In Toto, of the 21 cases, infected non-union resulted from previous surgeries in 13 cases. In six cases, infected non-union resulted from improper treatment of the open fracture by native bone setters and in two other cases, infected non-union resulted after cast immobilization for Grade 1 open fracture (Gustillo Anderson classification).

In the last 32 months, we had the opportunity to treat 21 cases of infected non-union with a monolateral external fixator. Of the 21 patients, 11 (52%) patients developed infected non-union following open fracture and ten patients (48%) developed infected non-union following previous implant surgeries for closed fractures [Figure 3]. Our follow-up of cases varied from 6 to 28 months (mean 16.8 months).

Union time ranged from 4 to 9 months (mean 5.9 months). Sinus tract got cleared in all cases except three where the sinus tracts were multiple and there was no progression toward union in those cases. There was no difficulty in this series as far as transportation of bone. There was considerable delay in the consolidation phase in all cases. Out of 21 cases, 11 cases had pin tract infection (52.3%). For wound dehiscence in the post-operative period, a split skin graft cover was given in two cases.

There was no neurological or vascular injury as a result of instrumentation. The bone healing index (BHI) 11 (days of fixator use/centimeters of length gain) was 47.1 days/cm.

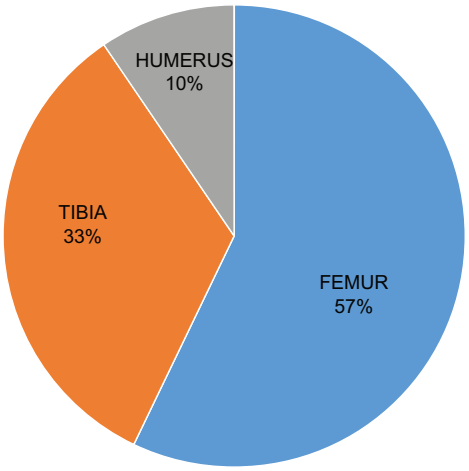

Figure 1: Non-union of long bones

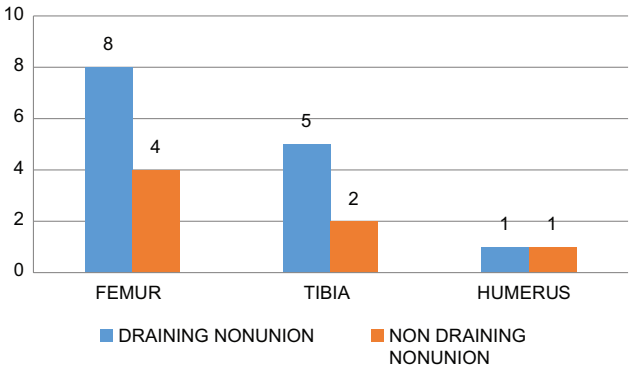

Figure 2: Draining and Non draining nonunion bones

Superficial pin tract infection was found in 11 of the 21 cases (52.3%). All superficial pin tract infections responded to intravenous or oral antibiotics, except in one case where the infection persisted.

Mild edema was frequently present and resolved after removal of fixator except in five5 cases, which persisted even after removal of fixator; such patients were advised full weight-bearing with Elasto crepe bandage in the daytime and limb elevation in the daytime the night time for a variable period of time.

During the distraction, metaphyseal pins got loosened in two cases, which were readjusted in the operation theatre. Equinus correction was done by a secondary surgical procedure like Achilles lengthening in two cases and triple arthrodesis in one case. Finally, in two cases, iliac bone grafting was done at the non-union site at the end of 4 months when there was insufficient evidence of bony union to aid in the union.

Malunion beyond the limits of acceptability occurred in four cases. In addition, persisting non-union of

the previous non united site occurred in three limbs [Figures 1 and 2].

DISCUSSION

The overall goal of reconstructing an infected un united long bone fracture involves more than control of infection. It includes creating a healed aligned and drainage-free limb functionally better than that which could have been achieved by amputation and prosthetic fitting. Several factors must be considered in the reconstruction of bone, including the patient's age, metabolic status, foot and ankle mobility, the integrity of neurovascular structures, and, importantly, the patient's motivation. The extent of bony debridement is defined by the presence of punctuate bleeding points observed. The non-union site must be resected as it is better to substitute a poorly biological atrophic bone area with two bone surfaces of good quality modeled in such a way as to allow for easy stabilization under compression.

The decision to proceed with the reconstruction is based on the surgeon's ability to restore a functional limb and the duration anticipated for treatment and the anticipated residual disability. Through wound debridement and removable of the doubtful bone and soft tissues to keep the area totally devoid of non-viable tissue is essential for achieving bony union. In our study, three cases had persistent non-union; all these cases had a persistent infection in spite of taking antibiotics. For two patients, a change of plan of management toward Ilizarov was considered and in another patient, repeat debridement, excision of all the necrotic bone and supracondylar corticotomy was planned for bone lengthening.

Table 1: Previous treatment received by the patients

Infected non union	Total	Plaster (POP)	External fixation	Plating	Nailing	Native treatment
FEMUR	12	-	2	2	3	5
TIBIA	7	2	1	-	3	1
HUMERUS	2	-	-	2	-	-

The patient must be cooperative and understand the length of time the frame has to be worn and complications requiring pin revision are a probability. In elective situations, the patients can meet other patients who have gone through this process, have pre-operative teaching, and elect this treatment protocol. Patients may accept these techniques better when they have chosen it as an elective reconstruction rather than when it is inflicted on them.

Patients require adequate nutrition, exercise, and encouragement to stop smoking. Although distraction osteogenesis is associated with marked improvement of the blood supply, good vascularization is necessary to obtain bone healing, especially in patients with infected non-union. Before the surgery, it is necessary to plan the procedure adequately. As in other series, functional results were inferior to bony results. An excellent bone result does not guarantee an excellent functional result.[5] As to the 11 cases where there was the rigidity of ankle/knee, it must be noted that eight were pre-existent and three were

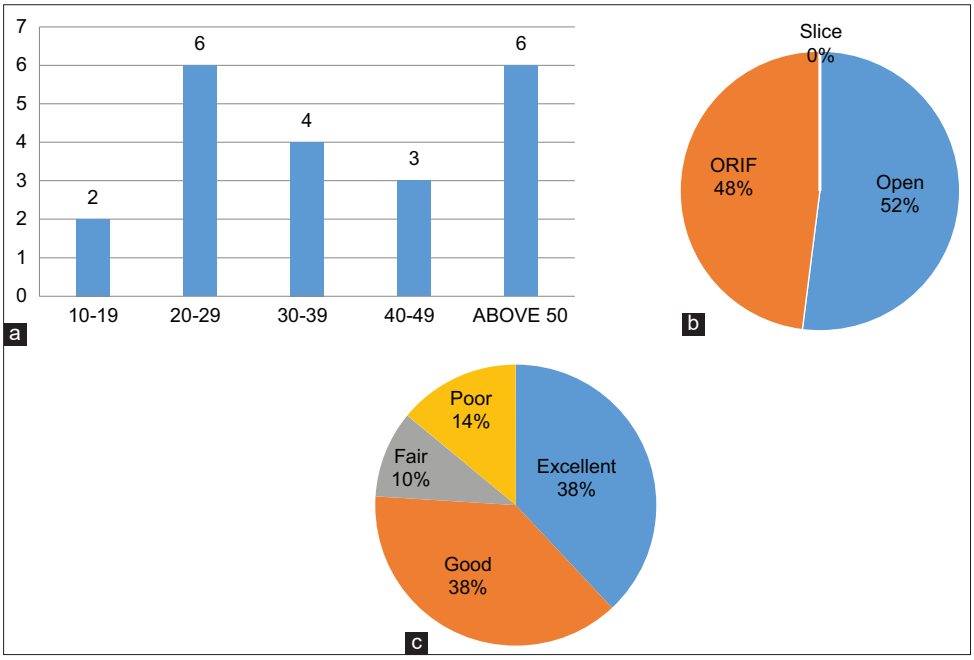

Figure 1: (a-c) Bony results

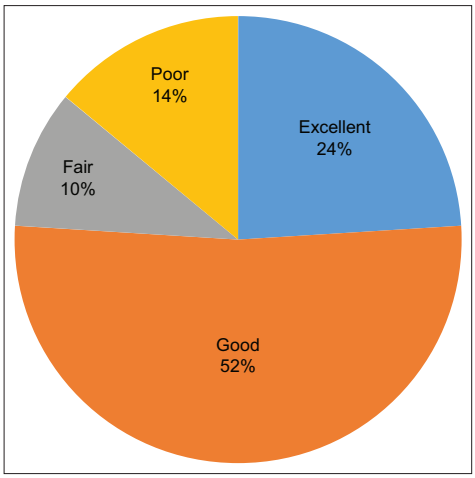

Figure 5: Functional results

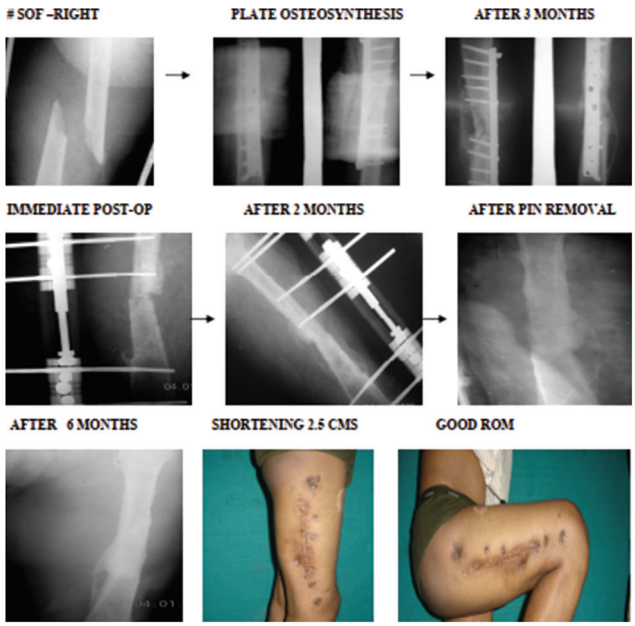

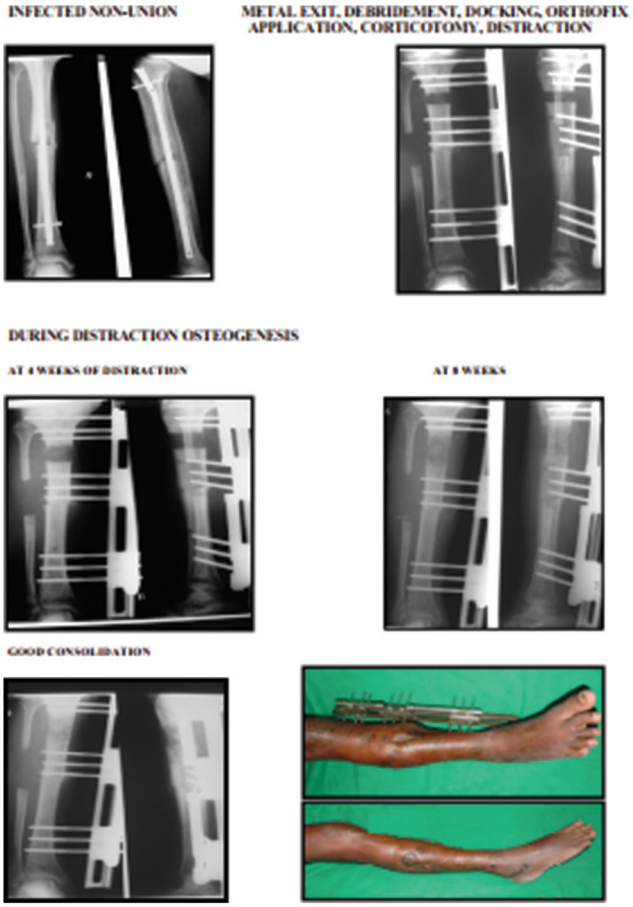

post-treatment. The functional result is affected by the condition of the nerves, muscles, vessels, joints, and to a lesser extent bone [Figures 4 and 5].

The non-union site united in all but three cases out of 21 (85.7%), which is comparable to the study conducted by Garcia-Cimbrelo *et al.*[8] in 2004 wherein the bony union result was 86.7%. Antonio Biasibetti and Aloj, in his study, had a success rate of 93%.[9]

Infected non-union of the humerus is a rare yet challenging problem to treat. In our study, two patients with infected non-union of the humerus were treated with hardware removal, debridement and stabilization in compression with an external fixator. The resultant shortening was accepted. There was evidence of good bony union in an average of 5 months (range 4–6 months), which is comparable to the study by Haidukewych and Sperling,[7] where the reported union time was 5.5 months. In another study conducted by Biasibetti and Aloj[9] the union time was 4 months. Since the non-union was in the diaphyseal region in both the cases and because of the cooperative mobilization exercises carried out by the patients, there was not much impairment of range of movements in shoulder/elbow joints for both the cases. Thus, the results were excellent for both functional aspects as well as the bony union.

In a long-term study of tibial fractures, Merchant and Dietz[10] determined that angular deformities of 10–15 degrees are well tolerated. Leg length discrepancy of up to 2.5 cm does not require any treatment, 5 to 6 degrees of tilt is acceptable. Likewise, minimal translation in the mechanical axis is acceptable. (Range of acceptability unknown)

Pin tract infection occurred in 11 out of 21 cases (52.3%), comparable to the study conducted by Gopal *et al.*,[11] where the reported pin tract infection was in ten out of 19 cases (53%). In another study by Coll, the reported pin tract infection was 30%. Hence, the rate of pin tract infection remained high in our study.

Bone transport resulted in a better restoration of limb length discrepancy in lower limbs. Larger bone defects can be tackled with two-level corticotomies. Our experience is only with single-level corticotomy. Some of the patients who had shortening of more than 1 cm of a lower limb did not give consent for limb lengthening procedure which was planned after evidence of union at the non-union site. The mean limb length discrepancy noted in our study was 2.06 cm. In a study of 26 non-union infected conducted by Eduardo *et al.* the mean limb length discrepancy as 2.03 cm. Bone grafts can be added after infection settles at the non-union site. A graft can also be added to the regenerate site if progression toward consolidation is slow, as quoted in the literature.[9]

The BHI in our study was 47.1 days/cm, which is high compared to that reported in the literature.[3] Various studies and their reported BHI: Aldegheri described 270 lengthening's with a mean BHI of 39 days/cm,[12] Noonan *et al.* reported BHI of 49 days/cm.[13]

The monolateral external fixator is a telescopic device that can be locked for rigid fixation or unlocked to permit load sharing. Even though the cost of the fixator is high, the patients, because of the following reasons, accept it: Lightweight, patient-friendly, and day-to-day activities can be done easily; since the pins are unilateral, it is much more comfortable for the patients; hence, joint mobilization can be done with ease. Furthermore, being rigid, early weight-bearing can be allowed with the device. Therefore, the patient can lengthen very easily.

Moreover, plastic surgery procedures such as a cross-leg flap, Fascio-cutaneous flap, and skin grafting can be done comfortably. Once the patients have been taught how to do distraction, they are advised to come for review once in 15 days to assess the length gained and also to assess the quality of the regeneration. Moreover, the fixator (other than the tapered half pins) can be reused for another patient, provided no damage to the apparatus.

The disadvantages include the high cost of the system, inability to use the apparatus for correction of infected non-union with gross deformity, severe osteoporosis, stabilization very close to a joint, for which Ilizarov fixator could be a better option.

The cost factor has been reasonably managed by the introduction of the Indian version of Orthofix. Compared with the Ilizarov ring fixator, the unilateral external fixator is simpler to apply and better tolerated by the patients. The learning curve for implementing the unilateral fixator is less steep than that encountered with the Ilizarov fixator.

CONCLUSION

In this study, we could achieve a success rate of 86%, giving good encouraging results to most of our patients. Hence, we conclude that the Indian version of the monolateral external fixation system is an effective and convenient method for the treatment of infected non-union of long bones. This can also be used to correct the limb length discrepancies simultaneously, which can arise during the treatment. However, patients with poor cooperation are not good candidates for this technique, which requires wearing the frame for a long time, with probably additional secondary surgical procedures.

REFERENCES

1. David GL. Campbells Operative Orthopaedics. 10th ed. St. Louis: Mosby; 2003. p. 2897.
2. Mahaluxmivala J, Nadarajah R, Allen PW, Hill RA. Ilizarov external fixator: Acute shortening and lengthening versus bone transport in the management of tibial non-unions. Injury 2005;36:662-8.
3. Szabo RM, Marder RA. In: Chapman MW, editor. Chapman's Orthopaedic Surgery. Philadelphia, PA: Lippincott Williams and Wilkins; 2001.
4. Ruedi TP, Murphy WM. AO principles of fracture management. In: AO Principles of Fracture Management. Stuttgart: Thieme; 2000. p. 868-8.
5. Dendrinos GK, Kontos S, Lyritsis E. Use of the Ilizarov technique for treatment of non-union of the tibia associated with infection. J Bone Joint Surg Am 1995;77:835-46.
6. Jain AK, Sinha S. Infected non-union of the long bones. Clin Orthop Relat Res (1976-2007) 2005;431:57-65.
7. Haidukewych GJ, Sperling JW. Results of treatment of infected humeral nonunions: The Mayo Clinic experience. Clin Orthop Relat Res 2003;414:25-30.
8. Garcia-Cimbrelo E, Martí-González JC. Circular external fixation in tibial nonunions. Clin Orthop Relat Res 2004;419:65-70.
9. Biasibetti A, Aloj D. Mechanical and biological treatment of long bone non-unions. Injury 2005;36:S45-50.
10. Merchant TC, Dietz FR. Long-term follow-up after fractures of the tibial and fibular shafts. J Bone Joint Surg Am 1989;71:599-606.
11. Gopal S, Majumder S, Batchelor AG, Knight SL, De Boer P, Smith RM. Fix and flap: The radical orthopaedic and plastic treatment of severe open fractures of the tibia. J Bone Joint Surg Br 2000;82:959-66.
12. Aldegheri R, Renzi-Brivio L, Agatini S. The callotasis method of limb lengthening. Clin Orthop 1989;241:137-45.
13. Noonan KJ, Price CT, Sproul JT, Bright RW. Acute correction and distraction osteogenesis for the malaligned and shortened lower extremity. J Pediatr Orthop 1998;18:178-86.

How to cite this article: Thambiah MV. Analysis of the Treatment of Infected Non-union of Long Bones using Monolateral External Fixator. Int J Sci Stud 2021;9(5):140-145.

Source of Support: Nil, **Conflicts of Interest:** None declared.