

Adenomatoid Odontogenic Tumour: Report of a Case and Review of Literature

Vikas Singh,
D J Bhaskar¹,
R Chandan Agali²,
Mallika Kishore³,
Safalya S Kadtane⁴,
Harender Singh⁵

Post Graduate Student, Department of Public Health Dentistry, Teerthanker Mahaveer University, Moradabad (U.P), India, ¹Professor & H.O.D, Department of Public Health Dentistry, Teerthanker Mahaveer University, Moradabad (U.P), India, ²Reader, Department of Public Health Dentistry, Teerthanker Mahaveer University, Moradabad (U.P), India, ³Post Graduate Student, Department of Oral Medicine and Radiology, Institute of Dental Sciences, Bareilly (U.P), India, ⁴Post Graduate Student, Department of Public Health Dentistry, Teerthanker Mahaveer University, Moradabad (U.P), India, ⁵Post Graduate Student, Department of Public Health Dentistry, Teerthanker Mahaveer University, Moradabad (U.P), India

Corresponding Author: Dr. Vikas Singh, Department of Public Health Dentistry, Final Year Postgraduate Student, Teerthanker Mahaveer Dental College & Research Centre.
E-mail: drvikas7@gmail.com

Abstract

Adenomatoid odontogenic tumor (AOT) is a distinct odontogenic tumor that is exclusively odontogenic epithelium in origin which accounts for about 3-7% of all odontogenic tumors. It is a benign (hamartomatous), noninvasive lesion with slow but progressive growth. It is predominantly found in young and female patients, located more often in the maxilla in most cases associated with an unerupted permanent tooth. Treatment is conservative surgical excision and the prognosis is excellent. AOT frequently resembles other odontogenic lesions such as dentigerous cysts. Immunohistochemically AOT is characterized by positive reactions with certain cytokeratins. Here we report a case of adenomatoid odontogenic tumor (AOT) in the maxilla in a young girl aged 14 years.

Keywords: Adenomatoid odontogenic tumor, True neoplasm, Maxilla

INTRODUCTION

Adenomatoid odontogenic tumour was first described in 1907 by Dreibladt, as a pseudo adenoameloblastoma.¹ Over the years a variety of terminologies have been used to designate this extremely fascinating entity like adenoameloblastoma, adenoameloblastic odontoma, epithelial tumour associated with ameloblastic adenomatoid tumour, developmental cysts, and adenomatoid or pseudo adenomatous ameloblastoma.² Philipsen and Birn proposed the name adenomatoidodontogenictumour in 1969 and suggested that it not be regarded as a variant of ameloblastoma because of its different behaviour.^{3,4} Adenomatoid odontogenic tumor is also called 'two-thirds tumor,' because 2/3rd occur in young females, 2/3rd of adenomatoid tumors occur in the maxilla, 2/3rd of the cases are associated with un-erupted teeth, and two-thirds of the affected teeth are canines.⁵ There are 3 variants of adenomatoid odontogenic tumour, the follicular type (accounting for 73% of cases), which has a central lesion associated with an embedded tooth; the extrafollicular

type (24% of case), which has a central lesion and no connection with the tooth; and the peripheral variety (3% of cases).⁶ The WHO histological typing of odontogenic tumors, jaw cyst and allied lesions (2005) has defined AOT as a tumor of odontogenic epithelium with duct-like structures and with varying degree of inductive changes in the connective tissue.⁷ Conservative surgical enucleation is the most suggested choice of treatment. Recurrence rate for AOT is exceptionally rare. Except only three cases which are reported in Japanese patients showed recurrence of this tumor, therefore, the prognosis is excellent when completely removed in toto.⁵

CASE REPORT

A 14-year-old female child reported to the Department of public health dentistry with a complaint of swelling in the right upper front tooth region since 5 months. History of the present illness revealed that initially the swelling was small in size and gradually it increased to reach upto the present size. It was not associated with any pain or

discharge with no history of trauma associated with it. Extra oral examination revealed mild facial asymmetry with the obliteration of the nasolabial fold (Figure 1). Intraoral examination revealed a solitary diffuse swelling was present on the right anterior maxillary teeth region extending from mesial aspect of 51 to mesial aspect of 13 roughly oval in shape measuring about 1×2 cm in greatest dimension. The colour of overlying mucosa was normal. On palpation, all inspectory findings are confirmed the swelling was soft in consistency, non tender. In hard tissue examination, there was retained 51 with clinically missing 11. There was vestibular obliteration with respect to 51,12,13 (Figure 2). So, based on the history and clinical examination a provisional diagnosis of dentigerous cyst i.r.t 11 was given with a differential diagnosis of adenomatoid odontogenic tumor. In investigations fine needle aspiration cytology was done which revealed a straw coloured fluid and protein estimation level was 4.9 gm/dL. (Figure 3). Intraoral periapical radiograph showed a well defined unilocular radiolucency was seen with respect to 51 with impacted 11. Root resorption in relation to 51 was noted (Figure 4).

Occlusal radiograph also shows well defined radiolucency with impacted 11 (Figure 5). Orthopantomograph of the patient was also taken with showed similar findings (Figure 6). In the treatment surgical excision was done and the specimen was sent for the histopathological examination which revealed cuboidal to columnar cells arranged in the form of nests and rosettes. Tubular appearance, solid areas, duct-like pattern, and whorled arrangement of cells evident. Few cells were also arranged in a plexiform pattern

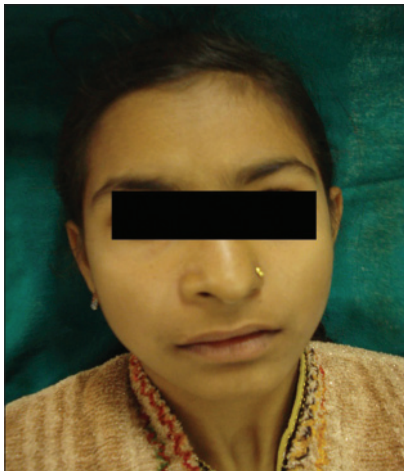

Figure 1: Extraoral view showing obliteration of nasolabial fold

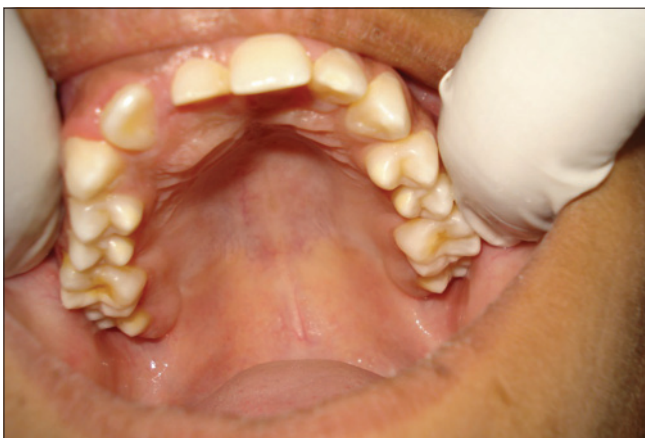

Figure 2: Intraoral view demonstrates the palatal aspect of the swelling

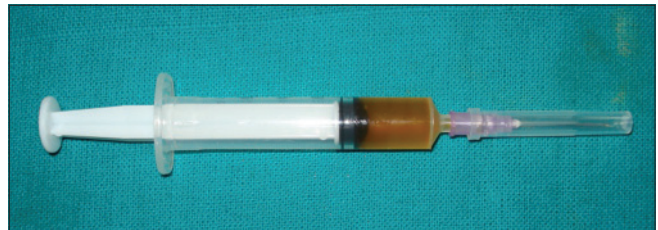

Figure 3: Fine needle aspiration cytology revealed straw coloured fluid

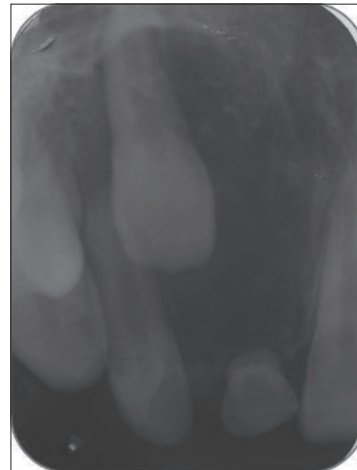

Figure 4: Intraoral periapical radiograph of the region from maxillary right incisor to the canine region showing unilocular radiolucency

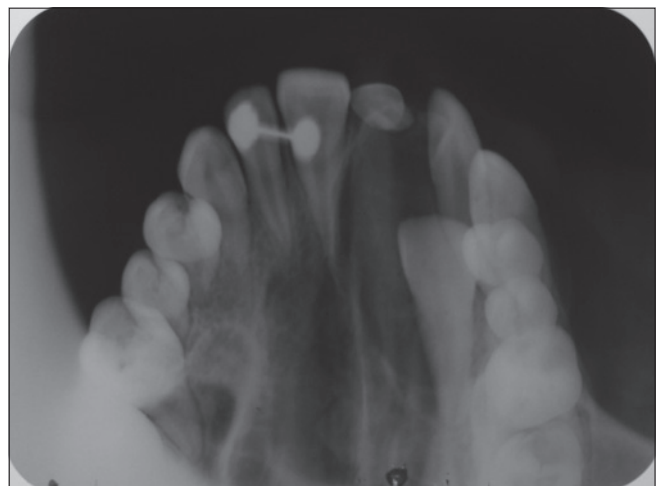


Figure 5: Occlusal radiograph

and cribriform areas are also seen, At high magnification, sheets, nests of polyhedral cells along with ductal pattern lined by cuboidal to columnar cells (Figure 7), At low magnification, sheets of epithelial cells along with ductal pattern (Figure 8), which confirmed the final diagnosis of Adenomatoid odontogenic tumour i.r.t.¹¹.

DISCUSSION

AOT is a benign, non-invasive odontogenic lesion showing slow growth. It is generally intraosseous, but can also occur rarely in peripheral locations.⁸ Sixty-nine percent of

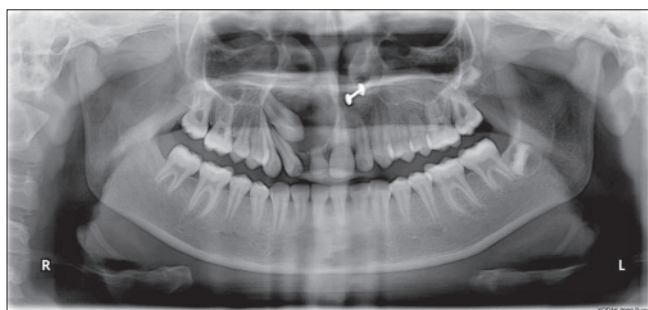


Figure 6: Orthopantomograph (OPG) reveals Unilocular Radiolucency with an impacted 11

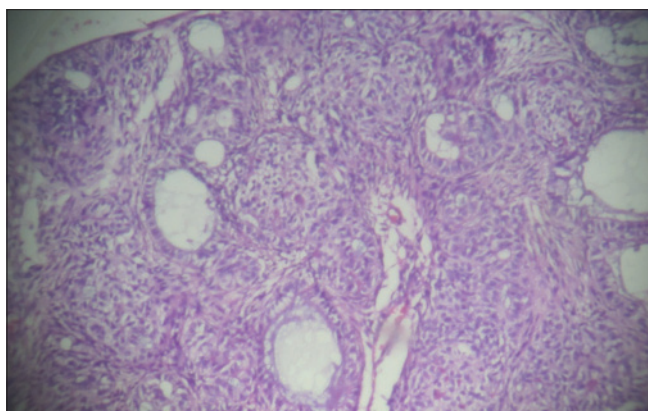


Figure 7: High magnification

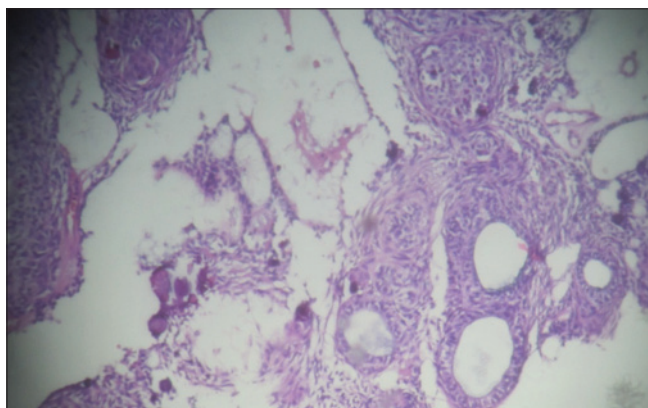


Figure 8: Low magnification

adenomatoid odontogenic tumours are diagnosed in the second decade of life, and more than half occur during the teenage years. There is 2:1 female to male ratio for all age groups and all variants. Generally the tumours do not exceed 1–3 cm in greatest diameter, but they can be larger, usually occurs within the tooth bearing areas of jaws and often found in association with impacted teeth.^{9,10} The origin of AOT is believed to be from an odontogenic source, The cytological features are similar to those of the enamel organ, reduced enamel epithelium, dental lamina and their remanants.⁸ The lesions are typically asymptomatic, but growth of the types with central lesion results in cortical expansion. The involved teeth are commonly impacted, and adjacent teeth may be slightly displaced.¹¹ The radiographic findings of AOT frequently resemble other odontogenic lesions such as dentigerous cysts, calcifying globule-maxillary cysts, calcifying odontogenic cysts, odontogenic tumors, ameloblastomas, odontogenic keratocysts and periapical disease.¹² Displacement of neighbouring teeth due to tumor expansion is much more common than root resorptions. The peripheral lesions may show some erosions of the adjacent cortical bone.⁹ Intraoral periapical radiographs allows perception of the radiopacities in AOT as discrete foci having a flocculent pattern within radiolucency even with minimal calcifies deposits while panoramic often do not. Approximately 78% of AOTs shows those calcified deposits.¹³ Conservative surgical enucleation is the treatment modality of choice. Guided tissue regeneration with membrane technique is suggested for periodontal intrabony defects caused by AOT after complete removal of the tumor.¹⁴

CONCLUSION

AOT is an uncommon odontogenic lesion, seen but it can be usually identified from its clinical and radiographic appearance. Persistence of deciduous teeth for a longer duration and unerupted succeeding permanent teeth, when associated with a swelling, always need to be investigated for odontogenic lesions.

REFERENCES

1. Batra P, Prasad S, Parkash H. Adenomatoid odontogenic tumour: Review and case report. *J Can Dent Assoc.* 2005;71:250-3.
2. Stafne EC. Epithelial tumors associated with developmental cysts of the maxilla: report of 3 cases. *Oral Surg Oral Med Oral Pathol* 1948;1:887.
3. Mallon HL, Sabes WR, Monaco F. Ameloblastic adenomatoid tumor. *Oral Surg Oral Med Oral Pathol* 1968;25:143-4.
4. Garg D, Palaskar S, Shetty VP, Bhushan A. Adenomatoid odontogenic tumor-hamartoma or True neoplasms: A case report. *J Oral Sci.* 2009;51:155-9.
5. Philipsen HP, Reichart PA, Nikai H: The adenomatoid odontogenic tumour (AOT): An update. *Oral Medicine & Pathology.* 1997, 2:55-60.
6. Dare A, Yamaguchi A, Yoshiki S, Okano T. Limitations of panoramic radiography in diagnosing adenomatoid odontogenic tumor. *Oral Surg Oral Med Oral Pathol Oral Radiol Endod.* 1994;77(6):662-8.

7. Vimi S Mutalik, Ashish Shreshtha, Sunil S Mutalik, and Raghu Radhakrishnan. Adenomatoid odontogenic tumor: A unique report with histological diversity. *J Oral Maxillofac Pathol.* 2012;16(1): 118-121.
8. Rick GM. Adenomatoid odontogenic tumour. *Oral Maxillofac Surg Clin North Am.* 2004;16:333-354.
9. Philipsen HP, Reichart PA, Zhang KH, Nikai H, Yu QX. Adenomatoidodontogenic tumor: biologic profile based on 499 cases. *J Oral Pathol Med* 1991; 20(4):149-58.
10. Philipsen HP, Srisuwan T, Reichart PA. Adenomatoidodontogenic tumor mimicking a periapical (radicular) cyst: a case report. *Oral Surg Oral Med Oral Pathol Oral Radiol Endod.* 2002; 94(2):246-8.
11. Geist SY, Mallon HL. Adenomatoidodontogenic tumor: report of an unusually large lesion in the mandible. *J Oral Maxillofac Surg.* 1995; 53(6):714-7.
12. Konouchi H, Asaumi J, Yanagi Y, Hisatomi M, Kishi K: Adenomatoid odontogenic tumor: correlation of MRI with histopathological findings. *Eur J Rad* 2002;44:19-23.
13. Toida M, Hyodo I, Okuda T, Tatematsu N: Adenomatoidodontogenic tumor: report of two cases and survey of 126 cases in Japan. *J Oral Maxillofac Surg.*1990;48:404-408.
14. Blumenthal NM, Mostofi R: Repair of an intrabony defect from an adenomatoid odontogenic tumor. *J Periodontol.* 2000;71:1637-1640.

How to cite this article: Vikas Singh, D J Bhaskar, Chandan Agali R, Mallika Kishore, Safalya S Kadtane, Harender Singh. "Adenomatoid Odontogenic tumour: Report of a Case and Review of Literature". *International Journal of Scientific Study.* 2014;1(4):63-66.

Source of Support: Nil, **Conflict of Interest:** None declared.