Original Article

Radiological study of Oral and Craniofacial Findings in β Thalassaemic Children Undergoing Blood Transfusion

N S Venkatesh Babu[1], H A Amitha[2]

[1]*Professor and Head, MDS in the Department of Pedodontics and Preventive Dentistry, V.S Dental College and Hospital, Bangalore, Karnataka, India,* [2]*Senior Lecturer, MDS in the Department of Pedodontics and Preventive Dentistry, V.S Dental College and Hospital, Bangalore, Karnataka, India*

Corresponding Author: *Dr. N S Venkatesh Babu, Dept. of Pedodontics and Preventive Dentistry, V.S. Dental College and Hospital, K. R Road, V.V Puram, Bangalore, India. Phone - 09448710392, E-mail: drnsvbabu@gmail.com*

Abstract

Background: Thalassaemia is the single most common gene disorder in the world and represents major health burden. The most common oral and craniofacial manifestations are enlargement of maxilla, bossing of the skull and prominent malar eminences. The aim of the study was to assess the radiological changes of the oral and craniofacial region in β thalassaemic children with in the age group of 12-16 yrs.

Methodology: The study population consisted of 50 diagnosed cases of thalassaemic children attending for regular blood transfusions. In each patient three types ofdigital radiographs were taken, namely intraoral periapical radiograph (IOPAR), Orthopantomograph, and Lateral Cephalogram. The radiographs were interpreted forthinned lamina Dura, short roots, marrow space enlargement, altered trabecular pattern, widened diploic space, Salt and Pepper appearance of the skull, Hair on end appearance, Maxillary prognathism.

Results: IOPAR of mandibular molar teeth region showed 52% thin lamina Dura, 34% cases had short roots, 82% cases showed enlarged Marrow space. OPG revealed 84% of cases with alterations in trabecular pattern. Lateral Cephalogram showed 86% widened diploic space, 84% showed salt and pepper appearance of the skull, 2% of them showed hair-on-end appearance of cranial vault, 50% of them showed Maxillary prognathism.

Conclusion: The characters and the degree of bone changes are often increased markedly, with increase in age of the patient inspite of regular blood transfusion. Early diagnosis, counselling and regular follow up are necessary to reduce the morbidity and to reassure the patient for overall improvement of general and oral health.

Keywords: Altered trabecular pattern, Hair on end appearance, Maxillary prognathism, Short roots, Thalassaemia

INTRODUCTION

Thalassaemia refers to a group of inherited hemolytic anemia involving defects in synthesis of either alpha or beta polypeptide chains of Hemoglobin (alpha-thalassaemia, beta-thalassaemia.[1] The word thalasseamia is derived from Greek term thalas meaning the sea. The term "thalassaemia" was first used by Wimple and Bradford in 1932. The disease manifests as homozygous (thalassaemia major) and heterozygous (thalassaemia minor) form. Thalassaemia minor is mild and usually asymptomatic and blood transfusions are required at a less regular interval. The thalassaemia major exhibits the most severe form of clinical symptoms with marked orofacial deformities, and these children should have regular blood transfusions to survive.[1] Homozygous beta thalassaemia, also known as Cooley's anemia or Mediterranean anemia, is seen chiefly in Mediterranean populations, with prevalence in Greece, Turkey, Cyprus and southern Italy.[2] The onset of symptoms occurs early in infancy (usually at the age of 4-6 months) and the children are severely anemic and have a short life expectancy. Children with most severe form of the disease rarely survive into adulthood because of cardiac failure, chronic anemia and hypoxia.[3] However, with advanced management, the prognosis has improved. The most common oral and facial manifestations are enlargement of the maxilla, bossing of the skull and prominent malar eminences due to the intense compensatory hyperplasia of

the marrow. This leads to expansion of the marrow cavity and a facial appearance known as "chipmunk" face.[4] The maxillary hyperplasia frequently results in proclination of teeth and spacing of maxillary teeth and other degrees of malocclusion.[5,6]

General dental practitioners are less aware of this condition in their daily practices, and are required to be aware of the nature of the disease and its implication on dental care. Reviewing the literature revealed only some case reports regarding the radiological findings in children and very few large studies have been undertaken. Therefore, the aim of this study was to assess the radiological changes of oral and craniofacial region in thalassaemic children ranging from 12-16 years of age.

MATERIALS AND METHODS

This cross sectional study was conducted to evaluate radiologically, the oral and craniofacial manifestations in thalassaemic children in the Department of Pedodontics and preventive dentistry, V. S Dental College and Hospital, Bangalore, Karnataka, India. The study population consisted of 50 diagnosed cases of thalassaemic children attending regular blood transfusions at Indira Gandhi institute of child health, Bangalore, India. Signed written informed consent from all the parents/guardian was obtained. The research protocol was approved by institutional ethical committee. Detailed case histories, clinical examination followed by radiological examination were done. Three types of digital radiographs namely IOPAR, Orthopantomograph, and Lateral Cephalogram with standardization were taken.

IOPAR of mandibular molar teeth were taken by Paralleling Technique, CCX Digital Trophy Trex Group – X-ray machine with specifications of 70 kVp, 8 mA, 16 x/sec (Electronic X-ray timer). IOPAR Films- No. 2 (31 x 41 mm) (Kodak Dental Intra Oral E-Speed Film, Eastman Kodak Company, New York.

Orthopantomogram (OPG) (Odontorama Pc 100 Trophy Radiologie, France) 55-100 kVp, 3-10 mA, 14 seconds of exposure time.

Cephalostat (odontorama pc 100 trophy Radiologie, France**)** 1.20 to 1.60 seconds (Exposure time), 70 to 85 kVp, 8 mA to 10 mA. For Cassette: Rigid (8" x 10") Intensifying Screen (kiran intensifying screen). Lateral cephalographic films 8" x 10" (Kodak tmat g/ra, Eastman kodak company, roechester, New York). The examiner was calibrated prior to interpretation of radiographs. Following features like thinned lamina dura and short roots, marrow space enlargement, altered trabecular pattern, widened diploic space, Salt and Pepper appearance of the skull, Hair on end appearance and maxillary prognathism were assessed. Comprehensive dental treatment was provided to all the patients.

Tracing of Lateral Cephalogram

The lateral cephalogram were traced on acetate paper, after proper orientationof radiograph by attaching one side withcellophane tape. Steiner's analysis was carried out by marking 3 reference points on the radiograph. Then the soft tissue outline was traced.

N –Nasion: Most anterior point midway between frontal and nasal bones onfrontonasal suture.

S-Sella: Geometric centre of pituitary fossa and or sella tursica. It is aconstructed point in mild saggital plane.

Point A - Deepest point in the mid saggital plane between the anteriornasal spine and alveolar crest between the two central incisors. It is also called as subspinale. After registering the cephalometric landmarks SNA angle was calculated.

SNA Angle: Angle formed by the line drawn from sella-nasion to point A. Itrelates the anterior-posterior position of maxilla to the anterior cranial base. The mean SNA angle is around 82°. If it is greater than 82° it indicates forward positioning of the maxilla.

RESULTS

The thalassaemic children in the present study were between the age group of 12-16 years. The mean age was around 14 years, with male predominance (68%). There were 49 cases of β-thalassaemia major and one case of β-thalassaemia intermedia. All the children were under regular blood transfusion therapy and most of the children were under chelation therapy. Out of 50 patients 8 patients had undergone spleenectomy**.** Clinically 5% of them showed characteristic "chipmunk appearance" of the face. Data was statistically analyzed using SPSS software version 15.0. IOPAR of mandibular molar teeth showed 52% of thin lamina dura, 34% cases had short roots, 82% cases showed enlarged Marrow space. 16% of them showed overlapping of above findings (Figure 1, Table 1, Graph 1). OPG revealed 84% of cases with alterations in trabecular pattern (Figure 2). Lateral Cephalogram showed 86% of widened diploic space, 84% showed salt and pepper appearance of the skull, 2% of them showed hair-on-end appearance of cranial vault, 50% of them showed Maxillary prognathism with a mean SNA angle of 84° (Figure 3, 4 and Table 2, Graph 2).

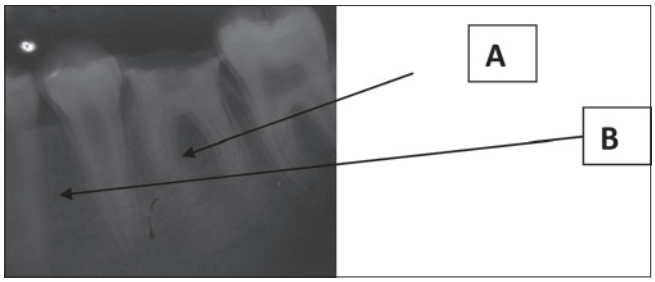

Figure 1: IOPAR showing presence of short roots, thin lamina dura (A) and enlarged marrow spaces (B)

Figure 2: OPG showing presence of alteration of trabecular pattern

Table 1: IOPAR findings

Findings	No.of cases (n)	No.of cases (n%)
Thin lamina dura	26	52
Normal lamina dura	24	48
Short roots	17	34
Normal roots	33	66
Enlarged marrow spaces	41	82

Table 2: Lateral cephalograph findings

Findings	No. of cases (n)	No. of cases (n%)
Widened diploic space	43	86%
Salt and pepper appearance	42	84%
Hair on end appearance	1	2%
Maxillary protrusion	25	50%

DISCUSSION

Thalassaemia is the most common single gene disorder in the world and represents a major health burden. It is a heterogeneous group of recessively inherited disorders of hemoglobin molecule characterized by the deficiency or absence of β or α globin chains. The children with thalassaemia classically present with severe anemia and have transfusion dependent survival. They have bony changes, retardation in growth, Splenomegaly, and iron overload

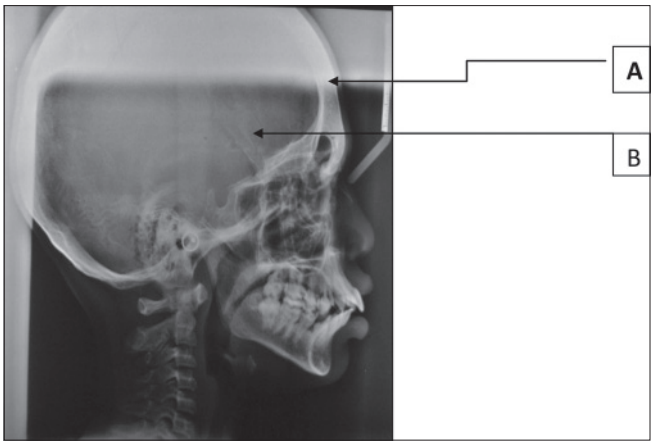

Figure 3: Lateral cephalogram showing, widening of diploic space (A) and salt and pepper appearance of the skull (B)

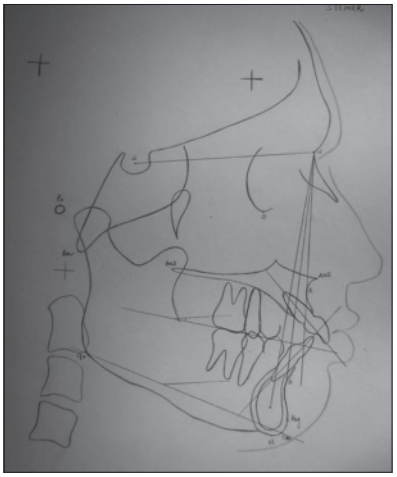

Figure 4: Steiner's cephalometric analysis with increased SNA angle

with consequent deposition in tissues.[7] Clinically 5% of them presented with characteristic 'chipmunk appearance' of the face. In the present study, mandibular molar teeth were considered for demonstrating the presence of short roots. 34% of cases showed short roots in this study. According to Wheeler's, the root lengths of mandibular first and second molars ranges from 13-14 mm. But in case of children with thalassaemia it was varied from 9-12 mm. Children with thalassaemia have generalized growth retardation, which may in turn affect the dimensions of the teeth. It may be due to variety of genetic and environmental factors, such as endocrine dysfunction and somatomedin deficiency which affects tooth size in thalassaemia major. Studies done by Poyton HG et al[8] and Hazza'a AM[9] have also reported cases with short roots. An intact lamina dura is seen as a sign of healthy periodontium. Present study showed 52% cases with thin lamina dura. Lamina dura is nothing but part of the alveolar bone that lines the socket as a thin layer of dense cortical bone. Absence or thinning of lamina dura is also seen in other systemic condition like secondary hyperparathydoism.[10,11] Studies done by

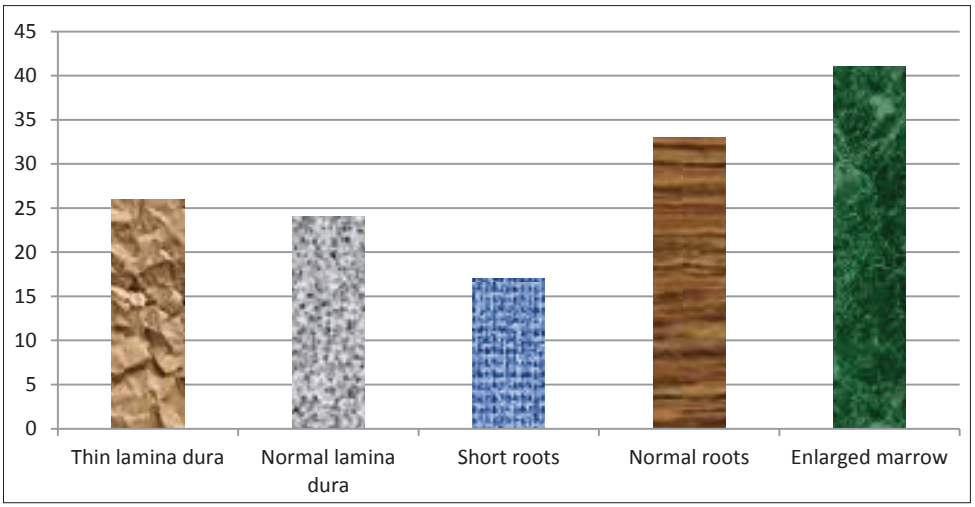

Graph 1: IOPAR findings

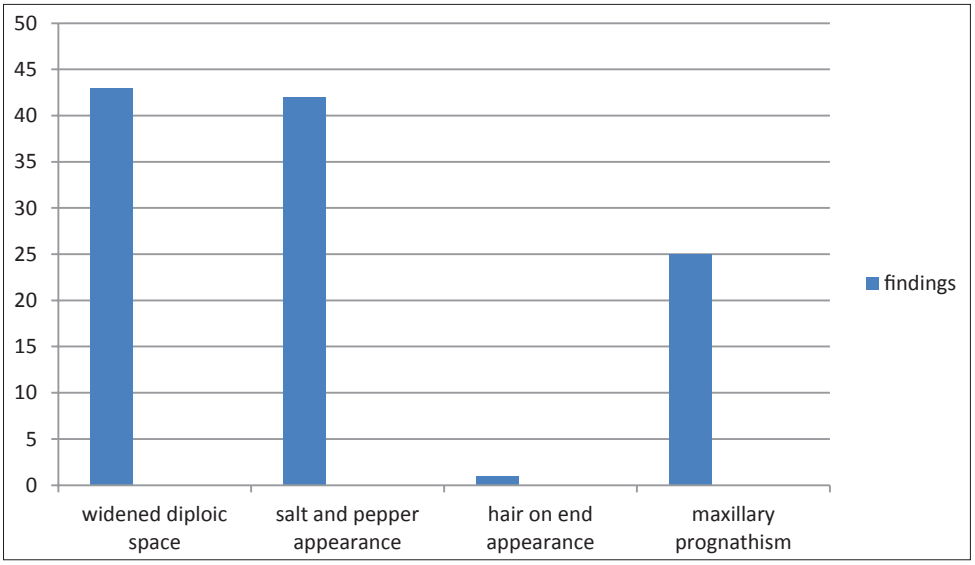

Graph 2: Lateral cephalogram findings

Poyton HG et al.[8] and Hazza'a AM et al.[9] reported thin lamina Dura in 46% and 87.5% of thalassaemic patients respectively. Children with thalassaemia have chronic anemia due to ineffective erythropoiesis which damages the red blood cell membrane. The body responds by increasing the production of red blood cells, consequently causing expansion of the bone marrow up to 15-30 times the normal amount.[9] Present study showed 82% cases with enlargement of marrow spaces. Studies done by Kaplan RI[12] and Parkin SF[13] reported enlargement of marrow spaces in 86% and 100% of their patients respectively. Study reported by Poyton HG and Davey KW showed 42% cases with enlarged marrow spaces.[8]

In the present study OPG revealed 84% of cases with alterations in trabecular pattern. These alterations are mainly due to hyperplasia of the bone marrow. Studies reported by Poyton HG[8], Kaplan et al.[12] showed 86% and 87.5% of the cases with similar findings.

Lateral Cephalogram of many children showed significant findings. Majority of the children (86%) showed widened diploic space. Hyperplasia of red bone marrow causes widening of the diploic spaces, which eventually leads to thinning or complete obliteration of the outer table of the skull. Study done by Roy RN et al. reported 73% of the cases with widening of diploic space.[14] Orzincolo et al. reported a case with similar finding.[15] Salt and pepper appearance of the skull is due to presence of osteopenia in thalassaemic patients. Regular blood transfusion of thalassaemic children leads to an iron overload and secondary hemochromatosis. As consequences to iron overload, endocrinopathies like hypogonadotropic hypogonadism may occur, which in turn leads to osteopenia. Present study showed 84% of

cases with salt and pepper appearance. Brandel M[16] and Wisetsin S[17] reported 36.6% of them with salt and pepper appearance of the skull. Orzincolo C et al. reported a case with similar finding.[15]

In our study hair-on-end appearance was observed in only one case (2%). The hair-on-end sign was seen in the diploic space as long and thin vertical striations. This is due to hyperplastic marrow which perforates or destroys the outer table, and new bone spicules are laid down perpendicular to the inner table. It is also more commonly seen in other hemoglobinopathies like sickle cell anemia, less commonly in patients with severe iron deficiency, cyanotic heart disease and also after long-term G-CSF treatment in severe congenital neutropenia.[18-22] Studies done by Wisetsin S[17] reported 8.3% and Roy AN et al.[14] reported 12% of patients with hair-on-end appearance. Parkin SF[13], Orzincolo C et al.[15] reported a case with similar finding. The present study showed 50% cases with maxillary prognathism. Studies done by Abu Alhaija et al.,[6] Bassimitci et al.[23] also reported maxillary prognathism based on cephalometric analysis.

Parkin SF[13], Beard ME et al.[24] reported that if the patient undergoes regular transfusion early in life, it helps to control the changes on the exterior of skull bones and in other bones, which are reflections of extra-medullary hemopoiesis (EMH) later in life. Scutellari PN et al. reported that in skull, the diploic space may become normal, and overgrowth of facial bones moderate, the hair-on-end pattern may disappear completely by regular blood transfusion.[25]

CONCLUSION

As the age increases the characters and the degree of bone changes are often increased markedly, in spite of regular blood transfusion. This is necessary for early diagnosis, counseling and regular follow up in order to reduce the morbidity, reassure the patient and to improve the overall general and oral condition of the patient. However, the findings of this study regarding the global trends in radiological manifestations, severity, patients care, parent's attitude about the disease did not show any greater variations as compared to other studies reported based on similar criteria.

REFERENCES

1. Weatherall JD, Clegg JB. The thalassaemia syndromes. 3rd ed. Oxford: Blackwell, 1981;132-174.
2. Preethi Girinath, Sonal P Vahanwala, Vasavi Krishnamurthy, Sandeep S Pagare. Evaluation of orofacial manifestations in 50 thalassemic patients: A clinical study. *Journal of Indian academy of oral medicine and radiology*. 2010;22 (3);126-132.
3. Modell B. Management of thalassaemia major. *Arch Dis Child*. 1983;58 (12):1026-30.
4. Kaplan RI, Werther R, Castano FA. Dental and oral findings in Cooley's anemia: A study of fifty cases. *Ann NY Acad Sci*. 1964;119: 664-666.
5. Van Dis ML, Langlais RP. The thalassaemias: oral manifestations and complications. *Oral Surg, Oral Med, Oral Pathol*. 1986; 62:229-233.
6. Abu Alhaija ES, Hattab FN, Al-Omari MA. Cephalometric measurements and facial deformities in subjects with beta thalassaemia major. *Eur J Orthod*. 2002; 24:9-19
7. Al-Wahadni A, Qudeimat MA, Al-Omari M. Dental arch morphological and dimensional characteristics in Jordanian children and young adults with β- thalassaemia major. *International Journal of Pediatric Dentistry*. 2005;15:98-104.
8. Poyton HG, Davey KW. Changes visible in radiographs used in dentistry. *Oral Surg, Oral Med, Oral Pathol*. 1968;25 (4):564-576.
9. Hazza'a AM and Al-Jamal. Radiographic features of the jaws and teeth in thalassaemia major Dentomaxillofacial Region. *Radiology*. 2006; 35,283-288.
10. William H. Kelly, Michael K. Mirahmadi, James H.S. Simon, John T. Gorman. Radiographic changes of the jaw bones in end stage renal disease. *Journal of Oral surg, oral med, oral path*. 1980;50 (4):372-381.
11. Kaffee, A. Tamse, Y. Schwartz, A. Buchner. Changes in the lamina Dura as a manifestation of systemic diseases: report of a case and review of the literature. *Journal of Endodontics*. 1982; 8 (10): 467-470.
12. Kaplan RI, Werther R, Castano FA. Dental and oral findings in Cooley's anemia: a study of fifty cases. *Ann NY Acad Sci*. 1964; 119: 664-666.
13. Parkin SF. Dental treatment for children with thalassaemia. Oral Surg, Oral Medicine, *Oral Pathology*. 1968; 25 (1):12-18.
14. Roy RN, Banerjee D, Chakraborty KN, Basu SP. Observations on radiological changes of bones in thalassaemia syndrome. *J Indian Med Ass*. 1971;57 (3):90-95.
15. Orzincolo C, Castaldi G, Bariani L, Franceschini F, Corcione S, Scutellari PN. Circumscribed lytic lesions of the thalassaemic skull. *Skeletal Radiol*. 1988;17 (5):344-7.
16. Brandel M, Osteopenia in beta-thalassemia major. *Schweiz med*. 1996;126 (44):1867-74
17. Wisetsin S. Cephalography in thalassemic patients. *J Dent Assoc Thai*. 1990;40 (6):260-8.
18. Azam. M, N Bhat. Images in paediatrics Hair-on-end appearance. *Arch Dis Child*. 2006; 91:735
19. Philip Lanzkowsky. Radiological features of Iron-Deficiency Anemia. *Am J Dis Child*. 1968; 116 (1):16-29.
20. Britton HA, Canby JP, Kohler CM. Iron deficiency anemia producing evidence of marrow hyperplasia in the calvarium. *Pediatrics*. 1960;25:621-8.
21. Walor DM, Berdon WE, Westra SJ. Hair-on-end" skull changes resembling thalassemia caused by marrow expansion in uncorrected complex cyanotic heart disease. *Pediatric Radiology*. 2005; 35: 698-701.
22. Albert MH, Notheis G, Wintergerst U, Born C, Schneider K. "Hair-on-end" skull induced by long-term G-CSF treatment in severe congenital neutropenia. *Pediatric Radiol*. 2007;37 (2): 221-4.
23. Bassimitci, Emel Yucel-Eroglu, Mine Akalae. Effects of thalassaemia major on components of the craniofacial complex. *British Journal of Orthodontics*. 1996;23:157-164.
24. Beard ME, Necheles TF, Allen DM. Clinical experience with intensive transfusion therapy in Cooley's anemia. *Ann N.Y. Acad Science*. 1969; 165: 415-22.
25. Scutellari PN, Orzincolo C, Franceschini F, Bagni B, Atti G. Thalassaemia today. The radiological evaluation of lesions of the skull and hand with reference to transfusion therapy. *Radio Med (Torino)*. 1988;76 (5):399-404.
26. Major M. Ash, Stanley J. Nelson. Wheeler's text book of dental anatomy, physiology and occlusion. 8th ed.:302-316.

How to cite this article: N S Venkatesh Babu, H A Amitha. "Radiological Study of Oral and Craniofacial Findings in β Thalassaemic Children Undergoing Blood Transfusion". Int J Sci Stud. 2014;2(1):11-15.

Source of Support: Nil, **Conflict of Interest:** None declared.