Salvaging an Implant with Abutment Screw Fracture by a Custom Titanium Post and Core Supported Prosthesis - A Novel Technique

K Harshakumar[1], Shashank Bhatia[2], R Ravichandran[3], P T Joy[4]

[1]Professor & MDS in the Department of Prosthodontics, Government Dental College, Thiruvananthapuram, Kerala, India, [2]MDS 3rd Year Post Graduate student in the Department of Prosthodontics, Government Dental College, Thiruvananthapuram, Kerala, India, [3]MDS & Professor in the Department of Prosthodontics, Government Dental College, Thiruvananthapuram, Kerala, India, [4]MDS & Assistant Professor in the Department of Prosthodontics, Government Dental College, Thiruvananthapuram, Kerala, India

Corresponding Author: *Dr. Shashank Bhatia, Room no. 301, Dept. of Prosthodontics, Government Dental College, Trivandrum, Medical College Po, Trivandrum - 695011, Mobile: 9387857203, 7209150168. E-mail: drshashank16@gmail.com*

Abstract

Screw loosening and its fracture is one of the most common mechanical complication of implant treatment. Retrieval of the fractured fragment is challenging when the fracture occurs below the head of implant or there is a damage to its internal threads. Many techniques have been described for the removal of the fractured segment from the screw hole. But when all the modalities fail to retrieve the segment or there is a damage to the internal threads during the process, the implant may be rendered useless. The clinician under such conditions might opt for removing the failed implant and replace it with a new one which would be an additional surgical trauma and financial burden to the patient. Thus salvaging the implant by other means appears to be a viable option in such situations. The management of a patient who had reported with fracture of an implant abutment screw by means of a custom cast post and core is presented.

Keywords: Abutment screw retrieval, Custom post and core, Damaged internal threads, Implant screw loosening, Implant screw fracture

INTRODUCTION

Dental implantation is a reliable and predictable treatment for partially and completely edentulous patients and is gaining tremendous popularity and interest amongst patients and dentists alike. With proper diagnosis and treatment planning, appropriate placement, adequate prosthetic design, and proper maintenance, dental implants can achieve a success rate of 97% to 99%.[1,2] The success of dental implants is based primarily on the extent of osseointegration.[3,4] However, many other factors also account for its failure. Amongst them Peri-implantitis and failure of implant-supported restorations are noteworthy. Failures of implant-supported restorations result from technical problems and can be divided into two groups: those related to the implant components, and those relating to the prosthesis.[5,6] Fracture of implant components may occur due to fatigue from biomechanical overload, improper placement techniques, non passive fit of the suprastructures,[7] or manufacturing errors.[8] Abutment failure due to fracture of its retaining screw is generally a challenge for the clinician due to the difficulty of removal of fractured screw fragments. A review of *in vivo* butt-joint implant studies reported abutment screw or prosthesis screw loosening as the most frequent mechanical complication.[9] In most circumstances, the fractured end can be retrieved and replaced by a new abutment screw. When the screw cannot be removed conservatively, rotary instruments can be used to retrieve the fractured screw. But it may damage the internal threads of the screw hole and the implant may be become useless. As a result, clinicians might choose to either remove the implant and replace it with a new one, or abandon the implant and cover it with soft tissue. This article describes a novel technique of salvaging an implant which suffered fracture of its abutment screw and damage of its internal threads.

CASE REPORT

A twenty four year old female patient reported to the Department of Prosthodontics, Govt. Dental College, Thiruvananthapuram with a chief complaint of dislodged crown in relation to an implant placed 5 years back in the upper anterior region (Figure 1). She noticed the mobility of the crown about three months back which gradually increased. But due to her personal commitments was unable to seek treatment on time. This was a typical case of screw loosening which eventually led to screw fracture (Figure 2). Intra oral examination revealed an implant supported crown at 11 with abutment screw fracture below the level of implant head. Radiographs revealed an osseointegrated endosseous screw form implant with the fractured screw fragment locked in the screw hole at around 5mm below the head of implant making its retrieval challenging (Figure 3). The other half of the fractured screw along with the abutment was in the dislodged crown. The fractured screw was visualized under magnification (×2.5). Internal threads of the screw hole appeared damaged under magnification (Figure 4). A fine ultrasonic endodontic tip was placed on the screw and vibrated at a low setting. There was no movement of the screw. Other methods of retrieval of screw fragment[10] was employed which also failed. This can be attributed to the damaged internal threads of the screw hole. The patient was unwilling to undergo extensive procedure of implant removal and placement of new implant and thus it was decided to use the screw hole as a channel for custom fabricated titanium post and core. The internal threads of the impant was eliminated (Figure 5) using a tungsten carbide bur (170 L) in a high speed air rotor handpiece under copious saline irrigation (Figure 6). Coronal fragment of the fractured segment was removed using a 8mm round ended tapered diamond and carbide bur to provide space for sufficient length of post which could resist the torsional forces. An acrylic resin pattern for the post was fabricated directly in the post space with an autopolymerizing acrylic resin and plastic pin using a brush-on technique (Figure 7). Care was taken to prevent locking of the pattern in the screw hole by removing it before it was completely polymerized. After the polymerization is complete, the pattern is replaced and the core portion is fabricated with resin, trimmed, finished and polished to appropriate length and shape (Figure 8). The pattern was sent to the lab for fabrication of titanium cast post and core (Figure 9). The titanium dowel core was tried in the screw hole (Figure 10). It was cemented into the implant using zinc phosphate cement (Phosphate

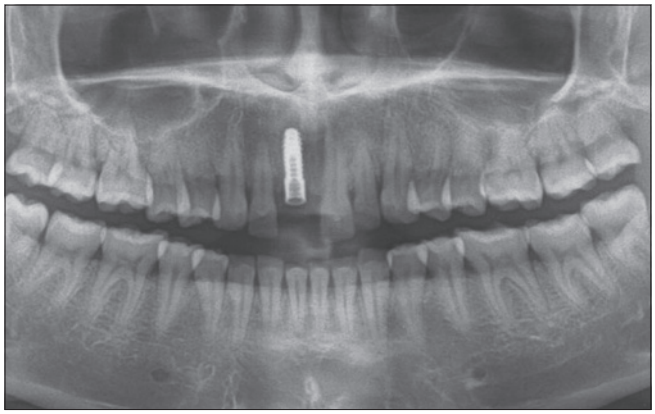

Figure 1: Oral pantamogram of the patient immediately after the placement of implant

Figure 2: Crown with the fractured abutment screw

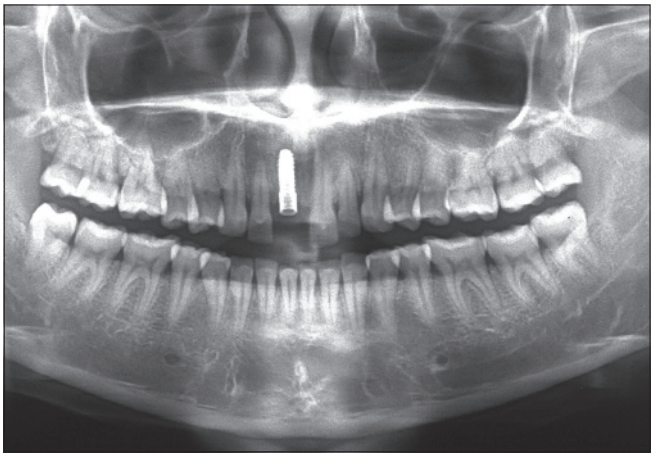

Figure 3: Oral pantamogram of the patient showing abutment screw fracture below thehead of implant

Figure 4: Damaged internal threads of the implant

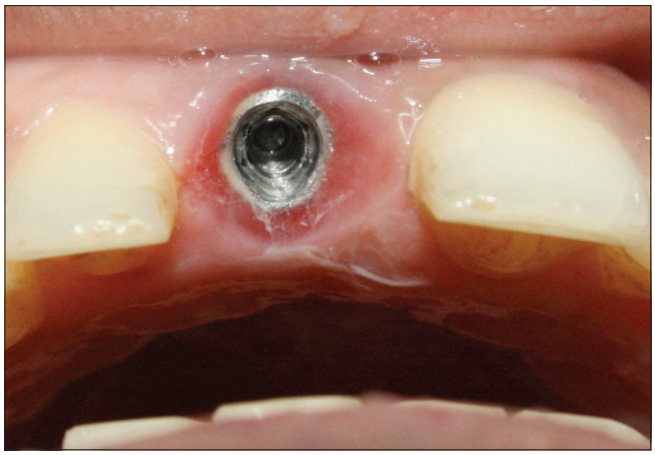

Figure 5: Prepared post space in implant by removing the internal threads

Figure 6: Post space preparation by removing the internal threads using tungsten carbide bur in a high speed air rotor under copious irrigation

Figure 7: Pattern for the custom post and core made using clear autopolymerizing acrylic resin

Figure 8: Trial of the pattern

Figure 9: Custom post and core

Figure 10: Custom post and core cemented to the implant using zinc phosphate cement

cement, Heraeus Kulzer, Germany). After cementation of the post and core, metal ceramic crown was fabricated following conventional prosthodontic procedure. The crown was cemented after eliminating the interferences in all protrusive and lateral excursive movements (Figure 11). The patient was followed up after six months with no signs of complications or failure of prosthesis (Figure 12).

Figure 11: Metal ceramic crown cemented over the cast core. Post operative intra oral view

Figure 12: Post operative extra oral view

DISCUSSION

Abutment screw fracture, although uncommon, occurs in clinical practice[6,11-12] and its removal can be quite challenging for the clinician. If an abutment screw fractures above the head of the implant, hemostats or artery forceps may be used to grasp the broken screw and remove it successfully. If the screw fracture occurs below the head of the implant or is stuck, other methods or systems can be employed to remove the fragment. Most of these systems involve drilling of a hole into the center of the broken screw followed by engaging a removal wedge into the broken screw. Reverse torque is then applied with the removal instrument. But if all the methods fail to retrieve the fractured segment or there is a damage to the internal threads of the implant screw hole, the implant may be rendered useless. In such a scenario a cast post and core supported prosthesis can salvage the near useless implant.

CONCLUSION

In this case report a relatively simple technique of salvaging an implant with abutment screw fracture and damaged internal threads has been described. The technique when executed with ultimate care and precision would provide excellent result. The non-invasive nature of the procedure would also be satisfying to the patient.

REFERENCES

1. Ekelund JA, Lindquist LW, Carlsson GE, Jemt T. Implant treatment in the edentulous mandible: a prospective study on Brånemark system implants over more than 20 years. *Int J Prosthodont* 2003;16: 602-8.
2. Schenk RK, Buser D. Osseointegration: a reality. *Periodontol* 2000 1998;17: 22-35.
3. Albrektsson T, Branemark PI, Hansson HA, Lindstrom J. Osseointegrated titanium implants. Requirements for ensuring a long-lasting, direct bone to-implant anchorage in man. *Acta Orthop Scand* 1981;52: 155-70.
4. Lindquist LW, Carlsson GE, Jemt T. A prospective 15-year follow-up study of mandibular fixed prostheses supported by osseointegrated implants. Clinical results and marginal bone loss. *Clin Oral Implants Res* 1996;7:329-36.
5. Bragger U, Aeschlimann S, Burgin W, Hammele CH, Lang NP. Biological and technical complications and failures with fixed partial dentures (FPD) on implants and teeth after four to five years of function. *Clin Oral Implants Res* 2001;12: 26-34.
6. Luterbacher S, Fourmousis I, Lang NP, Bragger U. Fractured prosthetic abutments in osseointegrated implants: a technical complication to cope with. *Clin Oral Implants Res* 2000;11: 163-70.
7. Cranin AN, Dibling JB, Simons A, Klein M, Sirakian A. Report of the incidence of implant insert fracture and repair of Core-Vent dental implants. *J Oral Implantol* 1990;16: 184-8.
8. Rosenstiel SF, Land MF, Fujimoto J. *Contemporary fixed prosthodontics*. 2nd ed. St Louis: Mosby; 2006. p. 425.
9. Goodacre C J, Kan J Y, Rungcharassaeng K. Clinical complications of osseointegrated implants. *J Prosthet Dent* 1999; 81: 537-552.
10. Maalhagh-Fard A, Jacobs LC. Retrieval of a stripped abutment screw: a clinical report. *J Prosthet Dent*. 2010; 104:212-5.
11. Williamson RT, Robinson FG. Retrieval technique for fractured implant screws. *J Prosthet Dent*. 2001;86:549-550.
12. Nergiz I, Schmage P, Shahin R. Removal of a fractured implant abutment screw: a clinical report. *J Prosthet Dent*. 2004;91: 513-7.

How to cite this article: K Harshakumar, Shashank Bhatia, R Ravichandran, P T Joy. "Salvaging an Implant with Abutment Screw Fracture by A Custom Titanium Post and Core Supported Prosthesis - A Novel Technique". Int J Sci Stud. 2014;2(1):36-39.

Source of Support: Nil, **Conflict of Interest:** None declared.