International Journal of Scientific Study

General Information

About The Journal

International Journal of Scientific Study (IJSS) is a monthly journal publishing research articles after full peer review and aims to publish scientifically sound research articles in across all science like Medicine, Dentistry, Genetics, Pharmacy, etc.

Each article submitted to us would be undergoing review in three stages: Initial Review, Peer Review & Final Review.

Abstracting & Indexing Information

PubMed - Selected Citations (As Mentioned on National Library of Medicine Catalog Website) - www.ncbi.nlm.nih.gov/nlmcatalog/101729001, Index Medicus (IMSEAR), Global Index Medicus, Google Scholar, WorldCat, SafetyLit, Genamics Journal Seek Ulrichsweb Serials Solutions, International Committee of Medical Journal Editors (ICJME) Geneva Foundation for Medical Education & Research (GFMER), Socolar, Bielefeld Academic Search Engine (BASE), Research Bible, Academic Journals Database, J-Gate, Jour Informatics, Directory of Research Journal Indexing (DRJI), Scientific Indexing Services (SIS) Rubriq-Beta, SHERPA RoMEO, New Journal (EIJASR), IndianScience.in, CiteFactor, Scientific Journal Impact Factor (SJIF), Journal Index.net, ROAD, Global Impact Factor (GIF), International Society for Research Activity (ISRA), Advanced Science Index (ASI)

Information for Authors

The authors should follow "Instructions to Authors" which is available on website http://www.ijss-sn.com/instructions-to-authors.html. Authors should fill the Copyright Transfer form & Conflict of Interest form. Manuscripts should be submitted directly to: editor@ijss-sn.com.

Publication Charges

International Journal of Scientific Study aims to encourage research among all the students, professionals, etc. But due to costs towards article processing, maintenance of paper in secured data storage system, databases and other financial constraints, authors are required to pay. However discount will be provided for the non-funding quality research work upon request. Details about publication charges are mentioned on journal website at: http://www.ijss-sn.com/publication-charges.html.

Advertising Policy

The journal accepts display and classified advertising Frequency discounts and special positions are available. Inquiries about advertising should be sent to editor@ijss-sn.com.

Publishing Details

Publisher Name: International Research Organization for Life & Health Sciences (IROLHS)

Registered Office: L 214, Mega Center, Magarpatta, Pune - Solapur Road, Pune, Maharashtra, India – 411028. Contact Number: +919759370871.

Designed by: Sinjore Technologies (www.sinjore.com)

Disclaimer

International Journal of Scientific Study

Editorial Board

International Journal of Scientific Study
April 2021 • Vol 9 • Issue 1

Contents

International Journal of Scientific Study

April 2021 • Vol 9 • Issue 1

International Journal of Scientific Study

April 2021 • Vol 9 • Issue 1

International Journal of Scientific Study

April 2021 • Vol 9 • Issue 1

Print ISSN: 2321-6379
Online ISSN: 2321-595X

Case Report

Pyogenic Granuloma of Tongue in a Middle-aged Patient – A Rare Case Report

Swaroop Dev[1], R K Vigneshwar[2], Shravya Pasunuti[2], R Balaje[3]

[1]Associate Professor, Department of ENT, Sri Siddhartha Medical College, Tumkur, Karnataka, India, [2]2nd year Post Graduate Students, Department of ENT, Sri Siddhartha Medical College, Tumkur, Karnataka, India, [3]1st year Post Graduate Students, Department of ENT, Sri Siddhartha Medical College, Tumkur, Karnataka, India

Abstract

Pyogenic granuloma (PG) is a benign vascular neoplasm of the oral cavity that usually presents as a small nodular lesion, the gingiva being the most common site. Occasionally, it occurs at uncommon sites with unusual sizes. Here, we report a case of a 57-year-old male patient with PG on the left lateral border of tongue. Its differential diagnosis, the importance of biopsy findings in establishing definitive diagnosis, and it's treatment are discussed.

Key words: Capillary hemangioma, Pyogenic granuloma, Tongue

INTRODUCTION

Pyogenic granuloma (PG), also known as lobular capillary hemangioma, is a benign vascular neoplasm.[1] The term PG is a misnomer as the cause is traumatic and not infectious. PG seen in the oral cavity arises in response to various stimuli such as local irritation, trauma, or hormonal factors. It usually occurs on gingiva but uncommonly it can occur on extragingival sites such as lips, tongue, and buccal mucosa.[2] The incidence of PG is 19.76–25%.[3] This pathology can be found at any age but is more common in the second and third decades of life.[4] Characteristically, PG of tongue is more common on the lateral side of the tongue which may be related to trauma from adjacent teeth or dentures.[5]

We present a case with lesion in the left lateral border of tongue to enlighten the readers to keep PG as a differential diagnosis while suspecting tumors of oral cavity, especially in older patients.

Access this article online

www.ijss-sn.com

Month of Submission : 02-2021
Month of Peer Review : 03-2021
Month of Acceptance : 03-2021
Month of Publishing : 04-2021

CASE REPORT

A 57-year-old male patient came to ENT outpatient department with complaints of mass on the left side of tongue for 5 months. Initially, the mass was of the size of a small pea which gradually progressed to the present size. There was no history of pain during chewing, difficulty in swallowing, occasional mild bleeding was present in the mass. There were no constitutional symptoms such as loss of appetite or weight loss.

The patient was a known case of hypertension on regular treatment. Not a known case of diabetes mellitus, asthma, epilepsy, tuberculosis. The patient was a pan chewer for 30 years, stopped for 6 months.

On intraoral examination, poor oral hygiene was present. A grayish-white pedunculated mass of about 1 cm × 1 cm with an irregular margin and smooth surface was seen on the left lateral border of tongue [Figure 1]. It was firm, mobile, mildly tender and bleeds mildly on touch. Other oral cavity examination revealed submucosal fibrous patches present on both sides of buccal mucosa and soft palate.

A differential diagnosis of PG or inflammatory fibroma was made. Excisional biopsy was performed under local anesthesia with 3 mm margin. The histopathological examination (HPE) revealed multiple lobules of capillaries of varying caliber lined by endothelial cells, with an overlying stratified squamous epithelium showing focal ulceration

Corresponding Author: Dr. R K Vigneshwar, Room No. 27, Jeevika Boys PG Hostel, Sri Siddhartha Medical College, Tumkur - 572107, Karnataka, India.

Figure 1: Gross appearance of the lesion arising from lateral border of tongue

[Figure 2]. This was consistent with the diagnosis of PG. Poor oral hygiene may be the precipitating factor in this case.

DISCUSSION

PG is one of the causes of soft-tissue swelling of the oral cavity that probably results from excessive hyperplasia of the tissue in response to trauma. Low-grade trauma such as chronic irritation due to a sharp tooth or a bad technique of tooth brushing may result in excessive tissue repair response, of which the patient may be unaware. This benign vascular neoplasm usually is a few millimeters in size, presenting as a papule or nodule, although cases with sizes up to a few centimeters have also been reported.[6] The most common sites in the oral cavity for PG are gingiva (61%), lip (14%), tongue (9%), and buccal mucosa (7%).[7] Although PG may occur in all ages, it is predominant in the second decade of life in young adult females, possibly because of the vascular effects of female hormones.[2]

The exact etiology of PG is not known. It was thought to be a botryomycotic infection in the past. At present, the etiopathogenesis of this condition is thought to be related to chronic trauma, which provides a pathway for invasion of the tissue by the non-specific microorganisms that, in turn, provide stimulus for the excessive proliferation of the vascular type of connective tissue. Granulation tissue thus formed may be covered with fibrin over the surface that mimics pus.[8]

Differential diagnosis of PG includes peripheral giant cell granuloma, peripheral ossifying fibroma, hemangioma, peripheral fibroma, leiomyoma, hemangioendothelioma, hemangiopericytoma, bacillary angiomatosis, Kaposi's sarcoma, angiosarcoma, non-Hodgkin's lymphoma, metastatic tumor, post-extraction granuloma, and pregnancy tumor.[9]

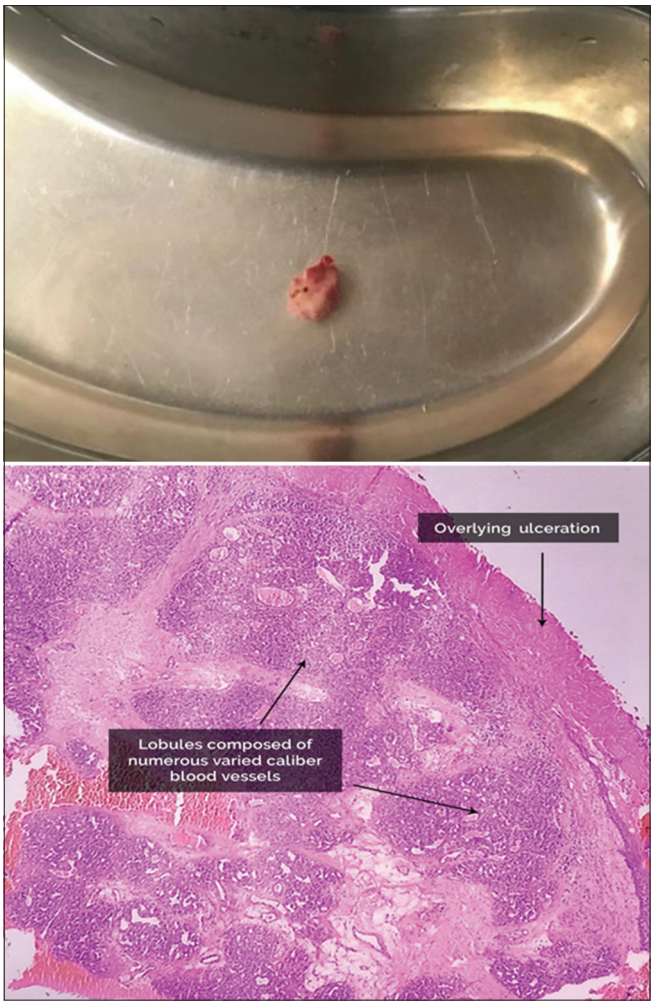

Figure 2: Histopathological examination showing lobules composed of numerous varied caliber blood vessels with an overlying ulceration

The treatment of choice for these lesions is wide surgical resection with margins of 2 mm from its periphery.[4] While treating such lesions, emphasis on maintenance of oral hygiene should be advised; therefore, dental consultation should be obtained when indicated. This benign vascular neoplasm does not undergo malignant transformation, but it can recur occasionally after surgical excision, commonly in gingival sites. Incomplete excision, failure elimination of etiological factors, recurrent trauma, or excessive production of angiogenic factors play a significant role in its recurrence.[10]

CONCLUSION

PG is a benign vascular neoplasm resulting from a hyperactive tissue repair response. It may have an unusual presentation, posing a diagnostic dilemma to the treating surgeon. Proper management including diagnosis, treatment, and further prevention is very important. HPE confirms the diagnosis and rules out various soft-tissue lesions with

similar appearance. Surgical excision is the treatment of choice. Recurrence is not uncommon in some cases and reexcision is necessary. PG as a benign tumor should be kept as a differential diagnosis of the masses on the lateral border of tongue in middle- and old-aged patients.

REFERENCES

1. Available from: https://www.issva.org/UserFiles/file/ISSVA-Classification-2018.pdf. [Last accessed on 2021 Jan 25].
2. Jafarzadeh H, Sanatkhani M, Mohtasham N. Oral pyogenic granuloma: A review. J Oral Sci 2006;48:167-75.
3. Buchner A, Shnaiderman A, Vared M. Pediatric localized reactive gingival lesions: A retrospective study from Israel. Pediatr Dent 2010;32:486-92.
4. Gomes SR, Shakir QJ, Thaker PV, Tavadia JK. Pyogenic granuloma of the gingiva: A misnomer? A case report and review of literature. J Indian Soc Periodontol 2013;17:514-9.
5. Croton E, Kale U. Midline pyogenic granuloma of the tongue: Two case studies. Eur Arch Otorhinolaryngol 2003;260:565-7.
6. Arunmozhi, U, Priya S, Kadhiresan R, Sujatha G, Shamsudeen SM. A large pregnancy tumor of tongue-a case report. J Clin Diagn Res 2016;10:ZD10-2.
7. Angelopoulus AP. Pyogenic granuloma of the oral cavity: Statistical analysis of its clinical features. J Oral Surg 1971;29:840-7.
8. Kamal R, Dahiya P, Puri A. Oral pyogenic granuloma: Various concepts of etiopathogenesis. J Oral Maxillofac Pathol 2012;16:79-82.
9. Amirchaghmaghi M, Farnaz F, Nooshin M, Mozafari PM. Extragingival pyogenic granuloma: A case report. Cases J 2008;1:371.
10. Dghoughi S, Elwady W. Pyogenic granuloma (botryomycoma) of the tongue. Indian J Dent 2012;5:1-4.

How to cite this article: Dev S, Vigneshwar RK, Pasunuti S, Balaje R. Pyogenic Granuloma of Tongue in a Middle-aged Patient – A Rare Case Report. Int J Sci Stud 2021;9(1):1-3.

Source of Support: Nil, **Conflicts of Interest:** None declared.

Print ISSN: 2321-6379
Online ISSN: 2321-595X

Case Report

Odontogenic Keratocyst in Posterior Mandible: A Case Report

Prabhat Kumar Soni[1], Bharat Choudhary[2], Vartika Vashistha[3], Pooja Sinha[4]

[1]Assistant Professor, Department of Oral and Maxillofacial Surgery, Guru Gobind Singh College of Dental Sciences and Research Centre, Burhanpur, Madhya Pradesh, India, [2]Assistant Professor, Department of Conservative Dentistry and Endodontics, Guru Gobind Singh College of Dental Sciences and Research Centre, Burhanpur, Madhya Pradesh, India, [3]Assistant Professor, Department of Paediatric and Preventive Dentistry, Guru Gobind Singh College of Dental Sciences and Research Centre, Burhanpur, Madhya Pradesh, India, [4]Student, Department of Conservative Dentistry and Endodontics, People Dental Academy, Bhanpur, Bhopal, Madhya Pradesh, India

Abstract

Odontogenic keratocyst (OKC) is a common developmental odontogenic cyst affecting the maxillofacial region that arises from the dental lamina. The OKC is distinctive among jaw cysts and has tendency toward recurrence along with aggressive clinical behavior. The recurrent rate of OKC is 25–30%. The following is an article of a case report of a 26-year-old male who presented with OKC involving right mandibular molar tooth region.

Key words: Carnoy's solution, Keratocyst, Marsupialization, Odontogenic

INTRODUCTION

Odontogenic cysts are the most common form of cystic lesions affecting the maxillofacial region. They are classified traditionally into a developmental group, including keratocysts and dentigerous cysts, and an inflammatory group, including radicular cysts.[1] The odontogenic keratocyst (OKC) was first described by Philipsen (1956), is now designated by the World Health Organization as, a keratocystic odontogenic tumor (KCOT).[2] It is defined as "a benign uni or multicystic, intraosseous tumors of odontogenic origin, with a characteristic lining of parakeratinized stratified squamous epithelium and potential for aggressive, infiltrative behaviors."[3] The percentage of OKCs versus other cysts of the jaws as given by different authors are as follows:[4] Hjorting-Hansen *et al.* (1969)[5] and Toller (1972)[6] as 11%; Brannon (1976)[7] and Payne (1972)[8] as 9%; and Pindborg and Hansen (1963)[9] as 7%. Growth is chiefly in the anteroposterior dimension, and the lesions may attain remarkable size without significantly deforming the jaw skeleton. The particular tendency to rapid growth is due to the higher activity of the epithelial cells of the cyst lining, stimulating osteolytic activity of prostaglandin substances in the cell population of the cyst lining, and the higher accumulation of hyperkeratotic scales in the lumen of the cyst, resulting in greater difference in hydrostatic pressure.[10]

Access this article online

www.ijss-sn.com

Month of Submission : 02-2021
Month of Peer Review : 03-2021
Month of Acceptance : 03-2021
Month of Publishing : 04-2021

CASE REPORT

A 26-year-old male patient reported to the Department of Oral and Maxillofacial Surgery, Guru Gobind Singh College of Dental Sciences and Research Centre, Burhanpur (Madhya Pradesh), with the chief complaint of swelling in lower right side of face for the past 4 months. There was no history of any trauma or discharge. A medical history revealed that there was no systemic illness present. There was no history of any deleterious habit such as smoking, tobacco or betel nut chewing, and alcohol, when asked for personal history.

The extraoral examination of the patient revealed diffuse swelling on lower right side of face, that is, approx. 2 cm × 3 cm in size extending anteriorly from right parasymphysis region to the angle of the mandible posteriorly, superiorly, it extended from ala tragus line and inferiorly up to lower border of mandible [Figure 1]. On palpation, it was hard

Corresponding Author: Dr. Prabhat Kumar Soni, Department of Oral and Maxillofacial Surgery, Guru Gobind Singh College of Dental Sciences and Research Centre, Burhanpur, Madhya Pradesh, India.

in consistency, non-tender, non-fluctuant, and a febrile to touch.

Intraoral examination revealed that there was obliteration of buccal vestibule wrt. 45, 46, and 47 teeth region, surrounding mucosa was reddish in color [Figure 2]. On palpation, it was hard in consistency, non-tender and no discharge was present. On aspiration, straw-colored fluid was present. With the above clinical finding, provisional diagnosis of OKC wrt. 45, 46, and 47 tooth region with differential diagnosis of unicystic ameloblastoma was made.

The panoramic radiograph (orthopantomogram) showed a well-defined unilocular radiolucency wrt. 44 to 48 tooth region with well-demarcated borders and thinning of cortical bone along with cortical expansion in body region. Furthermore, impacted 45 with resorption of root was noted wrt 46 and 47 [Figure 3]. Radiographic diagnosis of OKC was made along with differential diagnosis of unicystic ameloblastoma and dentigerous cyst. The panoramic radiograph (OPG) showed formation of bone over the inferior border of mandible [Figure 4]. After taking the informed consent of the patient, marsupialization was done under local anesthesia. Under local anesthesia, through intraoral incision, the full-thickness mucoperiosteal flap was raised. Enucleation of the lesion and removal of the involved teeth were accomplished [Figures 5 and 6]. Then, peripheral ostectomy of the whole surgical bed was completed followed by a single application of Carnoy's solution. The thinned out inner cortical lining of the bone was removed. The cheesy material and cystic lesion were sent for histopathologic examination [Figures 7 and 8]. Finally, the wound closure was done with 3-0 mursilk suture [Figure 9].

Figure 1: Extraoral swelling extending anteroposteriorly from corner of mouth to angle of mandible and superoinferiorly from tragus to inferior border of mandible

Figure 2: Intraoral swelling w.r.t. 44–46 tooth region

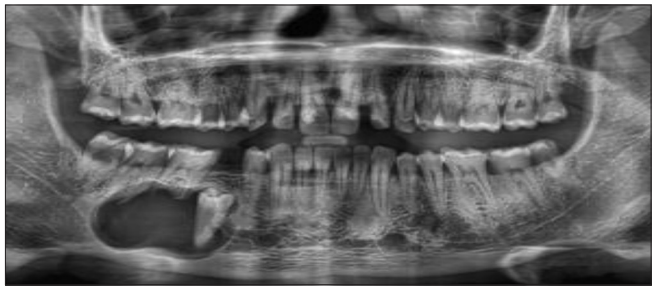

Figure 3: Panoramic radiograph showing unilocular radiolucency along with impacted 45

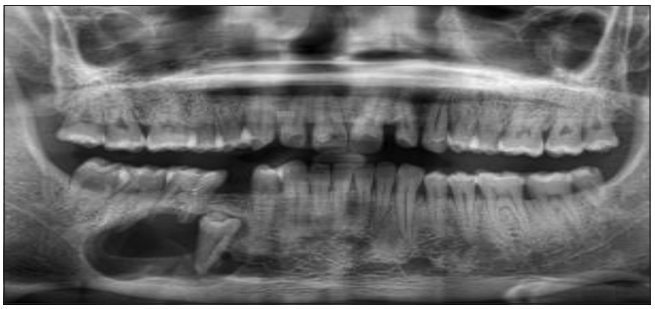

Figure 4: Panoramic radiograph showing formation of bone over the inferior border post marsupialization

Figure 5: Keratin removal

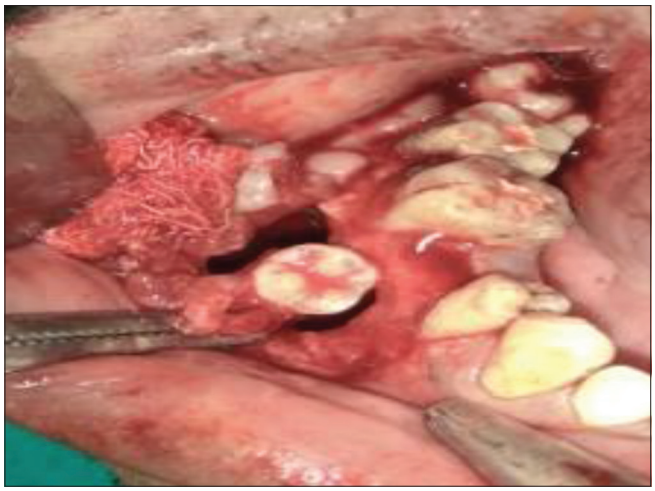

Figure 6: Removal of impacted tooth

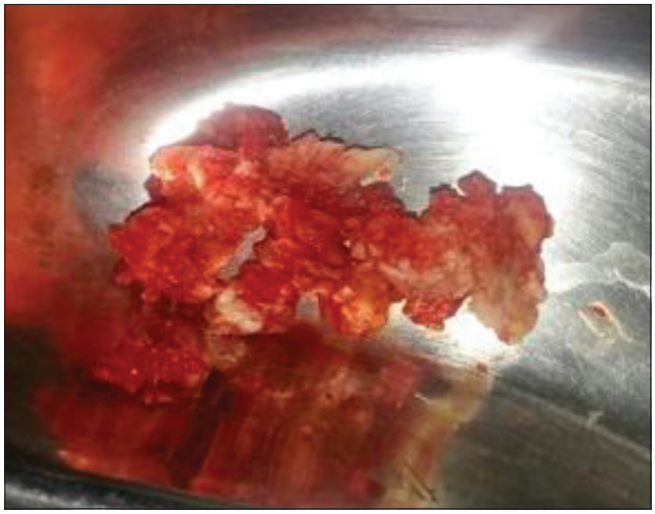

Figure 7: Complete removal of keratin

Histopathological examination of specimen revealed a cystic lining with orthokeratin layer, stratified squamous cells of 6–8 cell thickness, no daughter cyst, or epithelial detachment was found. The basal layer was composed of palisaded layer of cuboidal cells with hyperchromatic nucleus. The overall features were suggestive of OKC. Henceforth, the final diagnosis of OKC wrt. 45, 46, and 47 tooth region was made.

DISCUSSION

The OKC is a unique and prevalent clinical and histologic lesion with aggressive nature. It usually arises in the dental lamina, but some suggest a probable origin from basal cell component.[11] About 70% or more cases involve the mandible, especially in the third molar, angle, and ramus areas. Next, most common site of occurrence is the maxillary third molar followed by mandibular premolar and maxillary canine region.[12] There are few factors which led to recharacterization of the keratocyst as KCOT.[3] The KCOT

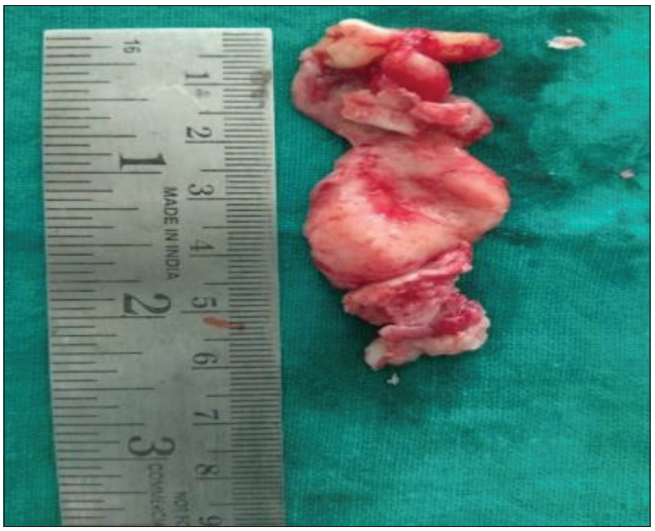

Figure 8: Cystic lining post-enucleation

Figure 9: Suturing and wound closure

exhibits locally destructive and highly recurrent behavior and is characterized by parakeratinized epithelium, in contrast to the orthokeratinized variant seen in OKC. KCOT reveals budding of the basal layer into the connective tissue and frequent mitotic figures. Furthermore, they are associated with inactivation of PTCH, the tumor suppressor gene.

Radiographically, OKC presents predominantly as a unilocular radiolucency with well-developed sclerotic borders. They may also present as a multilocular radiolucency with a ratio of unilocular to multilocular varying from 3:112 to 1:1.3. Multiple keratocysts are frequently associated with the bifid rib basal cell nevus syndrome (Gorlin syndrome).[13] Differential diagnosis includes dentigerous cyst (in OKC, the cyst is connected to the tooth at a point apical to cementoenamel junction), ameloblastoma (usually multilocular, no straw-colored

fluid on aspiration), traumatic cyst (unilocular with scalloped margins, rarely show cortical expansion), giant cell granuloma (usually in anterior region of jaw), and odontogenic myxoma.[14]

Treatment modalities for OKC include a conservative approach that is marsupialization and decompression which lead to ultimate complete resolution of the cystic lesion. They are preferred to preserve bone, teeth, and preventing damage to other vital structures, also for decreasing the chances of pathologic fracture. The principle behind these procedures is to decrease the cystic osmotic pressure by exposing it to the surrounding oral cavity. It is helpful in a bone deposition at the periphery of the lesion and also a progressive reduction in the cyst size.[15] Other treatment modalities are extensive surgeries, *en bloc*, and segmental resection.[16]

Two-step procedure in the management of OKCs is decompression which involves the placement of a surgical drainage tube, the following enucleation after the cyst has reduced to a manageable size. Enucleation is the complete and intact removal of a cystic lesion by surgically husking it from the surrounding tissues. About 17–56% of the recurrence rate of enucleation has been reported. Because of this, many surgeons prefer a combination of enucleation and adjunctive therapies to eliminate any residual cyst lining and islands within the cyst wall. Adjunctive therapy includes the application of Carnoy's solution which destroys cyst remnants using chemical cautery, intended to reduce recurrence rates.[17,18] It is often used as a complementary treatment of lesions such as the KCOT and is composed of 3 ml of chloroform, 6 ml of absolute ethanol, 1 ml of glacial acetic acid, and 1 g of ferric chloride.[18]

OKC has a particular tendency to recur after surgical treatment. The first to point out this peculiarly aggressive behavior was Pindborg and Hansen (1963).[9] Recurrence is encountered more often in mandibular OKC, particularly those in the posterior body and ascending ramus.[17] A total of 18% reduction in the recurrence potential is noted, when both combination of enucleation with adjunctive treatment are performed.[19]

CONCLUSION

KCOT has been identified as a "tumor" after observation of its biological behavior and genetic abnormalities consistent with neoplastic progression. This case report of OKC was noticed in a 26-year-old male patient on the right side of mandible showing the clinical and radiographic presentation, diagnosis, treatment, and follow-up. Research is still going on appropriate treatment modalities for OKCs because of it is genetic and molecular basis of pathogenesis. Surgeons should thoroughly examine each case individually and should provide better treatment options to the patients.

REFERENCES

1. Yazdani J, Kahnamouii SS. Developmental odontogenic cysts of Jaws: A clinical study of 245 cases. J Dent Res Dent Clin Dent Prospect 2009;3:64-6.
2. Philipsen HP. Om keratocyster (kolesteatom) i kaeberne. Tandlaege Bladet 1956;60:963-81.
3. Madras J, Lapointe H. Keratocystic odontogenic tumour: Reclassification of the odontogenic keratocyst from cyst to tumour. J Can Dent Assoc 2008;74:165-h.
4. Langland OE, Langlais RP. Diagnostic Imaging of Jaws. 2nd ed. Baltimore: Williams and Wilkens; 1995.
5. Hjorting-Hansen, Andreasen JO, Robinson LH. A study of odontogenic cyst, with special reference to location of keratocyst. Br J Oral Surg 1969;7:15-23.
6. Toller PA. Newer concepts of odontogenic cysts. Int J Ora Surg 1972;1:3-16.
7. Brannon RB. The odontogenic keratocyst. A clinicopathologic study of 312 cases. Part 1. Clinical features. Ora Surg Ora Med Ora Pathol 1976;42:54-72.
8. Payne TF. An analysis of the clinical and histopathologic parameters of the odontogenic keratocyst. Ora Surg Ora Med Ora Pathol Endod 1972;33:538-46.
9. Pindborg JJ, Hansen J. Studies on odontogenic cyst epithelium. 2. Clinical and roentgenologic aspects of odontogenic keratocysts. Acta Pathol Microbiol Scand 1963;58:283-94.
10. Haring JI, van Dis ML. Odontogenic keratocysts: A clinical, radiographic, and histopathologic study. Oral Surg Oral Med Oral Pathol 1988;66:145-53.
11. Neville BW. Oral and Maxillofacial Pathology. 3rd ed. St. Louis: Mosby, Elsevier; 2009.
12. Khalam AS, Zacariah RK. Under diagnosis of an odontogenic keratocyst-a controversial lesion. IOSR J Dent Med Sci 2012;2:37-40.
13. Karandikar S, Nilesh K, Dadhich A. Large odontogenic keratocyst of mandible: A case report. JIDA 2011;5:822-4.
14. Garg S, Sunil MK, Trivedi A, Singla N. Odontogenic keratocyst of the angle and ramus of the mandible-a case report. J Dent Spec 2015;3:195-8.
15. Almeida P Jr., Cardoso LC, Garcia IR Jr., Magro-Filho O, Luvizuto ER, Felipini RC. Conservative approach to the treatment of keratocystic odontogenic tumor. J Dent Child (Chic) 2010;77:135-9.
16. Kshirsagar RA, Bhende RC, Raut PH, Mahajan V, Tapadiya VJ, Singh V. Odontogenic keratocyst: Developing a protocol for surgical intervention. Ann Maxillofac Surg 2019;9:152-7.
17. Shetty A, Nagaraj T, Irugu K, Kale S. Keratocystic odontogenic tumor-a case report and review of literature. Int J Med Dent Case Rep 2016;2:1-4.
18. Sivanmalai S, Kandhasamy K, Prabu N, Prince CN, Prabu CS. Carnoy's solution in the mangement of odontogenic keratocyst. J Pharm Bioallied Sci 2012;4 Suppl 2:S183-5.
19. Shear M. The aggressive nature of the odontogenic keratocyst: Is it a benign cystic neoplasm? Part 1. Clinical and early experimental evidence of aggressive behaviour. Oral Oncol 2002;38:219-26.

How to cite this article: Soni PK, Choudhary B, Vashistha V, Sinha P. Odontogenic Keratocyst in Posterior Mandible: A Case Report. Int J Sci Stud 2021;9(1):4-7.

Source of Support: Nil, **Conflicts of Interest:** None declared.

Print ISSN: 2321-6379
Online ISSN: 2321-595X

Case Report

A Rare Case of Bilateral Electric Cataract Post High-Voltage Electric Injury

Prashant Kumar, Reena Kumari, Dinesh Kumar Bhagat, Soumya Shashi, Sumit Randhir Singh

Senior Resident, Department of Ophthalmology, Mata Gujri Memorial Medical College and L.S.K Hospital, Kishanganj, Bihar, India

Abstract

Electric burn-related injury occurs when high-voltage electric current passes through the human body with the extent of injury depending on intensity and duration of electric current. High-voltage shock can cause deeper injury to the internal organs. Ocular complications result from electric injury to head, neck, or scalp region with cataract being the most common ocular manifestation. We report a case of bilateral cataract after 8 months of injury with high-voltage electric current. Both entry and exit wound on scalp and foot, respectively, were discernible. The patient underwent phacoemulsification and foldable intraocular lens implantation with good post-operative outcome.

Key words: Electric cataract, Electric injury, Phacoemulsification

INTRODUCTION

Electric current-related injuries present with a variety of ocular manifestations. Most common complication is bilateral cataract formation, whereas others such as corneal opacity, uveitis, anisocoria, macular edema, macular cyst, macular hole, chorioretinal atrophy, and retinal detachment are also known to occur. The exact pathogenesis of cataract formation is not well understood with coagulation of lens protein proposed as the main mechanism.[1] It takes several days to months to develop cataract after electrical injury.[1,2] Here, we report a case of high-voltage electric injury in a young male who developed bilateral cataract.

CASE REPORT

A 25-year-old male came to our eye clinic 8 months following electric injury with high-tension wire (11,000 volts) falling over his head. Chief ocular complaints of gradual, painless, progressive diminution of vision in the left eye were elicited. On general examination, there was circular raw area with superficial burn of entry wound on scalp and angle of mouth [Figure 1a]. An exit wound was seen in the right foot with amputated little toe [Figure 1b].

There was a history of the right eye cataract extraction with posterior chamber intraocular lens (PCIOL) elsewhere 3 months back. On ocular examination, best-corrected visual acuity (BCVA) of the right eye was 6/9, N/6 and in the left eye hand movements close to face with accurate projection of rays in all quadrants. Both pupils were round, regular, and reactive. Slit-lamp examination showed mature cataract in the left eye [Figure 2a]. On fundoscopic examination of the right eye media was clear, disc margin was well defined with cup-to-disc ratio of 0.4, and the foveal reflex was well made out. The left eye ultrasound B scan revealed attached retina with anechoic vitreous cavity.

Routine blood investigations were unremarkable. Ocular biometry was within normal limits with an intraocular lens power of +23D. Subsequently, the left eye phacoemulsification with foldable PCIOL implantation under peribulbar anesthesia was performed. Postoperatively, BCVA was 6/6 at 1 month follow-up [Figure 2b].

DISCUSSION

High-voltage electrical burn and injury are known to cause many ocular complications such as corneal opacity, uveitis,

Access this article online

www.ijss-sn.com

Month of Submission : 02-2021
Month of Peer Review : 03-2021
Month of Acceptance : 03-2021
Month of Publishing : 04-2021

Corresponding Author: Dr. Sumit Randhir Singh, Department of Ophthalmology, Mata Gujri Memorial Medical College and L.S.K Hospital, Kishanganj, Bihar, India.

Figure 1: (a) Facial profile showing entry wound site on scalp and angle of mouth (yellow arrows). (b) Exit wound was seen at area of little toe which underwent amputation due to necrosis post-electric injury

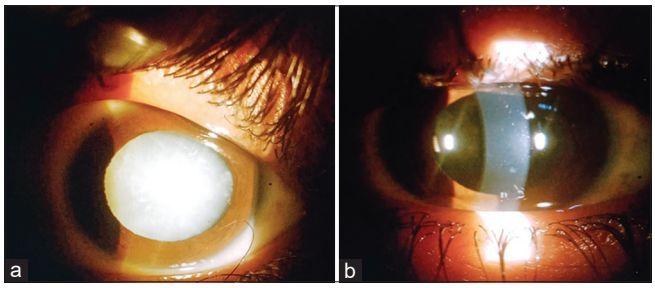

Figure 2: (a) Pre-operative and post-operative slit-lamp photograph showing total cataract and (b) posterior chamber intraocular lens

anisocoria, macular edema, macular cyst, macular hole, chorioretinal atrophy, and retinal detachment. Cataract formation is the most commonly seen ocular finding in eyes with electric injuries and may take month to year to develop cataract.[1-3] The incidence of electrical cataract ranges from 0.7% to 8.0%.[4] The type of cataract and rate of progression vary from patient to patient. In a subset, the cataract may remain stationary for a long period, whereas in another group, there may be progression to mature cataract within months.

The presence of an entry and exit wound made the diagnosis of electric cataract likely especially considering the young age of the patient.

CONCLUSION

Prompt diagnosis and timely surgical intervention in eyes with cataract related to electric injury helps in good visual outcomes and early visual rehabilitation.

REFERENCES

1. Saffle JR, Crandall A, Warden GD. Cataracts: A long-term complication of electrical injury. J Trauma 1985;25:17-21.
2. Baranwal VK, Satyabala K, Gaur S, Dutta AK. A case of electric cataract. Med J Armed Forces India 2014;70:284-5.
3. Boozalis GT, Purdue GF. Ocular changes from electrical burn injuries. A literature review and report of cases. J Burn Care Rehabil 1991;12:458-62.
4. Duke-Elder S, MacFaul PA. Injuries: Non-mechanical injuries. In: Duke-Elder S, editor. System of Ophthalmology. Vol. 14. London: Henry Kimpton; 1972. p. 813-35.

How to cite this article: Kumar P, Kumari R, Bhagat DK, Shashi S, Singh SR. A Rare Case of Bilateral Electric Cataract Post High-Voltage Electric Injury. Int J Sci Stud 2021;9(1):8-9.

Source of Support: Nil, **Conflicts of Interest:** None declared.

Print ISSN: 2321-6379
Online ISSN: 2321-595X

Review Article

Fat in Disguise – Mask Unleashed on Breast Imaging

Harini Gnanavel[1], Bhawna Dev[2], Leena Dennis Joseph[3], Pavithra Vittalraj[4], Sheela Chinnappan[1], Priya Palanisamy[1], Venkata Sai Pulivadula Mohanarangam[2]

[1]Senior Resident, Department of Radiology, Sri Ramachandra Institute of Higher Education and Research Centre, Chennai, Tamil Nadu, India, [2]Professor, Department of Radiology, Sri Ramachandra Institute of Higher Education and Research Centre, Chennai, Tamil Nadu, India, [3]Professor, Department of Pathology, Sri Ramachandra Institute of Higher Education and Research Centre, Chennai, Tamil Nadu, India, [4]Assistant Professor, Department of Pathology, Sri Ramachandra Institute of Higher Education and Research Centre, Chennai, Tamil Nadu, India

Abstract

Fat-containing lesions of the breast are a heterogeneous group of conditions and are predominantly benign tumors. Fat necrosis of the breast is a non-suppurative benign inflammatory condition of the adipose tissue that can be mistaken for cancer during a clinical examination or imaging studies as it progresses through various stages of pathological transformation. Injury to breast tissue is the cause for this condition and the sources include blunt trauma, procedure surgeries, and radiation. The clinical symptoms and radiological findings can mimic malignancy and hence precise history is a key feature that points to the diagnosis. The imaging features of fat necrosis may vary depending on the stage of evolution. Mammogram can either be normal, show asymmetry, malignant features or may present as a straightforward oil cyst. Ultrasound can be normal or show inflammatory changes, dilated ducts, or malignant characteristics. Magnetic resonance imaging is not the modality of choice for fat necrosis unless a diagnostic confusion of malignancy or recurrence occurs. Hence, in-depth knowledge of the various imaging features during different phases can help in diagnosing fat necrosis. However, histopathology remains a necessity to arrive at a final diagnosis.

Key words: Cytology, Fat necrosis, Histopathology, Mammogram, Ultrasound.

INTRODUCTION

Fat-containing lesions of the breast are a heterogeneous group of conditions and are predominantly benign tumors.[1] Fat necrosis is a benign non-suppurative inflammatory process of the adipose tissue.[2] Previously it was said to result from blunt trauma to the breast. In the present day, with the growing number of surgeries, procedures, and radiation therapy, fat necrosis is being encountered often in routine practice. Fat necrosis has varied imaging appearances from benign to suspicious for malignancy during its many stages of evolution.[3] The spectrum of radiologic manifestations of fat necrosis poses a challenge in diagnosing the condition even with the new diagnostic modalities.[4] Hence, it is important for radiologists to know the accurate history and have knowledge of the various imaging findings to achieve the correct diagnosis and avoid unnecessary interventions.[2] In this article, the various presentations of fat necrosis on imaging with histopathological examination (HPE) correlation are discussed.

Access this article online

www.ijss-sn.com

Month of Submission : 02-2021
Month of Peer Review : 03-2021
Month of Acceptance : 03-2021
Month of Publishing : 04-2021

DISCUSSION

The incidence of fat necrosis is estimated to be 0.6%, accounting for 2.75% of all benign breast lesions.[5] Fat necrosis of the breast is a benign inflammatory process that may be mistaken for cancer in clinical examination or imaging studies. With the growing number of breast surgeries performed today (e.g., breast-conserving, autologous tissue reconstruction, and mammoplasty), fat necrosis is often encountered in daily practice.[6] The mammary gland is a common site for traumas which often leads to the formation of intraglandular hematomas. The abundance of fat tissue in this gland accounts for

Corresponding Author: Bhawna Dev, Grassland Apartments, Mugalivakkam, Chennai - 600 016, Tamil Nadu, India.

the relatively high frequency of fat necrosis and the self-digestion of fat by lipases after traumas.[7] Knowledge of its imaging features could improve clinical management, including the avoidance of unnecessary biopsy procedures.[6]

CLINICAL FEATURES

The presentation can vary from being clinically occult to a hard lump with skin changes highly suspicious for malignancy. A history of accidental trauma raises the suspicion of fat necrosis in a breast lump. However, the absence of a history of trauma does not exclude fat necrosis.[5] Fat necrosis presents as a small, painless, ill-defined breast mass when it becomes palpable. Usually, the palpable abnormality is periareolar and superficial in location, rarely can present with bruising and tenderness, skin tethering, and nipple retraction. These lesions may enlarge, remain unchanged, regress, or resolve over a period of time.[8]

PATHOPHYSIOLOGICAL EVOLUTION OF FAT NECROSIS

Fat necrosis is a sterile, inflammatory process that results from aseptic saponification of fat employing blood and tissue lipase.[9]

In the early phase, fat necrosis appears as an area of hemorrhage in fat, resulting in induration and firmness on gross pathology. On cytology, a newly insulted adipose cell will first lose its nucleus accompanied by degenerative changes in adipocytes with hemorrhage.[5]

After several weeks, the affected area becomes demarcated, forming a distinct yellow (due to saponification) and focally reddish mass. In the intermediate stage of fat necrosis, it is replaced by foamy histiocytes, macrophages, and multinucleated giant cells filled with dead adipose cells. Lesions that do not resolve undergo cystic degeneration, resulting in a cavity that contains oily fluid.[5]

In the late stage over months to years of fat necrosis, calcification develops which is seen as a chalky white lesion, and fibrosis presents as a yellow-gray mass. Finally, scar formation develops due to reactive inflammatory components giving rise to fibrosis. Hemosiderin deposition may be seen and indicates remote hemorrhage. At lower magnification, necrotic material is wrapped by a layer of fibrous tissue. Fibrosis gives the appearance of an irregular spiculated mass due to the retraction of nearby vascularized tissue within 2–4 weeks. Calcification develops within 6–12 months around the lesion.[9] Imaging appearances can mimic malignancy at this stage unless the characteristic benign lucent-centered or rim calcifications are seen on a mammogram.[5]

The varied appearances of fat necrosis on imaging studies are attributed to various amounts of histiocytic infiltration, hemorrhage, fibrosis, and calcification.[8]

Immunohistochemistry with CD 68 is helpful in confirmation of the histiocytic nature of the macrophages. Confusion may arise with invasive lobular carcinoma in areas of extensive fibrosis. In invasive lobular carcinoma, discohesive single cells with small monomorphic nuclei that infiltrate the stroma are seen. Pan Cytokeratin is a very useful marker in these situations, and is a helpful problem-solving tool, and shows uptake by the tumor cells.[10]

The diagnosis can be confirmed based on either serial imaging studies that show chronological changes compatible with the evolution of fat necrosis or improvement in clinical symptoms (lump no longer detectable on palpation). Histological confirmation may be reserved for indeterminate or suspicious imaging features.[5]

Imaging

As mentioned earlier, the imaging appearances of fat necrosis depend on its stage of evolution.[5]

Mammography

Mammographic findings in fat necrosis of the breast include lipid cysts, microcalcifications, coarse calcifications, spiculated areas of increased opacity, asymmetry, and/or focal masses. Fat necrosis manifesting as a clinically palpable mass also may demonstrate no appreciable mammographic finding.

Lipid Cyst

Lipid cysts are pathognomonic of benign fat necrosis. A lipid cyst is a round to oval, smooth-bordered, and lucent mass with a thin rim [Figures 1a-c, 12d, and e]. The fibrous rim of the cyst may or may not calcify.[11] Calcifications are usually smooth and round or curvilinear.[12]

Microcalcifications

Fat necrosis uncommonly manifests as branching, rodlike calcifications, angular, or pleomorphic microcalcifications that are mammographically indistinguishable from those of malignancy.[12]

Spiculated Area of Increased Opacity

If the reparative phase fibrosis replaces all of the necrotic fat, it gives the appearance of an irregular, dense, and spiculated mass which makes it difficult for differentiation from malignancy on a mammogram [Figure 4a-c].[12] Hence, fat necrosis should be included in the differential diagnosis

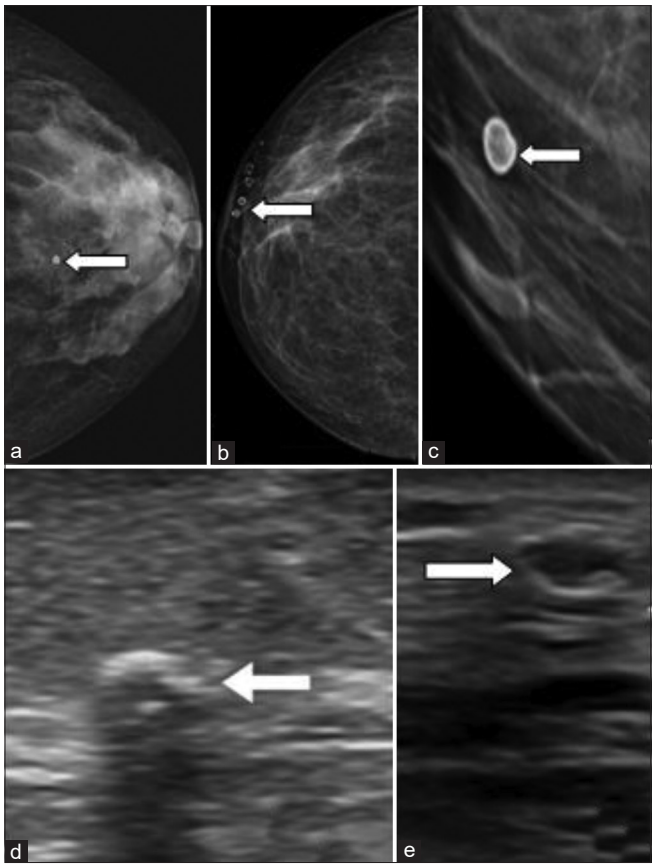

Figure 1: Different patients who came for routine annual checkup. (a and b) X-ray mammogram CC view and (c) zoomed-in view showing oil cysts with rim calcification (arrow). (d and e) Ultrasound images showing oil cyst with peripheral calcification (arrow)

of a spiculated mass in addition to carcinoma, radial scar, and post-biopsy changes.[11]

Focal Mass/Asymmetry

Rarely, fat necrosis manifests as a non-lucent, focal mass [Figures 2b and 7a], or asymmetry [Figure 3b and d] with or without associated macrocalcification. However, the presence of lucent areas within a mass representing fat [Figure 4a-c] suggests that the lesion is almost always benign.

Ultrasound (US)

Similar to mammogram, US of fat necrosis shows a gamut of imaging findings that can appear benign or malignant. Virtually all the cases have findings on US, inclusive of those cases with a normal mammogram. Hence, US plays an important role in excluding malignancy and suggesting fat necrosis as the diagnosis.

US features that are relatively reliable predictors of benignity include hyperechogenicity, well-defined margins, and parallel orientation. Lack of color flow on Doppler is an additional feature; however, it is

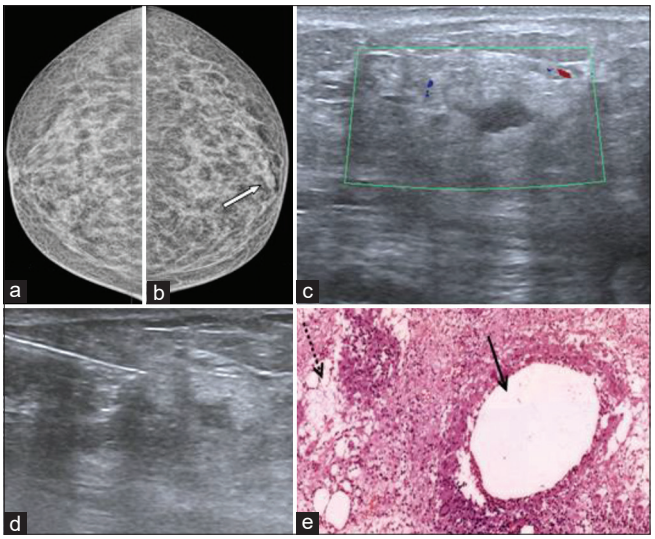

Figure 2: A 65-year-old female with a history of pain in the left retro areolar region breast with no other specific history X-ray mammogram CC view (a) Right breast with no abnormality (b) Left breast shows a subcentimeter irregular high-density nodularity in the subareolar region (arrow) (c) Ultrasound with color Doppler shows an irregular parallelly oriented circumscribed hyperechoic mass with central cystic changes with combined posterior features and absent vascularity. (d) Ultrasound-guided tru-cut biopsy of the mass (e) H & E: Chronic Mastitis with focal cystic change (Black Arrow) and adjacent fat necrosis (Dotted Arrow) ×100

not a reliable discriminator. Some malignant and indeterminate features in the US constitute an indistinct border with anechoic areas within, irregular shape, taller-than-wide morphology, and posterior acoustic shadowing.

Fat is interspersed in between the fibroglandular tissue in the deeper layer of breast parenchyma. Hence, one needs to be prudent and careful while encountering a hyperechoic nodule in the deeper tissue planes.[5]

The common presentation that we see on a daily routine is a well-defined hypoechoic lesion with peripheral echogenic calcific rim representing an oil cyst [Figures 1d, e and 12f]. An echogenic band within an oil cyst that shifts in orientation with changes in patient position is the most specific feature of fat necrosis.[5]

Other features that we encounter in US include solid hypoechoic [Figures 4a and 10a and b]/isoechoic/hyperechoic masses [Figures 6a and b and 10a] with posterior acoustic shadowing or enhancement, causing architectural distortion of the parenchyma, hyperechoic masses with cystic areas [Figures 2c, 3e, 7b and c] to complex intracystic masses with a mural nodule [Figure 5e], echogenic bands. These features illustrate the histological evolution of fat necrosis.[10]

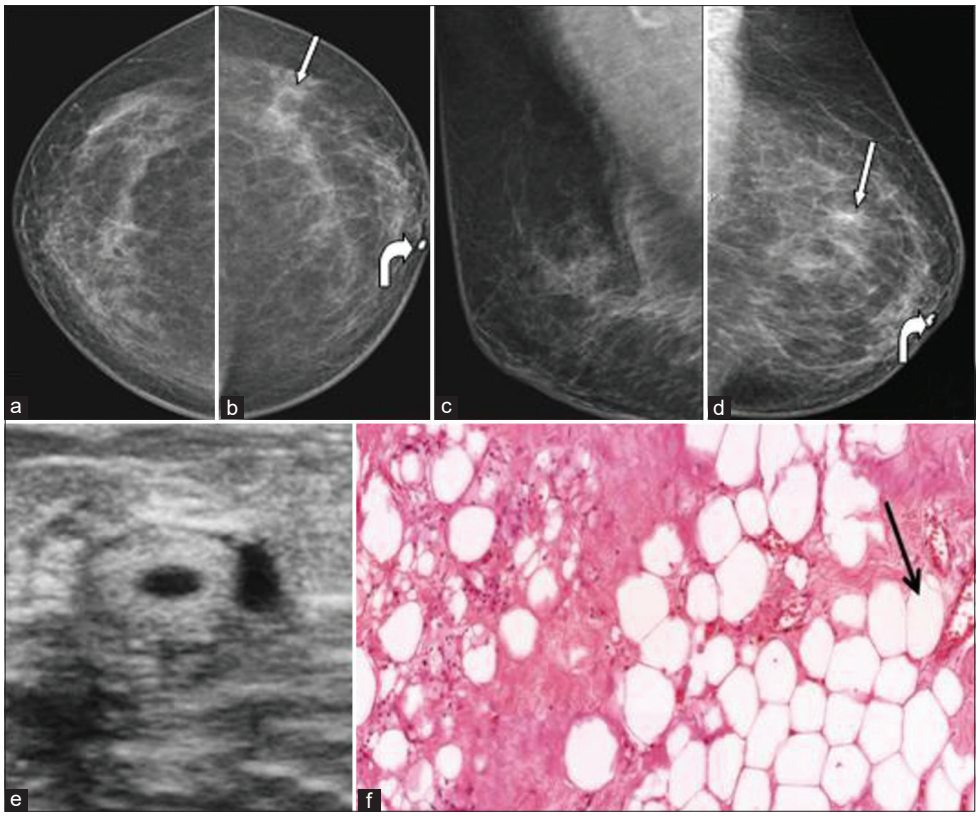

Figure 3: A 48-year-old female with complaints of focal pain in the outer half of the left breast for 1 year, exaggerated for 1 month with no history of trauma. X-ray mammogram (a and c) of the right breast (CC and MLO view) with no abnormality and b&d left breast (CC and MLO view) shows focal asymmetry (straight arrow) in the upper outer quadrant, benign focal round calcification (curved arrows) in the retroareolar region (e) ultrasound image shows an oval parallelly oriented circumscribed hyperechoic mass with central cystic component. (f) H&E: Fibroadipose tissue with focal necrosis of adipocytes (Black Arrow) ×200

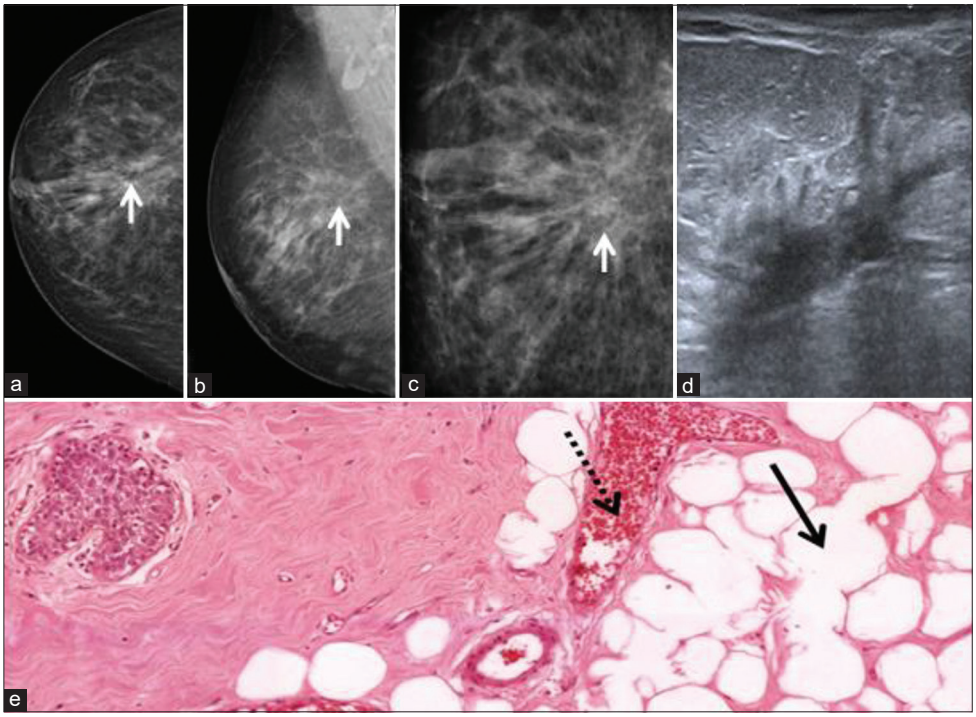

Figure 4: A 58-year-old female with complaints of pain in the right breast for 1 year, history of surgery in the same breast 3 years before for a benign condition. X-ray mammogram of right breast (a) CC view showing speculations and architectural distortion with fat lucencies (white arrow) suggestive of post-operative scaring and (b) MLO view and (c) Spot magnification view shows the speculations are spread out with interspersed fat lucencies (white arrow). (d) Ultrasound image showing an irregular, spiculated, hypoechoic mass with combined posterior features. (e) H&E: Fat necrosis (solid arrow) with adjacent congested vessels (Dotted Arrow) - ×200

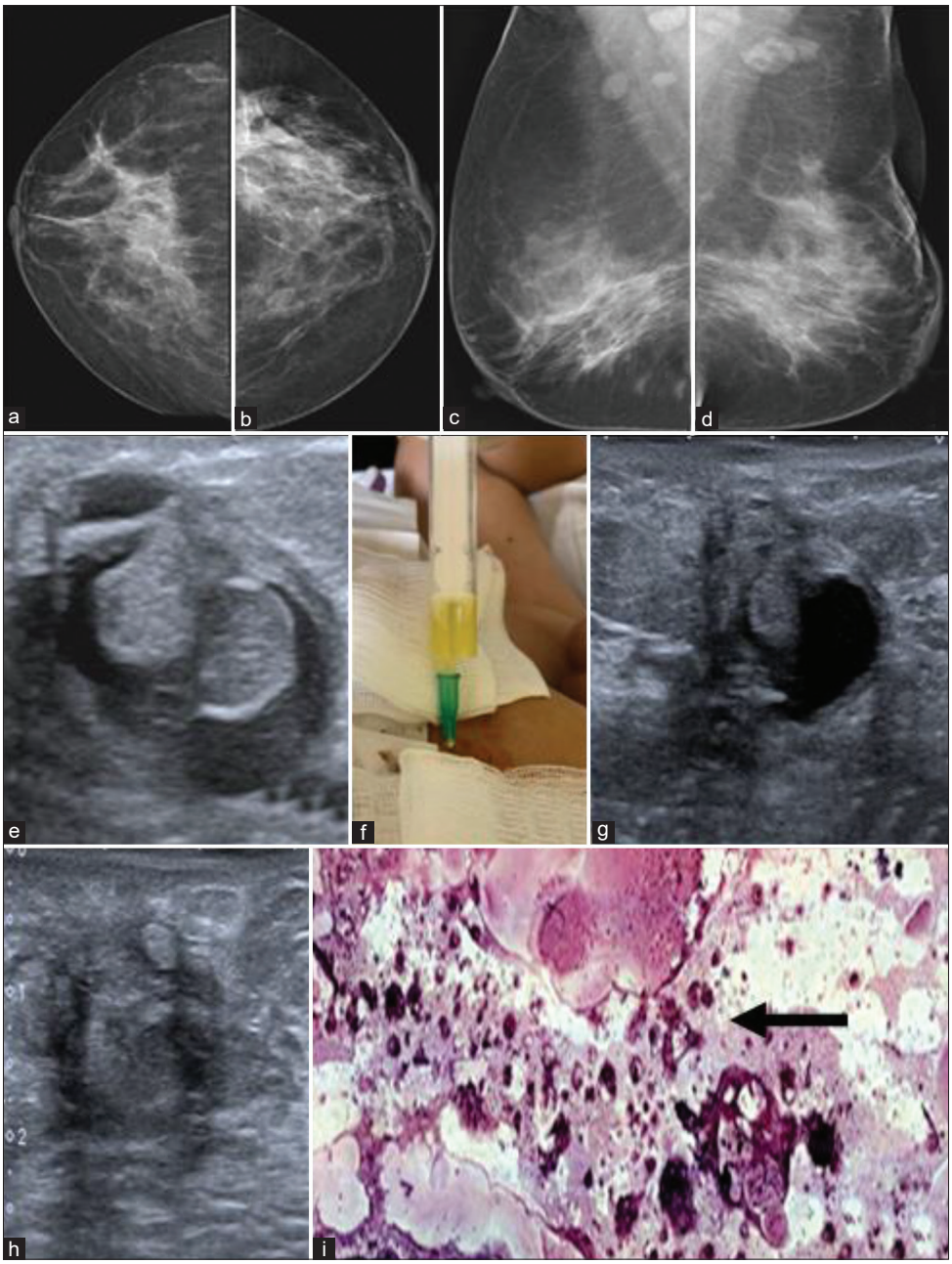

Figure 5: A 46-year-old female post-operative case of phyllodes tumor – 18 months, came for a routine check-up with no specific complaints. X-ray mammogram (a and c) CC and MLO view of the right breast shows no abnormality and (b and d) CC and MLO view of the left breast shows architectural distortion involving the upper outer quadrant with adjacent skin retraction (e) ultrasound image shows an oval parallel oriented circumscribed anechoic mass with few hyperechoic areas within (g) shows image of fine-needle aspiration of the mass with thick yellow oily fluid being aspirated. (h) Post-aspiration image showing complete resolution of the cystic mass. (i) Cytology: H & E: Showing fat necrosis (Black Arrow) ×200

Hyperechoic masses very rarely personify a malignancy and are reported in <0.8% of tumors.[12] Although rare, malignant hyperechoic lesions include invasive ductal and lobular carcinoma, lymphoma, angiosarcoma, and liposarcoma.[10]

In our article, we present few cases of fat necrosis that have a unique presentation of multiple irregularly dilated ducts showing thick internal echoes with surrounding inflammation [Figures 8a and b, 9b]. Some cases had associated features of skin thickening. Most of these cases demonstrated normal X-ray mammogram except for focal skin thickening [Figure 9a] in one case. HPE correlation of these cases unveiled the appearance of fat necrosis.

A case report by Coyne shows that intraductal fat necrosis can occur due to the displacement of fatty tissue into the ducts following prior needling. This form of fat necrosis is termed as membranous intraductal fat necrosis. Although this is a rare entity, we need to keep this into consideration

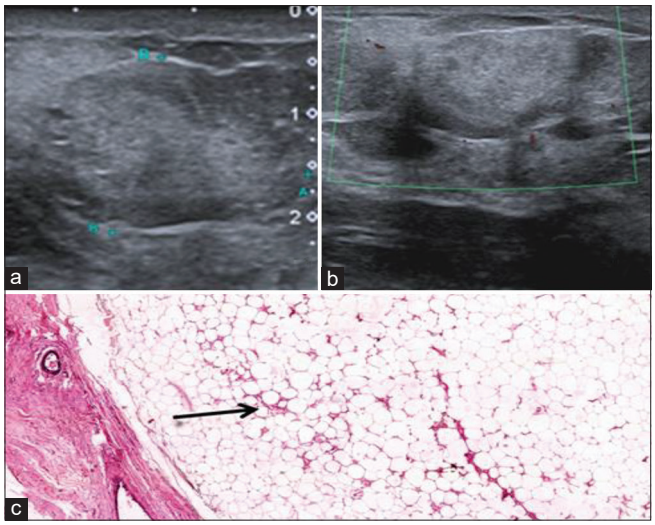

Figure 6: A 37-year-old female with complaints of a lump in the breast for 8 months. (a and b) Ultrasound and color Doppler image show an oval, parallel oriented, circumscribed, hyperechoic mass with few cystic changes at the periphery (arrows) with no posterior features or vascularity. (c) H & E: Well circumscribed mass with adipocytes showing fat necrosis (Black Arrow) ×100

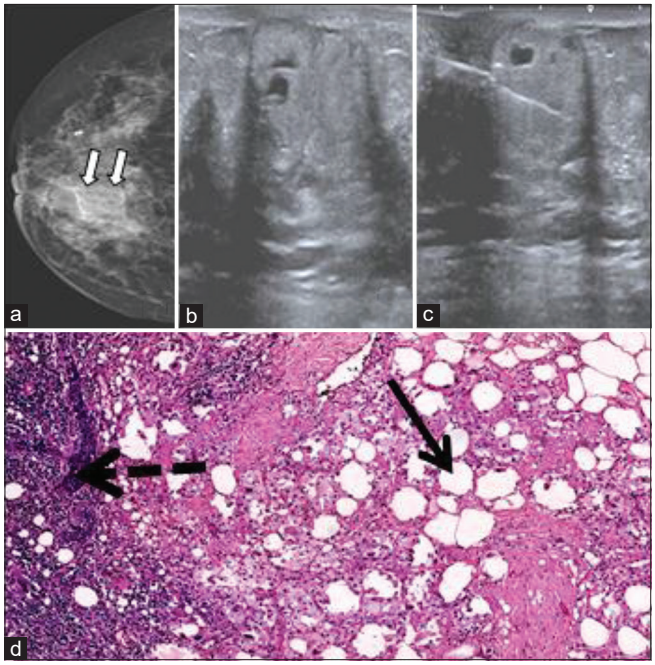

Figure 7: A 43-year-old female with a history of a lump in the right breast for 6 months. (a) X-ray mammogram CC view shows an irregular indistinct equal density mass (arrows). Two specks of benign round calcification noted in outer quadrant. (b) Ultrasound image shows an oval parallel oriented circumscribed predominantly hyperechoic mass with cystic changes and no obvious posterior features. (c) Ultrasound-guided biopsy image of the same mass (d) H&E: Lymphocytic mastopathy (Dotted Arrow) with adjacent fat necrosis (black arrow) ×200

when fat necrosis within a dilated duct is seen and ask for a history of the previous procedure.[13]

The proposed follow-up of probably benign USG lesions is to do a diagnostic mammogram and/or US

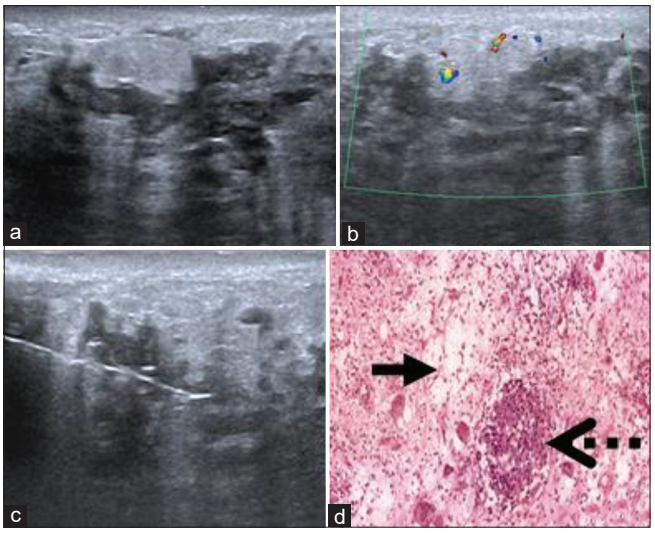

Figure 8: A 31-year-old female with a history of skin changes 1 week and progressive hardness of breast 4 months. (a) Ultrasound image shows multiple dilated ducts with thick internal echoes seen within. (b) Color Doppler image shows vascularity within the adjacent parenchyma- probable diagnosis of idiopathic granulomatous mastitis was made. (c) Ultrasound-guided biopsy of the mass. Multiple biopsy cores were obtained from within and periphery of the abnormal ducts. (d) H &E: Granulomatous lesion (Dotted Arrow) with adjacent fat necrosis (Black Arrow) ×200

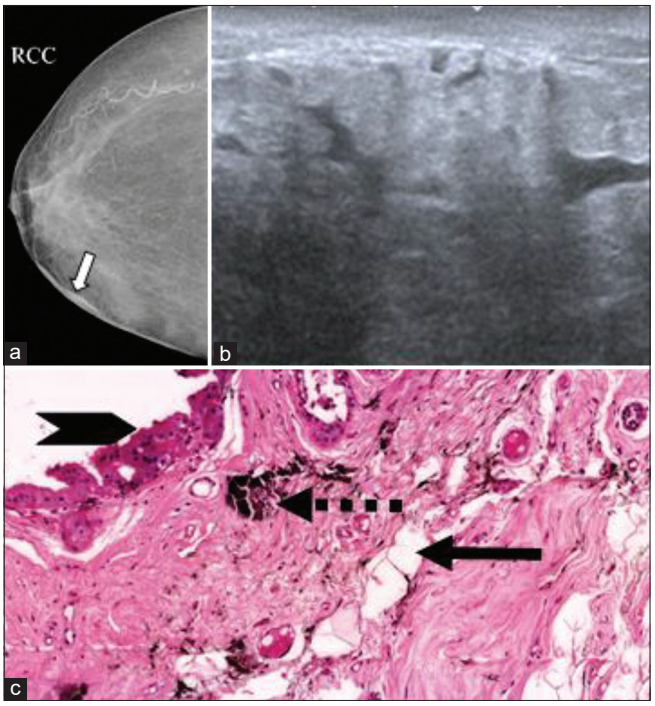

Figure 9: A 48-year-old female with bilateral non-cyclical mastalgia and a vague history of domestic accident 3 months back. Family history of breast cancer positive. (a) X-ray mammogram CC view of the right breast shows focal skin thickening (arrow) and benign vascular calcification in the outer quadrant. b. Ultrasound image shows prominent ducts with surrounding edematous parenchyma, focal skin thickening, and no definitive mass. (c) H & E: Benign calcification (dotted arrow) with apocrine metaplasia (arrowhead) of ducts and adjacent fat necrosis (black arrow) ×200

at a 6-monthly interval for a year and annually for either 1 or 2 years. The usual findings in follow-up US's include normalization of the subcutaneous reflectivity, progression into anechoic areas, and solid and complex lesions becoming more cystic.

In doubtful cases, especially with a complex nodule at initial presentation, fluid aspiration is recommended. If the aspirate is oily material [Figure 5f], the diagnosis of malignant complex mass is excluded and fat necrosis is confirmed. Other findings include flattening of the lesion and resorption of the pure oily fat and an increase in the serosanguinous fluid.[5]

COMPUTED TOMOGRAPHY

In the early stages, fat demonstrates low density [Figure 11b and c] and in later stages with the development of fibrosis linear densities of fibrous bands are seen. In cases of inflammation, enhancement is seen after contrast.[10]

Computed tomography is not the modality of choice in diagnosing fat necrosis in the breast.[10]

Magnetic Resonance Imaging (MRI) Mammogram

Similar to other imaging modalities, MRI appearance of fat necrosis varies depending on the amount of inflammatory

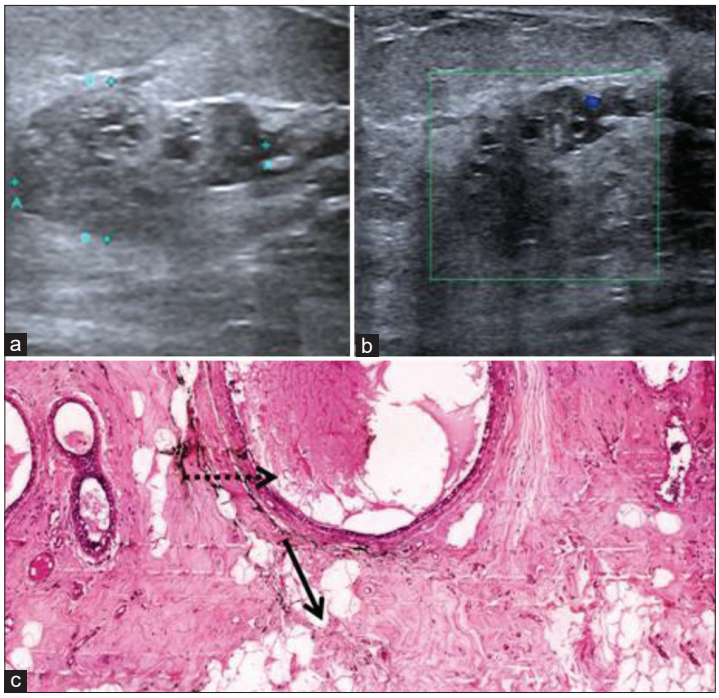

Figure 10: A 35-year-old female with no complaints came for a regular checkup. No history of trauma. (a and b) Ultrasound and color Doppler image shows an irregular hypoechoic mass with tiny cystic changes with absent vascularity and no obvious posterior features (arrow). (c) H & E: Dilated ducts (dotted arrow) and adjacent fat necrosis (black arrow) ×200

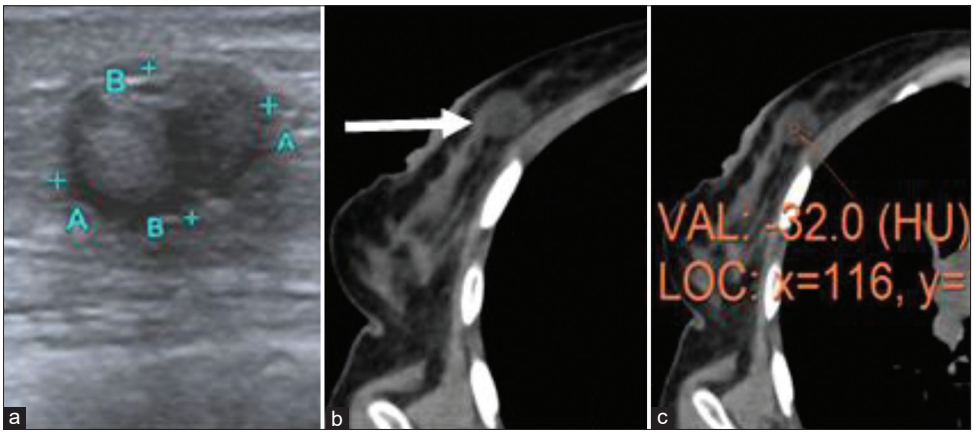

Figure 11: (a) 49-year-old female with no specific complaints. Ultrasound image shows an oval, parallel oriented, circumscribed heterogeneous mass predominantly hyperechoic with no posterior features. Axial section of plain computed tomography in soft tissue window (b) shows a well-defined hypodense mass in the medial quadrant of the breast (arrow). (c) Showing fat density (–32 HU) within the mass

reaction, liquefied fat, and degree of fibrosis. It can have a benign appearance and at times mimic carcinoma, especially postoperatively, as more fibrotic lesions can enhance irregularly or appear spiculated, which are key characteristics of malignancy.[14] The most common appearance of a lipid cyst is a round or oval non-enhancing central mass with an enhancing edge. The immature granulation tissue at the edges of the lesion may enhance after contrast injection due to poor vessel wall integrity. It is hyperintense on T1-weighted imaging and hypointense on T2-weighted imaging – can be used to differentiate fat necrosis from a malignancy, which would not generally contain a central region of fat. Furthermore, the mass becomes hypointense on T1-weighted signal on fat saturation[14] [Figure 12h]. In instances where fat necrosis presents as fibrosis, the appearance is that of a spiculated or irregular mass. On contrast, administration, thin, thick, irregular, or spiculated enhancement may be seen.

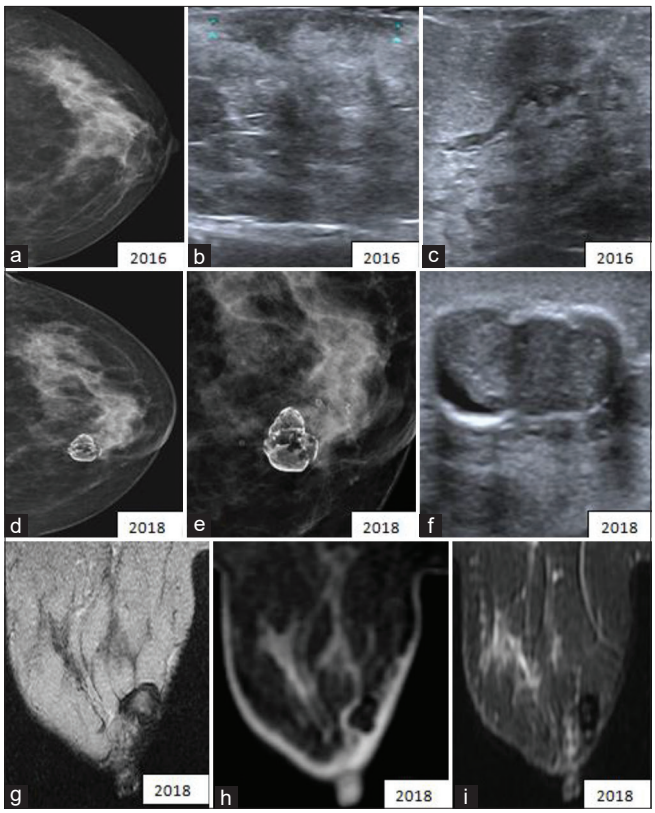

Figure 12: A 43-year-old female with a history of surgery for malignancy in 2015. November 2016 imaging for a routine checkup – (a) X-ray mammogram CC view of the left breast appears normal. (b and c) Ultrasound image shows ill-defined areas of heterogeneity at the operative site corresponding to post-operative inflammatory changes. November 2018 imaging for a routine checkup –X-ray Mammogram of the left breast (d) CC view and (e) zoomed-in view shows a circumscribed radiolucent mass with rim calcification suggestive of fat necrosis. Few other small oil cysts with rim calcification are noted adjacent to the larger lesion. (f) Ultrasound image shows an oval parallel oriented circumscribed hypodense mass with peripheral calcification in the mass and combined posterior features. (g) Axial sections of T2 weighted magnetic resonance imaging (MRI) shows a circumscribed isointense mass compared to adjacent parenchyma with peripheral hypointenserim. (h) Axial T2 FS images show hypointense mass, with fat being suppressed within the mass. (i) Axial contrast-enhanced MRI shows a non-enhancing mass

A recently identified characteristic of fat necrosis on MRI is the "black hole" sign in which there is marked hypointensity on STIR images when compared with surrounding fat.[10]

Prognosis and Complications

Fat necrosis has a good prognosis with no risk of developing cancer in the future. However, the similarity in the clinical and radiological presentation of mimicking a malignancy warrants histopathological correlation. There are no major complications related to fat necrosis; however, pain, infection, and breast deformity are a few of the minor issues.

Few differentials that need to be considered during imaging evaluation include breast carcinoma, breast cyst, fibroadenoma, and granulomatous mastitis.[9]

CONCLUSION

The varied spectrum of clinical presentation and imaging findings of fat necrosis puts the clinician and radiologist in a diagnostic dilemma. Proper history with an insight into the imaging features makes it easier in differentiating fat necrosis from other conditions. Therefore, it is mandatory to have a clear history, assess risk factors, and consider the age of the patient. In high-risk patients, namely, those who had primary oncologic surgery, patients older than 40 years of age, and those with very delayed presentation of fat necrosis, a more extensive workup is necessary. Mammography is a better modality of choice for fat necrosis than US especially in diagnosing a lipid cyst. However, in the late stages, there is an overlap in features with malignancy resembling a spiculated mass due to the fibrotic reaction. All these factors pose a challenge to arrive at the diagnosis and hence an in-depth knowledge of the spectrum of imaging findings will help in arriving at a diagnosis and can avoid unnecessary procedures and the anxiety caused to the patient. However, biopsy remains the gold standard where the diagnostic dilemma lingers on.

ACKNOWLEDGMENTS

I would like to record my gratitude and profound thanks to my teachers, colleagues, and family members for the inspiring guidance, constant encouragement, and support during all stages of my work.

REFERENCES

1. Ayyappan AP, Crystal P, Torabi A, Foley BJ, Fornage BD. Imaging of fat-containing lesions of the breast: A pictorial essay. J Clin Ultrasound 2013;41:424-33.
2. Atasoy MM, Oren NC, Ilica AT, Güvenç İ, Günal A, Mossa-Basha M. Sonography of fat necrosis of the breast: Correlation with mammography and MR imaging. J Clin Ultrasound 2013;41:415-23.
3. Saidian L, Lee SJ, Mahoney MC. Multimodality imaging of fat necrosis of the breast. Contemp Diagn Radiol 2017;40:1-7.
4. Tuncbilek N, Sezer A, Altaner S, Mentes A, Mercangül D, Durmus Y, *et al*. Nontraumatic giant fat necrosis of the breast presenting as a rapidly growing tumor. Prague Med Rep 2011;112:50-5.
5. Upadhyaya V, Uppoor R, Shetty L. Mammographic and sonographic features of fat necrosis of the breast. Indian J Radiol Imaging 2013;23:366-72.
6. Chala LF, de Barros N, de Camargo Moraes P, Endo E, Kim SJ, Pincerato KM, *et al*. Fat necrosis of the breast: Mammographic, sonographic, computed tomography, and magnetic resonance imaging findings. Curr Probl Diagn Radiol 2004;33:106-26.
7. Ashok K, Nitin N, Ritvij P, Akshay P, Mayank V, Tejas C, *et al*. A rare case of traumatic breast avulsion. Int J Health Sci Res 2014;4:200-3.
8. Taboada JL, Stephens TW, Krishnamurthy S, Brandt KR, Whitman GJ. The many faces of fat necrosis in the breast. AJR Am J Roentgenol 2009;192:815-25.
9. Genova R, Waheed A, Garza RF. Breast Fat Necrosis. Treasure Island, FL: StatPearls Publishing; 2020.
10. Kerridge W, Kryvenko O, Thompson A, Shah BA. Fat necrosis of the breast: A pictorial review of the mammographic, ultrasound, CT, and MRI findings with histopathologic correlation. Radiol Res Pract 2015;2015:613139.
11. Hogge JP, Robinson RE, Magnant CM, Zuurbier RA. The mammographic spectrum of fat necrosis of the breast. Radiographics 1995;15:1347-56.
12. Fornasa F, Bonifacio S. The Modern Imaging of Fat Necrosis: A "Great Mimicker" in the Breast and Beyond. Vienna, Austria: Paper Presented at European Congress of Radiology; 2011. p. 3-7.
13. Coyne JD. Intraductal membranous fat necrosis in a fibroadenoma of breast: A case report. Int J Surg Pathol 2014;22:564-5.
14. Gilliver R, Zhong J, Palkhi E, Rengabashyam B. Fat Necrosis of the Breast: A Pictorial Review. Vienna, Austria: Paper Presented at European Congress of Radiology; 2018.

How to cite this article: Gnanavel H, Dev B, Joseph LD, Vittalraj P, Chinnappan S, Palanisamy P, Mohanarangam VSP. Int J Sci Stud 2021;9(1):10-18.

Source of Support: Nil, **Conflicts of Interest:** None declared.

Print ISSN: 2321-6379
Online ISSN: 2321-595X

Review Article

Predatory Bacteria: A Remarkable Milestone of Antibiotic Resistance in Post-antibiotic Era

Deepika[1], Shailendra Singh Chauhan[2], Aditya Sinha[3], Satendra Sharma[3], Ankita Garg[1], Dhruv Rastogi[4]

[1]Post Graduate Student, Department of Periodontology, Kanti Devi Dental College and Hospital, Mathura, Uttar Pradesh, India, [2]Professor and Head of Department, Department of Periodontology, Kanti Devi Dental College and Hospital, Mathura, Uttar Pradesh, India, [3]Reader and MDS, Department of Periodontology, Kanti Devi Dental College and Hospital, Mathura, Uttar Pradesh, India, [4]Post Graduate Student, Department of Conservative Dentistry and Endodontics, Divya Jyoti College of Dental Sciences and Research, Modinagar, Uttar Pradesh, India

Abstract

Antimicrobial resistance is an economic and health crisis we are facing across the globe. With the rise of antibiotic resistance, the unconventional therapies are the new areas of research to meet the current needs for new therapies for the treatment of Gram-negative infections. One budding approach is the use of living predatory bacteria, known as "*Bdellovibrio bacteriovorus,*" a "living antibiotic" that demands the investigation in our health systems. We aim to review the science that supports the feasibility and future directions of predatory bacteria as an alternative to antibiotics and more research is needed to evaluate its full potential.

Key words: Antibiotics, Antimicrobial resistance, *Bdellovibrio bacteriovorus*

INTRODUCTION

Antibiotics are responsible for the sharp decline of infectious disease-related deaths caused by bacteria over the past 50 years. However, due to the overuse and misuse of the antibiotics, the multidrug-resistant (MDR) bacterial infections have been rising which possess a serious threat to general public health.

The World Health Organization estimated that 20 years are added to each person's life with antibiotics. However, this overuse of antibiotics puts persuades the bacteria to develop resistance against such drugs, leading to the emergence of untreatable superbugs. Researchers of South Korea's Ulsan National Institute of Science and Technology (UNIST) are planning to launch predatory bacteria which are capable of attacking other bacteria without harming human cells, that is, "Bacteria eating bacteria."

Access this article online

www.ijss-sn.com

Month of Submission : 02-2021
Month of Peer Review : 03-2021
Month of Acceptance : 03-2021
Month of Publishing : 04-2021

The antimicrobial resistance dilemma shows no signs of reduction and can hamper the health-care systems in the near future as bacteria show resistance toward the aminoglycoside, penicillin, quinolone, sulfonamide, and tetracycline classes of antibiotics which are mainly procured to amend the bacterial infections.[1] In the midst of this global crisis, a potential discovery of "*Bdellovibrio*" and other members has resulted in the birth of a new research in identifying the potential value in clinical setup.

Therefore, the looming problem of resistance to antibiotics in microorganisms is a global health concern. The drug-resistant microorganisms which originate from anthropogenic sources and commercial livestock farming have given rise to serious environmental and health challenges. The environmental "resistome" from the genes of antibiotic resistant is transferred to human and veterinary pathogens. Hence, the transfer of these genes into pathogens is extremely important for the development of therapeutic interventions to curtail the infections to prevent the havoc of microbial drug resistance.

Predatory Bacteria

Professor Robert Mitchell is developing a natural compound called violacein to tackle *Staphylococcus*, a group of around 30 different bacteria known to cause skin infections, pneumonia, and blood poisoning. Some *Staphylococcus*

Corresponding Author: Dr. Deepika, Department of Periodontology, Kanti Devi Dental College and Hospital, Mathura, Uttar Pradesh, India.

bacteria such as methicillin-resistant *Staphylococcus aureus* are resistant to antibiotics which make infections harder to treat.

Violacein known as "bisindole:" A metabolite produced by bacteria from the condensation of two molecules of tryptophan (an essential amino acid used in many organisms to ensure normal functioning and avoid illness and death). Bisindole is vibrant purple in color and has a research future for its anticancer, antifungal, and antiviral properties. Researchers have discovered that it can stop the bacteria from reproducing, killing the MDR bacterium *S. aureus*.

The team is now collaborating with fabric manufacturer Yeejoo Co., the Korea Institute of Ceramic Engineering and Technology, and research teams in Turkey and Romania to manufacture antibacterial fabrics infused with violacein that can effectively kill *S. aureus*.

The prime candidate predatory bacterium is known as "*Bdellovibrio bacteriovorus*."[2] It is a Gram-negative deltaproteobacterium that expresses a single polar flagellum that is expressed as one of the fastest moving organisms in nature usually found in soils and water.

B. bacteriovorus are free-living, harmless obligate predator of bacteria harmless to humans. They are the group that includes *Salmonella*, *Escherichia coli*, and several other pathogens.[3]

Bdellovibrio were accidentally discovered in the 1960s by scientists hunting for bacteria-killing viruses in the soil known as bacteriophages (or, simply, phages). Viruses are usually non-motile and grow quickly, forming clear patches on plates of bacteria. *Bdellovibrio* took longer to show up in cultures, but the patches created expanded as the predators swarmed over their sessile prey.

Kadouri[4] began studying *Bdellovibrio* in 2003 for breaking stubborn biofilms formed by *Pseudomonas aeruginosa*, a Gram-negative microbe causing infections in burns, wounds, the lung, eye, and other areas. During that time, antibiotic resistance was a concern mainly associated with Gram-positive bacteria. *Bdellovibrios* have also been recovered from the gills of blue crabs and oysters, and more recently from mammalian feces and the mammalian gastrointestinal tract.

MECHANISM OF ACTION

Bdellovibrio are efficient killing machines which punches a hole in the membranes of their prey, then enter and consume their contents, then burst out again to search for their next meal. The entire process is both quick and efficient and takes only 2–3 h for a single prey cell for the complete digestion. Researchers are evaluating *Bdellovibrio* and other similar predatory bacteria as a route for treating intractable, antibiotic-resistant infections.

Researchers are now beginning to evaluate *Bdellovibrio* and other similar predatory bacteria as a route to treating intractable, antibiotic-resistant infections.

Certain pills which are full of predatory bacteria will not be able to replace antibiotics at pharmaceuticals. Researches on these microbes will help us prepare for the future when certain antibiotics fail to treat MDR infections.

Although free-living *Pseudomonas* are susceptible to antibiotics but biofilm acts as a protective shield and drugs are not able to eliminate them. In early experiments, Kadouri[3] found that predatory bacteria could penetrate biofilms and break them up, making pathogens susceptible to antibiotics. *Bdellovibrio* species are found to be effective against some biofilms whereas another group known as *Micavibrio* proved more potent against other bacterial prey. Unlike *B. bacteriovorus*, *Micavibrio,* and some other *Bdellovibrio* species have behavior similar to leeches, which usually sticks to the outside of host cells and suck their contents inside out. Each bacterium has a different host specificity and some have different mechanisms of killing their prey.

There is "Attack initiation mechanism" used by "predatory bacteria," capable of invading and killing harmful bacteria including *E. coli* or *Salmonella*.

These bacteria attack other bacteria by attaching to the cell exterior, then burrowing through and devouring the cell from the inside.

The predatory bacteria which attack the type of cells are responsible for many infections that are resistant to currently available antibiotics. Gram-negative bacteria are surrounded by a distinctive double membrane which the predatory bacteria exploit by temporarily living between the two layers. In this private dining niche, the invaders thrive and consume the cell's nutrients.

Therefore, these bacteria can be harnessed as a therapy against antibiotic-resistant bacteria. Usually, *B. bacteriovorus* creates a porthole in a host's cell membrane to enter its body and once inside, the hole is sealed up and then the enzymes released are digested by the host's contents. It then replicates within its prey and then reemerges to invade new hosts. This process wherein the host species' contents never spill out has proven useful in therapeutic approach

because it avoids the spillage of the pathogen's innards, if released, it can trigger a damaging inflammatory response.

Sockett, Kadouri,[4] (2009), and others studied the mechanism of predatory bacteria whereas another group of researchers exposed a crisis in which they found out a severely ill patient's infections which was caused by New Delhi metallo-beta-lactamase-1, a drug-resistant strain of the Gram-negative pathogen *Klebsiella pneumoniae*. Researchers began to revisit phage therapy and other alternatives for antibiotics that were once considered too unusual to be useful clinically. The following figure shows molecular structure of 'Bdellovibrio bacteriovorus' [Figure 1].

B. bacteriovorus lifecycle has long been described to be biphasic, divided into a free-living attack phase (AP) and an intraperiplasmic growth phase (GP) [Figure 2].

Rotem *et al.* (2015)[5] introduced a transition phase from attack phase to intraperiplasmic growth phase in which prey-derived cues is triggered by specific bdellovibrio transcription profile. In the AP, *B. bacteriovorus* collides and attaches to Gram-negative prey cells. A pore is created in the outer membrane in which the prey cells cross the peptidoglycan layer and establishes itself within the prey periplasm. Collision with the prey occurs seemingly at random and the predatory cell remains reversibly attached for "recognition" period before becoming irreversibly anchored. Successful recognition triggers the transition to an intermediate phase that facilitates invasion into the host cell and forms an osmotically stable niche, which is protected from phage attacks, photo-oxidation and pollutants, called bdelloplast. *B. bacteriovorus* uses its type IV pili to pass through the membrane, sheds the flagellum and the pore is resealed after entering the prey. Second prey cue is facilitated by sensing transition to the GP and filamentous growing. Formation of bdelloplast causes a distinct round up of the rod-shaped prey cell, resulting from the modification of peptidoglycan cell wall. This modification prevents self-competition between individual predators for the same prey and promote 1:1 predator to prey ratio. When the prey gets exhausted, the predator is divided into several flagellated progeny cells, followed by host cell lysis and progeny release, whereupon the cycle begins anew. The figure shows high resolution electron microscopy image *B. bacteriovorus* [Figure 3].

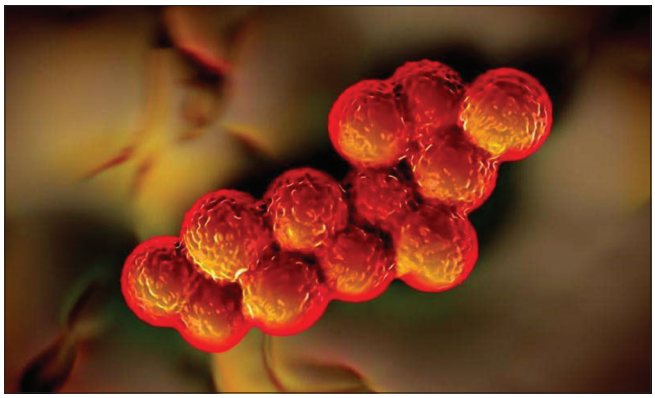

Figure 1: Molecular structure of *"Bdellovibrio bacteriovorus"*

FUNCTIONING

Predatory ability of *B. bacteriovorus* affected by indole, a metabolite produced by *E. coli* and many other bacteria regulates various biological functions in bacteria which stabilize small DNA molecules, as well as functioning as a signaling molecule, through which different communities of bacteria "talk" and coordinate gene expression within a population.

Bacterial version of a gladiator contest was put in the flasks face to face with *B. bacteriovorus* and then artificially added different concentrations of indole and evaluated *B. bacteriovorus* predatory behavior. They found that *B. bacteriovorus* takes much longer to attack *E. coli* (a common bacterial strain that can cause food poisoning, infections, and fever) with indole. To make sure, the predator-prey relationship was not influenced by *E. coli's* own production of indole, they also tested the predatory ability of *B. bacteriovorus* on another bacterium called *Salmonella* (food poison causing bacteria), which does not produce indole.

The result was the same: Indole in high concentrations blocks and prevents the predatory bacteria from attacking altogether.

Ulsan National Institute of Science and Technology found that *B. bacteriovorus* can be used to control the attack by

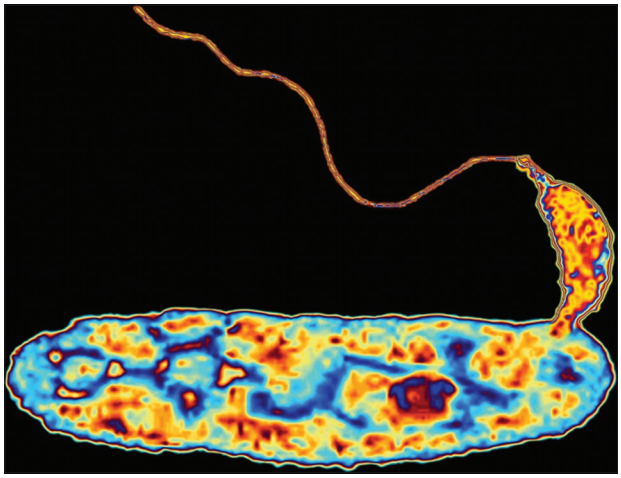

Figure 2: *Bdellovibrio*— false-colour transmission electron microscopy image at 50,000× magnification—as a means of treating intractable, antibiotic-resistant infections. Image credit: Science Source/ALFRED PASIEKA

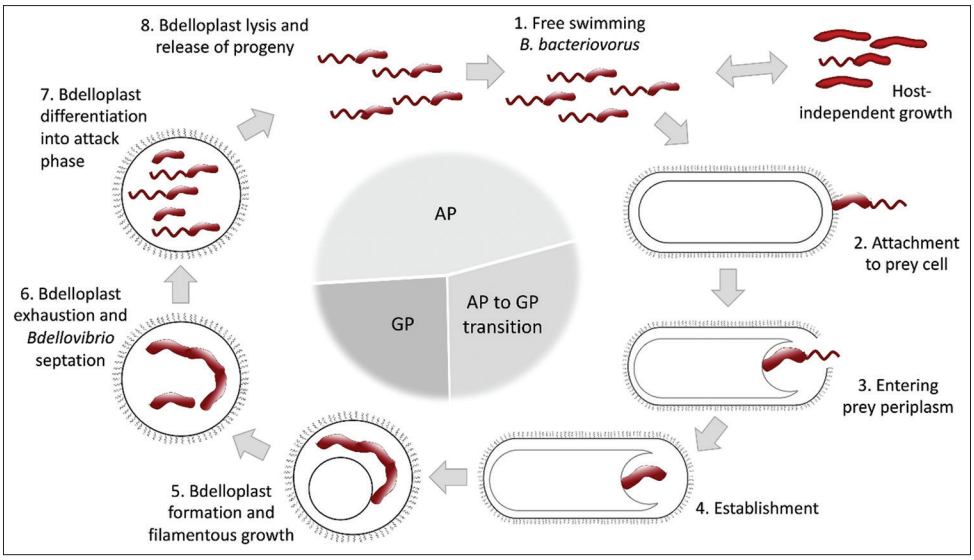

Figure 3: Schematic representation of *B. bacteriovorus* life cycle

specific bacteria which causes illness, while avoiding the 'good' bacteria necessary for daily survival. This can further help in the development of 'living antibiotics'. A false-colour transmission electron microscopy image is shown of *B. bacteriovorus* at 50,000× magnification [Figure 4].

AREAS OF MEDICAL IMPLEMENTATIONS

1. The key health-care application of predatory bacteria would be to treat ailments in which MDR organisms are the etiologic agents
2. The usage of bacterial predators as anti-periodontitis agents *in vivo* is a grey area as of now because their aerobic lifestyle (Rotem *et al*., 2014)[5]
3. *B. bacteriovorus* HD100 had the highest versatility as it was capable of preying on four of the six pathogens, that is, *Aggregatibacter actinomycetemcomitans* (*A. actinomycetemcomitans*), *Eikenella corrodens* (*E. corrodens*), *Fusobacterium nucleatum* (*F. nucleatum*), and *Prevotella intermedia* (*P. intermedia*)
4. Predatory bacteria have also shown the ability to control the overgrowth of MDR bacteria *in vitro* from the genera *Acinetobacter*, *Escherichia*, *Klebsiella,* and *Pseudomonas*
5. Biofilms having susceptibility to predatory bacteria attack *in vitro*.

POTENTIAL ADVANTAGES

Efficacy to Control Infection

a. Predatory bacteria have the ability to be developed into novel antimicrobial agent as they were able to control a Gram-negative infection *in vivo*

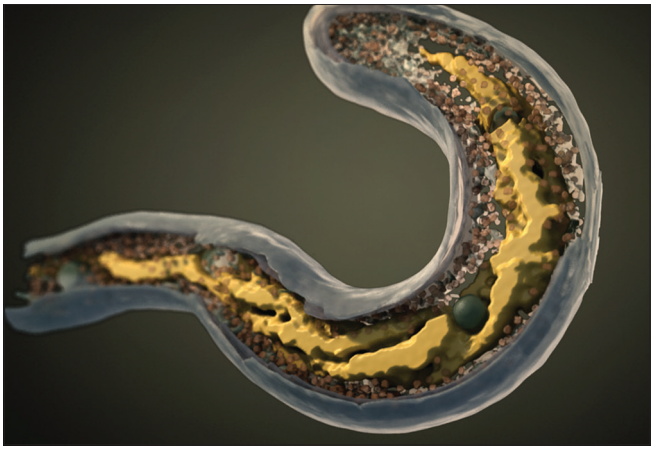

Figure 4: High-resolution electron microscopy

b. Determination of predation with the help of live cell imaging *in vivo* and that the predators cooperate with native host immune cells to first decrease the bacterial burden, before being cleared up from the host by neutrophils and macrophages
c. Predatory bacteria treatment potentially could be effective for infections occurring at immune privileged sites, such as the urinary tract, as the predators could persist longer with less immune elements in their direct environment
d. Direct topical application on wounds due to its wide spectrum activity coupled with their non-toxic nature (secreted proteases against human cells)
e. Little or no effects on the gut microbial diversity as compared with antibiotics
f. Predatory bacteria may contribute to health by serving as an ecological balancer in normal gut flora, as

B. bacteriovorus has been found in lower abundances in patients with chronic diseases of the gut compared with healthy individuals.

Resistance to Predation

a. Development of predation resistance of current antibiotics in a normally susceptible bacterial species
b. A potential advantage of bacterial cells can develop a transient, plastic resistance to predation; so, it was hypothesized that although the prey might evolve to avoid predation, the predator, being a live microorganism, might differentiate quickly to counter any emerging resistance

Novel Antibody modulating Tools

B. bacteriovorus is now an upcoming new source for the identification of novel enzymes with biotechnological potential which is exemplified by the identification and characterization of BspK and BspE with described enzymatic activities on human antibodies. BspK specifically hydrolyzes IgG_1 (most common therapeutic antibody) in the hinge, enabling middle-down MS analysis of the biological therapeutics.

Biofilm Formation and Degradation

Self-formation of biofilms

The presence of nutrients and lack of access to prey favoured the diversification, and it was speculated that this phenotypic change resembling a biofilm may benefit BALOs persistence in the environment having the ability to form biofilms. *B. bacteriovorus* forms biofilm as HI mutants in nutrient-rich environment.[6] Williams *et al.*(2009)[7] hypothesized that biofilms formed by HI cells have high importance for the long-term presence of naturally occurring bacteria in certain environments of biotechnological approaches serving as a reservoir for predators. Finally, the mutants reduce the ability of other bacteria to form biofilms by preventing the coating on surfaces with HI.

Regulation of prey and non-prey biofilms

The vast majority of Gram-negative bacteria within the sludge have sensitivity to BALOs in the biofilm.[6]

Potential Applications

a. Bacterial predators are effective antibacterial agents, do not induce a sustained immune response, and are rapidly cleared from mammalian hosts
b. Efficacy of bacterial predators to kill keratitis isolates of *P. aeruginosa* and *Serratia marcescens* (*S. marcescens*), a common cause for irreversible blindness
c. Bacterial predators could potentially be used to label infections due to *Helicobacter pylori (H. pylori)*, a Group 1 carcinogen because multiple strains of *Bdellovibrio* have predation capacity against the pathogens in both viable and viable but nonculturable
d. Use of bacterial predators for gastrointestinal ailments is limited
e. The natural resistance of *Bdellovibrios* to β-lactam antibiotics has the possibility for treatments using these bacteria in conjunction with penicillin.

FUTURE DIRECTIONS

a. Even a single dose of *Bdellovibrio* has broad-ranging, non-specific activities which seemingly have both pros and cons
b. *Bdellovibrio* consumes beneficial microflora
c. The use of bacteria as antibacterial therapy poses manufacturing and regulatory challenges as *Bdellovibrio* grows only on other bacteria and carries its own LPS – a molecule that's currently used as a marker of contamination in drug manufacturing
d. New standards have to be set for predatory bacteria-based remedies
e. With the rise of antibiotic resistance, the unconventional therapies should be more researched. The time has come to treat infectious disease the way we treat cancer with a combination of immunotherapy, radiation therapy, chemotherapy, and more
f. Overall, *B. bacteriovorus* secretome has shown to be extremely dynamic, revealing cell cycle-dependent functions of many proteins. Thus, in respect to its arsenal of hydrolytic enzymes, *B. bacteriovorus* are to be considered an interesting biological source for identifying novel bacterial proteins with applications within basic research and the life science industry
g. *B. bacteriovorus* and *Micavibrio aeruginosavorus* have inability to invade mammalian cells, and no apparent pathological effects or signs of cytotoxicity or reduction in cell viability, supporting the proposition that these two BALOs are inherently non-pathogenic to mammals.

ADVANCEMENT

A new research led by Dr. Andrew Lovering and others, University of Birmingham's, School of Biosciences, investigated a new study published in nature communications which showed the initiation "trigger" from one common type of predator called *B. bacteriovorus*.

Using a range of techniques, the production of a particular enzyme was described, called DgcB, when the bacterium encounters its potential prey. The enzyme senses modification of its own floppy "tail" and then triggers production of a messenger molecule, which switches the

bacteria from a cruising and searching mode into invasion mode. These types of signals kickstart the invasion and the process of killing is of significance.

The next step for the research team is to build a bigger picture of the bacteria's signaling network, finding out more about how the DgcB tail modification is triggered, and what stimuli are important for this to happen.

CONCLUSION

B. bacteriovorus is among the best-studied BALOs and serves as a model organism for bacterial predation described as a highly motile, δ-proteobacterium that employs an endobiotic (periplasmic) hunting strategy.

The issue of antimicrobial resistance needs to be addressed and bacterial predators offer a potential path forward. The present findings showed that predatory bacteria demonstrate impressive activity *in vitro* against multiple pathogens but are not indicative *in vivo* efficacy. Combinatorial therapy should be the preferred for the use as bacterial predators appear to function better as an ancillary therapy. Monotherapy could be suitable in specific conditions. Bacterial predators are only be effective against Gram-negative organisms. Therefore, efficacy on other Gram-positive organisms and intracellular organisms should be assessed.

The plethora of hydrolases produced by predatory bacteria may act as a source for exploration of new biotechnologically relevant enzyme. This area needs further research to evaluate its full potential. Although a number of fundamental properties of *B. bacteriovorus* predation have been explored, it is evident that still much research needs to be done before comprehensive understanding of this ubiquitous yet a very versatile predator.

REFERENCES

1. Rames A. Predatory bacteria: A possible key for the lock of antibiotic resistance. Trans Sci Technol 2020;7:8-17.
2. Madhusoodanan J. Inner workings: Predatory bacteria as an antibacterial remedy. Proc Natl Acad Sci U S A 2019;116:22887-90.
3. Kadouri D, O'Toole GA. Susceptibility of biofilms to *Bdellovibrio bacteriovorus* attack. Appl Environ Microbiol 2005;71:4044-51.
4. Shatzkes K, Connell ND, Kadouri DE. Predatory bacteria: A new therapeutic approach for a post-antibiotic era. Future Microbiol 2017;12:469-72.
5. Rotem O, Pasternak Z, Jurkevitch E. The genus *Bdellovibrio* and like organisms. In: The Prokaryotes: *Deltaproteobacteria* and *Epsilonproteobacteria*. Berlin, Heidelberg: Springer-Verlag; 2014. p. 3-17.
6. Bratanis E, Andersson T, Lood R, Bukowska-Faniband E. Biotechnological Potential of *Bdellovibrio* and like organisms and their secreted enzymes. Front Microbiol 2020;11:662.
7. Williams HN, Turng BF, Kelley JI. Survival response of *Bacteriovorax* in surface biofilm versus suspension when stressed by extremes in environmental conditions. Microb Ecol 2009;58:474-84.

How to cite this article: Deepika, Chauhan SS, Sinha A, Sharma S, Garg A, Rastogi D. Predatory Bacteria: A Remarkable Milestone of Antibiotic Resistance in Post-antibiotic Era. Int J Sci Stud 2021;9(1):19-24.

Source of Support: Nil, **Conflicts of Interest:** None declared.

Print ISSN: 2321-6379
Online ISSN: 2321-595X

Review Article

Review of Artificial Intelligence Applicability of Various Diagnostic Modalities, their Advantages, Limitations, and Overcoming the Challenges in Breast Imaging

Swati Goyal[1], B R Srivastava[2]

[1]Associate Professor, Department of Radiodiagnosis, Government Medical College, Bhopal, Madhya Pradesh, India, [2]Professor, Cancer Hospital and Research Institute, Gwalior, Madhya Pradesh, India

Abstract

Integrating all imaging modalities, namely, mammography, ultrasound, magnetic resonance imaging, and tomosynthesis, allows for a comprehensive morphological examination of the breast to distinguish between normal and abnormal breasts. The key target is to correctly detect malignant lesions in the early stages and improve the prognosis of breast cancer patients. Radiologists may increase their efficiency and free up more resources for patients or clinical practice using machine learning software that can include a second opinion, assess malignancy, and assist in patient triage. It would, though, need a lot of training data and its meticulous labeling. Data augmentation and multitask transfer learning are effective for training convolutional neural networks in medical image processing. This review article provides an introductory summary of artificial intelligence (AI) development in imaging, as well as the increasingly increasing AI development through various imaging modalities along with their advantages and limitations.

Key words: Artificial intelligence, Digital breast tomosynthesis, Magnetic resonance imaging, Mammography, Ultrasonography

INTRODUCTION

Mammography, ultrasound, magnetic resonance imaging (MRI), and tomosynthesis are some of the modalities used in modern diagnostic senology, the branch of medicine that deals with breast disorders. Integrating all imaging modalities allows for a comprehensive morphological examination of the breast to distinguish between normal and abnormal breasts. The key target is to correctly detect malignant lesions in the early stages and improve the prognosis of breast cancer patients.

A single modality is inadequate to detect breast cancer, necessitating several procedures to diagnose a lesion accurately. As a result, this review article provides an introductory summary of artificial intelligence (AI) development in imaging, as well as the increasingly increasing AI development through various imaging modalities along with their advantages and limitations.

Access this article online

www.ijss-sn.com

Month of Submission : 02-2021
Month of Peer Review : 03-2021
Month of Acceptance : 03-2021
Month of Publishing : 04-2021

THE EVOLUTION OF AI IN IMAGING

In 1967, Winsberg *et al.* created a method to detect changes in optical densities on mammogram films and highlight regions with shaded rectangles to display left and right breast differences.[1] Lodwick *et al.* focused on developing computer systems capable of automatically diagnosing conditions from radiological images.[2] Although very novel computer simulations yielded promising results, these attempts were ultimately unsuccessful due to a lack of computing resources, digital images, and sophisticated imaging processing techniques.[3,4]

Let's have an overview of applicability of AI using various modalities such as mammography, digital breast

Corresponding Author: Dr. Swati Goyal, D/16, Upant Colony, Bhopal, Madhya Pradesh, India.

tomosynthesis (DBT), sonography, and MRI apart from discussing their advantages and challenges.

MAMMOGRAPHY

The proper patient positioning, exposure, technique, and automatic exposure device result in the best image quality. The appropriate compression to the breast tissue distributes it evenly, reduces its thickness, and significantly decreases geometric unsharpness, motion blur, radiation dose, artifacts due to skin fold, and scattered radiation apart from enhancing the spatial resolution.[5]

SCREENING MAMMOGRAPHY

The primary reason for screening mammography in an asymptomatic patient is to look for occult breast cancer. It entails the physician taking a thorough history and performing a clinical breast examination.[6] According to the American College of Radiology, screening mammography should be done annually after the age of 40 and in high-risk cases.[7] Patients with a history of irradiation and prior breast cancer, as well as first-degree relatives with breast cancer, should be screened sooner. Any patients with new or expanding lumps should be offered diagnostic mammography.[8]

DIAGNOSTIC MAMMOGRAPHY

In patients with a palpable mass and any radiographic abnormality on a screening mammogram, two standard views – craniocaudal projection (CC view) and mediolateral view (MLO view) – of each breast are taken, with additional views as needed. Diagnostic mammography should be considered in patients with specific signs and symptoms such as clear or bloody nipple discharge, nipple retraction, skin dimpling, or a history of carcinoma breast.[9]

AI AND DIGITAL MAMMOGRAPHY APPLICATIONS

Breast cancer is one of the most lethal ailments, and it is the second leading cause of death in women. When malignant, cancerous lumps form in the breast cells. In today's computer-assisted diagnostic (CAD) analysis, there are two main components: Computer-aided identification (CADe) uses computer output to pinpoint the position of suspected lesions, while computer-aided diagnosis (CADx) produces a report that describes the lesions' characteristics.[10] Conventional machine learning techniques with manual extraction of features are being displaced by deep learning constituting automatic extraction of features.[11]

Rodrguez-Ruiz *et al.* concluded that AI improved a radiologist's performance in identifying breast cancer compared to unaided image reading. The input datasets consisted of 240 digital mammography images of 100 normal, 100 malignant, and 40 false-positive cases. To delineate microcalcifications and soft-tissue lesions, deep learning (convolutional neural network [CNNs]) feature classifiers and image recognition algorithms were used. The area under the curve (AUC) (0.89 vs. 0.87, $P = 0.002$), sensitivity (86 vs. 83%, $P = 0.046$), and specificity (79 vs. 77%, $P = 0.06$) values favored the AI system as a radiology assistance.[12] Huynh *et al.* concluded that transfer learning could enhance existing CADx approaches by contrasting support vector machine classifiers based on CNN extracted image features to their previous computer-extracted features (AUC 0.86) to distinguish benign and malignant lesions.[13]

ADVANTAGES OF USING AI WITH MAMMOGRAPHY IMAGES

AI is not just a computerized approach but an interface between humans and machines. Radiologists can gain more time for patients or clinical practice using machine learning tools that enable them to automate tasks that enhance their efficiency. Standardized views, availability of images for comparison, systematized reporting style, and classifiable outcome are the necessary properties that make mammography appropriate for training machine learning algorithms. It can give a second opinion, tell us how normal cases will turn out, make predictions about malignancy, and help us prioritize patients. It is especially advantageous in heavily populated and developing countries with limited medical resources. The problem of excessive workload and doctor scarcity can be partly minimized using AI algorithms.[14]

CHALLENGES FACED USING AI IN MAMMOGRAPHY IMAGES AND METHODS TO OVERCOME

AI algorithms require massive volumes of training data; moreover, supervised learning and CNN-based techniques require complicated and time-consuming data labeling.[15] Where medical images are involved, these deep learning algorithms can prove to be problematic. The main challenge that interferes with teaching machine learning algorithms is acquiring accurate annotated image data, not the data's availability. The translation of free text files of radiologists necessitates the use of sophisticated text mining techniques.[16]

The two realistic options that can be used to solve the problem at least partially include data augmentation and transfer learning. Data augmentation with affine transformations, including localization, rotation, and scaling, can be used to create new data from old data. Moreover, multitask transfer learning is effective for training deep CNN (DCNN) in medical image processing,[17] especially when testing samples from a modality are limited.[18]

Furthermore, label noise can be a significant constraint in algorithm design, particularly when domain experts label data. One should think about how to deal with noise and how best to resolve uncertainty while using such data to train a deep learning algorithm. The other choice is to specify the loss function clearly in the first iteration. Usually, a binary classification: Normal versus abnormal is used in medical imaging. However, as they can vary greatly, there is a broad generalization. Alternatively, an exhaustive annotation of the whole subclasses could turn the deep learning system into a multiclass system. Thus, this contributes to the dilemma of expert availability for annotation and is, as a result, frequently impractical.[16]

Another data-related problem is the existence of an unbalanced class structure. When it comes to searching pictures for the various diagnostic medical imaging classes, finding the correct ones may be challenging. Although AI-based CAD systems have shown the capacity for improving breast and lung images, they can also erroneously categorize normal structures as abnormal. This false-positive identification is a major stumbling block affecting recall rates, performance, and costs which can be mitigated by the radiologist who can differentiate true-positive from false-positive cases.[19,20] A 2016 study discovered that four different CAD systems linked to the computed tomography scan revealed the previously undetected lung nodules, including 17% of lesions <3 mm and more than 70% of cancers from 3 to 6 mm sizes which are usually underestimated by professionals.[21]

The fine-tuning of algorithms to tasks with large data sets is not easy. To begin with, it is not easy to train a CNN to detect both masses and calcifications. And hence, sometimes, different CNNs are trained for both types of lesions, and only the results are merged in the performance of the AI support structure.[22] However, the algorithms must also be reliable and repeatable for mammograms collected by separate technologists using multiple vendor machines. Testing the deep learning algorithms from different vendors is essential since most vendors incorporate their own post-processing data to prepare mammograms which means that a CNN trained on one vendor's data might not be applicable on another. Thus, the ML strategies must be implemented to normalize mammograms.[23]

DBT

DBT tends to localize minor breast lesions in thick breast tissue. It is also advantageous when overlapping structures on 2D imaging may obscure an area of interest leading to a false-negative result. Sometimes, the summation artifact of overlapping normal structures might give a false-positive result. Breast cancer, even if not calcified, may be diagnosed with DBT. The breast positioning of MLO and CC views is like conventional mammography and does not require any special operator experience. Although radiation is minimal and within the safety limits, radiation exposure with DBT is still more than conventional mammography.[24]

AI AND DBT

Using a multistage transfer learning approach, DCNN has been developed recently to classify malignant and benign lesions in optical breast tomosynthesis (DBT).[25] It is advantageous even when the training sample size is small. AdaBoost algorithm, with deep learning, has been suggested for the recognition and early detection of breast cancer.[26]

The use of machine learning to produce synthetic mammograms can accentuate suspicious findings. However, they can also altogether remove normal tissue and mask the relevant findings. The use of a multiplanar reconstruction fitted through the most suspicious lesions detected by a conventional CAD system in a DBT examination improved reader performance compared to that with full-field digital mammography.

Radiomics is the translation of images to minable data by decoding their quantitative features such as intensity, shape, size, and texture extracted from the background. Massive and well-curated data sets help data mining, that is, discovering patterns in large datasets. Further studies have shown that the radiomics features of the parenchyma from DBT in women with breast cancer vary from those who do not have cancer and that offer the possibility of predicting disease risk.[27]

ULTRASONOGRAPHY (USG)

The use of high-frequency, 7.5–13 MHz probes delineates the internal structure of the breast with better lateral and tissue contrast resolution and lesion characterization. Ultrasound is used in concurrence with mammography for better lesion characterization. It is non-ionizing and hence the modality of choice in young females and women with mammographically dense breasts. Since it is real time, it helps in accurate localization for biopsy of the lesion.[28]

AI AND SONOGRAPHY

Fujioka *et al.* inferred that deep learning with CNN has high diagnostic efficiency (AUC = 0.913 and 0.728–0.845, $P = 0.01–0.14$) for ultrasound-based differentiation between benign and malignant breast lesions. They obtained 480 images of 96 benign lesions and 467 images of 144 malignant lesions retrospectively for training purposes. A deep learning model was built using the CNN architecture GoogLeNet and used to evaluate test data consisting of 48 benign and 72 malignant lesions. To conclude, the CNN model and radiologists had a sensitivity of 0.958 and 0.583–0.917, specificity of 0.925 and 0.604–0.771, and accuracy of 0.925 and 0.658–0.792, respectively.[29] Tanaka *et al.* concluded that the CNN-based CAD method is intended to support physicians in the detection and clinical practice of breast cancer utilizing deep learning with ultrasound images. The images of 1536 breast masses (897 malignant and 639 benign) were taken using various angles by an ultrasound imaging probe from a large-scale clinical trial performed by the Japan Association of Breast and Thyroid Sonography. They used two fine-tuned CNN models (VGG19 and Res152) trained through augmentation, applied a mass level classification method to enable the CNN to classify a lesion using all views. Independent test set constituting 154 masses (77 malignant and 77 benign) revealed a sensitivity of 90.9% (95% confidence interval 84.5–97.3), a specificity of 87.0% (79.5–94.5), and an AUC of 0.951 (0.916–0.987) compared to that of the two CNN models.[30] Another study uses shear-wave elastography data to suggest a segmentation-free radiomics system for classifying malignant and benign breast tumors.[31]

ADVANTAGES OF USING AI WITH SONOGRAPHY IMAGES

Ultrasound is the modality used traditionally for distinguishing between benign and malignant breast masses. Its use has increased substantially as it can also detect mammographically occult cancers. Its non-ionizing nature, ease to use, affordability, and capability to provide real-time feedback and tracking are advantageous compared to other modalities such as mammography, DBT, and MRI.[28]

In recent years, AI algorithms have been increasingly applied to breast USG, mostly in feasibility studies for automated detection, differential diagnosis, and segmentation.

The studies reveal that AI can help revolutionize USG algorithms by making them accessible even in settings with a lack of expert radiologists. Apart from reducing the radiologists' workload and improving workflow productivity, AI systems offer a second opinion on results that are missing or misinterpreted and help to avert perception errors.[32]

CHALLENGES FACED USING AI WITH SONOGRAPHY IMAGES

An AI technology is guided by the volume and consistency of training data. The substantial AI model for USG can only be developed using a multivendor, large-scale dataset with a wide-ranging spectrum of benign and malignant pathologies. The same lesion is quantified in various forms because of different ultrasound equipment with various transducers and technical settings. Older ultrasonographic images have lower resolution and higher noise, whereas newer ones have higher resolution and lower noise. The training dataset used in older algorithms may not be valid for modern images.[33]

The number of images used per patient in AI development has not been made consistent. For most training and validation, though more than 1 image per patient is needed, but based on the recently proposed Checklist for AI in Medical Imaging, specific details on the number of patients and images are also required.

Additional documentation might be required to include specifications for a generalizable AI system that targets various datasets (training/validation/test). The requirement of a large number of annotated images (usually more than thousands), being both time and labor intensive, impedes the development of well-performing and stable AI systems, not to mention the subjective bias that may come into play. Hence the role of semi-supervised methods is elevated, as it reduces the number of images to be manually labelled, allowing for a larger dataset than would otherwise have been possible. The images are usually cropped with a fixed margin around the region of interest after the image annotation. Then, these images are resized to a fixed size before adding them as an input to AI models. Most of the recent algorithms were trained using data from a small range of institutions and ultrasound systems, so they do not work well in varied environments.

Data augmentation constitutes a series of data manipulation methods, such as flipping, rotation, translation, and the addition of noise to create new images. It avoids overfitting and increases the volume of data. Even though processes such as resizing and data augmentation are necessary for AI model training, they change the characteristics of breast lesions and might reduce the classification performance. Byra *et al.* proposed that images should not be rotated with shifts in the longitudinal direction. For example, the posterior acoustic shadowing suggesting a malignant lesion gets anterior by longitudinal flipping.[34,35]

MRI BREAST

Multiparametric assessment of breast lesions helps in differentiating benign and malignant lesions.

AI AND MRI

One hundred and eleven breast DCE MRI examinations (54 malignant and 57 benign lesions) were evaluated with the improvement of the average AUC of all readers from 0.71 to 0.76 ($P = 0.04$) when using the AI system.[36] The CADx device was trained using a training sample of 121 breast lesions (77 malignant and 44 benign). Six breast imaging radiologists evaluated the risk of malignancy and the need for biopsy using a different test set of 60 lesions (30 malignant and 30 benign). As CADx was used, radiologists' overall output was substantially increased, as shown by improvements in the mean area under the receiver operating characteristic curve (from 0.80 to 0.84, $P = 0.007$), mean sensitivity (from 83 to 88%, $P = 0.001$), and the average number of biopsy referrals for malignant cases (1.7 additional biopsies for malignant lesions for CADx use, $P = 0.001$). While the mean specificity increased (from 50% to 53%), the rise was not statistically relevant ($P = 0.2$).[37]

ADVANTAGES OF USING AI WITH MRI

Availability of potentially extractable large data sets from MRI breast eases its use for AI applications. MR images encompass hidden information that is not always perceivable from human interpretation but can be extracted using machine learning methods and analyzed for a better disease understanding. It aids in faster, accurate, and tailored diagnosis and prognosis.[38]

CHALLENGES FACED USING AI WITH MRI

Training data sets for deep learning networks require annotated images, and extracting information from multimodal image processing is a significant challenge for AI in medical imaging.[39] DCE MRI and DWI are complicated advanced breast imaging methods. The hardware and software configurations used by various vendors may result in visible variations in image quality and appearance. Besides that, acquisition guidelines differ significantly within different suppliers and can require various spatiotemporal resolutions, contrast agents, and imaging parameters (TR, TE, fat suppression, etc.). Post-processing, such as tumor delineation and segmentation, can further complicate this image. Quantitative functions, either manually engineered or taught by CNNs, are used in machine learning models and can be significantly influenced by such improvements. Due to the impossibility of gathering data for all potential acquisition protocols, these factors must be carefully addressed during the creation, preparation, and evaluation of machine learning models. The challenge of developing stable machine learning models that generalize through several contexts remains, in several respects, an accessible research issue. Another crucial concern to answer is whether CNN-based features are more immune to certain differences than hand-engineered features. There are two approaches to building efficient machine learning models independent of acquisition parameters: Image standardization/harmonization and more robust feature extraction/selection.[40] However, further research is needed to examine a wider variety of imaging parameters and functions.

CONCLUSION

We are just at the inception stage of AI-based breast imaging. Rapid advancements in imaging technologies and algorithms have paved the way for modern clinical applications of AI, including detection, management, prognosis, and risk assessment. Images, in addition to hereditary, pathologic, and clinical factors, are particularly relevant in the study of breast cancer. Despite the escalating published research on this topic, the current analysis offers an overview of a paradigm that is likely to develop in the immediate future. Radiologists today have expanded imaging capability and access to imaging datasets due to the advancement of newer imaging techniques. The integration of an AI enabled breast imaging workflow helps to act as a catalyst for personalized, multidisciplinary applications, and clinical strategic coordination from various data sources.

REFERENCES

1. Winsberg F, Elkin M, Macy J, Bordaz V, Weymouth W. Detection of radiographic abnormalities in mammograms by means of optical scanning and computer analysis. Radiology 1967;89:2115.
2. Kruger RP, Townes JR, Hall DL, Dwyer SJ 3rd, Lodwick GS. Automated radiographic diagnosis via feature extraction and classification of cardiac size and shape descriptors. IEEE Trans Biomed Eng 1972;19:174-86.
3. Gizaw Z. Public health risks related to food safety issues in the food market: A systematic literature review. Environ Health Prev Med 2019;24:68.
4. Fazal MI, Patel ME, Tye J, Gupta Y. The past, present and future role of artificial intelligence in imaging. Eur J Radiol 2018;105:246-50.
5. Dustler M, Andersson I, Förnvik D, Tingberg A. The Effect of Breast Positioning on Breast Compression in Mammography: A Pressure Distribution Perspective. In: Medical Imaging: Physics of Medical Imaging. International Society for Optics and Photonics. SPIE Medical Imaging Conference; 2012. p. 83134M.
6. Monticciolo DL, Newell MS, Hendrick RE, Helvie MA, Moy L, Monsees B, *et al*. Breast Cancer screening for average-risk women: Recommendations from the ACR commission on breast imaging. J Am Coll Radiol 2017;14:1137-43.
7. Mainiero MB, Moy L, Baron P, Didwania AD, diflorio RM, Green ED, *et al*. ACR appropriateness criteria ® breast cancer screening. J Am Coll Radiol 2017;14:S383-90.

8. Monticciolo DL, Newell MS, Moy L, Niell B, Monsees B, Sickles EA. Breast cancer screening in women at higher-than-average risk: Recommendations from the ACR. J Am Coll Radiol 2018;15:408-14.
9. Barlow WE, Lehman CD, Zheng Y, Ballard-Barbash R, Yankaskas BC, Cutter GR, *et al*. Performance of diagnostic mammography for women with signs or symptoms of breast Cancer. J Natl Cancer Inst 2002 7;94:1151-9.
10. Mansoor A, Bagci U, Foster B, Xu Z, Papadakis GZ, Folio LR, *et al*. Segmentation and image analysis of abnormal lungs at CT: Current approaches, challenges, and future trends. Radiographics 2015;35:1056-76.
11. Gao J, Jiang Q, Zhou B, Chen D. Convolutional neural networks for computer-aided detection or diagnosis in medical image analysis: An overview. Math Bio Sci Eng 2019;15;16:6536-61.
12. Rodríguez-Ruiz A, Krupinski E, Mordang J-J, Schilling K, Heywang-Köbrunner SH, Sechopoulos I, *et al*. Detection of breast cancer with mammography: Effect of an artificial intelligence support system. Radiology 2019;290:305-14.
13. Huynh BQ, Li H, Giger ML. Digital mammographic tumor classification using transfer learning from deep convolutional neural networks. J Med Imaging (Bellingham) 2016;3:034501.
14. Goyal S. An overview of current trends, techniques, prospects, and pitfalls of artificial intelligence in breast imaging. RMI 2021;14:15-25.
15. LeCun Y, Bengio Y, Hinton G. Deep learning. Nature 2015;521:436-44.
16. Litjens G, Kooi T, Bejnordi BE, Setio AA, Ciompi F, Ghafoorian M, *et al*. A survey on deep learning in medical image analysis. Med Image Anal 2017;42:60-88.
17. Mikołajczyk A, Grochowski M. Data Augmentation for Improving deep Learning in Image Classification Problem, 2018 International Interdisciplinary PhD Workshop (IIPhDW), 2018. p. 117-22.
18. Samala RK, Chan HP, Hadjiiski LM, Helvie MA, Cha KH, Richter CD. Multi-task transfer learning deep convolutional neural network: Application to computer-aided diagnosis of breast cancer on mammograms. Phys Med Biol 2017;62:8894-908.
19. Baum F, Fischer U, Obenauer S, Grabbe E. Computer-aided detection in direct digital full-field mammography: Initial results. Eur Radiol 2002;12:3015-7.
20. Armato SG 3rd, Giger ML, Moran CJ, Blackburn JT, Doi K, MacMahon H. Computerized detection of pulmonary nodules on CT scans. Radiographics 1999;19:1303-11.
21. Liang M, Tang W, Xu DM, Jirapatnakul AC, Reeves AP, Henschke CI, *et al*. Low-dose CT screening for lung cancer: Computer-aided detection of missed lung cancers. Radiology 2016;281:279-88.
22. Tajbakhsh N, Shin JY, Gurudu SR, Hurst RT, Kendall CB, Gotway MB, *et al*. Convolutional neural networks for medical image analysis: Full training or fine tuning? IEEE Trans Med Imaging 2016;35:1299-312.
23. Wang X, Liang G, Zhang Y, Blanton H, Bessinger Z, Jacobs N. Inconsistent performance of deep learning models on mammogram classification. J Am Coll Radiol 2020;17:796-803.
24. Baker JA, Lo JY. Breast Tomosynthesis: State-of-the-art and review of the literature. Acad Radiol 2011;18:1298-310.
25. Samala RK, Chan HP, Hadjiiski L, Helvie MA, Richter CD, Cha KH. Breast cancer diagnosis in digital breast tomosynthesis: Effects of training sample size on multi-stage transfer learning using deep neural nets. IEEE Trans Med Imaging 2019;38:686-96.
26. Zheng J, Lin D, Gao Z, Wang S, He M, Fan J. Deep learning assisted efficient Ada boost algorithm for breast cancer detection and early diagnosis. IEEE Access 2020;8:96946-54.
27. Crivelli P, Ledda RE, Parascandolo N, Fara A, Soro D, Conti M. A new challenge for radiologists: Radiomics in breast cancer. Biomed Res Int 2018;2018:6120703.
28. Goyal S. Essentials of abdomino-pelvic sonography In: A Handbook for Practitioners. Boca Raton: CRC Press; 2018. p. 262.
29. Fujioka T, Kubota K, Mori M, Kikuchi Y, Katsuta L, Kasahara M, *et al*. Distinction between benign and malignant breast masses at breast ultrasound using deep learning method with convolutional neural network. JPN J Radiol 2019;37:466-72.
30. Tanaka H, Chiu SW, Watanabe T, Kaoku S, Yamaguchi T. Computer-aided diagnosis system for breast ultrasound images using deep learning. Phys Med Biol 2019;64:235013.
31. Zhou Y, Xu J, Liu Q, Li C, Liu Z, Wang M, *et al*. A radiomics approach with CNN for shear-wave elastography breast tumor classification. IEEE Trans Biomed Eng 2018;65:1935-42.
32. Kim J, Kim HJ, Kim C, Kim WH. Artificial intelligence in breast ultrasonography. Ultrasonography 2021;40:183-90.
33. Park SH. Artificial intelligence for ultrasonography: Unique opportunities and challenges. Ultrasonography 2021;40:3-6.
34. Byra M, Galperin M, Ojeda-Fournier H, Olson L, O'Boyle M, Comstock C, *et al*. Breast mass classification in sonography with transfer learning using a deep convolutional neural network and color conversion. Med Phys 2019;46:746-55.
35. Yu AC, Eng J. One algorithm may not fit all: How selection bias affects machine learning performance. Radiographics 2020;40:1932-7.
36. Jiang Y, Edwards AV, Newstead GM. Artificial intelligence applied to breast MRI for improved diagnosis. Radiology 2021;298:38-46.
37. Shimauchi A, Giger ML, Bhooshan N, Lan L, Pesce LL, Lee JK, *et al*. Evaluation of clinical breast MR imaging performed with prototype computer-aided diagnosis breast MR imaging workstation: Reader study. Radiology 2011;258:696-704.
38. Codari M, Schiaffino S, Sardanelli F, Trimboli RM. Artificial intelligence for breast MRI in 2008-2018: A systematic mapping review. Am J Roentgenol 2019;212:280-92.
39. Le EPV, Wang Y, Huang Y, Hickman S, Gilbert FJ. Artificial intelligence in breast imaging. Clin Radiol 2019;74:357-66.
40. Chan HP, Samala RK, Hadjiiski LM. CAD and AI for breast cancer-recent development and challenges. Br J Radiol 2020;93:20190580.

How to cite this article: Goyal S, Srivastava BR. Review of Artificial Intelligence Applicability of Various Diagnostic Modalities, their Advantages, Limitations, and Overcoming the Challenges in Breast Imaging. Int J Sci Stud 2021;9(1):25-30.

Source of Support: Nil, **Conflicts of Interest:** None declared.

Print ISSN: 2321-6379
Online ISSN: 2321-595X

Review Article

Correlation of Carotid Doppler with Non-contrast Computed Tomography Head and Magnetic Resonance Imaging Brain in Patients of Acute Cerebral Ischemia

Satish Kumar Raghuwanshi[1], Sonali Kadwey[1], Lovely Kaushal[2]

[1]Junior Resident, Department of Radiodiagnosis, Gandhi Medical College and Hamidia Hospital, Bhopal, Madhya Pradesh, India, [2]Professor and Head, Department of Radiodiagnosis, Gandhi Medical College and Hamidia Hospital, Bhopal, Madhya Pradesh, India

Abstract

Introduction: Stroke is defined as an abrupt onset of neurologic deficit due to vascular cause. It is one of the leading causes of mortality and morbidity all over the world. Lesions of extra cranial carotid arteries are implicated in majority of cases of acute ischemic stroke. Carotid Doppler is a non-invasive imaging technique, with sensitivity approaching that of angiography.

Aims and Objectives: To find out correlation of carotid artery Doppler findings with NCCT head and MRI brain findings in clinically suspected acute ischemic stroke patients.

Materials and Methods: This is a hospital based prospective cross sectional study of sample size 61 subjects. The study population include patients referred to the Department of Radio-Diagnosis with clinically suspected stroke for color Doppler study of bilateral carotid artery within 7 days of onset of symptoms, underwent bilateral carotid artery colour Doppler study, subsequently NCCT head and MRI brain scans were performed on 128 slice CT and 1.5T MRI machine. Study includes patients in duration of January 2019 to December 2020.

Results: Carotid stenosis is one of the common causes of ischemic stroke. Carotid Doppler findings is positive in 60.4% cases detected on MRI in MCA territory and right side was affected more than the left side. The prevalence of carotid stenosis increases with increase in age.Carotid stenosis is more common in male gender. Carotid artery stenosis is associated with risk factors like smoking, diabetes mellitus, hypertension and hyperlipidemia.

Conclusion: The present analysis showed that mean age was 54.26 years; mean NIHSS score was 9.41 and stroke (infarct) was more common in males in the age group of 60-69 years. Most common risk factor associated with stroke (infarct) was hypertension followed by tobacco chewing and diabetes. Sensitivity of predicting stroke by carotid Doppler is 60.4%.

Key words: Stroke, Carotid colour doppler, Non contrast computed tomography, Magnetic resonance imaging

INTRODUCTION

Stroke is a condition caused due to insufficient supply of blood (lack of oxygen) to the brain cells which damages them and may result in their death. Blood flow may be interrupted due to clot in the blood vessel that occludes the supply. It causes sudden loss of neurological function by disrupting the blood supply to the brain. It is the biggest cause of physical disability in developed countries, and second most common cause of death after heart attack. For management of stroke patient's main aim is to limit brain damage, prevents recurrence, and optimizes recovery. Risk factors that predispose to stroke are hypertension, hyperlipidemia, diabetes, and smoking (tobacco chewing).

The two principal pathological processes that give rise to stroke are occlusion of arteries, causing cerebral ischemia or infarction and rupture of arteries, causing intracranial

Access this article online

www.ijss-sn.com

Month of Submission : 02-2021
Month of Peer Review : 03-2021
Month of Acceptance : 03-2021
Month of Publishing : 04-2021

Corresponding Author: Dr. Sonali Kadwey, Department of Radiodiagnosis, Gandhi Medical College and Hamidia Hospital, Bhopal, Madhya Pradesh, India.

hemorrhage. Hemorrhage tends to be much more destructive and dangerous than ischemic stroke, with higher mortality rates. Ischemic stroke is much more common and has a much wider range of outcomes.

Plaque or thrombosis of the extracranial carotid arteries is one of the important risk factor for development of stroke.[1] Severe stenosis of internal carotid artery (ICA) is correlated for predicting cardiovascular ischemic events.[2] Doppler is non-invasive imaging tool for evaluation of extracranial carotid arteries, widely available with sensitivity approaching that of angiography.

Patients who had a hemispheric transient ischemic attack related to ICA disease had a high risk of stroke in the 1st few days after the transient ischemic attack. Early risk of stroke was not affected by the degree of ICA stenosis. Transient ischemic attacks are often early warning signs of artherosclerotic disease.

Imaging Modalities for Diagnosis of Stroke

Evaluation of carotid occlusive diseases may be possible non-invasively through a combination of magnetic resonance angiography (MRA) and ultrasound examinations of the carotid arteries. Carotid Doppler is a simple non-invasive screening procedure that have profound diagnostic and therapeutic implications in predicting and preventing a potentially fatal and devastating consequences of stroke. Computed tomography (CT) is extensively used for the identification of suspected stroke in the initial stages. Subtle changes in scan may reflect regions of cytotoxic edema which results in ischemia. In the first 6 h from the onset of the stroke, the CT scan fails to capture the early ischemic changes in most cases. Thus, in an emergency setting, CT is primarily used to rule out any intracerebral hemorrhage. Use of CT angiography and CT perfusion aids the analysis of stroke on a CT scan, however, at the cost of additional contrast material and radiation exposure. Conventional magnetic resonance imaging (MRI) (diffusion-weighted imaging [DWI] Sequence) is more sensitive to ischemic changes as compared to CT. Doppler sonography provides a rapid, non-invasive, relatively inexpensive, and accurate means of diagnosing carotid artery stenosis and highlighted on the importance of Doppler sonography in stroke prevention.[3] For anterior circulation stroke, thrombosis/plaque of carotid arteries of same side is an important cause.[4] To detect minimal flow Power Doppler mode is used in cases of total occlusion. Color flow imaging is superior to B-mode scanning in identification of hypoechoic plaques and degree of stenosis by directly measuring residual lumen at the site of maximum stenosis and comparing it with total lumen. Spectral waveform analysis at the maximal stenosis site was done and degree of stenosis is calculated. Peak systolic velocity (PSV) criteria, ICA/common carotid artery (CCA) PSV ratio, and ICA end diastolic velocity (EDV) were measured. Color Doppler imaging is helpful as it improves visualization of the lumen and consequently allows for more accurate placement of the cursor and correction of the Doppler angle. Carotid occlusion was diagnosed by the absence of arterial pulsations, occlusion of lumen by echogenic material, absence of Doppler flow signals, increased ICA/CCA PSV ratio, increased EDV, area of stenosis, and increased Carotid intima media thickness (CIMT).

Standard MRI T1WI and T2WI images are good at detecting vasogenic edema that is present in the subacute phase of stroke and is seen in more than 24 h to several days. Fast spin echo T2-weighted sequences can clearly demonstrate areas of edema not visible on the CT and can help identifying a subacute stroke as seen in fluid attenuated inversion recovery sequences designed to suppress signal from the cerebrospinal fluid so that it will appear dark. MR diffusion is DWI and can be obtained within 5 min and dramatically alter care, so the clinical determination of ischemic stroke can be confirmed quickly. DWI sequence of MRI is used to detect early ischemic changes (acute stroke and cytotoxic edema) with greater conspicuity than standard MRI. MRI with DWI is quickly becoming the gold standard in acute stroke imaging. DWI sequence of MRI noninvasively detects ischemic changes within minutes of stroke onset.

Aspect Score

Alberta stroke program early CT score is a quantitative 10 point topographic score. For nullifying interobserver variability of radiologist and for easy reproducibility grading system for reporting infarcts, Alberta stroke program early CT score was developed. Same aspect score is also applicable in MRI. For calculating ASPECT score, two regions are evaluated one at capsulo-ganglionic region and another at ventricular level involving centrum semiovale and corona radiata (supra ganglionic level). To calculate the ASPECT score, each region involved will get −1 score, so total score is calculated by substracting score for each region involved. No region involvement will give a score of 10 and if all regions are involved total ASPECT score will be 0.

Doppler technique

Two-dimensional gray scale can be used for measuring the intima-media thickness, which is very good marker for atherosclerosis.[5,6] Vessel wall thickness of intima-media complex >0.8 mm was considered abnormal.[7,8] The plaque morphology is related to the risk of stroke. Plaque texture was classified as being hypoechoic, echogenic, or calcified. Calcified plaque produces posterior acoustic shadowing and is common in asymptomatic individuals. Hypoechoic

plaque is characterized pathologically by containing deposits of lipid and cholesterol.[7]

Parameters measured included[9] PSV and peak EDV. Carotid occlusion was diagnosed by – the absence of arterial pulsations, occlusions of lumen by echogenic material, and absence of Doppler flow signals and sub-normal vessel size (chronic occlusion).

Modern medicine provides several techniques for stroke diagnosis. Evaluating the patient on a neurological examination (NIHSS),[10] *in vivo* imaging techniques such as Carotid Doppler, CT and magnetic resonance imaging are necessary for diagnosis and thrombolytic therapy with tissue plasminogen activator (tPA) within 3 h of ischemic stroke onset, intra-arterial thrombolysis within 6 h and mechanical thrombectomy,[11] are the established practices followed for stroke diagnosis and treatment.

Epidemiology and Etiology of Stroke

Annually, there are nearly 800000 strokes in the United States and 15 million strokes worldwide. Stroke is the third leading cause of death in western societies and the leading cause of long-term disability in the United States. Ischemic stroke is more common (85%) then hemorrhagic stroke and can be classified into two broad categories.

Embolic

Causes of embolic stroke may be arterial (e.g., aortic artheroma or atherosclerosis in the carotid, vertebral or basilar arteries) or cardiac (e.g., left ventricular thrombus, post-myocardial infarction, atrial fibrillation and valvular disorders) in origin. Atherosclerotic disease of the extracranial carotid arteries has long been recognized as the frequent source of emboli that travel to the brain causing stroke.[12]

Thrombotic

Thrombotic stroke may be caused by stenosis of smaller intracerebral arteries, a hyper-coagulable state or a systemic inflammatory condition.

Pathophysiology

Reduction in the flow of blood to any part of the brain first causes Ischemia, reversible loss of function and then, if reduction is severe or prolonged, infarction with irreversible cell death. The blood supply to the anterior parts of the brain comes from the two carotid arteries, which give rise to the internal carotid arteries; these again give rise to the anterior and middle cerebral arteries. The basilar artery formed by two vertebral arteries which give rise to posterior cerebral artery which is supplying the posterior aspect of brain, thalami, mid brain, and pons.

The CCA is divided into the internal and external carotids at the C4-5 level in 50% of the patients. In approximately 40% of patients, the bifurcation is higher, and it is lower in the remaining 10%. The circle of Willis provides collateral flow between the left and right hemispheres of the brain and connects the anterior and posterior circulation. Plaque or thrombus of the ICA near the burfurcation is the most important cause of stroke.[13]

The NIH stroke scale is commonly used clinical score that was built to assess the cognitive effects of stroke. It gives quantitative measure of stroke related neurologic dysfunction. It is now used by health professionals to determine the severity of stroke. It also helps create a common language between all people involved in stroke patient's treatment. In a treatment setting, the scale has three major purposes:

- It evaluates the severity of stroke
- It helps determine the appropriate treatment
- It predicts patient's outcomes.

Strokes may be classified and dated as:

- Early hyperacute (0–6 h old)
- Late hyperacute (6–24 h old)
- Acute (24 h to 7 days)
- Subacute (1–3 weeks)
- Chronic (more than 3 weeks old).

Stroke Complications

Malignant edema and hemorrhagic transformation are the most feared complications of ischemic stroke.[14,15] Hemorrhagic transformation is a common complication of severe stroke.[16-18]

Treatment

Therapeutic clot removal can be achieved mechanically (thrombectomy) or by dissolving the thrombus using clot busting drugs (thrombolysis). Thrombectomy is the removal of blood clots in the cerebral arteries by interventional neuroradiological methods. Thrombolysis rapidly recanalizes the occluded artery and improves the chances for a good neurological outcome in acute ischemic stroke using recombinant tPA (rtPA).[11]

Aims and Objectives

The aim of the study was to find out correlation of carotid artery Doppler findings with non contrast CT (NCCT) head and MRI brain findings in clinically suspected acute ischemic stroke patients.

MATERIALS AND METHODS

Study Design

This is a hospital-based prospective cross-sectional study of sample size 61 subjects. The study population include

patients referred to the department of radio-diagnosis with clinically suspected stroke for color Doppler study of bilateral carotid artery within 7 days of onset of symptoms underwent bilateral carotid artery color Doppler study on MINDRAY ultrasound and color Doppler machine, subsequently all NCCT head and MRI scans were performed on 128 slice HITACHI and 1.5Tesla HITACHI MRI machine. Study includes patients in duration of January 2019 to December 2020. Complete evaluation of all patients was done includes their history of risk factors (tobacco chewing, hypertension, ischemic heart disease, smoking, and diabetes), clinical evaluation as per NIHSS format, carotid color Doppler format, NCCT head and MRI brain reporting format as per ASPECT scale. Data are collected, systematic analysis of data was performed and statistical test applied.

- Descriptive statistical analysis was carried out with Statistical Package for the Social Sciences (SPSS Complex Samples) Version 21.0 for windows. Results on continuous measurements are presented as Mean ± SEM and results on categorical measurements are presented in number (%). Significance is assessed at a level of 1%. Correlation of data done using Pearson correlation coefficient using SPSS.

RESULTS

All statistical calculations were done by SPSS software applying Pearson correlation coefficient, scatter graph was generated and r value was calculated using $P < 0.01$. In the duration of this study, total of 61 patients with ischemic stroke were evaluated by carotid Doppler, NCCT head, and DWI sequence of MRI within 7 days of stroke onset. The present analysis showed that mean age was 54.26 years; mean NIHSS score was 9.41; and stroke (infarct) was more common in males in the age group of 60–69 years [Table 1]. Most common risk factor associated with stroke (infarct) was hypertension, followed by tobacco chewing and diabetes.

Carotid Doppler findings were correlated with infarct detected by DWI sequence of MRI in middle cerebral artery (MCA) territory [Figure 1]. Carotid Doppler findings were also correlated with NCCT head findings and NCCT head findings were also correlated with infarct diagnosed by MRI [Figures 2-5]. Most frequent NIHSS score is between 6 and 10. In carotid Doppler most common artery affected was CCA. The plaques were classified according to their anatomical location .The right side was affected more than the left side. Most common MRI DWI MCA ASPECT score is between 4 and 7. Infarct is seen most commonly in MCA territory in 70.4 % cases.

Pearson correlation coefficient for PSV of ICA with MRI DWI MCA ASPECT score is –0.455. It suggests negative correlation of PSV of ICA with MRI DWI MCA ASPECT score, finding suggesting increase in PSV of ICA will show decrease in ASPECT score. Pearson correlation coefficient for grey scale ultrasound of carotid artery with MRI DWI MCA ASPECT score and NCCT ASPECT score is –0.696 and –0.546, respectively. It suggests negative correlation of grey scale ultrasound with MRI DWI MCA and NCCT ASPECT score, finding suggesting increase in plaque will show decrease in ASPECT score. Pearson correlation coefficient for percentage of stenosis of carotid artery with MRI DWI MCA and NCCT ASPECT score is –0.785 and –0.579. It suggests negative correlation of percentage stenosis of carotid artery with MRI DWI MCA and NCCT ASPECT score, finding suggesting increase in grade of stenosis of carotid artery will show decrease in ASPECT score. Pearson correlation coefficient for CIMT of carotid artery with MRI DWI MCA and NCCT ASPECT score is –0.745 and –0.586. It suggests negative correlation of CIMT of carotid artery with MRI DWI MCA and NCCT ASPECT score, finding suggesting increase in CIMT of carotid artery will show decrease in ASPECT score. Pearson correlation coefficient of NCCT ASPECT score in MCA territory with MRI DWI MCA ASPECT score is 0.745, suggesting increase in ASPECT score in MCA territory in NCCT head will also show increase in MRI DWI MCA ASPECT score.

Carotid stenosis is one of the common causes of ischemic stroke. Carotid Doppler findings are positive in 60.4% cases detected on MRI in MCA territory and right side was affected more than the left side. NCCT head shows infarct in 20.9% cases, considering DWI MRI sequence as gold standard. The prevalence of carotid stenosis increases with increase in age. Carotid artery stenosis is seen in both male and female with male predominance and associated with risk factors such as smoking, diabetes mellitus, and hypertension.

A simple, non-invasive screening procedure like Doppler sonography of the carotid arteries in high risk individuals could, therefore, have profound diagnostic and therapeutic implications in predicting and preventing a potentially fatal and devastating stroke. Percentage grading of stenosis increased with an increase in age and was more prevalent in men than women. Smoking and heart disease showed maximum positive correlation with stenosis. The prevalence of severe stenosis (>70%) was low while the prevalence of mild-to-moderate stenosis (<50% and 50–69%) was quite high. Stenosis was more profound in terms of frequency and severity in men at all ages than women. Atherosclerotic plaques were mostly found at the site of carotid bifurcation.

With increase in PSV of ICA, plaque size, NCCT, and MRI DWI MCA ASPECT score decreases. Increase in

grading percentage of stenosis and CIMT of carotid artery associated with decrease in NCCT MCA and MRI DWI MCA ASPECT score.

DISCUSSION

The present analysis showed that mean age was 54.26 years; mean NIHSS score was 9.41 and stroke (infarct) being more common in age group of 60–69 years. Out of total cases, 39.4% were female and 60.6% were males. This study showed that ischemic stroke is common in both sexes with male predominance. This corresponds to study by Tegos *et al.*[19]

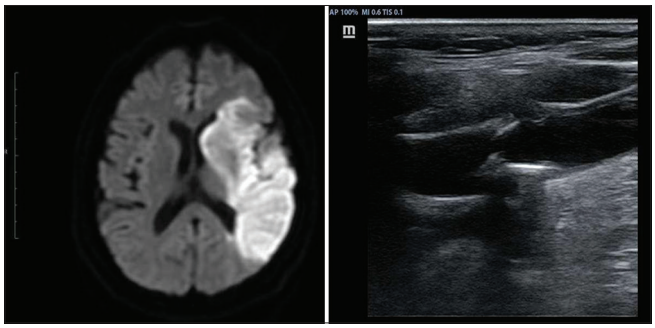

Figure 1: Magnetic resonance imaging-diffusion-weighted imaging image shows restriction in the left caudate nucleus, internal capsule, M1, M2, and M3 in middle cerebral artery distribution in a patient presenting with hemiparesis. In a same patient longitudinal grey scale ultrasound images of the left carotid artery shows echogenic plaque giving posterior acoustic shadowing noted in left common carotid artery and causing significant stenosis

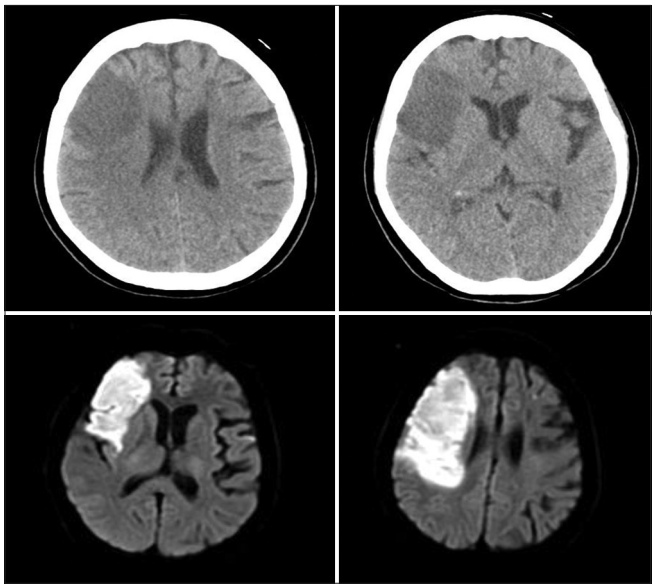

Figure 2: Non-contrast computed tomography (NCCT) and magnetic resonance imaging-diffusion-weighted imaging (DWI) brain image shows different ASPECT score in same patient with hypodensity in NCCT with involvement of M1 and M4 area only, while in DWI it shows restriction in M1, M2, M4, and M5 area as per ASPECT distribution in middle cerebral artery distribution in a patient of hemiparesis

In our study, out of total 61 cases, 24 had hypertension. Hypertension showed strongest positive correlation with ischemic stroke in territory of carotid artery which is consistent with study done by Shivani *et al.*[20]

Carotid Doppler examination aids in determining the occlusive lesions in the carotid vessels. Patients with severe stenosis (≥ 70%) are at increased risk of developing cerebral infarction.

The most common lesion was atherosclerotic plaque. Of the 61 patients examined, 26 (60.4%) patients have positive Doppler findings on carotid Doppler study, nine (20.9%) [Table 2] patients had positive findings in MCA territory in NCCT head, and 43 patients (70.4%) [Table 3] have positive findings of infarct in MCA territory in MRI. Carotid Doppler findings were positive in 60.4% cases, as detected on MRI in MCA territory. In our study, we found plaque in 60.4% cases which was more than detected by study done by Sehrawat *et al.*, (33.94%).

The plaques were classified according to their anatomical location. The right side was affected more than the left side which is consistent with findings detected by Sehrawat *et al.*

The plaques formed in the carotid vessels were divided into hypoechoic plaque, echogenic plaque, and calcified plaque. In our study, we had found that echogenic plaques

Table 1: Demographic characteristics

Age and Sex Distribution	
Age (Years) (%)	
<30	3 (4.9)
30–40	8 (13.1)
41–50	12 (19.6)
51–60	15 (24.5)
61–70	18 (29.5)
>70	05 (8.1)
Sex (%)	
Male	37 (60.6)
Female	24 (39.4)

Table 2: NCCT head findings

NCCT head findings	Number (%)
Normal	52 (85.2)
Infarct	09 (14.7)

NCCT: Non-contrast computed tomography

Table 3: MRI brain findings

MRI brain findings	Number (%)
Normal	18 (29.5)
Infarct	43 (70.4)

MRI: Magnetic resonance imaging

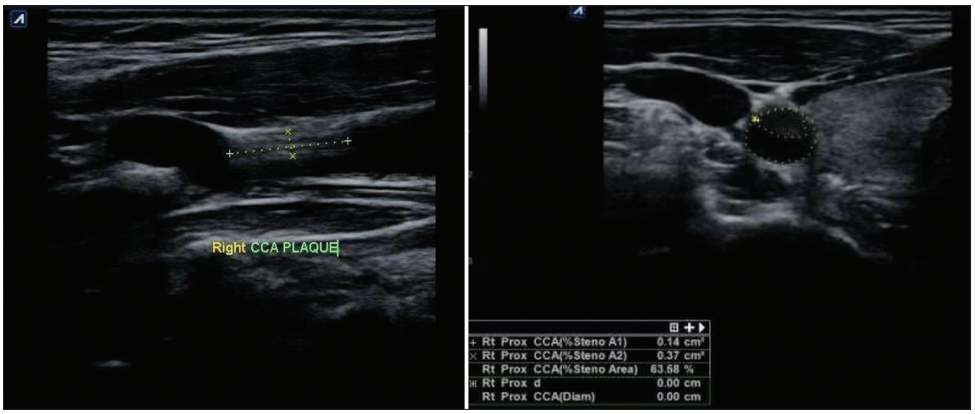

Figure 3: In same patient longitudinal and transverse grey scale ultrasound images of right carotid artery shows hyperechoic plaque in right common carotid artery causing significant 63% stenosis

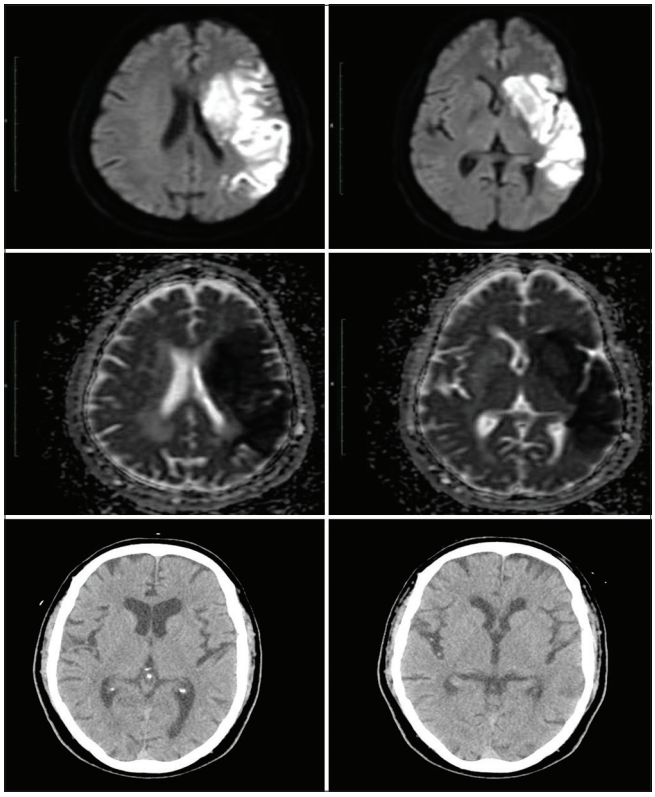

Figure 4: Magnetic resonance imaging-diffusion-weighted imaging apparent diffusion coefficient (ADC) image shows restriction in the left caudate nucleus, left internal capsule, M1, M2, M3, M4, and M5 with corresponding reduced diffusivity in ADC map in middle cerebral artery distribution in a patient who had normal non contrast computed tomography head

were more common which was consistent with findings detected by Geroulakos *et al*.

In this study, we found plaque in 26 patients, out of which 54.1% had right side involvement as compared to 45.9% on left side. This finding is more than as detected by Sehrawat *et al*.[21]

In our study, we found that the carotid bifurcation was the most common site involved by the atherosclerotic plaque,

Table 4: Grey scale USG findings in carotid duplex scan

Grey scale USG findings	Number (%)
No Plaque	35 (57.3)
Plaque in ICA	14 (22.9)
Plaque in ICA and CCA	12 (19.6)

ICA: Internal carotid artery, CCA: Common carotid artery, USG: Ultrasounds

Table 5: Percentage area of grading of stenosis in carotid duplex scan

Percentage area of grading of stenosis	Number (%)
No stenosis	35 (57.3)
<50% stenosis	13 (21.3)
50–69% stenosis	12 (19.6)
>70% stenosis	01 (0.01)

followed by ICA [Table 4]. On right side, 35% plaques were present at bifurcation and on the left side 23.5% were present at bifurcation. These findings were similar to study done by Sethi *et al*.[22]

Plaques are more common at bifurcation due to transient reversal of flow, flow separation, and eddy formation in these areas.[23] In our study, we found that the increase in CIMT of carotid artery is associated with increase in plaque formation and ischemic stroke. These findings are consistent with study done by Kazmierski *et al*.[24] and O'Leary *et al*.[25]

In our study, there was negative correlation of NCCT head MCA ASPECT score and MRI DWI MCA ASPECT score with CIMT of carotid artery, finding suggesting that NCCT head MCA ASPECT score and MRI-DWI ASPECT score decreases with increase in CIMT of carotid artery.

Our study suggested that PSV is an important flow parameter, more specifically applying to stenosis, and a predictive marker for ischemic cerebral lesions [Table 5].

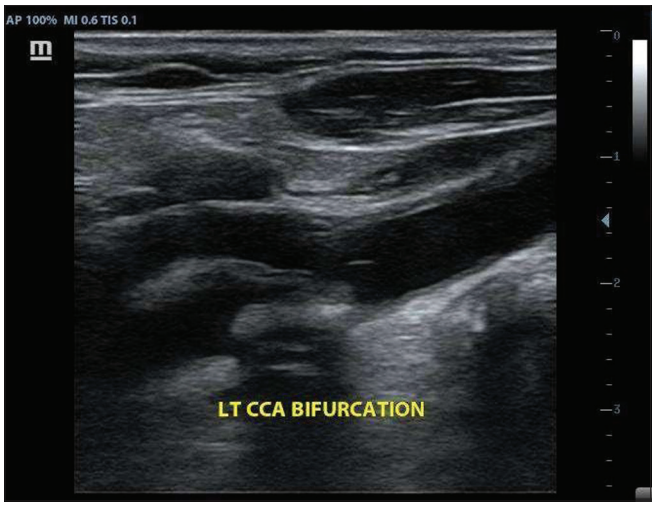

Figure 5: In same patient longitudinal grey scale ultrasound images of the left carotid artery shows echogenic plaque giving posterior acoustic shadowing noted in the left internal carotid artery and causing significant stenosis

These findings were consistent with study done by Gunduz *et al.*[26]

Out of 26 cases who had stenosis, the prevalence of mild stenosis (<50%) was 21.3% and moderate stenosis (50–69%) was 19.3%. This correlates with study by O'Leary *et al.*[25]

According to the criteria mentioned by Grant *et al.*, (PSV >140 cm/s was observed in patients with >70% stenosis of carotid artery), in our study, PSV increased with the increase in stenosis.[27] PSV is considered the best parameter since it is easy to measure. Grant *et al.* also found that mean PSV increases with increase in grade of stenosis.[28]

CONCLUSION

MRI is considered as gold standard for diagnosis of stroke. NCCT head is considered as prime modality in stroke patients to rule out intraparenchymal hemorrhage. Sensitivity of predicting stroke by carotid Doppler is 60.4%. This study shows that carotid Doppler is an important non-invasive diagnostic tool. It can be used for screening in high risk asymptomatic patients, patients with history of cerebral vascular event. It helps in guiding treatment. Thus, it should be used as first-line investigation in these patients and will determine treatment plan for patients in places where NCCT head and MRI brain facility is not available. It will also complement NCCT head negative patients where MRI brain facility is not available.

The importance of Doppler sonography in acute ischemic stroke patients and can serves as a screening tool where NCCT head and MRI brain facility is not available. Seventy percent of population lives in villages and cannot have access to big cities where good diagnostic infrastructure such as NCCT and MRI is available. In developing countries like India, where facilities to detect acute ischemic stroke are not available in small towns, tehsils, and even districts, Carotid Doppler can serve as low cost inexpensive tool for screening of acute ischemic stroke patients and can initially guide physicians to plan treatment.

REFERENCES

1. Gillian EM, Helen S, Anne F, Paul AO, Charles NM. Carotid disease in acute stroke. Age Ageing 1998;27:677-82.
2. Liapis CD, Kakisis JD, Kostakis AG. Carotid stenosis. Factors affecting symptomatology. Stroke 2001;32:2782-6.
3. Mohr JP, Biller J, Hilal SK, Yuh WT, Tatemichi TK, Hedges S, *et al*. Magnetic resonance versus computed tomographic imaging in acute stroke. Stroke 1995;16:807-12.
4. Murray CJ, Lopez AD. Mortality by cause for eight regions of the world: Global burden of disease study. Lancet 1997;349:1269-76.
5. Bots ML, Hoes AW, Koudstaal PJ, Hofman A, Grobbee DE. Common carotid intima-media thickness and risk of stroke and myocardial infarction: The Rotterdam Study. Circulation 1997;96:1432-7.
6. Ross R. The pathogenesis of atherosclerosis: A perspective for the 1990s. Nature 1993;362:801-9.
7. Polak JF. Carotid ultrasound. RCNA 2001;39:569-89.
8. Jadhav UM, Kadam NN. Carotid intima-media thickness as an independent predictor of coronary artery disease. Indian Heart J 2001;53:458-62.
9. Carroll BA. Carotid ultrasound. Neuroimaging Clin North Am 1996;6:875-97.
10. Gray-Weale AC, Graham JC, Burnett JR, Byrne K, Lusby RJ. Carotid artery atheroma: Comparison of preoperative B-mode ultrasound appearance with carotid endarterectomy specimen pathology. J Cardiovasc Surg (Torino) 1988;29:676-81.
11. Wardlaw JM, Murray V, Berge E, del Zoppo G, Sandercock P, Lindley RL, *et al*. Recombinant tissue plasminogen activator for acute ischaemic stroke: An updated systematic review and meta-analysis. Lancet 2012;379:2364-72.
12. Eliasziw M, Kennedy J, Hill MD, Buchan AM, Barnett HJ, North American Symptomatic Carotid Endarterectomy Trial Group. Early risk of stroke after a transient ischemic attack in patients with internal carotid artery disease. Can Med Assoc J 2004;170:1105-9.
13. Coll RE, Will RG. Diseases of nervous system. In: Edwards CR, Bouchier IA, Haslett C, Chilvers ER, editors. Davidson's Principles and Practice of Medicine. 17th ed. San Diego, CA: Harcourt Publishers Ltd.; 1996. p. 1071-8.
14. Mlynash M, Lansberg MG, DeSilva DA, Lee J, Christensen S, Straka M. Refining the definition of the malignant profile: Insights from the DEFUSE-EPITHET pooled data set. Stroke 2011;42:1270-5.
15. Saver JL. Hemorrhage after thrombolytic therapy for stroke: The clinically relevant number needed to harm. Stroke 2007;38:2279-83.
16. Hacke W, Schwab S, Horn M, Spranger M, De Georgia M, von Kummer R. 'Malignant' middle cerebral artery territory infarction: Clinical course and prognostic signs. Arch Neurol 1996;53:309-15.
17. Hatsukami TS, Ross R, Polissar NL, Yuan C. Visualization of fibrous cap thickness and rupture in human atherosclerotic carotid plaque in vivo with high-resolution magnetic resonance imaging. Circulation 2000;102:959-64.
18. Heinsius T, Bogousslavsky J, Van Melle G. Large infarcts in the middle cerebral artery territory. Etiology and outcome patterns. Neurology 1998;50:341-50.
19. Tegos TT, Kalodiki E, Sabetai MM, Nicolaides AN. The genesis of atherosclerosis and risk factors: A review. Angiology 2001;52:89-98.
20. Lyden P, Lu M, Jackson C, Marler J, Kothari R, Brott T, *et al*. Underlying structure of the National Institutes of Health Stroke Scale: Results of a factor analysis. NINDS tPA Stroke Trial Investigators. Stroke 1999;30:2347-54.
21. Sehrawat S, Singh S, Singh V, Kuber R, Naware S, Shrotri H, *et al*. Colour Doppler evaluation of extracranial carotid artery in patients presenting with features of cerebrovascular disease. Med J Dr. D. Y. Patil Vidyapeeth 2012;5:137-43.

22. Sethi SK, Solanki RS, Gupta H. Colour and duplex doppler evaluation of extracranial carotid artery in patients presenting with transient ischemic attack and stroke- a clinical and radiological correlation. Indian J Radiol Imaging 2005;15:91-8.
23. Philips DJ, Green FM Jr., Langlois Y, Roederer GO, Strandness DE. Flow velocity patterns in the carotid bifurcations of young, presumed normal subjects. Ultrasound Med Biol 1983;9:39-49.
24. Kaźmierski R, Watała C, Podsiadły E, Dorszewska J, Adamczewska-Goncerzewicz Z, Tylewska-Wierzbanowska S, *et al*. Carotid intima-media thickness better differentiates between groups of stroke patients and persons without cerebrovascular disease than other conventional and novel risk factors. Folia Morphol (Warsz) 2004;63:253-60.
25. Polak JF, Tracy R, Harrington A, Zavodni AE, O'Leary DH. Carotid artery plaque and progression of coronary artery calcium: The multi-ethnic study of atherosclerosis. J Am Soc Echocardiogr 2013;26:548-5.
26. Gunduz Y, Akdemir R, Ayhan LT, Keser N. Can doppler flow parameters of carotid stenosis predict the occurrence of new ischemic brain lesions detected by diffusion-weighted MR imaging after filter-protected internal carotid artery stenting? AJNR Am J Neuroradiol 2014;35:760-5.
27. Grant EG, Benson CB, Moneta GL, Alexandrov AV, Baker JD, Bluth EI, *et al*. Carotid artery stenosis: Gray-scale and doppler US diagnosis--Society of Radiologists in Ultrasound consensus conference. Radiology 2003;229:340-6.
28. Grant EG, Duerinckx AJ, El Saden AM, Melany ML, Hathout GM, Zimmerman PT, *et al*. Ability to use duplex US to quantify internal carotid arterial stenoses: Fact or fiction? Radiology 2000;214:247-52.

How to cite this article: Raghuwanshi SK, Kadwey S, Kaushal L. Correlation of Carotid Doppler with Non-contrast Computed Tomography Head and Magnetic Resonance Imaging Brain in Patients of Acute Cerebral Ischemia. Int J Sci Stud 2021;9(1):31-38.

Source of Support: Nil, **Conflicts of Interest:** None declared.

Print ISSN: 2321-6379
Online ISSN: 2321-595X

Expert Opinions

Clinical Efficacy of Favipiravir Therapy against Coronavirus Disease 2019

Akash Juneja[1], Anil Vardani[2], Balbir Singh Gandhi[3], BK Agarwal[4], DK Chauhan[5], Surya Dev Chauhan[6], Ram Niwas Patel[7], Sanjay Jain[8], Sanjay Raina[9], Sudhir Oswal[10]

[1]ENT, Department of Pediatric Otorhinolaryngologist, Otologist, Neurotologist, [2]Director, Department of Internal Medicine, BLK Super Speciality Hospital, Rajendra Place, New Delhi, India, [3]ENT Specialist, [4]Head, Department, Department of Medicine, Sant Parmanand Hospital, Civil Lines, New Delhi, India, [5]Consultant Physician and Child Specialist, [6]Telemedicine, Private Practice, [7]Senior Consultant Physician, Baba Ramdev Hospital, Jodhpur, Rajasthan, India, [8]ENT/Otorhinolaryngologist, [9]Senior Consultant, Bhagwan Mahavir Hospital and Heart Institute, Pitampura, New Delhi, India, [10]Cardiologist

Antiviral therapy shortly after symptom onset reduces viral load, limits disease progression, shortens the course of clinical illness and prevents subsequent consequences.[1,2]

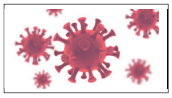

Need for early antiviral therapy

Viral load peaks at around 5–6 days after symptom onset and lasts up to 14 days[3]

Within 9-12 days, increased viral load disregulates immune response and leads to cytokine storm[4,5]

~15% of COVID-19 patients will develop severe lung disease after 7-14 days[6]

Continuation of 14-day antiviral therapy seems important despite negative RT-PCR test.[3-8]



Negative test does not mean recovery from COVID-19![7]

- Test results are influenced by stage of infection, quality of specimen, presence of virus in other organs, and variable sensitivity and specificity of the employed test[8]
- Recovery assessment should include duration, severity fluctuating symptoms, and functionality and quality of life[7]

14-day favipiravir therapy demonstrated 94% response rate and better recovery[9]

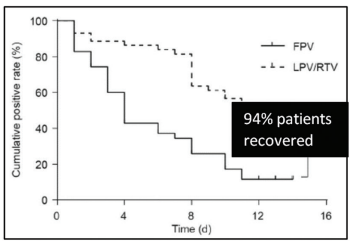

The median time of viral clearance for the patients treated with favipiravir was estimated to be 4 days (IQR: 2.5–9)

Improved clinical status at 14 days after starting favipiravir treatment[10]

88% Mild disease

84% Moderate disease

Dr. Akash Juneja
M.B.B.S., M.S. - ENT
ENT/Otorhinolaryngologist
Pediatric Otorhinolaryngologist
Otologist/Neurotologist

I have treated many coronavirus disease (COVID) patients with oral antiviral therapy, especially with favipiravir along with other supportive medicine, and I am satisfied with the response of COVID patients to favipiravir therapy. I strongly recommend initiation of oral antiviral therapy as soon as reverse transcription polymerase chain reaction test comes positive to patients having mild symptoms such as fever, dry cough, headache, or diarrhea. The 14-day favipiravir therapy should be given as early phase therapy, because it helps in rapid reduction in the viral load, faster clinical recovery, prevents progression to severe and critical stage, and prevents development of cytokine storm. I have seen many patients recover in 7-10 days after initiation of therapy. Most of the symptoms were absent after 10 days, and very rare side effects were reported with oral antiviral favipiravir therapy. It prevents progression of disease to severe cases and averts the need for hospitalization, thus reducing the overall cost of treatment. I strongly recommend favipiravir therapy in mild-to-moderate COVID patients, as it helps in early recovery and better patient prognosis with least side effects.

Access this article online

IJSS
www.ijss-sn.com

Month of Submission : 02-2021
Month of Peer Review : 03-2021
Month of Acceptance : 03-2021
Month of Publishing : 04-2021

Corresponding Author: Scientimed Solutions Private Limited, B/44, 1st Floor, Nand Bhavan, Mahakali Caves Road, Opposite Onida House and Near McDonalds, Andheri (East), Mumbai, India.

Dr. Anil Vardani
M.B.B.S., M.D. (Medicine)
Director in Internal Medicine Department at BLK Super Speciality Hospital, New Delhi

I frequently prescribe favipiravir in COVID-19 pandemic, especially in patients with early disease stages. It is highly effective as an early antiviral therapy in patients with mild-to-moderate disease. People who have received favipiravir did not have any serious complications, and did not show disease progression. Only one or two cases may need further management with other injectable antiviral drug. In my opinion, around 70–80% of patients show immediate clinical response within 1–2 days with early favipiravir therapy.

Dr. Balbir Singh Gandhi
M.B.B.S., M.D.
ENT Specialist

Severe acute respiratory syndrome coronavirus 2 (SARS-COV-2) is a positive sense single-stranded RNA virus and has incubation period of 2 weeks. Viral shredding is seen 1–2 days before symptoms and may continue for 1–2 weeks in mild-moderate cases, and in severe cases may go beyond 2 weeks. About 80% of patients have no symptoms. However, in elderly population and patients with comorbid conditions, risks of infection, and severity of symptoms are very high. Symptoms usually appear between 2 and 14 days after exposure. Shortness of breath can occur, which leads to progressive illness (severe in 14% and critical in 5%) including the hyperinflammatory response causing multiorgan failure. Not only in patients with mild-to-moderate symptoms managed at home, this drug has also been useful in COVID-19 patients with moderate symptoms who were discharged earlier from hospital. Also provision of multiple treatment benefits include faster time to clinical cure and delay in the need for supportive oxygen therapy.

It has been observed that antiviral drugs interfere with the viral cycle inside the host cell, hence reducing the viral load and viral shredding. Thus, the antiviral drugs administered shortly after the onset of symptoms can shorten the course of disease and also reduce the spread of infection by reducing viral shredding. It has been reported that if a patient receives antiviral therapy in the early phase of infection, there is a high chance of decreased viral shredding and also the intensity of symptoms as well.

Favipiravir, an oral, broad-spectrum RdRp inhibitor, has an established safety profile and also has effective concentration against it the SARS-COV-2 infection. Being an oral formulation and 80% of patients having mild-to-moderate COVID-19 infection, it is effective and useful in a sizeable majority of population of COVID-19 on outpatient basis.

Most frequent side effects observed were mild-to-moderate diarrhea and decreased neutrophil counts in some patients.

Dr. B.K. Agarwal
M.B.B.S., M.D. (Medicine)
HOD (Head of Department) Medicine, Sant Parmanand Hospital, Delhi

Early initiation of antiviral therapy is an appropriate way to manage COVID-19 and has better prognosis. If a patient has tested positive for COVID and is observed to be in the early phase of viral infection suffering from mild or moderate symptoms, it is better to initiate antiviral therapy as soon as possible.

Antiviral drug favipiravir has been a good choice of drug for rapid reduction of viral load and faster clinical recovery. It is crucial to consider the duration of therapy to achieve expected results. Favipiravir 14-day therapy after positive COVID test has shown better clinical improvement and overall recovery.

I have used this in large number of patients and found excellent results, with very good recovery rate. None of my patients suffered from any complications or side effects caused by this drug.

Dr. DK Chauhan
Consultant Physician and Child Specialist (M.B.B.S., M.C.A.I., M.N.C.P., M.A.C.C.P., D.D.M.).
Dr. Surya Dev Chauhan
M.B.B.S.
Telemedicine, Private Practice

The novel coronavirus, after getting attached to the cell surface, gets internalized, and begins to express and rapidly replicate its genomic RNA to produce full-length copies, that are then incorporated into newly produced viral particles. After certain such cycles of viral replication inside the cell, the cell is lysed and virions are secreted from the infected cell by exocytosis. These virions breakthrough and infect other cells. Viral genomic replication is initiated by the synthesis of full-length negative-sense genomic copies; the latter function as templates for the generation of new positive-sense genomic RNA. These newly synthesized genomes are used for translation to generate more nsps and replication-transcription complexes or are packaged into new virions.

Now, this cellular debris and viruses are highly immunogenic and thrombogenic material. The more the number of viruses and dead cells, the worst the outcome may become. The increasing viral load in the host warrants an effective and safe antiviral drug that will reduce the complications. This is where favipiravir has its role.

The key to success lies in identifying the disease early, and treating it with effective antiviral drugs at its early stage wherein the viral replication has not yet been boosted many fold.

If the medicine is initiated late; say on the 10th day; the antiviral will not have much role to play at this juncture. Probably, this is the time when we are required to modify the immune system to mitigate the viruses' ill effects.

I have used favipiravir in hundreds of patients with excellent results. It leads to faster resolution of fever and speedy recovery. Of course, most of the patients exhibited mild-to-moderate symptoms, and did not require hospitalization. Furthermore, there were no significant adverse events requiring discontinuation of the drug. All the patients could complete the entire course of the medication.

Dr. Ram Niwas Patel
M.D. Medicine
Senior Consultant Physician, Baba Ramdev Hospital, Jodhpur

Initial viral replication phase is the most important segment of the disease progression. Appropriate treatment intervention at this stage helps in preventing severe and critical disease state which is characterized by cytokine storm.

Antiviral therapy for initial 14 days after symptom onset and positive test result is advised. The duration is important from the point of view of long-term improvement and prevention of severe disease. It is advisable to continue 14-day antiviral therapy even if the test results are negative.

Dr. Sanjay Jain
M.B.B.S., M.S. Otorhinolaryngology
Practicing ENT/Otorhinolaryngologist with an experience of 27 years in New Delhi

Favipiravir has demonstrated promising results in the treatment of mild-to-moderate COVID-19. Fourteen-day antiviral therapy with favipiravir, if started in early phase of the illness, provides faster clinical recovery and prevents cytokine storm and progression to severe/critical stage.

Dr. Sanjay Raina
M.B.B.S., M.D. (Medicine)
Senior Consultant – Bhagwan Mahavir Hospital and Heart Institute, Delhi
Consultant – Saroj Hospital and Heart Institute, Delhi

I have personally used favipiravir in more than 300 COVID-19 patients and found wonderful results.

I observed faster clinical recovery and rapid reduction in viral load.

It prevented most of my patients from progressing to severe and critical stage, and also prevented cytokine storm. In fact, very less number of my patients required admission and could be managed with home quarantine with 14 days therapy.

Favipiravir should be started at the earliest stage in mild-to-moderate cases to get very good results.

Dr. Sudhir Oswal
M.B.B.S., M.D.
Cardiologist

Increased viral load is associated with worse disease severity, lower lymphocyte counts, and increased systemic inflammation, which further increase the risk of complications and mortality. Thus, it is necessary to prevent progression of the disease in the initial phase itself.

Antiviral drugs are effective in declining viral load by reducing viral replication and associated cascade events leading to irreversible severe state of the disease.

Symptom onset and positive COVID-19 test should prompt initiation of antiviral drug at the earliest post-detection.

REFERENCES

1. Vora A, Tiwaskar M. Favipiravir. J Assoc Physicians India 2020;68:91-2.
2. Joshi S, Parkar J, Ansari A, Vora A, Talwar D, Tiwaskar M, *et al*. Role of favipiravir in the treatment of COVID-19. Int J Infect Dis 2020;102:501-8.
3. Mitjà O, Clotet B. Use of antiviral drugs to reduce COVID-19 transmission. Lancet Glob Health 2020;8:e639-40.
4. Khadke S, Ahmed N, Ahmed N, Ratts R, Raju S, Gallogly M, *et al*. Harnessing the immune system to overcome cytokine storm and reduce viral load in COVID-19: A review of the phases of illness and therapeutic agents. Virol J 2020;17:154.
5. Tang Y, Liu J, Zhang D, Xu Z, Ji J, Wen C. Cytokine storm in COVID-19: The current evidence and treatment strategies. Front Immunol 2020;11:1708.
6. Hossen MS, Barek M, Nusrat J, Mohammad I. A review on current repurposing drugs for the treatment of COVID-19: Reality and challenges. SN Compr Clin Med 2020;2020:1-13.
7. Alwan N. A Negative COVID-19 Test does not Mean Recovery. Available from: https://www.media.nature.com/original/magazine-assets/d41586-020-02335-z/d41586-020-02335-z.pdf. [Last accessed on 2020 Dec 23].

8. Adapted from SRL Diagnostics Report of SARS-CoV-2, Real time RT-PCR Test.
9. Cai Q, Yang M, Liu D, Chen J, Shu D, Xia J, *et al*. Experimental treatment with favipiravir for COVID-19: An open-label control study. Engineering (Beijing) 2020;6:1192-8.
10. Interim Report of the Favipiravir (Avigan) Observational Study. Available from: https://www.fujita-hu.ac.jp/en/news/kka9ar0000000ep3.html. [Last accessed on 2020 Dec 23].

How to cite this article: Juneja A, Vardani A, Gandhi BS, Agarwal BK, Chauhan DK, Chauhan SD, Patel RN, Jain S, Raina S, Oswal S. Clinical Efficacy of Favipiravir Therapy Against Coronavirus Disease 2019. Int J Sci Stud 2021;9(1):39-42.

Source of Support: Nil, **Conflicts of Interest:** None declared.

Print ISSN: 2321-6379
Online ISSN: 2321-595X

Original Article

"War of the Varnishes – A Comparative Evaluation between Three Remineralizing Agents Using Confocal Microscopy"

Charles James[1], Parvathy Premnath[2], Basil Joseph[3], S Vidhya Shankari[4]

[1]CRRI, ASAN Memorial Dental College and Hospital, Chengalpattu, India, [2]Senior Lecturer, Department of Public Health Dentistry, ASAN Memorial Dental College and Hospital, Chengalpattu, India, [3]Senior Lecturer, Department Of Orthodontics and Maxillofacial Orthopaedics, ASAN Memorial Dental College and Hospital, Chengalpattu, India, [4]Senior Lecturer, Department of Endodontics and Conservative Dentistry, ASAN Memorial Dental College and Hospital, Chengalpattu, India

Abstract

Objective: Dental caries is still considered even in this day and age as the major contributor to the vast multifarious oral disease conditions affecting people all around the globe. Once thought to be irreversible, dental caries lesions are now being approached with the focus on remineralization of the tooth structure by means of artificially designed remineralizing agents. Fluoride was considered the mainstay for the remineralization regimen, but today numerous manufacturers have opened up the options with a wide selection of remineralizing products ranging from dentifrices to varnishes. The present *in vitro* study compares three such options for their efficacy in remineralizing an artificially produced carious lesion in permanent human teeth. The aim of the study was to compare and evaluate the remineralization potential of Copal Care varnish (sodium fluoride), MI varnish (Casein phosphopeptide-amorphous calcium phosphate [CPP-ACP-F]), and Cervitec F+ (chlorhexidine varnish) using confocal microscopy.

Materials and Methods: Enamel windows were created on the middle third of the buccal surface of the crown of orthodontically extracted permanent premolars. The samples were demineralized, sectioned using a hard tissue microtome and randomly divided into three experimental groups of 10 each. Group A specimens were coated with Copal Care varnish, Group B with MI varnish, and Group C with Cervitec F+ varnish using applicators for 60 s. The samples were then subjected to a pH cycling for a period of 5 days, where the samples underwent cyclic demineralization and remineralization within the respective artificially prepared solutions. The samples after pH cycling were subjected to confocal scanning microscopic analysis and the collected data were tabulated and statistically analyzed using SPSS software (version 27). The data were subjected to Fisher's paired *t*-test and one-way ANOVA.

Results: All the three groups showed significant remineralization of the artificial carious lesion on the confocal images. Copal Care showed the highest remineralization followed by Cervitec F+ and MI varnish. The differences in mean lesion depth values among three groups at baseline and post-treatment of all three products were found to be not statistically significant with the $P \leq 0.05$. However, the differences in mean lesion depth between the three groups were statistically significant with $P \geq 0.05$.

Conclusion: Copal Care showed the greatest remineralization potential followed by Cervitec F+ and MI varnish, respectively.

Key words: Chlorhexidine varnish, Confocal microscopy, MI varnish, Sodium fluoride varnish

INTRODUCTION

Dental caries hails even in this era of advancements as the leading cause of oral health disease that affects millions worldwide, causing substantial loss in the productive hours which amounts to significant number each year. This oral condition takes several forms and varies in intensity and frequency among individuals affecting the more industrialized population by observed trend.[1]

The concept of cariogenicity is based on two episodic processes taking place one after the other – demineralization and remineralization.[2] The two key processes rely on 4 important factors – a susceptible host, a colony of bacteria, presence of simple carbohydrates, or sugars in the diet and adequate time for the bacteria to be in contact with the sugars and to the dental hard tissues to form soluble acids mainly lactic acid.[3]

Access this article online

www.ijss-sn.com

Month of Submission : 02-2021
Month of Peer Review : 03-2021
Month of Acceptance : 03-2021
Month of Publishing : 04-2021

Corresponding Author: Charles James, CRRI, Asan Memorial Dental College and Hospital, Keerapakam, Chengalpattu, Tamil Nadu, India

The first sign of demineralization is the appearance of white spot lesions indicating a subsurface demineralization which if left uncontrolled by use of different remineralizing agents leads to cavitation. The condition is of particular concern in patients undergoing orthodontic treatment, where due to lack of proper cleansing there is a high risk for incipient lesion.[4] The major concern is the ignorance of these lesions in the beginning and use of proper protective agents, as most remain subclinical. For years fluoride has been considered the gold standard form the treatment of incipient lesions in the enamel since its development in the 1970s. The natural earth mineral is extracted and used in a surfeit range of dental care products ranging from dentifrices to varnishes.

The products all have one function, to elevate the fluoride concentration locally to strengthen the enamel structure by formation of fluoridated hydroxyapatite crystals that have an exceptional capacity to oppose demineralization when compared to naturally formed hydroxyapatite crystals. It begins to remineralize the incipient carious lesions in the presence of calcium and phosphate.[5]

Among the vast selection of fluoride products varnishes has shown the best remineralizing potential because of its better and prolonged adhesive action which increases the fluoride concentration for maximum formation of fluorapatite. Over the years, fluoride varnishes have been in supply in different concentrations of fluoride ranging from 7000 ppm to 26,000 ppm. Many studies have been conducted to study the efficacy of these various concentrations of fluoride for remineralization of enamel. In recent years, varnishes have been modified using various natural and chemical substitutes both to try increase efficacy of the product and to overcome the side effects of fluoride use at excessive concentrations.[6]

Sodium fluoride has been recognized as an efficient remineralizing agent with an effective fluoride concentration of 23,600 ppm, more than any other fluoride combinations. It interacts with the oral fluids, combines with calcium and phosphate saturated within the oral fluids, and forms fluorapatite. The efficiency of the product depends on the surface concentration of the varnish and the frequency of application.[7]

Casein phosphopeptide-amorphous calcium phosphate (CPP ACP) was introduced in the year 1998, CPP-ACP comprises nanocomplexes of milk protein CPP with ACP. It promotes remineralization of the carious lesions by maintaining a supersaturated state of essential minerals and at the same time it also hinders colonization of dental surfaces by cariogenic bacteria.[8]

Cervitec is a varnish designed for mechanical protection of the tooth structure, fluoridation, and antimicrobial action. It contains 1400 ppm fluoride from ammonium fluoride in a varnish base with ethanol and water as solvents with the additional action of 0.3% chlorhexidine (CHX).[9] The fluoride content prevents enamel demineralization, promotes re-mineralization, and exerts minimal anti-plaque action. The CHX provides the major anti-microbial cover especially against *Streptococcus mutans*, bringing complete overall protection. CHX being cationic has both hydrophilic and hydrophobic properties which help it bind to the negatively charged *S. mutans* cell wall especially in higher concentration, leading to disruption in the integrity of the cell wall, leaking of intracellular contents and finally bacterial cell death.[10]

The lack of literature on the remineralization potential and antimicrobial action of Cervitec F against *S. mutans* and a comparative evaluation between the alternatives, two widely accepted products (copal care and MI) has paved way to the present study which is a comparative evaluation between Copal Care varnish (sodium fluoride), MI varnish (cpp acp-f), and Cervitec f+ CHX varnish in remineralization of samples of enamel sections in *in vitro* and evaluation and visualization of remineralization through confocal microscopy.

MATERIALS AND METHODS

The following *in-vitro* study was conducted in the department of public health dentistry, Asan Dental College and Hospital, Chennai, India, for a period of 30 days after an ethical approval was obtained from the Institutional review board.

Sample Selection and Preparation

The sample size for the study was determined at $n = 30$ which provided a maximum of 10 samples per experimental group. Orthodontically extracted sound permanent premolars were collected in which there were no signs of caries, attrition, hypoplasia, discoloration, or any other developmental defects. The samples were put through these inclusion criteria to provide a comparatively equal rate of progression of demineralization in each sample. The selected sample was cleansed of debris, stains, and calculus and stored in 10% formalin solution.

The selected samples were then prepared for enamel window preparation as shown in Figure 1. The enamel window provided a controlled area of demineralization. It was created by marking a 3*3 mm square on the middle third of the buccal surface of each premolar. The remainder of the tooth was covered in acid resistant nail polish and allowed to dry before beginning the pH cycling procedure.

Preparation of Demineralizing and Remineralizing Solution

The incipient carious lesions were created on the enamel window of the samples by placing them in an artificially prepared demineralizing solution as shown in Figure 2. The demineralizing solution contained a blend of calcium chloride (2.0 mmol/L), tri sodium phosphate (2.0 mmol/L) in acetate buffer (75 mmol/L) solution at pH 4.4 as shown in Figure 3, that is, at the critical pH at which there is pronounced demineralization of hydroxyapatite crystals.[11] The samples were suspended inside test tubes with measured, equal quantity (10 ml) of the prepared demineralization solution for a period of 4 days at room temperature(37°).

A remineralizing solution was also prepared to place the samples which were treated with the respected products in the artificial media to observe the alterations in baseline lesion depth of the demineralized enamel sections after a pH cycling of 7 days. The remineralizing solution contained Na_3PO_4 - 3.90 mM, $NaCl_2$ - 4.29 mM, KCl - 17.98 mM, $CaCl_2$ - 1.10 mM, $MgCl_2$ - 0.08 mM, H_2SO_4 - 0.50 mM, $NaHCO_3$ - 3.27 mM, distilled water, with pH maintained at 7.2.[12]

Experimental Groups

The demineralized samples were randomly divided into 3 groups with 10 samples each:
Group A (n = 10)- Copal Care (sodium fluoride)
Group B (n = 10) – M I Varnish (CPP-ACP-F)
Group C (n = 10)- Cervitec F+ (CHX varnish)

Sectioning of Samples

The samples of each group were mounted in wax blocks [Figure 4], sectioned using a hard tissue microtome (Leica SP 1600) [Figure 5] into longitudinal sections of thickness 150–200 μ [Figure 6]. The samples were then mounted on to glass slides. The sections were all stained with rhodamine.

B solution and the baseline lesion depth for each sample were determined using confocal laser scanning microscopy.

Application of Remineralizing Products and pH Cycling

The specimens in group A were coated with Copal Care [Figure 7] using applicators for 60 s per specimen. The procedure was repeated for the application of MI varnish [Figure 8] on the specimens of group B and Cervitec+F [Figure 9] on specimens of group C. Once dry the samples were then subjected to a pH cycle of alternative demineralization and remineralization. The demineralization of the samples was carried out in the prepared demineralizing solution for 3 hours. The samples were then transferred into the remineralizing solution, where they underwent remineralization for a period of 21 hours. The consecutive cycle was followed for a period of 7 days.

Post-treatment Analysis

The samples after a period of 5 days of pH cycling were stained with freshly prepared Rhodamine B solution for 1 h and mounted on frosted glass slides. The specialized stain integrates into the demineralized structures within the samples and provides contrast from the sound tooth structure. The samples were washed thoroughly with phosphate solution to remove excess stains and were remounted with 80% glycerol mountant. Cover slips were placed on top making sure of no air entrapment and edges of the coverslips were coated with transparent nail enamel to prepare the slides for confocal analysis. A confocal laser scanning microscope (Leica TCS SL inverted microscope) was used to measure the post-treatment lesion depth. The software analyzed the linear depth of fluorescence and also the average or total fluorescence. The images were captured from the buccal surface that is one each from either side of the mid-point measured from the occluso-cervical length of the tooth at (×5) magnification and for excitation and emission range of 498–514 nm wavelength an, Argon laser was used at 488 nm wavelength. Two images were captured from either side of the midpoint of occluso-cervical length on the buccal surface.

Statistical Analysis

The values for each specimen were noted and tabulated. A statistical analysis was done using SPSS software (version 27). The data were subjected to Fisher's paired t-test and one-way ANOVA.

RESULTS

The three groups showed significant remineralization of the artificial carious lesion based on the confocal images although, Copal Care showed the highest remineralization [Figure 10] followed by Cervitec F+ [Figure 11] and MI varnish [Figure 12]. Table 1 depicts the mean lesion depth values among three groups at baseline. The mean lesion depth value was found to be higher for Group A (576.26 ± 1.17) closely followed by Group B (546.56 ± 1.19) and then Group C (422 ± 1.24). The difference in lesion depth was found to be significant statistically. Table 2 depicts the mean lesion depth values among the three groups after pH-cycling. The mean lesion depth value was found to be higher for Group A (383 ± 1.15) followed by Group B (365.61 ± 1.43) and then Group C (234.10 ± 1.10). The difference in lesion depth was found to be significant statistically.

DISCUSSION

Incipient carious lesion is the "white spots" found on the enamel subsurface, formed by decalcification of the enamel. The surface of the enamel is intact with no

Table 1: Mean lesion depth values among three groups at baseline

Groups	Lesion depth (Mean±SD)	F –value	Degrees of freedom	*P*-value
Group A (sodium fluoride)	576.26±1.17	46023.013	2	0.000*
Group B (MI)	546.56±1.19			
Group C (Cervitec F)	422±1.24			

*One-way ANOVA. The difference in lesion depth was found to be significant statistically

Table 2: Mean lesion depth among three groups after pH-cycling

Groups	Lesion depth (Mean±SD)	F –value	Degrees of freedom	*P*-value
Group A (sodium fluoride)	383±1.15	43226.633	2	0.000*
Group B (MI)	365.61± 1.43			
Group C (Cervitec F)	234.10±1.10			

*One-way ANOVA. The difference in lesion depth was found to be significant statistically

cavitation. It is the initial step in the process that leads to the clinically significant caries associated cavities, sensitivity, and pain.[13] This stage of caries is often left unnoticed due to the shortfall of conventional signs and symptoms of a carious lesion. As discussed earlier, the formation of these lesions are multifactorial. The initial step in the caries formation is the plaque formation. The primary organism that initiates colonization on the enamel surface is the well-known, *S mutans*. The organism plays the key role beginning from the accumulation of plaque, acid formation, and finally the decalcification of enamel.[14]

The conventional treatment modalities would involve the removal of the plaque and calculus, extension of cavities to sound enamel with proper outline form, and sealing of those cavities with either dental cements or sealants. The treatment provides relief but is not conservative of the tooth structure. The early clinical detection of the incipient lesions and their objective monitoring would help remineralize the lesion to sound form without the need to cut enamel or dentin.[15]

Demineralization begins as the acids produced by break down of sugars within the plaque bacteria reduce the oral pH. The lowered pH un-saturates the plaque fluids of calcium and phosphate ions. At this point, the calcium and phosphates from the enamel leaches out until the plaque fluids are saturated again. Demineralization controls the progression of caries. Remineralization on the other hand causes reversal of the ion transfer and deposits calcium

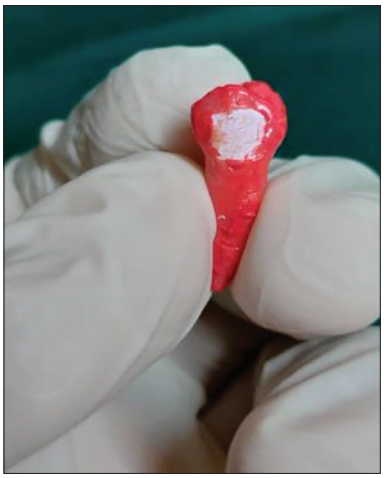

Figure 1: Preparation of enamel window

Figure 2: Specimens placed in demineralizing solution

Figure 3: pH meter

and phosphates until the lesion is saturated. It occurs only as the pH rises above the critical pH.[16]

It has been reported that even trace quantities of fluoride ions are effective in formation of hydroxyapatite crystals.[17] Hence, fluoride has been the key ingredient within most

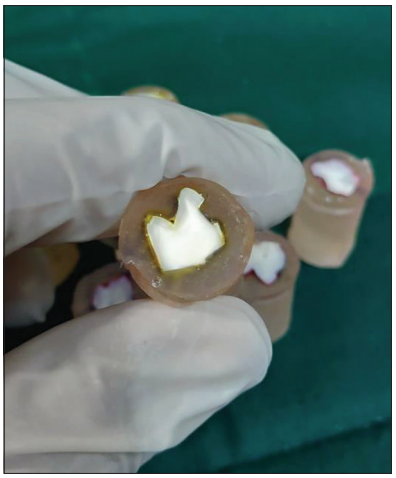

Figure 4: Mounted section



Figure 5: Hard tissue microtome

Figure 6: Longitudinal section of enamel section

Figure 7: Sodium fluoride varnish



Figure 8: MI varnish

Figure 9: Chlorhexidine varnish

enamel remineralization products. Fluoride varnishes were developed in the late 1960s and 70's. Fluorides showed topical anti-cariogenic effects which were ascribed to the reduced solubility of fluoridated crystal lattice of enamel or also known as fluorapatite.[18] Even though rare the fluoride varnishes due to the high fluoride content (22,600 ppm) does have side effects, majorly fluorosis, and fluoride toxicity.[19]



Figure 10: The confocal laser scanning microscopic image of sodium fluoride varnish applied section at post-treatment lesion depths

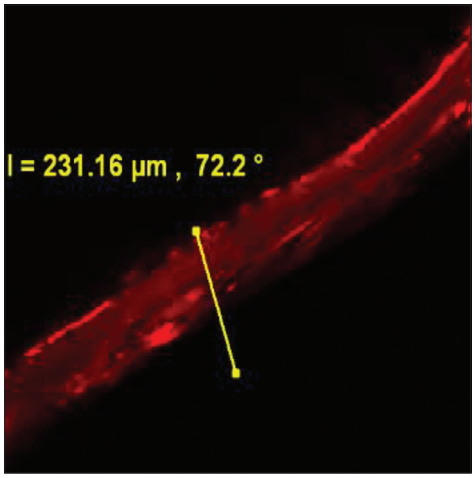

Figure 11: Confocal laser scanning microscopic images of chlorhexidine varnish applied section at post-treatment lesion depths



Figure 12: The confocal laser scanning microscopic images of MI varnish applied section at post-treatment lesion depths

CPP is milk protein derived peptides which substantially increase the levels of calcium phosphate in plaque which in turn decreases enamel demineralization. The present study utilizes MI varnish. Even though conventional CPP shows efficient remineralization, because of the added benefit of fluoride (NaF 0.2%), CPP-ACPF shows marginally more amount of remineralization than CPP-ACP.[20]

Cervitec+F is a relatively new product which other than the anti-cariogenic action of fluoride, incorporates the anti-microbial action of CHX against plaque bacteria especially *S mutans,* the primary colonizer. CHX has been reported effective in the control of plaque formation and caries prevention. 0.2–2% of CHX is effective enough to reduce the self-degradation of collagen fibrils by inhibiting host-derived protease activity in demineralized dentin and influence dentin remineralization.[21,22] The combination of CHX and fluoride in form of a varnish has shown similar effectiveness in the prevention of caries in both permanent and primary dentitions.[10,23] Even though proven efficient there is a lack of literature to substantiate the efficacy of CHX varnish compared to the fluoride and CPP-ACP alternatives.

A confocal scanning microscopic analysis of the demineralized enamel sections provided substantial information on the difference between the baseline lesion depth and post-treatment lesion depth between the groups. Confocal microscopy provided the control of field depth, elimination of background information from the focal plane and collection of serial optical sections from the thick enamel sections. The expense, chances of artefacts, and the difficulty to mount thick sections into the scanning electron microscope chamber made controlled low strength materials more feasible for the present study.[24]

The post-treatment results showed that the specimens applied with sodium fluoride showed the greatest remineralization of the incipient carious lesions when compared to Group B and Group C, i.e., CPP-ACPF and CHX varnish, respectively. The difference was found to be statistically significant. This was in accordance with the study by Chokshi *et al.*, which concluded that sodium fluoride does have better efficacy in remineralization of *in-vitro* produced incipient enamel lesions when compared to CPP-ACP within the time intervals of 20 days and at 40 days.[25] Contrary to the results of the present study in a study conducted by Akin *et al.*, which compared the efficacy of two mouth washes containing sodium fluoride and casein phosphopeptide, respectively, in treatment of white spot lesions in 80 patients, post-orthodontic therapy, the group which used CPP-ACP showed higher remineralization of the white spots within the time frame of 6 months.[26]

Now in the present when comparing the fluoride group (Group A) and CHX group (Group C) both lesions show

significant reduction in baseline lesion depth although group A had better results. Similar results were found to be in a study by Naidu *et al.*, where in an *in vivo* study conducted in children the groups containing fluoride, CHX, and a combination of both had increased post-treatment levels of enamel calcium and phosphate as compared to the negative control group.[10] A randomized control study conducted by Papas *et al.* too concludes that there is significant reduction in the number of un-cavitated carious lesions when treated with CHX varnish in an adult population over a period of 6 months.[27] There is currently scarce literature testing the effectiveness of CHX varnish in an *in-vitro* scenario and a comparison between CHX and CPP-ACP varnishes.

A study by Somasundaram *et al.* comparing effect of paste containing CPP-ACP, fluoride, on enamel remineralization, it was concluded that enamel surfaces treated with the CPP-ACP paste exhibited the least lesion depths followed by the enamel surfaces treated with the fluoridated tooth paste and control group, respectively.[28] A similar study conducted by Datta *et al.*, on 45 subjects with occlusal white spot lesions, groups that were treated with CPP-ACP showed superior remineralization that the fluoride treated group.[29] The results from the following studies are contrary to the results obtained in the present study. However, in every study, the results of remineralization by fluoride and CPP-ACP have no significant variations.

Limitations

The *in-vitro* study does not account for the dynamic microbiological system in the oral cavity. This glaring constraint must be considered and assumptions must be made with caution when compared to clinical studies. Furthermore, clinical trials are required to validate the findings in the current study.

CONCLUSION

Copal Care showed the greatest remineralization potential followed by Cervitec F+ and MI varnish, respectively. The differences in mean lesion depth values among three groups at baseline and post-treatment of all three products were not statistically significant with the $P \leq 0.05$. However, the difference in mean lesion depth between the three groups was statistically significant with $P \geq 0.05$. Fluoride does have a profound effect on the level of caries progression but we cannot always recommend high fluoride strategies. They cannot be followed due to the adverse effects of fluoride topically and systemically. Hence, there is still a need for remineralizing agents with less fluoride content and comparable anticaries progression properties to the current high fluoride options.

REFERENCES

1. Petersen PE. World Health Organization global policy for improvement of oral health-World Health Assembly 2007. Int Dent J 2008;58:115-21.
2. Pulido M, Wefel J, Hernandez M, Denehy G, Guzmán-Armstrong S, Chalmers J, *et al*. The inhibitory effect of MI paste, fluoride and a combination of both on the progression of artificial caries-like lesions in enamel. Oper Dent 2008;33:550-5.
3. Larsen MJ, Fejerskov O. Chemical and structural challenges in remineralization of dental enamel lesions. Scand J Dent Res 1989;97: 285-96.
4. Karabekiroglu S, Erdur EA, Ileri Z, Unlu N. Effectiveness of remineralization treatments on incipient lesions: A controlled clinical trial. Int J Oral Dent Health 2018;4:54.
5. Fischer RB, Muhler JC, Wust CJ. Effects of several fluoride reagents on the surface structure of powdered dental enamel. J Dent Res 1954;33:50-4.
6. Peter S. Essentials of Public Health Dentistry. India: Arya Medi Publishing House Pvt. Ltd.; 2015.
7. Said SN, Ekambaram M, Yiu CK. Effect of different fluoride varnishes on remineralization of artificial enamel carious lesions. Int J Paediatr Dent 2017;27:163-73.
8. Reynolds EC. Anticariogenic complexes of amorphous calcium phosphate stabilized by casein phosphopeptides: A review. Spec Care Dentist 1998;18:8-16.
9. Scientific Documentation Cervitec F. Available from: https://www.ivoclarvivadent.com/zoolu-website/media/document/38346/cervitec+f. [Last accessed on 2020 Aug 21].
10. Naidu S, Tandon S, Nayak R, Ratnanag PV, Prajapati D, Kamath N. Efficacy of concomitant therapy with fluoride and chlorhexidine varnish on remineralization of incipient lesions in young children. Int J Clin Pediatr Dent 2016;9:296-302.
11. Shashikala K, Sheela NV. Qualitative analysis of re mineralized carious lesions subjected to fluoride supplement through confocal laser scanning microscope. OJST 2011;1:55-60.
12. Lata S, Varghese NO, Varughese JM. Remineralization potential of fluoride and amorphous calcium phosphate-casein phospho peptide on enamel lesions: An *in vitro* comparative evaluation. J Conserv Dent 2010;13:42-6.
13. Arends J, Christoffersen J. The nature of early caries lesions in enamel. J Dent Res 1986;65:2-11.
14. Ajdić D, McShan WM, McLaughlin RE, Savić G, Chang J, Carson MB, *et al*. Genome sequence of *Streptococcus mutans* UA159, a cariogenic dental pathogen. Proc Natl Acad Sci USA 2002;99:14434-9.
15. Jablonski-Momeni A, Stachniss V, Ricketts DN, Heinzel-Gutenbrunner M, Pieper K. Reproducibility and accuracy of then ICDAS-II for detection of occlusal caries *in vitro*. Caries Res 2008;42:79-87.
16. Schemehorn BR, Orban JC, Wood GD, Fischer GM, Winston AE. Remineralization by fluoride enhanced with calcium and phosphate ingredients. J Clin Dent 1999;10:13-6.
17. Gibbs CD, Atherton SE, Huntington E, Lynch RJ, Duckworth RM. Effect of low levels of fluoride on calcium uptake by demineralized human enamel. Arch Oral Biol 1995;40:879-81.
18. Zero DT, Raubertas RF, Fu J, Pedersen AM, Hayes AL, Featherstone JD. Fluoride concentrations in plaque, whole saliva, and ductal saliva after application of home-use topical fluorides. J Dent Res 1992;71:1768-75.
19. Chu CH, Lo E. Uses of sodium fluoride varnish in dental practice. Ann R Australas Coll Dent Surg 2008;19:58-61.
20. Jayarajan J, Janardhanam P, Jayakumar P. Efficacy of CPP-ACP and CPP-ACPF on enamel remineralization-an *in vitro* study using scanning electron microscope and DIAGNOdent. Indian J Dent Res 2011;22:77-82.
21. Kim DS, Kim J, Choi KK, Kim SY. The influence of chlorhexidine on the remineralization of demineralized dentine. J Dent 2011;39:855-62.
22. Matthijs S, Adriaens PA. Chlorhexidine varnishes: A review. J Clin Periodontol 2002;29:1-8.
23. Petersson LG, Magnusson K, Andersson H, Almquist B, Twetman S. Effect of quarterly treatments with a chlorhexidine and a fluoride varnish on approximal caries in caries-susceptible teenagers: A 3-year clinical study. Caries Res 2000;34:140-3.
24. Pawley J, editor. Handbook of Biological Confocal Microscopy. Berlin:

Springer Science & Business Media; 2010.
25. Chokshi K, Chokshi A, Konde S, Shetty SR, Chandra KN, Jana S, *et al*. An *in vitro* comparative evaluation of three remineralizing agents using confocal microscopy. J Clin Diagn Res 2016;10:ZC39-42.
26. Akin M, Basciftci FA. Can white spot lesions be treated effectively? Angle Orthod 2012;82:770-5.
27. Papas AS, Vollmer WM, Gullion CM, Bader J, Laws R, Fellows J, *et al*. Efficacy of chlorhexidine varnish for the prevention of adult caries: A randomized trial. J Dent Res 2012;91:150-5.
28. Somasundaram P, Vimala N, Mandke LG. Protective potential of casein phosphopeptide amorphous calcium phosphate containing paste on enamel surfaces. J Conserv Dent 2013;16:152-6.
29. Krithikadatta J, Fredrick C, Abarajithan M, Kandaswamy D. Remineralisation of occlusal white spot lesion with a combination of 10% CPP-ACP and 0.2% sodium fluoride evaluated using diagnodent: A pilot study. Oral Health Prev Dent 2013;11:191-6.

How to cite this article: James C, Premnath P, Joseph B, Shankari SV. "War of the Varnishes – A Comparative Evaluation between Three Remineralizing Agents Using Confocal Microscopy". Int J Sci Stud 2021;9(1):43-50.

Source of Support: Nil, **Conflicts of Interest:** None declared.

Print ISSN: 2321-6379
Online ISSN: 2321-595X

Original Article

Submental Flap for Head and Neck Reconstruction: An Observational Cross-sectional Analytical Study

Sachin Verma[1], Harshita Kakoriya[2], Sonia Moses[3], Mukesh Sharma[1], Pavan More[2], Jitendra Rawat[2], Shashank Singh Baghel[2]

[1]Assistant Professor, Department of Surgery, Mahatma Gandhi Memorial Medical College, Indore, Madhya Pradesh, India, [2]Junior Resident M.S. Surgery, Department of Surgery, Mahatma Gandhi Memorial Medical College, Indore, Madhya Pradesh, India, [3]Associate Professor, Department of Surgery, Mahatma Gandhi Memorial Medical College, Indore, Madhya Pradesh, India

Abstract

Introduction: Submental flap is a good alternative for reconstruction of head and neck cancer defects.

Aims and Objectives: The aimof the study was to study benefits and risk of submental flap for head and neck reconstruction, to study surgical detail of submental flap, and to compare the association between pre-operative factors and complication of submental flap.

Material and Methods: Thirty-five patients are included in this study who had T1-3 N0 stage oral cancer (squamous cell carcinoma). Patients with the previous history of surgery or radiation or who presented with metastatic neck nodes were excluded from the study. All patients underwent surgical resection and immediate reconstruction with submental flap.

Results: Out of 35 patients, 33 were males two were females ranging from age 30 to 50 years. The primary tumor site was tongue (19), buccal mucosa (8), lip (5), alveolar ridge (2), and palate (1). Four patients had complications such as partial flap necrosis (n = 2), hair growth (n = 1), and hair growth (n = 1). Mean flap size and defect size are 23.510 cm^2 and 15.620 cm^2, respectively, mean operating time was found to be 4.014 h. Statistically significant association was found between flap size and complications.

Conclusion: Submental flap is an excellent choice as it considerably thin, pliable, versatile, easy to raise flap, saves the operative time, lessens hospital stay, and good blood supply can cover medium to large oral defects, matches the facial skin tone as well, with less donor site morbidity.

Key words: Cancer, Complication, Duration, Head and neck, Reconstruction, Submental flap

INTRODUCTION

Head and neck tumors are the sixth most common cancer worldwide, out of 6.4 million head and neck cancer cases diagnosed worldwide[1,2] every year, nearly 1.5 million cases are from India, which accounts for 20% of all head and neck cancers of the world (statistics in India 2019).[3]

Access this article online

www.ijss-sn.com

Month of Submission : 02-2021
Month of Peer Review : 03-2021
Month of Acceptance : 03-2021
Month of Publishing : 04-2021

According to National Cancer Database, squamous cell carcinoma (SCC) is the most common head and neck tumor of the major head and neck sites (88.9%), adenocarcinoma is the most common salivary glands (56.4%), SCC is the most common of the sinonasal tract (43.6%), and lymphoma is the most common of the sites classified as other (82.5%).[4]

Proper treatment of head and neck squamous cell carcinoma requires careful evaluation and accurate radiographic and clinical staging. In general, early stage disease (Stage I or II) is treated by surgery or radiation. Late stage disease (Stage III or IV) is best treated by combination of surgery and radiation therapy or chemotherapy and radiation therapy or all three modalities, depending on the site of the primary.

Corresponding Author: Dr. Harshita Kakoriya, Department of Surgery, office - G-72, MY Hospital Main Building, Indore, Madhya Pradesh, India.

Surgical excision of larger lesions usually creates a two-dimensional or three-dimensional facial defects thus is a challenging task for the surgeons for good cosmesis, anatomical integrity, and early restoration of functionality.

There are various options for reconstruction of defects such as skin grafting, local flaps, free flaps, pedicled flaps, and depending on the size and location of defects.

In general, small defects are healed by secondary intention while for larger defects there is an option of free flaps.[5,6] Reconstruction with microvascular free flaps is the gold standard but requires high degree of expertise, cost, and time consumption and prolonged hospital stay.

However, the pedicled flaps are the good alternative. The myocutaneous platysma and submental flaps are commonly used for reconstruction of small to medium sized facial oral and neck defects.

The submental flap is submental artery based submental island flap (SIF). It is an axial fasciocutaneous flap. SIFs pedicled on submental artery and veins which includes skin, subcutaneous tissue, platysma, and fat.[7]

It can be used in many forms as cutaneous, musculofascial (cervicofacial and platysma), or osteocutaneous flap. This flap is used for small to medium sized defects.[8] In this study, we will study the use of submental flap at various sites for head and neck reconstruction with *en block* excision of tumor with clinically negative lymph node status while using different size of flaps and assessing post-operative complications, time to harvest the flap intraoperative duration, common age groups involved, gender, tumor staging, type of blood supply, and local recurrence.

MATERIALS AND METHODS

From February 2019 to July 2020 at the Department of General Surgery Mahatma Gandhi Memorial College and Maharaja Yeshwantrao Hospital, a total of 35 patients with oral cavity carcinoma (lip, tongue, buccal mucosa, and palate) presented to our OPD. Patients included in this study are of TNM T1 T2 T3 and N0 stage who has not received any radiotherapy preoperatively and all had SCC in histopathological examination.

Surgical Technique

Position

The patient lies in supine position with extended neck and tilted/ turned to opposite side.

Flap Design

An ellipse shape marked after pinch test based on skin laxity in submental area across the midline. The length of flap depends on the size of defect may extend from one mandibular angle to other if necessary. The upper incision is made approximately 1.5 cm below the mandible in midline and ~3.5 cm below the mandible angle on both sides while the lower incision is the limit of pinch test allowing primary closure adequately [Figure 1]. The lower neck subplatysmal flap is raised first up to clavicle to allow adequate traction facilitating closure. Afterward upper cervical flap is raised while carefully identifying and protecting marginal mandibular nerve. The subplatysmal dissection is performed near inferior border of mandible anteriorly including the ipsilateral anterior belly of digastric muscle. To protect the cutaneous perforator's platysma is sutured to skin paddle.

On approaching, the submandibular triangle facial artery and vein are meticulously identified and dissected away from gland [Figure 2] and also preserving the submental vessels and ligating the glandular branches and dissecting off the submandibular gland. Contralateral side of flap is raised in the subplatysmal flap up to the midline. The facial vessels above the origin of submental vessel need to be ligated in proximal based flap (anterograde blood supply which we have used in this study). The facial vein has quite a variable course draining either directly into internal jugular vein or external jugular vein by communicating with the facial vein and anterior division of the retromandibular vein.

Later neck dissection starts before harvesting the flap. Taking extreme caution preserving submental and facial vessels while doing neck dissection. To understand the possible recurrence in the submental flap raised, it was taken care that 1a and 1b lymph nodes were sent for

Figure 1: Incision marked for submental flap after pinch test

histopathology separately from the rest of the chain of cervical lymph nodes.

Harvesting the FLAP

Flap dissection starts from contralateral side of the pedicle in the subplatysmal flap. Care is taken to identify the submental vessels while reaching the midline. Ipsilateral anterior belly of digastric is included in the flap sometimes a strip of mylohyoid muscle is included in the flap after bluntly dissecting off ipsilateral geniohyoid muscle. This results in complete mobilization of flap [Figures 3 and 4].

Then, a generous tunnel created between the defect and donor site. The flap is rotated lateral to the mandible to cover the defects involving buccal mucosa. Alternatively, flap is rotated medially to cover the defects involving floor of the mouth, base of the tongue, retromolar trigone, and alveolar ridges. The part of the flap passing through the tunnel is de-epithelialized and flap is inserted to the site. In all the cases, ryle's nasogastric tube is inserted and used for immediate post-operative feeding until there is no evidence of fistula or wound dehiscence. Postoperatively, radiotherapy is advised and 3 monthly follow-up.

Figure 2: Identification and securing of facial artery

Figure 3: Submental flap raised with pedicle

RESULTS

A total of 35 patients were included in our study of which a majority of patients, that is, 25 belonged to 35 to 45 years of age. Moreover, the mean age of cancer incidence was found to be 38.09 years with a SD of ± 4.60 years.

Likewise, the population was also analyzed for sex distribution, it was noted that 94.3% of the patients (33 in number) were males, and only two patients comprising 5.7% were females [Table 1].

Regarding the site of cancer, it was deduced that 54.3% of the cases mainly arise from the tongue and second largest subset of oral cancers comes from buccal mucosa having 22.9% of all the cases. Palate is the least involved site in this study. Lip and alveolar ridge have primary tumors 14.3% and 5.7%, respectively.

The defect size after excision of the primary tumor was noted in all cases and was found to be of average of 15.620 ± 8.011 cm^2 in area, 18 out of 35 patients had defect size of less than 15.620 cm^2 and 17 patients measured defect size more than the mean. Harvested submental flap was found to have mean area of 23.510 ± 9.810 cm^2. 17 patients' harvested flaps were larger whereas 18 patients were harvested a smaller sized flap accounting for 48.6% and 51.4%, respectively.

In our study, out of all patients only 11.4% had complication in terms of partial flap necrosis ($n = 2$), dehiscence ($n = 0$),

Table 1: Distribution of patients of the study population according to the age, sex, and site of the cancer lesion

Parameter	Frequency	Percent	Mean±SD
Age group (years)			
30–35	7	20.0	38.09±4.60
35–40	13	37.1	
40–45	12	34.3	
45–50	3	8.6	
Total	35	100.0	
Sex			
Female	2	5.7	
Male	33	94.3	
Total	35	100.0	
Site			
Alveolar ridge	2	5.7	
Buccal mucosa	8	22.9	
Lip	5	14.3	
Palate	1	2.9	
Tongue	19	54.3	
Total	35	100.0	

Figure 4: Serial surgical steps demonstrating submental flap harvesting and reconstruction of the left sided defect after wide local excision for left buccal mucosa carcinoma

skin infection ($n = 0$), hematoma ($n = 1$), and lastly one of the patient developed hair growth ($n = 1$) onto the flap due to failure to receive post-operative radiotherapy [Table 2].

It was observed that mean duration of surgery (primary tumor resection, neck dissection, and flap harvesting) is about 4.014 ± 0.521 h. It was inferred from our study observations that mean submental flap size was 23.51 cm^2 as previously discussed, 17 patients had larger sized flaps compared to the mean size out of which four of the patients developed post-operative complications such as flap necrosis and hematoma in contrast with 0 complications in the smaller sized flaps. This association was found to be statistically significant with $P = 0.029$. ($P < 0.05$), implying bigger the size more are the complications.

For larger (>23.51 cm^2) flaps, the duration of surgery was 4.055 ± 0.511 h compared to 3.970 ± 0.544 h in smaller flaps the comparison of both these entities yields no significant change of duration of surgery between larger and smaller flaps with *P*-value being $P > 0.05$, that is, $P = 0.637$.

From Table 3, it is evident that four patients had complication of flap post-operative, three out of which belonged to the recipient site of Ca buccal mucosa, and one of the site was a Ca tongue with no complications

Table 2: Distribution of study population in terms of defect size, flap size, complications, and operating time

Parameter	Frequency	Percent	Mean	SD
Defect size category				
Small (<15.62 cm²)	18	51.4	15.620	8.011
Large (≥15.6 cm²)	17	48.6		
Total	35	100		
Flap size category				
Large (≥23.51 cm²)	17	48.6	23.510	9.810
Small (<23.51 cm²)	18	51.4		
Total	35	100		
Complications				
No	31	88.6	NA	NA
Yes	4	11.4		
Total	35	100		
Operating time (OT)				
OT in hours	35	100	4.014	0.521

Table 3: Association of complication of flap with the flap size

Complication	Flap size category		Total
	Large (≥23.51 cm²)	Small (<23.51 cm²)	
No			
Count	13	18	31
%	76.5%	100.0%	88.6%
Yes			
Count	4	0	4
%	23.5%	0.0%	11.4%
Total			
Count	17	18	35
%	100.0%	100.0%	100.0%
Pearson Chi-square			
Value	Df	*P*-value	Result
4.782	1	0.029	Significant

in cases of lip, alveolar ridge, and palate. As depicted in Table 4, there is no significant relation between presence or absence of complication based on the site of the primary tumor, with $P = 0.130$, that is, $P > 0.05$.

DISCUSSION

Over the past two-decades, SIFs have been employed as a reliable reconstructive choice for head and neck operations especially the oral and oropharyngeal cancer surgeries. Earlier free flaps were considered as the gold standard for the soft-tissue reconstruction of head and neck cancers. Since the proposal of this pedicled flap by Martin *et al.* in 1993, many studies have been conducted to establish the status of submental flap as the preferred choice of reconstruction for selected patients. In comparison to free flap the submental flap surgery takes less time for operation, has lesser duration of intensive care unit (ICU) and hospital stay, does not need specialized equipment, and microvascular surgical expertise and also costs lesser overall.[9]

Table 4: Association of complication of the flap with the site of the cancer lesion

Site	Complications		Total
	No	Yes	
Alveolar ridge			
Count	2	0	2
%	6.50%	0.00%	5.70%
Buccal mucosa			
Count	5	3	8
%	16.1%	75.00%	22.90%
Lip			
Count	5	0	5
%	16.1%	0.00%	14.3%
Palate			
Count	1	0	1
%	3.20%	0.00%	2.90%
tongue			
Count	18	1	19
%	58.10%	25.00%	54.30%
Total			
Count	31	4	35
%	100.00%	100.00%	100.00%
Pearson Chi-square			
Value	df	*P*-value	Result
7.118	4	0.130	Non-significant

The SIF has an excellent skin color match and long vascular pedicle, wide arc of rotation[10] close proximity to facial and intra oral defects and providing adequate bulk and mucosal lining and can extend to the whole ipsilateral face and oral cavity, except for a part of the forehead. It has good versatility, reliable blood supply, minimal donor site morbidities, and few post-operative complications. It does not require ICU monitoring and is economical along with reduced intraoperative time and hospital stay.

There are other flaps too which meet these conditions and can be harvested from anterior neck such as platysma supraclavicular and infrahyoid flaps but each of them have some known disadvantages including limited mobility, poor donor site morbidity, unreliability, and submental flap is relatively free from these limitations.

According our study, Ca tongue is the most commonly occurring oral and oropharyngeal cancers with a contribution of 54.3%.

In our study of 35 patients flap size ranges from 45 cm² to 9 cm² with the mean size of 23.51 cm² ± 9.810 cm², it has been proposed by Martin *et al.* that a skin paddle up to 126 cm² (18 × 7) can be raised depending on the laxity of submental skin.

Size of the flap is often dependent on the defect size created by the resection of the primary tumor. In our study, we noted that the defect size was found to be of 15.620 ± 8.011 cm² on an average ranging from 7.6 cm² to 23.6 cm²,

in most of the studies done across the web database it has been opined that there is no specific guideline for the size of the submental flaps, it is observed that surgeons decide the size of the flap with respect to the extent of primary tumor resection and by the pinch test for the donor site to be approximated without tension.

In our study, four (11.4%) out of 35 patients had complications, two patients had partial flap necrosis [Figure 5] resolved conservatively with secondary healing out of four, one patient developed hematoma, and one had hair growth over the flap because of not receiving post-operative radiotherapy for which patient had de-epithelization afterwards. In our study, there is significant association found between flap size and complications with $P = 0.029$. ($P < 0.05$), out of 17 patients who have large flap size (>23.51 cm^2) four patients develop complications; no identical studies found showing such association.

- Liu *et al.* study of 30 patients had showed association between complications and comorbidities such as cardiac disease out of 30 patients two patients had full thickness flap necrosis

Possible complications of submental flap include facial palsy, or damage to the marginal mandibular nerve. This damage to the marginal mandibular nerve is greatly lessened by the supraplatysmal dissection. The use of nerve stimulators associated to a careful dissection decreases the possibility of damage to these nerves. Hair bearing submental flap causes problematic intraoral reconstructions. This problem has been managed using different techniques, such as laser ablation, second operations, mechanical depilation, and electrolysis or de-epithelialized variant of the submental flaps.[11] Trismus is also lesser known complication of submental flaps due to intraoral scarring managed by physiotherapy.

It is notable that there is no significant time difference to harvest smaller or considerably larger flaps. Shirley *et al.* conducted a meta-analysis including studies of Paydarfar *et al.*, Aslam *et al.*, Kramer *et al.*, Sittitrai and Forner concluded that mean (SD) operative times for SMIF and FFT cohorts were 5.5 h and 9 h, respectively, and SMIF was correlated with both reduced operative time and hospitalization by a large effect size. Pradhan *et al.*[12] concluded that SF took lesser time than fractional flow reserve (186 min vs. 474 min) In our study, we observed that mean operating time is about 4.014 ± 0.521 h.

In the present study, we noticed that there is no significant association in the presence of complication based on the site of the tumor or the recipient site [Figure 6]. No recurrences were noted in the study whereas four patients had flap related complications as mentioned before.

One major concern and hence a strong contradictory promotion for submental flap reconstruction is the loco regional recurrence at recipient site due to occult tumor of submental region being in the vicinity of the primary tumors. Therefore, oncological safety has been controversial in the submental flap surgeries.

- Jiang *et al.* had concluded in their study that submental cannot be used in the cases where donor site has been radiated before surgery and have submental and submandibular lymph nodes positive
- Pradhan *et al.* proposed XV and evaluation of feasibility and oncological safety. When harvested with meticulous dissection of lymph nodes at level 1, the SF is oncologically safe to use even in node-positive cases
- Sebastian *et al.* claim that submental flap should be avoided in any suspicion of Level I involvement
- Kramer *et al.*[13] did a retrospective study on this issue comparing radial free flap to the submental flap reconstruction surgeries, they noted that both groups had similar rates of loco regional recurrences (11%

Figure 5: Post-operative picture of a patient with necrosed flap

Figure 6: Post-operative picture of a patient with right-sided involvement of tongue

local recurrences in each group). In their study, 4.4% regional recurrence was seen in submental group and 6.7% was noted in radial free flap surgery

- Chow *et al.*[14] found out in their study that in the select patient with a median follow-up 21 months, there were no cases of total flap failure, but partial necrosis occurred in two cases. Three patients experienced tumor recurrence, but only one case might have been related to use of the submental flap. Thus, suggesting if the plane of dissection is respected in all the surgeries following the technique of subplatysmal dissection and elevation of submental flaps not only reduces tumor recurrences but also provides adequate clearance of Group I lymph nodes.

In our study, all of the patients underwent radiotherapy except for one and we observed there were no cases of loco regional recurrences with a median follow-up of 12 months, all patients included in our study were N0 on diagnosis with tumor stages being T1, T2, and T3, three patients turned out to have 1a,1b lymph node spread on histopathological examination but no recurrence was noticed implying that in select cases and appropriate planes of dissection the outcome of submental flaps is better than free flaps.

In a study conducted by Reuter patients that underwent a SIF reported a significantly better QOL than patients who underwent a RFFF. Furthermore, patients that had a SIF also had significantly less operative time.[15,16]

CONCLUSION

SIF reconstruction in selected group of oral cavity and oropharyngeal early cancers is an excellent choice as it considerably thin, pliable, versatile, easy to raise flap, saves the operative time, lessens hospital stay, good blood supply, can cover medium to large oral defects, matches the facial skin tone as well, with less donor site morbidity. The major advantages being no need of special equipment or no requirement of microvascular expertise. There is no association between post-operative complications of flap with age of the patient or the site of primary pathology. Oncological safety or loco regional recurrence is the main controversial area of this flap when used in patients with tumors spread to local lymph nodes and that too has been reduced with meticulous dissection under large magnification and proper selection of patients. Post-operative radiotherapy is another major aid to prevent the tissue loss and recurrence rather than pre-operative radiotherapy.

REFERENCES

1. Jemal A, Siegel R, Ward E, Murray T, Xu J, Smigal C, Thun MJ. Cancer statistics, 2006. CA Cancer J Clin 2006;56:106-30.
2. Warnakulasuriya S. Global epidemiology of oral and oropharyngeal cancer. Oral Oncol 2009;45:309-16.
3. Kulkarni MR. Head and neck cancer burden in India. Int J Head Neck Surg 2013;4:29-35.
4. Cooper JS, Porter K, Mallin K, Hoffman HT, Weber RS, Ang KK, *et al*. National Cancer Database report on cancer of the head and neck: 10-year update. Head Neck 2009;31:748-58.
5. Sun G, Lu M, Hu Q. Reconstruction of extensive lip and perioral defects after tumor excision. J Craniofac Surg 2013;24:360-2.
6. Fang QG, Li ZN, Zhang X, Liu FY, Xu ZF, Sun CF. Clinical reliability of radial forearm free flap in repair of buccal defects. World J Surg Oncol 2013;11:26.
7. Katre M, Keche P, Gaikwad A, Deshmukh S. Versatility of the submental island flap in head and reconstruction. Int J Otorhinolaryngol Head Neck Surg 2017;3:1072-6.
8. Sebastian P, Thomas S, Varghese BT, Iype EM, Balagopal PG, Mathew PC. The submental island flap for reconstruction of intraoral defects in oral cancer patients. Oral Oncol 2008;44:1014-8.
9. Forner D, Phillips T, Rigby M, Hart R, Taylor M, Trites J. Submental island flap reconstruction reduces cost in oral cancer reconstruction compared to radial forearm free flap reconstruction: A case series and cost analysis. J Otolaryngol Head Neck Surg 2016;45:11.
10. Martin D, Baudet J, Mondie JM, Peri G. The submental island skin flap. A surgical protocol. Prospects of use. Ann Chir Plast Esthet 1990;35:480-4.
11. Schonauer F, Di Martino A, Nele G, Santoro M, Dell'Aversana Orabona G, Califano L. Submental flap as an alternative to microsurgical flap in intraoral post-oncological reconstruction in the elderly. Int J Surg 2016;33 Suppl 1:S51-6.
12. Pradhan SA, Kannan R, Tiwari N, Jain S, Khan S, Rodrigues D, *et al*. Submental flap: Game changer in oral cancer reconstruction-A study of 1169 cases. J Surg Oncol 2020;1-7.
13. Kramer FJ, Böhrnsen F, Moser N, Schliephake H. The submental island flap for the treatment of intraoral tumor-related defects: No effect on recurrence rates. Oral Oncol 2015;51:668-73.
14. Chow TL, Chan TT, Chow TK, Fung SC, Lam SH. Reconstruction with submental flap for aggressive orofacial cancer. Plast Reconstr Surg 2007;120:431-6.
15. Reuter TJ. Quality of life and cost of care for patients undergoing head and neck soft tissue reconstruction using a submental island flap versus a radial forearm free flap. J Oral Maxillofac Surg 2009;67:52.
16. Liu FY, Li RW, Safdar J, Li ZN, Guo N, Xu ZF, et al. Modified incision design for submental flap: An excellent design method for the reconstruction of a defect after head and neck tumor resection. PLoS One 2013;8:e74110.

How to cite this article: Verma S, Kakoriya H, Moses S, Sharma M, More P, Rawat J, Baghel SS. Submental Flap for Head and Neck Reconstruction: An Observational Cross-sectional Analytical Study. Int J Sci Stud 2021;9(1):51-57.

Source of Support: Nil, **Conflicts of Interest:** None declared.

Print ISSN: 2321-6379
Online ISSN: 2321-595X

Original Article

Evaluation of Two Adhesive Systems on the Pit and Fissure Sealant Success in Permanent Molars: An *In vivo* Study

Henna Mir[1], K. K. Shivalingesh[2], Divya Srivastava[1], Adeeba Saleem[1], Waseem Ashraf[3], Swati Pathak[3]

[1]3rd Year Student, Department of Public Health Dentistry, Institute of Dental Sciences, Bareilly, Uttar Pradesh, India, [2]Professor and Head, Department of Public Health Dentistry, Institute of Dental Sciences, Bareilly, Uttar Pradesh, India, [3]2nd Year Post Graduate Student, Department of Oral Medicine and Radiology, Vyas Dental College, Jodhpur, Rajasthan, India

Abstract

Introduction: Fissure sealants were first introduced in 1967 by Cueto and Buonocore and their effectiveness was recognized by the American Dental Association in 1971. The fifth-generation adhesive system sealants were traditionally placed (which is a two-bottle system). The seventh-generation bonding agents, introduced in the early 2000s, contain acidic primers and adhesive monomers in a single bottle.

Materials and Methods: All the schools with the children aged 6–13 years situated in Bareilly city were enlisted. From the list of schools, four schools were randomly selected by simple random sampling method. Clinical evaluation of marginal integrity, discoloration, and anatomical form will be rated at baseline, 1st month, 3rd month, and after 6 months.

Results: Out of 60 schoolchildren, there were 33 males and 27 females. The 5th generation had more loss in anatomical form as compared the 7th generation bonding agent group and sealant alone group and was statistically significant.

Discussion: The 7th generation bond has more retention because, relative to the 5th generation bonding agent, it has greater microtensile bond strength. Compared to the 7th generation group, more losses were seen in the 5th generation group at first follow-up. This may be attributed to the technique sensitivity at the time of sealant application. Since several steps were needed for the application of the bonding agent of the 5th generation, there are more chances of contamination of moisture that causes sealant retention failure.

Conclusions: Since etch-and-rinse steps for the seventh-generation bonding agent are not needed separately, it can be recommended that the application of sealant along with the seventh-generation bonding agent can improve the success of the sealant and can also be used in field preventive programs for caries prevention.

Key words: Bonding agents, Pit and fissures, Sealant

INTRODUCTION

Among the various chronic diseases, dental caries is among the most common one. Dental caries is a multifactorial microbial infectious disease characterized by demineralization of the inorganic and destruction of the organic substance of the tooth. These microorganisms are mainly found in the pit and fissures of the tooth. The World Health Organization reported the prevalence of caries in school-aged children to be 60–90%.[1]

Of all caries in children, 75% were found in pits and fissures.[2,3] However, the use of pit and fissure sealant forms an integral part of primary prevention, especially in children, because they offer specific protection against the occurrence and progression of dental caries. They have also been proven very cost effective as compared to other restorative materials. Fissure sealants were first introduced in 1967 by Cueto and Buonocore[4] and their effectiveness was recognized by the American Dental Association in 1971.[5]

Access this article online

www.ijss-sn.com

Month of Submission : 02-2021
Month of Peer Review : 03-2021
Month of Acceptance : 03-2021
Month of Publishing : 04-2021

Corresponding Author: Dr. Henna Mir, House no. J2, Rose lane colony, Chanapora, Srinagar, Jammu and Kashmir, India.

The rationale behind fissure sealants is that it provides a physical barrier between the microorganisms and the healthy tooth structure underneath. The chances of caries development beneath it will be minimal as long as the sealant remains intact. However, due to inadvertent moisture and salivary contamination of etched surface, the application of sealants is not as high as expected.

It is generally observed that an adhesive must initially wet the substrate to form a strong bond with that substrate. Therefore, maximizing the wettability of the tooth surface is critical in achieving a successful bond.[6] Recent work on improved bonding of sealants to saliva-contaminated enamel may help improve clinician confidence in sealant success, even in circumstances of application that is less than ideal.[7]

The fifth-generation adhesive system sealants were traditionally placed (which is a two-bottle system). As it is a multistep technique, it would increase chair side time, patient discomfort, and risk of salivary contamination. To overcome this problem, the seventh-generation bonding agents (which are a one-bottle technique) were introduced. The seventh-generation bonding agents, introduced in the early 2000s, contain acidic primers and adhesive monomers in a single bottle, eliminating acid etching and rinsing steps and thus minimizing the time required for isolation and ensuring successful bonding.[8]

As only a few studies have compared clinical sealant success after the application of different bonding agents, thus the aim of this study was to compare the effect of the fifth- and seventh-generation bonding agents on pit and fissure sealant success.

MATERIALS AND METHODS

The study was done among 6–13-year-old schoolchildren. This study has been reviewed and approved by the Ethical Committee of the Institute of Dental Sciences Bareilly. Permission was obtained from the respective school authorities to conduct the survey in the selected schools. Informed consent was also obtained from the parents and their children for the study.

The objectives were to evaluate the marginal integrity, marginal discoloration, and anatomical form of pit and fissure sealant restoration on the occlusal surface.

Figure 1: Screening of schoolchildren

Figure 2: Armamentarium used in the study

Figure 3: Application of etchant on tooth surface

Table 1: Comparison of sealant loss (anatomical form) among males and females at 1, 3 and 6 month interval

Sealant with 5th and 7th gen.bonding agents	Baseline		1 month			3 months			6 months		
	Males teeth	Females teeth	M	F	*P*-value	M	F	*P*-value	M	F	*P*-value
Sealant alone (120)	0/66	0/54	1/62	2/54	1.000	3/64	1/54	1.000	1/62	3/54	1.000
Sealant+5th generation bonding agent (60)	0/33	0/27	3/31	2/27	1.000	4/32	4/27	1.000	5/31	2/27	1.000
Sealant+7th generation bonding agent (60)	0/33	0/27	1/31	2/27	1.000	0/32	1/27	1.000	1/31	1/27	1.000

M: Male, F: Female

Inclusion Criteria

The following criteria were included in the study:

- Children belonging to the age group of 6–13 years
- Children whose parents or guardians gave voluntary informed written consent
- Fully erupted bilateral permanent 1st or 2nd molar teeth in both upper and lower arches
- Deep occlusal pits and fissures in molar teeth.

Exclusion Criteria

The following criteria were excluded from the study:

- Subjects with one carious or restored permanent 1st or 2nd molar tooth on either side
- Molar teeth with the missing antagonistic teeth
- Subjects having some form of physical or mental disorder
- Uncooperative patients
- Children who would migrate within 1 year.

The kappa coefficient value for the reliability of intraexaminer, for the detection of marginal integrity, marginal discoloration, and anatomical form was found to be 0.82, 0.84, and 0.90, respectively. These values reflect a high degree of observational conformity.

All the schools with the children aged 6–13 years situated in Bareilly city were enlisted. From the list of schools, four schools were randomly selected by simple random sampling method [Figure 1]. Screening of all the children aged 6–13 years was done. Of the screened students who met the inclusion and exclusion criteria and gave consent, 60 subjects (33 males; 27 females) were selected. The informed consent forms were distributed among the

Table 2: Distribution of sealed teeth with and without bonding agent

Sealant with 5th and 7th gen. bonding agents	Total no. of teeth	Maxillary teeth	Mandibular teeth
Sealant alone	120	60	60
Sealant+5th Gen. bonding agent	60	30	30
Sealant+7th Gen. bonding agent	60	30	30

*Fisher's exact test used at $P < 0.05$ significant, **An attrition of 2, 1, and 2 subjects at 1, 3, and 6 months, respectively

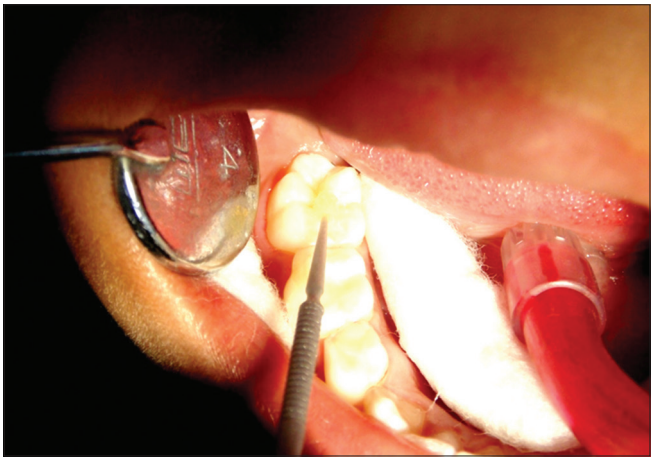

Figure 4: Application of bonding agent on tooth surface

Figure 5: Application of sealant on tooth surface

Table 3: Comparison of sealant retention (anatomical form) among maxillary and mandibular teeth at 1, 3, and 6 months interval

Sealant distribution among maxillary and mandibular teeth	Baseline	1 month				3 months				6 months			
	Total no. of teeth	Total no. of teeth	No loss	Partial loss	Complete loss	Total no. of teeth	No loss	Partial loss	Complete loss	Total no. of teeth	No loss	Partial loss	Complete loss
5th generation													
Maxilla	30	29	27	1	1	30	27	1	2	29	26	1	2
Mandible	30	29	26	2	1	29	27	0	2	29	26	0	3
			χ^2=2.93; P=0.315				χ^2=1.99; P=0.812				χ^2=2.13; P=0.504		
7th generation													
Maxilla	30	29	28	1	0	29	28	1	0	29	29	0	1
Mandible	30	29	29	0	0	30	29	1	0	29	28	1	0
			χ^2=0.001; P=0.821				χ^2=0.001; P=0.981				χ^2=0.001; P=0.821		
Sealant													
Maxilla	60	58	57	1	0	59	57	1	1	58	57	1	1
Mandible	60	58	57	1	0	59	58	1	0	58	58	1	0
			χ^2=0.99; P=0.589				χ^2=1.01; P=0.431				χ^2=0.001; P=0.821		

*Chi-square test at $P < 0.05$ significant, **An attrition of 2, 1, and 2 subjects at 1, 3, and 6 months, respectively

Table 4: Comparison of Marginal Discoloration, Marginal Integrity and Anatomical Form in 5th generation group at 1, 3 and 6 month interval

	5th generation						
Marginal Discoloration, Marginal Integrity, Anatomical Form at 1, 3 and 6 months with 5th generation bonding agent	Baseline no. of tooth (%)	1 month		3 months		6 months	
		No. of tooth (%)	Significance of difference as compared to baseline (Fisher's exact test)	No. of tooth (%)	Significance of difference as compared to baseline (Fisher exact test)	No. of tooth (%)	Significance of difference as compared to baseline (Fisher 's exact test)
Marginal discoloration	0/60 (0)	2/58 (3.44)	0.348 (NS)	3/59 (5.08)	0.392 (NS)	3/58 (5.17)	0.236 (NS)
Marginal integrity	0/60 (0)	2/58 (3.44)	0.413 (NS)	3/59 (5.08)	0.392 (NS)	4/58 (6.89)	0.061 (NS)
Anatomical form	0/60 (0)	5/58 (8.62)	0.023 (S)	5/59 (8.47)	0.011 (S)	6/58 (10.34)	0.012 (S)

*Fisher's exact test at $P < 0.05$ significant, **An attrition of 2, 1, and 2 at subjects 1, 3, and 6 months, respectively

Table 5: Comparison of marginal discoloration, marginal integrity, and anatomical form in the 7th generation group at 1, 3, and 6 months interval

	7th generation						
Marginal Discoloration, Marginal Integrity, Anatomical Form at 1, 3 and 6 months with 7th generation bonding agent	Baseline no. of tooth	1 month		3 months		6 months	
		No. of tooth	Significance of difference as compared to baseline (Fisher exact test)	No. of tooth	Significance of difference as compared to baseline (Fisher exact test)	No. of tooth	Significance of difference as compared to baseline (Fisher's exact test)
Marginal discoloration	0/60 (0)	0/58 (0)	0.89 (NS)	1/59 (1.69)	0.137 (NS)	1/58 (1.72)	0.236 (NS)
Marginal integrity	0/60 (0)	1/58 (1.72)	0.23 (NS)	2/59 (3.39)	0.517 (NS)	3/58 (5.17)	0.127 (NS)
Anatomical form	0/60 (0)	1/58 (1.72)	0.23 (NS)	2/59 (3.39)	0.517 (NS)	2/58 (3.44)	0.127 (NS)

*Fisher's exact test at $P < 0.05$ significant. **An attrition of 2, 1, and 2 subjects at 1, 3, and 6 months, respectively

Table 6: Comparison of marginal discoloration, marginal integrity, and anatomical form in sealant group at 1, 3, and 6 months interval

	Sealant						
Marginal Discoloration, Marginal Integrity, Anatomical Form at 1, 3 and 6 months with sealant	Baseline no. of tooth	1 month		3 months		6 months	
		No. of tooth	Significance of difference as compared to baseline (Fisher's exact test)	No. of tooth	Significance of difference as compared to baseline (Fisher's exact test)	No. of tooth	Significance of difference as compared to baseline (Fisher's exact test)
Marginal discoloration	0/120 (0)	1/116 (0.86)	0.321 (NS)	1/118 (0.84)	0.210 (NS)	1/116 (0.86)	0.321 (NS)
Marginal integrity	0/120 (0)	0/116 (0)	0.511 (NS)	1/118 (0.84)	0.210 (NS)	3/116 (2.5)	0.321 (NS)
Anatomical form	0/120 (0)	2/116 (1.72)	0.511 (NS)	3/118 (2.54)	0.612 (NS)	3/116 (2.5)	0.321 (NS)

*Fisher's exact test at $P < 0.05$ significant

participants on school working days and were instructed to get it signed by their parents before returning the same to the examiner on the next day. Sealant was placed in such a manner that out of 240 teeth, sealant along with the fifth-generation bonding agent was placed on 60 teeth, that is, 15 maxillary right molar, 15 maxillary left molar, 15 mandibular right molar, and 15 mandibular left molar. Similarly, 60 teeth were sealed with sealant along with the seventh-generation bonding agent and remaining 120 contralateral teeth were sealed with sealant alone (split mouth design). Explorer was used to check the sealant retention. Micromotor headpiece and finishing burs were used to make the necessary occlusal adjustments. For the maintenance of the oral hygiene, instructions were given to all the study subjects [Figure 2].

Clinical evaluation of marginal integrity, discoloration, and anatomical form will be rated at baseline, 1st month, 3rd month, and after 6 months [Figures 3-5]. After drying each tooth, the detailed examination was done to assess the sealant success, according to the criteria given by Feigal *et al.*

A total of 58 subjects were available at first follow-up visit (after 1 month), that is, two subjects were not present on the follow-up day. A total of 59 subjects were available at second visit (after 3 months), and finally, 58 subjects were present at the final follow-up (6 months).

Statistical Analysis

The statistical analysis was done using Statistical Package for the Social Sciences Version 22.0 statistical analysis software.

The values were represented in number and percentages (%). Fisher's exact *t*-test and Chi-square tests were used.

RESULTS

Table 1 shows the distribution of teeth for sealant placement in maxillary and mandibular arches. Out of 240 teeth, 120 teeth (60 teeth in maxilla and 60 teeth in mandible) were sealed with sealant alone, 60 teeth (30 teeth in maxilla and 30 teeth in mandible) were sealed with sealant plus fifth-generation bonding agent and 60 teeth (30 teeth in maxilla and 30 teeth in mandible) were sealed with sealant plus seventh-generation bonding agent.

In Table 2, out of 60 schoolchildren, there were 33 males and 27 females. Sixty-six teeth in males and 54 teeth in females were receiving sealant alone while 33 teeth in males and 27 teeth in females each were receiving sealant along with the 5th generation and 7th generation bonding agents. There was no statistically significant difference found in sealant loss (anatomical form) among all the three groups at 1, 3, and 6 months interval.

Table 3 shows that 30 teeth in maxilla and 30 teeth in mandible received sealant along with 5th generation and 7th generation bonding agent whereas 60 teeth in maxilla and 60 teeth in mandible received sealant alone. There was no statistically significant difference found in sealant retention among maxillary and mandibular teeth in 5th generation, 7th generation and sealant alone at 1, 3 and 6 months of interval.

The comparison of marginal discoloration, marginal integrity and anatomical form in 5th generation group at 1, 3 and 6 month intervalis shown in Tables 4 and 5 shows the comparison of Marginal discoloration, Marginal integrity and Anatomical form in 7th generation group at 1, 3 and 6 month interval. Similarly Table 6 shows the comparison of Marginal Discoloration, Marginal Integrity and Anatomical Form in sealant group at 1, 3 and 6 month interval. Table 7 shows the comparison of marginal discoloration, marginal integrity and anatomical form among all the groups at 1, 3 and 6 month of interval. There was no statistically significant difference found among all the three groups. Table 8 shows the comparison of sealant retention (anatomical form) between baseline and 1month, 1 and 3 months and 3 and 6 months among 5th generation, 7th generation and sealant group. There was no statistically significant difference found among all the three groups.

DISCUSSION

5th Generation Versus Sealant

Out of 60 schoolchildren, 33 in males and 27 in females were receiving sealant along with the 5th generation bonding

Table 7: Comparison of marginal discoloration, marginal integrity, and anatomical form among all the groups at 1, 3, and 6 months interval

Intergroup comparison	1 month					3 months					6 months				
	Total no. of teeth	Marginal discoloration scores	Marginal integrity scores	Anatomical form scores	Total no. of teeth	Marginal Discoloration Scores	Marginal integrity scores	Anatomical form scores	Total no. of teeth	Marginal discoloration scores	Marginal integrity scores	Anatomical form scores
		0 1 3	0 1 3	0 2b 3		0 1 3	0 1 3	0 2b 3		0 1 3	0 1 3	0 2b 3
5th generation	58	56 2 -	54 2 -	53 3 2	59	56 2 1	56 2 1	54 3 2	58	55 2 1	56 2 2	52 3 3
7th generation	58	58 - -	57 1 -	57 1 -	59	59 - 1	59 1 1	57 1 1	58	57 - 1	58 2 1	57 1 1
Sealant	116	115 - 1	114 - -	114 1 1	118	117 - 1	117 - 1	115 2 1	116	115 - 1	115 2 1	115 2 1
Overall (among groups)		χ^2=2.103; *P*=0.326	χ^2=2.45; *P*=0.159	χ^2=2.082; *P*=0.102		χ^2=3.03; *P*=0.301	χ^2=2.06; *P*=0.436	χ^2=7.85; *P*=0.051		χ^2=2.713; *P*=0.273	χ^2=1.916; *P*=0.384	χ^2=4.38; *P*=0.130
5th versus 7th Gen		χ^2=1.318; *P*=0.215	χ^2=0.017; *P*=0.279	χ^2=1.77; *P*=0.121		χ^2=1.15; *P*=0.251	χ^2=1.03; *P*=0.251	χ^2=4.12; *P*=0.062		χ^2=0.321; *P*=1.001	χ^2=0.134; *P*=1.011	χ^2=0.86; *P*=0.285
5th Gen versus sealant		χ^2=1.921; *P*=0.197	χ^2=2.052; *P*=0.062	χ^2=3.62; *P*=0.082		χ^2=1.14; *P*=0.210	χ^2=2.46; *P*=0.168	χ^2=3.83; *P*=0.074		χ^2=0.414; *P*=0.106	χ^2=0.414; *P*=0.106	χ^2=4.03; *P*=0.060
7th Gen versus sealant		χ^2=0; *P*=1	χ^2=0.121; *P*=0.302	χ^2=0.99; *P*=0.303		χ^2=0.467; *P*=0.367	χ^2=1.40; *P*=0.145	χ^2=2.02; *P*=0.111		χ^2=0.414; *P*=0.106	χ^2=0.414; *P*=0.106	χ^2=0.500; *P*=0.621

*Chi-square test at $P < 0.05$ significant, **An attrition of 2, 1, and 2 subjects at 1, 3, and 6 months, respectively

agent. Statistically no significant difference was seen in sealant retention among males and females, which was similar to the study conducted by Kaur and Kaur,[9] whereas contradictory results were obtained in a study done by Jafarzadeh *et al.* in 2008 which stated that females had more sealant retention as compared to males, as in females, molars erupted early in the oral cavity as compared to males.[10]

In the present research, sealant retention loss was statistically non-significant as compared with maxillary and mandibular teeth at 1, 3, and 6 months periods, which is identical to the outcome of the study conducted by Bhushan and Goswami[11] and Tandon *et al.*[12] However, these findings were antithesis to the studies conducted by Kaur and Kaur,[9] AL-Sultani *et al.*,[13] and Rakesh *et al.*[14] which reported that upper teeth retained sealants better than the lower teeth. Such findings could be due to comparatively wider occlusal surface areas of mandibular teeth (as compared to maxillary teeth), which may allow the sealants to get more exposed to the oral atmosphere and reduce their retention.[14]

Anatomical Form

The percentage loss in anatomical forms at the end of 1, 3, and 6 months interval was 8.62%, 8.47%, and 10.34%, respectively, and statistically significant results were found ($P = 0.023$; $P = 0.011$; and $P = 0.012$). This finding was in contrary to the results obtained by Rakesh *et al.*[14] at 3 and 6 months interval. The authors in their study have concluded that pit and fissure sealants are successful in the prevention of dental caries, but no statistically significant variation was observed between retention of pit and fissure sealants.

7th Generation Versus Sealant

Sealant loss was recorded at 1, 3, and 6 months intervals for maxillary teeth and mandibular teeth, and this difference was found to be statistically non-significant, similar to the research conducted by Nikhil *et al.*[15] However, relative to mandibular teeth, the retention rate of maxillary molars was found to be poor and the difference was found by Feigal *et al.* to be statistically significant ($P = 0.03$). It agrees with previous evidence from going and associates (1977) and Horowitz *et al.* (1977), although there is no uniform finding in the literature on variance in sealant success by arch. However, equivalent declines between maxillary and mandibular molars were seen by an Australian clinical survey (Messer *et al.*, 1997), and others indicate slightly greater defects in mandibular sealants (Futatsuki *et al.*, 1995).[16]

Anatomical Form

At the end of the 1, 3, and 6 months interval, the percentage of marginal discoloration rates for teeth receiving sealant along with the 7th generation bonding agent was 1.72%, 3.39%, and 3.44%, respectively, and no statistically significant difference was found. Mohammad *et al.* also achieved similar findings in their research. The authors added that there were no statistically significant differences found in the retention of sealants by conventional acid etching and self-etching bonding agents. These results are similar to those of Boksman *et al.* who used ScotchBond 2 and universal bond and demonstrated no variations in sealant retention rates. Peng *et al.* in their analysis of the Adper Prompt SE adhesive and PAE system also did not find variations between the two groups at 12 months. These findings contrast with studies by Feigal *et al.* which documented improved preservation of sealants in teeth sealed with a primer and bond.[17]

On considering time period among the 7th generation group, the loss of sealant retention (anatomical form) between baseline and 1 month, 1 month and 3 months, and 3 months and 6 months interval was statistically non-significant.

5th versus 7th Generation Bonding Agent

When comparing the 5th generation to the 7th generation groups, the split mouth design was not considered as contralateral teeth were sealed with sealant alone.

Anatomical Form

Because more sealant retention losses (anatomical form) occurred in the 5th generation group relative to the 7th generation group, this difference was statistically significant. This result disagreed with a study performed by Aman *et al.*

Table 8: Comparison of sealant retention at different time interval

Overall comparison	Baseline	Baseline–1 month			1 month–3 months			3 months–6 months		
	Total no. of teeth	Total no. of teeth	Loss (%)		Total no. of teeth	Loss (%)		Total no. of teeth	Loss (%)	Chi-square; *P* value
5th generation	60	58	8.62	$\chi^2 = 0.345$; $P = 0.134$	59	1.9	$\chi^2 = 0.117$; $P = 0.611$	58	0.2	$\chi^2 = 0.003$; $P = 0.836$
7th generation	60	58	1.7	$\chi^2 = 0.213$; $P = 0.218$	59	1.6	$\chi^2 = 0.001$; $P = 0.672$	58	0.14	$\chi^2 = 0.001$; $P = 0.662$
Sealant	120	116	1.7	$\chi^2 = 0.115$; $P = 0.452$	118	0.8	$\chi^2 = 0.173$; $P = 0.338$	116	0.1	$\chi^2 = 0.003$; $P = 0.451$

*Chi-square test at $P < 0.05$ significant

in which, relative to the 7th generation bonding agent, a larger proportion of full retention was found in the total etch (5th generation bonding agent) arm.[18]

The 7th generation bond has more retention because, relative to the 5th generation bonding agent, it has greater microtensile bond strength.[19] Compared to the 7th generation group, more losses were seen in the 5th generation group at first follow-up. This may be attributed to the technique sensitivity at the time of sealant application. Since several steps were needed for the application of the bonding agent of the 5th generation, there are more chances of contamination of moisture that causes sealant retention failure.[20]

Literature does not include a clear response as to whether enamel bonded self-etch adhesives can survive the chemical and mechanical challenges of the oral cavity. Some clinical and experimental trials have found that the combination of self-etching adhesive systems with pit-and-fissure sealants is less effective than the use of etch-and-rinse adhesive systems.[19] Good results for this association have been reported by many other studies.[21,22]

Limitations

- Blinding could not be performed, as the operator and the examiner were the same person. To which extent, this factor affected the results of the study could not be assessed
- As the study was only for 6 months, long-term evaluation of the sealants could not be done.

CONCLUSIONS

Because it is difficult to obtain full monitoring of intraoral moisture, the development of a moisture-insensitive hydrophilic bonding agent will improve effective sealant retention. Since etch-and-rinse steps for the seventh-generation bonding agent are not needed separately, it can be recommended that the application of sealant along with the seventh-generation bonding agent can improve the success of the sealant and can also be used in field preventive programs for caries prevention.

REFERENCES

1. Amid I, Tellez M, Pitts BN, Ekstrand RK, Ricketts D, Longbottom C, *et al*. Caries management pathways preserve dental tissues and promote oral health. Community Dent Oral Epidemiol 2013;41:e12-40.
2. Deery C. Caries detection and diagnosis, sealants and management of the possibly carious fissure. Br Dent J 2013;214:551-7.
3. Oulis JC, Berdouses DE, Homata ME, Polychronopoulou A. Prevalence of sealants in relation to dental caries on the permanent molars of 12 and 15-year-old Greek adolescents. A national pathfinder survey. BMC Public Health 2011;11:100.
4. Chaitra TR, Reddy S, Devarasa GM, Ravishankar TL. Flowable resin used as a sealant in molars using conventional, enameloplasty and fissurotomy techniques: An *in vitro* study. J Indian Soc Pedod Prev Dent 2010;28:145-50.
5. Beauchamp J, Caufield PW, Crall JJ, Donly K, Feigal R, Gooch B, *et al*. Evidence-based clinical recommendations for the use of pit-and-fissure sealants: A report of the American dental association council on scientific affairs. J Am Dent Assoc 2008;139:257-68.
6. Council on dental materials and devices pit and fissure sealants. J Am Dent Assoc 1971;82:1101-3.
7. Newman GV, Sharpe LH. On the wettability of tooth surfaces: Preliminary investigation. J N Jersey Dent Assoc 1996;7:289-93.
8. Khetani P, Sharma P, Singh S, Augustine V, Baruah K, Thumpala KV, *et al*. History and selection of pit and fissure sealants-a review. J Med Dent Sci Res 2017;4:5-12.
9. Kaur S, Kaur M. Retention of pit and fissure sealants used by two different techniques: A comparatively study. Int J Appl Dent Sci 2018;4:70-2.
10. Jafarzadeh M, Malekafzali B, Tadayon N, Fallahi S. Retention of a flowable composite resin in comparison to a conventional resin-based sealant: One-year follow-up. J Dent (Tehran) 2010;7:1-5.
11. Bhushan U, Goswami M. Evaluation of retention of pit and fissure sealants placed with and without air abrasion pretreatment in 6-8 year old children-an *in vivo* study. J Clin Exp Dent 2017;9:e211-7.
12. Tandon V, Lingesha RT, Tangade PS, Tirth A, Pal SK, Lingesha CT, *et al*. Effect of adhesive application on sealant success: A clinical study of fifth and seventh generation adhesive systems. J Dent (Tehran) 2015;12:712-9.
13. Al-Sultani HF, Aljanabi WH, Hasan HA, Al-Murib NM, Alam MK. Clinical evaluation of pit and fissure sealants placed by undergraduate dental students in 5-15 years-old children in Iraq. Pesqui Bras Odontopediatria Clín Integr 2020;20:e5110.
14. Rakesh, Chhabra V, Sonia. Assessment of pit and fissure sealants retention using two different techniques. Int J Res Health Allied Sci 2020;6:54-7.
15. Nikhil V, Singh V, Chaudhry S. Comparative evaluation of bond strength of three contemporary self-etch adhesives: An *ex vivo* study. Contemp Clin Dent 2011;2:94-7.
16. Feigal RJ, Musherure P, Gillespie B, Levy-Polack M, Quelhas I, Hebling J. Improved sealant retention with bonding agents: A clinical study of two-bottle and single-bottle systems. J Dent Res 2000;79:1850-6.
17. Mohammed PI, Jaleel FB, Hiremath SS, Manjunath C, Amarah U, Krishnamoorthy A. Comparison of effectiveness of traditional acid etching and of the selfetching agent in sealant retention: A randomized controlled trial. J Indian Assoc Public Health Dent 2016;14:4-9.
18. Aman N, Khan RF, Salim A, Farid H. A randomized control clinical trial of fissure sealant retention: Self etch adhesive versus total etch adhesive. J Conserv Dent 2015;18:20-4.
19. Feigal RJ, Quelhas I. Clinical trial of a self-etching adhesive for sealant application: Success at 24 months with Prompt L-Pop. Am J Dent 2003;16:249-51.
20. Das UM, Viswanath D, Venkat S, Suma G. Retention of pit and fissure sealants with and without seventh generation bonding agents: A clinical study. Dent India 2008;2:1-6.
21. Hannig M, Grafe A, Atalay S, Bott B. Microleakage and SEM evaluation of fissure sealants by use of self-etching priming agents. J Dent 2004;32:75-81.
22. Al-Sarheed MA. Evaluation of shear bond strength and SEM observation of all-in one self-etching primer used for bonding of fissure sealants. J Contemp Dent Pract 2006;7:9-16.

How to cite this article: Mir H, Shivalingesh KK, Srivastava D, Saleem A, Ashraf W, Pathak S. Evaluation of Two Adhesive Systems on the Pit and Fissure Sealant Success in Permanent Molars: An *In vivo* Study. Int J Sci Stud 2021;9(1):58-64.

Source of Support: Nil, **Conflicts of Interest:** None declared.

Print ISSN: 2321-6379
Online ISSN: 2321-595X

Original Article

Effect Occupational Exposure to Rice Husk Dust on the Levels of Oxidative Stress Markers and Pulmonary Functions in Individuals Working in Rice Mills Around Raichur District Urban Area

Praveen S. Patil[1], Manjunath Aithal[2], Sushrit A. Neelopant[3]*

[1]Tutor, Department of Physiology, Raichur Institute of Medical Sciences, Raichur, Karnataka, India, [2]Professor, Department Of Physiology, Shri B M Patil Medical College, Hospital and Research Centre, BLDE University, Vijayapura, Karnataka, India, [3]Assistant Professor, Department of Community Medicine, Raichur Institute of Medical Sciences, Raichur, Karnataka, India

Abstract

Introduction: Air pollution to heart disease linkage involves the direct effects of pollutants on the CVS, blood/lung receptors, and/or indirect effects also mediated through inflammatory responses and pulmonary oxidative stress. The lung is an important target for pro-oxidant compounds mediated genotoxicity. The products such malondialdehyde (MDA) provide the evidence to support the involvement of free radical reaction in toxicology and disease. Increased levels of nitric oxide (NO) cause loss of local vascular regulation, vasoconstriction, and mechanical blockage of vessels cause a reduction in pulmonary vascular region. Both Vitamin C and Vitamin E are powerful antioxidants found in the lungs where they protect cells from oxidative damage.

Objectives: The objectives of the study were to evaluate the effect of rice husk dust on the levels of oxidative stress markers and pulmonary functions in the individuals working in rice mills by analyzing pulmonary function tests (PFTs) and estimating oxidative stress markers.

Materials and Methods: The study was carried on 134 rice mill workers. The PFTs and oxidative stress markers were estimated. Statistical analysis was carried out by applying Student's "*t*" test, ANOVA, and regression analysis.

Results: Forced expiratory volume$_1$ percentage was significantly reduced in elder age groups and long-term exposure groups compared to young age group and short-term exposure group individuals, respectively. MDA, NO levels were increased and Vitamin-C levels decreased in elder age groups and long-term exposure groups compared to young age group and short-term exposure group individuals, respectively. On regression analysis, there was an association with increased age and exposure duration with PFTs and oxidative stress markers.

Conclusion: The findings of the study clearly indicated the deleterious effect of long-term exposure to rice husk dust on pulmonary functions and also causing increased oxidative stress in the individuals. Furthermore, advancing age found to be additive factor for the levels of oxidative stress markers and decreased pulmonary functions.

Key words: Malondialdehyde, Nitric oxide, Oxidative stress, PFTs, Rice husk dust, Vitamin-C

INTRODUCTION

Many studies have found that increased cardiovascular morbidity and mortality are associated with exposure to ambient air pollution, particularly particulate matter. There is no clear evidence whether such dust exposures increase the risk for ischemic heart disease or not. Till now, there is limited knowledge of the underlying mechanisms in pathogenesis.

A analytical study on carpenters to analyze the long-term occupational exposure to airborne wood dust particulate matter on oxidative stress showed a significant increase in serum malondialdehyde (MDA) with significant decrease in antioxidant level.

Access this article online

IJSS
www.ijss-sn.com

Month of Submission : 02-2021
Month of Peer Review : 03-2021
Month of Acceptance : 03-2021
Month of Publishing : 04-2021

Corresponding Author: Sushrit A. Neelopant, Department of Community Medicine, Raichur Institute of Medical Sciences, Raichur, Karnataka, India.

According to the reputed biological mechanisms, air pollution to heart disease linkage involves the direct effects of pollutants on the CVS, blood/lung receptors, and/or indirect effects also mediated through inflammatory responses and pulmonary oxidative stress.[1] The direct effects may possibly mediate through many varieties of agents which can readily cross the pulmonary epithelium into the systemic circulation. Within the systemic circulation, these direct effects stand for a probable explanation for the mechanism of rapid cardiovascular responses such as increased myocardial infarctions.[2]

The lung is an important target for pro-oxidant compounds mediated genotoxicity because the bronchial epithelium being a physicochemical barrier plays a crucial role in initiating and augmenting defense as well as signaling systemic responses.

The detection and measurement of lipid peroxidation products such MDA provide the evidence to support the involvement of free radical reaction in toxicology and disease

Increased levels of nitric oxide (NO) cause loss of local vascular regulation, vasoconstriction, and mechanical blockage of vessels all together cause a reduction in pulmonary vascular region.[3-5]

Each tissue has an antioxidant potential which is determined by the balance between factors promoting auto-oxidation and those exerting an antioxidant action. Multiple lines of antioxidant defense have evolved and serve to protect human body from oxidative stress including prevention, interception, and repair.[6,7]

Vitamin C (ascorbic acid) is a principal and powerful antioxidant. It works in aqueous environment of the body. Both Vitamin C and Vitamin E are powerful antioxidants found in the lungs where they protect cells from oxidative damage.[8] Vitamin C quickly identifies and removes many reactive species.[9]

Many prospective studies so far have observed an inverse relationship between Vitamin C intake and cardiovascular diseases and also a strong protective effect of Vitamin E supplementation on coronary patients. Finnish and Swiss studies indicated that myocardial infarction is predicted in diminished nutritional status of vitamin and low blood levels of ascorbate. Low levels of Vitamin C increases 2.7 times the risk of myocardial infarction and this is independent of other risk factors.

MATERIALS AND METHODS

Study Design

It was cross-sectional analytical study.

1. Exposed
2. Unexposed.

Risk factor included was – exposure to dust.

Sample size

One hundred and thirty-four individuals were selected in each group.

Control – appropriate number of non-exposed subjects of same age group were selected as control.

Inclusion Criteria

- Volunteered rice mill workers aged above 20 and below 50 were included
- Only male individuals were selected
- Individuals working in rice mills having experience of 5 years or more were included
- Only rice mill workers who were working in dust and exposed to dusty environment were included in the study.

Informed consent was taken from all the individuals participated in the study. While the collection of data, structured questionnaire was used. It has helped to determine information in regard of general health, disease history, duration of exposure, and details of habits such as smoking and alcohol consumption.

Recording of lung function parameters: For the recording of lung function parameters, a computerized digital spirometer (SPIRO EXCEL 1.3) was used.

Before recording of pulmonary function tests (PFTs), individual participants were thoroughly explained regarding the procedure in their own language along with demonstration of the procedure.

For estimation of serum MDA and serum NO- 6 ml of intravenous blood was collected in plane tubes. Moreover, 2 ml of blood was collected in EDTA tube for estimation of ascorbic acid in plasma.

- Estimation of serum lipid peroxide (MDA)[10]
- Estimation of serum NO as nitrite (NO)[11]
- Estimation of serum ascorbic acid by phenyl-hydrazine[12] spectrophotometry method.

RESULTS

Table 1 shows the Mean±SD of exposed and control groups. Student's "*t*" test was applied to know the significance between both the groups, $P < 0.05$ is considered as significant difference at CI of 95%. There were no significant differences in age, height, and weight between individuals of both the groups. Body mass index of both the groups has found in normal limits though groups show statistically significant difference ($P < 0.05$).

Table 2 shows the Mean ± SD of PFT parameters of study and control groups. Forced vital capacity (FVC) of exposed individuals has found significantly lower than control group individuals ($P < 0.0001$). Forced expiratory volume in first second ($FEV_{1)}$ of exposed group individuals is also found significantly low compared to control group. Hence, FEV_1/FVC ratio is exposed group individuals, is also found significantly lower in comparison with control group individuals. Obtained values of PFT parameters of both the groups were in the lower normal limit.

Table 3 depicts the Mean±SD values of serum levels of MDA, NO, and also plasma level of Vitamin-C of exposed and control group. Oxidants level (MDA and NO) in exposed group was highly significant ($P < 0.0001$) compared to control group.

Exposed group was divided into three subgroups based on exposure duration to know the effect of duration of exposure. 5–9 years as exposed-I ($n = 82$), 10–18 years as exposed-II ($n = 31$), and 19–27 years as exposed-III ($n = 21$).

Table 4 represents Mean±SD of different groups and analysis of effect of duration of exposure to dust in rice mills on PFTs using ANOVA followed by *post hoc* "*t*" test. There was significant effect of exposure duration on FVC, FEV_1, and FEV_1/FVC of rice mill workers, exposed-III group showed below normal level of FEV_1/FVC ratio than exposed-I and exposed-II groups. *Post hoc* "*t*" test was performed to know the significantly affected group. There was significant decrease in FVC, FEV_1, and FEV_1/FVC ratio in all the groups of comparison.

Table 5 represents Mean ± SD of PFT parameters of exposed individuals with different age groups. Student's unpaired "*t*" test showed significant differences in FVC ($P < 0.001$) and FEV_1 ($P < 0.001$) among all the age groups of comparison whereas FEV_1/FVC ratio was significantly decreased in exposed individuals of Group-II and Group-III. There was no significance in FEV_1/FVC ratio of Group-I.

Table 1: Anthropometric parameters of the study and control groups

Parameters	Mean±SD of exposed (*n*=134)	Mean±SD of control (*n*=134)	*P* value
Age (years)	29.24±5.899	32.81±8.705	-
Height (cm)	165.0±4.799	164.6±6.168	0.562
Weight (kg)	59.21±8.777	60.87±6.830	0.084
Body mass index (kg/m^2)	21.75±3.019	22.43±1.541	0.022*
Years of exposure (years)	9.776±6.476	-	-

*–*P*<0.05, **–*P*<0.01, ***–*P*<0.001

Table 2: Comparison of Mean±SD of pulmonary function test parameters of study and control groups

Parameters	Mean±SD of exposed (*n*=134)	Mean±SD of control (*n*=134)	*P*- value
FVC (forced vital capacity) (in liters)	2.890±0.465	3.233±0.322	*P*<0.0001***
FEV_1 (forced expiratory volume in first second) (in liters)	2.232±0.472	2.630±0.361	*P*<0.0001***
Forced expiratory volume$_1$/forced vital capacity ratio (%)	76.88±8.937	81.16±5.914	*P*<0.0001***

*–*P*<0.05, **–*P*<0.01, ***–*P*<0.001

Table 3: Comparison Mean±SD of biochemical parameters of study and control groups

Parameters	Mean±SD of exposed (*n*=134)	Mean±SD of control (*n*=134)	*P*-value
Serum malondialdehyde (μmol/l)	7.009±1.892	5.639±2.091	*P*<0.0001*
Serum nitric oxide (μmol/l)	51.03±16.812	36.73±14.157	*P*<0.0001*
Plasma Vitamin C (mg/l)	0.863±0.324	1.173±0.262	*P*<0.0001*

*–*P*<0.05,**–*P*<0.01,***–*P*<0.001

Table 6 depicts the Mean ± SD of serum MDA, serum NO, and plasma Vitamin-C of exposed and control individuals in different age groups (Group-I, Group-II, and Group III). There was significant difference obtained in plasma Vitamin-C ($P < 0.01$) of exposed individuals in Group-I. No significant differences obtained in serum levels of MDA and NO in Group-I. There were high serum levels of MDA ($P < 0.01$), NO ($P < 0.001$), and low level of plasma Vitamin-C ($P < 0.001$) of exposed individuals in Group-II and there were higher serum levels of MDA ($P < 0.001$), NO ($P < 0.001$), and lower level of plasma Vitamin-C ($P < 0.001$) of exposed individuals in Group-III compared to Group I and II.

Regression analysis was done to know the association of different predictors on dependent variables.

Table 4: ANOVA followed by *post hoc* "*t*" test showing Mean±SD of pulmonary function test parameters of study group with duration of exposure

Parameters	Control (Mean±SD) *n*=134	Exposed-I (5–9 years) (Mean±SD) *n*=82	Exposed-II (10–18 years) (Mean±SD) *n*=31	Exposed-III (19–27 years) (Mean±SD) *n*=21	F value	*P* value
FVC (forced vital capacity) (in liters)	3.233±0.322	2.924±0.374	2.801±0.643	2.891±0.485	17.133	0.000***
FEV_1 (forced expiratory volume in first second) (in liters)	2.629±0.361	2.335±0.369	2.091±0.665	2.037±0.389	25.370	0.000***
Forced expiratory volume $_1$/ Forced vital capacity ratio (%)	81.161±5.914	79.816±6.855	73.339±11.478	70.018±7.863	20.763	0.000***

Post hoc "*t*" test

Parameters	Control versus exposed-I	Control versus exposed-II	Control versus exposed-III
	P -value	*P* -value	*P* -value
FVC (forced vital capacity) (in liters)	0.000***	0.000***	0.001**
FEV_1 (forced expiratory volume in first second) (in liters)	0.000***	0.000***	0.000***
Forced expiratory volume $_1$/ Forced vital capacity ratio (%)	0.434	0.000***	0.000***

*–*P*<0.05, **–*P*<0.01, ***–*P*<0.001

Table 5: Comparison of Mean±SD of biochemical parameters of exposed individuals with different age groups

Parameters	Group I (21–30 years)			Group II (31–40 years)			Group III (41–50 years)		
	Control (*n*=68)	Exposed (*n*=68)	*P* Value	Control (*n*=32)	Exposed (*n*=33)	*P* value	Control (*n*=34)	Exposed (*n*=33)	*P* value
Serum malondialdehyde (μmol/l)	5.659±2.251	6.291±1.647	0.064	5.969±1.981	7.503±1.757	0.002**	5.288±1.848	7.994±1.941	*P*<0.0001***
Serum nitric oxide (μmol/l)	37.61±16.26	42.18±14.09	0.082	36.56±9.591	59.63±15.22	P<0.0001***	35.13±13.43	60.69±13.72	*P*<0.0001***
Plasma Vitamin C (mg/l)	1.176±0.265	1.018±0.308	0.002**	1.241±0.201	0.709±0.257	P<0.0001***	1.103±0.292	0.696±0.258	*P*<0.0001***

*–*P*<0.05,** –*P*<0.01,*** –*P*<0.001

On consideration of FEV_1/FVC ratio as dependent variable and exposure, age, MDA, Vitamin-C, and NO as constants, the R squared value(r^2) obtained was 28.2%. There was significant association of exposure ($P < 0.05$) and age ($P < 0.001$) on FEV_1/FVC ratio of exposed individuals. There was no significant association of MDA, Vitamin-C, and NO with FEV_1/FVC ratio of exposed individuals.

On consideration of MDA as dependent variable and exposure, age, Vitamin-C, and NO as constants, the R squared value (r^2) obtained was 70.5%. There was significant association of Vitamin-C ($P < 0.001$) on MDA of exposed individuals. There was no significant association of exposure, age, and NO on MDA of exposed individuals.

On consideration of NO as dependent variable and exposure, age, Vitamin-C, and MDA as constants, the R squared value (r^2) obtained was 85.8%. There was significant association of age ($P < 0.01$) Vitamin-C ($P < 0.001$) on NO of exposed individuals. There was no significant association of exposure and MDA on NO of exposed individuals.

On consideration of Vitamin-C as dependent variable and exposure, age, MDA, and NO as constants, the R squared value (r^2) obtained was 89.5%. There was significant association of MDA ($P < 0.001$) and NO ($P < 0.001$) on Vitamin-C in exposed individuals. There was no significant association of exposure, age Vitamin-C of exposed individuals.

There was no significant association of any of the dependent variables with the constants in control group individuals.

In the present study, we have obtained lower FVC ($P < 0.0001$), FEV1 ($P < 0.0001$), and FEV1/FVC ratio ($P < 0.0001$) compared to control [Table 2]. However, the obtained values are within the normal limits and are statistically significant. Our results are in agreement with the conclusions of Gildea and McCarthy (2003). They obtained a low but not a significant decrease in FVC relative to the control groups. However, absence of alteration in pulmonary function cannot be justified by FVC alone because in patients with obstructive lung diseases, FVC

Table 6: Regression analysis showing the effect of different predictors on dependent variables in exposed group

Dependent variable: FEV_1/FVC ratio				
Group	**R Value**	**R Square (r^2)**	**Constants**	**Significance**
Exposed	0.531 (53.1%)	0.282 (28.2%)	Exposure	0.028*
			Age	0.000***
			MDA	0.191
			Vitamin C	0.690
			Nitric oxide	0.786
Controls	0.121 (12.1%)	0.015 (1.5%)	Exposure	Not applicable
			Age	0.713
			MDA	0.232
			Vitamin C	0.515
			Nitric oxide	0.744
Dependent variable: MDA				
Group	**R Value**	**R Square (r^2)**	**Constants**	**Significance**
Exposed	0.840 (84.0%)	0.705 (70.5%)	Exposure	0.362
			Age	0.735
			Vitamin C	0.000***
			Nitric oxide	0.370
Controls	0.121 (12.1%)	0.015 (1.5%)	Exposure	Not applicable
			Age	0.362
			Vitamin C	0.419
			Nitric oxide	0.584
Dependent variable: NO				
Group	**R Value**	**R Square (r^2)**	**Constants**	**Significance**
Exposed	0.926 (92.6%)	0.858 (85.8%)	Exposure	0.350
			Age	0.004**
			Vitamin C	0.000***
			MDA	0.370
Controls	0.160 (16.0%)	0.025 (2.5%)	Exposure	Not applicable
			Age	0.425
			Vitamin C	0.127
			MDA	0.584
Dependent variable: Vitamin C				
Group	**R Value**	**R Square (r^2)**	**Constants**	**Significance**
Exposed	0.946 (94.6%)	0.895 (89.5%)	Exposure	0.895
			Age	0.820
			Nitric oxide	0.000***
			MDA	0.000***
Controls	0.162 (16.2%)	0.026 (2.6%)	Exposure	Not applicable
			Age	0.457
			Nitric oxide	0.127
			MDA	0.419

*–P<0.05, **–P<0.01, ***–P<0.001. FVC: Forced vital capacity, FEV: Forced expiratory volume, MDA: Malondialdehyde

can be normal or slightly decreased."[13] Similar results have been seen in the study carried out by Anupriya *et al.*[14] on saw mill workers.

Among the duration of dust exposure groups, we have obtained clinically significant lower values of FVC (P < 0.0001), FEV1 (P < 0.0001), and FEV1/FVC (P < 0.0001) ratio in higher exposure duration groups (1–9 years >10–18 years >19–27 years) compared to control group [Table 4]. Decrease in FVC and FEV1 may be due to obstructive impairment which further increases with increase in number of years of exposure. In other words, there is a dose exposure relationship. Similar research studies conducted by Al-Neaimi *et al.* 2001 and Mwaiselage *et al.* 2004. The results also showed a significant reduction in FEV1%, which is an indication of obstructive impairment it is in turn may be due to mechanical irritation caused by dust exposure and individual susceptibility. These changes in pulmonary volume suggest an urgent need of improvement in dust control measures and health awareness toward dust preventive measures.[15,16]

In comparison of FVC, FEV_1, and FEV_1/FVC ratio of study group with control group among different individuals with age groups [Table 5], we have obtained significantly lower values of higher age groups (21–30 years >31–40 years >41–50 years). This show as the age advances there is decrease in flexibility hence loss of compliance and also increased airway resistance, which ultimately leads to decrease in FVC, FEV_1, and FEV_1/FVC ratio. Our results are in contrast to the results obtained by Ghotkar *et al.*[17] They have shown as there is no significant decrease in FEV_1/FVC ratio, though there is decrease in values of FEV_1 and FVC in groups of individuals with increase in age.

Our study is in agreement with Hernberg *et al.* also shown that "there is a strong significant association between MDA level and oxidative stress. He also proved that ascorbic acid has significant role in reducing the oxidative stress."[18]

In the present study, we have categorized the exposed individuals into three groups based on years of exposure. We have noticed that as the duration of exposure increased, there were marked increase in oxidative stress markers such as MDA and NO. Ascorbic acid level was significantly reduced in groups of individuals with longer duration of exposure. The present study is supported by the previous study conducted by Debra *et al.*, they observed as duration of exposure was increased, oxidative stress effect was also enhanced. They showed long-term exposure to cotton dust results in inflammatory cell migration into the air spaces. This will generate reactive oxygen species by opsonization, thereafter appear to precede increased lung permeability and reflect a loss of integrity of epithelial tight junction.[19]

On regression analysis for effect of different predictors on dependent variables, we have obtained positive correlation between age and FEV_1/FVC percentage, negative correlation between exposure duration and FEV_1/FVC percentage. Other predictors showed no significant effect in exposed group. There was a negative correlation between serum MDA, serum NO, and antioxidant Vitamin C. Age has shown positive correlation on serum level of NO

Table 7: ANOVA showing Mean±SD of biochemical parameters of study group with duration of exposure

Parameters	Control (Mean±SD) *n*=134	Exposed-I (5–9 years) (Mean±SD) *n*=82	Exposed-II (10–18 years) (Mean±SD) *n*=31	Exposed-III (19–27 years) (Mean±SD) *n*=21	F value	*P* value
Serum malondialdehyde (μmol/l)	5.639±2.091	6.627±1.749	7.600±2.103	7.629±1.797	13.425	0.000***
Serum nitric oxide (μmol/l)	36.729±14.157	48.316±17.620	54.251±15.252	56.899±13.817	21.591	0.000***
Plasma Vitamin C (mg/l)	1.173±0.262	0.915±0.331	0.798±0.330	0.752±0.248	27.708	0.000***

Post hoc "t" test

Parameters	Control versus exposed-I	Control versus exposed-II	Control versus exposed-III
	P-value	*P*-value	*P* value
Serum malondialdehyde (μmol/l)	0.001**	0.000***	0.000***
Serum nitric oxide (μmol/l)	0.000***	0.000***	0.000***
Plasma Vitamin C (mg/l)	0.000***	0.000***	0.000***

*–*P*<0.05,**–*P*<0.01,***–*P*<0.001

Table 8: Comparison of Mean±SD of pulmonary function test parameters of exposed and control individuals with different age groups

Parameters	Group I (21–30 years)			Group II (31–40 years)			Group III (41–50 years)		
	Control (*n*=68)	Exposed (*n*=68)	*P* value	Control (*n*=32)	Exposed (*n*=33)	*P* value	Control (*n*=34)	Exposed (*n*=33)	*P* value
FVC (forced vital capacity) (in liters)	3.272±0.30	3.033±0.346	*P*<0.0001***	3.280±0.302	2.906±0.439	0.0002***	3.111±0.344	2.580±0.560	*P*<0.0001***
FEV_1 (forced expiratory volume in first second) (in liters)	2.644±0.334	2.443±0.349	0.0008***	2.712±0.370	2.198±0.387	*P*<0.0001***	2.522±0.389	1.831±0.510	*P*<0.0001***
Forced expiratory $volume_1$/Forced expiratory volume ratio (%)	80.72±5.946	80.55±7.002	0.885	82.49±6.485	75.70±6.708	*P*<0.0001***	80.80±5.236	70.47±10.58	*P*<0.0001***

*–*P*<0.05, **–*P*<0.01, ***–*P*<0.001

among exposed group. There was no significant correlation between predictors and dependent variables in control group [Tables 7 and 8].

CONCLUSION

- FVC, FEV_1, and FEV_1/FVC percentage were significantly decreased in exposed group compared to control group. This indicates the adverse effect of dust exposure on lung function parameters
- Decrease in values of PFT parameters was observed in group with exposure duration of 19–27 years compared to groups with exposure duration of 10–18 years and 5–9 years. It is concluded that the duration of exposure is increased, the vital capacity of lungs decreased significantly. Expiratory capacity also decreased significantly which indicates that there is an increase in airway obstruction as the duration of exposure to dust is increased
- Significant decrease in PFT parameters was observed in group III (age 41–50 years) compared to group II (age 31–40) and Group I (age 21–30). It signifies that as age advances, there is decrease in vital capacity along with increase in airway resistance. Therefore, abnormal decrease in efficiency of lungs may occur
- On comparison with control group, we found significant increase in serum levels of MDA and NO which are oxidants present in blood and are regarded as oxidative stress markers. We found significant decrease in plasma level of ascorbic acid which is a first line of defense among the antioxidants. These findings show that there is an increased oxidative stress which could be the causative factor for cardiovascular dysfunction and hematological abnormalities in rice mill workers on longstanding exposure.
- When individuals are grouped according to age and exposure duration, elderly age group and long-term exposure groups have shown mild decrease in PFTs. These groups have also shown increased stressor level to upper normal values and decreased anti-stressor to lower normal values. As the age advances adverse effect of dust on serum NO level is enhanced. This is an alarming message for individuals working in rice mills that continued and longstanding exposure may lead to increased oxidative stress and oxidative damage.

- It may be advisable to estimate levels of oxidative stress markers such as serum MDA, serum NO, and plasma ascorbic acid as routine investigations for industrial workers.
- Supplementation of Vitamin C may be recommended for rice mill workers.
- Dietary supplementations of citrus fruits and vegetables may be advised for such workers.

Limitations

- We have not estimated the chemical and physical properties of dust to which workers were exposed
- We have not estimated the total antioxidant level
- Female individuals were not included in the study.

ACKNOWLEDGMENTS

Self.

REFERENCES

1. Brook R, Franklin B, Cascio W, Hong Y, Howard G, Lipsett M, *et al*. Air pollution and cardiovascular disease: A statement for healthcare professionals from the Expert Panel on Population and Prevention Science of the American Heart Association. Circulation 2004;109:2655-71.
2. Peters A, Dockery DW, Muller JE, Mittleman MA. Increased particulate air pollution and the triggering of myocardial infarction. Circulation 2001;103:2810-5.
3. Henson PE, Johnston RB. Tissue injury in inflammation. Oxidants, proteinases, and cationic proteins. J Clin Invest 1987;79:669-74.
4. Crystal RG. Oxidants and respiratory tract epithelial injury: Pathogenesis and strategies for therapeutic intervention. Am J Med 1991;91:39S-44.
5. Cotran RS, Kumar V, Robbins SL. Robbins and Cotran Pathologic Basis of Disease. 6th ed. Singapure: Hartcourt Asia Private Ltd.; 1999. p. 584.
6. Fuchs J. Oxidative Injury in Dermatopathology. Berlin: Springer; 1992.
7. Cheeseman KH, Slater TF. An introduction to free radical biochemistry. Br Med Bull 1993;49:481-93.
8. Heffner JE, Repine JE. Pulmonary strategies of antioxidant defense. Am Rev Respir Dis 1989;140:531-54.
9. Gueguen S, Pirollet P, Leroy P, Guilland JC, Arnaud J, Paille F, *et al*. Changes in serum retinol, alpha-tocopherol, vitamin C, carotenoids, xinc and selenium after micronutrient supplementation during alcohol rehabilitation. J Am Coll Nutr 2003;22:303-10.
10. Satoh K. Serum lipid peroxide in cerebrovascular disorders determined by a new colorimetric method. Clin Chem Acta 1978;90:37-43.
11. Cortas NK, Wakid NW. Determination of inorganic nitrate in serum and urine by a kinetic cadmium-reduction method. Clin Chem 1990;36:1440-3.
12. Burtis CA, Ashwood ER. Tietz Textbook of Clinical Chemistry and Molecular Diagnosis. 3rd ed. St. Louis: Elsevier; 1999. p. 1024-5.
13. Gildea TR, Mccarthy K. Pulmonary Function Tests. Cleveland: Cleveland Clinic Center for Continuing Education; 2003.
14. Deshpande A, Afshan A. Effect of chronic exposure of sawdust in workers employed in sawmills: A cross-sectional study. Sch J Appl Med Sci 2014;2:1202-5.
15. Al-Neaimi YI, Gomes J, Lloyd OL. Respiratory illnesses and ventilatory function among workers at a cement factory in a rapidly developing country. Occup Med (Lond) 2001;51:367-73.
16. Mwaiselage J, Bratveit M, Moen B, Mashalla T. Cement dust exposure and ventilatory function impairment: An exposure-response study. J Occup Environ Med 2004;46:658-67.
17. Ghotkar VB, Maldhure BR, Zodpey SP. Involvement of lung function tests in stone quarry workers. Indian J Tuberc 1995;42:155-60.
18. Hernberg S, Kärävä R, Koskela RS, Luoma K. Angina pectoris, ECG findings and blood pressure of foundry workers in relation to carbon monoxide exposure. Scand J Work Environ Health 1976;2 Suppl 1:54-63.
19. Sherman DL, Keaney JF Jr., Biegelsen ES, Duffy SJ, Coffman JD, Vita JA. Pharmacological concentrations of ascorbic acid are required for the beneficial effect on endothelial vasomotor function in hypertension. Hypertension 2000;35:936-41.

How to cite this article: Patil PS, Aithal M, Neelopant SA. Effect Occupational Exposure to Rice Husk Dust on the Levels of Oxidative Stress Markers and Pulmonary Functions in Individuals Working in Rice Mills Around Raichur District Urban Area. Int J Sci Stud 2021;9(1):65-71.

Source of Support: Nil, **Conflicts of Interest:** None declared.

Print ISSN: 2321-6379
Online ISSN: 2321-595X

Original Article

High Resolution Ct Features of Coronavirus Disease Pneumonia: Initial and Follow-up Changes

Ankit Shah[1], Satish Kumar Raghuwanshi[2], Lovely Kaushal[3]

[1]Senior Resident, Department of Radio diagnosis, Gandhi Medical College and Hamidia Hospital, Bhopal, Madhya Pradesh, India, [2]Junior Resident, Department of Radio Diagnosis, Gandhi Medical College and Hamidia Hospital, Bhopal, Madhya Pradesh, India, [3]Professor and Head, Department of Radio diagnosis, Gandhi Medical College and Hamidia Hospital, Bhopal, Madhya Pradesh, India

Abstract

Introduction: In the latter part of December 2019, new pneumonia cases have emerged in China and were reported to the World Health Organization that coined the term coronavirus disease (COVID-19). On March 11, 2020 WHO has declared the novel CORONA virus (COVID-19) outbreak a global pandemic. The first of the few cases was confirmed in our country on January 27, 2020 in Kerala. The diagnosis of COVID-19 requires specific viral genetic material in the specimen collected from nose, pharynx, and respiratory secretions which were detected by reverse transcription-polymerase chain reaction (RT-PCR) method. However, its variable sensitivity threatens its validity. High-resolution computed tomography (HRCT) chest plays an essential role in the evaluation of COVID-19 even sometimes before the clinical symptoms become apparent and also when other diagnostic methods are inconclusive.

Purpose: The aim of our study was to characterize the various HRCT features in the patient with COVID-19 infection retrospectively and to facilitate its early identification and isolation. We also aimed to evaluate the changes in the HRCT pattern on short-term follow-up including changes in the CT severity score, mean attenuation value, and cross section area of involvement of the largest patch.

Materials and Methods: It was a hospital-based retrospective observational study in 31 COVID positive patients (by genomic analysis through RT-PCR) at tertiary care center in Gandhi Medical College, Bhopal and Hamidia Hospital from July to December 2020. Only those patients who had undergone at least one follow-up scan 1 week apart were included in the study. HRCT findings were correlated with the initial and follow-up studies.

Results: Among the confirmed COVID positive 31 cases, most of patients were young adults in the fifth and sixth decade of age group with mean age of 47.5 years. There was a male preponderance (77% male and 33% female). In terms of distribution, our study suggested involvement of the right lung predominantly. In the early stage as per initial HRCT scan single or multiple ground-glass infiltration, consolidation, interstitial thickening could be seen, with ground-glass opacity as the predominant finding. As the disease progressed as per follow-up scan the patches of discrete ground-glass opacities were seen coalescing to form a larger patch, severe cases had more consolidation with air bronchogram and fibrosis. Our study also showed the difference in initial and follow-up CT which was of Δ sum area cm² −3.2±12.1 in the cross-sectional area of the largest patch and Δ HU – 69.4±311 in density.

Conclusion: The results of the study confirmed that HRCT chest is an important tool in COVID-19 infection for the diagnosis and its management with follow-up. The pattern of changes in the progression of disease has been documented in various studies and our study describes the same. The role of cross section area of largest patch and density had showed some role along with CT severity scores in the evaluation, progression, and management of the disease, thereby it should be considered while making the radiological assessment of the disease.

Key words: Area, Coronavirus disease, Density, Follow-up, High-resolution computed tomography, Pneumonia

Access this article online

www.ijss-sn.com

Month of Submission : 02-2021
Month of Peer Review : 03-2021
Month of Acceptance : 03-2021
Month of Publishing : 04-2021

INTRODUCTION

In the latter part of December 2019, new pneumonia cases have emerged in Wuhan city of China and were reported to the World Health Organization who coined the term coronavirus disease (COVID-19).[1] This novel strain had respiratory symptoms similar to that of MERS and

Corresponding Author: Satish Kumar Raghuwanshi, Department of Radio diagnosis, Gandhi Medical College and Hamidia Hospital, Bhopal, Madhya Pradesh, India.

SARS-CoV-2.[2] The World Health Organization (WHO) on March 11, 2020 has declared the novel CORONA virus (COVID-19) outbreak a global pandemic.

The first of the few cases was confirmed in our country on January 27, 2020 in Kerala.[3] The diagnosis of COVID-19 requires specific viral genetic material in the specimen collected from nose, pharynx, and respiratory secretions which was detected by reverse transcription-polymerase chain reaction (RT-PCR) method. However, its variable sensitivity threatens its validity.[4]

High-resolution computed tomography (HRCT) chest plays an essential role in the evaluation of COVID-19 even sometimes before the clinical symptoms become apparent also when the other diagnostic methods are inconclusive.[5,6] For every suspect patients, HRCT chest is indispensable for definitive diagnosis and follow-up. There is evidence of prognostic value of HRCT chest which has been documented in the recent studies where a specific score of CT scan could predict the morbidity and mortality of the patients with COVID-19. Various patterns of changes have been mentioned in the previous studies in the HRCT follow-up, ranging from a patch of ground-glass opacity (GGO) to consolidation, crazy paving pattern and fibrosis, its area of involvement, and its mean attenuation value (HU).[7,8]

The purpose of our study was to characterize the various HRCT features in the patient with COVID-19 infection retrospectively and to facilitate its early identification and isolation. We also aimed to evaluate the changes in the HRCT pattern on short-term follow-up including changes in the CT severity score, mean attenuation value, and cross section area of involvement of the largest patch.

MATERIALS AND METHODS

It is a hospital-based retrospective observational study in 31 patients which was done after the approval of the ethical committee; informed consent was waived off as the study involves no potential risk to the patients. Here, we included patients with COVID-19 who had been admitted to the Gandhi Medical College and Hamidia Hospital, Bhopal (Madhya Pradesh) from July to December 2020 and had undergone at least one follow-up scan 1 week apart. The COVID-19 infection was confirmed using RT-PCR test.

The patients with pre-existing lung diseases were excluded from the study such as lung mass or any other infective pathologies or interstitial lung diseases.

The HRCT images were obtained using Hitachi 128 slice CT machine. Patients were scanned in the supine position from the level of the upper thoracic inlet to the inferior level of costophrenic angle with the following parameters: A tube voltage of 120 kVp and automated tube current modulation of 196 mAs, and slice thickness reconstruction of 0.625–1.25 mm. All patients underwent initial CT on an average of 4 days, range 1–11 days after the onset of symptoms the mean interval from the initial to follow-up examination was about 7 days ranging from 5 to 13 days.

All the CT images were reviewed by the radiologists through OSIRIX viewer. HRCT was reviewed at the window width/level of 1000–1500 HU and −500–−650 HU, respectively, for the lung parenchyma.

For each 31 patients, the initial and follow-up CT images were evaluated for the following.

1. GGO, consolidation, inter lobular septal thickening, crazy paving, and fibrous stripes.[9-11]
2. Severity of opacification (CT severity score)
3. Any other manifestations such as pleural effusion.

Segments of bilateral lung were assessed for the involvement and the lesions were graded as 0, 1, and 2 (0-none, 1–<50%, 2–>50%) with a total sum score of 40 for the severity of opacification.[12]

Changes in the score between initial and follow-up scan were calculated to qualify the changes of opacification over time. The largest cross section area and its attenuation (HU value) of the most obvious largest patch of the lungs on the initial CT were delineated and followed up.

RESULTS

In our study of 31 COVID-19 positive patients, the mean age group of the patients was 47.5±13.8 years, with maximum number of patients from the 5th decade with male predominance (24/31, 77.4%) [Table 1].

Initial HRCT Findings

The data of the initial and follow-up HRCT chest imaging findings are listed in the table.

In our study of 31 cases of covid-19, in initial HRCT, right lung was predominantly involved than the left lung (21 and 10 cases, respectively) and the superior segment of right lower lobe (11/31, 35.5%) was the most vulnerable bronchopulmonary segment involved followed by posterior basal segment of right lower lobe (4/31, 12.9%).

The initial HRCT showed single or multiple patches of GGO as a predominant finding (21/31, 67.7%) and in 29% of cases consolidation was the predominant finding, pleural effusion (2/31, 6.5%) was also seen in Table 2.

In the initial HRCT, the CT severity score ranged from 2.5% to 55% of lung involvement with mean 21.61±17.39, the average area of largest lesion in cross section was 8.65±11.7 cm², and the mean density of that lesion was −481±223.6 HU, respectively.

Changes in Follow-up CT

Most of the cases exhibited a progressive process according to HRCT during the study time window. In the follow-up HRCT, most of the single GGO patch progressed to multiple GGO patches, also had more cases of consolidation, crazy paving pattern, inter lobular septal thickening, pleural effusion, and fibrosis.

The CT severity score in follow-up cases ranged from 0% to 72.5% of the lung involvement with the mean score of 25.33±18.93. The difference between initial and followup CT severity score was (Δ *score* 7±24). In follow up scans the average area of largest lesion in the cross section was 6.94±9.84 cm² and the mean density of that lesion was −445.03±256 HU. The CT severity score and density of the largest lesion in the initial CT were less than follow-up ΔHU −69.4±311

However, cross-sectional areas of the largest patch in follow-up CT cases were smaller compared to the initial CT findings (Δ sum area cm² −3.2±12.1) [Table 3].

Table 1: Demographic characteristics

Age (years)	
<40	10 (32.2%)
40–50	4 (12.9%)
51–60	11 (35.4%)
>60	6 (19.3%)
Sex	
Male	24 (77.4%)
Female	7 (22.6%)

Table 2: Comparison of initial and follow-up HRCT findings

Characteristics	Initial HRCT	Follow-up HRCT
Both absent	2	1
Only GGO present	15	12
GGO and consolidation both present	12	15
Only consolidation	2	3
Frequency of lobe involvement		
Right upper lobe	1	1
Right middle lobe	4	4
Right lower lobe	16	16
Left upper lobe	2	2
Left lower lobe	8	8
CT severity score	21.61±17.39	25.33±18.93
Cm² of max lesion in cross section	8.65±11.7	6.94±9.84
Density (HU) of max lesion in cross section	-481±223.6	-445.03±256
GGO	22 (70.9%)	20 (64.5%)
Consolidation	9 (29%)	11 (35.4%)
Fibrosis	1 (3.2%)	5 (16.1%)
Crazy paving	3 (9.6%)	10 (32.2%)
Pleural effusion	1 (3.2%)	4 (12.9%)
CT severity index		
Mild	21	18
Moderate	8	9
Severe	2	3

GGO: Ground-glass opacity, HRCT: High-resolution computed tomography

DISCUSSION

COVID-19 infection is a newly described viral infection leading to the current pandemic, along with the symptoms lab investigations such as RT PCR, rapid diagnostic kit, and imaging investigations emerged to be a valuable tool to diagnose, evaluate, and follow-up the disease. Various patterns on HRCT have been described by multiple studies worldwide.

Our study was aimed to establish the facts and to observe the changes in COVID-19 positive patients over a week span gap by a follow-up scan.

In our study, the cases were seen predominantly in the fifth decade of life with male preponderance which was seen in 77% of the total cases which were similar to other studies.[13-15]

In terms of distribution, our study showed involvement of the right lung predominantly and among the bronchopulmonary segments the superior segment of right lower lobe was the most commonly involved, these findings were similar with the study by Li *et al.*,[13] Long *et al.*,[16] and Vancheri *et al.*[14]

In our study, the pulmonary lesions were most commonly in the subpleural, peribronchovascular area, or diffusely distributed. In the early stage, as per initial CT scan single or multiple ground-glass infiltration, consolidation, interstitial thickening could be seen, with GGO as the predominant lesion.[13-15,17,18]

As the disease progressed as per follow-up scan, the patches of discrete ground-glass opacities were seen coalescing to form a larger patch, severe cases had more consolidation and fibrosis. The diffuse lesion described as white lung was seen in the most severely affected patients; these findings were similar to the studies by Zheng *et al.*,[18] Li *et al.*,[13] and

Table 3: Changes in the follow-up high-resolution computed tomography over a mean of 7 days

Δscore%	7.08±24
Δcm² of max lesion in cross section	−3.25+12.1
ΔHU of max lesion in cross section	69.4+311

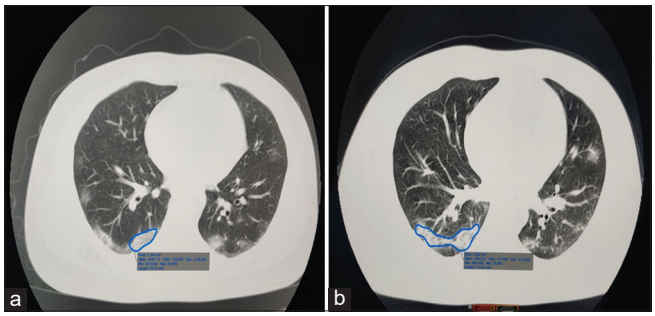

Figure 1: Initial (a) and follow-up (b) high-resolution computed tomography axial images of same patient; showing increase in the cross-sectional area of largest patch of ground-glass opacity and consolidation along with its density (HU)

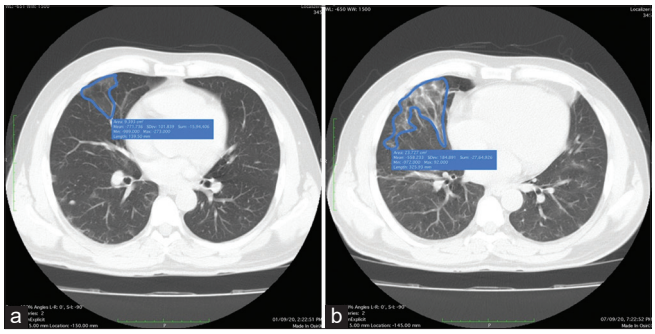

Figure 2: Initial (a) and follow-up (b) high-resolution computed tomography axial images of middle aged male patient; showing progressive change from a patch of ground-glass opacity to consolidation with increase in the cross-sectional area along with its density (HU)

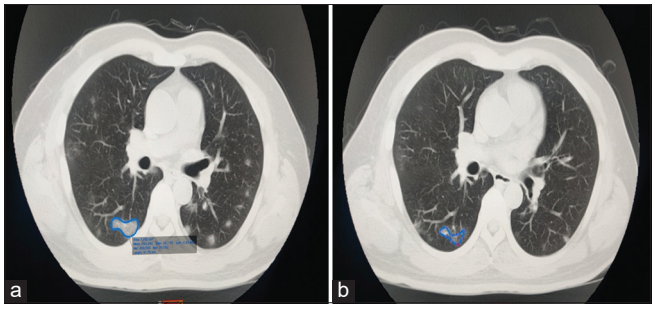

Figure 3: Initial (a) and follow-up (b) high-resolution computed tomography axial images of a male patient; showing resolving changes in the form of decrease in the cross-sectional area and its attenuation (HU), however, the computed tomography severity score in this patient was same

Barbosa *et al*.[15] Fibrous stripes, crazy paving could also be seen in our study in the follow-up scans.

Various previous studies suggested the role of CT severity scores in the treatment protocol, its progression, recovery, and prognosis; our study suggested the same.[19-21]

The sum of opacification (severity score) was positively correlated with days of illness onset to initial CT; in our study, the mean score in the initial scan was 21.61±17.39, while follow-up scan suggested increase in the score of severity by the difference of about Δ *score* 7±24%, which was again consistent with the studies done by Xiong *et al*.[19] and Jiang *et al*.[20]

Along with the CT severity scores, the role of the cross-sectional area of the largest patch and its mean density in the Hounsfield unit has also been described which has been found useful in assessment of the treatment, improvement, progression, and prognosis of the disease.[7,18,22] Our study showed the difference in initial follow-up CT which was of Δ sum area cm² −3.2±12.1 in the cross-sectional area of the largest patch and Δ HU −69.4±311 in density. Similar findings were reported by Xiong *et al*.[19] and Jiang *et al*. [Figures 1-3].[20]

CONCLUSION

The results of the study confirmed that HRCT chest is an important tool in COVID-19 infection for the diagnosis, its management, and follow-up. The pattern of changes in the progression of disease has been documented and our study describes the same. The role of the cross section area of largest patch and density had shown some role along with CT severity scores in the evaluation, progression, and management of the disease; it should be considered while making the radiological assessment of the disease.

Our study has some limitations, major being the sample size, in which we included only the hospitalized patients with follow-up sheet examination the possible selection bias, should be noted and further study of a larger cohort is required. Second, the quantitative and semi quantitative methods for measuring the pulmonary lesions may have certain subjectivity. Third, the susceptibility of COVID-19 was considered (initially and incorrectly) to be very low among infants, children, and adolescents, so we did not retrospectively study these groups. Fourth, CT imaging was not possible in severely or critically ill patients. More effort should be made to identify the clinical and imaging features in these groups in future studies.

REFERENCES

1. World Health Organization. Coronavirus Disease (COVID-2019) Situation Reports. Geneva: World Health Organization; 2020.
2. Chung M, Bernheim A, Mei X, Zhang N, Huang M, Zeng X, *et al*. CT imaging features of 2019 novel coronavirus (2019-nCoV). Radiology 2020;295:202-7.
3. Andrews MA, Areekal B, Rajesh KR, Krishnan J, Suryakala R, Krishnan B, *et al*. First confirmed case of COVID-19 infection in India: A case report. Indian J Med Res 2020;151:490-2.
4. Wang W, Xu Y, Gao R, Lu R, Han K, Wu G, *et al*. Detection of SARS-CoV-2 in different types of clinical specimens. JAMA 2020;323:1843-4.
5. Pan Y, Guan H, Zhou S, Wang Y, Li Q, Zhu T, *et al*. Initial CT findings

and temporal changes in patients with the novel coronavirus pneumonia (2019-nCoV): A study of 63 patients in Wuhan, China. Eur Radiol 2020;30: 3306-9.
6. World Health Organization. Clinical Management of Severe Acute Respiratory Infection When Novel Coronavirus (nCoV) Infection is Suspected; 2020. Available from: https://www.who.int/publications-detail/clinical-management-of-severe-acute-respiratory-infection-when-novel-coronavirus-(ncov)-infection-is-suspected. [Last accessed 2020 Mar 15].
7. Pan F, Ye T, Sun P, Gui S, Liang B, Li L, *et al*. Time course of lung changes at chest CT during recovery from coronavirus disease 2019 (COVID-19). Radiology 2020 295:715-21.
8. Bernheim A, Mei X, Huang M, Yang Y, Fayad ZA, Zhang N, *et al*. Chest CT findings in coronavirus disease-19 (COVID-19): Relationship to duration of infection. Radiology 2020;295:200463
9. Adams HJ, Kwee TC, Yakar D. Chest CT imaging signature of coronavirus disease 2019 infection: In pursuit of the scientific evidence. Chest 2020;158:1885-95.
10. Salehi S, Abedi A, Balakrishnan S, Gholamrezanezhad A. Coronavirus disease 2019 (COVID-19): A systematic review of imaging findings in 919 patients. Am J Roentgenol 2020;215:87-93.
11. Simpson S, Kay FU, Abbara S, Bhalla S, Chung JH, Chung M, *et al*. Radiological society of north america expert consensus document on reporting chest CT findings related to COVID-19: Endorsed by the Society of Thoracic Radiology, the American College of Radiology, and RSNA. Radiol Cardiothorac Imaging 2020;2:e200152.
12. Yang R, Li X, Liu H, Zhen Y, Zhang X, Xiong Q, *et al*. Chest CT severity score: An Imaging tool for assessing severe COVID-19. Radiol Cardiothorac Imaging 2020;2:e200047.
13. Li SK, Ng FH, Ma KF, Luk WH, Lee YC, Yung KS. Patterns of COVID-19 on computed tomography imaging. Hong Kong Med J 2020;26:289-93.
14. Vancheri SG, Savietto G, Ballati F, Maggi A, Canino C, Bortolotto C, *et al*. Radiographic findings in 240 patients with COVID-19 pneumonia: Time-dependence after the onset of symptoms. Eur Radiol 2020;30:6161-9.
15. Barbosa CS, Chaves GW, de Oliveira CV, Bachion GH, Chi CK, Cerri GG, *et al*. COVID-19 pneumonia in the emergency department: Correlation of initial chest CT findings with short-term outcome. Emerg Radiol 2020;27:691-9.
16. Long CJ, Fang P, Song TJ, Zhang JC, Yang Q. Imaging features of the initial chest thin-section CT scans from 110 patients after admission with suspected or confirmed diagnosis of COVID-19. BMC Med Imaging 2020;20:64.
17. Song F, Shi N, Shan F, Zhang Z, Shen J, Lu H, *et al*. Emerging 2019 novel coronavirus (2019-nCoV) pneumonia. Radiology 2020;295:210-7.
18. Zheng Q, Lu Y, Lure F, Jaeger S, Lu P. Clinical and radiological features of novel coronavirus pneumonia. J Xray Sci Technol 2020;28:391-404.
19. Xiong Y, Sun D, Liu Y, Fan Y, Zhao L, Li X, *et al*. Clinical and high-resolution CT features of the COVID-19 infection: Comparison of the initial and follow-up changes. Invest Radiol 2020;55:332-9.
20. Jiang Y, Guo D, Li C, Chen T, Li R. High-resolution CT features of the COVID-19 infection in Nanchong City: Initial and follow-up changes among different clinical types. Radiol Infect Dis 2020;7:71-7.
21. Lu X, Gong W, Peng Z, Zeng F, Liu F. High resolution CT imaging dynamic follow-up study of novel coronavirus pneumonia. Front Med (Lausanne) 2020;7:168.
22. Shi H, Han X, Jiang N, Cao Y, Alwalid O, Gu J, *et al*. Radiological findings from 81 patients with COVID-19 pneumonia in Wuhan, China: A descriptive study. Lancet Infect Dis 2020;20:425-34.

How to cite this article: Shah A, Raghuwanshi SK, Kaushal L. High Resolution Ct Features of Covid-19 Pneumonia: Initial and Follow-up Changes. Int J Sci Stud 2021;9(1):72-76.

Source of Support: Nil, **Conflicts of Interest:** None declared.

Print ISSN: 2321-6379
Online ISSN: 2321-595X

Original Article

Cross-sectional Study on Comorbidities in Pulmonary Tuberculosis: Red Flags for Prognosis

Uma Rani[1], Sara Roohen[2], Akber Ali Khan[3], MK Sivasubramaniyam[4], Shabnam Anjum[5], B Arundhati[6]

[1]Assistant Professor, Department of Community Medicine, Osmania Medical College, Hyderabad, Telangana, India, [2]Senior Resident, Department of Community Medicine, Telangana Institute of Medical Sciences, Hyderabad, Telangana, India, [3]MDS, Department of Oral Medicine and Radiology, Helping Hand Foundation, Hyderabad, Telangana, India, [4]Post Graduate Student, Department of Community Medicine, Osmania Medical College, Hyderabad, Telangana, India, [5]Postgraduate Student, Department of Community Medicine, Osmania Medical College, Hyderabad, Telangana, India, [6]Senior Resident, Department of Community Medicine, Telangana Institute of Medical Sciences, Hyderabad, Telangana, India

Abstract

Context: Comorbidity of tuberculosis (TB) with non-communicable diseases (e.g., diabetes mellitus, malnutrition, smoking, and alcohol-related diseases) and other communicable diseases (e.g., human immunodeficiency virus [HIV]/AIDS) is prevalent in regions of the world that are highly endemic for TB, thereby posing as important contributors to the TB burden.

Objective: The aims of the study were as follows: (1) To estimate the prevalence of major comorbidities in pulmonary TB patients and (2) to assess the sociodemographic profile of pulmonary TB patients.

Settings and Design: A cross-sectional study was conducted in tertiary care facility (TB and Chest Government Hospital, Erragadda) in Hyderabad district.

Materials and Methods: A total of 150 patients were recruited from August to September by consecutive sampling. All patients who met the inclusion criteria for the study were interviewed by a peer-reviewed questionnaire. Height and weight were measured by standardized techniques and body mass index (BMI) calculated.

Statistical Analysis Used: Descriptive analyses were done to estimate the prevalence of various comorbidities and Chi-square test was applied to test the significance with various comorbidities.

Results: The prevalence of diabetes was 20%, as determined by self-report and the HIV prevalence was found to be 10% among TB cases. In total, severe malnourished was 43% (BMI <16) and 31% were found to have a normal BMI (>18.4). Among males, 35% were smokers. Alcohol use was reported by 36% and hazardous alcohol use disorders identification test-C by 21%.

Conclusion: Alcohol abuse and malnutrition in the study population are key drivers of TB in the region. Alcohol treatment programs are few in this area and more may be needed. It is possible that malnutrition is secondary to TB itself accounting for the high prevalence.

Key words: Alcohol abuse, Comorbidities, Diabetes mellitus, Human immunodeficiency virus, Malnutrition, Pulmonary tuberculosis, Smoking

INTRODUCTION

Tuberculosis (TB) is one of the top 10 causes of death worldwide. In 2017, 10 million people fell ill with TB, and 1.6 million died from the disease (including 0.3 million among people with human immunodeficiency virus [HIV]).[1] Globally, the epidemic of TB is on a decline. In 2017, the proportion of people with TB who died from the disease was 16%, down from 23% in 2000, but in developing countries like India, the burden of TB still persists with the global TB report 2017 estimating the incidence of TB in India as approximately 2,800,000 accounting for about a quarter of the world's TB cases.[1] The reasons for the persistence of the epidemic in India are mainly the abundance of risk factors and coexistence with other comorbid conditions that on the rise in the country. Levels of unsuspected comorbidity are also high; patients with concurrent communicable or non-communicable diseases (NCDs) are frequently overlooked. People living

Access this article online

IJSS
www.ijss-sn.com

Month of Submission : 02-2021
Month of Peer Review : 03-2021
Month of Acceptance : 03-2021
Month of Publishing : 04-2021

Corresponding Author: Dr. Sara Roohen, Department of Community Medicine, Telangana Institute of Medical Sciences, Hyderabad, Telangana, India.

with chronic communicable diseases such as TB and HIV/AIDS are most likely to develop comorbidity with NCDs (diabetes mellitus [DM], malnutrition, smoking, and alcohol-related diseases).[2] Moreover, coexisting communicable and NCDs augment the risk or effect of the other. Active TB disease is linked with the breakdown in immune surveillance. This explicates the strong association between active TB disease and other communicable diseases or NCDs that exercise a toll on the immune system.[3] Common TB-NCD comorbidities include DM, smoking, alcohol use disorders, chronic lung diseases, cancer, and depression.[2,4,5] It is, therefore, important to identify these comorbidities in people diagnosed with TB, especially in a high burden country like India to ensure early diagnosis and improve comanagement. The aim of this study is to identify the prevalence of these comorbidities in relation to the local epidemiology and subsequently providing opportunities to investigate commonalities and potential synergies in prevention and control.[2]

MATERIALS AND METHODS

Sample and Procedure

A cross-sectional study was conducted in the tertiary care facility (Government Chest and TB Hospital, Erragadda) of Hyderabad district, which is the main referral center for TB patients in the district. In a cross-sectional survey, new TB patients were interviewed, and medical records assessed in consecutive sampling within 2 months of anti-TB treatment. Patients were recruited from the DOTS clinic of the facility. Written informed consent was obtained from all individuals meeting the study inclusion criteria.

Inclusion Criteria Include

1. Newly diagnosed pulmonary TB
2. Having taken at least 2 months of anti-TB medication
3. Age group of 15–45 years.

Exclusion Criteria Include

1. Patients with extra-pulmonary TB
2. Those who did not consent and were in the age group of <15 and >45 years of age.

Study Procedures

The sample size was calculated to be 150 from the formula $4pq/l^2$, taking an absolute error of 5% and considering the prevalence of HIV comorbidity which was lowest among all the studied comorbidities (6%) so that the sample size was adequate for all the comorbidities studied.

Consecutive sampling was followed and patients were recruited from the OPD of the DOTS clinic, patients were interviewed consecutively, and a maximum of 20 samples was taken in a day. The study was conducted over a period of 2 months from August to September.

Measures

Diabetes was defined as random blood sugar >200 mg/dL or self-report; severe malnutrition was defined as body mass index (BMI) <16 kg/m^2 and malnutrition as BMI ≤18.5 kg/m^2. Hazardous alcohol use was defined as per alcohol use disorders identification test-C (AUDIT-C).

On enrollment, all patients were interviewed by a peer-reviewed questionnaire, the first part included sociodemographic characteristics including age, gender, marital status, religion, and education. In the second part, participants were asked about alcohol use and smoking. Alcohol use was assessed using the AUDIT-C questionnaire[6] (a modified version of AUDIT) which assessed hazardous alcohol use among the alcohol users. HIV status was assessed from the reports. Baseline anthropometric measurements included height and weight measured by standardized techniques and BMI calculated.

Data Analysis

Data were entered and analyzed into Microsoft excel. Data were checked for normality distribution and outliers. Chi-square tests were used to test for differences in proportions. Probability below 0.05 was regarded as statistically significant.

RESULTS

A total of 150 subjects were interviewed for identifying comorbidities associated with TB. The mean age of the study population was 32 years.

Males constituted 59% (n = 89) and females constituted 40.6% (n = 61) of the study. Total 76% (n = 115) were married and 23.3% (n = 35) were unmarried. Occupation wise highest were semiskilled workers 54.6% (n = 82), and least were professional 1.5% (n = 2) [Table 1].

Education wise, the proportion of illiterates was highest at 35% (n = 53) and proportion of middle school education was lowest. In terms of socioeconomic status classified according to BG Prasad's classification 2018, highest was lower middle class 31.3% (n = 47) status followed by upper middle class status 24.6% (n = 37) and least were of lower status 10.6% (n = 16) [Table 1].

Prevalence of Risk Factors Stratified by Patient Characteristics

The distribution of risk factors as classified by patient characteristics is shown in Table 1. Compared with TB patients without risk factors, those with one risk factor (comorbidity) or more were likely to be males, married,

semiskilled by occupation and belonging to the Hindu religion [Table 2].

When stratified by education, illiterates showed the highest prevalence and those belonging to the lower middle class (100%) followed by lower class (68.7%) by socioeconomic status.

Prevalence of Risk Factors

The prevalence of individual comorbidities, of frequency, included. Malnutrition 68% (n = 45) and alcohol abuse 36% (n = 54) in the study population are key drivers of TB in the region, followed by smoking 34.6%, diabetes 20%, and least were HIV 10%. P value came to be significant for alcohol use between males and females and insignificant for HIV positivity. The prevalence of all comorbidities was higher in males compared to females. Diabetes, Smoking and Hazardous alcohol use were exclusively found in males [Figure 1].

When classified according to BMI, overall 68% has malnourishment with a BMI <18.4, of these 64 (43.3%) had a BMI <16 and were severely malnourished followed by 23 (15.3%) with a BMI between 16 and 16.9 and at least 15 (10%) with a BMI of 17–18.4. The majority of the males were malnourished (75%) with BMI <18.4 and females accounting for 25% of those with malnutrition [Figure 2].

Table 1: Sociodemographic characteristics of study population

Variable	*n* (%)	Prevalence of comorbidities, *n* (%)
Sex		
Male	89 (59.4)	65 (73)
Female	61 (40.6	27 (44.2)
Marital status		
Married	115 (76)	74 (64.3)
Unmarried	35 (23.3)	17 (48.5)
Religion		
Hindu	81 (54)	52 (64.1)
Muslim	66 (44)	41 (62.1)
Christian	3 (2)	0 (0)
Occupation		
Professional	2 (1.5)	0 (0)
Skilled	22 (14.6)	12 (54.5)
Semiskilled	82 (54.6)	58 (70.7)
Unskilled	44 (29.3)	29 (65.9)
Education		
Illiterate	53 (35.4)	35 (66)
Primary	20 (13.4)	20 (100)
Middle	15 (10)	7 (46.6)
High	25 (16.6)	19 (25)
Intermediate	37 (24.6)	0 (0)
Socioeconomic status		
Upper	24 (16)	12 (50)
Upper middle	37 (24.6)	12 (32.4)
Middle	26 (17.3)	0 (0)
Lower middle	47 (31.3)	47 (100)
Lower	16 (10.6)	11 (68.7)

Table 2: Genderwise distribution of risk factors

Risk factor	*n* (%) total	Male	Female	*P*-value
Diabetes	30 (20)	30 (100)	0 (0)	–
HIV	15 (10)	11 (73.3)	4 (26.7)	0.09982
BMI (malnourishment≤18.4)	102 (67.5)	76 (75.5)	26 (24.5)	–
Smoking	52 (34.6)	52 (100)	0 (0)	–
Alcohol use	54 (36)	53 (99)	1 (1)	<0.0000001
Hazardous alcohol use (AUDIT-C)	31 (20.6)	31 (100)	0 (0)	–

DISCUSSION

The study population had a majority of males with a percentage of 59% (n = 89), the majority of whom were married 76% (n = 115) and were semiskilled 58% (n = 82) in occupation. When prevalence was assessed according to patient characteristics, compared with TB patients without risk factors, those with one risk factor (comorbidity) or more were likely to be males, married, semiskilled by occupation and belonging to lower middle and lower class. This is similar to a study conducted by Peltzer *et al.*, where the study population was mostly composed of married males and had lower education.[7] The higher prevalence of comorbidity among men in this sample may be because alcohol and tobacco use were included and that the two substance use disorders were much more common in men than women in this study and in the general population.

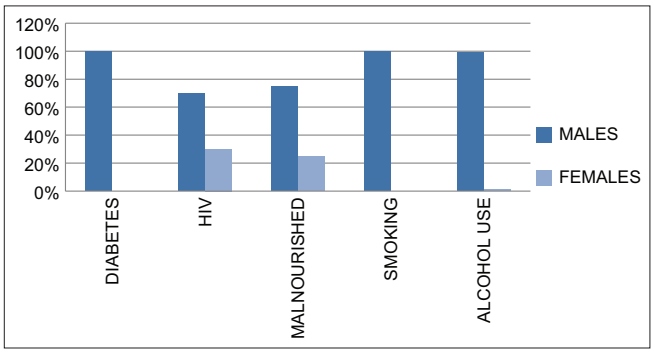

Figure 1: Prevalence of risk factors in sample population

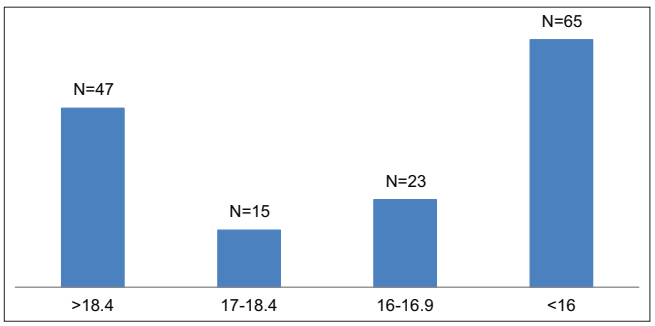

Figure 2: Classification of body mass index

The likelihood of TB risk factors was higher in TB patients with lower education and poorer socioeconomic status (poverty) than those with better socioeconomic status, which is in agreement with the previous studies and reviews.[8,9] The present study showed that the prevalence of diabetes in TB subjects was 20%, all of whom were male. The higher prevalence of DM among men than women might be a cumulative effect of other risk factors which are also in a higher percentage in males. The prevalence of DM in similar studies conducted in the area shows prevalence from 10% to 25%[10,11] and on a higher percentage in males which is in line with the present study. According to Gupta *et al*.,[12] the prevalence of HIV in TB patients was found to be 8.4%. Similarly, according to national statistics, the % of HIV positive among TB cases −6%, in our study, the prevalence has come out as 10%. In this study, undernutrition was the most prevalent comorbidity, present in 68% of men and women with pulmonary TB of which more than two-thirds were moderate to severely underweight according to BMI-based criteria. These results were similar to a study by Bhargava *et al*.[13] and Shetty *et al*.,[14] in which the prevalence of malnourishment was found to be 85% and 72% of these majority being severely malnourished. No women smoked (100% in males) or drank (99% in males), so the results are largely related to men. In a reference study conducted in South India,[15] among males, 55% had smoked and 49% had used alcohol which is similar to our study where the prevalence was 36% and 35%, respectively.

Study Limitations

The study was limited to only one tertiary hospital and the inclusion of more DOTS centers can provide a different profile with the inclusion of more study participants and thereby increasing the sample size and power. As this was a cross-sectional study, causality between the compared variables cannot be concluded. In addition, the study assessed individual comorbidities, the effect of multimorbidities cannot be ignored as disease severity, the specific combination of comorbidities and access to health care may affect each other.

CONCLUSION

Diagnosis and treatment of harmful drinking and alcohol misuse disorders should be part of basic clinical care for people with TB. Control measures for tobacco, alcohol, are an obvious priority for improving public health in the study area. The fact that malnutrition is very common in India, with regard to adults, one-third of both adult men and women were found to have evidence of chronic undernutrition, with a BMI <18.5 kg/m^2 in the National Family Health Survey of 2005–2006 may account for its large contribution to the TB burden.

TB is commonly accompanied by comorbidities such as HIV, DM, smoking, and alcohol or substance abuse which have their own nutritional implications, and these should be fully considered during nutrition screening, assessment, and counseling. Reducing the burden of TB in the study area will depend to a great extent on dealing with the factors that drive the TB burden in these areas. The current end TB strategy needs to be complemented with efforts to address comorbidities and social determinants. In principle, reducing the prevalence of the comorbidities will reduce TB incidence. This may be achieved by tackling these risk factors directly or the social determinants – on the individual, community, national, and international level – that lay behind them. The National TB Program could strengthen collaboration with other public health programs to contribute to the prevention, treatment, and management of HIV, malnutrition, smoking-related conditions, diabetes, and alcohol abuse. Frameworks for such work are already well established for HIV (WHO, 2006) and on the way to smoking.[16]

Several medical conditions are risk factors for TB and for poor TB treatment results, while TB can complicate the disease course of some diseases. It is, therefore, important to identify these comorbidities in people diagnosed with TB to ensure early diagnosis and improve comanagement.

REFERENCES

1. World Health Organization. Global Tuberculosis Report-2018. Geneva: World Health Organization; 2018.
2. Marais BJ, Lönnroth K, Lawn SD, Migliori GB, Mwaba P, Glaziou P, *et al*. Tuberculosis comorbidity with communicable and non-communicable diseases: Integrating health services and control efforts. Lancet Infect Dis 2013;13:436-48.
3. Bates M, Marais BJ, Zumla A. Tuberculosis comorbidity with communicable and noncommunicable diseases. Cold Spring Harb Perspect Med 2015;5:a017889.
4. Sweetland AC, Kritski A, Oquendo MA, Sublette ME, Norcini Pala A, Silva LR, *et al*. Addressing the tuberculosis-depression syndemic to end the tuberculosis epidemic. Int J Tuberc Lung Dis 2017;21:852-61.
5. Rehm J, Samokhvalov AV, Neuman MG, Room R, Parry C, Lönnroth K, *et al*. The association between alcohol use, alcohol use disorders and tuberculosis (TB). A systematic review. BMC Public Health 2009;9:450.
6. Babor T, Higgins-Biddle JC, Saunders JB, Monteiro MG. AUDIT: The Alcohol Use Disorders Identification Test: Guidelines for Use in Primary Health Care. Geneva: World Health Organization; 2001.
7. Peltzer K. Tuberculosis non-communicable disease comorbidity and multimorbidity in public primary care patients in South Africa. Afr J Prim Health Care Fam Med 2018;10:e1-6.
8. Phaswana-Mafuya N, Peltzer K, Chirinda W, Musekiwa A, Kose Z, Hoosain E, *et al*. Self-reported prevalence of chronic non-communicable diseases and associated factors among older adults in South Africa. Glob Health Action 2013;6:20936.
9. Violan C, Foguet-Boreu Q, Flores-Mateo G, Salisbury C, Blom J, Freitag M, *et al*. Prevalence, determinants and patterns of multimorbidity in primary care: A systematic review of observational studies. PLoS One 2014;9:e102149.
10. Rao MS, Shridhar M, Pavani K, Vinayaraj EV, Dass SM. Screening of

tuberculosis in diabetic patients at a tertiary care hospital in Hyderabad. Indian J Microbiol Res 2015;2:220-6.
11. Viswanathan V, Kumpatla S, Aravindalochanan V, Rajan R, Chinnasamy C, Srinivasan R, *et al*. Prevalence of diabetes and pre-diabetes and associated risk factors among tuberculosis patients in India. PLoS One 2012;7:e41367.
12. Gupta S, Shenoy VP, Bairy I, Srinivasa H, Mukhopadhyay C. Diabetes mellitus and HIV as co-morbidities in tuberculosis patients of rural South India. J Infect Public Health 2011;4:140-4.
13. Bhargava A, Chatterjee M, Jain Y, Chatterjee B, Kataria A, Bhargava M, *et al*. Nutritional status of adult patients with pulmonary tuberculosis in rural central India and its association with mortality. PLoS One 2013;8:e77979.
14. Shetty N, Shemko M, Vaz M, D'Souza G. An epidemiological evaluation of risk factors for tuberculosis in South India: A matched case control study. Int J Tuberc Lung Dis 2006;10:80-6.
15. Gajalakshmi V, Peto R. Smoking, drinking and incident tuberculosis in rural India: Population-based case-control study. Int J Epidemiol 2009;38:1018-25.
16. Lönnroth K, Jaramillo E, Williams BG, Dye C, Raviglione M. Drivers of tuberculosis epidemics: The role of risk factors and social determinants. Soc Sci Med 2009;68:2240-6.

How to cite this article: Rani U, Roohen S, Khan AA, Sivasubramaniyam MK, Anjum S, Arundhati B. Cross-sectional Study on Comorbidities in Pulmonary Tuberculosis: Red Flags for Prognosis. Int J Sci Stud 2021;9(1):77-81.

Source of Support: Nil, **Conflicts of Interest:** None declared.

Print ISSN: 2321-6379
Online ISSN: 2321-595X

Original Article

Sturge-Weber Syndrome – Rare Cases with Rare Presentation

Sri Saravanan[1], Asit Roy[2]

[1]Professor, Department of Neurosurgery, Madurai Medical College, Madurai, Tamil Nadu, India, [2]Resident, Department of Neurosurgery, Madurai Medical College, Madurai, Tamil Nadu, India

Abstract

Introduction: In theses case series we present 2 cases of Sturge Weber Syndrome(SWS) Type 1 and Type 3 which is very rare. The classical presentation of SWS is ipsilateral port wine stain with leptomeningeal enhancement with or without seizure which is Type 1. Type 3 which present with leptomeningeal enhancement without port wine stain.the patient with Type 3 has typical radiological features of transparenchymal medullary vessels. Patient may present with seizure and neurological deficit and subclinical stroke due to steal phenomenon.

Objective: The Objective of these case report is to present the rare presentation of Sturge Weber Syndrom (SWS) so that early diagnosis can be made and treatment can be started as early as possible.

Material and Method: These two patient underwent clinical, electrophysiological and radiological investigation and diagnosed as Type 1 and Type 3 Sturge Weber Syndrome(SWS) with typical radiological feature. Both patient are treated symptomatically and followed up for 2 years.

Conclusion: There must be high index of suspicion of diagnosis Sturge Weber Syndrome(SWS) specially Type 3 so that early treatment can be started aiming to improving prolonged neurological outcome.

Key words: Congenital neurocutaneous syndrome, Intracranial leptomeningeal angioma, Lobectomy or hemispherectomy, Sturge-Weber syndrome, The Roach scale

INTRODUCTION

Sturge-Weber syndrome (SWS) was first described by Sturge in 1879 and cerebral involvement was described by Kalischer in 1897.[1] SWS occurs sporadically, with an estimated incidence of 1 in 50,000 live births.[2] SWS is a rare, congenital neurocutaneous syndrome characterized by unilateral facial cutaneous vascular malformation (port-wine stain) in association with ipsilateral leptomeningeal angiomatosis.[3] Angiomas of SWS result due to failure of regression of a vascular plexus around cephalic portion of neural tube which is destined to become facial skin which normally forms at the 6th week of intrauterine life and regresses by the 9th week. Failure of its regression results in residual vascular tissue and has normal endothelial mitotic activity which forms angiomas of leptomeninges, face, and eye.[4,5] These vascular plexus have abnormal blood flow, venous occlusion, thrombosis, and "vascular steal phenomenon" resulting in ischemia, gliosis, atrophy, and calcification of underlying cortical tissue.[6] Sturge-Weber syndrome can be classified into three types using the Roach scale.[7] The most common is type 1, which is the classic manifestation of PWS and intracranial leptomeningeal angioma. Type 1 may or may not have ocular abnormalities, such as glaucoma. Type 2 is characterized by a PWS and an ocular involvement but with no brain abnormalities. Type 3 is characterized by leptomeningeal angiomatosis without cutaneous lesions or ocular abnormalities. This form is usually diagnosed during imaging for epilepsy. The diagnosis and management of SWS requires the combined skills of a radiologist, ophthalmologist, pediatrician, and physiotherapist. Here, we report two cases of SWS, one is type 1 which was presented with seizure managed conservatively with antiepileptic alone and other one was type 3 with right hemiplegia and seizures which were treated with antiepileptic drugs and aspirin. The patient recovered near complete.

Access this article online

www.ijss-sn.com

Month of Submission : 02-2021
Month of Peer Review : 03-2021
Month of Acceptance : 03-2021
Month of Publishing : 04-2021

Corresponding Author: Asit Roy, Department of Neurosurgery, Madurai Medical College, Madurai, Tamil Nadu, India.

MATERIALS AND METHODS

Cases were prospectively studied during the period of 2019–2020. They are admitted in the department of neurosurgery during these periods. All the cases were studied by clinical examination and magnetic resonance imaging (MRI) and electroencephalogram. They were followed up a period of 2 years.

Case 1

A patient, Asvika, a 4-month-old female child, presented by her parents with complaining of seizure multiple episode. On examination, the baby was active, alert, cry good, with no change in voice while crying, tongue was in midline, can follow light, can follow sound. No facial asymmetry can suck and swallow breast milk without difficulty. Anterior fontanelle lax, head circumference 40 cm, weight 10 kg, moves all four limbs without any paucity. On local examination , there is an erythematous area [Figure 1a] over the left side of face involving the left side of forehead, periorbital area, and malar area, that is, ophthalmic and maxillary area. Ophthalmological study was normal. Clinically, we suspect SWS. To confirm and to rule out reason of seizure, radiological investigation was done. MRI brain with contrast shows pial enhancement [Figures 1b and 2a] on contrast over left frontotemporoparietal region with underlying atrophy of cortex. Abnormal transparenchymal vessels connecting cortical veins with subependymal vessels called medullary vessels [Figure 2b]. After radiological evaluation, the patient was diagnosed type 1 SWS. The patient was treated with antiepileptic drug. Seizure was controlled. The patient was discharged and asks for regular follow-up and ophthalmological evaluation.

Case 2

A patient, Master Raja, a 12-year-old male child, brought by his father with complaints of head ache, vomiting, followed by weakness of right side, for 4 days. He also complains of multiple episode of vomiting. Parents also noticed gradual development of slurring of speech with deviation of angle of mouth on the left side. Following admission in our hospital, the patient develops multiple episode of seizure. On examination, the patient was drowsy, disoriented, aphasic, afebrile, pupil bilaterally equally reacting to light, eye movement was full and right hemiplegia. No sensory impairment. Bladder and bowel were normal. There was no neurocutaneous marker [Figure 3c]. Oral cavity was normal. Ophthalmological evaluation was normal. Other systemic examination was normal.

There was a history of seizure disorder following meningoencephalitis at the age of 8 years when MRI brain was done which shows prominent triangle of vessels consisting of prominent components from arteries and vein

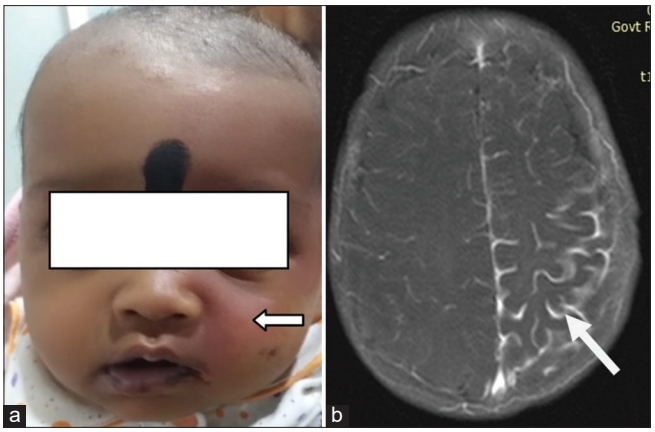

Figure 1: (a) Showing port wine stain on left side of face. (b) Magnetic resonance imaging T1 contrast showing parietooccipital cortical enhencement

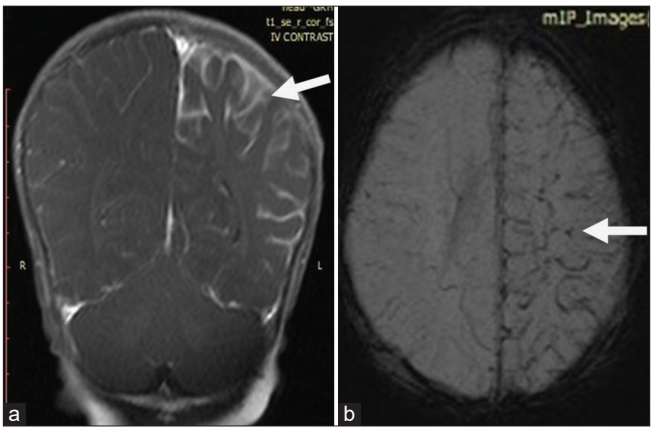

Figure 2: (a) Magnetic resonance imaging brain T1 contrast coronal cut showing pial enhancement in temporoparietal region. (b) Magnetic resonance imaging brain SWI film showing trans parenchymal medullary veins connecting subependymal vein with cortical veins

which are seen in posterior aspect of lateral ventricle and 3rd ventricle suggestive of arteriovenous malformation? Vein of Galen malformation. The patient was investigated for recent signs and symptoms. Routine blood investigation, serum electrolyte, chest X-ray, electrocardiogram, and some radiological imaging study were done. Computed tomography brain shows normal study [Figure 3b], no evidence of infarct or hemorrhage. MRI brain study reveals multiple dilated radially arranged transparenchymal medullary veins [Figure 3a] communicating the cortical veins with the subependymal vessels, abnormal left sided leptomeningeal enhencement with minimal atrophy of left hemicortex [Figure 4a]. Contrast showed no abnormal arteriovenous shunting of blood, no evidence of any acute infarct / hemorrhage. These radiological feature along with clinically absence of port wine stain [Figure 3c] suggestive of type 3 Sturge Weber syndrome. The patient was treated with antiepileptic, aspirin, and physiotherapy. Hemiplegia

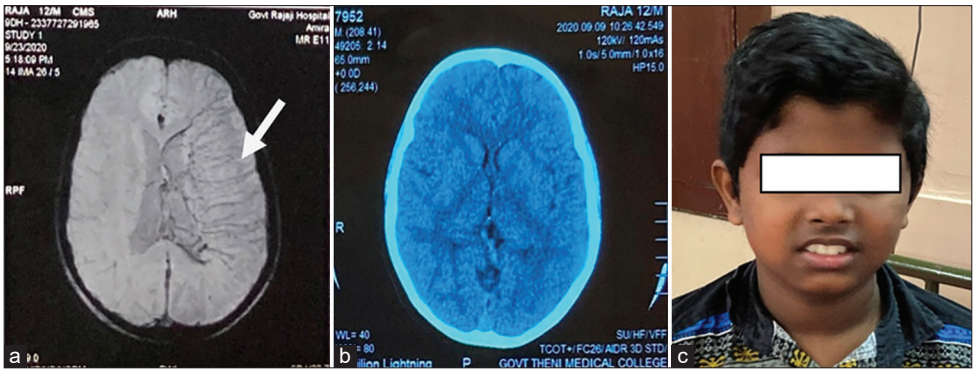

Figure 3: (a) Magnetic resonance imaging brain SWI film showing trans parenchymal medullary veins connecting subependymal vein with cortical veins. (b) Computed tomography brain plain axial cut shows normal study. (c) patient picture without skin manifestation

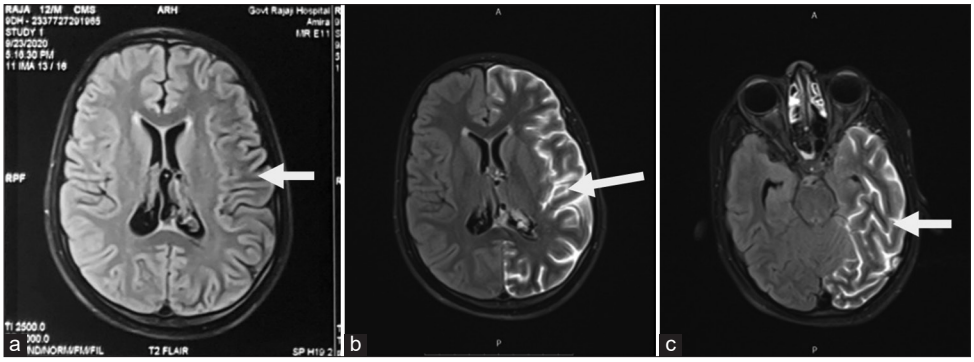

Figure 4: (a) Magnetic resonance imaging T2 FLAIR shows atrophy of cortex. (b and c) Magnetic resonance imaging T2 post contrast FLAIR shows left frontotemporoparietooccipital pial enhancement

gradually turns into hemiparesis and recovered nearly complete [Figure 4b and c].

DISCUSSION

Imaging has an important role in the diagnosis, detection, and follow-up of patients with SWS. Although, historically, the imaging finding that SWS is most known for its "tramline" of progressive calcification seen on X-ray. MRI is now considered a superior imaging modality. MRI specifically T1-weighted MRI with gadolinium contrast and susceptibility-weighted imaging[8] is the best imaging modality to diagnose the intracranial manifestations of SWS and is often cited as the "criterion standard" to diagnose SWS.[9,10] MRI may demonstrate thickened cortex, decreased convolutions, abnormal white matter, and gadolinium enhancement of leptomeningeal angioma[9] as well as enlargement of transmedullary and periventricular veins associated dilation and enhancement of the choroid plexus on the involved side, and dilated deep draining venous vessels.[11,12] Although the exact etiology of SWS remains unclear, the fundamental pathophysiologic abnormality in areas of brain affected by pial angiomatosis is the absence of an adequately functioning superficial cortical venous system.[13] Consequently, blood is rerouted centrally through the medullary veins resulting in venous hypertension and stagnation.[14] Type 1 SWS is common out of these three subtypes which has classical presentation of port-wine stain with radiological pial enhancement with or without ocular involvement. Type III SWS is the rarest subtype and it is difficult to diagnose as it does not involve skin abnormalities. Making the diagnosis of type 3 SWS, preferably before the onset of neurologic sequelae, may have an important impact on patient management. Aggressive treatment of epilepsy is advocated[15] with some studies even suggesting neurodevelopmental benefits with prophylactic anticonvulsants before the onset of seizures.[16] Prophylactic daily aspirin[17] and early surgery in the form of lobectomy or hemispherectomy, corpus callosotomy, and vagal nerve stimulation for the neurological manifestations[18,19] when seizures are not controlled by medical treatment may also be of benefit.[15] SWS has a spectrum of clinical and imaging findings, and it is important to recognize those patients at the fringes of the spectrum who may benefit from therapies and monitoring applied in more conventional cases. In our case, we got type 1 and type 3 variety which is very rare

and responds to medical therapy and discharged and the patients were asked for regular follow-up.

CONCLUSION

Though there are variety is exist early Sturge Weber Syndrome is a rare disorder, among the three types Type 3 is very rare that too with rare presentation and diagnosis is sometimes difficult. So high index of suspicion is necessary to diagnose Sturge Weber syndrome specially type 3 so that treatment can be started as early as possible aiming at improving prolonged neurological outcome.

REFERENCES

1. Berg BO. Neurocutaneous syndromes: Phakomatoses and allied conditions. In: Swaiman KF, Ashwal S, editors. Pediatric Neurology Principles and Practice. St. Louis: Mosby Inc. Co.; 1999. p. 530-50.
2. Thomas-Sohl KA, Vaslow DF, Maria BL. Sturge-Weber syndrome: A review. Pediatr Neurol 2004;30:303-10.
3. Neto FX, Junior MA, Ximenes LS, Jacob CC, Junior AG, Palheta CP, *et al*. Clinical features of Sturge-Weber syndrome. Arq Int Otorrinolaringol 2008;12:565-70.
4. Parsa CF. Focal venous hypertension as a pathophysiologic mechanism for tissue hypertrophy, port-wine stains, the Sturge-Weber syndrome, and related disorders: Proof of concept with novel hypothesis for underlying etiological cause (an American ophthalmological society thesis). Trans Am Ophthalmol Soc 2013;111:180-215.
5. Mulliken JB, Glowacki J. Hemangiomas and vascular malformations in infants and children: A classification based on endothelial characteristics. Plast Reconstr Surg 1982;69:412-22.
6. Takeoka M, Riviello JJ. Sturge Weber Syndrome; 2017.
7. Roach ES. Neurocutaneous syndromes. Pediatr Clin North Am 1992;39:591-620.
8. Sudarsanam A, Ardern-Holmes SL. Sturge-Weber syndrome: From the past to the present. Eur J Paediatr Neurol 2014;18:257-66.
9. Sanghvi J, Mehta S, Mulye S. Paroxysmal vascular events in Sturge-Weber syndrome: Role of aspirin. J Pediatr Neurosci 2014;9:39-41.
10. Nema N, Jain J, Porwal V. A rare presentation of bilateral Sturge-Weber syndrome. Oman J Ophthalmol 2014;7:46-8.
11. Aylett SE, Neville BG, Cross JH, Boyd S, Chong WK, Kirkham FJ. Sturge-Weber syndrome: Cerebral haemodynamics during seizure activity. Dev Med Child Neurol 1999;41:480-5.
12. Hu J, Yu Y, Juhasz C, Kou Z, Xuan Y, Latif Z, *et al*. MR susceptibility weighted imaging (SWI) complements conventional contrast enhanced T1 weighted MRI in characterizing brain abnormalities of Sturge-Weber syndrome. J Magn Reson Imaging 2008;28:300-7.
13. Griffiths PD. Sturge-Weber syndrome revisited: The role of neuroradiology. Neuropediatrics 1996;27:284-94.
14. Probst FP. Vascular morphology and angiographic flow patterns in Sturge-Weber angiomatosis: Facts, thoughts and suggestions. Neuroradiology 1980;20:73-8.
15. Comi AM. Sturge-Weber syndrome and epilepsy: An argument for aggressive seizure management in these patients. Expert Rev Neurother 2007;7:951-6.
16. Ville D, Enjolras O, Chiron C, Dulac O. Prophylactic antiepileptic treatment in Sturge-Weber disease. Seizure 2002;11:145-50.
17. Maria BL, Neufeld JA, Rosainz LC, Drane WE, Quisling RG, Ben-David K, *et al*. Central nervous system structure and function in Sturge-Weber syndrome: Evidence of neurologic and radiologic progression. J Child Neurol 1998;13:606-18.
18. Siddeswari R, Manohar S, Abhilash T. Sturge Weber syndrome. J Med Allied Sci 2014;4:88-90.
19. Neville Bwd DD, Allen CM, Bouquot JE. Patologia oral e maxilofacial. Rio de Janeiro Guanabara Koogan, 1998, 87-89 medical record and literature review. Arch Neurol 2005;62:1924-7(s).

How to cite this article: Saravanan S, Roy A. Sturge-Weber Syndrome – Rare Cases with Rare Presentation. Int J Sci Stud 2021;9(1):82-85.

Source of Support: Nil, **Conflicts of Interest:** None declared.

Print ISSN: 2321-6379
Online ISSN: 2321-595X

Original Article

Assessment of Magnitude of Head Injury Due to Motorized Two-wheeler Vehicle Road Traffic Accidents: A Prospective Observational Study

Manish Kaushal[1], Zafar Sheikh[2], Arvind Ghanghoria[3], Vaibhav Gupta[4], Jitendra Yadav[4], Lakhan Parmar[4]

[1]Professor, Department of General Surgery, Mahatma Gandhi Memorial Medical College and Maharaja Yeshwantrao Hospital, Indore, Madhya Pradesh, India, [2]Assistant Professor, Department of General Surgery, Mahatma Gandhi Memorial Medical College and Maharaja Yeshwantrao Hospital, Indore, Madhya Pradesh, India, [3]Professor and Head, Department of General Surgery, Mahatma Gandhi Memorial Medical College and Maharaja Yeshwantrao Hospital, Indore, Madhya Pradesh, India, [4]Resident, Department of General Surgery, Mahatma Gandhi Memorial Medical College and Maharaja Yeshwantrao Hospital, Indore, Madhya Pradesh, India

Abstract

Introduction: Globally, injuries and fatalities occur in all forms of transportation but road traffic accidents (RTAs) accounts rank first among all causes. Head injuries are leading causes of death from motorized two wheeler accidents with significant mortality despite optimal use of the standard medical facilities.

Material and Method: This prospective observational study will be conducted in the Department of General Surgery, MGMMC, Indore, to see the magnitude of head injury due to motorized two wheelers RTAs.

Result: A total of 251 cases of head injuries due to motorized two wheeler accidents were reported for the study. Riders constituted (79.3%) and pillion riders (20.7%). Most victims were male (88.88%). Majority of victims were not wearing helmet. Linear fracture of vault (37.8%) was the most common pattern of fracture observed in two wheeler accidents. Intracerebral hemorrhage was also the commonest intracranial hemorrhage.

Conclusion: This study highlights that wearing helmets by the two wheeler riders are very essential in preventing injury and reducing the casualty during a RTA. There is need for increased helmet use among pillion rider in both rural and urban areas.

Key words: Motorized two wheelers, Pillion riders, Riders, Road traffic accidents

INTRODUCTION

India is undergoing major economic and demographic transformation coupled with increasing urbanization and motorization. Motorized two wheelers being inexpensive and very common mode of public transportation in Asian countries, India.[1] The number of mortality and morbidity due to motor vehicle collision is reported to be escalating day by day. According to "Road Accidents in India - 2016–2017" Ministry of road transport and highways transport Research Wing New Delhi. 147,913 persons were killed in road traffic accidents (RTAs) and out of those, 48,746 (33%) were killed while riding on motorized two wheelers.[2] The head and the abdomino-pelvic cavity have been looked on as the most vulnerable region. Mortalities and morbidities are more common in head injuries for both riders and pillion riders of two wheelers. Since the head contains brain, a very important vital organ, trauma to this region challenges the individual because of its anatomical position, size, and movements in all directions.[3] The mechanical forces such as shearing, strains, and biophysical motion that occurs during accidents to the top are liable for patterns of injuries. In spite of improvements in safety measures in vehicles and increased accessibility of emergency measures, head injuries have not declined.[4] Few reliable epidemiological data are available for the study of RTA involving two wheelers with and without wearing helmet. The aim of the present study is to find out the magnitude, patterns, and distribution of head

Access this article online

www.ijss-sn.com

Month of Submission : 02-2021
Month of Peer Review : 03-2021
Month of Acceptance : 03-2021
Month of Publishing : 04-2021

Corresponding Author: Dr. Vaibhav Gupta, Office Room No G-72, Department of General Surgery, Maharaja Yeshwantrao Hospital Main Building, Indore, Madhya Pradesh, India.

injuries in deaths due to RTA with or without helmet and other associated risk factors and to provide a feedback for controlling such injuries.

MATERIALS AND METHODS

A prospective observational study will be conducted to see the magnitude of head injury due to two wheelers RTAs. Informed consent will be taken from all the patients/guardians of the patients included in the study. 251 cases of head injuries due to motorized two wheeler RTA involving riders and pillion riders of two wheelers of both sexes, all age groups, treated and untreated, irrespective of duration of survival was included in the study. Cases of head injuries other than two wheeler RTAs reported at M.Y. Hospital, MGMMC, Indore, are not included in this study. All patients in the study will undergo a detailed history taking, general examination, and investigations. Patient outcome and complications will be recorded. Records will be maintained. Record analysis will be done at the end of study period. Patient's identity will be kept confidential.

OBSERVATIONS AND RESULTS

A total number of 251 cases of RTAs due to motorized two-wheeler were recorded. It was revealed that RTAs were more common in males (88.8%) than females (11.2%) [Table 1]. Most common involved age group were 21–30 years (36.7%), followed by 31–40 years (26.7%). There were 9.2% people who had been the sufferer of RTA in the age below 20 years [Table 2].

It was found that out of 144 riders from rural area majority were not wearing helmet (126 [87.5%]) whereas 18 (12.5%) were wearing helmet. Whereas out of 39 victims who were Pillion rider from rural area, all had not wear helmet (39 [100%]). Out of 55 riders from urban area, majority were not wearing helmet (36 [65.5%]) and 19 (34.5%) were wearing helmet whereas, out of 13 Pillion rider who's accident took place in urban area, majority were not wearing helmet (12 [92.3%]). The distribution was highly significant with $P < 0.001$ [Table 3].

It was found that most common accident mechanism in the present study was collision with either four wheeler (31.47%) or bike slip (27.9%), followed by collision with two wheeler (23.90%). Fall from bike was recorded in 13 (5.2%) people [Table 4].

It was observed that majority of the road accidents took place between 18 and 21 h (29.48%), followed by 15–18 h (19.92%), 21–24 h (17.53%), and 12–15 h (16.33%). There were early morning accidents where 27 (10.76%) took place between 9 and 12 h and seven took place between 6 and 9 h (2.79%) [Table 5].

It was found that out of 199 riders. Majority had (n = 73) linear fracture of vault, followed by linear fracture of vault and base in 42 riders. Whereas out of 52 Pillion rider, majority had linear fracture of vault [Table 6].

It was found that majority of the RTA victims had intracerebral hemorrhage (ICH) (52 [20.7%]) followed by extradural hemorrhage (EDH) (34 [13.4%]), subdural hemorrhage (SDH) (27 [10.8%]), combination of SDH + ICH (21 [8.4%]), and subarachnoid hemorrhage + ICH (11 [4.4%]) [Table 7].

DISCUSSION

Motorized two wheelers are economical and are common modes of public transportation in India and account for nearly three-fourths of the total registered vehicles.

RTAs are the leading cause of death by injury globally and now make up a significant portion of the worldwide burden of ill-health. A large number of people from all walks of life and of all age groups become sufferers from this disaster. According to WHO, approximately 1.35 million people die each year as a result of road traffic crashes.[5]

The aim of present study is to describe the distribution of magnitude of head injury due to motorized two-wheeler RTAs. In the present study, out of 251 people, RTA was more common in the age group of 21–30 years of age group people (36.7%), followed by 31–40 years (26.7%). It was also found that victims of both rural and urban area, majority had age between 21 and 40 years. There were 12.4% people who had been the victim of RTA in the age of 41–50 years. According to gender, most of the males were more commonly involved in RTAs (88.8%), followed by females (11.2%).

Similarly, in the study of Chourasia *et al.*, out of 237 RTAs cases, majority were males (82.5%) than females (17.5%). The maximum number of RTA fatalities was recorded in the age group of 21–30 72 years and the minimum no of RTA cases was noted in elderly above 80 years of age.[6] Bhoi *et al.* in their study recorded that highest number of cases (n = 120) were in the 21–30 years age group, followed by 31–40 age group (n = 68) and 11–20 age group (n = 63). Males were more commonly involved in road traffic injuries (n = 276) than female patients (n = 41).[7] Meyyappan *et al.* also noted that majority of individuals were in the age group of 21–40 years (56%). Among the victims, males were predominant (84.3%) than females (15.7%).[8]

Properly designed helmets might be effective in reducing the severity of head trauma. Only a few cities of India are actually following mandatory helmet law for drivers and pillion riders.[9] In the present study, it was observed that out of 251 two wheeler RTA victims, only 38 among them were wearing helmet and majority were riders (37 [97.4%]). It was found that out of 144 riders from rural area, majority were not wearing helmet (126 [87.5%]) whereas out of 55 rider from urban area, only 19 (34.5%) were wearing helmet. This highlight that people from rural area are lacking the information on the risk associated with not wearing the helmet. Out of 52, only 1 pillion rider from urban area were wearing helmet. In Bhoi *et al.* study, 49.8% of victims had used helmet at the time of accident.[7] In Tripathi *et al.* study, a very low rate (13.4%) of helmet use is reported in 74 two-wheeler riders (drivers: 16.5% and pillion riders: 3.7%) at the time of accident at $P < 0.001$.[10] Another study by Pathak *et al.* in Jaipur found that among motorized two-wheeled vehicles most of the victims (87.2%) were not wearing any protective helmet at the time of incidence.[11] Prasannan *et al.* study majority of the riders were wearing helmet as compared to pillion riders.[12] In Gupta *et al.* study, helmets were used by 301 victims in whom 292 were drivers and 9 pillion riders. Only 32.7% (292 out of 892) drivers were wearing helmet while driving.[13] Yadukul *et al.* in their study where people from rural area have the tendency to not wear helmet and results in maximum road accident related death.[14] Results of these studies were comparable to that of present study.

A large number of road users in India are pedestrians, two-wheeler riders and bicyclists who are known to be vulnerable road users.[15] In the present study, most common accident mechanism was collision with 4-wheeler (31.47%) or bike slip (27.9%), followed by collison with 2-wheeler (23.90%). Fall from bike was recorded in 13 (5.2%) people. In Meyyappan *et al.* study, two-wheeler accidents accounted for 66.4% of the RTAs and 21.6% were due to four-wheeler accidents.[8] According to Chourasia *et al.* study, the maximum number of vehicles involved in the accident was involving the two-wheeler (78.3%), followed by light motor vehicle (15.9%) and heavy motor vehicle (5.7%).[6] While in Singh *et al.* study the highest number of fatalities involved pedestrians (47.6%), followed by two-wheeler occupants (33.1%) and light motor vehicle occupants (10.4%). The pedestrians were most commonly involved probably 73 because children are usually less aware of traffic rules and regulations and try to cross the road while the traffic is moving.[16]

In the present study, majority of the road accidents took place between 18 and 21 h (29.48%), followed by 15–18 h (19.92%), 21–24 h (17.53%), and 12 to 15 h (16.33%). Early morning accidents were 27 (10.76%) took place between 9 and 12 h and seven took place between 6 and 9 h (2.79%). It was found that out of 74 road accidents that took place between 18 and 21 h, for them most common cause of accident was drunk and drive ($n = 36$) and negligent driving ($n = 14$). Out of 49 accidents that took place between 15 and 18 h, majority were due to over speeding ($n = 10$) and drunk and drive ($n = 10$). Out of 45 cases of road accident that took place between 21 and 24 h, majority were due to drunk and drive ($n = 28$) whereas out of 41 road accident that took place between 0 and 3 h, majority were due to over speeding ($n = 12$) and negligent driving ($n = 10$). These 75 findings are similar to many other studies by Singh *et al.* and Biswas *et al.* Singh *et al.* reported that most (40.15%) of the RTA's occurred in the evening (18–12 midnight).[17] Biswas *et al.* and Ghangale *et al.*

Table 1: Distribution of patients according to gender

Gender	Frequency	Percent
Female	28	11.2
Male	223	88.8
Total	251	100.0

Table 2: Distribution of patients according to age

Age group	Frequency	Percent
<20	23	9.2
21–30	92	36.7
31–40	67	26.7
41–50	31	12.4
51–60	19	7.6
61–70	15	6.0
>70	4	1.6
Total	251	100.0

Table 3: Comparing rider and pillion rider with wearing of helmet in rural/urban area

Helmet wearing	Rural		Urban		*P*-value
	Rider	Pillion rider	Rider	Pillion rider	
Yes	18 (12.5)	0 (0)	19 (34.5)	1 (7.7)	<0.001
No	126 (87.5)	39 (100)	36 (65.5)	12 (92.3)	
Total	144 (100)	39 (100)	55 (100)	13 (100)	

Table 4: Distribution of patients according to accident mechanism

Accident mechanism	Frequency	Percent
2-wheeler	60	23.90
3-wheeler	5	1.99
4-wheeler	79	31.47
Pedestrian	18	7.17
Fixed object	6	2.39
Bike slip	70	27.89
Fall from bike	13	5.18
Total	251	100.00

Table 5: Distribution of patients according to time of accident

Time of accident (24 h)	No of patients	Percentage
9:00–12:00	27	10.76
12:00–15:00	41	16.33
15:00–18:00	50	19.92
18:00–21:00	74	29.48
21:00–24:00	44	17.53
00:00–3:00	7	2.79
3:00–6:00	1	0.40
6:00–9:00	7	2.79
Total	251	100

Table 6: Relationship between injury to skull and rider and pillion rider

Injury to skull	Role of victim		Total
	Pillion rider	Rider	
Comminuted fracture of base	0	1	1
Comminuted fracture of vault	1	19	20
Comminuted fracture of base and vault	4	21	25
Linear fracture of base	5	7	12
Linear fracture of vault	22	73	95
Linear fracture of base and vault	8	42	50
No fracture	12	36	48
Grand total	52	199	251

noted that peak incidence of RTA found between 18 PM and 12 PM Midnight.[18] However, contrast to the observations made by Chourasia *et al.*, where maximum numbers of RTA cases (43.7%) were reported to occur between 12 PM and 6 PM, followed by the period of 6 PM to 12 midnight (29.6%, $n = 78$). This is due to the fact that around this time many office goers in this city which is an IT hub begin their home journey. These findings are similar to many other studies.[6] Prasannan *et al.* in 2015 were majority of the road accident took place in night time where there is a less visibility.[12]

Head injuries are extremely common among the RTA victims. Craniocerebral injuries are the predominant and fatal injuries among the motor cyclists accounting for 80% of deaths. In adults, cranium varies in thickness and varies from place to place. Most common site of fracture is temporo-parietal region. In RTA, force is transmitted to a wider area and when sufficient to exceed the elasticity of the skull, fractures may commence from the site of impact or from the area remote to the site of impact, or commencing at a distance and run back to the site of impact. A heavy impact on the skull, fracture the vault of the skull running into the base of the skull usually the floor of the Middle Cranial Fossa, separating the floor into halves termed hinge fracture also termed as Motor Cyclists fracture.

The present study shows the relationship between injury to skull and rider and pillion rider. It was found that out of

Table 7: Distribution of patients according to ICH

ICH	Frequency	Percent
EDH	34	13.5
EDH+Pneumocephalus	4	1.6
EDH+SDH+ICH	4	1.6
EDH+ICH	10	4.0
EDH+SAH	1	0.4
EDH+SAH+ICH	3	1.2
EDH+SAH+SDH	2	0.8
EDH+SDH	3	1.2
EDH+SDH+SAH+ICH+IVH	1	0.4
ICH	52	20.7
ICH+IVH	2	0.8
ICH+Pnuemocephalus	4	1.6
ICH+SAH	3	1.2
ICH+SDH	1	0.4
IVH+SDH	1	0.4
No document available	2	0.8
Pneumocephalus	8	3.2
SAH	6	2.4
SAH+SDH	6	2.4
SAH+ICH+Pnuemocephalus	1	0.4
SAH+SDH+ICH	2	0.8
SAH+ICH	11	4.4
SAH+ICH+IVH	2	0.8
SAH+IVH	1	0.4
SDH	27	10.8
SDH+Pneumocephalus	5	2.0
SDH+ICH+Pneumocephalus	2	0.8
SDH+ICH	21	8.4
SDH+ICH+IVH	4	1.6
SDH+SAH+EDH+ICH	1	0.4
SDH+SAH+ICH	4	1.6
SDH+SAH+ICH+IVH	2	0.8
Within normal limit (WNL)	21	8.4
Total	251	100.0

EDH: Extradural hemorrhage, SDH: Subdural hemorrhage, ICH: Intracerebral hemorrhage, IVH: Intraventricular hemorrhage, SAH: Subarachnoid hemorrhage

199 riders. Majority had ($n = 73$) linear fracture of vault, followed by linear fracture of vault and base in 42 riders. Whereas out of 52 Pillion riders, majority had linear fracture of vault. Zhao *et al.* in 2011 found the difference in the distribution between the riders and the pillion riders regarding the superficial injuries. For drivers than passengers, the injuries in the hand and perineum region were comparatively in high fraction.[19] Fitzharris *et al.* 2009 reported in their study that fracture of the head and neck region was higher in female pillion riders (18%) and compared to male pillion riders (6.8%).[20] Another study by Prasannan *et al.*, in skull fractures fissure fracture was present in 32.59% of cases. Pillion riders showed more incidence than drivers, may be due to the protection by 81 helmets. Incidence of skull base fissure fracture was almost same in both riders and pillion riders.[12]

In the present study, majority of the RTA victims had ICH 20.7%, followed by EDH 13.4%, SDH 10.8%, combination of SDH and ICH 8.4%, and combination of SDH and ICH 4.4%. In Ravikumar *et al.* study, sub-

dural hemorrhage was the common ICH.[21] In Fonesca *et al*. study, the second peak ICH was subdural/epidural hematomas, hemothorax/pneumothorax, pelvic fractures, and spleen/liver lacerations.[22] The most frequent injury type was contusion (28.3%), followed by ICH (18.9) and subdural hematoma (17.0%).[23]

CONCLUSION

Present study concludes that RTAs were more common in males of younger age group. Most common accident mechanism was collision with either 4-wheeler or bike slip. This study highlights that wearing helmets by the two wheeler riders are very essential for prevention of injuries and reducing the casualty during RTA. There is need for increased helmet use among pillion rider in both rural and urban areas. Majority of the road accidents happened between 18 and 21 h in rural area. Nearly 37.8% victims suffered from linear fracture of vault injury. Over speeding of 2-wheeled vehicles is one very important preventable etiological factor in RTAs. Understanding the pattern, important cause and risk factors for RTA provide very important information for controlling the event.

REFERENCES

1. MOTOR VEHICLE WRITUP-Statistical Year Book, India 2015. Ministry of Statistics and Programme Implementation; 2015. p. 7. Available from: http://www.mospi.nic.in. [Last accessed on 2016 Jul 19].
2. Ministry of Road Transport and Highways, Transport Research Wing, Road Accidents in India; 2017.
3. Mukhopadhyay S, Khan J. Pattern of head injuries due to road traffic injuries involving two-wheelers in the jurisdiction of NRS medical college Morgue, Kolkata. IOSR J Dent Med Sci 2020;19:5-9.
4. Meaney DF, Smith DH. Biomechanics of concussion. Clin Sports Med 2011;30:19-31.
5. World Health Organization, KY Facts; 2020. Available from: https://www.who.int/news-room/factsheets/detail/road-traffic-injuries. [Last accessed on 2020 Aug 26].
6. Chourasia S, Baghel J, Rautji R, Radhakrishna KV, Shivakumar DK. An autopsy study of fatal road traffic accidents (RTA) at medico legal centre of a tertiary health care hospital in South Western Maharashtra: Six year retrospective study. Int J Biomed Adv Res 2019;10:e5152.
7. Bhoi S, Singh A, Sinha TP, Pal R, Galwankar S, Baluja A, *et al*. Magnitude and spectrum of injuries sustained in road traffic accidents among two wheeler riders and correlation with helmet use. J Emerg Trauma Shock 2018;11:160-4.
8. Meyyappan A, Subramani P, Kaliamoorthy S. A comparative data analysis of 1835 road traffic accident victims. Ann Maxillofac Surg 2018;8:214-7.
9. Pruthi N, Chandramouli BA, Sampath MS, Devi BI. Patterns of head injury among drivers and pillion riders of motorised two-wheeled vehicles in Bangalore. Indian J Neurotrauma 2010;7:123-8.
10. Tripathi M, Tewari MK, Mukherjee KK, Mathuriya SN. Profile of patients with head injury among vehicular accidents: An experience from a tertiary care centre of India. Neurol India 2014;62:610-7.
11. Pathak A, Desania NL, Verma R. Profile of road traffic accidents and head injury in Jaipur (Rajasthan). J Indian Acad Forensic Med 2008;30:6-9.
12. Prasannan K, Sheeju PA. A descriptive study of pattern of injuries in driver and pillion rider victims of fatal two wheeler accidents. Asian J Biomed Pharm Sci 2015;5:29-32.
13. Gupta V, Kumar A, Gupta P, Singh SP, Pal Singh SP, Singh V, *et al*. Pattern of two wheeler road traffic accidents in rural setting: A retrospective study. Int Surg J 2016;3:521-5.
14. Yadukul S, Devadass PK, Gururaj G. Role of helmet in preventing head injury among two-wheeler occupants in fatal road traffic injuries. Indian J Forensic Med Toxicol 2016;10:6-10.
15. Peden M, Scurfield R, Sleet D, Mohan D, Hyder AA, Jarawan E, *et al*. World Report on Road Traffic Injury Prevention. Geneva: World Health Organization; 2004.
16. Singh D, Singh SP, Kumaran M, Goel S. Epidemiology of road traffic accident deaths in children in Chandigarh zone of North West India. Egypt J Forensic Sci 2016;6:255-60.
17. Singh A, Bhardwaj A, Pathak R, Ahluwalia SK. An epidemiological study of road traffic accident cases at a tertiary care 99 hospital in rural Haryana. Indian J Community Health 2011;23:20-4.
18. Biswas G, Verma SK, Sharma JJ, Aggarwal NK. Pattern of road traffic accidents in Northeast Delhi. J Forensic Med Toxicol 2003;20:27-9.
19. Zhao H, Chen R, Deng G, Yin Z, Yang G, Liu S, *et al*. Comparison of injuries sustained by drivers and pillion passengers in fatal head-on motorcycle collision accidents. Forensic Sci Int 2011;207:188-92.
20. Fitzharris M, Dandona R, Kumar GA, Dandona L. Crash characteristics and patterns of injury among hospitalized motorised two-wheeled vehicle users in urban India. BMC Public Health 2009;9:11.
21. Ravikumar R, Patterns of head injuries in road traffic accidents involving two wheelers: An autopsy study. J Indian Acad Forensic Med 2013;35:349-52.
22. Fonesca RJ, Marciani RD, Turvey TA. Oral and Maxillofacial Surgery. 2nd ed., Vol. 2. Philadelphia, PA, United States: Saunders, Elsevier; 2009. p. 1.
23. Piantini S, Pierini M, Delogu M, Baldanzini N, Franci A, Mangini M, *et al*. Injury Analysis of Powered Two-Wheeler Versus Other-Vehicle Urban Accidents, IRC-16-102; 2016.

How to cite this article: Kaushal M, Sheikh Z, Ghanghoria A, Gupt V, Yadav J, Parmar L. Assessment of Magnitude of Head Injury Due to Motorized Two-wheeler Vehicle Road Traffic Accidents: A Prospective Observational Study. Int J Sci Stud 2021;9(1):86-90.

Source of Support: Nil, **Conflicts of Interest:** None declared.

Print ISSN: 2321-6379
Online ISSN: 2321-595X

Original Article

A Diagnostic Role of Plasma Lipid Profile in Patients with Head-and-neck Malignancy

Ratnesh Meena[1], Rekha Harshvardhan[2], Mahendra Singh Hada[3], Shubhangi Gupta[4], Prem Singh Jat[5], Sunita Agarwal[6]

[1]Junior Resident, Department of Otorhinolaryngology and Head and Neck Surgery, Swai Man Singh Medical College, Jaipur, Rajasthan, India, [2]Senior Professor, Department of Otorhinolaryngology and Head and Neck Surgery, Swai Man Singh Medical College, Jaipur, Rajasthan, India, [3]Associate Professor, Department of Otorhinolaryngology and Head and Neck Surgery, Swai Man Singh Medical College, Jaipur, Rajasthan, India, [4]Senior Resident, Department of Otorhinolaryngology and Head and Neck Surgery, Swai Man Singh Medical College, Jaipur, Rajasthan, India, [5]Assistant Professor, Department of Otorhinolaryngology and Head and Neck Surgery, Swai Man Singh Medical College, Jaipur, Rajasthan, India, [6]Head, Department of Otorhinolaryngology and Head and Neck Surgery, Swai Man Singh Medical College, Jaipur, Rajasthan, India

Abstract

Introduction: Head-and-neck squamous cell cancer is the sixth leading cancer by incidence worldwide. Head-and-neck cancer accounts for 30–40% of all malignant tumors in India and the most common malignant neoplasm is oral squamous cell carcinoma. Usefulness of variations in blood cholesterol levels in diagnosis and treatment of various diseases including cancers has been studied by several researchers.

Aims and Objectives: The aim of the study was to compare the serum lipid profiles of different histological grades of head-and-neck squamous cell carcinoma with that of clinically normal controls and also among the grades of head-and-neck squamous cell carcinoma with that of clinically normal controls and also among the grades of carcinoma.

Materials and Methods: A total of 160 subjects were studied. They were divided into case group (with cancer) and control group (without cancer). Lipid profile was compared between these groups in terms of mean and standard deviation.

Results and Conclusion: The mean difference in the levels of total cholesterol (TC), high-density lipoprotein (HDL), low-density lipoprotein (LDL), and triglyceride (TG) between the case group and control group was significant in our case study, that is, these lipid parameters were significantly lower in the case group than that of the control group. On receiver operating characteristic curve, TC, HDL, and LDL had shown good inverse relation with cancer versus control group as area under the curve (AUC) was 96%, 89%, and 88%, respectively, whereas TG had fair relation with AUC 70%. The lower plasma lipid status may be a useful indicator for initial changes occurring in neoplastic cells. However, a detailed study of cholesterol carrying lipoprotein transport and the efficiency of the receptor system may help in understanding the underlying mechanisms of regulation of plasma cholesterol concentrations in cancer.

Key words: Grades of tumor differentiation, Head-and-neck cancer, Lipid profile, Squamous cell carcinoma

INTRODUCTION

The annual incidence of head-and-neck cancers worldwide is more than 550,000 cases with around 300,000 deaths each year. About 90% of all head-and-neck cancers are squamous cell carcinomas (HNSCCs). HNSCC is the sixth leading cancer by incidence worldwide.[1,2]

Head-and-neck cancer accounts for 30–40% of all malignant tumors in India and the most common malignant neoplasm is oral squamous cell carcinoma.[3,4]

Most HNSCCs arise in the epithelial lining of the oral cavity, oropharynx, larynx, and hypopharynx.[1] These cancers are strongly associated with certain environmental and lifestyle risk factors such as tobacco and alcohol consumption.[2]

Usefulness of variations in blood cholesterol levels in diagnosis and treatment of various diseases including cancers has been studied by several researchers.[5-8]

Access this article online

www.ijss-sn.com

Month of Submission : 02-2021
Month of Peer Review : 03-2021
Month of Acceptance : 03-2021
Month of Publishing : 04-2021

Corresponding Author: Dr. Shubhangi Gupta, 11 Van Vihar Colony, Dev Nagar, Tonk Road, Jaipur, Rajasthan - 302018, India.

It is believed that tobacco carcinogens induce generation of free radicals and reactive oxygen species responsible for the high rate of oxidation/peroxidation of polyunsaturated fatty acids which affects the cell membrane and are thus involved in carcinogenesis. Because of the lipid peroxidation, there is a greater utilization of lipids for new membrane biogenesis.[9]

Hence, the aim of the study was to compare the serum lipid profiles of different histological grades of head-and-neck squamous cell carcinoma with that of clinically normal controls and also among the grades of head-and-neck squamous cell carcinoma with that of clinically normal controls and also among the grades of carcinoma.

Aims and Objectives

Aim

This study aims to find out plasma lipid profile in head-and-neck malignancy patients.

Objectives

The objectives of the study were as follows:

1. To evaluate the plasma lipid profile including (1) total cholesterol (TC), (2) low-density lipoproteins (LDLs), (3) high-density lipoproteins (HDLs), (4) very LDL (VLDLs), and (5) triglycerides (TGs) in head-and-neck malignancy patients
2. To compare the plasma lipid levels in patients with head-and-neck malignancy and in without malignancy
3. To compare the plasma lipid profile in different histopathological grades of head-and-neck malignancy.

MATERIALS AND METHODS

Study Universe

All patients attending the Department of Otorhinolaryngology and Head and Neck Surgery, Sawai Man Singh Hospital, Jaipur.

Study Place

The present study was conducted on outdoor and indoor patients in the Department of Otorhinolaryngology and Head and Neck Surgery, Sawai Man Singh Hospital, Jaipur.

Study Period

The study period was from July 2019 to September 2020.

Study Design

This was a cross-sectional study.

Type of Study

This was a hospital-based descriptive study.

Methodology

These study subjects were divided into two groups.

Group I

Between July 2019 and September 2020, 80 patients presenting with histopathologically confirmed head-and-neck malignancy in the ENT and head-and-neck cancer department of our hospital, a tertiary care referral, were enrolled in the study.

Group II

Control group comprised age- and sex-matched healthy subjects who had no complaint or history of any major illness in recent past and belonged to the similar socioeconomic group as head-and-neck cancer patients.

Histopathologically, head-and-neck malignancy was divided on the basis of their degree of differentiation:

1. Well differentiated
2. Moderately differentiated
3. Poorly differentiated
4. Undifferentiated.

The pathologist from the Department of Pathology of the Sawai Man Singh Medical College, Jaipur, performed the histopathological grading in head-and-neck cancer.

Outcome variable: Following parameters were noted in the patients:

1. TC
2. HDLs
3. VLDLs
4. LDLs
5. TG.

Outcome Analysis

1. Qualitative data were expressed as rate and proportions while quantitative data were expressed as mean and standard deviation
2. Appropriate statistical test was applied as per data yield
3. $P < 0.05$ was taken as statistically significant
4. Low cutoff value drawn by receiver operating characteristic (ROC) curve.

OBSERVATIONS AND RESULTS

The present study was conducted at the Department of ENT and Head and Neck Surgery, Sawai Man Singh Medical College, Jaipur, from July 2019 to September 2020. The aim of the study was to find out plasma lipid profile in head-and-neck malignancy patients. A total number of patients included in this study were 160, these patients were divided into two groups, 80 patients in the case study group and 80 patients in the control group.

The mean age in all 160 patients irrespective of group was 45.29 years, in the case group was 46.00 years and control

group, it was 44.58 years. The percentage of male and female was 90% and 10% in each group. Hence, in a study population, majority of patients were male. It was observed that the oral cavity (71.25%) was the most common site of malignancy followed by larynx (18.75%) and pharynx (10%) in our study [Table 1].

We observed that maximum of patients in our study had tobacco chewing habit 39 (48.75%) followed by smoking 24 (30%). Five cases were related with both tobacco chewing and smoking. Only 4 cases (5%) with head-and-neck malignancy patients had no habits [Figure 1].

TC level and LDL levels were found significantly lower in head-and-neck malignancy cases who had habit of smoking or chewing tobacco product in comparison to cases with no habit of smoking or chewing tobacco, *P*-value was found statistically significant ($P \leq 0.001$ and $P = 0.004$, respectively) [Table 2].

Most of our study cases presented with well-differentiated squamous cell carcinoma grade of tumor (50%) followed by moderately differentiated squamous cell carcinoma (35%) and only 8 (10%) had poorly differentiated squamous cell carcinoma grade of tumor [Figure 2]. The intergroup evaluation of serum lipid profile levels among various grades of differentiation did not show a significant correlation of serum lipid profile and the degrees of differentiation [Table 3].

In our case study, the mean difference of 80.61 mg/dl in TC level was found which was statistically significant (case group vs. control group – 96.94 ± 25.07 mg/dl vs. 177.55 ± 32.57 mg/dl) [Table 4]. Similarly in HDL, the mean difference of 18.82 mg/dl in the case group versus control group (36.81 ± 9.64 mg/dl vs. 55.63 ± 10.89 mg/dl) [Table 5], the mean difference of 39.94 mg/dl in LDL (55.45 ± 21.41 mg/dl vs. 95.39 ± 26.48 mg/dl) [Table 6], and the mean difference in TG level of 33.28 mg/dl (88.51 ± 21.99 mg/dl vs. 121.79 ± 50.8 mg/dl) [Table 7] were found statistically significant except VLDL with the mean difference of 2.93 mg/dl (21.93 ± 9.64 mg/dl vs. 24.86 ± 11.22 mg/dl) was not statistically significant ($P = 0.078$) [Table 8].

On ROC curve, the maximum area under the curve (AUC) was covered by TC (96%) and the minimum AUC was covered by VLDL (58%) [Table 9 and Graph 1].

Table 1: Distribution according to site of tumor

Site of tumor	*n*	%
Oral cavity	57	71.25
Larynx	15	18.75
Pharynx	8	10
Total	80	100.00

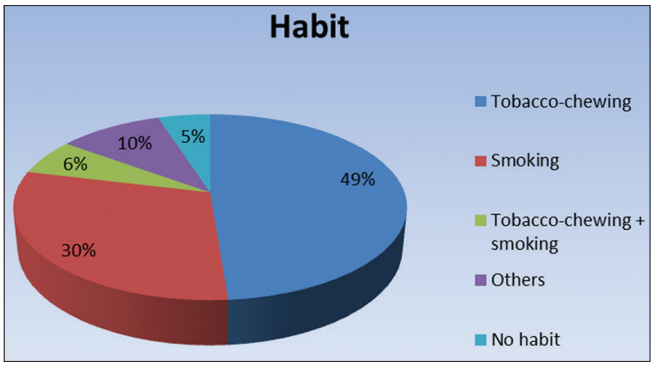

Figure 1: Distribution of study cases according to patients' habits

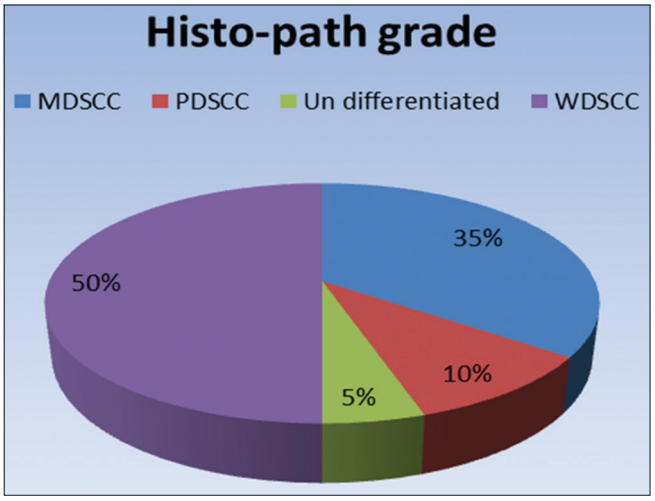

Figure 2: Distribution of cases according to histopathological grade

Low cutoff value for acceptable sensitivity and specificity was calculated and was found for TC – 135 mg/dl (sensitivity 95% and specificity 90%), HDL – 45 mg/dl (sensitivity 83% and specificity 82%), and LDL – 75 mg/dl (sensitivity 82% and specificity 82%) [Table 10].

DISCUSSION

Several authors propose that hypocholesterolemia is a predisposing factor for cancer development. We studied HNSCC cases and compared the serum lipid profile over multiple factors.

Kumar *et al.*[10] in their study found serum TC and HDL to decrease marginally with loss of tumor differentiation, but the finding was not significant statistically. All other parameters, that is, LDL, VLDL, and TG showed no correlation with the grade of tumor differentiation.[10] The results of the present study were also similar with the studies conducted by Patel *et al.*,[11] Lohe *et al.*,[12] and Chawda *et al.*[13] who found no statistically significant correlation of lipid profile with the grade of tumor differentiation.

Table 2: Correlation of serum lipid profile level with tobacco chewing and smoking habit

Lipid profile	T. chewer		Smoke		Chewer+smoking		Others		No habit		*P*-value
	Mean	SD	Mean	SD	Mean	SD	Mean	SD	Mean	SD	
TC	80.58	20.92	104.56	24.61	99.80	14.97	93.38	22.37	124.25	11.03	<0.001
HDL	35.67	7.90	37.67	10.53	38.80	8.76	33.25	9.54	40.00	13.24	0.675
LDL	42.79	15.69	59.90	19.00	66.40	23.22	55.63	15.19	74.00	46.47	0.004
VLDL	23.54	13.29	20.79	6.98	22.00	7.48	21.88	10.79	23.25	9.39	0.870
TG	89.58	19.53	88.97	22.90	87.60	18.19	80.38	21.06	95.00	37.90	0.830

TC: Total cholesterol, HDL: High-density lipoprotein, LDL: Low-density lipoprotein, TG: Triglyceride, VLDL: Very low-density lipoprotein

Table 3: Correlation of serum lipid profile levels among various grades of differentiation

Lipid profile	WDSCC		MDSCC		PDSCC		Undifferentiated		*P*-value
	Mean	SD	Mean	SD	Mean	SD	Mean	SD	
TC	93.58	23.65	102.61	23.48	88.38	26.91	108.00	42.68	0.280
HDL	38.40	10.30	37.11	8.77	29.00	5.88	34.50	9.54	0.083
LDL	55.93	23.74	55.68	19.78	52.25	18.10	55.50	20.82	0.978
VLDL	20.95	7.51	21.50	10.37	25.88	14.63	26.75	12.53	0.428
TG	87.68	21.68	87.07	23.93	94.38	15.85	95.25	26.37	0.778

TC: Total cholesterol, HDL: High-density lipoprotein, LDL: Low-density lipoprotein, TG: Triglyceride, VLDL: Very low-density lipoprotein, WDSCC: Well-differentiated squamous cell carcinoma, MDSCC: Moderately differentiated squamous cell carcinoma, PDSCC: Poorly differentiated squamous cell carcinoma

Table 4: Distribution of subjects according to TC level

		TC					
Group	*n*	Mean	SD	Median	Minimum	Maximum	*P*-value
Case	80	96.94	25.07	98.00	44	170	<0.001
Control	80	177.55	32.57	177.50	97	260	
Total	160	137.24	49.74	132.00	44	260	

TC: Total cholesterol

Table 5: Distribution of subjects according to HDL level

		HDL					
Group	*n*	Mean	SD	Median	Minimum	Maximum	*P*-value
Case	80	36.81	9.64	35.00	17	68	<0.001
Control	80	55.63	10.89	56.50	27	77	
Total	160	46.22	13.93	45.00	17	77	

HDL: High-density lipoprotein

Table 6: Distribution of study subject according to LDL level

		LDL					
Group	*n*	Mean	SD	Median	Minimum	Maximum	*P*-value
Case	80	55.45	21.41	54.00	13	138	<0.001
Control	80	95.39	26.48	95.00	13	167	
Total	160	75.42	31.26	75.00	13	167	

LDL: Low-density lipoprotein

Table 7: Distribution of study subject according to TG level

		TG					
Group	*n*	Mean	SD	Median	Minimum	Maximum	*P*-value
Case	80	88.51	21.99	91.50	43	146	<0.001
Control	80	121.79	50.89	110.00	43	288	
Total	160	105.15	42.49	99.00	43	288	

TG: Triglyceride

In our present study, the majority of the cases of head-and-neck cancer group had habit of tobacco. The mean serum lipid profile level of TC, HDL, LDL, VLDL, and TG, between head-and-neck cancer no habit tobacco and who habit tobacco, was compared, there was significant difference found in mean HDL and LDL levels ($P < 0.001$ and 0.004, respectively).

The mean difference in the levels of TC, HDL, LDL, and TG between the case group and control group was significant in our case study, that is, these lipid parameters were significantly lower in the case group than that of the control group. However, the mean difference in VLDL levels was not statistically significant. Lohe *et al*.[12] also found similar observations of the serum lipid profile that there was significant decrease in TC, HDL, VLDL, and TG in oral cancer group as compared with the control group.

On ROC curve, TC, HDL, and LDL had shown good inverse relation with cancer versus control group as AUC was 96%, 89%, and 88%, respectively, whereas TG had fair relation with AUC 70%.

Our results added to this evidence of an inverse relationship between lower plasma lipid profile and head-and-neck malignancies. This was in accordance with various studies

Table 8: Distribution of study subject according to VLDL level

	VLDL						
Group	*n*	Mean	SD	Median	Minimum	Maximum	*P*-value
Case	80	21.93	9.64	21.00	9	59	0.078
Control	80	24.86	11.22	22.00	9	63	
Total	160	23.39	10.53	21.00	9	63	

VLDL: Very low-density lipoprotein

Table 9: AUC

Test result variable (s)	AUC	Std. error (a)	Asymptotic sig. (b)	Asymptotic 95% confidence interval	
				Lower bound	Upper bound
TC	0.968	0.012	0.000	0.944	0.992
HDL	0.894	0.026	0.000	0.844	0.945
LDL	0.888	0.028	0.000	0.834	0.942
VLDL	0.580	0.045	0.082	0.491	0.668
TG	0.705	0.042	0.000	0.623	0.787

TC: Total cholesterol, HDL: High-density lipoprotein, LDL: Low-density lipoprotein, TG: Triglyceride, VLDL: Very low-density lipoprotein, AUC: Area under the curve

Table 10: Coordinates of the curve

Test result variable (s)	Positive if ≤ (a) (mg/dl)	Sensitivity	1-specificity
TC	135.50	0.950	0.100
HDL	45.50	0.838	0.188
LDL	75.50	0.825	0.188
VLDL	21.50	0.613	0.488
TG	99.50	0.638	0.375

TC: Total cholesterol, HDL: High-density lipoprotein, LDL: Low-density lipoprotein, TG: Triglyceride, VLDL: Very low-density lipoprotein

which had shown an inverse association between blood lipid profile and head-and-neck cancers.[14-16]

There are three main competing hypotheses to explain the inverse association between cholesterol concentrations and the incidence of cancer. First, lower cholesterol values, even before the manifestation or detection of cancer, may be a result of the cancer process.

Second, lower cholesterol values may precede the development of cancer but the association with cancer is secondary, that is, cholesterol serves as a marker for some other causal set of variables.

Third, lower cholesterol values may precede the development of cancer and may be causally associated with the occurrence of some forms of cancer.[17]

The lower plasma lipid status may be a useful indicator for initial changes occurring in neoplastic cells. However, a detailed study of cholesterol carrying lipoprotein transport and the efficiency of the receptor system may help in understanding the underlying mechanisms of regulation

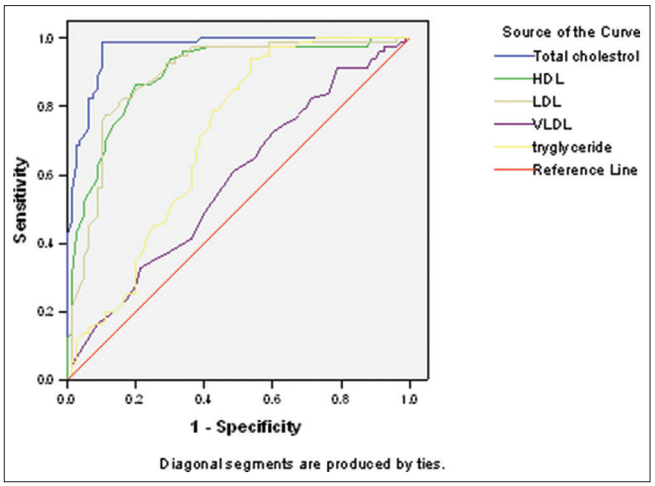

Graph 1: Receiver operating characteristic curve

of plasma cholesterol concentrations in cancer. In our study, we found that altered lipid profile was associated with head-and-neck malignancies.

SUMMARY AND CONCLUSION

Cholesterol and TGs are important lipid constituents of the cell and are essential to carry out several vital physiological functions. In some malignant diseases, blood cholesterol undergoes early and significant changes. Low levels of cholesterol in the proliferating tissues and in blood compartments could be due to the ongoing process of oncogenesis. The results of the present study showed evidence of an inverse relationship between the serum lipid profile and head-and-neck malignancy, suggesting that serum lipid profile may be used as a biochemical indicator for initial changes occurring in the neoplastic cells.

ETHICAL APPROVAL

All procedures performed in studies involving human participants were in accordance with the ethical standards of the institutional and/or national research committee and with the 1964 Helsinki Declaration and its later amendments or comparable ethical standards.

REFERENCES

1. Jemal A, Bray F, Center MM, Ferlay J, Ward E, Forman D. Global cancer statistics. CA Cancer J Clin 2011;61:69-90.
2. Kreimer, A, Clifford G, Boyle P, Franceschi S. Human papillomavirus types in head and neck squamous cell carcinomas worldwide: A systematic review. Cancer Epidemiol Biomarkers Prev 2005;14:467-75.
3. Day TA, Davis BK, Gillespie MB, Joe JK, Kibbey M, Martin-Harris B, *et al*. Oral cancer treatment. Curr Treat Options Oncol 2003;4:27-41.
4. Joshi M, Patil R. Estimation and comparative study of serum total sialic acid levels as tumour markers in oral cancer and precancer. J Cancer Res Ther 2010;6:263-6.

5. Dinkar A, Satoshkar S. Diagnostic aids in early oral cancer detection: A review. J Indian Acad Oral Med Radiol 2006;18:82-9.
6. Feinleib M. Review of the epidemiological evidence for a possible relationship between hypocholesterolemia and cancer. Cancer Res 1983;43 Suppl 5:2503s-7s.
7. Kritz H, Zielinski C, Sinzinger H. Low cholesterol and cancer. J Clin Oncol 1996;14:3043-8.
8. Law MR, Thompson SG. Low serum cholesterol and the risk of cancer: An analysis of the published prospective studies. Cancer Causes Control 1191;2:253-61.
9. Allampallam K, Dutt D, Nair C, Shetty V, Mundle S, Lisak L, *et al*. The clinical and biologic significance of abnormal lipid profiles in patients with myelodysplastic syndromes. J Hematother Stem Cell Res 2000;9:247-55.
10. Kumar P, Augustine J, Urs AB, Arora S, Gupta S, Mohanty VR. Serum lipid profile in oral cancer and leukoplakia: Correlation with tobacco abuse and histological grading. J Cancer Res Ther 2012;8:384-8.
11. Patel PS, Shah MH, Jha FP, Raval GN, Rawal RM, Patel MM, *et al*. Alterations in plasma lipid profile patterns in head and neck cancer and oral precancerous conditions. Indian J Cancer 2004;41:25-31.
12. Lohe VK, Degwekar SS, Bhowate RR, Kadu RP, Dangore SB. Evaluation of correlation of serum lipid profile in patients with oral cancer and pre-cancer and its association with tobacco abuse. J Oral Pathol Med 2010;39:141-8.
13. Chawda JG, Jain SS, Patel HR, Chaduvula N, Patel K. The relationship between serum lipid levels and the risk of oral cancer. Indian J Med Paediatr Oncol 2011;32:32-5.
14. Kumar P, Singh A, Sankhla B, Naraniya A. Alteration in plasma lipid profile in oral submucous fibrosis patients: A case control study. South Asian J Cancer 2013;2:147.
15. Gupta S, Gupta S. Alterations in serum lipid profile patterns in oral cancer and oral precancerous lesions and conditions-a clinical study. Indian J Dent 2011;2:1-7.
16. Khandekar SP, Bagdey PS, Tiwari RR. Oral cancer and some epidemiological factors: A hospital based study. Indian J Community Med 2006;31:157-9.
17. Iype EM, Pandey M, Mathew A, Thomas G, Sebastian P, Nair MK. Squamous cell carcinoma of the tongue among young Indian adults. Neoplasia 2001;3:273-7.

How to cite this article: Meena R, Harshvardhan R, Hada MS, Gupta S, Jat PS, Agarwal S. A Diagnostic Role of Plasma Lipid Profile in Patients with Head-and-neck Malignancy. Int J Sci Stud 2021;9(1):91-96.

Source of Support: Nil, **Conflicts of Interest:** None declared.

Print ISSN: 2321-6379
Online ISSN: 2321-595X

Original Article

Management of Anterior Mandibular Fractures using 2 mm Titanium Locking Plate

Jyoti B[1], Syed Zakaullah[2], Chaitanya Kothare[3], Deepa Pande[4], Nandini Biradar[5], Jerin Jose[6]

[1]Senior Lecturer, Department of Oral and Maxillofacial Surgery, The Oxford Dental College and Hospital, Bengaluru, Karnataka, India, [2]Principal and Professor, Department of Oral and Maxillofacial Surgery, Al-Badar Dental College and Hospital, Kalburga, Karnataka, India, [3]Professor, Department of Oral and Maxillofacial Surgery, Al-Badar Dental College and Hospital, Kalburga, Karnataka, India, [4]Reader, Department of Oral and Maxillofacial Surgery, The Oxford Dental College and Hospital, Bengaluru, Karnataka, India, [5]Reader, Department of Dentistry, Bidar Institute of Medical Sciences, Bidar, Karnataka, India, [6]Post Graduate Student, Department of Oral and Maxillofacial Surgery, The Oxford Dental College and Hospital, Bengaluru, Karnataka, India

Abstract

Background: Mandible is the 2nd most commonly fractured bone of the maxillofacial skeleton because of its vulnerable position. The locking miniplates in comparison with conventional miniplate offer greater stability and easier plate adaptation without hampering the bony perfusion and function as internal fixators.

Aim: The aim of the study was to evaluate the efficacy of 2 mm titanium locking miniplates in the management of anterior mandibular fractures.

Materials and Methods: Twenty patients with mandibular anterior fracture underwent open reduction internal fixation under general anesthesia using a 2 mm titanium locking miniplates. The study evaluated first, post-operative occlusion, and radiographic healing at the 1st, 6th, and 12th weeks and, second, evaluated for any associated clinical complications such as wound dehiscence, infection, and plate/screw fracture. The Chi-square test was used to compare differences between pre-surgical and post-surgical occlusion. Radiographic healing of the fracture site was compared at the 1st week, 6th weeks, and 12th weeks with Student's *t*-test.

Results: Satisfactory occlusion was obtained in all 20 patients (100%) postoperatively. The radiographic assessment at the 12th post-operative week revealed osteogenesis in 10 patients (50%) and bony union in 9 patients (45%), while evidence of resorption was in 1 patient (5%). One (5%) case of wound dehiscence was noted. No cases of infection or plate/screw fracture were observed.

Conclusion: The study has demonstrated that the use of a 2 mm titanium locking plate is effective in the management of anterior mandibular fractures with excellent stability and sound bone healing with early functional rehabilitation.

Key words: Anterior mandibular fracture, Miniplate, Titanium locking plate

INTRODUCTION

The treatment of maxillofacial injuries is well known in this era of increasing automobilization, industrialization, and technology. Management of this maxillofacial trauma is quite challenging in dental and surgical practice. The mandible is the most prominent and only mobile bone of the facial skeleton and shows the highest percentage of all facial fractures.[1-3] The aim of management of the mandibular fracture is to restore an anatomical form and function. Traditional indirect wiring techniques for closed reduction achieve satisfactory occlusion but may not restore anatomical reduction. Techniques for the treatment of mandibular fractures have evolved significantly in the past decade from closed reduction with maxillomandibular fixation (MMF) to open reduction and internal fixation (ORIF).[4] The definitive treatment for mandibular fracture is internal fixation. Champy's method is one of the most acceptable methods for ORIF of mandibular fracture.[5] Miniplate osteosynthesis was first introduced by Michelet in 1973 and further developed by Champy *et al.* in 1975.[6] The conventional miniplates plate system attains its occlusal stability when the heads of the screws

Access this article online

www.ijss-sn.com

Month of Submission : 02-2021
Month of Peer Review : 03-2021
Month of Acceptance : 03-2021
Month of Publishing : 04-2021

Corresponding Author: Dr. Jerin Jose, Department of Oral and Maxillofacial Surgery, The Oxford Dental College and Hospital, Bengaluru, Karnataka, India; Dr. Nandini Biradar, Department of Dentistry, Bidar Institute of Medical Sciences, Bidar, Karnataka, India.

compress the plate to the bone, moreover, it prevents further changes in the position of the fractured fragments. In contrast, the locking plate system attaches the plates to the bone by locking the screws to both the bone and the plate, thus maintains excellent stability without altering the alignment of fractured fragments. In addition, it causes fewer problems with bone vascularization and allows the easier placement of the plates when compared to the conventional miniplates.[7,8] The current study aimed to evaluate the efficacy of 2 mm titanium locking miniplates in the management of anterior mandibular fractures.

MATERIALS AND METHODS

Source of Data

A prospective clinical study was conducted on 20 subjects regardless of the gender of age group between 20 and 50 years, who reported to the outpatient department of oral and maxillofacial surgery. Ethical clearance was obtained from the Institutional Ethical Committee. Written informed consent was also obtained from each subject for the participation of the study.

Inclusion Criteria

The following criteria were included in the study:

- Patients under the ASA-1 category
- Patients within the age group of 20–50 years
- Patients with symphysis and parasymphysis fracture of the mandible that required ORIF
- Patients with displaced or undisplaced fracture of the mandible.

Exclusion Criteria

The following criteria were excluded from the study:

- Patients with comminuted fractures
- Patients with any immunocompromised state or other bone pathology
- Patients with mandibular fractures were ORIF which was contraindicated
- Fractures associated with any infection
- Fractures in completely edentulous patients.

Twenty patients who fulfilled the above criteria were selected for the study and through clinical examination was done on all 20 subjects which included a detailed case history to evaluate age, sex, type of fracture, etiology, and pre-surgical occlusion (deranged or not deranged). Subsequently, these patients were subjected to radiographic investigation for assessing the occlusion using extraoral radiograph (orthopantomograph, posteroanterior view of the mandible) and intraoral radiograph (occlusal view of mandible). All 20 patients with anterior mandibular fracture had undergone ORIF using 2 mm titanium locking plate.

Surgical Procedure

The patients were intubated under general anesthesia. The patient was scrubbed with 2% cetrimide hydrochloride, normal saline, and 5% povidone-iodine and draped as per standard protocol. Irrigation of the oral cavity was done with 0.2% chlorhexidine gluconate solution. The surgical approach for the fractures was through the intraoral incision in 13 patients and in 7 patients through existing laceration. Infiltration was done using 2% lignocaine hydrochloride with 1:80,000 adrenaline. The lip was then retracted, and the marking of incision was made using bonny's blue ink. A curvilinear incision was made perpendicular to the mucosal surface. Care was taken to place the incision out into the lip, leaving at least 1 cm of attached gingiva. Then, mentalis muscle was identified and incised perpendicular to the bone, leaving a flap of muscle attached to the bone for closure. Then, the dissection was carried out subperiosteally to identity the mental neurovascular bundle, approximately midway between the alveolar ridge and inferior border, below the second premolar or slightly anterior. The fracture site was then identified and reduced. Intraoral occlusion was achieved with intermaxillary fixation. The bone plates were adapted and held with a plate holding forceps to make bur holes for the screws. The drill was made using a drill bit of 1.5 mm ×8 mm using a drill guide. The fractured segments were then fixed with two bone plates using 2 mm titanium locking miniplates four holes with gap and a 2 mm ×8 mm length monocortical screws [Figures 1 and 2]. There were no difficulties encountered during locking plate fixation. However, care was taken to avoid damage to the roots of the teeth and the mental nerve. Once adequate fixation was achieved, the area was irrigated with povidone-iodine and normal saline. After achieving adequate hemostasis, the wound was closed in layers with 3–0 Vicryl. An adhesive bandage was applied to the chin to support the mentalis muscle and prevent its drooping. Then, intermaxillary fixation was released and extubation was done uneventfully, and the throat pack was removed. All patients were kept postoperatively on intravenous antibiotics for 5 days and analgesics for 3 days. In addition, 0.2% chlorhexidine gluconate mouthwash was prescribed for 30 days to maintain oral hygiene.

Post-operative Assessment

All 20 patients were evaluated for the stability of the fracture site postoperatively first, by assessing occlusion and, second, compared the pre-operative radiograph of the fracture site with the post-operative radiographic healing at the 1st, 6th week, and 12th weeks. In addition, post-operative complications, including wound dehiscence, infection, and plate/screw fracture, were also assessed. Radiographic healing was evaluated as[9]

- Unchanged: Follow-up radiographic features that showed no change from preoperatively were classified as unchanged
- Resorption: Smoothing of previously irregular fracture lines was classified as resorption

- Osteogenesis: External or internal callus formation visible on radiographs was classified as osteogenesis
- Union: Almost total absence of fracture lines or the presence of continuous anatomical structures around a fracture site which was reduced in width, was classified as union.

Statistical Analysis

Total sample size of the study population was 20. The Chi-square test was used to compare differences between pre-surgical and post-surgical occlusion. Radiographic healing of the fracture site was compared at the 1st week, 6th weeks, and 12th weeks with Student's *t*-test.

RESULTS

The present study aimed to evaluate the efficacy of 2 mm titanium locking miniplates in the management of anterior mandibular fractures. For this purpose, a total of 20 patients with symphysis and parasymphysis fractures of the mandible were selected based on the inclusion and exclusion criteria. Among these, 10 patients were aged between 20 and 30 years, 5 were between 30 and 40 years, and 5 between 40 and 50 years with a mean age of 32.15 years. Furthermore, 4 patients (20%) were female and 16 patients (80%) were men. The etiological factors for mandibular fractures among the 20 subjects were as follows: Road traffic accidents in 16 (80%), assault in 3 (15%), and sports-related injury in 1(5%). Of these 20 patients, 5 had symphysis (5%) fracture, 6 had parasymphysis fracture (30%), and rest 9 patients had parasymphysis fracture (30%) associated with other mandibular fractures, which included 5 condyle fracture (25%), 3 body fracture (15%), and 1 angle fracture (5%). On clinical examination out of 20 patients, 17 patients (85%) had a deranged and 3 (15%) patients had non-deranged occlusion. Furthermore, 11 (55%) presented with a displaced fracture and 9 (45%) presented with an undisplaced fracture. Moreover, these fractures were approached intraorally in 13 (65%) and 7 (35%) and extraoral through an existing laceration. All patients were followed up for post-operative occlusion, radiographic healing at intervals of the 1st week, 6th weeks, and 12th weeks. Furthermore, associated complications were also assessed such as wound dehiscence, plate/screw fractures, and infection.

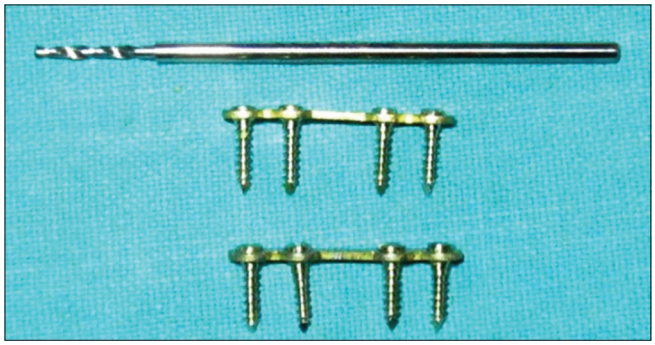

Figure 1 : The image of locking titanium miniplate

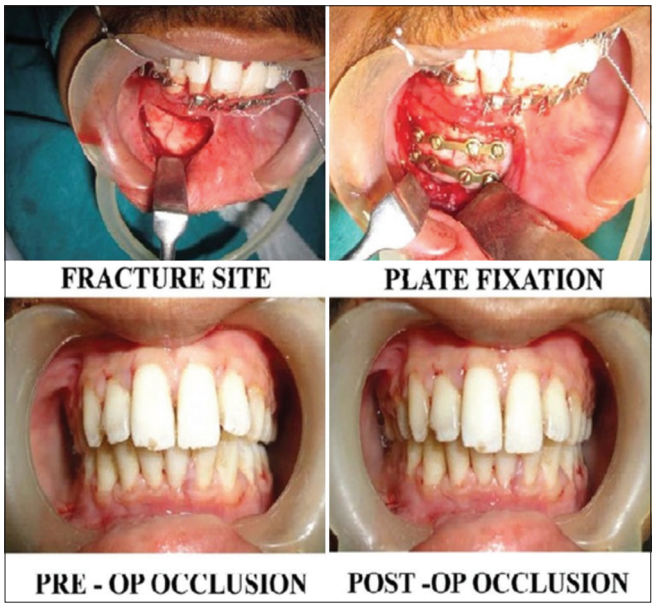

Figure 2: The placement of locking titanium miniplate after open reduction internal fixation

Table 1 demonstrates the distribution of the number of patients according to pre-surgical and post-surgical occlusion using a Chi-square test. The results showed satisfactory post-surgical occlusion in all the 20 patients (100%). Moreover, the Chi-square value was 40, which proved that it was statistically significant [Table 1 and Figure 3].

Table 1: The distribution of number of patients according to pre-surgical and postsurgical occlusion using a Chi-square test

Occlusion	Pre-surgical		Post-surgical
	n (%)		*n* (%)
Deranged	17 (85)		00 (00)
Normal	3 (15)		20 (100)
Chi-square value		40.0	

Table 2: The distribution of number of patients according to radiographic healing

Radiographic healing	1st week	6th week	12th week
	n (%)	*n* (%)	*n* (%)
Unchanged	20 (100)	00 (00)	00 (00)
Resorption	00 (00)	11 (55)	01 (05)
Osteogenesis	00 (00)	09 (45)	10 (50)
Union	00 (00)	00 (00)	09 (45)

Table 2 depicts the distribution of the number of patients according to radiographic healing. Clinically and radiographically, an adequate reduction was obtained in all 20 patients. The radiograph showed an unchanged finding at the 1st week follow-up. However, 11 patients (55%) showed resorption, and 9 patients (45%) showed osteogenesis around the fracture site at the 6th week follow-up. In addition, at the 12th weeks, 10 patients (50%) showed osteogenesis, 9 patients (45%) showed bony union, and only 1 patient (5%) showed resorption around the fracture site [Table 2].

Table 3 demonstrates the comparison of radiographic healing of the fracture site at the 1st, 6th, and 12th week's postoperatively using Student's *t*-test. The *t*-value indicates that there is a significant change in radiographic healing for P = 0.05. Between the 1st week and 6th week, *t*-value was 21.47, between 1st week and 12th week $t = 25.42$, and between the 6th week and 12th week $t = 5.40$. They suggested that there was a statistically significant radiographic healing when compared between the 1st, 6th, and 12th week postoperatively [Table 3 and Figure 4].

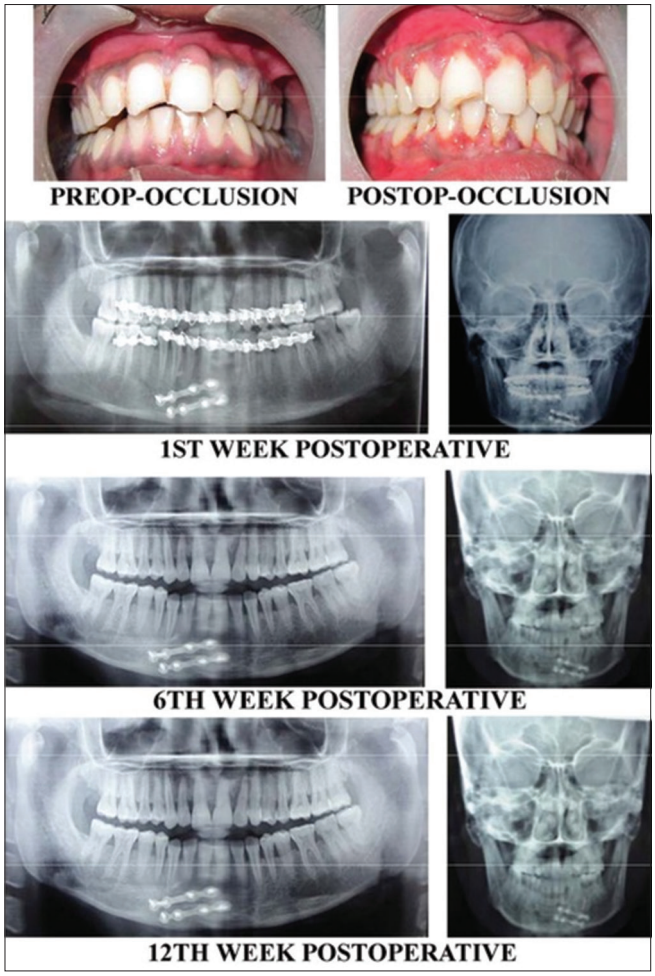

Figure 3: The pre-operative and post-operative occlusion after open reduction internal fixation using locking titanium miniplate

Table 4 demonstrates the distribution of the number of patients according to post-operative complications. The results showed that postoperatively only 1 (5%) patient presented with wound dehiscence which was treated with wound irrigation and local measures. None of the cases had any infection and plate/screw fractures [Table 4].

DISCUSSION

The etiological factors for the mandibular fractures are interpersonal violence, traffic accidents, and falls. The incidence of the mandible fractures is 38%.[9] The primary goal of the treatment of mandibular fractures is to achieve satisfactory occlusion. Earlier, closed reduction and ORIF using wire osteosynthesis were the main treatment modalities. However, an average of 6 weeks of immobilization by MMF is required to achieve satisfactory healing and this would cause airway problems, weight loss, poor oral hygiene, malnutrition, speech difficulties, social inconvenience, insomnia, and difficulty in achieving the normal function of the jaw. On the other hand, rigid and semi-rigid fixation of the mandible fractures enables

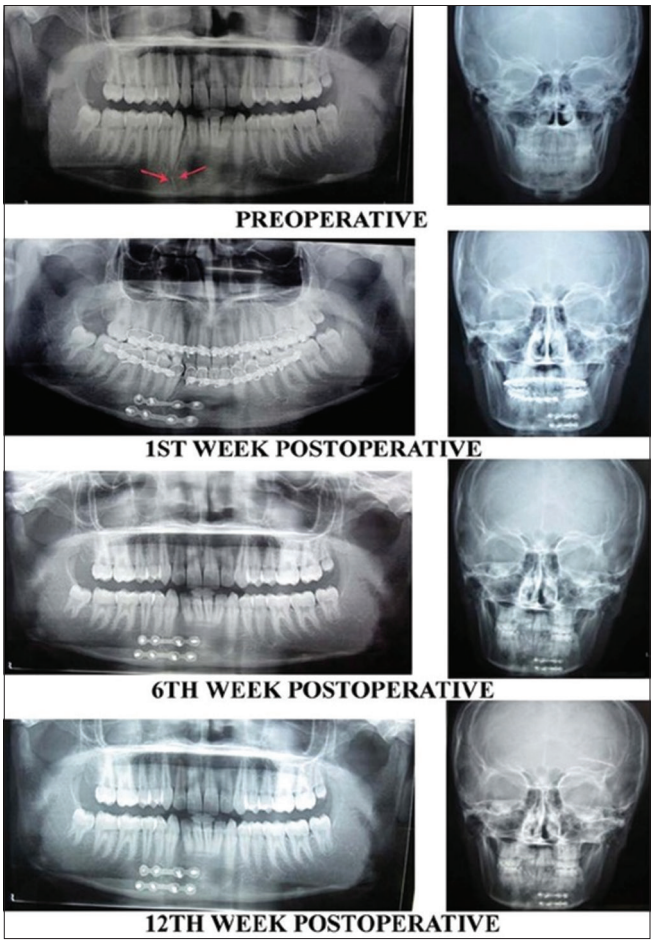

Figure 4: The pre- and post-operative radiographic healing in an orthopantomogram and posteroanterior view

Table 3: The comparison of radiographic healing of the 1st week, 6th week, and 12th weeks, respectively, using with Student's *t*-test

Between the 1st week and 6th week	*t*=21.47
Between the 1st week and 12th week	*t*=25.42
Between the 6th week and 12th week	*t*=5.40

t-value indicates that there is significant change in radiographic healing for *P*=0.05

Table 4: The distribution of number of patients according to post-operative complication

Post-operative complication	No	Yes
	n (%)	*n* (%)
Wound dehiscence	19 (95)	01 (05)
Infection	20 (100)	00 (00)
Plate fracture	20 (100)	00 (00)

early mobilization and restoration of normal function.[11] Miniplate fixation of mandible fractures along the "ideal lines of osteosynthesis" has become the most widely used technique. Champy *et al*.[6] performed several studies to validate this technique, and two miniplates are applied in the inter foraminal region.[12] Miniplates are easy to handle and avoid extraoral procedures but these are semi-rigid and smaller in size. This can cause torsional movements of the fracture segments under functional loading, this would further results in infection or non-union or both. Due to the reduced stability of miniplate fixation, it is recommended to use the maxillomandibular fixation for 1–2 weeks.[13] However, according to AO/Association for the study of internal fixation principles, the primary objective of ORIF in the management of mandibular fractures is to achieve immediate restoration of form and function without the adjunctive use of maxillomandibular fixation.[14] Moreover, miniplate would require a precise adaptation of the plate to the underlying bone. This would further disturb the blood supply and leads to bone necrosis. However, various types of bone plating systems have been developed to provide stable fixation. Fixation of mandibular anterior fracture with 3D locking plates also provides stability and carries low infection rate. However, it is quite expensive, and moreover, managing oblique fractures and those fractures involving the mental nerve area would be extremely difficult because of its excessive implant material.[15]

To overcome these shortcomings, a new internal mini-locking system has been developed in collaboration with the AO/ASIF-Institute (Davos, Switzerland).[16] In this plating system, screw thread fits exactly into the threaded plate holes and locks the screw into the plate during fixation. The introduction of locking plate/screw system for the treatment of mandibular fracture has various advantages over conventional miniplates. First, it facilitates stable anatomic reduction and prevents micromotion of the bony fragments, with immediate functional recovery.[17] Second, it avoids intimate contact with the underlying bone and do not disrupt the underlying cortical bone perfusion. Moreover, it makes plate adaptation easier and prevents any change in the occlusal relationship on screw tightening. Third, it decreased incidence of inflammatory complications from loosening of hardware.[6] Fourth, it offers greater stability between fragments and less time consuming when compared with non-locking systems.[6] The current study used 2.0 mm titanium locking miniplate/screw system to evaluate their efficacy in the management of anterior mandibular fractures.

Studies conducted by Saikrishna and Yang who showed that locking plates accord more rigid fixation than non-locking plates.[18,19] A study conducted by Batbayar *et al*. also showed that fixation of mandibular fractures using locking plate systems would require less post-operative maxillomandibular fixation.[20] In the current study, all 20 patients (100%) showed satisfactory occlusion postoperatively with excellent rigid fixation without the need for maxillomandibular fixation. However, a study conducted by Sauerbier and Kuenz who showed 6% of patients with minor occlusal disturbance postoperatively. This was attributed to the presence of concomitant facial fractures, particularly condylar neck fractures and pre-surgical occlusal disturbances.[21]

Loosening of screws and plates propagates an inflammatory response. However, with the use of a 2.0 locking miniplate system, no longer requires the adaptation of the plate to the bone. This preserves cortical perfusion with a decrease in the incidence of bone necrosis, thus enhancing bony healing and regeneration. Studies conducted by Collins and Singh who showed no significant differences between locking and non-locking plate systems regarding post-operative complication rates.[12,22] However, the current study used 2.0 locking miniplate in management of anterior mandibular fracture and showed one case of wound dehiscence. However, this was not related to the use due to the associated risk factors such as the age of the patient, poor oral hygiene, and positive history of alcoholism.

The present study has evaluated the radiographic healing of the fracture site at the 1st week, 6th weeks, and 12th week postoperatively. The study, first, showed an excellent healing of the fracture site postoperatively in all patients except for one minor complication of wound dehiscence. However, the wound infection was further resolved with IV antibiotics and intraoral irrigation. Second, it showed that healing of fracture was enhanced in younger patients with the more bony union than the older patients with

osteogenesis. With a limited sample size, this study attempts to throw light on the significance of locking titanium miniplates as promising in the effective management of anterior mandibular fracture.

CONCLUSION

Within the limitation of the present study, we can conclude that

- All 20 patients achieved a satisfactory occlusion
- Excellent radiographic healing of the fracture site was observed
- Postoperatively, only 1 (5%) patient presented with wound dehiscence which was further resolved with wound irrigation and IV antibiotics
- None of the cases showed infection or plate/screw fracture
- The overall complication rate was 5%.

REFERENCES

1. Almahdi HM, Higzi MA. Maxillofacial fractures among Sudanese children at Khartoum dental teaching hospital. BMC Res Notes 2016;9:120.
2. Ribeiro RL, da Silva Gillet LC, Vasconcelos HG, Rodrigues CL, de Jesus Viana Pinheiro J, de Melo Alves-Junior S. Facial fractures: Large epidemiologic survey in Northern Brazil reveals some unique characteristics. J Oral Maxillofac Surg 2016;74:2480.e1-12.
3. Singaram M, Vijayabala GS, Udhayakumar RK. Prevalence, pattern, etiology, and management of maxillofacial trauma in a developing country: A retrospective study. J Korean Assoc Oral Maxillofac Surg 2016;42:174-81.
4. Bohluli B, Mohammadi E, Oskui IZ, Moharamnejad N. Treatment of mandibular angle fracture: Revision of the basic principles.Chin J Traumatol 2019;22:117-9.
5. Singh A, Arunkumar KV. Standard 3D titanium miniplate versus locking 3D miniplate in fracture of mandible: A prospective comparative study. J Maxillofac Oral Surg 2016;15:164-72.
6. Champy M, Wilk A, Schnebelen JM. Tretment of mandibular fractures by means of osteosynthesis without intermaxillary immobilization according to F.X. Michelet's technic. Zahn Mund Kieferheilkd Zentralbl 1975;63:339-41.
7. Glória JC, Fernandes IA, da Silveira EM, de Souza GM, Rocha RL, Galvão EL, *et al.* Comparison of bite force with locking plates versus non-locking plates in the treatment of mandibular fractures: A meta-analysis. Int Arch Otorhinolaryngol 2018;22:181-9.
8. Herford AS, Ellis E 3rd. Use of locking reconstruction bone plate/screw system for mandibular sugery. J Oral Maxillofac Surg 1998;56:1261-5.
9. Kawai T, Murakami S, Hiranuma H, Sakuda M. Radiographic changes during bone healing after mandibular fractures. Br J Oral Maxillofac Surg 1997;35:312-8.
10. Oruç M, Işik VM, Kankaya Y, Gürsoy K, Sungur N, Aslan G, *et al*. Analysis of fractured mandible over two decades. J Craniofac Surg 2016;27:1457-61.
11. El-Anwar MW. Changing trends in the treatment of mandibular fracture. Int Arch Otorhinolaryngol 2018;22:195-6.
12. Collins CP, Pirinjian-leonard G, Tolas A, Alcalde R. A prospective randomized clinical trial comparing 2.0mm locking plates to 2.0mm standard plates in treatment of mandibular fractures. J Oral Maxillofac Surg 2004;62:1392-5.
13. Fonseca R. In: Baker S, Dalrymple D, Norman J, editors. Oral and Maxillofacial Trauma. 3rd ed., Vol. 2. St. Louis: Elsevier Mosby Saunders; 2005. p. 1147-8.
14. Kumar BP, Kumar KA, Venkatesh V, Mohan AP, Ramesh K, Mallikarjun K. Study of efficacy and the comparison between 2.0 mm locking plating system and 2.0 mm standard plating system in mandibular fractures. J Maxillofac Oral Surg 2015;14:799-807.
15. Budhraja NJ, Shenoi RS, Badjate SJ, Bang KO, Ingole PD, Kolte VS. Three-dimensional locking plate and conventional miniplates in the treatment of mandibular anterior fractures. Ann Maxillofac Surg 2018;8:73-7.
16. Gutwald R, Alpert B, Schmelzeisen R. Principles and stability of locking plates. Keio J Med 2003;52:21-4.
17. Prabhakar C, Shetty JN, Hemavathy OR, Guruprasad Y. Efficacy of 2-mm locking miniplates in the management of mandibular fractures without maxillomandibular fixation. Natl J Maxillofac Surg 2011;2:28-32.
18. Saikrishna D, Shetty SK, Marimallappa TR. A comparison between 2.0-mm standard and 2.0-mm locking miniplates in the management of mandibular fractures. J Maxillofac Oral Surg 2009;8:145-9.
19. Yang L, Patil PM. Comparative evaluation of 2.0 mm locking plate system VS 2.0 mm nonlocking plate system for mandibular angle fracture fixation: A prospective randomized study. Eur Rev Med Pharmacol Sci 2015;19:552-6.
20. Batbayar EO, Dijkstra PU, Bos RM, van Minnen B. Complications of locking and non-locking plate systems in mandibular fractures. Int J Oral Maxillofac Surg 2019;44:1213-26.
21. Sauerbier S, Kuenz J. Clinical aspects of a 2.0-mm locking plate system for mandibular fracture surgery. J Craniomaxillofac Surg 2010;38:501-4.
22. Singh V, Kumar I, Bhagol A. Comparative evaluation of 2.0-mm locking plate system VS 2.0-mm nonlocking plate system for mandibular fracture: A prospective randomized study. Int J Oral Maxillofac Surg 2011;40:372-7.

How to cite this article: Jyoti B, Zakaullah S, Kothare C, Pande D, Biradar N, Jose J. Management of Anterior Mandibular Fractures Using 2 mm Titanium Locking Plate. Int J Sci Stud 2021;9(1):97-102.

Source of Support: Nil, **Conflicts of Interest:** None declared.

Print ISSN: 2321-6379
Online ISSN: 2321-595X

Original Article

Ventriculoperitoneal Shunt Surgery and the Incidence of Shunt Revision in Pediatric Patients

Sheik Mohammed Sameer Khan[1], Rjvv Prasad[2], Asit Roy[1], Rajachaitanya Reddy[1], R. Veerapandian[3]

[1]Postgraduate, Department of Neurosurgery, Madurai Medical College and Government Rajaji Hospital, Madurai, Tamil Nadu, India, [2]Consultant Neurosurgeon, Department of Neurosurgery, Velammal Medical College, Madurai, Tamil Nadu, India, [3]Professor and Head, Department of Neurosurgery, Madurai Medical College and Government Rajaji Hospital, Madurai, Tamil Nadu, India

Abstract

Introduction: Ventriculoperitoneal shunt (VPS) insertion for the treatment of hydrocephalus is associated with several complications including infections, mechanical failure, obstruction, bowel perforation with or without extrusion through natural orifices, nonvisceral perforation, shunt migrations, and shunt disconnection. Many of these complications occurring following VPS implantation require shunt revision, and the requirement of revisions is significantly more in pediatric patients compared to adults.

Objective: The objective of the study was to analyze 100 cases of hydrocephalus, their etiology, VPS failures, and incidence of shunt revision in pediatric population.

Materials and Methods: We selected 100 cases of pediatric patients who underwent shunt surgeries for various reasons and presented with complication of the procedure. Demographic details, etiology of first shunt surgery, causes for shunt failure, and age at which revision of shunt done are tabulated and analyzed. In our study, we have either done revision of shunt on same side, the other side or endoscopic third ventriculostomy (ETV).

Results: Out of 100 cases studied, the most common cause for shunt surgery was post-meningitis hydrocephalus, and most common age at first surgery was <3 months. Upper end failure was most common reason for shunt failure, age at revision was 2–5 years, and lower end failure is reason for most of multiple shunt revisions. Most of the patients underwent revision on same side, followed by opposite side, ETV, shunt removal, etc.

Conclusion: VPS procedure is the mainstay treatment for hydrocephalus in pediatric age group, but in long term it is often associated with manifold complications which necessitate its revision.

Key words: Shunt failures, Shunt related complications, Shunt revision, Ventriculoperitoneal shunt

INTRODUCTION

Hydrocephalus has been described in medical writings since the time of Hippocrates. In 1914, Dandy and Blackfan[1] first established the pathology of hydrocephalus and developed sound anatomical, physiological, and surgical principles for its treatment. In 1955, Scott *et al.*[2] described the use of a ventriculoperitoneal shunt (VPS). Scarf[3] tabulated the published results of the different methods up to 1963; he found a strong tendency for the VPS to become obstructed at the distal end and a high incidence (30–50%) of permanent failures.

Access this article online

IJSS

www.ijss-sn.com

Month of Submission : 02-2021
Month of Peer Review : 03-2021
Month of Acceptance : 03-2021
Month of Publishing : 04-2021

Ventriculoperitoneal shunt (VPS) insertion for the treatment of hydrocephalus is associated with several complications including infections, mechanical failure, obstruction, bowel perforation with or without extrusion through natural orifices, nonvisceral perforation, shunt migrations, and shunt disconnection.[4-6] Many of these complications occurring following VPS implantation require shunt revision, and the requirement of revisions is significantly more in pediatric patients compared to adults.[4,6]

Objective

The objective of the study was to analyze 100 cases of hydrocephalus, their etiology, VPS failures, and incidence of shunt revision in pediatric population.

Corresponding Author: Dr. Rjvv Prasad, Department of Neurosurgery, Velammal Medical College, Madurai, Tamil Nadu, India.

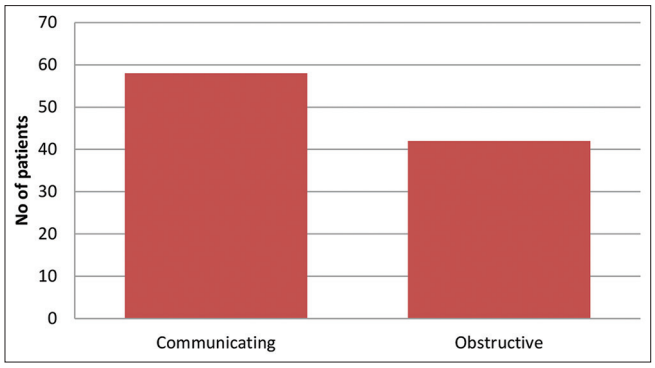

Graph 1: Type of hydrocephalus

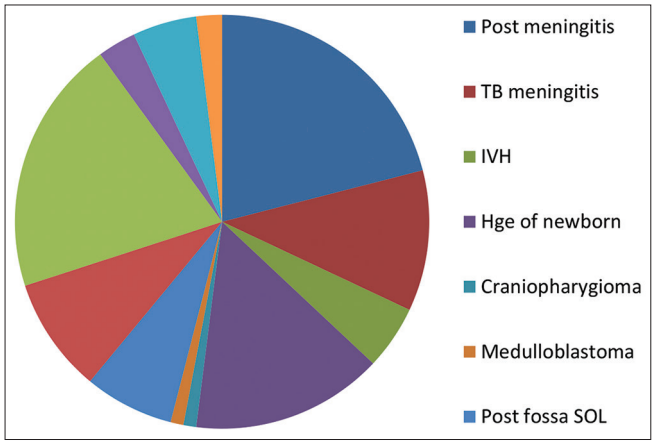

Graph 2: Etiology of hydrocephalus and indication for ventriculoperitoneal shunt surgery

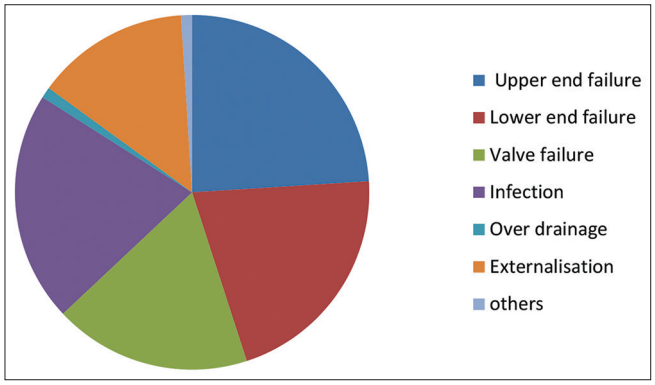

Graph 3: Various causes of shunt revision

MATERIALS AND METHODS

We selected 100 cases of pediatric patients who underwent shunt surgeries for various reasons and presented with complication of the procedure. Demographic details, etiology of first shunt surgery, causes for shunt failure, and age at which revision of shunt done are tabulated and analyzed. In our study, we have either done revision of shunt on same side, the other side or endoscopic third ventriculostomy (ETV).

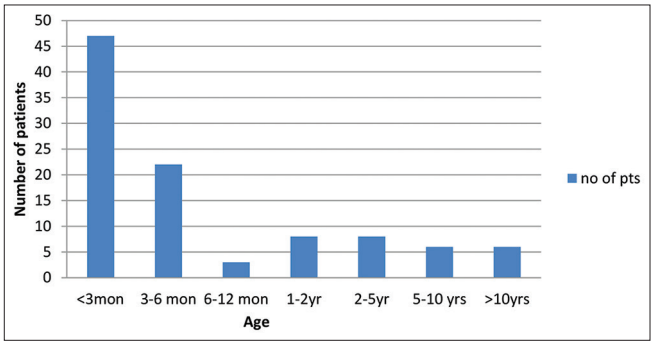

Graph 4: Age at which first shunt was done

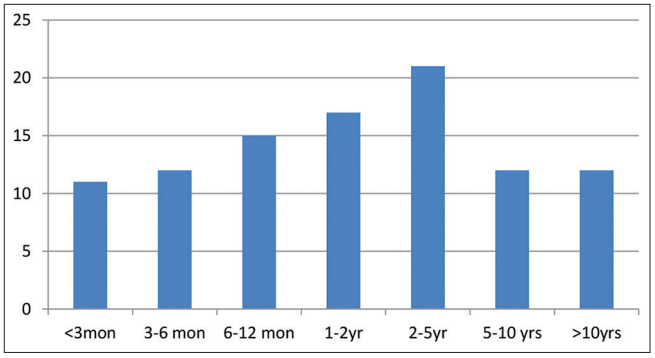

Graph 5: Age ranges at which shunt revision was done

RESULTS

Out of 100 cases studied, the most common cause for shunt surgery was post-meningitis hydrocephalus, and most common age at first surgery was <3 months. Upper end failure was most common reason for shunt failure, age at revision was 2–5 years, and lower end failure is reason for most of multiple shunt revisions. Most of the patients underwent revision on same side, followed by opposite side, ETV, shunt removal, etc.

DISCUSSION

In our study, 58 cases were communicating and rest were obstructive type of hydrocephalus [Graph 1]. The spectrum etiology with which they presented is tabulated in Graph 2. All the cases underwent right VPS surgery at the time of presentation.

Most of the cases were due to meningitis, communicating hydrocephalus of which major portion was due to tuberculosis, followed by hemorrhagic disease of new born [Graph 3]. Children younger than 3 months of age underwent shunt surgeries for the 1st time, followed by age between 3 and 6 months [Graphs 4 and 5].

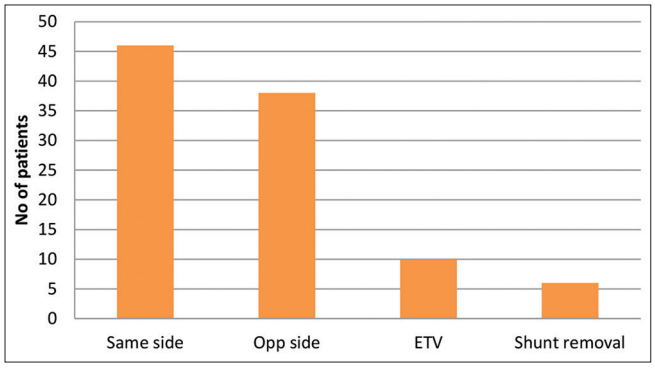

Graph 6: Methods of shunt revision done

Figure 1: (a) Clinical picture of baby showing progressive head size in spite of shunt in situ, (b) skin erosions over reservoir, (c) computed tomography scan of the baby showing unresolved hydrocephalus with shunt *in situ*, (d) erect X-ray of abdomen shows lower end failure in the form entangled shunt tube

Most of the shunt system dysfunction is due to upper end failure [Figure 1], followed by lower end failure [Figure 2], but cause for multiple shunt revision surgeries is due to lower end failure. Few of miscellaneous causes include peritubal effusion [Figure 3].

In as many as 46 patients, revision is done on same side either by upper or lower end revision alone or replacing the entire shunt system on same side. However, 38 patients underwent revision on opposite side. ETV is done in ten

Figure 2: Pictures showing extrusion of shunt tube through anal canal

Figure 3: Clinical pictures of a boy with shunt tube disconnection and peritubal effusion

patients and permanent shunt removal done in remaining six patients who became shunt independent [Graph 6].

CONCLUSION

This retrospective study evaluates various complications associated with VPS surgeries in pediatric population. We found that upper end failures are the common cause for shunt failure and shunt infection remains an avoidable cause for the same. However these complications can be avoided by proper pre-operative assessment, adopting periprocedural sterile environment, and meticulous surgical techniques.

ACKNOWLEDGMENT

Since we come across many cases of congenital hydrocephalus in our institute, we did a retrospective study in ventriculoperitoneal surgery and its complications. We wish to share our experience of 100 such cases through your esteemed journal publication.

REFERENCES

1. Dandy WE, Blackfan KD. Internal hydrocephalus: An experimental, clinical and pathological study. Am J Dis Child 1914;8:406-82.
2. Scott M, Wycis HT, Murtagh F, Reyes V. Observations on ventricular and lumbar subarachnoid peritoneal shunts in hydrocephalus in infants. J Neurosurg 1955;12:165-75.
3. Scarff JE. Treatment of hydrocephalus: An historical and critical review of methods and results. J Neurol Neurosurg Psychiatry 1963;26:1-26.
4. Paff M, Alexandeu-Abrams D, Muhonen M, Loudon W. Ventriculoperitoneal shunt complications: A review. Interdiscip Neurosurg 2018;13:66-70.
5. Lee L, Low S, Low D, Ng LP, Nolan C, Seow WT, *et al*. Late pediatric ventriculoperitoneal shunt failures: A singapore tertiary institution's experience. Neurosurg Focus 2016;41:E7.
6. Ghritlaharey RK, Budhwani KS, Shrivastava DK, Srivastava J. Ventriculoperitoneal shunt complications needing shunt revision in children: A review of 5 years of experience with 48 revisions. Afr J Paediatr Surg 2012;9:32-9.

How to cite this article: Khan SMS, Prasad RJV, Roy A, Reddy R. Ventriculoperitoneal Shunt Surgery and the Incidence of Shunt Revision in Pediatric Patients. Int J Sci Stud 2021;9(1):103-106.

Source of Support: Nil, **Conflicts of Interest:** None declared.

Print ISSN: 2321-6379
Online ISSN: 2321-595X

Original Article

Comparison of the Effect of Different Irrigating Solutions on Bond Strength of Obturating Materials: An *In vitro* Study

Chaudhary Shweta[1], K Kade Kimaya[2], Jagtap Chetana[3], R Patel Alok[4], P Shah Preetam[5], H Kambale Amol[3]

[1]Associate Professor, Department of Paediatric and Preventive Dentistry, Bharati Vidyapeeth Deemed to be University, Dental College and Hospital, Pune, Maharashtra, India, [2]Student, Department of Paediatric and Preventive Dentistry, Bharati Vidyapeeth Deemed to be University, Dental College and Hospital, Pune, Maharashtra, India, [3]Assistant Professor, Department of Paediatric and Preventive Dentistry, Bharati Vidyapeeth Deemed to be University, Dental College and Hospital, Pune, Maharashtra, India, [4]Professor and HOD, Department of Paediatric and Preventive Dentistry, Bharati Vidyapeeth Deemed to be University, Dental College and Hospital, Pune, Maharashtra, India, [5]Professor, Department of Paediatric and Preventive Dentistry, Bharati Vidyapeeth Deemed to be University, Dental College and Hospital, Pune, Maharashtra, India

Abstract

Background: Success in endodontic therapy depends on debridement of the root canal system through the use of instruments and effective irrigating solutions. The aim of instrumentation and irrigation is to prepare a debris-free canal for subsequent obturation.

Aim: Comparison of the effect of different irrigating solutions on bond strength of obturating materials: An *in vitro* study.

Materials and Methods: Healthy sound caries-free premolars are included. Forty teeth were divided into four groups, *Azadirachta indica*, *Curcuma longa*, methyl ethylene diaminotetraacetic acid, and sodium hypochlorite (NaOCl) as irrigating solution. Roots were vertically placed in the center of blocks of resin. Sectioning was carried out horizontally. Three root sections of 2 mm thickness at 3, 7, and 11 mm from the apex were obtained. Each piece was further subjected to a compressive load through a universal testing machine. The push-out bond strength was calculated. Using one-way ANOVA test followed by *post hoc,* comparison of bond strength among four study groups was evaluated.

Results: Mixture of tetracycline, acid, and detergent has highest push-out bond strength among all 4.54 mpa. MTAD has highest pushout bond strength among all which is 4.54 mpa. Significant p value is 0.005 in the middle region. NaOCl has highest mean value than others. Pairwise comparison is done in coronal region. No significant results were found.

Conclusion: Hence, we can easily replace NaOCl with herbal irrigating material. However, natural alternatives such as *A. indica* and *C. longa* may prove to be more inert irrigating solutions.

Key words: *Azadirachta indica*, Irrigation, Mixture of tetracycline, acid, and detergent, Sodium hypochlorite

INTRODUCTION

Preservation of primary teeth is crucial for the harmonious development of occlusion, maintenance of arch length, an optimum function of chewing speech, and preservation of a healthy oral environment. Endodontic treatment is necessary when pulp is got contaminated by bacteria and their toxins.[1] Root canal preparation is a rudimentary step in endodontic treatment.[2] Successful root canal therapy is relying on the removal of microorganisms from the pulp canals, tissue remnants, and dentinal debris of the root canal system during chemomechanical instrumentation and irrigating solutions. Three-dimensional obturation along with microorganism free canals leads to a path of success for a dentist.[3]

Chemical debridement is needed for primary teeth for complicated internal anatomy and zones are out of

Access this article online

www.ijss-sn.com

Month of Submission : 02-2021
Month of Peer Review : 03-2021
Month of Acceptance : 03-2021
Month of Publishing : 04-2021

Corresponding Author: K Kade Kimaya, Department of Paediatric and Preventive Dentistry, Bharati Vidyapeeth Deemed to be University, Dental College and Hospital, Pune, Maharashtra, India.

reach to debridement, such as accessory canals, dentinal tubules that might be not reachable by instrumentation. The choice of materials in the pulpal therapy of primary teeth should be taken into consideration. Therefore, it is necessary to noticeably reduce or, to an extent possible, the microorganisms and their by-products present to the root canals using effective and biocompatible irrigants, which also helps in dissolving organic debris.[4]

Dentin microhardness is diplomatic toward composition and surface changes in tooth structure and the multiple chemical irrigants that are used tend to decrease microhardness. These changes may have a profound effect on the tooth's strength.[5]

Berutti *et al*. stated that solutions used as irrigation agents could penetrate about 130 μm into the internal surfaces of root.[6] However, bacteria may be present in the root dentinal tubules up to 1000 μm depths.[7] In clinics, different irrigating solutions have been suggested for deciduous teeth, such as sodium hypochlorite (NaOCl), chlorhexidine gluconate, ethylenediaminetetraacetic acid (EDTA), hydrogen peroxide, mixture of tetracycline, acid, and detergent (MTAD), and others.[8]

Byström and Sundqvist, 1985, stated that NaOCl is used as an endodontic irrigant as it is the most potent, easily available, and inexpensive and universally accepted irrigant which has an effective antimicrobial and tissue-dissolving capabilities.[9] It has low viscosity allowing easy introduction into the canal anatomy, an acceptable shelf life.

In the root canal treatment of deciduous teeth, NaOCl can damage permanent tooth buds, tissues, and oral mucosa. The major disadvantages of NaOCl are its cytotoxic effect if injected into the surrounding tissue, a foul smell, taste, and its ability for causing corrosion. It is also known to produce an allergic reaction.[10,11]

Herbal products have been used since ancient times in folk medicine, involving both eastern and western medical traditions. MTAD, *Azadirachta indica*, and *Curcuma longa* also show effective antibacterial and irrigating properties. Hence, it is very important to study and evaluate the new irrigating materials to achieve long-term, successful endodontic treatment. Endodontic literature has scrutinized the effect of many endodontic irrigants on the bond strength of various types of root canal sealers. Sealers can be used in association with core filling material as gutta-percha (GP).

The comparison of antibacterial efficacy has been evaluated, but there are very few studies that have evaluated their effect on dentin and obturating material. Hence, this study aims to compare the effect of the same. Hence, this study is needed to evaluate newer irrigating agents such as *C. longa*, *A. indica*, and methyl ethylene diaminotetraacetic acid (MTDA) with regard to their effect on dentin microhardness and bond between dentin and obturating material.

MATERIALS AND METHODS

The study was conducted on 40 extracted permanent teeth from the Department of Oral Maxillofacial Surgery, Bharati Vidyapeeth Dental College and Hospital, Deemed to be University, Pune, for dental treatment. Freshly extracted human permanent single-rooted premolars were taken for the study. Debris and soft-tissue remnants on the root surfaces were cleaned with a sharp scalpel and all teeth were stored in phosphate-buffered saline at until used. The selected teeth were stored in a jar filled with natural buffered thymol at room temperature.

Canal patency and working length were established by inserting K-file to the root canal terminus and subtracting 1 mm from this measurement. The root canals were instrumented. Each canal was enlarged to size #40 at the working length. Irrigation with 1 ml saline was performed between each file size. A total volume of 1 ml of each solution were inserted into the canal lumen in each root segment and left in place for 60 s exposure time.

Finally, the root canals were flushed with 5 ml distilled water after the completion of preparation.

The teeth were irrigated with material 1, material 2, and material 3, and material 4 as follows:

1. Group 1 – *A. indica*
2. Group 2 – *C. longa*
3. Group 3 – MTDA
4. Group 4 – NaOCl.

Preparation of Solutions

[Figure 1] *C. longa*: The rhizomes were washed with distilled water and dried. They were then cut into irregular large pieces and dried in an oven by tray drying process at a temperature of 45 ± 5°C for a period of about 9–10 days till they were completely moisture free. The irregular large-sized pieces were minced to form a rough powder. The maceration process of extraction is then performed on this coarse powder of the rhizomes. Two hundred and fifty grams g of coarsely ground powder of *C. longa* rhizomes were placed in two large glass chambers each. To one glass chamber, 1000 ml of sterile distilled water were added to prepare the aqueous extract. The glass chamber was locked with a glass lid to avert evaporation of the menstruum and this system was permitted to stand for 7 days with

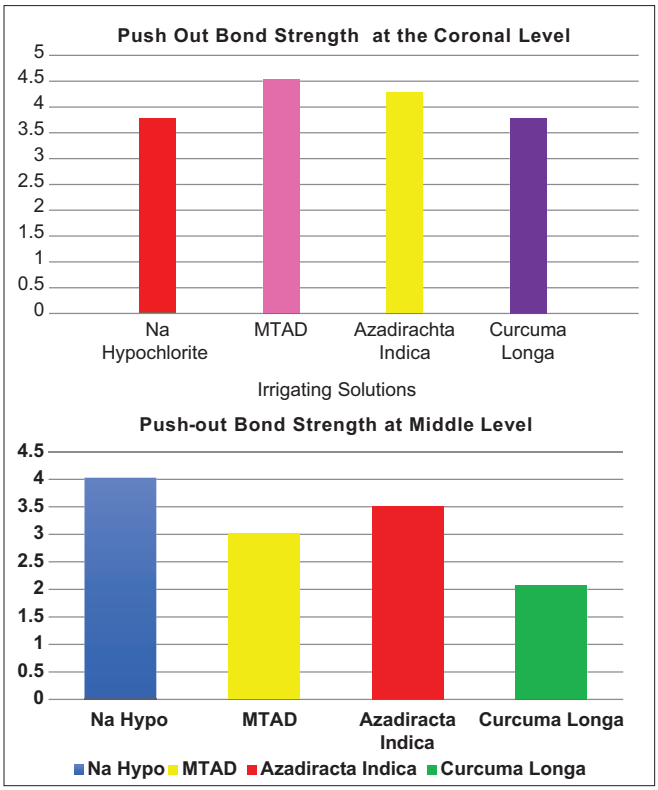

Figure 1: Materials used for this study

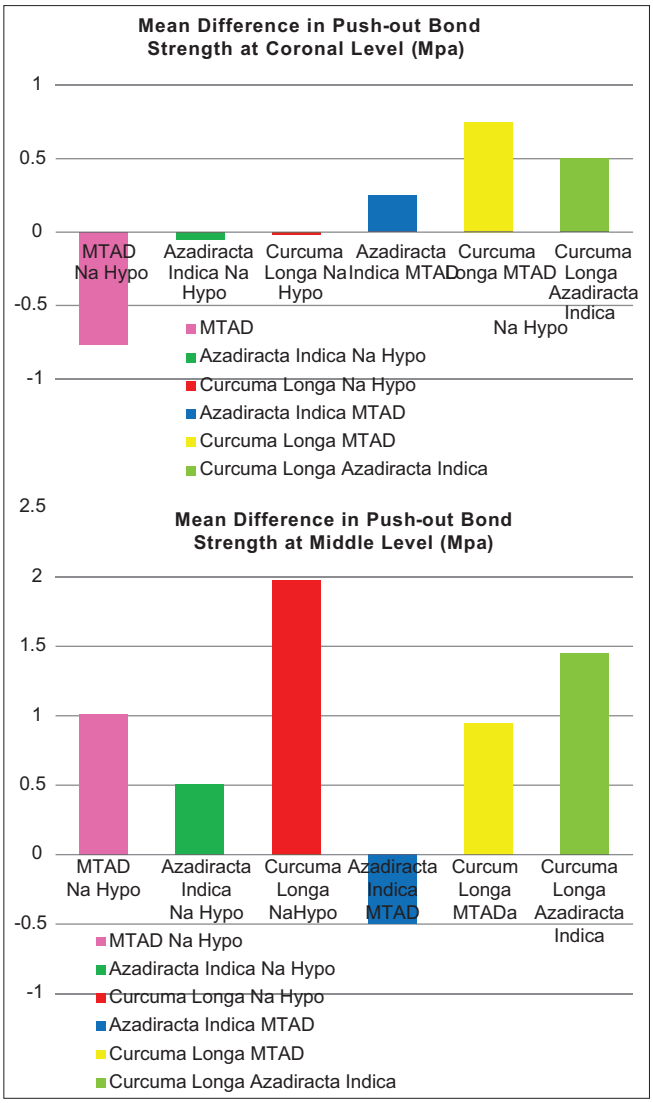

Figure 2: Filtration of curcuma lounga

occasional stirring. The liquid, that is, the menstruum was then sieved and the solid residue, called marc, was bearing down on to retrieve as much occluded solution as possible. The strained and expressed liquid was mixed infrequently and purified using the filtration method [Figure 2]. The filtration was carried out in a beaker using a filter paper no 1. The menstruum obtained was stored in a refrigerator at 4°C in a beaker. China dishes were used for evaporation of the menstruum [Figure 3].

Figure 3: Filtration of Azadirecta indica

The irrigation procedure was accomplished using an irrigating syringe with a 27-gauge needle. All canals were dried with absorbent points. After mixing the AH plus sealer, a GP master cone was lightly layered with sealer and placed till the working length. A System B plugger size fine medium was used to condense the master cone to within 1 mm from the working length. The sectioned tooth was placed in 100% humidity for 48 h after coding to ensure the complete setting of the sealers. The tooth is sectioned horizontally using a microtome with constant fresh cooling water. Sectioning was implemented in a horizontal plane perpendicular to the long axis of the main canal. Three sections of 2 mm thickness were acquired at 3, 7, and 11 mm to represent apical, middle, and coronal third, respectively, from the root. The coronal surface of each section was coded and the exact thickness of each slice was measured with a Vernier caliper instrument. Each root section was then yielded to a compressive load through a universal testing machine. The plunger tip was positioned in such a way that it only contacted the filling material. The

Figure 4: Herbal extract

push-out force was applied in an apicocoronally direction until bond failure occurred, which was manifested by extrusion of the obturation material and a sudden drop along the load deflection. The maximum failure load was recorded in Newtons and it was used to calculate the push-out bond strength in megapascals.

MPa According to the Following Formula[10]

Push-out bond strength = Maximum load

Adhesion area of root canal filling (2 mm)

RESULTS

1. Machine specifications: Universal testing machine (computerized, software based)
2. Company: ACME Engineers, India. Model No. UNITEST-10
3. Accuracy of the machine: ±1%, crosshead speed: 1 mm/min
4. Area: Coronal: 8.16 mm^2, middle: 6.28 mm^2, apical: 5.02 mm^2

The mean values of bond strengths recorded for different groups for different areas are presented in Table 1 and Graph 1. MTAD yielded significantly the highest mean push-out bond strength at the coronal level (average 4.54 mpa) followed by *A. indica* and *C. longa*. On the other hand, the significantly lowest mean push-out bond was recorded for NaOCl (3.77 mpa) [Graph 2].

At the middle level, NaOCl shows the highest mean push-out bond strength. The apical sections of the specimen were not consideration as they were not fitting into the plunger. This is a drawback of this study.

Analyses of the push-out bond strength data indicated a statistically significant difference between the values of the differently treated groups and also within the groups. Using a one-way ANOVA test followed by a *post hoc,* comparison of bond strength among four study groups was evaluated. Pairwise comparison is done in the coronal region. No significant results are found. Significant p value seen in the middle area.

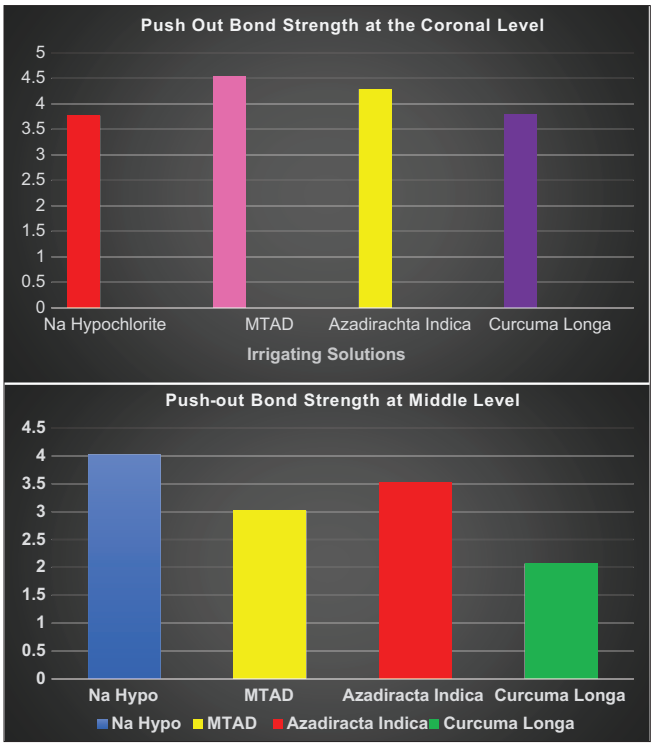

Graph 1: (a) Push out bond strength at coronal level, (b) Push out bond strength at middle level

Table 1: The mean values of bond strengths recorded for different groups

Average	Sodium hypo	MTAD	*A. indica*	*C. longa*
Coronal (mpa)	3.77	4.54	4.29	3.79
Middle (mpa)	4.02	3.02	3.52	2.07
Apical (mpa)	–	–	3.38	3.38

The pairwise difference was calculated which indicates a significant difference at $P \leq 0.05$. In between groups, Na hypo *C. longa* = mean diff is 1.98 and significant value is 0.004*. *A. indica* and *C. longa* mean value is 1.45 and significant diff is 0.027*. The maximum failure load was recorded in Newtons and it was used to calculate the push-out bond strength in megapascals [Figure 4].

DISCUSSION

The main purposes of root canal filling are to avert leakage from the oral cavity and the periradicular tissue into the root canal system.[12] Dentin surface treatment with distinct

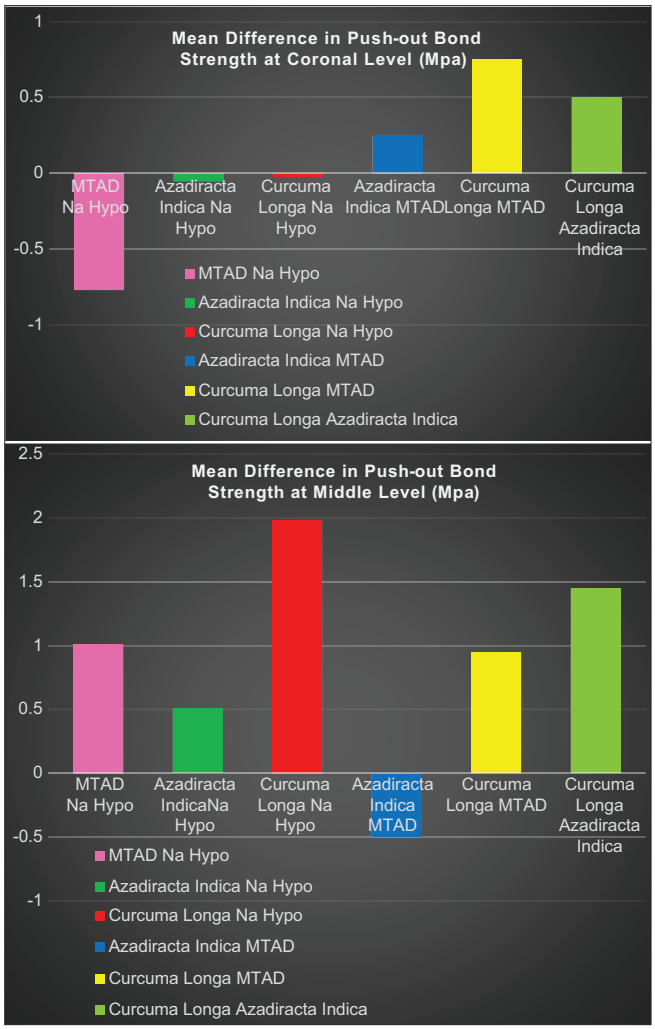

Graph 2: (a) Mean diff in push out bond strength (b) Mean diff in push out bond strength at middle level

irrigation solutions gives rise to a shift in the chemical and structural architecture of the human dentine, which may change permeability and solubility characteristics. These properties influence the bonding of materials to the dentin surface. Solubility characteristics affect the adhesion of filling materials to dentin surfaces. The clinical longevity of endodontically treated teeth depends on the effective adhesion of the obturating material to the dentin.[13,14] Lateral condensation was used currently as it is widely accepted as an obturation technique and resulted in higher bond strengths of the materials to root canal dentin.[15]

An ideal root canal sealer should adhere tightly to both dentin and core filling materials.[16] In the present study, it was found that the irrigation regimens influence the bond strength of the tested specimen. Therefore, suitable dentin substrate like AH Plus Sealers is required to provide the adhesion of hydrophobic materials.[17,18] Fisher *et al.* used sealers for evaluating their bond strength to the smear-free root dentin and found that AH Plus resin sealer had significantly higher bond strength compared with the other sealers available.[19]

The effective removal of the smear layer may enhance the adhesion of the AH Plus sealer with increased penetration of AH Plus sealer into dentinal tubules. It has been stated that good adaptation, penetration, and adhesion properties have a positive effect on sealing because of the increased surface contact between the sealer and dentin.[20] Bond strength testing is the most used method for determining the effectiveness of binding capacity between endodontic materials and tooth components.[21] As fracture occurs parallel to the dentine bonding interface, the push-out test is preferred to measure the bond strength, making it a true shear test for parallel sided samples. Push-out test permits root canal sealers to be evaluated even when bond strengths are low at different levels of root canal walls so we used to push-out bond strength for this study.[22]

Therefore, different irrigation regimens were used in the current study to examine their effect on the push-out bond strength of the AH Plus sealer with root canal obturation. Saleh *et al.* verbalized that the penetration of the endodontic sealers into the dentinal tubules when the smear layer was abstracted was not associated with higher bond strength.[16]

In the present study, the bond strength decreased from the coronal to the apical direction. Our result when compared with results from many studies juxtaposed that the binding ability of root canal sealers generally less in the coronal to the apical direction.[23] The shortness of approach to the end region of irrigation solutions and they result in incomplete extrapitation of the smear layer, due to that decrease the penetration of the sealer into the dentinal tubules and may affect the adhesion in the apical region.[24] The present results demonstrated that the push-out bond strengths for the coronal and middle root dentin were higher than that of the apical root dentin. This is probably because of insufficient volume or penetration of the irrigation into the apical portion of the canal. This was supported by Torabinejad *et al.* who show that MTAD is an effective solution for the removal of the smear layer and does not significantly change the structure of the dentinal tubules when canals are irrigated.[25] Moreover, Whitaker *et al.*[26,27] concluded that the structure of dentin in the apical region of human teeth, where the number of dentinal tubules was considered fewer than that in the cervical and middle dentine. The low number of dentinal tubules, the irregular structure of secondary dentin, and the presence of cementum like tissue apically on the root canal wall resulted in reduced penetration of adhesives into the apical root dentin collated to coronal.

This result is juxtaposed with results from several studies. It shows that the adhesion of root sealers is generally better in the coronal and middle regions.[23]

Torabinejad *et al.* introduced MTAD as a MTAD. They concluded that MTAD has shown that it is clinically effective and biocompatible with sustained antibacterial activity.[25]

The necrotic tissue-dissolving property of NaOCl is distinctive. Its activity increases with the concentration, temperature, and duration of application.[23] Many mishaps, such as the spattering of NaOCl into the patient's or dentist's eye, staining of the patient's clothes, extrusion of NaOCl beyond the apical foramen, unintentional injection of irrigants instead of anesthesia, or allergic reaction to the irrigation solution, can occur during root canal treatment. NaOCl is used in concentrations ranging from 0.5% to 5.25%; it is a vigorous antimicrobial agent and productively dissolves the remaining part of pulpal tissue and organic components of dentine. Farag *et al.* revealed that MTAD is a final irrigation solution when used with either NaOCl or CHX as irrigation solutions throughout instrumentation enhanced the bonding of obturation material to root canal dentin compared to EDTA solution. The current finding divulges that utilizing NaOCl throughout instrumentation and as a final rinse had significantly lower bond strength than compared groups. Hence, we can say why MTAD is better in the middle region than in NaOCl.[28]

Nikaido *et al.* commented that the use of NaOCl for irrigation was found to reduce the bond strength between the adhesive system and the dentinal wall. NaOCl is thought to remove debris from the dentin surface, thereby reducing the formation of the hybrid layer, which is required to achieve a dentin-adhesive link.[29]

NaOCl increased the wettability of root canal dentin so it might be the reason why MTAD shows the highest bond strength than NaOCl.[30] Sundaram *et al.* exclaimed that 5.25% NaOCl is more effective as irrigant when compared with neem leaf extract and honey.[31]

Deus *et al.* (2008) found no significant difference between EDTA and MTAD after the evaluation of bond strength but low bond strength in the NaOCl group. This may be claimed to the better cleaning efficacy of MTAD solution on the canal walls. Its active ingredient of 4.25% citric acid and the detergent Polysorbate 80, which decreased the surface tension, might allow MTAD to penetrate into dentinal tubules and enhance its effect on smear layer removal.[32] Wu *et al.* revealed that the effect of MTAD on smear layer removal was superior to EDTA.[33] It was also supported by Torabinejad *et al.*[35] and Adigüzel *et al.*[34] proved that the superlative results and excellent efficacy were associated with MTAD.

Herbal extracts such as *A. indica*, *C. longa*, *A. vulgaris*, and honey are well known for antimicrobial, anti-fungal, anti-inflammatory, antioxidant, antipyretic, and analgesic properties also they are less expensive hypoallergenic easily available, better tolerated and renewable in nature. The extract from neem bark, leaves, fruits, and flowers contains flavonoids, flavonoglycosides, dihydrochalcones, and tannins.[36,37] Although herbal irrigants have excellent biocompatibility and comparable antimicrobial properties as NaOCl, its ability to remove the smear layer is still lacking.[38]

CONCLUSION

In the recent past, there has been a shift from the recently used synthetic chemical substances to the natural herbal ingredients. Hence, we can easily replace NaOCl with herbal irrigating material. However, natural alternatives such as *A. indica* and *C. longa* might be more inert irrigating solutions. We can consider MTAD as a potent irrigating solution.

It could be inferred that within the limitations of this study:
1. MTAD has the highest push-out bond amongst all in the apical area
2. Middle sections showed higher bond strength values than the coronal and apical sections.

The present observations suggest that canal irrigation with various chemical solutions leads to structural changes as evidenced by the reduction of dentine microhardness.

REFERENCES

1. Pascon FM, Kantovitz KR, Rontani RM. Influence of cleansers and irrigation methods on primary and permanent root dentin permeability: A literature review. Braz J Oral Sci 2006;5:1063-9.
2. Oguntebi BR. Dentine tubule infection and endodontic therapy implications. Int Endod J 1994;27:218-22.
3. Kaur R, Singh R, Sethi K, Garg S, Miglani S, Vats S. Irrigating solutions in pediatric dentistry: Literature review and update. J Adv Med Dent Sci Res 2014;2:104-15.
4. Ito IY, Matoba F Jr., Paula-Silva FW, Da Silva LA, Leonardo MR, Nelson-Filho P. Microbial culture and checkerboard DNA-DNA hybridization assessment of bacteria in root canals of primary teeth pre-and post-endodontic therapy with a calcium hydroxide/chlorhexidine paste. Int J Paediatr Dent 2011;21:353-60.
5. Zehnder M. Root canal irrigants. J Endod 2006;32:389-98.
6. Berutti E, Marini R, Angeretti A. Penetration ability of different irrigants into dentinal tubules. J Endod 1997;23:725-7.
7. Haapasalo M, Orstavik D. *In vitro* infection and disinfection of dentinal tubules. J Dent Res 1987;66:1375-9.
8. Kaur R, Singh R, Sethi K, Garg S, Miglani S, Vats S. Review article irrigating solutions in pediatric dentistry: Literature review and update. J Adv Med Dent Sci 2014;2:104-15.

9. Byström A, Sundqvist G. The antibacterial action of sodium hypochlorite and EDTA in 60 cases of endodontic therapy. Int Endod J 1985;18:35-40.
10. O'Hoy PY, Messer HH, Palamara JE. The effect of cleaning procedures on fracture properties and corrosion of NiTi files. Int Endod J 2003;36:724-32.
11. Gomes BP, Ferraz CC, Vinna ME, VBerber VB, Teixeria FB, Souza Filho FJ. *In vitro* antimicrobial activity of several concentrations of sodium hypochlorite and chlorhexidine gluconate in the elimination of *Enterococcus faecalis*. Int Endod J 2001;34:424-8.
12. Cohen S, Burns R. Pathways of the Pulp. 8th ed. St Louis, Missouri: Mosby; 2002.
13. Saleh IM, Ruyter IE, Haapasalo M, Ørstavik D. The effects of dentine pretreatment on the adhesion of root-canal sealers. Int Endod J 2002;35:859-66.
14. van Meerbeek B, Lambrechts P, Inokoshi S, Braem M, Vanherle G. Factors affecting adhesion to mineralized tissues. Oper Dent 1992;5:111-24.
15. Carneiro SM, Sousa-Neto MD, Rached FA Jr., Miranda CE, Silva SR, Silva-Sousa YT. Push-out strength of root fillings with or without thermomechanical compaction. Int Endod J 2012;45:821-8.
16. Saleh IM, Ruyter IE, Haapasalo MP, Orstavik D. Adhesion of endodontic sealers: Scanning electron microscopy and energy dispersive spectroscopy. J Endod 2003;29:595-601.
17. Attal JP, Asmussen E, Degrange M. Effects of surface treatment on the free surface energy of dentin. Dent Mater 1994;10:259-64.
18. Buzoglu HD, Calt S, Gümüsderelioglu M. Evaluation of the surface free energy on root canal dentine walls treated with chelating agents and NaOCl. Int Endod J 2007;40:18-24.
19. Uppalapati LV, Mandava J. Evaluation of push out bond strengths of two different adhesive root canal obturation systems: An in vitro study. J NTR Univ Health Sci 2012;1:111-5.
20. Balguerie E, van der Sluis L, Vallaeys K, Gurgel-Georgelin M, Diemer F. Sealer penetration and adaptation in the dentinal tubules: A scanning electron microscopic study. J Endod 2011;37:1576-9.
21. Gogos C, Economides N, Stavrianos C, Kolokouris I, Kokorikos I. Adhesion of a new methacrylate resin-based sealer to human dentin. J Endod 2004;30:238-40.
22. Ungor M, Onay EO, Orucoglu H. Push-out bond strengths: The epiphany-resilon endodontic obturation system compared with different pairings of epiphany, resilon, AH plus and gutta-percha. Int Endod J 2006;39:643-7.
23. Nagas E, Cehreli ZC, Durmaz V. Effect of light-emitting diode photopolymerization modes on the push-out bond strength of a methacrylate-based sealer. J Endod 2011;37:832-5.
24. Wu M, van der Sluis LW, Wesselink PR. A preliminary study of the percentage of gutta-percha-filled area in the apical canal filled with vertically compacted warm gutta-percha. Int Endod J 2002;35:527-35.
25. Torabinejad M, Khademi AA, Babagoli J, Cho Y, Johnson W, Bozhilov K, *et al*. A new solution for the removal of the smear layer. J Endod 2003;29:170-5.
26. Whittaker DK, Kneale MJ. The dentin-predentine interface in human teeth. A scanning electron microscope study. Br Dent J 1979;146:43-6.
27. Mannocci F, Ferrari M. Apical seal of roots obturated with laterally condensed gutta-percha, epoxy resin cement, and dentin bonding agent. J Endod 1998;24:41-4.
28. Farag HA, Etman WM, Alhadainy HA, Darrag AM. Effect of different irrigating protocols on push out bond strength of resilon/epiphany obturation system. Tanta Dent J 2015;12:241-8.
29. Nikaido T, Takano Y, Sasafuchi Y, Burrow MF, Tagami J. Bond strengths to endodontically-treated teeth. Am J Dent 1999;12:177-80.
30. Yılmaz Z, Basbag B, Buzoglu HD, Gümüsderelioglu M. Effect of low-surface-tension EDTA solutions on the wettability of root canal dentin. Oral Surg Oral Med Oral Pathol Oral Radiol Endod 2011;111:109-14.
31. Sundaram D, Narayanan RK, Vadakkepurayil K. A comparative evaluation on antimicrobial effect of honey, neem leaf extract and sodium hypochlorite as intracanal irrigant: An *ex vivo* study. J Clin Diagn Res 2016;10:ZC88-91.
32. Pimenta JA, Zaparolli D, Pecora JD, Cruz-Filho AM. Chitosan: Effect of a new chelating agent on the microhardness of root dentin. Braz Dent J 2012;23:212-7.
33. Wu L, Mu Y, Deng X, Zhang S, Zhou D. Comparison of the effect of four decalcifying agents combined with 60°C 3% sodium hypochlorite on smear layer removal. J Endod 2012;38:381-4.
34. Adigüzel O, Yiğit-Özer S, Kaya S, Uysal I, Ganidağli-Ayaz S, Akkuş Z. Effectiveness of ethylenediaminetetraacetic acid (EDTA) and MTAD on debris and smear layer removal using a self-adjusting file. Oral Surg Oral Med Oral Pathol Oral Radiol Endod 2011;112:803-8.
35. Torabinejad M, Cho Y, Khademi AA, Bakland LK, Shabahang S. The effect of various concentrations of sodium hypochlorite on the ability of MTAD to remove the smear layer. J Endod 2003;29:233-9.
36. Asif M. Antimicrobial potential of azadirachta indica against pathogenic bacteria and fungi. J Pharmacog Phytochem 2012;1:78-83.
37. Silva FB, Almeida JM, Sousa SM. Natural medicaments in endodontics-a comparative study of the anti-inflammatory action. Braz Oral Res 2004;18:174-9.
38. Ambhore S. Influence of routinely used root canal irrigants vs herbal extracts on fracture resistance of endodontically treated teeth. Glob J Res Anal 2018;7:48-51.

How to cite this article: Shweta C, Kimaya KK, Chetana J, Alok RP, Preetam PS, Amol HK. Comparison of the Effect of Different Irrigating Solutions on Bond Strength of Obturating Materials: An *In vitro* Study. Int J Sci Stud 2021;9(1):107-113.

Source of Support: Nil, **Conflicts of Interest:** None declared.

Print ISSN: 2321-6379
Online ISSN: 2321-595X

Original Article

Comparative Evaluation of Results of Arthroscopic Single-row versus Double-row Repair in Full-thickness Rotator Cuff Tear in Adults

Tanmay Datta[1], Pinaki Das[2], Md Sharjeel Khan[3], Debayan Sinharoy[4]

[1]Associate Professor, Department of Orthopaedics, IPGME and R and SSKM Hospital, Kolkata, West Bengal, India, [2]Junior Resident, Department of Orthopaedics, IPGME and R and SSKM Hospital, Kolkata, West Bengal, India, [3]Contractual Medical Officer, Department of Orthopaedics, Gardenreach Superspeciality Hospital, Kolkata, West Bengal, India, [4]Senior Resident, Department of Orthopaedics, Calcutta National Medical College, Kolkata, West Bengal, India

Abstract

Objective: The objective of the study was to evaluate and compare the results of single-row (SR) versus double-row (DR) arthroscopic rotator cuff repair.

Materials and Methods: From January 2019 to August 2020, 24 arthroscopic rotator cuff repairs were performed using suture anchors. After applying the exclusion criteria, there were 20 patients to be evaluated. The patients were divided into two groups: SR with 10 shoulders and DR with 10 shoulders. The scoring system for clinical evaluation was simple shoulder test (SST) score.

Results: The follow-up period in both the groups was at least 6 months. The proportion of patients with improvements of SST at different time intervals of the patients treated with arthroscopic DR was higher than that of the patients treated with arthroscopic SR but it was not significant ($P > 0.05$).

Conclusion: No statistically significant difference was found between SR and DR arthroscopic rotator cuff repair performed by a single surgeon in the comparative analysis of SST scores.

Key words: Arthroscopy, Double-row, Rotator cuff tears, Rotator cuff, Single-row

INTRODUCTION

Rotator cuff injuries are a common shoulder trauma involving both young and elderly population.[1] Patients with a rotator cuff injury usually have an insidious onset of progressive pain and weakness, with concomitant loss of active motion. Loss of continuity of rotator cuff can be described as acute or chronic, partial or full thickness, and traumatic or degenerative.[2]

This particular case series included only full-thickness rotator cuff tears. These tears can be managed conservatively and with surgical intervention. However, results of non-operative treatment are unknown and excellent results are reported in operative managements ranging from 80% to 90% of patients, with improvements in pain, function, active forward flexion, strength, and early mobilization.[3] Ideally, rotator cuff repair provides initial strong fixation strength and minimization of gap formation during the process of the tendon incorporating into the bone.

Arthroscopic rotator cuff repair may be done with single- or double-row (SR or DR) repair techniques. SR construct is traditionally repaired with anchors placed in a linear manner from anterior to posterior on the greater tuberosity that offers excellent clinical results [Figure 1]. DR rotator cuff repair techniques incorporate a medial and lateral row of suture anchors in the repair configuration.[4]

One possible explanation for the high rate of repair site failure is that the SR technique does not completely recreate the native footprint insertion of the tendon onto the greater tuberosity, leading to incomplete anatomical healing [Figure 2].[5]

Access this article online

www.ijss-sn.com

Month of Submission : 02-2021
Month of Peer Review : 03-2021
Month of Acceptance : 03-2021
Month of Publishing : 04-2021

Corresponding Author: Pinaki Das, B 1512 Sector 6 CDA Abhinab Bidanasi, Cuttack - 753 014, Odisha, India.

The DR technique provides a greater contact area, reestablishes the footprint of rotator cuff which may contribute to developing a better environment for tendon healing. Good clinical outcomes have been reported for arthroscopic rotator cuff repair using a DR technique. Several studies have also reported anatomic or biomechanical advantages of the DR fixation technique.[6] We aim to review the history of repair techniques and current practice and to give our views on the indications and benefits for each technique.

MATERIALS AND METHODS

The proposed study is institution based, conducted at the Orthopedics Department of I.P.G.M.E.R.& S.S.K.M. Hospital, Kolkata, a tertiary health care center catering to people of West Bengal and adjacent states of East India. The study period included 20 months (from January 2019 to August 2020) with a 6-month follow-up of all the patients. The sample size included 20 patients.

Study Parameter

The results of the management of full-thickness rotator cuff injury treated with arthroscopic SR versus DR repair with suture anchor were evaluated by:

A. Time taken for complete healing of the rotator cuff injury
B. Range of movement of shoulder
C. Pain during movement of shoulder
D. Simple shoulder test (SST)

Inclusion Criteria

The following criteria were included in the study:

1. Adult age group (20–60 year)
2. Type of injury: Full-thickness rotator cuff injury
3. Fresh tear <3 weeks old
4. Patients willing to participate in the study through signing of consent form.

Exclusion Criteria

The following criteria were excluded from the study:

1. Patients with comorbid conditions not fit for surgery
2. Old age-related degenerative tears
3. Partial thickness tears
4. Rotator cuff tears with associated fractures of proximal shoulder
5. Patient unwilling to undergo surgery.

Patient's history was taken and name, age, and gender were recorded. They were evaluated regarding the pre-injury mobility status on the basis of their ability to do normal day-to-day activities such as light household activities at home, their ability to lift light weights, their ability to go shopping, and use public transport.

History of any other comorbid diseased was obtained.

Mode and time of injury were noted if any. Thorough clinical examination of the patient was done to rule out associated intra-abdominal, intrathoracic, head-and-neck injuries, or any other associated injuries. The affected limb was thoroughly examined to rule out vascular and neurological injury.

Anteroposterior and lateral view radiograph, ultrasound, and T1- and T2-weighted magnetic resonance imaging (MRI) of affected shoulder were obtained. To minimize discomfort, all shoulders were initially put in an arm pouch sling.

Before surgery, all patients were evaluated medically for hypertension, ischemic heart disease, diabetes mellitus, chronic obstructive pulmonary disease, cerebrovascular disease, and urinary tract infection to minimize any potential risk for surgery. Analgesics, antibiotics, and proper care of injury were taken.

Data Organization

Out of total 20 patients, 10 patients were randomly allocated to one group that was treated using SR rotator cuff repair, while rest 10 patients were randomly allocated to another second group treated with DR rotator cuff repair technique. Observations basing on age, sex, affected side, post-operative range of motion (ROM), SST score, and complications were recorded for each patient for both the treatment modalities.

Statistical Technique

Statistical analysis was done using SPSS software (IBM Version-20). Statistical difference between continuous variables was assessed using Student's *t*-test. Categorical variables were compared using Chi-square test. Statistical significance was set at $P = 0.05$ or less.

Surgical Technique

All surgeries were performed under interscalene brachial block and combined general anesthesia. A 25–30° wide-angle arthroscope measuring 4.5 mm in diameter was used. In shoulder arthroscopy, a traction or an articulated forearm positioning device is required.

The basic set is composed of a probe, which is used routinely; a powerful grasping forceps, preferably with serrated jaws; straight and angled 3.5 mm scissors; 3.5 mm and 5 mm punch forceps; and 90° basket forceps. Bipolar electrocoagulation and radiofrequency ensure safe

electrocoagulation in a saline environment. A pressure pump that maintains a constant pressure within the shoulder is useful for sophisticated procedures such as subacromial decompression and suture placement.

The patient was anesthetized before the final positioning on the operating table and depending on the preference of the surgeon; the patient can be positioned in lateral decubitus or in beach chair position.

Using a sterile marker, the bony landmarks and the portals needed are outlined on the skin. The first and primary entry portal in shoulder arthroscopy is the posterior portal. Using this portal, most of the joint can be examined and other accessory portals can be established.

After the introduction of the arthroscopic sleeve between the infraspinatus and teres minor interval the blunt trocar is removed, and the camera is inserted into the joint.

The anterior portal is located lateral to the halfway point between the coracoid process and the anterolateral tip of the acromion [Figure 3]. This portal is used to complete the diagnostic examination of the shoulder and to observe the posterior capsule, rotator cuff, glenohumeral ligaments, and the subscapularis tendon. The lateral portal passes through the deltoid muscle and is located 3 cm lateral to the lateral edge of the acromion. Its primary use is in the surgery of the subacromial space. After these three working portals, other accessory portals can be spread out anteriorly and posteriorly as necessary, usually using a spinal needle and under the direct visualization.

Subacromial decompression and bursectomy are performed to ensure good visualization of the sutures. The depth and type of tear are determined along with the retraction and mobility of the tendon.

The tendon footprint is prepared by abrading the site without resecting the bone. The potential location sutures are determined so as to prevent any fracture or suture crowding. The decision is taken to proceed with a SR repair or a DR repair basing on the degree and type of tear.

In SR repair [Figure 4], the anchors are placed in a linear manner from anterior to posterior on the greater tuberosity, whereas in DR repair [Figure 5], the sutures are placed in medial and lateral configuration with medial anchors 5 mm off the articular suture and lateral anchors 0.5 mm lateral to the greater tuberosity.

The lateral row is visualized and electrocautery is used to resect the soft tissue and expose the site of insertion of anchors. The sutures are passed through the anterior port and tied and snuggly fit with the repaired tendon with the help of a grasper. The excess suture is cut and the ROM of hand is checked. The skin is closed with monofilament nylon suture.

Post-operative and Follow-up Protocol

The operated shoulder was supported by an arm pouch immediately after surgery. Intravenous antibiotics were given preferably Inj. cefuroxime 1.5 g twice daily for 3 days. Post-operative analgesia protocol was maintained. For the first 24 h, all the patients received Inj. diclofenac 75 mg intramuscular 8 hourly. From 24 h onward, tablet ibuprofen 400 mg was prescribed on requirement basis. Ice compression over the operated shoulder was advised. On the 2nd post-operative day, dressing was changed taking sterile measures. Patients were discharged from hospital 3 days after surgery.

From the 1st post-operative day, pendulum exercises of shoulder were started. Patients were allowed to actively mobilize their elbow and wrist, fingers. From the 14th post-operative day onward, passive ROM exercises of the affected for flexion, abduction, and external rotation were started along with removal of stitches. Active ROM of elbow, wrist, and hand is continued. Patients were encouraged to remove sling from the 4th post-operative week and active ROM is initiated with maximum abduction up to 90 degrees. At around 12th post-operative week, isotonic exercises are allowed with light to moderate weight-bearing. Contact sports and racquet sports should be allowed after 4 months.

Sutures were removed 2 weeks after surgery. Patients were assessed with the SST and ROM was noted post-operative 2 weeks, 4 weeks, 8 weeks, and 12 weeks and thereafter every 3 months. On each visit, patients were evaluated clinically for the presence or absence of pain, any wound site complications, etc., and data recorded.

RESULTS

The mean age of patients in SR and DR groups was 40.70 ± 7.6 years and 40.0 ± 9.50 years, respectively, and did not differ significantly (P = 0.85). The number of males in DR group was as more 60% compared to that of SR 40%. Other general data were collected from the patients regarding side of injury, time from date of injury to operation, etc. [Table 1]. Both treatment groups were comparable in terms of general data preoperatively.

Test of proportion showed that 100% of the patients of both the groups had no pain on the 4th week onward (Z=14.14; $P < 0.0001$) [Table 2].

Corrected Chi-square (χ^2) test showed that there was no significant association between ROM at different time

intervals and the patients of the two groups ($P > 0.05$) [Table 3]. Thus, improvements of ROM at different time intervals of the patients of the two groups were more or less equally distributed [Table 4].

However, proportion of patients with improvements of ROM at different time intervals of the patients treated with arthroscopic DR was higher than that of the patients treated with arthroscopic SR but it was not significant ($P > 0.05$).

Corrected Chi-square ($\chi 2$) test showed that there was no significant association between SST at different time intervals and the patients of the two groups ($P > 0.05$). Thus, improvements of SST at different time intervals of the patients of the two groups were more or less equally distributed.

However, proportion of patients with improvements of SST at different time intervals of the patients treated with arthroscopic DR was higher than that of the patients treated with arthroscopic SR but it was not significant ($P > 0.05$).

Table 1: The frequency and percentage distribution of pre-operative parameters

Parameters	Single-row group		Double-row group	
	Frequency	Percentage	Frequency	Percentage
No. of patients	10	50	10	50
Sex, no. M/F	4/6	40/60	6/4	60/40
Mean±(SD) age, years	40.70±7.6		40.0±9.50	
Side, no. Left/right	4/6	40/60	4/6	40/60
Time from DOI to surgery				
<12	4	40	4	40
>12	6	60	6	60

DISCUSSION

Rotator cuff pathology can be treated by various modalities depending on symptoms, type of lesion, and patient's expectations. A surgical treatment has to be considered to

Table 2: Comparison of pain at different time intervals and the patients of the two groups

Pain	2nd week		4th week		8th week		12th week	
	Group-S (*n*=10)	Group-D (*n*=10)	Group-S (*n*=10)	Group-D (*n*=10)	Group-S (*n*=10)	Group-D (*n*=10)	Group-S (*n*=10)	Group-D (*n*=10)
Present	10	10	0	0	0	0	0	0
Row %	50.0	50.0	0.0	0.0	0.0	0.0	0.0	0.0
Col %	100.0	100.0	0.0	0.0	0.0	0.0	0.0	0.0
Absent	0	0	10	10	10	10	10	10
Row %	0.0	0.0	50.0	50.0	50.0	50.0	50.0	50.0
Col %	0.0	0.0	100.0	100.0	100.0	100.0	100.0	100.0
Total	10	10	10	10	10	10	10	10
Row %	50.0	50.0	50.0	50.0	50.0	50.0	50.0	50.0
Col %	100.0	100.0	100.0	100.0	100.0	100.0	100.0	100.0

Table 3: Comparison of range of motion at different time intervals and the patients of the two groups

Range of motion	2nd week		4th week		8th week		12th week	
	Group-S (*n*=10)	Group-D (*n*=10	Group-S (*n*=10)	Group-D (*n*=10)	Group-S (*n*=10)	Group-D (*n*=10)	Group-S (*n*=10)	Group-D (*n*=10)
0–110	1	1	0	0	0	0	1	1
Row %	50.0	50.0	0.0	0.0	0.0	0.0	50.0	50.0
Col %	10.0	10.0	0.0	0.0	0.0	0.0	10.0	10.0
0–120	4	3	0	0	0	0	4	3
Row %	57.1	42.9	0.0	0.0	0.0	0.0	57.1	42.9
Col %	40.0	30.0	0.0	0.0	0.0	0.0	40.0	30.0
0–130	2	3	0	0	0	0	2	3
Row %	40.0	60.0	0.0	0.0	0.0	0.0	40.0	60.0
Col %	20.0	30.0	0.0	0.0	0.0	0.0	20.0	30.0
0–140	0	1	0	0	0	0	0	1
Row %	0.0	100.0	0.0	0.0	0.0	0.0	0.0	100.0
Col %	0.0	10.0	0.0	0.0	0.0	0.0	0.0	10.0
Total	10	10	10	10	10	10	10	10
Row %	50.0	50.0	50.0	50.0	50.0	50.0	50.0	50.0
Col %	100.0	100.0	100.0	100.0	100.0	100.0	100.0	100.0
Chi-square ($\chi 2$)	3.14		5.46		4.33		3.67	
p-value	0.67 NS		0.36 NS		0.63 NS		0.59 NS	

Table 4: Comparison of SST at different time intervals and the patients of the two groups

SST	2nd week		4th week		8th week		12th week	
	Group-S (*n* = 10)	Group-D (*n* = 10)	Group-S (*n* = 10)	Group-D (*n* = 10)	Group-S (*n* = 10)	Group-D (*n* = 10)	Group-S (*n* = 10)	Group-D (*n* = 10)
2/12	1	1	0	0	0	0	0	0
Row %	50.0	50.0	0.0	0.0	0.0	0.0	0.0	0.0
Col %	10.0	10.0	0.0	0.0	0.0	0.0	0.0	0.0
3/12	2	2	0	0	0	0	0	0
Row %	50.0	50.0	0.0	0.0	0.0	0.0	0.0	0.0
Col %	20.0	20.0	0.0	0.0	0.0	0.0	0.0	0.0
4/12	4	3	3	2	0	1	0	0
Row %	57.1	42.9	60.0	40.0	0.0	100.0	0.0	0.0
Col %	40.0	30.0	30.0	20.0	0.0	10.0	0.0	0.0
5/12	3	3	0	0	3	1	0	2
Row %	50.0	50.0	0.0	0.0	75.0	25.0	0.0	100.0
Col %	30.0	30.0	0.0	0.0	30.0	10.0	0.0	20.0
6/12	0	1	3	1	0	0	3	0
Row %	0.0	100.0	75.0	25.0	0.0	0.0	100.0	0.0
Col %	0.0	10.0	30.0	10.0	0.0	0.0	30.0	0.0
7/12	0	0	4	7	0	0	0	0
Row %	0.0	0.0	36.4	63.6	0.0	0.0	0.0	0.0
Col %	0.0	0.0	40.0	70.0	0.0	0.0	0.0	0.0
8/12	0	0	0	0	2	3	0	0
Row %	0.0	0.0	0.0	0.0	40.0	60.0	0.0	0.0
Col %	0.0	0.0	0.0	0.0	20.0	30.0	0.0	0.0
9/12	0	0	0	0	3	4	0	0
Row %	0.0	0.0	0.0	0.0	42.9	57.1	0.0	0.0
Col %	0.0	0.0	0.0	0.0	30.0	40.0	0.0	0.0
10/12	0	0	0	0	2	1	1	1
Row %	0.0	0.0	0.0	0.0	66.7	33.3	50.0	50.0
Col %	0.0	0.0	0.0	0.0	20.0	10.0	10.0	10.0
11/12	0	0	0	0	0	0	3	4
Row %	0.0	0.0	0.0	0.0	0.0	0.0	42.9	57.1
Col %	0.0	0.0	0.0	0.0	0.0	0.0	30.0	40.0
12/12	0	0	0	0	0	0	3	3
Row %	0.0	0.0	0.0	0.0	0.0	0.0	50.0	50.0
Col %	0.0	0.0	0.0	0.0	0.0	0.0	30.0	30.0
Total	10	10	10	10	10	10	10	10
Row %	50.0	50.0	50.0	50.0	50.0	50.0	50.0	50.0
Col %	100.0	100.0	100.0	100.0	100.0	100.0	100.0	100.0
Chi-square ($\chi 2$)	1.14		2.01		2.67		5.14	
P-value	0.88 NS		0.36 NS		0.61 NS		0.27 NS	

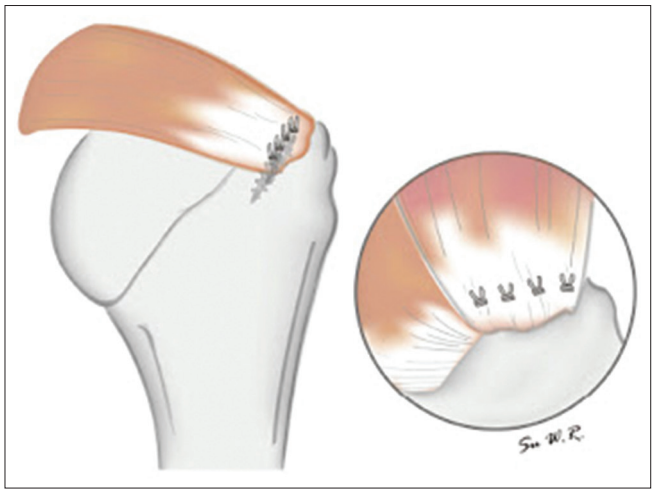

Figure 1: Single-row repair

Figure 2: Double-row repair

improve pain and function in full-thickness rotator cuff tears because of tendon retraction and a difficult biological environment (poor tendon vascularity, interference from synovial fluid, and reduced cellularity). Arthroscopic rotator cuff repair is the gold standard treatment for full-thickness rotator cuff repair. It may be done with SR or DR repair techniques. SR constructs is traditionally repaired with anchors placed in a linear manner from

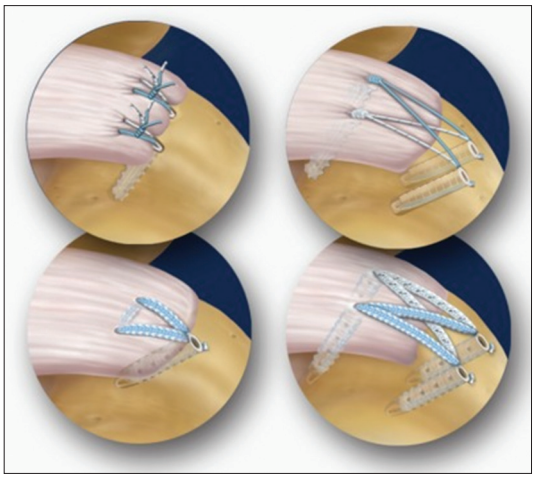

Figure 3: Major arthroscopic portals

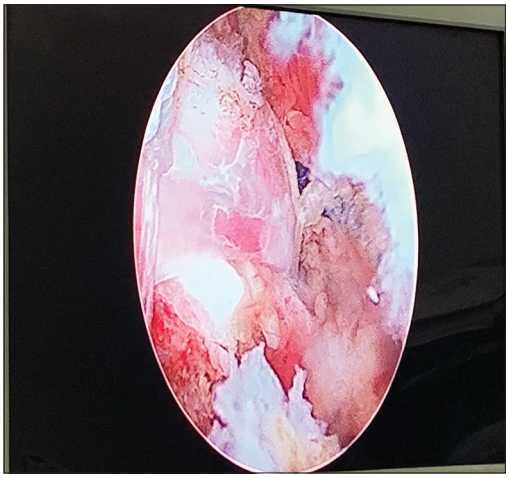

Figure 4: Single-row construct

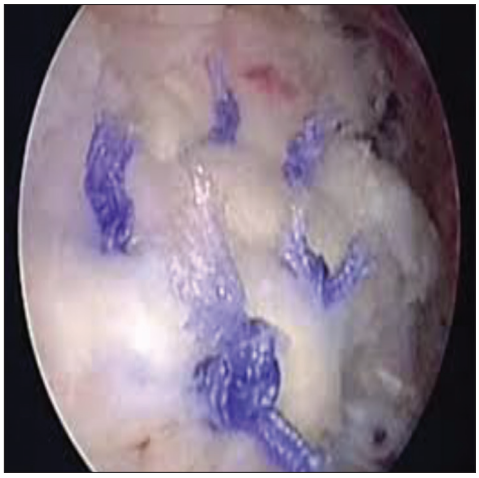

Figure 5: Double-row construct

anterior to posterior on the greater tuberosity, offer excellent clinical results. DR rotator cuff repair techniques incorporate a medial and lateral row of suture anchors in the repair configuration.

Reruptures, suture anchor loosening leading to implant failure impair the functional outcome, cause stiffness and lead to decreased patient satisfaction. To improve the coverage area of the insertional footprint of the rotator cuff and decrease the chances of a rupture, the DR technique was introduced. The principal aim of a DR repair is to recreate the "anatomic footprint" that is thought to promote healing and recovery of function. Biomechanical studies have suggested that a DR repair results in a greater contact area of tendon to tuberosity, decreased gap formation, and an increased load to failure and cyclic load to failure.

Tudisco *et al.* conducted a retrospective, *in vivo* study in which they used 3-Tesla MRI to analyze rerupture rates after rotator cuff repair. The rerupture rate in the SR group was 60%, while in the DR group, it was 25%.[7] Even in the face of all these factors, which have demonstrated the laboratory and *in vivo* superiority of DR, many studies have failed to demonstrate a difference in the scores obtained in the standardized scales for the clinical evaluation of patients.

In another systematic review of the literature, Saradakis and Jones concluded that despite the lack of statistical differences when comparing all SR with DR results, a statistical difference was observed when only injuries larger than 3.0 cm were taken into account.[8,9] Full-thickness tears were more likely to progress than partial-thickness tears (52% vs. 8%). Age was an important predictor of tear deterioration with 54% of tears in patients over 60 progressing versus only 17% of tears in patients under 60 years.[10] Keeping these principle and ideas in our mind, we conducted a study in our institute comparing the results and functional outcomes of arthroscopic SR versus DR repair with suture anchor of full-thickness rotator cuff injury of shoulder in adults of age group 20–60 years.

CONCLUSION

This study compared the clinical and functional outcomes of the SR versus DR arthroscopic repair techniques. Using a DR repair, technique is theoretically superior to the SR repair technique achieving better healing and functional outcomes as reported by biomechanical studies. Our study also reveals the clinical outcomes of SR and DR repair to be almost identical.

ACKNOWLEDGMENT

We would like to acknowledge both our Associate Professors, Department of Orthopedics, Dr. Dibyendu

Biswas, Dr. Arnab Karmakar and all the faculty members who helped relentlessly in conducting our research work.

REFERENCES

1. Azar F, Canale ST, Beaty J. Campbell's Operative Orthopaedics. 13th ed. Amsterdam: Elsevier; 2016. p. 2311.
2. Blom A, Warwick D, Whitehouse M. The shoulder and pectoral girdle. In: Apley and Solomon's System of Orthopaedics and Trauma. 10th ed., Ch. 13. CRC Press Taylor, Francis Group; 2018. p. 362.
3. Matthewson G, Beach CJ, Nelson AA, Woodmass JM, Ono Y, Boorman RS, *et al*. Partial thickness rotator cuff tears: Current concepts. Adv Orthop 2015;2015:458786.
4. Pietschmann MF, Fröhlich V, Ficklscherer A, Hausdorf J, Utzschneider S, Jansson V, *et al*. Pullout strength of suture anchors in comparison with transosseous sutures for rotator cuff repair. Knee Surg Sports Traumatol Arthrosc 2008;16:504-10.
5. Yi JW, Cho NS, Cho SH, Rhee YG. Arthroscopic suture bridge repair technique for full thickness rotator cuff tear. Clin Orthop Surg 2010;2:105-11.
6. Randelli P, Cucchi D, Ragone V, de Girolamo L, Cabitza P, Randelli M. History of rotator cuff surgery. Knee Surg Sports Traumatol Arthrosc 2015;23:344-62.
7. Senna LF, Ramos MR, Bergamaschi RF. Arthroscopic rotator cuff repair: Single-row vs. double-row-clinical results after one to four years. Rev Bras Ortop 2018;53:448-53.
8. Saridakis P, Jones G. Outcomes of single-row and double-row arthroscopic rotator cuff repair: A systematic review. J Bone Joint Surg Am 2010;92:732-42.
9. Arthroscopic Basic to Advance. Ch. 43. Rotator Cuff Tear: Europe Springer Nature; 2016. p. 552-3.
10. Keener JD, Hsu JE, Steger-May K, Teefey SA, Chamberlain AM, Yamaguchi K. Patterns of tear progression for asymptomatic degenerative rotator cuff tears. J Shoulder Elbow Surg 2015;24:1845-51.

How to cite this article: Datta T, Das P, Khan MS, Sinharoy D. Comparative Evaluation of Results of Arthroscopic Single-row versus Double-row Repair in Full-thickness Rotator Cuff Tear in Adults. Int J Sci Stud 2021;9(1):114-120.

Source of Support: Nil, **Conflicts of Interest:** None declared.

Print ISSN: 2321-6379
Online ISSN: 2321-595X

Original Article

Evaluation of the Histology of Carious Human Primary Incisor after Treatment with 38% Silver Diamine Fluoride

Sanket Kunte[1], Chaitanya Gholap[2], Priya Deo[3], Chetana Jagtap[4], Sneha Desai[4], Laxmi Lakade[5]

[1]Professor, Department of Paediatric and Preventive Dentistry, Bharati Vidyapeeth Dental College and Hospital, Pune, Maharashtra, India, [2]Post Graduate Student, Department of Paediatric and Preventive Dentistry, Bharati Vidyapeeth Dental College and Hospital, Pune, Maharashtra, India, [3]Assistant Professor, Department of Oral Pathology and Microbiology, Bharati Vidyapeeth Dental College and Hospital, Pune, Maharashtra, India, [4]Assistant Professor, Department of Paediatric and Preventive Dentistry, Bharati Vidyapeeth Dental College and Hospital, Pune, Maharashtra, India, [5]Associate Professor, Department of Paediatric and Preventive Dentistry, Bharati Vidyapeeth Dental College and Hospital, Pune, Maharashtra, India

Abstract

Aim: The aim of the present study is to evaluate the histologic characteristics of carious human primary incisor after treatment with 38% silver diamine fluoride (SDF).

Objectives: The objectives of the study were as follows: (1) To evaluate the tertiary dentin formation after treatment with 38% SDF and (2) to evaluate the silver deposition in the dentinal tubules after treatment with 38% SDF.

Materials and Methods: As the study was an observational study and there was no comparative group present, we just observed the histologic changes that took place on the carious tooth surface with a sample size of 20. After the 38% SDF application on the carious tooth surface, they were decalcified with 10% nitric acid and subsequently stained with hematoxylin and eosin and observed under the light microscope.

Results: On histological examination, there was no pulp exposure seen. Tertiary dentin formation and silver deposition were noted in the dentinal tubules up to a depth of 1.2–1.5 μm.

Conclusion: The findings concluded that 38% SDF was advantageous in comprehensive and pre cooperative children.

Key words: 10% nitric acid, 38% silver diamine fluoride, Light microscope, Primary incisor

INTRODUCTION

Silver nitrate appears to be the first silver compound that was used to arrest dental caries without significantly affecting the dental pulp. The use of silver diamine fluoride (SDF) for the arrest of caries lesions, prevention of dental sensitivity, and prevention of the development of additional carious lesions is increasing in popularity during the past few years. SDF effect on the progression of dental caries is based on the fact that it combines the benefits of fluoride and silver; fluoride promotes remineralization and silver has an antimicrobial action.[1]

Access this article online

www.ijss-sn.com

Month of Submission : 02-2021
Month of Peer Review : 03-2021
Month of Acceptance : 03-2021
Month of Publishing : 04-2021

First documented usage of silver compounds in dentistry was reported by Stebbins in 1891, when he described the arrest of carious dental lesions by the application of silver nitrate. Silver was used in dentistry as early as the 1840s in the form of "nitrate of silver" (known as silver nitrate, $AgNO_3$). Percy Howe, then Director of the Forsyth Institute in Boston, added ammonia to silver nitrate making it more stable and effective as an antimicrobial for application to any infected tooth structure.[2]

In the past, several chemical and therapeutic agents have been used to arrest the caries formation. Many of the proposed remineralizing agents in the past are unable

Corresponding Author: Dr. Chaitanya Gholap, Department of Paediatric and Preventive Dentistry, Bharati Vidyapeeth Dental College and Hospital, Pune, Maharashtra, India.

to arrest the caries and new dentin formation. However, very few studies have claimed the caries arresting efficacy of 38% SDF. Hence, the aim of the present study is to observe the histologic changes taking place on the caries during the treatment with 38% SDF. The two main components, fluoride and silver, are made soluble in water by the addition of ammonia. While metallic silver is inert, silver ions are broad-spectrum antimicrobial with high biocompatibility and low toxicity in humans. These act as tiny "silver bullets" that damage and degrade bacterial cell walls, disrupt bacterial DNA synthesis and replication, and disrupt intracellular metabolic activity, eventually leading to cell death.[1] The only disadvantage of the use of SDF is that it stains the treated lesion black.[2,3]

MATERIALS AND METHODS

A total of 20 pediatric patients between the age group of 6 and 9 years were selected for the study, with primary incisors having bilateral caries extending up to enamel/enamel and dentin on both the mesial and distal surfaces of the teeth.

A periapical radiograph of the tooth was taken to reveal the caries extent, tooth mobility, and periapical pathology of the tooth if present. Teeth with bilateral caries extending up to enamel/enamel and dentin, with Grade I or Grade II mobility, and without any pain and periapical pathology were selected [Figure 1].

Histological Evaluation of the Mesial Surface of the Teeth

The mesial surface of the teeth was treated with the application of 38% SDF with the purpose to arrest caries with a monthly follow-up for 6 months [Figure 2]. The teeth were judged at every monthly follow-up for its mobility and any other pain or periapical pathology. The teeth when attained a Grade III mobility were indicated for extraction with due consent of the patient. The teeth were then decalcified with 10% nitric acid. The decalcified tissues of the teeth were further tissue processed with the aim to remove water from tissues and replace with a medium that solidifies to allow thin sections to be cut.[4] First, the process of fixation was carried out, in which the specimen was placed in a liquid fixing agent (fixative), that is, 10% formalin which will slowly penetrate the tissue causing chemical and physical changes that will harden and preserve the tissue and protect it against subsequent processing steps.[5] This was followed by the routine steps of tissue processing. After paraffin embedding, 4–6 μm sections were cut on the microscopic slides and were stained with hematoxylin and eosin stain and then examined under light microscope.

Figure 1: Clinical picture of teeth with bilateral caries involving enamel and dentin

Safety Parameters Taken into Consideration

The study was being carried out under complete ethical considerations and clearance. The patients were asked to report as soon as possible if the tooth exfoliates physiologically before the span of 6 months and preserve it in a biocompatible material like their own saliva or milk available at home/store, until getting it to the hospital. They were kept under a monthly follow-up for 6 months and if any adverse event takes place before time, they were asked to report as soon as possible to the hospital for the same. They were priorly informed about the only disadvantage of the study that the material used in the study stains the treated lesion black. The study was carried out in an age group which is subjected to physiological exfoliation of teeth and therefore there was no such potential risk to the patient. The patients were provided with the written explanation of the study and an informed consent was taken. Anonymization of the patient data was strictly followed during the study.

RESULTS

The results after histologic examination showed evidence of tertiary dentin formation with no pulp exposure and inflammation. (1) A slight faded layer of irregular tertiary dentin was seen adjacent to the flattened odontoblastic layer [Figure 3]. (2) Silver deposition was noted to a depth of 1.2–1.5 mm in the dentinal tubules [Figure 4].

Figure 2: Application of 38% SDF under cotton roll isolation

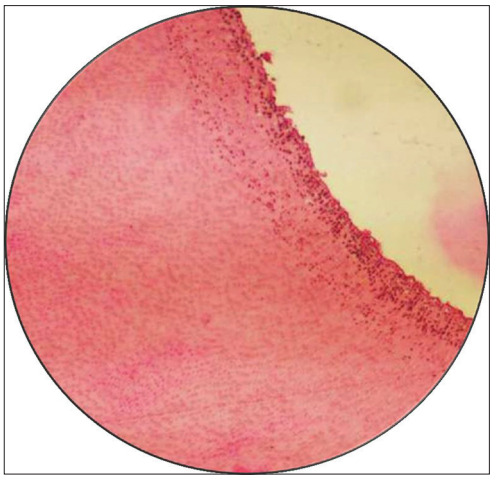

Figure 3: Low-power view demonstrating irregular tertiary dentin formation with minimal inflammation of the adjacent dental pulp (haematoxylin and eosin stain, original magnification 10×)

Figure 4: Medium-power view of dentinal tubules demonstrating black discoloration secondary to silver deposition (haematoxylin and eosin stain, original magnification 40×)

DISCUSSION

First research on SDF was conducted in 1969 at Osaka University in Japan. The powerful antimicrobial properties of silver with the benefits of a high dose of fluoride were combined and this formulation also resulted in a precipitate that occluded dentinal tubules and reduced the hypersensitivity.[6] This compound, AgF (NH3), is commonly misspelled or misinterpreted as SDF, however, the correct terminology is SDF as it contains two ammine groups (NH3), not two amine groups (NH2). The use of the term "diamine" became wide in use and has become the accepted form both in the scientific and marketing literature.[1]

Based on many studies all over world, a concentration of 38% SDF was found to be superior at arresting caries compared to lower concentrations of 10% or 12%. Stebbins successfully reported the usage of silver nitrate for arresting dental caries and reported a success (87 out of total 142 treated lesions were arrested) over 3-year period.[7] There have been various studies done previously on the microbial, histologic, and inhibition of demineralizing effects of SDF and silver fluoride on bovine enamel blocks, extracted human teeth with no caries, atraumatic technique using SDF followed with glass ionomer and non-carious dentin blocks, but not in extracted human carious teeth.[8-10]

A similar study was done by Enrique Bimstein and Douglas Damm in 2018, to describe the histological characteristics of a primary tooth with a 6-month follow-up after being treated with SDF.[11] They reported no carious pulp exposure tertiary dentin, a flattened odontoblastic layer adjacent to irregular tertiary dentin, dentinal tubules with silver deposits to a depth of 1 mm, and no bacteria. Kulnipa, Thanida, and Thansinee in 2017 did a study to investigate the remineralizing effect of 38% SDF and 1000 ppm fluoride toothpaste, where they concluded that 38% SDF enhances remineralization based on mineral density and depth compared to 1000 ppm fluoride toothpaste alone.[12] This study shows that SDF not only has an effect in arresting caries but also a remineralizing effect on the tooth.

There was a study done by Fung *et al.* in 2018, where they compared the effectiveness of two concentrations (12% or 38%) of SDF on a 30-month randomized clinical trial. They concluded that SDF at a concentration of 38% is more effective than that of 12% in arresting active caries in primary teeth and the application of 38% SDF semi-annually alone is more effective than that of 12% in arresting caries in primary teeth.[13] The results of this study are quite similar to our study and evidently shows the effect of 38% SDF applied over a period of 6 months, which is the concentration used in our study.

Since the presence of bacteria inside the dental tubules adjacent to deep caries is normal, it was unique that in the present study, the teeth showed no bacteria inside the dentinal tubules adjacent to the deep caries lesion, this being most likely the result of the antibacterial properties of SDF that include the "zombies effect:" When bacteria killed by silver ions are added to living bacteria, the silver kills the living bacteria.[14] It is also outstanding that despite the deep carious cavity minimal to none, signs of pulp inflammation were evident suggesting that the caries arrest, remineralization, and formation of tertiary dentin under the SDF may lead to pulp healing of reversible pulpitis.

CONCLUSION

The use of SDF to arrest deep caries in children until comprehensive treatment is available, leads to the

formation of the tertiary dentin and penetration of the silver ions in the dentinal tubules causing destruction of the bacteria. The use of this material will also be beneficial in reducing the morbidity and mortality rate in children due to pharmacological techniques of behavior management who are in still in their cognitive stage of development.

SDF is getting popularity for medical management of dental caries, but still there is a question on its parental acceptability on staining of the tooth. Further, research is needed to have a broader understanding of these values and of the decision-making factors related to parental acceptability of SDF.[15]

REFERENCES

1. Marwah N. Textbook of Pediatric Dentistry. Silver Diamine Fluoride. 4th ed. New Delhi: Jaypee Brothers; 2019. p. 1014-8.
2. Chu CH, Gao SS, Li SK, Wong MC, Lo EC. The effectiveness of the biannual application of silver nitrate solution followed by sodium fluoride varnish in arresting early childhood caries in preschool children: Study protocol for a randomised controlled trial. Trials 2015;25:426.
3. Shah S, Bhaskar V, Venkatraghan K, Choudary P, Ganesh M, Trivedi K. Silver diamine fluoride: A review and current applications. J Adv Oral Res 2014;5:25-35.
4. Rolls G. An Introduction to Specimen Processing; 2019.
5. Hopwood D. Fixation and fixatives. In: Bancroft J, Stevens A, editors. Theory and Practice of Histological Techniques. New York: Churchill Livingstone; 1996.
6. Russell AD, Hugo WB. Antimicrobiological activity and action of silver. Prog Med Chem 1994;31:351-70.
7. Stebbins EA. What value has argenti nitras as a therapeutic agent in dentistry? Int Dent J 1891;12:661-70.
8. Nelson T, Scott JA, Crystal YO, Berg JH, Milgrom P. Silver diamine fluoride in pediatric dentistry training programs: Survey of graduate program directors. Pediatr Dent 2016;38:212-7.
9. Horst JA, Ellnikiotis H, Milgrom P. UCSF protocol for caries arrest using silver diamine fluoride: Rationale, indications, and consent. J Calif Dent Assoc 2016;44:16-28.
10. Knight GM, McIntyre JM, Craig GG, Mulyani, Zilm PS, Gully NJ. Differences between normal and demineralized dentine pretreated with silver fluoride and potassium iodide after an *in vitro* challenge by *Streptococcus mutans*. Aust Dent J 2007;52:16-21.
11. Bimstein E, Damm D. Human primary tooth histology six months after treatment with silver diamine fluoride. J Clin Pediatr Dent 2018;42:442-4.
12. Punyanirun K, Yospiboonwong T, Kunapinun T, Thanyasrisung P, Trairatvorakul C. Silver diamine fluoride remineralized artificial incipient caries in permanent teeth after bacterial pH-cycling *in vitro*. J Dent 2017;69:55-9.
13. Fung MH, Duangthip D, Wong MC, Lo EC, Chu CH. Randomized clinical trial of 12% and 38% silver diamine fluoride treatment. J Dent Res 2018;97:171-8.
14. Wakshlak RB, Pedahzur R, Avnir D. Antibacterial activity of silver-killed bacteria: The "zombies" effect. Sci Rep 2015;5:9555.
15. Gordon NB. Silver diamine fluoride staining is acceptable for posterior primary teeth and is preferred over advanced pharmacologic behavior management by many parents. J Evid Based Dent Pract 2018;18:94-7.

How to cite this article: Kunte S, Gholap C, Deo P, Jagtap C, Desai S, Lakade L. Evaluation of the Histology of Carious Human Primary Incisor after Treatment with 38% Silver Diamine Fluoride. Int J Sci Stud 2021;9(1):121-124.

Source of Support: Nil, **Conflicts of Interest:** None declared.

Print ISSN: 2321-6379
Online ISSN: 2321-595X

Original Article

Comparative Evaluation of Antifungal Efficacy of Irreversible Hydrocolloid Incorporated with Silver Zeolite and Copper Oxide Nanoparticles

M. Harikrishna[1], T. Satyendra Kumar[2], Y. Ravi Shankar[3], K. Bhargavi[4], P. Naseemoon[4]

[1]Associate Professor, Department of Prosthodontics, GITAM Dental College and Hospital, Visakhapatnam, Andhra Pradesh, India, [2]Reader, Department Of Prosthodontics, Gitam Dental College and Hospital, Visakhapatnam, Andhra Pradesh, India, [3]Vice Principal, Professor and Head, Department of Prosthodontics, Gitam Dental College and Hospital, Visakhapatnam, Andhra Pradesh, India, [4]Post Graduate Student, Department of Prosthodontics, Gitam Dental College and Hospital, Visakhapatnam, Andhra Pradesh, India

Abstract

Aim: The purpose of this study is to compare and evaluate the antifungal efficacy of two commercially available irreversible hydrocolloids incorporated with silver zeolite and copper oxide nanoparticles.

Statement of Problem: Conventional method of disinfection led to some adverse changes in dimensional properties in various alginate studies.

Objectives: The objectives of the study were as follows: • To prove the antifungal efficacy of irreversible hydrocolloids incorporated with silver zeolite nanoparticles. • To prove the antifungal efficacy of irreversible hydrocolloids incorporated with copper oxide nanoparticles. • To compare the antifungal efficacy of irreversible hydrocolloid incorporated with silver zeolite and copper oxide nanoparticles.

Materials and Methods: Two commercially available irreversible hydrocolloids were incorporated with 2.5%, 5%, and 7.5% concentrations of silver zeolite and copper oxide and antifungal efficacy is evaluable by measuring the zone of inhibition which is measured in millimeters.

Results: Addition of different types of nanoparticles in different concentrations to the commercially available irreversible hydrocolloid impression materials increased the antifungal activity significantly.

Conclusion: Alginate with silver zeolite (7.5%) showed highest antifungal efficacy compared to alginate with copper oxide.

Key words: Antifungal efficacy, Copper oxide nanoparticles, Impression material, Silver zeolite nanoparticles, Zone of inhibition

INTRODUCTION

The study of biomaterials and its properties is of immense interest in the field of research and innovative technology. One of the most widely accepted materials used in dentistry is hydrocolloid alginate impression due to its several advantages over the others. Impression material has been one of the many biomaterials that have captured the attention of many researchers. Dental impressions have a prime role in treating the patient for prosthodontic purpose. These impressions inevitably come into contact with the patient's saliva, blood, and bacterial plaque, all of which may carry pathogenic microorganisms. Contamination of impressions is major source for the transmission of diseases from patients to the dentist/dental auxiliaries.[1-7]

Therefore, disinfecting the impressions effectively before transportation to the dental laboratory becomes indispensable. Initially, sterilization of impressions is the ideal way to avoid disease transmission, disinfection is routinely practiced. This practice is justified in view of dimensional changes that occur in the impressions due to sterilization.[7-10]

Access this article online

www.ijss-sn.com

Month of Submission : 02-2021
Month of Peer Review : 03-2021
Month of Acceptance : 03-2021
Month of Publishing : 04-2021

Corresponding Author: M. Harikrishna, Department of Prosthodontics, GITAM Dental College and Hospital, Visakhapatnam, Andhra Pradesh, India.

Various disinfectants such as sodium hypochlorite, sodium metabisulfite, biguanides, iodine compounds (such as iodophors), quaternary ammonium salts, phenolic, and glutaraldehyde are used routinely. However, no single disinfectant can be selected as a universal disinfectant for all impressions, it is imperative to select a disinfectant with superior antifungal activity that does not affect recorded details. Despite the importance of disinfection of impressions, some investigations indicate that such disinfection is not regularly practiced.

Alginate is the routinely used impression material in clinical practice for recording preliminary impressions which is a major source for the transmission of diseases from patient to dentist/laboratory personnel. During impression recording, the surface texture and hydrophilic nature of irreversible hydrocolloid impression material allows it to retain the maximum amount of microbial pathogens not only on the surface but also with in the material.[11-14]

Clinical Implications

Addition of different types of nanoparticles such as silver zeolite and copper oxide will impart significant anti-activity to the impression materials without significantly affecting their properties.

Conventional immersion or spray disinfection of such materials might be avoided.

In general, these irreversible hydrocolloids are disinfected either by spray or an immersion technique using a disinfectant solution. However, both the techniques disinfect the impression only on the surface. Further, these processes may result in significant dimensional changes in the irreversible hydrocolloid impression material, leading to loss of detail. Deterioration in the surface quality and hardness of gypsum casts obtained from disinfected irreversible hydrocolloid impression materials has also been widely reported.

Hence, the duration of disinfection should be short to avoid significant dimensional changes. However, such a reduction in immersion time may significantly reduce the efficacy of disinfection, especially for a porous irreversible hydrocolloid impression material.

Self-disinfectant irreversible hydrocolloids have been developed by adding disinfectant to the irreversible hydrocolloid compositions to compensate the drawbacks associated with conventional disinfection.

The purpose of this *in vitro* study was to evaluate the antifungal activity of two commercially available irreversible hydrocolloid impression materials modified with the incorporation of silver zeolite and copper oxide nanoparticles.[15-19]

MATERIALS AND METHODS

Two commercially available irreversible hydrocolloid impression materials used in the study are Zelgan Plus and Tropicalgin. Medical grade commercially available silver zeolite and copper oxide nanoparticles was used. Varying concentrations (2.5, 5%, and 7.5%) of nanoparticles of 80–100 nm in size were added to the irreversible hydrocolloid impression materials and their antifungal properties were evaluated. *Candida albicans* ATCC 24433 were obtained from the culture collection and incubated at 37°C for 24 h. The lawn cultures of these microorganism were made with a bacterial or yeast suspension matching the turbidity of a 0.5 McFarland standard. To test the antimicrobial activity, Mueller-Hinton agar plates were incorporated with 2% glucose. After 24 h, antimicrobial activity was evaluated by measuring the zones of inhibition in millimeters (mm).

Antifungal Testing

Antimicrobial activity was assessed using the Kirby–Bauer diffusion method ($n = 3$). Concentrations of 2.5%, 5%, and 7.5% of silver zeolite and copper oxide were incorporated into alginate powder and mixed thoroughly, then water was added following manufacturer's instructions to form a smooth, homogenous mix. A poly(vinyl chloride) pipe of 3 mm diameter was taken and filled with the mix. After setting, alginate material is retrieved from the pipe, discs of 3 mm in thickness were sliced from the alginate with a sterile scalpel, placed on Mueller-Hinton agar plates containing the lawn cultures of *C. albicans*. The Petri plates containing these discs were incubated for 24 h at 37°C. After 24 h, zone of inhibition (MID) is measured from the midpoint of the sample to the border of the diameter of the sample in millimeters [Figure 1].

RESULTS

The results obtained show the antifungal activity of irreversible hydrocolloids against the selected microorganism *C. albicans*. The silver zeolite and copper oxide incorporated irreversible hydrocolloids exhibited dose-dependent antifungal activity. The mean diameter of the zone of inhibition against the tested microorganisms observed with the control and irreversible hydrocolloids incorporated with silver zeolite and copper oxide nanoparticles are presented in Table 1. The control specimens of Zelgan did exhibit a very minimal anticandidal activity but it is not significant. In contrast, Tropicalgin exhibited some activity against *C. albicans*. The anticandidal activity of irreversible hydrocolloids against *C. albicans* increased significantly with the incorporation of silver zeolite and copper oxide



Figure 1: Alginate discs showing zone of inhibition

Table 1: Antimicrobial activity, mean diameter values, of irreversible hydrocolloids incorporated with silver zeolite and copper oxide nanoparticles (average mean diameter)

Concentration	Zelgan		Tropicalgin	
Control	Silver zeolite	Copper oxide	Silver zeolite	Copper oxide
2.5 wt%	11.4	10.2	11.4	8.3
5 wt%	13.9	14.5	14.6	9.8
7.5 wt%	20	19.5	19.6	14.8

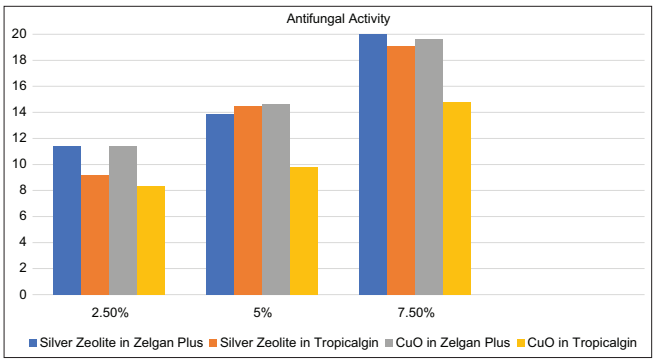

nanoparticles ($P < 0.001$). Furthermore, a significant interaction between the concentration of silver zeolite and copper oxide nanoparticles in the irreversible hydrocolloids and zone of inhibition was found with 2-way ANOVA, indicating that increasing concentrations of silver zeolite and copper oxide nanoparticles significantly increased the antimicrobial activity of both Zelgan ($P = 0.003$) and Tropicalgin ($P < 0.001$). 2.5wt%, 5wt%, and 7.5wt% silver zeolite in Zelgan showed the mean diameter of 11.4, 13.9, 20.2.5,5 and in Tropicalgin showed 11.4, 14.6, and 19.6 mean diameter. 2.5, 5, and 7.5wt% of copper oxide in Zelgan showed 10.2, 14.5, and 19.5 mean diameter and in Tropicalgin showed 8.3, 9.3, and 14.8.

In Zelgan Plus, silver zeolite has more antimicrobial efficacy than copper oxide. In Tropicalgin, silver zeolite has more antimicrobial efficacy than copper oxide. Therefore, 7.5 wt % silver zeolite shows more zone of inhibition in Zelgan Plus and Tropicalgin compared to copper oxide.

DISCUSSION

Disinfection of impressions is of utmost importance in breaking the barrier system of transmission of infectious diseases from dental clinics to the laboratory. Conventional disinfection of impressions using spray or immersion technique has shown to be an effective means against the cross-infection. Hence, surface disinfection cannot disinfect the alginate adequately. In addition, dimensional changes associated with surface disinfection advocate for better alternative disinfection methods.

Conventional alginate without incorporation of any antifungal agents exhibits a very minute inherent anticandidal activity due to its composition. Hence, various antimicrobial agents have been incorporated into alginate composition with an aim to self-disinfect the alginate without the need for spray or immersion disinfection. The association of antifungal agents such as chlorhexidine gluconate, nystatin, and fluconazole did not yield best results.[20-22]

Among the other antimicrobial agents, increased attention is being directed at nanoparticles. Nanoparticles being inert do not alter dimensional and mechanical properties of impression material. Colloidal solution of silver has been used previously with superior antimicrobial activity against oral microorganisms but silver when used in combination showed decreased cytotoxic activity. As using silver in combination is advantageous, silver zeolite nanoparticles are preferred for the present study.

Denture stomatitis is most common opportunistic infection in edentulous patients due to decreased immunity. It is caused by *C. albicans*. Hence, antifungals used in the study were tested against *C. albicans*. Silver zeolite is an alkaline or alkaline earth metal ion complexed with crystal aluminosilicate is partially replaced with silver ion by the ion exchange method. Since these antimicrobial composites are being believed to have low toxicity for humans and the activity of the antimicrobial compound is durable, it is extensively used. Silver ion strongly interacts with the ceramics matrix and is minimally released from the matrix in deionized water. Two mechanisms are proposed for the bacterial action of silver zeolite. One is the action of silver ion itself released from zeolite and the other is that of reactive oxygen species generated from silver in the matrix. While oxygen has been reported to be necessary for the

bactericidal activity of silver zeolite by some researchers, silver zeolite has also been reported to be effective on oral bacteria under anaerobic conditions by other investigators.

Silver zeolite has shown significant antimicrobial activity in various medical applications and also when incorporated into dental materials and CuO-NP has been used as antimicrobial agents in various investigations. CuO-NP has shown significant antimicrobial activity against a variety of oral microorganisms such as *Streptococcus mutans*, *Prevotella intermedia*, and *Porphyromonas gingivalis*. CuO-NP has been used in toothpastes and also as additives in dental biomaterials to impart antimicrobial activity.[23-25]

In the present study, addition of silver zeolite and CuO-NP to alginates was found to increase the antifungal activity against *C. albicans*. The observed antifungal activity was dependent on the candidal strain, alginate material, as well as on the concentration of nanoparticles.

The antifungal activity of silver zeolite and CuO-NP, like most metal based nanoparticles, can be attributed to their ability for the disruption of microbial cell membrane along with damaging the DNA or inhibiting its replication. It is also possible that zinc ions interfere with the bacterial enzymes, thereby exhibiting the antimicrobial activity.

CONCLUSION

Within the limitations of the present *in vitro* study, it can be concluded that the incorporation of silver-based nanoparticles such as silver zeolite and copper oxide nanoparticles imparted significant antifungal activity to the irreversible hydrocolloid impression materials tested. Therefore, 7.5wt% silver zeolite showed significant antifungal property.

REFERENCES

1. Jennings KJ, Samaranayake LP. The persistence of microorganisms on impression materials following disinfection. Int J Prosthodont 1991;4:382-7.
2. Samaranayake LP, Hunjan M, Jennings KJ. Carriage of oral flora on irreversible hydrocolloid and elastomeric impression materials. J Prosthet Dent 1991;65:244-9.
3. Leung RL, Schonfeld SE. Gypsum casts as a potential source of microbial cross contamination. J Prosthet Dent 1983;49:210-1.
4. Cottone JA, Young JM, Dinyarian P. Disinfection/sterilization protocols recommended by manufacturers of impression materials. Int J Prosthodont 1990;3:379-83.
5. Infection control recommendations for the dental office and the dental laboratory. ADA council on scientific affairs and ADA council on dental practice. J Am Dent Assoc 1996;127:672-80.
6. Yüzbasioglu E, Saraç D, Canbaz S, Saraç YS, Cengiz S. A survey of cross infection control procedures: Knowledge and attitudes of Turkish dentists. J App Oral Sci 2009;17:565-9.
7. Ferreira FM, Novais NR, Júnior PC, Soares CJ, Neto AJ. Evaluation of knowledge about disinfection of dental impressions in several dental schools. Rev Odontol Bras Central 2010;19:285-9.
8. Bolla MM, Pégurier LL, Velly AM, Bolla M. A survey of disinfection of irreversible hydrocolloid and silicone impressions in European Union dental schools: Epidemiologic study. Int J Prosthodont 2004;17:165-71.
9. Rubel BS. Impression materials: A comparative review of impression materials most commonly used in restorative dentistry. Dent Clin N Am 2007;51:629-42.
10. Nallamuthu NA, Braden M, Patel MP. Some aspects of the formulation of alginate dental impression materials setting characteristics and mechanical properties. Dent Mater 2012;28:756-62.
11. Srivastava A, Aaisa J, Tarun TA, Ginjupalli K, Upadhya NP. Alginates: A review of compositional aspects for dental applications. Trends Biomater Artif Organs 2012;26:31-6.
12. Ramer MS, Gerhardt DE, McNally K. Accuracy of irreversible hydrocolloid impression material mixed with disinfectant solutions. J Prosthodont 1993;2:156-8.
13. Taylor RL, Wright PS, Maryan C. Disinfection procedures: Their effect on the dimensional accuracy and surface quality of irreversible hydrocolloid impression materials and gypsum casts. Dent Mater 2002;18:103-10.
14. Boden J, Likeman P, Clark R. Some effects of disinfecting solutions on the properties of alginate impression material and dental stone. Eur J Prosthodont Restor Dent 2001;9:131-5.
15. Tobias RS, Browne RM, Wilson CA. An *in vitro* study of the antibacterial and antifungal properties of an irreversible hydrocolloid impression material impregnated with disinfectant. J Prosthet Dent 1989;62:601-5.
16. Rice CD, Dykstra MA, Feil PH. Microbial contamination in two antimicrobial and four control brands of alginate impression material. J Prosthet Dent 1992;67:535-40.
17. Touyz LZ, Rosen M. Disinfection of alginate impression material using disinfectants as mixing and soak solutions. J Dent 1991;19:255-7.
18. Amalan A, Ginjupalli K, Upadhya N. Evaluation of properties of irreversible hydrocolloid impression materials mixed with disinfectant liquids. Dent Res J 2013;10:65-73.
19. Casemiro LA, de Souza Fde CP, Panzeri H, Martins CH, Ito IY. *In vitro* antimicrobial activity of irreversible hydrocolloid impressions against 12 oral microorganisms. Braz Oral Res 2007;21:323-9.
20. Rosen M, Touyz LZ. Influence of mixing disinfectant solutions into alginate on working time and accuracy. J Dent 1991;19:186-8.
21. Baker PS, Plummer KD, Parr GR, Parker MH. Dermal and mucosal reactions to an antimicrobial irreversible hydrocolloid impression material: A clinical report. J Prosthet Dent 2006;95:190-3.
22. Knetsch ML, Koole LH. New strategies in the development of antimicrobial coatings: The example of increasing usage of silver and silver nanoparticles. Polymers 2011;3:340-66.
23. Gutierrez FM, Thi EP, Silverman JM, de Oliveira CC, Svensson SL, Vanden Hoek A, *et al*. Antibacterial activity, inflammatory response, coagulation and cytotoxicity effects of silver nanoparticles. Nanomedicine 2012;8:328-36.
24. Kim JS, Kuk E, Yu KN, Kim JH, Park SJ, Lee HJ, *et al*. Antimicrobial effects of silver nanoparticles. Nanomedicine 2007;3:95-101.
25. Lemon JC, Okay DJ, Powers JM, Martin JW, Chambers MS. Facial moulage: The effect of a retarder on compressive strength and working and setting times of irreversible hydrocolloid impression material. J Prosthet Dent 2003;90:276-81.

How to cite this article: Harikrishna M, Kumar TS, Shankar YR, Bhargavi K, Naseemoon P. Comparative Evaluation of Antifungal Efficacy of Irreversible Hydrocolloid Incorporated with Silver Zeolite and Copper Oxide Nanoparticles. Int J Sci Stud 2021;9(1):125-128.

Source of Support: Nil, **Conflicts of Interest:** None declared.

Print ISSN: 2321-6379
Online ISSN: 2321-595X

Original Article

Comparative Evaluation of Results of Vertically Oriented Figure of 8 Tension Band Wiring Versus Horizontally Oriented Figure of 8 Tension Band Wiring for Displaced Transverse Fracture of Patella in Adults

Tanmay Datta[1], Sharjeel Khan[2], Ananda Kisore Pal[3], Debayan Sinharoy[4], Pinaki Das[5]

[1]Associate Professor, Department of Orthopaedics, Institute of Post Graduate Medical Education and Research and Seth Sukhlal Karnani Memorial Hospital, Kolkata, West Bengal, India, [2]Contractual Medical Officer, Department of Orthopaedics, Gardenreach Superspeciality Hospital, Kolkata, West Bengal, India, [3]Professor, Department of Orthopaedics, Institute of Post Graduate Medical Education and Research and Seth Sukhlal Karnani Memorial Hospital, Kolkata, West Bengal, India, [4]Senior Resident, Department of Orthopaedics, Calcutta National Medical College, Kolkata, West Bengal, India, [5]Junior Resident, Department of Orthopaedics, Institute of Post Graduate Medical Education and Research and Seth Sukhlal Karnani Memorial Hospital, Kolkata, West Bengal, India

Abstract

Introduction: Displaced fractures of patella are common: They require adequate internal fixation to achieve maximum interfragmentary compression and early mobilization. The purpose of this paper was to evaluate and compare the outcomes of vertically oriented figure of 8 tension band wiring (TBW) versus horizontally oriented figure of 8 TBW.

Materials and Methods: A longitudinal study was performed on 20 patients with displaced transverse patella fractures who were operated at the Department of Orthopaedics, IPGME and R and SSKM Hospital, Kolkata, India, between 2018 and 2019. The patients were randomly allocated into two groups, one operated by vertically oriented figure of 8 TBW while the other group by horizontally oriented TBW.

Results and Analysis: Results were evaluated in terms of post-operative pain, fracture union rates, knee range of motion (ROM), Oxford Knee Score (OKS), and complications such as implant loosening and infection. Both groups were comparable in terms of age and gender. Time taken for fracture union was equal in both groups, with no significant difference between post-operative pain and complications. The knee arc of motion at 1 month and OKS at 2 months were better in the horizontal group (P = 0.036443 and 0.044735, respectively). But overall, the difference in arc of motion and OKSs between the two groups was statistically not significant (P = 0.809391 and 0.805302, respectively).

Conclusion: Horizontally oriented figure of 8 TBW produces better ROM and knee scores at 1 and 2 months, but its overall outcomes are comparable to the more popular and widely performed vertically oriented figure of 8 TBW.

Key words: Horizontal figure of 8, Horizontal tension band wiring, Horizontally oriented tension band wiring, Modified tension band wiring, Patella fracture, Patella tension band wiring, Tension band wiring

INTRODUCTION

Patella fracture is a fracture consisting 1% of all extremity fractures, and among them, transverse type is the most common.[1] Closed fractures with minimal displacement, minimal articular incongruity, and an intact extensor retinaculum can be successfully treated non-operatively.[2] However, 30% of patella fractures require surgical intervention.[3] The purpose of operative treatment for patellar fracture is to restore anatomical reduction of the joint surface and to make a strong enough fixation to allow early passive range of motion (ROM) exercise, which prevents intra- and periarticular fibrosis and helps articular cartilage healing.[4-6]

Tension band wiring (TBW) for displaced transverse fracture of patella is a simple, inexpensive technique of

Access this article online

www.ijss-sn.com

Month of Submission : 02-2021
Month of Peer Review : 03-2021
Month of Acceptance : 03-2021
Month of Publishing : 04-2021

Corresponding Author: Dr. Sharjeel Khan, Department of Orthopaedics, Gardenreach Superspeciality Hospital, Kolkata, West Bengal, India.

fixing the fracture with good patient compliance and advantage of early mobilization of the joint. However, the technique has some disadvantages as second procedure is required for removal of the metallic implant and risk of Kirschner wire (K-wire) sliding and causing skin problems.[7]

The most common type of fixation method used for transverse patella fracture is modified TBW using two K-wires across the fracture site with a figure of eight pattern cerclage wiring [Figure 1].[5]

In a reported case series, 22% of fractures treated with TBW had a displacement of 2 or >2 mm within the early post-operative period.[8] It would be understandable to most surgeons that, to reduce the risk of displacement or failure, a construct that produces the greatest interfragmentary compression and has the maximum stiffness to resist cyclic loads should be used.[9]

In vertically oriented figure of 8 TBW, only a component of the secondary force vector acts vertically to produce compression at the fracture site [Figure 1], whereas in horizontally oriented figure of 8 TBW, both primary and secondary force vectors act vertically to produce compression [Figure 2]. Thus, in theory, a horizontal construct with four strands of SS wire crossing the fracture (as opposed to two) should provide better interfragmentary compression at the fracture site.

In a biomechanical study published in 2016 by Ali *et al.*, it was found that placement of the figure of eight in a horizontal orientation with two wire twists at the corner improved interfragmentary compression by 63% [Figure 2]. Permanent fracture displacement was 67% lower with horizontal figure of eight constructs ($P < 0.05$; *t*-test).[9]

It shall be the aim of this study to compare the result and functional outcomes of horizontally oriented figure of 8 TBW versus vertically oriented figure of 8 TBW in transverse fracture of patella.

Aims and Objectives

The aim was to compare the results of vertically oriented figure of 8 TBW versus horizontally oriented figure of 8 TBW for displaced transverse fracture of patella in adults.

The objective was to analyze the results in terms of fracture union rates, pain relief, knee ROM, Oxford Knee Score (OKS), and complications such as implant loosening and infection.

Null hypothesis

There is no statistically significant difference in the outcomes obtained by vertically oriented figure of 8 TBW and horizontally oriented figure of 8 TBW in displaced transverse fracture of patella in adults.

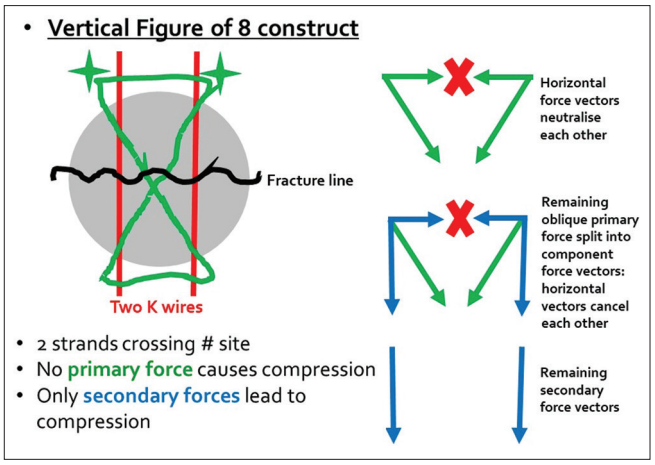

Figure 1: Force vectors acting in vertical figure of 8 construct

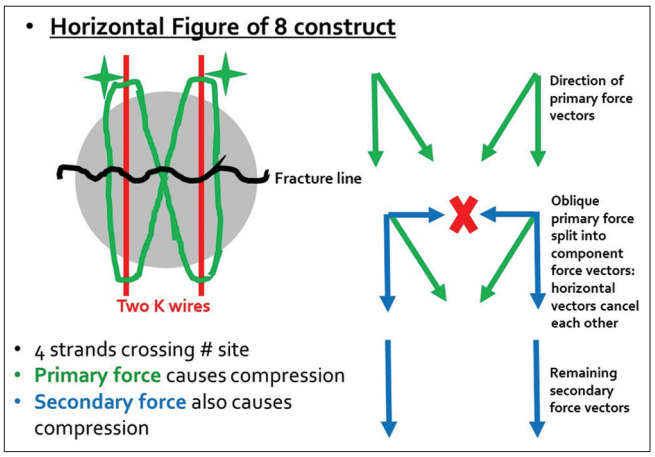

Figure 2: Force vectors acting in horizontal figure of 8 construct

MATERIALS AND METHODS

This is a prospective, longitudinal study conducted at the Department Orthopaedics, IPGME&R and SSKM Hospital, Kolkata, India, between 2018 and 2020 on 20 patients with displaced transverse fractures of patella. Patients were randomly allocated into two groups, "Vertical" group consisting of 10 patients who were operated by vertically oriented figure of 8 TBW and the "Horizontal" group, who were operated by horizontally oriented figure of 8 TBW. The inclusion criteria were adult patients (age 18–75 years) who suffered displaced transverse fracture of patella, <3 weeks old duration, and those who consented for participation in the study. Exclusion criteria were undisplaced fracture, comminuted fracture, fractures more than 3 weeks old, patients with serious comorbidities barring surgical anesthesia, and refusal to participate in the study. Pre-operative patient

parameters such as age, gender, side of affected limb, and delay in surgery were noted. On admission, routine tests were done according to hospital protocol and anteroposterior and lateral radiographs of the affected knee were obtained. All patients were operated under spinal anesthesia in supine position. The fracture was approached through a midline longitudinal incision and, after clearing the fracture ends, towel clips were used to assist in reduction. Two 2 mm K-wires were introduced parallelly from below upward and a pre-tensioned 18-gauge stainless steel wire was wound around the K-wires in a vertical figure of 8 fashion (in the vertical group) or in a horizontal figure of 8 fashion (in the horizontal group). Pliers were used to make two knots on the SS wire (at the superolateral and superomedial margins of the construct). Medial and lateral retinaculum was repaired using no. 1 polyglactin 910 suture and then subcutaneous tissue and skin closed in layers. Post-operative radiographs were obtained and the patient was allowed knee bending as tolerated from the 1st post-operative day. Sutures were removed at 14 days and active ROM exercises started. Post operatively, all patients were followed up for 2 years [Figures 3 and 4]. Post-operative follow-up parameters recorded were time taken for radiological union of fracture, pain relief, knee ROM, OKS, and complications such as implant loosening and infection. OKS is a self-reported questionnaire given to the patient consisting of 12 questions and score ranging from 0 to 48; 0–19 represents poor score, 20–29 represents moderate score, 30–39 represents good score, and 40–48 represents excellent score.

Research Method

Data have been summarized as mean and standard deviation for numerical variables, and as ratio and percentage for categorical variables. Student's unpaired *t*-test was applied to compare numerical variables between groups, while unpaired proportions were compared by Chi-square test in Microsoft Excel. The significance level was set at 0.05, at which the null hypothesis is either rejected or accepted.

RESULTS AND ANALYSIS

Mean age of patients in the vertical group was 44.3 ± 7.394 years (range 30–55 years) and that in the horizontal group was 45.9 ± 10.005 years (range 28–65 years). The male:female ratio in the vertical group was 1:1 (five males and five females) and that in the horizontal group was 3:2 (six males and four females). The left-sided patella was more commonly fractured (6 out of 10 in the vertical group and 7 out of 10 in the horizontal group). Mean delay between date of injury and date of surgery in the vertical group was 6.3 ± 7.166 days (range 1–20 days), while that in the horizontal group was 6.1 ± 6.100 (range 1–19 days). At 2 weeks post-operative, 3 out of 10 patients reported mild pain in the vertical group, while 2 out of 10 patients reported mild pain in the horizontal group. At 4 weeks post-operative, 2 out of 10 patients reported mild pain in the vertical group, while 1 out of 10 patients reported mild pain in the horizontal group. Thereafter, no patient from either group reported any pain in the subsequent follow-ups. *P* value at 2 weeks post-operative was 0.605577 and at 4 weeks post-operative was 0.531168, that is, the difference in post-operative pain between the two groups is statistically not significant. Time taken for radiological union of fractures was identical in both groups, with all fractures showing signs of union by 4 weeks postoperatively, that is, there is no difference in the rates of union observed in the two groups.

The mean arc of motion in the vertical group at 2 weeks, 4 weeks, 2 months, 3 months, 6 months, 1 year, and 2 years postoperatively was 60 ± 15.492, 105 ± 11.785, 133± 8.233, 136 ± 5.164, 137 ± 4.831, 137 ± 4.831, and 138 ± 4.216 degrees, respectively [Figure 3], and that in the horizontal group was 70 ± 13.333, 115 ± 7.071, 134 ± 8.433, 137 ± 6.750, 138 ± 4.216, 138 ± 4.216, and 139 ± 3.162 degrees, respectively [Figure 4]. The difference in the arc of motion at 4 weeks was statistically significant ($P = 0.036443$) but the overall difference in the mean arc of motion in the follow-up period was statistically not significant ($P = 0.799724$) [Chart 1].

Patients in both groups had moderate knee scores (20–29) at 2 weeks, good knee scores (30–39) at 4 weeks, and excellent knee scores (40–48) at subsequent follow-ups. The mean OKS in the vertical group at 2 weeks, 4 weeks, 2 months, 3 months, 6 months, 1 year, and 2 years postoperatively was 26.9 ± 2.998, 37.5 ± 3.53553, 41.4 ± 2.271, 43.7 ± 2.111, 45.1 ± 1.792, 45.6 ± 1.647, and 46.7 ± 1.338, respectively, and that in the horizontal group was 28.1 ± 2.514, 38.4 ± 2.011, 43.3 ± 1.567, 45.2 ± 1.989, 46.4 ± 1.075, 46.5 ± 0.972, and 47 ± 0.943, respectively.

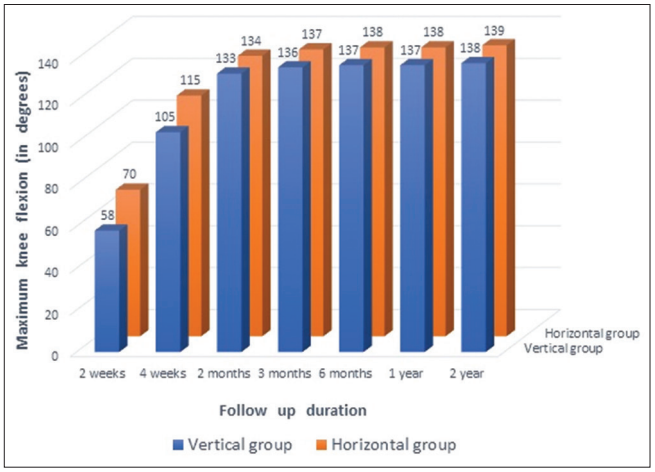

Chart 1: Comparison of mean arc of motion between two groups

The difference in OKSs at 2 months was statistically significant ($P = 0.044735$) but the overall difference in the mean OKSs in the follow-up period was statistically not significant ($P = 0.762026$) [Chart 2].

Slippage of SS wire was the only complication observed: It occurred in 3 out of 10 patients in the vertical group and in 2 out of 10 patients in the horizontal group. The difference in the rates of complication between the two groups is statistically not significant ($P = 0.605577$).

DISCUSSION

Patella fracture is a fracture consisting 1% of all extremity fractures, and among them, transverse type is the most common.[1] About 30% of patella fractures require surgical intervention.[3] Opinion differs as to the optimal treatment of displaced patellar fractures. Accepted methods include a variety of wiring techniques, screw fixation, partial patellectomy, and total patellectomy.[2]

TBW for displaced transverse fracture of patella is a simple, inexpensive technique of fixing the fracture with good patient compliance and advantage of early mobilization of the joint.[7] The most common type of fixation method used for transverse patella fracture is modified TBW using two K-wires across the fracture site with a figure of eight pattern cerclage wiring.[5] In a biomechanical study published in 2016 by Ali *et al.*, it was found that placement of the figure of eight in a horizontal orientation with two wire twists at the corner improved interfragmentary compression by 63% and permanent fracture displacement was 67% lower with such constructs ($P < 0.05$; *t*-test).[9]

With this in mind, a study was conducted at our hospital on 20 patients who were randomly allocated into two groups and then operated by vertically oriented figure of 8 TBW or horizontally oriented figure of 8 TBW, and the results were compared. The two groups were comparable in terms of age and gender distribution, side of affected limb, and delay between date of injury and date of surgery. There was no statistical difference in post-operative pain between the two groups. Furthermore, time taken for radiological union of fractures was similar in both groups, with all fractures showing signs of union by 4 weeks postoperatively.

Mean arc of motion was better in the horizontal group at 4 weeks post-operative, but the overall differences in mean arc of motion were statistically not significant. Patients treated with horizontally oriented figure of 8 TBW also had better knee scores at 2 months postoperatively but the overall differences in mean knee scores were not significant. Although patients treated with horizontal TBW had fewer complications, the difference observed in the two groups was not statistically different. The better outcomes in the horizontal group in the early post-operative period could be attributed to better interfragmentary compression as

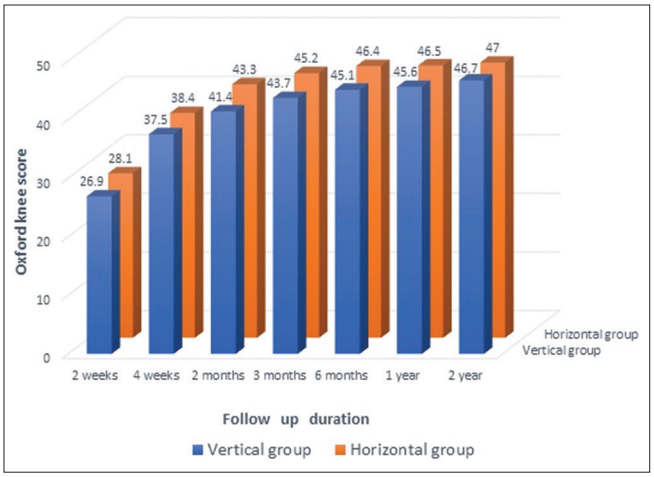

Chart 2: Comparison of mean Oxford Knee Scores between two groups

Figure 3: Radiographs and clinical photographs of vertical group

Figure 4: Radiographs and clinical photographs of horizontal group

demonstrated in the biomechanical study published in 2016 by Ali *et al*.[9]

Thus, in this study, we accept the null hypothesis, that is, there is no statistically significant difference in the outcomes obtained by vertically oriented figure of 8 TBW and horizontally oriented TBW in displaced transverse fracture of patella in adults.

CONCLUSION

Displaced transverse fracture of patella in adults is best treated by open reduction and internal fixation using TBW. Using a horizontal figure of 8 construct is theoretically superior to the more common vertical figure of 8 construct, achieving better interfragmentary compression as reported by biomechanical studies. In our study too, patients treated with horizontally oriented figure of 8 TBW had statistically significant better arc of motion at 4 weeks post-operative and better knee scores at 8 weeks postoperatively than those treated with vertically oriented figure of 8 TBW; they also had fewer complications compared to vertical TBW. However, the overall outcomes in terms of arc of motion, knee score, complication rate, fracture union rate, and post-operative pain were not significantly different.

ACKNOWLEDGMENT

We would like to acknowledge our senior orthopaedic faculty members, Dr. Dibyendu Biswas, Dr. Arnab Karmakar and Dr. Avijit Basak for their constant guidance; and Dr. Sohel Rana Chowdhury, Dr. Ayon Ghosh and Dr. Vaibhav Singh who have helped in conducting our research work.

REFERENCES

1. Boström A. Fracture of the patella: A study of 422 patellar fractures. Acta Orthop Scand 1972;43:1-80.
2. Azar FM, Beaty JH, Canale ST, editors. Campell's Operative Orthopaedics. 13th ed., Vol. 3. Amsterdam, Netherlands: Elsevier; 2017. p. 2775.
3. Scilaris TA, Grantham JL, Prayson MJ. Biomechanical comparison of fixation methods in transverse patella fractures. J Orthop Trauma 1998;12:356-9.
4. Wall A, Board T. The biological effect of continuous passive motion on the healing of full-thickness defects in articular cartilage. In: An Experimental Investigation in the Rabbit. Classic Papers in Orthopaedics. Berlin: Springer; 2014. p. 437-9.
5. Gwinner C, Mardian S, Schwabe P, Schaser KD, Krapohl BD, Jung TM. Current concepts review: Fractures of the patella. GMS Interdiscip Plast Reconstr Surg DGPW 2016;5:Doc01.
6. Kakazu R, Archdeacon MT. Surgical management of patellar fractures. Ortho Clin 2016;47:77-83.
7. Aggarwal S, Raghuwanshi G. Outcome study of application of modified tension band wiring (TBW) in patellar fracture: A prospective study Glob J Res Anal 2015;4:100-3.
8. Smith ST, Cramer KE, Karges DE, Watson JT, Moed BR. Early complications in the operative treatment of patella fractures. J Orthop Trauma 1997;11:183-7.
9. Ali M, Kuiper J, John J. Biomechanical analysis of tension band wiring (TBW) of transverse fractures of patella. Chin J Traumatol 2016;19:255-8.

How to cite this article: Datta T, Khan S, Pal AK, Sinharoy D, Das P. Comparative Evaluation of Results of Vertically Oriented Figure of 8 Tension Band Wiring Versus Horizontally Oriented Figure of 8 Tension Band Wiring for Displaced Transverse Fracture of Patella in Adults. Int J Sci Stud 2021;9(1):129-133.

Source of Support: Nil, **Conflicts of Interest:** None declared.

Print ISSN: 2321-6379
Online ISSN: 2321-595X

Original Article

A Prospective Randomized Comparative Study of Coblation-Assisted Adenotonsillectomy and Conventional Adenotonsillectomy

Ravikant Agrawal[1], Shraddha Sharma[2], Giriraj Prasad Trivedi[3], Yogesh Aseri[4], Praveen Chandra Verma[5], B K Singh[5]

[1]Resident Doctor, Department of Otorhinolaryngology, JLN Medical College, Ajmer, Rajasthan, India, [2]Senior Resident Doctor, Department of Otorhinolaryngology, SMS Medical College, Jaipur, Rajasthan, India, [3]Senior Resident Doctor, Department of Otorhinolaryngology, JLN Medical College, Ajmer, Rajasthan, India, [4]Associate Professor, Department of Otorhinolaryngology, JLN Medical College, Ajmer, Rajasthan, India, [5]Senior Professor, Department of Otorhinolaryngology, JLN Medical College, Ajmer, Rajasthan, India

Abstract

Background: In recent years, with the arrival of coblator, results of coblation adenotonsillectomy have been encouraging from many studies. There are various modalities to perform surgery diathermy, laser, cryosurgery, dissection and snare method, etc.

Materials and Methods: In our prospective study type, we included 50 children (4–14 year) and divided them equally: 25 conventional adenotonsillectomy versus 25 surgically treated with Coblation II system Arthrocare. We compared estimated blood loss during surgery, duration of surgery, the post-operative pain and post-operative bleeding, tonsillar fossa healing, and return of normal activity and diet.

Results: We found statistically significant differences ($P < 0.0001$) in these parameters in both surgical techniques: The intensity of pain is less in the patients treated with the Coblation method in all 3 follow-up days. In regard of intraoperative blood loss ,in conventional method average blood loss was 48 ml whereas average blood loss in coblation method was 30 ml. The difference of average blood loss between the two techniques was 15-20 ml which was statistically highly significant ($P<0.0001$). The post-operative tonsillar fossa healing was estimated by the amount of slough covered in tonsillar fossa and it was compared on the 1st, 2nd, and 7th post-operative day. In conventional side, mean area of slough covered was 38.8%, 47%, and 14.4%, respectively, and on coblation side, it was 79.6%, 84.4%, and 36%, respectively. Hence, slough formation is more in coblation side compared to conventional side.

Conclusion: This study revealed a significantly less intraoperative or post-operative complications and morbidity in coblation adenotonsillectomy in comparison with traditional method. These findings addressed coblation adenotonsillectomy as an advanced method.

Key words: Adenotonsillectomy, Coblation, Complications, Conventional

INTRODUCTION

Adenotonsillectomy, despite less performed surgery nowadays, still is a very common surgical procedure. There are various modalities to perform surgery (diathermy, laser, cryosurgery, and coblation). Among these, dissection and snare method is commonly done by ENT surgeons. Other modalities are not used regularly considering the cost of equipment. With the arrival of coblator, results of coblation adenotonsillectomy have been encouraging from many studies. Unlike most operative procedures, which are closed primarily, tonsillectomy produces an open wound that heals by secondary intention.

The major post-operative morbidity problems are pain and hemorrhage.[1] The pain is the result of disruption of mucosa and glossopharyngeal nerve fiber irritation followed by inflammation and spasm of the pharyngeal muscles that lead to ischemia and protracted cycle of pain; it does not completely subside until the muscle becomes covered with mucosa 14–21 days after surgery.[2] The post-operative secondary hemorrhage is due to secondary infection of

Access this article online

www.ijss-sn.com

Month of Submission : 02-2021
Month of Peer Review : 03-2021
Month of Acceptance : 03-2021
Month of Publishing : 04-2021

Corresponding Author: Dr. Giriraj Prasad Trivedi, Department of Otorhinolaryngology, JLN Medical College, Ajmer, Rajasthan, India.

the tonsillar fossa resulting in disruption of vessels and bleeding.[3] The various methods for tonsillectomy are dissection, guillotine, cryosurgery, monopolar and bipolar diathermy dissection, suction diathermy dissection, bipolar scissor dissection, ultrasonic removal, radiofrequency surgery, and laser surgery.[4]

Any improvement in the above procedures should have the advantages of decrease in the operating time, reduction in the intraoperative and post-operative blood loss, and reduction in post-operative morbidity.

Coblation is a new technique that was started in 1997[5] involves passing a radiofrequency bipolar electrical current through a medium of normal saline, resulting in a plasma field of highly ionized particles, which, in turn, breakdown intercellular bonds and thus melt tissue at around 70°C (in comparison with electrocautery which cuts tissues at 400°C). There are two different techniques for coblation tonsillectomy: (1) Subtotal, intracapsular ablation, in this technique some tonsil tissue may be left behind; (2) Total, subcapsular dissection of tonsils, in which the entire tonsil is removed by dissecting between the tonsillar capsule and the surrounding pharyngeal muscle [Image 1]. In concordance with other studies which state that subtotal tonsillectomy not be the best technique to use in chronic tonsillitis because tonsillar tissue is left behind and could result in recurrent infections, the subcapsular technique was adopted in this study to evaluate and compare the efficacy of coblation and conventional technique.[6]

MATERIALS AND METHODS

The prospective study was carried out in the Department of Otorhinolaryngology, Jawaharlal Nehru Medical (JLN) Medical College and Hospital, Ajmer, from April 1, 2018, to March 31, 2019. Approval from the Institutional Ethics Committee was obtained.

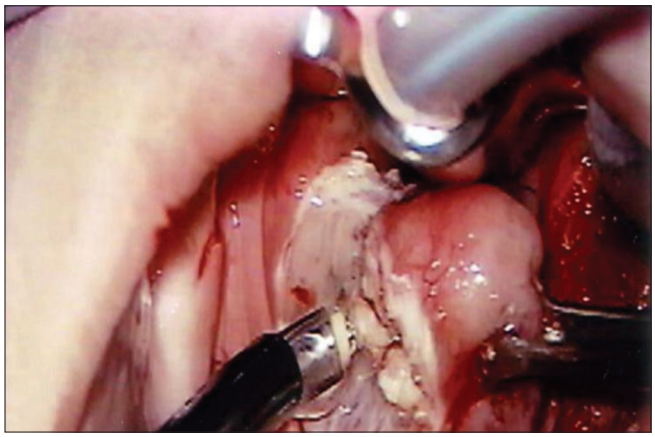

Image 1: Coblation tonsillectomy

The study included 50 cases with age group 4–14 years who presented with indications of adenotonsillectomy. Patients were allocated into two groups alternately Group 1 (conventional adenotonsillectomy) and Group 2 (coblation done adenotonsillectomy). Each group included 25 patients each.

A written and fully explained consent stating the voluntary participation of subjects in the study was taken by the parents before the enrolment of the children. All cases selected for the study were evaluated using preformed pro forma. A detailed history was taken as to age, sex, socioeconomic status, occupation, nature and duration of symptoms, etc. All patients underwent thorough history and ENT examination. A battery of investigation including routine blood investigation, urine examination, X-ray soft-tissue nasopharynx lateral view with open mouth for adenoids, X-ray chest, and electrocardiogram. All patients had undergone a thorough pre-anesthetic evaluation before surgery including history and physical examination. All tonsillectomies were performed under general anesthesia using the same standardized anesthetic technique. Operation time, from insertion till removal of mouth gag, was recorded for each case, intraoperative blood loss was measured through volume of blood in suction bottle after the operation. Data including volume of blood loss operation time, time period needed to return to work and normal diet and post-operative hemorrhage if occurred, were gathered in both groups.

Statistical analysis of these results was done by the Student's *t*-test using SPSS software and *P*-value was calculated. The results were assessed within 95% reliance and at a significance level of $P < 0.05$ [Figure 1].

RESULTS

A total of 50 cases were included in the study which were alternately allocated in Groups 1 and 2, respectively.

There were 30 male children and 20 female children between 4 and 14 years. The two groups were matched in terms of sex and age distribution. Group 1 has 18 males and 7 females. Group 2 has 12 male and 13 females. Nineteen patients in both groups were between the age of 4 and 10 years and six patients in both groups were between 11 and 14 years of age [Table 1].

The mean duration is measured from giving incision over the tonsil up to achieving complete hemostasis, for coblation adenotonsillectomy, the mean duration was 52.8 min, and for conventional adenotonsillectomy, mean duration was 36.16 min. Thus, coblation method takes average of 15 min longer duration compare to conventional method which was statistically highly significant ($P < 0.0001$) [Figure 2].

Table 1: Demographic characteristics of the study population

Characteristics	Group 1	Group 2
Gender		
Female	7	13
Male	18	12
Age distribution		
4–10 years	19	19
11–14 years	6	6

Table 2: Post-operative pain VAS score

Post-operative day pain scale	Conventional	Coblation	*t*-value	*P*-value
1st day	7.64±0.99	3.92±0.76	14.86	<0.001
2nd day	6.040±1.10	3.56±0.96	8.50	<0.001
7th day	4.08±0.81	2.96±1.04	4.25	<0.001

VAS: Visual analog scale

Table 3: Tonsillar fossa healing

Post-operative day tonsillar fossa healing	Conventional	Coblation	*t*-value	*P*-value
1st day	38.8	79.6	–23.82	<0.0001 (HS)
2nd day	47.000	84.40	–20.66	<0.0001 (HS)
7th day	14.4	36.00	–6.66	<0.0001 (HS)

The total blood loss during the procedure was measured by weighing the swabs before and after the procedure separately on each side and that in the suction apparatus. The amount of blood lost on an average on the coblation side was 30 ml and on the conventional side was 48 ml which is statistically highly significant ($P < 0.0001$) [Figure 3].

According to 70% of patients, coblation method was less painful for the overall 7-day recovery period than conventional method and this was statistically significant ($P = 0.01$). Pain was observed by visual analog scale (VAS).[7] The mean pain score for coblation averaged over 7 days was 2.96 and 4.08 for conventional technique. When pain scores were compared between the two techniques for each individual evaluation, the pain was consistently less on the coblation side, but the difference was small and not significant [Table 2].

There was no case of reactionary or secondary hemorrhage in any patient.

Each tonsillar fossa was assessed for healing at the time of each evaluation in terms of percent of slough covering over tonsillar fossa. Slough formation was early on the coblation

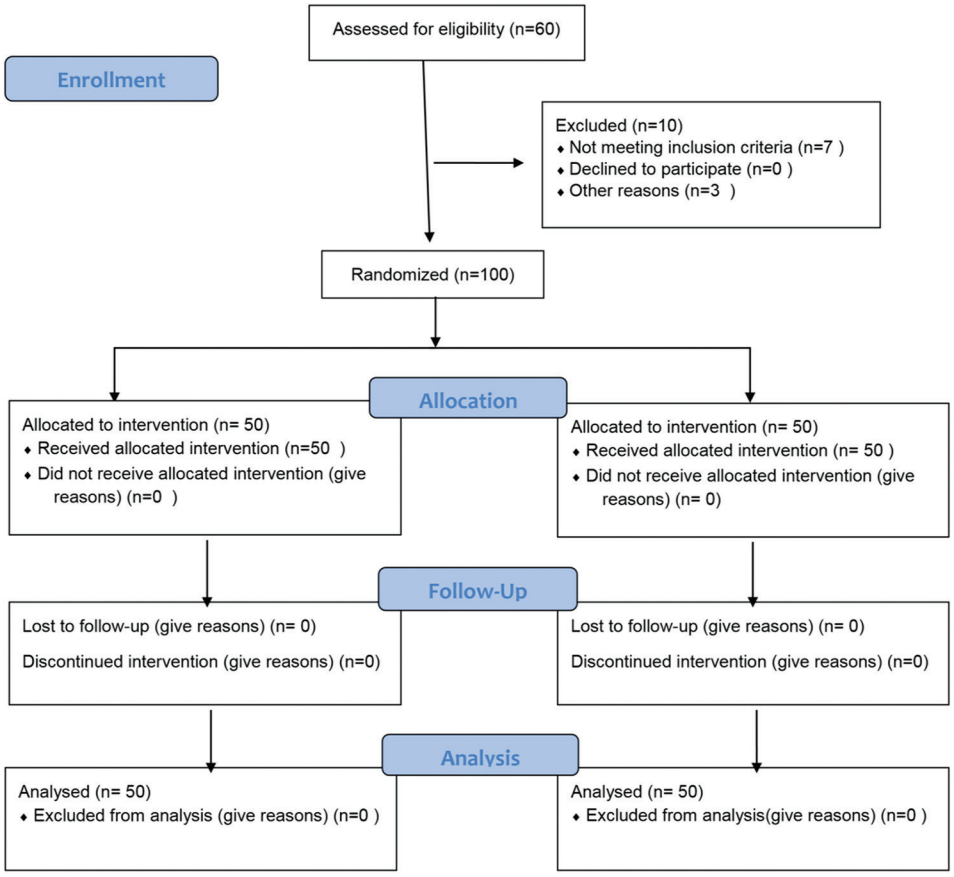

Figure 1: Consort flow diagram

Image 2: Tonsillar fossa healing 1st day

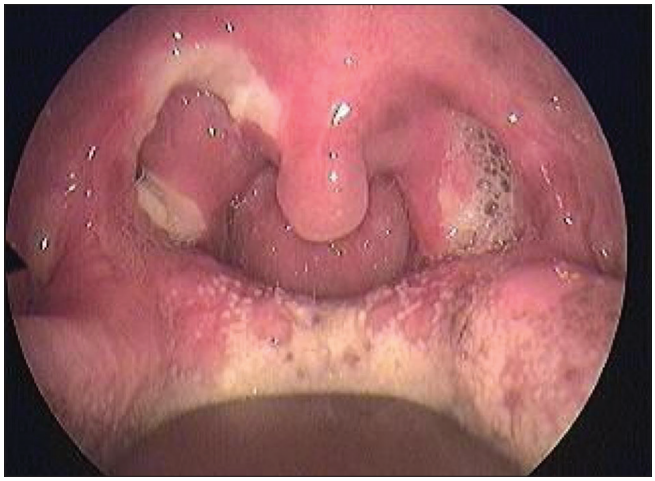

Image 3: Tonsillar fossa healing 7th day

side and remained there for a longer duration of time. The healing took longer on the coblation side [Table 3].

DISCUSSION

Coblation technique is a new advancement in technology and has shown to have promising results in adenotonsillectomy compared to conventional technique in terms of post-operative morbidity. Still, the argument about the outcomes of the two techniques continues.

In our study, the mean duration of surgery for coblation method was 52.8 min (ranging from 48 min to 60 min) and for conventional method was 36.16 min (ranging from 28 min to 45 min) supported by the previous study by Rakesh *et al.* (2012)[1] who also found that coblation has longer duration. Omrani *et al.* (2012)[2] described the duration of surgery in their studies showed evidence that coblation method had less duration compared to

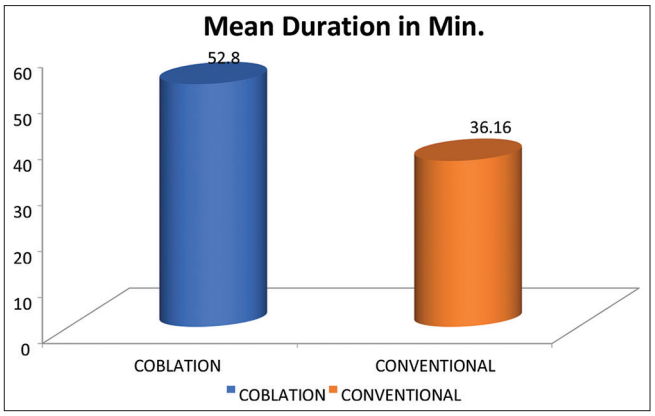

Figure 2: Bar chart showing duration of surgery in minutes

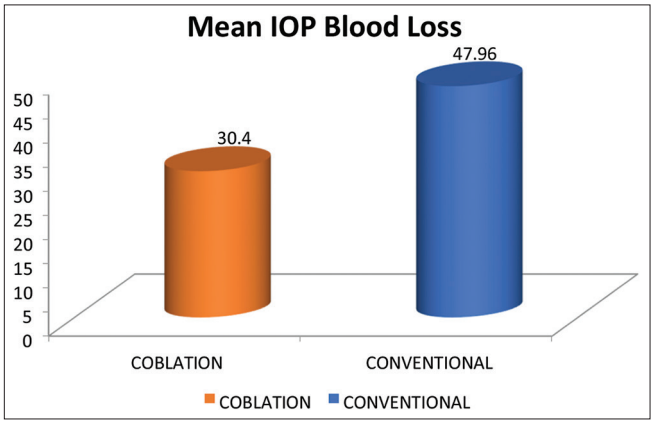

Figure 3: Bar chart showing intraoperative blood loss

conventional method [Figure 2]. In our study, coblation method takes longer duration compare to conventional method which was statistically highly significant ($P < 0.0001$).

The mean intraoperative blood loss in conventional method was 47.96 ml (ranging from 40 ml to 55 ml) and for coblation method was 30.4 ml (ranging from 20 ml to 40 ml) which is statistically significant ($P < 0.0001$). Our study was further supported by the previous study by Paramasivam *et al.*[8] (2012) who described that conventional tonsillectomy was associated with greater blood loss. Further evidence was supported by a meta-analysis report by Vangelin *et al.*[9] (2013) which showed that intraoperative bleeding was significantly less in coblation. Hong *et al.*[10] (2013) conducted a study in pediatrics patients undergoing tonsillectomy and demonstrated that coblation tonsillectomy has lesser blood loss. Similar studies were done by Omrani *et al.* (2011) and Rakesh *et al.* (2012) [Figure 3].

Initial studies on coblation showed a significant decrease in post-operative pain scores comparing with conventional method. On the other hand, some studies reported no

significant reduction in pain with coblation surgery. In our study, the post-operative pain was measured using VAS scale and compared in both methods on the 1st, 2nd, and 7th post-operative day. For conventional method group, the mean post-operative pain scores were 7.64, 6.04, and 4.08, whereas in coblation method group, score was 3.92, 3.56, and 2.95, respectively, showed less pain in coblation method [Table 2]. This is supported by the previous studies like Polites *et al.* (2006)[7] described that coblation tonsillectomy was significantly less painful and also less pain in the first 3 post-operative days and Timms *et al.*[11] suggested significant benefit in post-operative pain levels in coblation method.

In our study, we found that pain was significantly less on the 1st, 2nd, and 7th post-operative day in coblation method compare to conventional method ($P < 0.001$).

The tonsillar fossa healing was delayed in cases where adenotonsillectomy was performed using coblation method by the presence of slough in the fossa on the 1st [Image 2], 2nd, and 7th post-operative day [Image 3]. Coblation causes early slough formation and delayed healing.

Temple *et al.*[12] described that coblation has advantages in post-operative period and rapid return to normal diet. Noon *et al.*[13] described significantly higher hemorrhage rate in coblation comparing with diathermy. Divi *et al.*[14] in a retrospective study found no statistical difference between hemorrhage rates for coblation versus non-coblation tonsillectomy techniques. In our study, there was no reactionary or secondary hemorrhage in any patient.

CONCLUSION

From our study, we conclude that:

1. Coblation adenotonsillectomy is relatively easy technique to perform providing a near bloodless field and minimal surrounding tissue damage
2. The operative time required to perform coblation adenotonsillectomy was more than the conventional method. The longer time did not cause more intraoperative blood loss and post-operative pain
3. The intraoperative blood loss was significantly less in the coblation group than conventional group
4. Most importantly, post-operative pain scores were significantly lower in the coblation group on the 1st, 2nd, and 7th post-operative day. It helps the patients to resume their normal activities early
5. Healing was slightly delayed in the coblation group. To conclude, coblation adenotonsillectomy is easy to perform and it is safer with significant advantages in terms of decrease in intraoperative blood loss and post-operative morbidity. However, the only deterring factor in the regular usage of coblation is the cost factor which has to be overcome.

ACKNOWLEDGMENT

All procedures performed in the presented study involving human participants were in accordance with the ethical standards of the Institutional Ethical Committee of JLN Medical College, Ajmer (Letter no. 2370/Acad-III/MCA/2016), and with the 1964 Helsinki Declaration and its later amendments or comparable ethical standards.

INFORMED CONSENT STATEMENT

Written informed consent was obtained from all individual participants included in the study in native language.

DECLARATION ON COMPETING INTEREST

Authors declare no conflicts of interest.

FINANCIAL SUPPORT/GRANT

No financial funding received. Patients were treated free of cost under "MNDY (Mukhyamantri Nishulk Dava Yojana) scheme" sponsored by Government of Rajasthan.

CONSENT FOR PUBLICATION

Written informed consent was taken.

AVAILABILITY OF DATA AND MATERIAL

Pro forma of the data taken is filled for every patient and is available with the first author for review.

CODE AVAILABILITY

Not applicable (no special software was used).

REFERENCES

1. Omrani M, Barati B, Omidifar N, Okhovvat AR, Hashemi SA. Coblation versus traditional tonsillectomy: A double blind randomized controlled trial. J Res Med Sci 2012;17:45-50.
2. Rakesh S, Anand TS, Payal G, Pranjal K. A prospective, randomized, double-blind study of coblation versus dissection tonsillectomy in adult patients. Indian J Otolaryngol Head Neck Surg 2012;64:290-4.

3. Dempster JH. Post-tonsillectomy analgesia: The use of benzocaine lozenges. J Laryngol Otol 1988;102:813-4.
4. Baily BJ. Tonsils and adenoids: Snapshots from the laryngoscope scrapbook. Laryngoscope 1997;107:301-6.
5. Philpott CM, Wild DC, Mehta D, Daniel M, Banerjee AR. A double-blinded randomized controlled trial of coblation versus conventional dissection tonsillectomy on postoperative symptoms clinical. Otolaryngology 2005;30:143-8.
6. Friedman M, LoSavio P, Ibrahim H, Ramakrishnan V. Radiofrequency tonsil reduction: Safety, morbidity, and efficacy. Laryngoscope 2003;113:882-7.
7. Polites N, Joniau S, Wabnitz D, Fassina R, Smythe C, Varley P, *et al.* Postoperative pain following coblation tonsillectomy: Randomized clinical trial. ANZ J Surg 2006;76:226-9.
8. Paramasivam VK, Arumugam SV, Kameswaran M. Randomised comparative study of adenotonsillectomy by conventional and coblation method for children with obstructive sleep apnoea Int J Pediatr Otorhinolaryngol 2012;76:816-21.
9. Alexiou VG, Salazar-Salvia MS, Jervis PN, Falagas ME. Modern technology-assisted vs conventional tonsillectomy. Arch Otolaryngol Head Neck Surg 2011;137:558.
10. Hong SM, Cho JG, Chae SW, Lee HM, Woo JS. Coblation vs. electrocautery tonsillectomy: a prospective randomized study comparing clinical outcomes in adolescents and adults. Clin Exp Otorhinolaryngol 2013;6:90-3.
11. Timms MS, Temple RH. Coblation tonsillectomy: A double blind randomized controlled study. J Laryngtol Otol 2003;117:704-6.
12. Temple RH, Timms MS. Paediatric coblation tonsillectomy. Int J Pediatr Otorhinolaryngol 2002;116:450-26.
13. Noon AP, Hargreaves S. Increased post-operative haemorrhage seen in adult coblation tonsillectomy. J Laryngol Otol 2003;117:704-6.
14. Divi V, Benninger M. Postoperative tonsillectomy bleed: Coblation versus non-coblation. Laryngoscope 2005;115:31-3.

How to cite this article: Agrawal R, Sharma S, Trivedi GP, Aseri Y, Verma PC, Singh BK. A Prospective Randomized Comparative Study of Coblation-Assisted Adenotonsillectomy and Conventional Adenotonsillectomy. Int J Sci Stud 2021;9(1):134-139.

Source of Support: Nil, **Conflicts of Interest:** None declared.

Print ISSN: 2321-6379
Online ISSN: 2321-595X

Original Article

Study of Post-operative Hypocalcemia in Total Thyroidectomy Patients: A Prospective Study

N Subalakshmi[1], R Kannaki[2]

[1]Senior Assistant Surgeon, Department of General Surgery, Government Headquarters Hospital, Ramanathapuram, Tamil Nadu, India, [2]Civil Surgeon, Department of General Surgery, Government Headquarters Hospital, Ramanathapuram, Tamil Nadu, India

Abstract

Introduction: Hypocalcemia is a common complication in patients undergoing thyroid surgery. It compromises the patient's quality of life and increases hospitalization time, costs, and mortality. Post-operative hypocalcemia can be acute or irreversible in lifetime supplements, depending on the degree of parathyroid injury.

Aim: This study aimed to analyze the prevalence of hypocalcemia in patients undergoing total thyroidectomy.

Materials and Methods: This prospective study was done on patients who underwent total thyroidectomy at our site hospital from August 2018 to August 2020. A total of 40 patients of both genders were registered for the study. All the patients were above 18 years of age. Post-operative serum calcium levels were recorded.

Results: Among all patients, enrolled 90% (36) were women, whereas only 10% (4) were men. Most patients are from the age group of 31–40 (37.5%) and least are from the age group above 50 years (10%). Post-operative hypocalcemia occurred in 16 (40%) patients and the major surgical indication for total thyroidectomy was swelling of the thyroid or goiter.

Conclusion: The risk factor for hypocalcemia development is multilevel. The suggested operational technique for preventing permanent hypocalcemia is a thorough dissection and protection of the parathyroid gland and its blood supply.

Key words: Hypocalcemia, Post-operative hypocalcemia, Thyroid disease, Thyroidectomy

INTRODUCTION

A popular treatment performed in the world is a complete thyroidectomy. In patients with thyroid cancer, Graves' disease, and toxic multidose goiter, complete thyroidectomy is recommended.[1] In recent years, total thyroidectomy has become an option, particularly in endemic iodine-deficient areas, to treat patients with multinodular goiter. Complete thyroidectomy is generally done when the diagnosis of thyroid lobectomy or lobectomy is performed in the case of a presumed benign condition, such as an asymptomatic multinodular goiter.[1,2] Thyroid surgery (total or near-total thyroidectomy) can lead to severe complications, including transient or permanent cordal palsy or severe bleeding.[3]

Access this article online

www.ijss-sn.com

Month of Submission : 02-2021
Month of Peer Review : 03-2021
Month of Acceptance : 03-2021
Month of Publishing : 04-2021

However, hypocalcemia is the major complication after thyroid surgery.[3,4] Hypocalcemia frequently complicates the post-operative care of patients who have undergone thyroid surgery. This condition remains a common complication with an overall reported incidence in the adult population ranging from 1% to 50%.[5,6]

The risk factors predisposing to hypocalcemia after thyroid treatment are giant goiters, complete thyroidectomy, chronic goiters, carcinoma, and surgeons' experience, leading to devascularization or accidental removal of the parathyroid glands. Hypocalcemia can occur secondary to surgical trauma, devascularization, and unintended extraction of the glands.[7] Additional mechanisms, such as Vitamin D deficiency, an acute increase in calcitonin serum levels (because of gland handling during surgery), or a "hungry bone syndrome" are believed to contribute to this process.[8] Etiological considerations include post-operative alkalosis-induced hypocalcemia resulting from hyperventilation triggered by post-operative pain and dilution hypocalcemia.

Corresponding Author: Dr. R Kannaki, Department of General Surgery, Government Headquarters Hospital, Ramanathapuram, Tamil Nadu, India.

In most cases, hypocalcemia post-thyroidectomy is reversible, although it can take several months. A small number of patients (0–12%) remain during this time and are assumed to be permanent, even though the gap between temporary and permanent hypocalcemia ranges from 6 months to 1 year.[9] However, the patient is committed to lifelong symptomatic care with calcium or Vitamin D if the interval is permanent. The surgeon needs to make every effort to maintain one or more sustainable parathyroid, especially in total thyroidectomy or subtotal thyroidectomy, to avoid this complication.

Careful dissection and protection of parathyroid glands and their blood supply are recommended as an organizational strategy. Parathyroid glands must be correctly identified to help prevent accidental excision. Where less than 3 glands are found during the procedure, the probability of complication is higher.[10]

Factors that could predict post-thyroidectomy hypocalcemia development can help start calcium supplements early and thereby protect the patients from early hypocalcemia. In several studies, the occurrence of post-thyroidectomy hypocalcemia was correctly predicted by post-operative parathyroid hormone, which was lower than the value intraoperatively, or on the same day of the surgery, between 8 and 15 Pg/mL.[8]

Aim

This study aimed to determine the prevalence of post-operative hypocalcemia in patients undergoing total thyroidectomy.

MATERIALS AND METHODS

This prospective study was performed in the general surgery department from August 2018 to August 2020. The study included all patients who underwent total thyroidectomy. A total of 40 patients of both genders were enrolled for the study. All patients in the study were above 18 years of age. To prevent previously altered parathyroid functions, we excluded patients with altered pre-operative levels of calcium and excluded patients with prior radiation history, including those with a calcium supplement already excluded.

Post-operative Variables

Post-operative serum calcium levels (24 h after surgery) recorded. Postoperatively, hypocalcemic symptoms such as tingling and numbness of fingers, perioral region, muscles spasms, paresthesia, Chvostek's, and Trousseau's sign were noted if present. Histopathology reports were followed up to assess the condition of parathyroid glands in the surgical specimen. We have considered the presence of early hypocalcemia for calcium serum levels lower than 8.0 mg/dl measured 24 h after surgery.

Patients with near-total thyroidectomy were excluded from the study. To prevent previously altered parathyroid functions, we excluded patients with altered pre-operative calcium levels and excluded patients with prior radiation history, including those with a calcium supplement already excluded from the study.

RESULTS

A total of 40 patients have enrolled in the study; out of them, 36 patients were female and only 4 were male [Figure 1].

Patients enrolled for the study were divided into four groups, of which 13 patients were in the age group between <30, 15 were between 31 and 40 years, 8 were between 41 and 50 years, and 4 patients had >50 years [Figure 2]. The result showed that patients in the age group of 31–40 years were the highest and least in the age group of more than 50 years in our study.

The pre-operative surgical indication predisposing for total thyroidectomy consisted, 4 patients of malignancy, 14

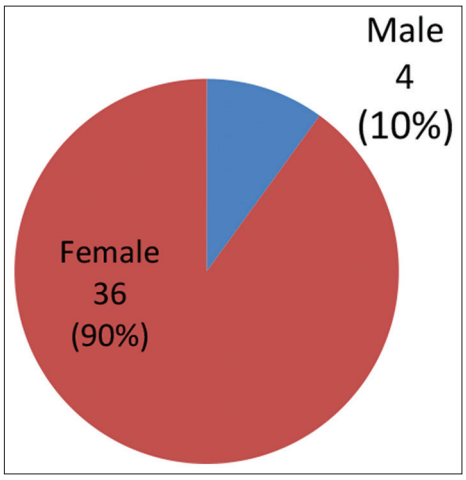

Figure 1: Distribution of gender in the patients

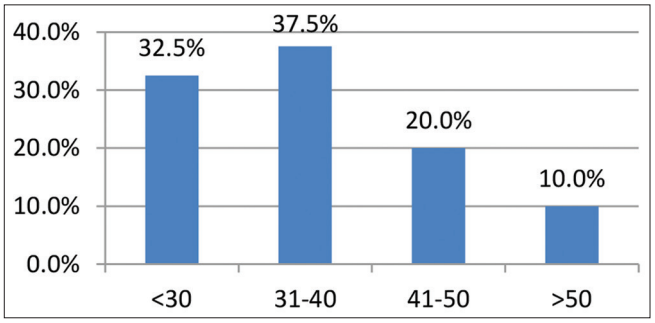

Figure 2: Distribution of age in the patients

patients of toxic features, and 22 patients with swelling/goiter [Figure 3]. Based on the result, the patients with swelling/goiter (55%) were the highest and patients with malignancy (10%) were the least in the study.

Based on evaluation of post-operative serum calcium level, it was observed that 16 patients had hypocalcemia and 24 patients had no hypocalcemia [Figure 4].

DISCUSSION

Post-operative hypocalcemia is a significant concern after a thyroid operation. It often increases the duration of hospitalization and significantly increases the overall cost of a thyroidectomy.[1,2] When severe, it can lead to severe complications and requires therapy to alleviate clinical symptoms and prevent serious complications.[4,5] The mechanism of hypocalcemia after thyroidectomy is not precisely disclosed, although it is accepted to be multifactorial; factors such as surgical technique, parathyroid damage (injury, edema, infarction, and ischemia), the extent of thyroidectomy, hyperthyroidism, malignancy, patient gender, perioperative serum calcium drop, presence of thyroiditis, diabetes, and number of the identified parathyroid gland during surgery can be considered as etiological factors.[11]

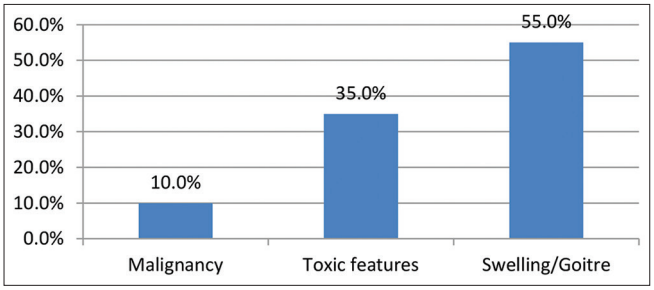

Figure 3: Pre-operative indication for total thyroidectomy

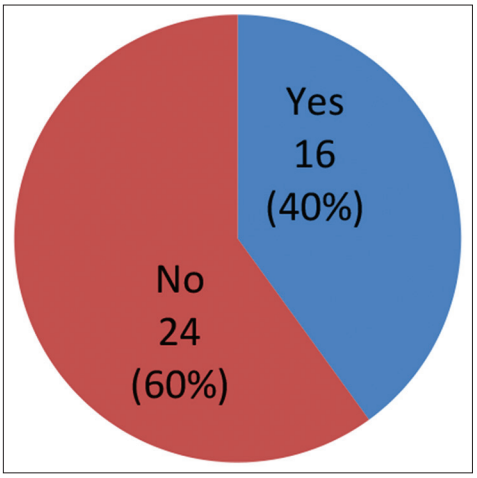

Figure 4: Post-operative hypocalcemia observed

After thyroidectomy, hypocalcemia is observed within 12 h after the operation, and it resolves spontaneously by 24 h in most patients. Hypocalcemia can remain permanent when caused by irreversible injury to the parathyroid glands.[12] The patients must be monitored before discharge to avoid the development of clinically relevant hypocalcemia.

In our study, 40% of patients showed post-operative hypocalcemia, whereas 60% of patients did not show any post-operative hypocalcemia; these findings are consistent with Sperlongano *et al.* study, which observed hypocalcemia in 27 out of 180 patients following thyroidectomy in total with 40.7%, 22.2%, 29.6%, 3.7%, and 3.7%, 2nd, 4th, and 5th day, hypocalcemia in all cases.[13]

Babu carried out their study in 75 patients who underwent total thyroidectomy; he found that 26 patients had hypocalcemia and 49 patients had no hypocalcemia.[14]

In another prospective study of 102 Pasque *et al.* patients, 18 patients experienced hypocalcemia, 38.8% on the 1st day after surgery, 22.2% on the 2nd day after surgery, and 33.3% on the 3rd day off, and 5.5% on the 4th day after the surgery.[12]

CONCLUSION

Transient hypocalcemia is one of the most common post-operative complications following thyroid surgery in clinical practice. It can be prevented with pre-operative preparation of patients with extreme caution and meticulous pre-operative dissection, prompt identification of parathyroids, and frequent post-operative monitoring of serum calcium.

REFERENCES

1. Chao TC, Jeng LB, Lin JD, Chen MF. Completion thyroidectomy for differentiated thyroid carcinoma. Otolaryngol Head Neck Surg 1998;118:896-9.
2. Cohen-Kerem R, Schachter P, Sheinfeld M, Baron E, Cohen O. Multinodular goiter: The surgical procedure of choice. Otolaryngol Head Neck Surg 2000;122:848-50.
3. Harris AS, Prades E, Tkachuk O, Zeitoun H. Better consenting for thyroidectomy: Who has an increased risk of postoperative hypocalcaemia? Eur Arch Otorhinolaryngol 2016;273:4437-43.
4. Bhattacharyya N, Fried MP. Assessment of the morbidity and complications of total thyroidectomy. Arch Otolaryngol 2002;128:389-92.
5. Demeester-Mirkine N, Hooghe L, van Geertruyden J, de Maertelaer V. Hypocalcemia after thyroidectomy. Arch Surg 1992;127:854-8.
6. Morris LF, Waguespack SG, Warneke CL, Ryu H, Ying AK, Anderson BJ, *et al*. Long-term follow-up data may help manage patient and parent expectations for pediatric patients undergoing thyroidectomy. Surgery 2012;152:1165-71.
7. Thomusch O, Machens A, Sekulla C, Ukkat J, Lippert H, Gastinger I, *et al*. Multivariate analysis of risk factors for postoperative complications in benign goiter surgery: Prospective multicenter study in Germany. World J Surg 2000;24:1335-41.
8. Sands NB, Payne RJ, Côté V, Hier MP, Black MJ, Tamilia M. Female

gender as a risk factor for transient post-thyroidectomy hypocalcemia. Otolaryngol Head Neck Surg 2011;145:561-4.
9. Pfleiderer AG, Ahmad N, Draper MR, Vrotsou K, Smith WK. The timing of calcium measurements in helping to predict temporary and permanent hypocalcaemia in patients having completion and total thyroidectomies. Ann R Coll Surg Engl 2009;91:140-6.
10. Wingert DJ, Friesen SR, Iliopoulos JI, Pierce GE, Thomas JH, Hermreck AS. Post-thyroidectomy hypocalcemia. Incidence and risk factors. Am J Surg 1986;152:606-10.
11. Garrahy A, Murphy MS, Sheahan P. Impact of postoperative magnesium levels on early hypocalcemia and permanent hypoparathyroidism after thyroidectomy. Head Neck 2016;38:613-9.
12. Pasquale S, Rossella S, Adriano M, Salvatore M, Emanuela E, Alessandro E, *et al*. Post thyroidectomy hypocalcemia: Timing of discharge based on serum calcium levels. Surg Res Open J 2015;2:62-5.
13. Sperlongano P, Sperlongano S, Foroni F, Lucia FP, Pezzulo C, Manfredi C, *et al*. Postoperative hypocalcemia: Assessment timing. Int J Surg 2014;12 Suppl 1:S95-7.
14. Babu ST. A study of post-operative hypocalcemia in thyroidectomy patients: Prospective observational study. Int J Sci Stud 2021;8:92-5.

How to cite this article: Subalakshmi N, Kannaki R. Study of Post-operative Hypocalcemia in Total Thyroidectomy Patients: A Prospective Study. Int J Sci Stud 2021;9(1):140-143.

Source of Support: Nil, **Conflicts of Interest:** None declared.

Print ISSN: 2321-6379
Online ISSN: 2321-595X

Original Article

A Study of Parameters of Lower Ends of Radius and Their Significance

Pankaj Kumar[1], Anshu Sharma[2]

[1]Demonstrator, Department of Anatomy, Government Medical College and Hospital, Chandigarh, India, [2]Professor and Head, Department of Anatomy, All India Institute of Medical Sciences, Raebareli, Uttar Pradesh, India

Abstract

Introduction: Lister's tubercle is the prominent bony tubercle over the dorsal aspect of the distal radius. Lister's tubercle is used as a standard anatomical landmark in hand surgery and arthroscopy procedures.

Material method and objective: In this study we aimed to identify the anatomical localization of Lister's tubercle in relation to the radial styloid process and the ulnar notch of radius and to evaluate its clinical and surgical importance. The present study was done on 50 (right = 23, left=27) dried adult cadaver radii. Vernier caliper was used to measure the distances from lister's tubercle to radial styloid process and to ulnar notch. Ratio of two measures was calculated.

Result and observations: We found that the position of lister's tubercle was variable. It was nearer to the radial styloid process in 13 radii and it was nearer to the ulnar notch in 37 radii. The radial Angle of inclination was found to be 15.55° in our study which is much less than other studies. This anatomical variation of Lister's tubercle and angle of has potential clinical implications for certain pathological conditions and pre-procedural planning

Key words: Extensor pollicis longus, Lister's tubercle, Radial styloid process, Ulnar notch

INTRODUCTION

Lister's tubercle is the prominent bony tubercle over the dorsal aspect of the distal radius. It acts as a pulley for the extensor pollicis longus (EPL) tendon before the tendon pivots and turns obliquely to insert onto the distal phalanx of the thumb. As a palpable structure, Lister's tubercle has been used as an anatomical landmark for localizing the first dorsal extensor compartment, posterior interosseous nerve, superficial branch of the radial nerve, and dorsal radiotriquetral ligament.[1] Lister's tubercle is also used as a landmark in wrist arthroscopy, wrist joint injections, and similar surgical and clinical procedures. However, there is no useful information in the reference anatomy books and literature. Besides being an anatomic landmark during surgery, there is also some clinical importance to the anatomical localization of Lister's tubercle. For example, when the screws are applied in unsuitable orientation and length, during volar plate fixation for distal radius fractures, they may irritate the EPL tendon which lies in the groove medial to the dorsal tubercle. This may cause EPL tendon ruptures over a long period. The aim of this study was to identify the anatomical localization of tubercle on the dorsum of radius in relation to the radial styloid or ulnar notch (sigmoid notch) of the radius and to demonstrate the clinical and surgical importance of its position.[2]

Access this article online

www.ijss-sn.com

Month of Submission : 02-2021
Month of Peer Review : 03-2021
Month of Acceptance : 03-2021
Month of Publishing : 04-2021

MATERIALS AND METHODS

The present study was done on 50 (right = 23 and left = 27) dried adult cadaver radii. All radii were from separate individuals and had completed their development. In the present study, the parameters were measured on the radii using Vernier caliper.

Following were the various landmarks used for the measurements of parameters:

1. Point 1 – Midpoint of the Lister's tubercle
2. Point 2 – Midpoint of the distance between volar and dorsal borders of the ulnar notch (the height of the ulnar notch)

Corresponding Author: Dr. Anshu Sharma, Department of Anatomy, All India Institute of Medical Sciences, Raebareli, Uttar Pradesh, India.

3. Point 3 – The midpoint of radial styloid process
4. Point 4 – Point of intersection of two lines. First drawn from midpoint of the height of the ulnar notch (point 2) to the midpoint of the radial styloid process (point 3), second from Lister's tubercle to this line.

Measurements taken on the radii
1. Length of radius – distance between the most lateral portions of the radial head to tip of radial styloid
2. Distance from Lister's tubercle to radial styloid – distance between point 3 and point 4
3. Distance from Lister's tubercle to ulnar notch – distance between point 2 and point 4
4. Ratio – distance from Lister's tubercle to radial styloid/ distance from Lister's tubercle to ulnar notch
5. Angle of radial inclination – the angle between a line joining the tip of radial styloid and the medial edge of the distal end of radius and a line perpendicular to the long axis of the radius.

RESULTS

Study done on the 50 dried cadaver radii showed that Lister's tubercle was nearer to the styloid process in 13 of the radii while it was nearer to the ulnar notch in 37 radii. The distance from Lister's tubercle to the radial styloid process extended between 9 mm and 16 mm [Table 1], whereas the distance from Lister's tubercle and ulnar notch extended between 11 mm and 17.1 mm [Table 1]. The highest ratio of the two distance was 1.30 (the nearest distance to the ulnar notch) while the lowest was 0.52 (the nearest distance to the radial styloid) [Table 1].

The mean length of radius in all subjects was 23.17 cm. Mean angle of radial inclination in all subjects was 15.55° [Table 2]. In our study, we have found a statistically significant correlation between length of radius and angle of radial inclination [Table 3]. In our study, we observed that angle of radial inclination increases with the increase in length of radius [Figure 1].

DISCUSSION

The dorsal surface of lower end of radius displays a palpable dorsal tubercle also called Lister's tubercle which is in line with the cleft between the index and middle fingers. There is a wide, shallow groove medial to the tubercle divided by a faint vertical ridge. The dorsal tubercle of radius receives a slip from the extensor retinaculum and is grooved medially by the tendon of EPL.[3]

Anatomical variation of Lister's tubercle has potential clinical implications for certain pathological conditions and pre-procedural planning.[1] Although the function of the tubercle is defined in reference anatomy books and in related literature, the position of it is not defined. Lister's tubercle is used as a landmark in wrist arthroscopy and wrist injections.[2]

In the present study, there is variation in the position of the Lister's tubercle on the radius. Either it is close to radial styloid process or to the ulnar notch. This knowledge of the position of the Lister's tubercle may helpful during the procedures of wrist and hand.

Agir *et al*. studied 27 cadaver radii and found that there is variation in the position of Lister's tubercle along the dorsal surface of the lower end of radius between the radial styloid process and ulnar notch. Their study suggested possible implications in various procedures of the region. In the present study, we also found differences in the location of Lister's tubercle.[2]

Pichler *et al*. measured the size of Lister's tubercle and also the extent of the EPL groove using computed tomography and three-dimensional analysis of 30 forearms. There is considerable variation in their study results. They suggested that increased height of Lister's tubercle and a deep EPL groove may increase the risk of dorsal screw penetration and lead to EPL rupture.[4]

Hazani *et al*. defined Lister's tubercle as an anatomical landmark for the first dorsal compartment. A point for the injections into the first dorsal compartment is determined by them in their study to manage de Quervain's disease.[5]

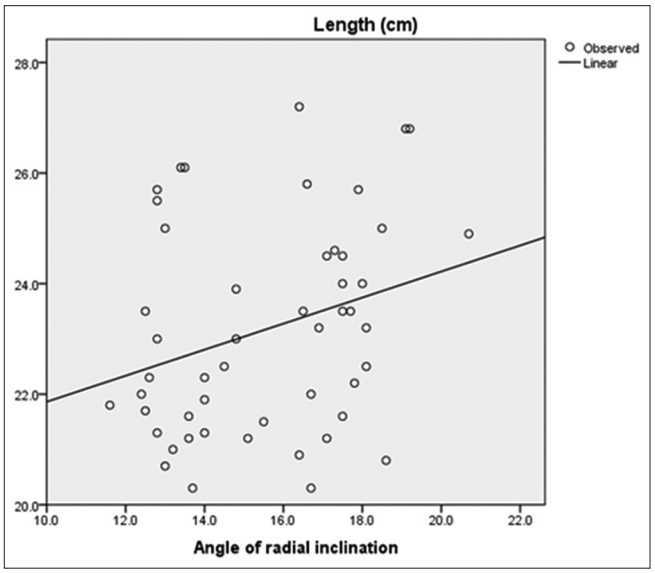

Figure 1: Graph showing correlation between length of radius and angle of radial inclination

Table 1: Distance from lister's tubercle to radial and ulnar notch and ratio between two measurements

	Distance from lister's tubercle to radial styloid (mm)	Distance from lister's tubercle to ulnar notch (mm)	Ratio
1	10	14.5	0.68
2	13.5	15	0.9
3	14	12.7	1.10
4	12.5	14	0.89
5	15	14	1.07
6	10.5	12.5	0.84
7	15	13.8	1.08
8	11.2	16	0.7
9	11.3	14.7	0.76
10	12.2	12.7	0.96
11	13	15.2	0.85
12	12.1	14.5	0.83
13	10.5	15	0.7
14	11.5	14.5	0.79
15	10.5	15	0.7
16	13.5	13	1.03
17	13.5	15.5	0.87
18	12	14	0.85
19	11	13	0.84
20	10	15	0.66
21	12	13	0.92
22	10	14.2	0.70
23	10.5	13.1	0.80
24	16	16.5	0.96
25	11	15.4	0.71
26	11	15	0.73
27	14	12.5	1.12
28	12	14.2	0.84
29	11	17	0.64
30	11	16	0.68
31	15	13.3	1.12
32	12	15.2	0.78
33	12	15	0.8
34	13	11	1.18
35	13	12	1.08
36	15	13	1.15
37	9	17.1	0.52
38	11	13	0.84
39	10.5	12.4	0.84
40	9.2	15	0.61
41	13.3	12	1.10
42	11.2	17	0.65
43	12	16.9	0.71
44	10	14	0.71
45	15.2	14	1.08
46	15.1	14.2	1.06
47	14	14.1	0.99
48	12	15	0.8
49	14.3	11	1.3
50	14	15.5	0.90

Table 2: Measurements of length of radius and angle of radial inclination

	Mean	Std. Deviation	N
Length (cm)	23.172	1.9099	50
Angle of radial inclination	15.558°	2.3333	50

Clement *et al.* measured the morphometry of Lister's tubercle in 100 cadaver radii. They measured the height of Lister's tubercle and depth of the EPL groove. The increased height of Lister's tubercle and a deep EPL groove in certain individuals could potentially obscure the field of view of surgeons during volar plate fixation. Greater differences in

Table 3: Correlation between length of radius and angle of radial inclination

		Length (cm)	Angle of radial inclination
Length (cm)	Pearson Correlation	1	0.288*
	Sig. (2-tailed)		0.043
	N	50	50
Angle of radial inclination	Pearson Correlation	0.288*	1
	Sig. (2-tailed)	0.043	
	N	50	50

*Correlation is significant at the 0.05 level (2-tailed)

Table 4: The comparison of angle of inclination given by different authors[6-9]

Parameter	Gupta *et al.* (Indian Cadaveric Study)	Prithishkumar *et al.* (Indian cadaveric study)	Werner *et al*	Schuind *et al.*	Our Study
Angle of inclination	Total: 25.05° Left side: 24.0° Right side: 25.6°	Left side: 21.8°±2.5 Right side: 22.1°±2.9	30°	24 (19-29)°	15.55°

heights of the radial and ulnar peaks are possibly associated with an increase in the perceived height of Lister's tubercle.[3]

In our study, we also found correlation between length of radius and angle of inclination which increased with length of radius. Among fractures of forearm bones, fracture of distal end of radius contributes around 15–18% of upper extremity fractures.[5] These parameters are useful in obtaining restoration of original angle and volar tilt. They also help in knowing success of the operation.

In literature, different studies show the angle of radial inclination varying from 24 to 30 [Table 4].[6-9] In our study, we found 15.5°.

CONCLUSION

In our study, we found that mean length of radius in all subjects was 23.17 cm. Mean angle of radial inclination in all subjects was 15.55°. We also found a statistically significant correlation between length of radius and angle of radial inclination and the angle of radial inclination increased with the increase in length of radius. These parameters help in regaining the original shape and angle postoperatively.

REFERENCES

1. Chan WY, Chong LR. Anatomical variants of Lister's tubercle: A new morphological classification based on magnetic resonance imaging. Korean J Radiol 2017;18:957-63.
2. Agir I, Aytekin MN, Kucukdurmaz F, Gokhan S, Cavus UY. Anatomical localization of Lister's tubercle and its clinical and surgical importance. Open Orthop J 2014;8:74-7.
3. Clement H, Pichler W, Nelson D, Hausleitner L, Tesch NP, Grechenig W. Morphometric analysis of Lister's tubercle and its consequences on volar plate fixation of distal radius fractures. J Hand Surg Am 2008;33A:1716-9.
4. Pichler W, Windisch G, Schaffler G, Rienmüller R, Grechenig W. Computer tomography aided 3D analysis of the distal dorsal radius surface and the effects on volar plate osteosynthesis. J Hand Surg Eur 2009;34:598-602.
5. Hazani R, Engineer NJ, Cooney D, Wilhelmi BJ. Anatomic landmarks for the first dorsal compartment. Eplasty 2008;8:e53.
6. Gupta C, Kalthur S, Malsawmzuali J, D'souza A. A morphological and morphometric study of proximal and distal ends of dry radii with its clinical implications. Biomed J 2015;38:323-8.
7. Prithishkumar IJ, Francis DV, Nithyanand M, Verghese VD, Samuel P. Morphometry of the distal radius-an osteometric study in the Indian population. Indian J Basic Appl Med Res 2012;1:166-71.
8. Werner FW, Palmer AK, Fortino MD, Short WH. Force transmission through the distal ulna: Effect of ulnar variance, lunate fossa angulation, and radial and palmar tilt of the distal radius. J Hand Surg Am 1992;17:423-8.
9. Schuind FA, Linscheid RL, An KN, Chao EY. A normal data base of posteroanterior roentgenographic measurements of the wrist. J Bone Joint Surg Am 1992;74:1418-29.

How to cite this article: Kumar P, Sharma A. A Study of Parameters of Lower Ends of Radius and Their Significance. Int J Sci Stud 2021;9(1):144-147.

Source of Support: Nil, **Conflicts of Interest:** None declared.

Print ISSN: 2321-6379
Online ISSN: 2321-595X

Original Article

Comparison between Z-Plasty versus Limberg Flap Technique in the Management of Sacrococcygeal Pilonidal Sinus

Ramana Prakash Baraju[1], B Vinay Babu[2], Ranjith Kumar Gatika[3], Goparaju Shanti Kumar[2], Divvela Mohan Das[4]

[1]Assistant Professor, Department of General Surgery, Mahatma Gandhi Memorial Hospital, Kakatiya Medical College, Warangal, Telangana, India, [2]Associate Professor, Department of General Surgery, Government Medical College, Suryapet, Telangana, India, [3]Postgraduate, Department of General Surgery, Mahatma Gandhi Memorial Hospital, Kakatiya Medical College, Warangal, Telangana, India, [4]Professor, Department of General Surgery, Mahatma Gandhi Memorial Hospital, Kakatiya Medial College, Warangal, Telangana, India

Abstract

Background: There are controversies about the etiology and management of primary and recurrent pilonidal sinus (PNS), and also there are number of techniques of treatment in treating PNS among which no single procedure is superior in all aspects.

Aim of the Study: The aim of this study was to compare two operative procedures (modified Limberg flap [MLF] vs. Z-plasty flap [ZPF]) in the management of sacrococcygeal PNS, regarding their complications including recurrence of the disease, hospital stay, day off work, post-operative complications, and morbidity.

Materials and Methods: This is comparative prospective study between MLF and ZPF in treatment of sacrococcygeal PNS. Thirty patients were divided into two groups: Group (1) treated with MLF and Group (2) treated with Z-plasty, and we follow up of the patients in both groups for post-operative complications, hospital stay, day off work, recurrences, and patients satisfactions.

Results: Operative time, hospital stay duration, and complete wound healing were longer in Group (2) Z-plasty group. Mobilization was early in MLF group than Z-plasty group (1 day vs. 2 days). Time to return to work, it was 14 (12–16) days in the MLF groups and 18 (15–22) in the Z-plasty group. Infection occurred only in one in the MLF Group (1) and two patients in the Z-plasty group (2). The mean time for complete healing of the wound after MLF Group (1) was 16 ± 4.2 days while in Z-plasty Group (2), it was 22 ± 6.8 days. Satisfaction score was better in MLF Group (1). Recurrence had not occurred in any of the patients included in this study during the follow-up period.

Conclusion: Both MLF and Z-plasty techniques are used to cause flattening of the natal cleft, thus reducing local recurrence rates. Hence, we recommend the use of flap technique for PNS patients. However, modified Limberg transposition flap is better than ZPF, because of the less hospital stay, early return to work, and cosmetically more accepted since it has less post-operative complications. Furthermore, ZPF has a major limitation as it is difficult to apply if there is a wide defect in the horizontal axis.

Key words: Modified limberg flap, Sacrococcygeal pilonidal sinus, Z-plasty

INTRODUCTION

Pilonidal sinus (PNS) literally means a cavity or sinus containing hairs (Pilus = hair, Nidus = nest) presentation range from asymptomatic pits to painful draining lesions in the intergluteal region. PNS has a male preponderance[1] and usually affects patients from mid-teens to early thirties.

Congenital and acquired theories have been proposed.[2-4] Initially, the entity was referred as jeep riders disease. Over 80,000 US army soldiers were hospitalized during World War II contributed much information about the disease, what we have today.

The pathology of PNS is an established one. There are one or more pits in the midline of the natal cleft. These pits lead to a cavity lined by granulation tissue and contain hairs.

Access this article online

www.ijss-sn.com

Month of Submission : 02-2021
Month of Peer Review : 03-2021
Month of Acceptance : 03-2021
Month of Publishing : 04-2021

Corresponding Author: Dr. B. Vinay Babu, Department of General Surgery, Government Medical College, Suryapet, Telangana, India.

Usually, from this cavity, one or more track run caudally and open either on the right or left of the midline. The secondary sinus is always laterally placed while the primary sinus is in the midline.

Numerous surgical techniques are employed for postnatal sacrococcygeal PNS. The exact procedure is determined by nature of disease presentation and the surgeons choice.

Aims and Objectives of the Study

Although this is no longer at the time of war, the duration of time spent in traffic is increasing day by day and also increase in the sedentary lifestyle has brought this disease renewed attention. It would not be surprise if more of software engineers rather than soldiers show up with the disease.

In our study, we wanted to compare two operative procedures (modified Limberg flap [MLF] vs. Z-plasty flap [ZPF]) in the management of PNS, regarding their

1. Complications
2. Duration of hospital stay
3. Time taken for wound healing
4. Time taken for return to work
5. Recurrence.

Management

The management of the PNS depends on the presentation of the disease. The common clinical presentations of the PNS disease are categorized into three categories. These are:

1. Acute pilonidal abscess
2. Chronic pilonidal disease
3. Complex or recurrent pilonidal disease.

The surgical management is then tailored to the above classification category. The goals of the ideal procedure for the treatment of this disease should be:

1. Low recurrence rate with better wound healing
2. Lesser hospital stay
3. Convenience to the patient
4. Less complications with fewer morbidity
5. Early return to normal activities as early as possible.

Various non-surgical and surgical modalities of treatment have been advocated in the management of pilonidal disease.

Non-surgical

- Injection of sclerosing agent
- Fibrin glue
- Cryosurgery
- Electrocauterization
- Repeated shaving or use of depilation creams.

Surgical

- Drainage with/without excision
- Marsupialization
- Excision with healing by secondary intention
- Excision with primary closure.

To prevent the recurrence rate and chronicity, various other techniques are brought into action. They are

- Karydaki's flap
- Bascom procedure
- Modified Bascom procedure.

Moreover, other procedures which use the technique of transposition flaps have been described. They are:

- Z-plasty
- V-Y fasciocutaneous advancement flap
- Crossed triangular flaps
- Gluteus maximus musculocutaneous flap
- Rhomboid flap of Limberg.

The above-mentioned surgeries have low recurrence rate by reducing the depth of the natal cleft and place the suture line away from the midline natal cleft and with low tension at the suture lines.

MATERIALS AND METHODS

This prospective randomized study was conducted at general surgery department at MGM Hospital, Warangal, during the period from June 2017 to August 2019. Thirty patients who were suffering from pilonidal disease were included in this study. Thirty patients were divided into two groups: Group (1) treated with MLF and Group (2) with ZPF.

Inclusion Criteria

The presence of sacrococcygeal PNS, patients willing to give written informed consent, adult (over 18 years of age) with PNS disease, patients fit for surgery with normal coagulation profile, and patients with no infection at time of surgery were included in the study.

Exclusion Criteria

Patients not willing to give informed consent, patients were unfit for surgery, age <18 year, patients presented with *de novo* PNS (presented for the 1st time), and patients with chronic medical conditions, such as diabetes mellitus, renal failure, immune suppression, or patients with defect in coagulation profile.

Informed consent was obtained from all patients and this study was approved by local ethics committee.

All patients were subjected to careful history taking: Duration of symptoms, previous operations, previous post-

operative complications, recurrence time after previous operations, presence or absence of discharge, and pre-operative routine laboratory investigations.

All patients were prospectively evaluated in terms of age, sex, body mass index (BMI), duration of pre-operative symptoms, location of sinus pits (midline or paramedian), numbers of pits (single or multiple) and followed up in post-operative time regarding hospital stay, return to work, post-operative complications (wound dehiscence, infections, hematoma, seroma, and cosmetics scars), satisfaction score, and recurrence.

All the patients followed up in outpatient's clinic after operation till complete wound healing and removal of suction drain and stitches then every 3 months for the 1st post-operative year then yearly afterward unless if there were any complaint. If the patient is from distant area, we contact him by telephone. Follow-up period ranges from 12 months to 30 months.

Procedure

Pre-operative preparation included shaving on the day of surgery and broad-spectrum antibiotic on the night before and at start of surgery.

MLF Method

The operation was performed as described by Mentes *et al*. Most of patients in this study were operated under spinal anesthesia in the operating room (only two patients requested general anesthesia). After anesthesia, the patients were placed in the prone, jack-knife position, with the buttocks strapped apart using wide adhesive tape, then marking of skin with marker pen to draw MLF to pass to other side to center the flap 1 cm from midline. The excision was carried down to the fascia overlying the sacrum and laterally to the fascia of the gluteus maximus muscle. Dissection was performed with electrocautery. Elliptical inverted triangular and rhomboid were used to include all sinuses. After excision, a Limberg flap (LF) was prepared from the right or left gluteal region, the subcutaneous tissues were closed with 3/0 polyglactin (Vicryl), and skin with 3/0 Prolene interrupted suture and compression dressing was applied. Suction was placed through a separate incision that was located 2 cm lateral from the initial incision and kept in place until the drainage decreased to <10 ml/day.

Limberg Rhomboid Flap Advantages

- Used to cover large defects
- Least likely to necrose as it is a well vascularized flap
- Flattens the gluteal cleft
- Closure can be achieved without tension
- Mean hospital stay is 6 days
- Recurrence rate is 4% following a follow-up period of 74 months.

Procedure

- Rhomboid incision made around the PNS and excision of all the existing sinuses down up to the presacral fascia carried out
- Incision enclosed rhombic area of skin, subcutaneous fat, and sinuses excised along with lateral extensions
- Long axis of the rhomboid is in midline and the short axis is transversely placed.

Measurements

- Rhomboid
- Line A–C drawn
- Point C adjacent to the perineal skin
- Point A placed so that all diseased tissue can be included in the excision
- Line B-D transects the mid-point of A-C at the right angles and is 60% of its length
- D-E is a direct continuation of line B-D and is of equal length to the incision B-A, to which it will be sutured after rotation
- E-F is parallel to D-C and of equal length. After rotation, it will be sutured to A-D
- Flap consists of skin and fat and is constructed by extending the incision to the gluteal muscle fascia. The skin is approximated after insertion of a vacuum drain.

ZPF

Steps as modified Limberg except skin flaps were raised and transposed. Each limb of Z was equal in length. Angle of the flaps was roughly equal to 60°. Excision including all pits between marks and closed in Z-shaped flap which was mobilized easily and not under tension.

Post-operative management

After operation it includes post-operative antibiotics, analgesics, daily dressing and suction was removed when <10 ml/day amount. Clinical assessment was performed at the end of the 5th post-operative day and 1, 3, 6 months, and 12 months following surgery.

Satisfaction score

For performing a patient's satisfaction score we asked, a standard question to every patient: Are you satisfied with outcome of your surgical treatment? The answers were scored in a discrete ordinal scale from 1 to 4 with 4 for excellent, 3 good, 2 fair, and 1 poor.

Statistical analysis

For all statistical analyses, $P < 0.05$ was considered statistically significant.

Z-Plasty

Principle

Obliterating the natal cleft and increasing the transverse length by recruiting the lateral tissue.

Procedure

- Excision of the midline sinus
- From the ends of the midline wound, the limbs of the "Z" are cut
- Subcutaneous flaps are raised up to the level of fascia
- Transposition of the flaps carried out
- Skin is closed.

Mansoory and Dickson used this technique on 120 patients and reported a complication rate of 4% and a recurrence rate of 1.65% after a follow-up for 9 years. The patients were discharged on post-operative day 1 and they returned to work 2 weeks later.

RESULTS AND ANALYSIS

Thirty patients were included in this study from June 2017 to August 2019, of whom 15 patients were treated using the MLF procedure and 15 patients were treated using the ZPF.

Ages of both groups range from 18 to 40 years with mean age in the MLF Group (1) about 23 years and 24 years in the Z-plasty Group (2). Most patients of both groups were males only four females in Group (1) and one female in Group (2).

Sex Distribution in both Groups

There was no significant difference between the two groups in age, BMI, sinus pits location, or presence of multiple or single pits but most pits were multiple and in midline in both groups.

Relation to Obesity in both Groups

About 27% of patients with sacrococcygeal pilonidal disease in our study were overweight (BMI: 25–29). Pre-operative durations of symptoms were nearly equal in both groups with ranges from 9 to 12 months with average 11 months.

Patient Complaints

The main complaints in both groups were pain then discharges and there was no significant difference between both groups regarding pre-operative complaints.

In the present study, majority complained of pain, discharge, and sinus, one presented with swelling.

Complaints	No. of cases	Percentage
Pain	30	100
Discharge	30	100
Sinus	30	100
Swelling	1	3.33

PNS in Relation to the Operative Time and Early Mobilization

Regarding operative time, there was a significant difference between both groups as it was longer in Z-plasty Group (2) than modified Limberg Group (1) also hospitalization was longer in Z-plasty Group (2) than MLF Group (1). Mobilization was early in the MLF group than the Z-plasty group as mean time to first mobilization was earlier in MLF Group (1) than Z-plasty Group (2) (1 day vs. 2 days) with mean (1–1) day versus 2 (1–3) days, respectively.

In Relation to Regarding Return to Work

As regarding suction drain usage, removal of suction drain was early in MLF Group (1) than Z-plasty Group (2) but without significant statistical difference. As regarding return to work, it was 14 (12–16) days in MLF Group (1) and 18 (15–22) days in Z-plasty Group (2). Satisfaction score was good to excellent in MLF Group (1) better than in Group (2) (Z-plasty) which was poor to good.

Post-operative Complications Results in MLF Versus Z-Plasty

As regarding post-operative complications: Only one patient had infections in MLF Group (1) and two patients in Z-plasty Group (2).

Seroma not occurred in any patient in MLF Group (1) and occurred in two patients in Z-plasty Group (2) which treated conservatively without intervention. Wound dehiscence had occurred only in one patient in Z-plasty Group (2) and treated successfully with daily dressing. As regarding flaps: Partial flap ischemia was occurred in one patient in MLF Group (1) and three patients in Z-plasty Group (2) and treated conservatively but total flap necrosis did not occur in any patient in both groups and flap edema had occurred in one patient in the MLF Group (1) and two patients in Group (2) so regarding flaps, there was no statistical difference in flap complications; just complications were lower in Group (1) than Group (2).

In Relation to Complete Wound Healing

The mean time for complete healing of the wound after MLF Group (1) were 16 ± 4.2 days while in Z-plasty Group (2) were 22 ± 6.8 days and irregular scar formation occurred only in one patient in Group (1) and four patients in Group (2).

When patient's satisfaction for post-operative cosmetic appearances was compared, there was a good acceptance from patients for modified Limberg scars than Z-plasty scars. Recurrence had not occurred in any of the patients included in this study during the follow-up period [Figures 1 and 2].

RESULTS AND ANALYSIS

Clinical comparison between two groups		
Parameter	**MLF Group (1)**	**ZPF Group (2)**
No. of patients in each group	15	15
Sex (M/F)	11/4	14/1
Age (years)	23	24
Site	0	
Midline single	12	11
Midline multiples	3	4
Para-midline	0	0
Duration of pre-operative complaints (months)	10.45±3.2	11.3.4±9.45
Main complaint		
Pain	15	15
Discharge sinus	15	15
Obesity		
Average BMI<25	12	11
Overweight (BMI 25–29.9)	2	3
Obese (BMI 30–39.9)	1	1
Morbidly obese (BMI≥40)	0	0

BMI: Body mass index

Operative and post-operative out comes in both groups		
Parameter	**MLF Group (1)**	**ZPF Group (2)**
Duration of operation (minutes)	52 (45–70)	75 (60–90)
First mobilization (day)	1 (1–1)	2 (1–3)
Painless toilet seating (days)	1 (1–2)	2 (1–3)
Drain usage	5.71±2.5	7.68±1.9
Length of hospital stay (days)	1.6 (1–4)	3.4 (3–7)
Time return to work	10 (8–15)	18 (14–22)
Pain VAS score	2 (1–3)	5 (2–6)
Complete healing time (day)	16 (14–24)	22 (18–28)
Patient satisfaction score	3.2±0.66	1.9±0.7
Follow-up (months)	14±8.6	15±7.8
Complications		
Wound infection	1	1
Seroma	0	2
Flap edema	1	2
Partial flap ischemia	1	3
Flap necrosis	0	0
Partial wound dehiscence	1	3
Total wound dehiscence	0	0
Irregular scar formation	1	4
Recurrence rate	0	0

DISCUSSION

PNS was described by Anderson in 1847 and by Hodges in 1880. Pilonidal as a word means "a nest of hair." PNS disease PSD is a benign chronic condition start with localized inflammation with abscess formation causing fistulae, sinuses, chronic inflammation, and discharge.

It may occur in many sites as axilla, umbilicus, and interdigital space but it is usually seen in the sacrococcygeal region (natal cleft), although it is chronic but often present with acute exacerbations. In the past, it was thought to be a congenital disease but recently, it is more accepted to be an acquired condition.

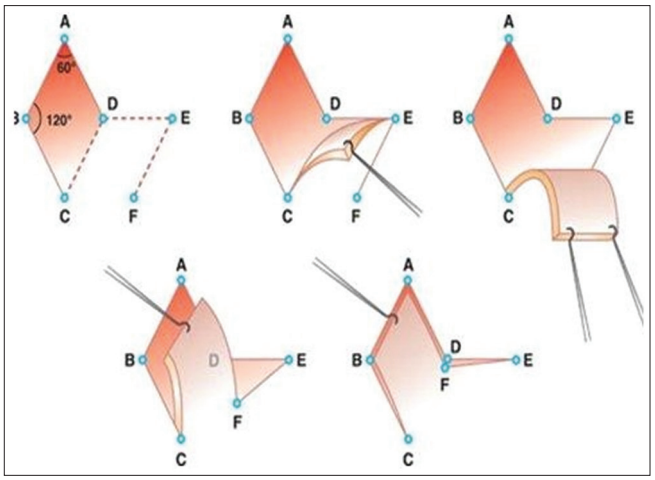

Figure 1: Diagrammatic representation of the Limberg flap

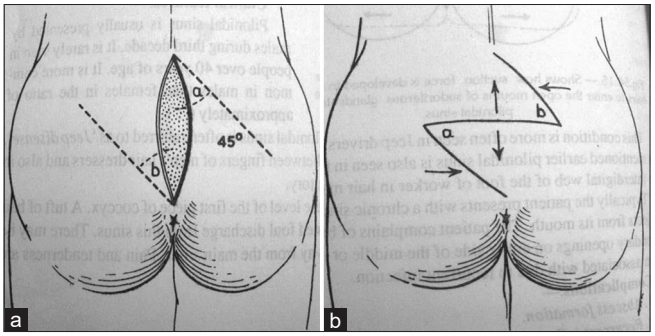

Figure 2: Z-plasty. (a) Marking of Z limbs a and b, (b) flaps created and transposition done and skin closed

It is mainly occurs in young age and more common in males than in females (male/female = 4–5/1). According to Gurer *et al.*, he reported a mean patient age of 25.5 and a gender balance of 95% males in a series about PNS disease.

In our study, mean age in both groups was 23 and 24 years, respectively, with range from 16 to 45 years and M:F was 6:1 with percentage 84%, although our study in recurrent group only, also many studies confirm that the disease is predominant in males. Although it is benign chronic disease, as it occurs in young adults in their main productive age so it has a negative impact on the socioeconomic condition, general economy, and financial state because it causes loss of work time, especially during acute exacerbations.

There are many risk factors implicated in occurrence of PSD including family history, local trauma, obesity, sedentary occupation, and poor body hygiene. There are many factors contributing in recurrences such as post-operative complications, obesity, smoking, size of sinus, and previous procedure used.

In the literature, there are two options which have been used for in the treatment of PSD, either conservative

medical methods or surgical treatment. Medical treatment options include alcohol, phenol, and silver nitrate injection into the cavity. Surgical treatment methods[5-8] include curettage after sinusotomy, excision, and leaving an open for secondary intention or marsupialized wound after excision, excision and primary closure, Bascom procedure, Karydakis flap procedure (KF), or sinus excision and skin flap methods, such as LF, ZPF, and MLF. Surgical treatment is the most preferred methods.

The use of complex plastic flaps for cleft obliteration is preferable in recurrent PNS. There is a disadvantage in surgical treatment of PSD in general as it is operator dependent. There is controversy about the ideal procedure for the treatment. The ideal treatment methods should result in rapid wound healing, short hospital stay, short period of work off days as most of patient are young working adult and working, less wound complications as seroma, dehiscence, infection, low recurrence rate, good patient satisfactions, and good cosmetic results. Hence, the main goal in the management of PNS should aim to complete excision of the sinuses and all pits with their ramifications, prevent wound complications that can result in recurrence, create an eccentric suture line, obliteration of the natal cleft using various flap techniques, improve local hygiene, and prevent hair regrowth in the site of the repair by always shaving hair in this area or any methods of hair ablation.

Recurrence is the main problem in the treatment of PNS and may occur due to inadequate excision, presence of dead space, deep midline gluteal clefts, poor personal hygiene, midline scar, early post-operative wound complications, excessive tension, and obesity. The lowest recurrence rates have been reported for procedures using local flap rotation. There are many flaps used in the treatment of recurrent PNS such as Z-plasty, W-plasty, KF, LF, MLF, rotation flap, gluteus maximus musculocutaneous flap, sacral adipofascial turn-over flap, cleft lift procedure, and V-Y fasciocutaneous advancement flap. In the literature, recurrence rates with flap procedures were ranging between 0 and 6%–8%.

In present study, if we compare prospectively between two flap procedures in treatment of PNS disease (MLF vs. ZPF) then its observed that both techniques not only cover the wound but also result in flattening of the natal cleft and decrease hair accumulation, decrease the mechanical irritation with low recurrence rates. Hence, both flaps had lowest recurrence rates reported in literature and this is important in the procedure used but in our study, we focused on other important factors sometimes neglected in many comparative study as hospital stay, time off work, and patients satisfactions.

This study was conducted on 30 patients in general surgery department at MGM Hospitals, Kaloji Narayana Rao University of Health Sciences, Warangal, during the period from June 2017 to August 2019 with pilonidal disease which were included in this study and divided into two groups: Group (1) treated with MLF and Group (2) with ZPF.

We found that most of the patients were young adults, and most of them were male, as present in literature, in MLF, female patients were four more than Z-plasty because after their counseling they preferred LF than ZPF as they had thought that it is cosmetically better than Z-plasty. As regarding operative time, hospital stay, time off work, post-operative complications, satisfaction score, and MLF were better than Z-plasty.

Regarding recurrences, we did not observe any recurrences in both groups this may be attributed to small number of patients in our study, or due to effectiveness of the both procedures, or follow-up time was shorter.

Although recurrence is the most important factor in the treatment of PNS disease, also there are many other important factors in the treatment of PNS with surgical procedures as post-operative pain, hospital stay, return to daily activities, time off work, and patient cosmetic satisfaction, especially in recurrence with large defects, as flap procedures can reduce aesthetic satisfaction because it may result in an irregular scar. Regarding duration of hospital stay in our study, we found that hospital stay time were 1.6 (1–4) days in MLF Group (1) lower than 3.4 (3–7) days in Z-plasty Group (2).

In our study, the MLF group had a better post-operative pain score, higher patient satisfactions, earlier first mobilization (1 vs. 2 days), and more painless toilet sitting (1 vs. 2 days). These patients also had shorter complete healing time (22/24 day) than the Z-plasty group.

A Cochrane overview has been performed to provide evidence-based guidance for surgical treatment. The review concluded that off-midline closure (including MLF, Karydakis and Bascom flaps natal cleft, and Z-plasty) is the best choice for primary and recurrent PNS.

CONCLUSION

From results of this present study, we found that LF procedure is a safe choice for the surgical treatment of primary and recurrent sacrococcygeal PNS disease due to its low complication rate, short length of hospital stay and early return to work, better post-operative pain score, high patient satisfaction, and shorter complete healing duration. Therefore, we recommend MLF procedure as a good option for the treatment of primary and recurrent PNS disease. Furthermore, ZPF has a major limitation

as it is difficult to apply if there is a wide defect in the horizontal axis.

REFERENCES

1. Sondenaa K, Andersen E, Nesvik I, Soreide JA. Patient characteristics and symptoms in chronic pilonidal sinus disease. Int J Colorectal Dis 1995;10:39-42.
2. Corman ML. Classic articles in colonic and rectal surgery, pilonidal sinus. Dis Colon Rectum 1981;24:324-6.
3. Aydede H, Erhan Y, Sakarya A, Kumkumoglu Y. Comparison of three methods in surgical treatment of pilonidal sinus disease. ANZ J Surg 2001;71:362-4.
4. de Parades V, Bouchard D, Janier M, Berger A. Pilonidal sinus disease. J Visc Surg 2013;150:237-47.
5. Arumugam PJ, Chandrasekaran TV, Morgan AR, Beynon J, Carr ND. The rhomboid flap for pilonidal disease. Colorectal Dis 2003;5:218-21.
6. Yilmaz S, Kirimlioglu V, Katz D. Role of simple V-Y advancement flap in the treatment of complicated pilonidal sinus. Eur J Surg 2000;166:269-72.
7. Cubukcu A, Gonullu NN, Paksoy M, Alponat A, Kuru M, Ozbay O. The role of obesity on the recurrence of pilonidal sinus disease in patients, who were treated by excision and Limberg flap transposition. Int J Colorectal Dis 2000;15:173-5.
8. Quinodoz PD, Chilcott M, Grolleau JL, Chavoin JP, Costagliola M. Surgical treatment of sacrococcygeal pilonidal sinus disease by excision and skin flaps: The Toulouse experience. Eur J Surg 1999;165:1061-5.

How to cite this article: Baraju RP, Babu BV, Gatika RK, Kumar GS, Das DM. Comparison between Z-Plasty versus Limberg Flap Technique in the Management of Sacrococcygeal Pilonidal Sinus. Int J Sci Stud 2021;9(1):148-154.

Source of Support: Nil, **Conflicts of Interest:** None declared.

Print ISSN: 2321-6379
Online ISSN: 2321-595X

Original Article

Cognizance, Comprehension, and Implementation of Green Dentistry among Dental Students and Practitioners, Navi Mumbai, India

Zil Boricha[1], Charu Girotra[2], Siddharth Acharya[3], Omkar Shetty[4], Ruchita Bhosle[5], Gaurav Tomar[6]

[1]BDS, School of Dentistry, DY Patil Deemed to be University, Navi Mumbai, Maharashtra, India, [2]Professor, Department of Oral and Maxillofacial Surgery, School of Dentistry, DY Patil Deemed to be University, Navi Mumbai, Maharashtra, India, [3]Lecturer, Department of Public Health Dentistry, School of Dentistry, DY Patil Deemed to be University, Navi Mumbai, Maharashtra, India, [4]Professor, Department of Prosthodontics Crowns and Bridges, School of Dentistry, DY Patil Deemed to be University, Navi Mumbai, Maharashtra, India, [5]BDS, School of Dentistry, DY Patil Deemed to be University, Navi Mumbai, Maharashtra, India, [6]PG Student, Department of Oral and Maxillofacial Surgery, School of Dentistry, DY Patil Deemed to be University, Navi Mumbai, Maharashtra, India

Abstract

Objectives: Green dentistry is evolving dental practice, including conservation of resources, reduction in water and energy usage and minimizing dental waste, and reducing pollution. Keeping in mind climate change issues and consistent demands and expectations of practicing sustainability, it is imperative to know knowledge and awareness of dental students and regarding green dentistry, and how much of it are they willing to implement in dental practices and to understand knowledge, awareness, and implementation of green dentistry in Navi Mumbai, India.

Materials and Methods: A survey questionnaire with dental practitioners and students enrolled in dental studies. Data were analyzed by Statistical Analysis Software Enterprise Guide.

Results: Half the participants were aware of the term "Green Dentistry," and few had minimal information on green dentistry. There was discord between knowledge and implementation of environment-friendly practices. Most participants cited a lack of awareness for non-implementation of environment-friendly practices.

Conclusion: Mass education and promotion of environment-friendly practices are necessary to reduce the impact of dentistry on the environment. Implementation of green dentistry in dental school curriculum and conducting seminars is recommended to improve awareness. Similar studies are recommended in different cities to enable comparison of perceptions and hindrances in practice of green dentistry.

Key words: Biomedical waste, Eco-friendly, Energy-saving equipment, Green dentistry

INTRODUCTION

In recent times, climate change movements have been at the forefront throughout the world. Carbon emissions, plastic-filled oceans, melting ice, rising sea levels, and frequent natural and manmade disasters are now seen as a major cause of concern for the planet.[1] It is now deemed vital for every individual on the planet to perform their duties while causing minimum damage to the environment by embracing environmentally friendly and sustainable practices. Climate change also causes direct impacts on the health of an individual. As the health of an individual suffers, extra burden is placed on health facilities and healthcare professionals to cater to the needs of the patients. A large amount of greenhouse gases emitted in the earth's atmosphere can be attributed to health care systems. As the needs of the growing population increase, the amount of emissions from healthcare settings also increases.

Hospitals and healthcare facilities use plenty resources for their day-to-day functioning. Similarly, dental services

Access this article online

www.ijss-sn.com

Month of Submission : 02-2021
Month of Peer Review : 03-2021
Month of Acceptance : 03-2021
Month of Publishing : 04-2021

Corresponding Author: Dr. Siddharth Acharya, Department of Public Health Dentistry, School of Dentistry, DY Patil Deemed to be University, Navi Mumbai, Maharashtra, India.

generate metallic waste, use excessive water, and electricity for their functioning.[2] To mitigate these issues, it is observed that in certain developed countries like the United Kingdom, the National Health Service is responsible for delivering health care to the people and has undertaken the implementation of sustainable practices to reduce their carbon footprints by developing sustainability measures, setting targets for the coming years, initiating steering groups, and developing guidance papers by means of its Sustainable Development Unit.[3] However, similar measures have not been observed specific to dentistry or dental practices. Despite promotion of environmentally friendly practices, uptake of the same has not been high in the field of dentistry. Dentistry is a highly energy and resource-intensive with significant environmental impact.[3] Dental professionals aim to endorse and enhance the oral health and well-being of their patients and to accomplish such goals, dentists use a variety of materials and instruments. Unfortunately, dentistry has a large impact on the environment by the pollution generated by general office waste, use of amalgam restorative materials, radiographic chemicals and lead foils, disinfectant solutions used, source of energy used, and use of plastic and paper.[4] Even though the waste produced and resources utilized by an average dentist might not be extensive, it is still harmful to the environment, and in the long-term, maybe more damaging. Hence, it is imperative for dentists to move toward environmentally acceptable and long-term sustainable practices. This can be possible by embracing green dentistry.[5]

Garla in 2012 defines green dentistry or eco-friendly dentistry as "a practice that reduces waste and pollution, saves energy, and money, incorporates high tech innovations, and is wellness-based."[6] Green dentistry or eco-friendly dentistry is considered as an upcoming dental practice which will involve conservation of resources, reduction in water and energy usage, and minimization of dental waste produced and reducing pollution.[7] It is an innovative way of dental practice which based on waste reduction, energy conservation, and pollution prevention. Chopra and Raju in 2017 explained green dentistry as an encompassed dedication toward sustainability, prevention, and precautions to protect the environment.[7] Green dentistry is still an evolving concept in most countries, and more so in developing countries like India; hence, it is vital to know how much knowledge and awareness do dental students and practitioners have about green dentistry and how much of it are they willing to implement in their dental practices. The aim of this study is to understand the knowledge, awareness, and implementation of green dentistry by dental students and dental practitioners in Navi Mumbai, India.

MATERIALS AND METHODS

Participants

A cross-sectional study was conducted in 2019 to determine the knowledge, awareness, and implementation of green dentistry. A survey was conducted in 4 Colleges in Navi Mumbai, involving 500 participants, of which 200 were dental practitioners and 300 were dental students. Among the 300 students, 190 were undergraduate interns (studying Bachelor of Dental Surgery [B.D.S]) and 110 were post-graduate students (studying Master of Dental Surgery [M.D.S]). All the participants were enrolled or working in different dental colleges, hospitals, or clinics in Mumbai and/ or Navi Mumbai.

Ethical Considerations

The study was approved by D.Y. Patil University, School of Dentistry Ethics Review (Number: FRC/2018/OS/10).

Data Collection

An 18 points and 17 points close-ended, self-structured questionnaire (in the English language) was designed for dental practitioners and dental students, respectively, and was checked for content and construct validity. The questionnaire included questions on knowledge and awareness about green dentistry practices and the willingness of the participants to embrace green dentistry or acquire more knowledge about the same. It was pilot-tested on 10 participants and was evaluated for uniformity of interpretation. Inter-rater reliability was checked using Pearson's correlation coefficient formula during the pilot study.

Necessary approvals and permissions were taken from the deans of the four respective colleges. The close-ended, self-administered questionnaire was given to the participants by the investigator by approaching them individually. The questionnaire was filled in the presence of the investigator to avoid any misrepresentation of factors from the participant's side. The investigator was available to answer any questions that the participants had about the questionnaire.

Analysis

The data were analyzed by means of quantitative data analysis. The data were coded and analyzed by Statistical Analysis Software Enterprise Guide (SAS), for example, Version 9.4 and comparisons were done using the Chi-square test. The analyses included coding, comparing, and drawing inferences.

RESULTS

The survey was conducted among 500 participants, of which 200 (40%) were dental practitioners and 300 (60%)

were dental students. Among the 200 dental practitioners, 128 (64.32%) were B.D.S and 72 (35.68%) were M.D.S students. Among the 300 students, 190 (63.33%) were undergraduate interns and 110 (36.67%) were post-graduate students. Response rate is 100%.

As many as 58.79% of dental practitioners, 57.69% of interns, and 54.29% of post-graduate students have heard the term green dentistry. 83.59% of dental practitioners, 66.11% of interns, and 68.32% of post-graduates understood the actual meaning of the term green dentistry which it is reduces waste and pollution, promotes wellness, and saves time, money, and energy.

When asked about the ideal type of dental office, only 42.71% of dental practitioners, 60.53% of interns, and 47.27% of post-graduate students thought that having your clinic in a concrete building with a double-glazed glass window is ideal. About 15.58% of dental practitioners, 10% of interns, and 6.36% of post-graduate students thought that linoleum flooring is ideal for the dental office. Ultra-low volatile organic compound (VOC) paint is ideal for dental office was known by 35.18% of dental practitioners, 54.21% of interns, and 52.73% of post-graduate students.

Chi-square test was performed for the following three questions to compare the knowledge about green building among the participants and the results are as follows:

Green dentistry focuses on waste reduction, energy conservation, and pollution prevention. To reduce waste, participants were asked if they would use the reusable substitutes for the products mentioned in Table 2, which shows us the number of participants who said yes to bring the change.

Participants were asked if they use the methods mentioned in Table 3 to reduce waste, conserve energy, and reduce pollution. Digital radiography was used by 64.10% of dental practitioners, 94.74% 0f interns, and 90.74% of post-graduate students, making it the widely used method of pollution reduction in dental offices. For energy conservation, 73.87% of dental practitioners, 76.34% of interns, and 78.85% of post-graduate students unplug all the electrical appliances after use.

Participants were also asked about bio-medical waste management in their place of practice. 54.77% of dental practitioners, 84.95% of interns, and 72.64% of post-graduate students said that they had bio-medical waste segregation plan, while of others who said no, 87.39% of dental practitioners, 76.67% of interns, and 81.82% of post-graduate students said that it was collected by authorized clinical/hospital waste collection. Of the participants who said that they had a biomedical waste segregation plan at their place of practice, only the participants mentioned in Table 4 could correctly identify the right colored bag for a particular waste product .The colour coding of the wate disposal bags is presented in Table 5.

When asked about methods of energy conservation methods, use of light-emitting diode (LED) lights received the highest responses from both dental practitioners and students [Figures 1 and 2]. Students were more drawn toward renewable sources of energy, as opposed to practitioners, who favored energy saver appliances.

When asked about considerations of any wellness-based modality systems, dental students were keen on considering many of the wellness-based modalities such as live plants, computer-aided design and computer-aided manufacturing (CAD-CAM) systems, digital screenings, laser diagnostics,

Questions asked in the survey	Chi-square	Probability
What is the ideal type of dental office?	7.33	0.119
What type of flooring is ideal for a dental office?	18.1	0.053
What should be the paint used on internal walls of your dental office?	25.4	0.001

Table 1: 3 questions in the questionnaire for which chi-square test was performed

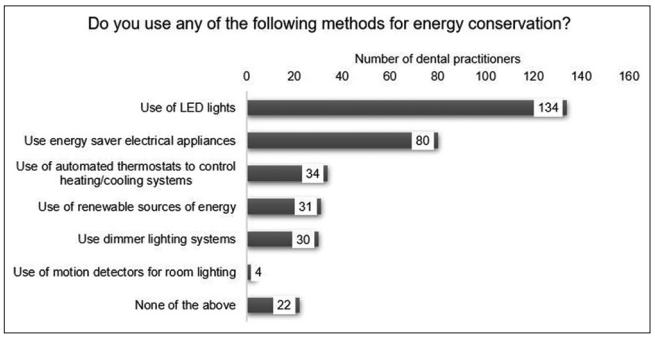

Figure 1: Gives the distribution of energy conservation methods preferred by dental practitioners

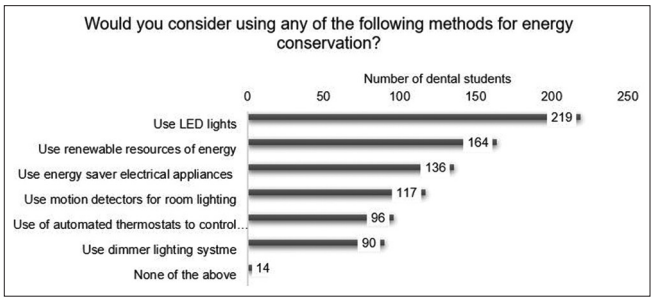

Figure 2: Gives the distribution of energy conservation methods preferred by dental students (interns and post-graduate students)

Environment friendly substitutes to every-day dental products	Dental practitioners	Interns	Post graduate students
A. Sterilized Cloth Masks over disposable masks	35.18%	44.21%	39.09%
B. Metal suction tips over disposable suction tips	53.27%	36.84%	45.45%
C. Sterilized cloth drapes	80.00%	84.74%	91.82%
D. Reusable sterilized cloth aprons/lab coats over disposable aprons	79.40%	82.11%	91.82%
E. Steel /autoclave-able drinking cups over plastic drinking cups	46.23%	55.26%	51.82%
F. Metal cartridges over disposable syringes	55.78%	43.16%	45.45%
G. Cloth instrument bags over disposable ones	59.30%	76.32%	83.64%
H. Sterilized Protective eye wear	93.47%	91.58%	91.82%
I. Sterilized Instruments, trays and film holding device that can be reused	88.45%	96.84%	100%
J. Laundered cloth towels over napkins	86.43%	66.32%	69.09%
K. Steam sterilization over cold sterilization	89.45%	93.16%	93.64%

Table 2: The first column in Table 2 represents the environment friendly substitutes to every-day dental products. The rest of the columns includes the percentage of participants that prefer these substitutes over conventional alternatives.

Methods used in dental offices to reduce waste/ conserve energy/ reduce pollution	Dental practitioners	Interns	Post graduate students
Digital Radiography	64.10%	94.74%	90.74%
Waterless/ dry vacuum system	28.27%	38.04%	56.73%
Water faucet sensors	27.51%	61.96%	62.62%
Waterless hand sanitizers	34.87%	50%	55.56%
Computer based patient records	59.26%	7.61%	7.41%
LCD Monitor	74.87%	84.62%	79.44%

Table 3: Table 3 gives the percent distribution of methods used in dental offices to reduce waste/ conserve energy/ reduce pollution by dental practitioners, interns and post graduate students.

and others [Figure 3]. As opposed to students, most dental practitioners (85) did not consider using any of the wellness-based modality systems [Figure 4].

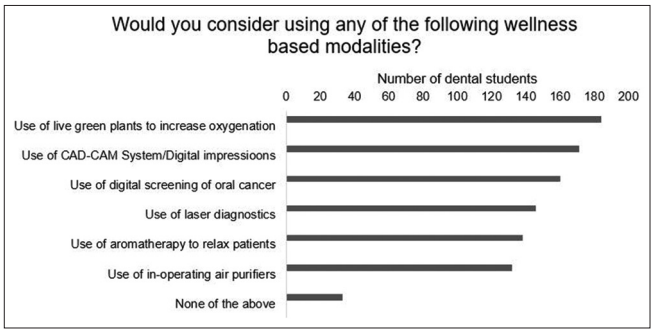

Figure 3: Gives the distribution of wellness-based modalities preferred by dental students (interns and post-graduate students)

Only 22.45% of dental practitioners, 52.75% of interns, and 40.38% of post-graduate students said they recycled the lead foils used in dental radiography. 14.07% of dental practitioners, 36.31% of interns, and 35.42% of post-graduate students said that they sent X-ray fixer solution to silver recovery system.

Amalgam management is one of the biggest concerns in dental practice, when given options for disposal of

Table 4 gives the percent distribution of the number of the participants who correctly identified the correct bags for different types of waste disposals.

Type of waste	Dental practitioners	Interns	Post graduate students	Chi-square and probability (p)
Blood waste in yellow bag	31.87%	20.47%	15%	32.8 p=0.000
Blood soaked cotton in yellow bag	45.05%	25.20%	15.79%	40.0 p=0.000
Gloves in red bag	35.29%	30.08%	30.64%	7.61 p=0.268
Discarded medicines in yellow bag	12.99%	42.15%	32.76%	32.1 p=0.000
Plastic bottles in red bag	26.97%	23.14%	19.30%	19.7 p=0.003
Broken glass article in blue bag	77.53%	28.80%	33.33%	65.1 p=0.000
Extracted teeth in white bag	14.12%	25.21%	26.32%	13.3 p=0.039
Catheter in red bag	54.55%	31.40%	23.64%	33.7 p=0.000
Syringes, IVs in red bag	53.76%	32.48%	38.60%	31.7 p=0.000
Sharps (blades, scalpels) in white bag	17.58%	24.79%	21.05%	29.6 p=0.000
Needles without syringes in white bag	28.92%	32.52%	29.82%	11.3 p=0.081

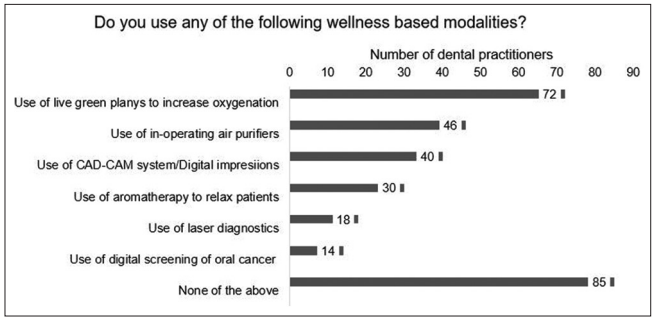

Figure 4: Gives the distribution of well-ness-based modalities preferred by dental practitioners

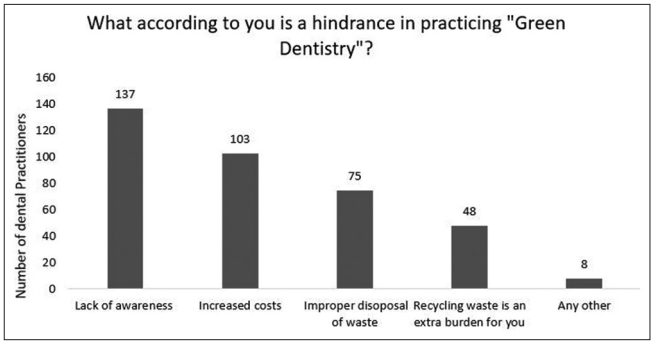

Figure 5: Represents hindrance faced by dental practitioners in the implementation of green dentistry

amalgam, 45.20% of dental practitioners, 28.26% of interns, and 21.36% of post-graduates use alternative to amalgam fillings. To transit impression or casts to and from the lab, 76.38% of dental practitioners, 65.38% of interns, and 65.05% of post-graduate students still use plastic bags.

91.19% of dental practitioners, 87.85% of interns, and 92.38% of post-graduate students have not attended any seminars related to green dentistry. 90.48% of dental practitioners, 89.35% of interns, and 86.41% of post-graduate students would like to attend seminars and workshops related to green dentistry. 98.99% of dental practitioners, 98.91% of interns, and 98.10% of post-graduate students would like to implement green dentistry in their practice to make earth a better place to live.

The following graph represents the hindrance faced by dental practitioners in practicing green dentistry [Figure 5].

Category	Type of waste
1. YELLOW	Human/animal anatomical waste Soiled Waste Expired/discarded medicine Chemical waste and Chemical liquid waste Discarded linen, mattresses, beddings contaminated with blood and body fluid Microbiology, biotechnology and clinical laboratory waste
2. RED	Contaminated waste (recyclable) such as tubing, bottles, intravenous tubes and gloves
3. WHITE OR TRANSLUCENT	Waste sharps such as blades, scalpels and needles
4. BLUE	Glassware (like vials) and metallic body implants

Table 5 shows color coding of waste disposal bags

DISCUSSION

The purpose of this survey is to understand the knowledge, awareness, and implementation of green dentistry in the dental practice of dental practitioners and dental students. According to Eco-Dentistry Association,[5] the prime worth of switching to eco-friendly dentistry is:

1. It is high-tech
2. It reduces waste and pollution
3. It saves time, energy, and money
4. It promotes wellness.

Implementation of green dentistry protocols in a dental setting can be initiated by choosing your office in a green building. Our results reveal a lack of knowledge about green clinics among the participants. Green building is environmentally responsible and resource-efficient through its life cycle: From its design, construction, and operation to maintenance, renovation, and demolition.[8] A green dental office may cost more in up front but, in the long run, will save money through lower operating costs over the life. Simple ways to go green are as follows;

1. Use of concrete instead of brick is considered ideal as it improved thermal efficiency reduced heat and cooling load
2. Use of double wall glass in window so as to reduce direct heat gain and glare while maximizing the sunlight entering your rooms
3. Use of non-toxic eco-friendly paints (ultralow VOC paints) as they do not produce toxic fumes
4. Use of linoleum flooring is a more eco-friendly choice.[9]

Participants in the survey revealed that they would prefer using reusable items in their dental practice for the reduction of waste. However, our results reveal low use of cloth mask, metal suction tips, steel/autoclavable drinking cups, and metal cartridges, most likely due to fear of disease transmission. However, use of reusable materials in a dental setting is encouraged, with the help of additional attention from the auxiliary staff to maintain the standard protocol of disinfection and ensure complete sterilization of materials to prevent disease transmission.

Participants were well aware of the need of energy conservation and hence most of them unplug all of the electrical appliances after use. A study reveals if electrical appliances are unplugged, they save 5–10% on your electricity bill.[10] More conservation of energy could be done using the following methods:

1. Use of LED lights, these lights last for several years, thereby reducing waste production and also use 70% less electricity in comparison to halogen light[11]
2. Use of renewable resources of energy like solar energy, electricity produced from windmill[7]
3. Use of automated thermostats which run on different temperatures at different times of day and should be adjusted according to outside temperature[12]
4. Use of motion detectors for room lighting reduces the use of electricity when the room is empty[2]
5. Use of controlled dimmer lighting systems[13]
6. Up to 1/3rd of energy, cost is preserved using energy saver electrical appliance which is energy star rated.[9]

Going digital in your dental practice is the new technique evolution for waste reduction,[8] this can be done using:

1. Laser diagnostic tools which help to detect dental caries more efficiently than naked eyes[14]
2. Use of CAD-CAM Systems/Digital impressions which is more efficient than material-based impression and reduces waste by not producing gypsum cast and no use of alginate or rubber-based impression materials. It is more convenient for dental laboratories as they do not have to travel to your clinics which reduces emission of greenhouse gases and reduces the use of plastic and paper
3. Digital screening of oral cancer reduces the production of hazardous tissue waste and frequent travel expenses
4. Use of intra-oral screening cameras and radiovisiography imaging techniques for dental radiographs.

Using wellness-based modalities not only makes your clinic appealing to your patients but also reduces aerosols produced during dental procedures. Use of aromatherapy helps calming patients naturally. Use of live green plants helps to improve the quality of oxygen in your clinics. Use of in-operating air purifiers removes aerosols produced during dental procedures from the air.[5] Participants had high knowledge about energy conservation as most of them preferred use of digital radiography and liquid crystal display monitors, but when asked about paper waste management, we received low responses for switching to computer-based patient records. This could be because the participants may have to appoint an additional staff/train

their assistant which could be an extra burden for them. Participants showed low response for the use waterless/dry vacuum system, water faucet sensor, and waterless hand sanitizers to conserve water. These systems could be used by fewer participants because of expensive costs in comparison to their conventional alternatives.

The term biomedical waste has been defined as "any waste that is generated during the diagnosis, treatment, or immunization of human beings or animals, or in the research activities pertaining to or in the production or testing of biological and includes categories mentioned in Schedule I of the Biomedical Waste (Management and Handling) rules 1998."[15] This makes it mandatory for dental clinics to segregate, disinfect, and dispose of their waste in the proper manner. There may be an increased risk of infections in patients and dental staff due to poor waste management. The best disposal options are to prevent or minimize the disposal of toxic substances from dental clinics into the environment. Biodegradable waste segregation plan was adopted by about 70% of participants, and they used yellow, red, blue, or white bags to segregate the waste produced. The remaining 30% of our participants disposed of their biomedical waste by handling it to authorize clinical/hospital waste collection or to house-to-house waste collection. Unfortunately, participants revealed a lack of knowledge when asked to segregate a few waste products into their respective bags. The plastic bags which are used for waste disposal are special non-chlorinated bags which are incinerable and are color-coded according to the waste to be disposed in them.[15]

Impression compound, agar, dental waxes, green stick compound, impression pastes, and shellac baseplates should be kept in a "yellow plastic bag" then sent for either incineration or deep burial.[15] Rubber base impression material, investment material, pumice, acrylic, metal dust, alginate, old models, and casts, old acrylic dentures and teeth kept in a "black plastic bag" and dispose of in municipal dump.[15]

Dental amalgam particles have sources of mercury, which is known to be neurotoxic and nephrotoxic. Our results revealed a low level of amalgam management strategies. Ideal method of reducing amalgam waste is using alternatives to silver amalgam such as composite, glass ionomer, and indirect restorative materials such as gold, ceramic, and porcelain. If that is not possible, then always use pre-encapsulated amalgam instead of manual manipulation;[12] after condensation, scrap should be collected and stored in air tight jar in water and does not dispose amalgam in regular trash; instead of it dispose it as hazardous waste/ send it to a recycler. Another option is to install amalgam separator that complies with the International Organization for Standardization (ISO) 11143.[8] Extracted teeth without amalgam restorations can be placed in white/translucent bag with sharps, which can then be sterilized, but it is preferred to recycle all amalgam found on extracted teeth.[16] Teeth with amalgam should be managed with protocols followed to dispose amalgam waste which is described above X-ray films used in conventional radiography produces waste in the form of lead foils which cannot be disposed of in biomedical waste as they are hazardous and need to be recycled for their scrap metal content.[9] Lead waste is held in topsoil, where it can persist for 2000 years which is rapidly picked up by plants and enters the food system.[8] Participants showed low response to correct disposal of lead foil and fixer solution; this may have occurred due to lack of knowledge about the same. Similarly, the fixer solution should be sent to silver recovery system as it contains chemicals such as aluminum thiocyanate and boric anhydride which can irritate skin, eyes, and respiratory tract, and prolonged exposure may be toxic for blood, thyroid, liver, and kidney, may lead to target organ failure.[8]

Plastic, once found to be having a wide number of advantages, is now a serious threat to the environment and health due to its non-biodegradable nature. Maximum participants used plastic bags for transit of impressions/cast to and from laboratory. Use of alternative to plastic bags in the form of cloth bag or steel containers is the need of hour.

Our results reveal that more than 90% of participants wish to attend lectures/seminars/workshops on green dentistry and implement it into their practice and make earth a better place to live. Lack of awareness was the most chosen option when dental practitioners were asked about the obstacles they face while implementing green dentistry; other hindrances in implementation of green dentistry were increased costs, improper waste disposal, considering recycling waste as an extra burden, lack of trained staff, and preferring convenience over responsibility toward the environment.

Amalgam, plastic, radiographic chemicals, and lead foils are waste material from dental settings, which lead to land and water pollution. Dentists can limit the burden on the environment by implementing the "Four R's of Going Green," namely, "Re-think, Reduce, Reuse, and Recycle."[4]

Re-think

We need to re-think the choices we make right from choosing our dental office to the materials and appliances that are to be used in our practice and the ways we will perform our dental procedures so that the choices we make will prove to be more environmental friendly and reduce the burden on earth.

Reduce

We need to reduce the use diminishing resources that are available to us such as water and electricity and make use of free resources like sunlight.

Reuse

Make use of materials/products that could be used more than once, this will help us to produce less waste on daily basis.

Recycle

Make use of materials that could be recycled; by doing this, we are using the material for a longer during before throwing it away in the waste.

CONCLUSION

This study has revealed the knowledge, comprehension, and implementation of green dentistry among dentists and students in the city of Navi Mumbai. We find that there is not enough awareness about green dentistry. There is also an apparent visible gap between knowledge and implementation. In addition, there is widespread misinformation about certain aspects of green transformations, for example, waste disposals. From the findings and discussions, we can conclude that there is an important need to create awareness among dental practitioners and students about the effects of dentistry on the environment and ideal implementation of green dentistry to mitigate these issues.

Recommendations

The current study faces limitations about the type of study design. We did not conduct interviews with participants, which would have provided us with more information on ways to support dentists for a green transition. The study was also concentrated in just one city and few institutions. However, despite these limitations, the study still provides insights into concepts of green dentistry, which are largely unexplored in developing countries like India. A similar study is recommended in different cities and towns of India to enable comparison of knowledge, perceptions, and hindrances, if any, in the practice of green dentistry. To increase knowledge about green dentistry among dentists, the Dental Council of India could include the concept of green dentistry in the existing syllabus. Conduction of widespread seminars regarding the management of finances while starting a green clinic can be delivered to fresh graduates, as well as seasoned practitioners, who would most likely implement it in the construction of their dental offices. Research work on the concept of green dentistry should be undertaken to provide further information on green dentistry practices; grants can also be provided for the same to encourage participation.

REFERENCES

1. Climate Change: How Do We Know? Climate NASA; 2020. p. 1. Available from: https://www.climate.nasa.gov/evidence. [Last accessed on 2020 Nov 20].
2. Rastogi V, Sharma R, Yadav L, Satpute P, Sharma V. Green dentistry, a metamorphosis towards an eco-friendly dentistry: A short communication. J Clin Diagn Res 2014;8:ZM01-2.
3. Mulimani P. Green dentistry: The art and science of sustainable practice. Br Dent J 2017;222:954-61.
4. Al-Qarni M, Shakeela NV, Alamri MA, Alshaikh YA. Awareness of eco-friendly dentistry among dental faculty and students of King Khalid University, Saudi Arabia. J Clin Diagn Res 2016;10:ZC75-8.
5. Mohelay N, Deolia SG, Jagyasi D, Lakhwani R, Sen S, Chapekar J. Eco-friendly dentistry: A green Business with Teeth. Int J Oral Health Med Res 2016;3:66-70.
6. Kumar GB. Green dentistry; ecofriendly dentistry: Beneficial for patients, beneficial for the environment. Ann Essences Dent 2012;4:72-4.
7. Chopra A, Raju K. Green dentistry: Practices and perceived barriers among dental practitioners of Chandigarh, Panchkula, and Mohali (Tricity), India. J Indian Assoc Public Health Dent 2017;15:53-6.
8. Karthika B, Sridhar T, Pavani M, Devi CR, Kanimozhiy S, Priya A. Bio-hazards in dentistry. Indian J Hosp Infect 2019;1:54-9.
9. Chopra A, Gupta N, Rao NC, Vashisth S. Eco-dentistry: The environment-friendly dentistry. Saudi J Health Sci 2014;3:61-5.
10. Brindle B. How Much Can You Save by Unplugging Appliances? 2011. p. 1-3. Available from: https://www.howstuffworks.com. [Last accessed on 2020 Nov 20].
11. Rathakrishnan M, Priyadarhini A. Green dentistry: The future. J Int Clin Dent Res Org 2017;9:59-61.
12. Al Shatrat SM, Shuman D, Darby ML, Jeng HA. Jordanian dentists' knowledge and implementation of eco-friendly dental office strategies. Int Dent J 2013;63:161-8.
13. 80 Ways to Make Your Dental Practice Green, ADA Center for Professional Success; 2018.
14. Bader JD, Shugars DA. A systematic review of the performance of a laser fluorescence device for detecting caries. J Am Dent Assoc 2004;135:1413-26.
15. Arora S, Mittal S, Dogra V. Eco-friendly dentistry: Need of future. An overview. J Dent Allied Sci 2017;6:22-7.
16. Thomas MV, Jarboe G, Frazer RQ. Regulatory compliance in the dental office. Dent Clin North Am 2008;52:629-39.

How to cite this article: Boricha Z, Girotra C, Acharya S, Shetty O, Bhosle R, Tomar G. Cognizance, Comprehension, and Implementation of Green Dentistry among Dental Students and Practitioners, Navi Mumbai, India. Int J Sci Stud 2021;9(1):155-162.

Source of Support: Nil, **Conflicts of Interest:** None declared.

Print ISSN: 2321-6379
Online ISSN: 2321-595X

Original Article

A Study on Ocular Morbidity among School-Going Children (6–12 Years) – A Cross-Sectional Study

S Kavitha[1], M Chandralekha[2], Heber Anandan[3]

[1]Assistant Professor, Department of Ophthalmology, Tirunelveli Medical college Hospital, Tirunelveli, Tamil Nadu, India, [2]Assistant surgeon, Department of Ophthalmology, Aruppukkottai Government Hospital, Aruppukkottai, Tamil Nadu, India, [3]Senior Clinical Scientist, Department of Clinical Research, Dr. Agarwal's Eye Hospital, Tamil Nadu, India

Abstract

Introduction: School health is an essential aspect of any community health program. The school age is a formative period, physically and mentally, transforming the child into a promising adult. Poor vision in childhood affects performance in school and negatively influences the child's future life.

Aim: This study aimed to assess the prevalence and associated factors related to ocular morbidity among primary rural school-going children (age 6–12 years).

Materials and Methods: This cross-sectional study was carried out from December 2018 to December 2019 in almost six primary schools in Kallur Block in the Tirunelveli district from the first to fifth standard (6–12 years). The Institutional Ethical Clearance and appropriate permissions from the school authorities were obtained through the medical officer of Kallur PHC and consent 51 from the parents.

Results: Out of 500 participants based on the age group, the participants were highest in 10–12 years of age group, 22%. The remaining distribution was 20.8% in 7 years of age, 20.4% in 9 years of age, 19.8% in 8 years of age, and 17% in 6 years of age. The participants were highest in the female, which was 54.8% and 45.2% in males. The blurring of vision was the most common complaint reported by 40.2% of the study participants. The prevalence of total ocular morbidity among our study participants was 15.4%.

Conclusion: This study proves that the risk factors associated with refractive error can be avoided, and creating awareness among children, parents, and teachers play an essential role in preventing visual impairment.

Key words: Children, Morbidity, Ocular, Refractive error, Vision

INTRODUCTION

School health is an essential aspect of any community health program. The school age is a formative period, physically and mentally, transforming the child into a promising adult. Poor vision in childhood affects performance in school and negatively influences the child's future life. Schoolchildren are affected by various eye disorders such as refractive errors, squint, Vitamin A deficiency, and eye infections. Uncorrected refractive errors form one of the important causes of visual impairment and blindness in most developing countries, including India. Because 30% of India's blind lose sight before the age of 20 years, the importance of early detection and treatment of ocular morbidity, and visual impairment in young children is evident.[1,2] This warrants early detection and treatment of ocular problems to prevent future blindness.

According to the WHO (Globally), among adults, there are 39 million people blind, and 246 million are visually impaired, and among children, there are 1.4 million blind and 18.9 million are visually impaired. Uncorrected refractive errors are the leading cause of visual impairment.[3] According to the National Programme for Control of Blindness and Visual Impairment, there are 9 million blind and million visually impaired adults. Among children, 2.7 lakh are blind, and 0.3/1000 are visually impaired.[4,5]

Access this article online

www.ijss-sn.com

Month of Submission : 02-2021
Month of Peer Review : 03-2021
Month of Acceptance : 03-2021
Month of Publishing : 04-2021

Corresponding Author: M. Chandralekha, Department of Ophthalmology, Aruppukkottai Government Hospital, Aruppukkottai, Tamil Nadu, India.

Common ocular morbidities in schoolchildren are refractive error, amblyopia, color blindness, Vitamin A deficiency allergic conjunctivitis, infectious conjunctivitis, blepharitis chalazion, stye, congenital cataract, traumatic cataract, squint, and ptosis.

A normally developed eye (by 5–6 years of age) acts as a convex lens of +60D. This power is divided into two major components, that is, the corneal and lenticular. The converging power of the cornea is +43D.[6] This leaves the lens with +17D of power; normal aqueous and vitreous contribute a negligible converging power. In an eye with normal refractive (dioptric) power, parallel rays are brought to focus on the retina with accommodation at rest; the parallel rays form a circle of least diffusion.[7] This refractive status is called emmetropia. In contrast to this, if all parallel rays are not brought to focus on the retina in all the meridian with accommodation at rest, the condition is called ametropia.[8]

A full-term normal child at birth is about +2 to +3D hypermetropic. This is due to the shorter axial length of the newborn's eyeball. As the child grows, this power is neutralized by the eyeball's corresponding lengthening up to 5–7 years when all eyes should become emmetropic. However, if the increase in length does not stop at this point, the eye becomes myopic, and if the eye fails to reach the emmetropic length (24 mm), the eye becomes hypermetropic.[9]

Aim

This study aimed to assess the prevalence and associated factors related to ocular morbidity among primary rural school-going children (age 6–12 years).

MATERIALS AND METHODS

This cross-sectional study was carried out from December 2018 to December 2019 in almost six primary schools in Kallur Block in Tirunelveli district. The study population comprised students from the first to fifth standard (6–12 years). Inclusion criteria include children age group 6–12 years, both males and females, visual acuity <6/9, and improving with pinhole was considered to be refractive error, strabismus was diagnosed by recording corneal light reflex combined with extraocular movements and cover-uncover tests, a probable diagnosis of amblyopia was made, if the vision was <6/9, not improving with pinhole and no organic lesions were detected after the complete ocular examination.

Exclusion criteria include children below 6 years and above 12 years, children's absence on the day of examination, and children with previous ocular surgery or any ocular disease. The Institutional Ethical Clearance and appropriate permissions from the school authorities were obtained through the medical officer of Kallur PHC, and consent from the parents was obtained. A complete history was taken from the students and parents. Complete eye examination of both eyes was carried out in all students, and free of cost, referral, and treatment were provided at Tirunelveli Medical College and Hospital.

Eye examination of each student included torchlight examination of the eye and adnexa. Visual acuity for distance vision was tested separately for each eye with a Snellen chart at a distance of 6 m. In children already prescribed spectacles, visual acuity was tested with glasses. Visual acuity for near vision tested separately for each eye with a Jaeger's near vision chart at a distance of 25 cm. A single experienced optometrist tested visual acuity to avoid interobserver variation, ocular deviation (phoria and tropia) – determined using the cover test.

Fundus examination using direct ophthalmoscopy, students with visual acuity 6/9 or less were further evaluated at the tertiary health care center (Tirunelveli Medical College and Hospital). These students underwent cycloplegic refraction with 1% cyclopentolate eye drops. Streak retinoscopy was performed, and a post-mydriatic test was carried out on all students. Children were given a final prescription based on post-mydriatic test and subjective acceptance. Amblyopic children were given full refractive correction. Patching was advised and followed up every 3 months.

RESULTS

The age group distribution was equal in all the groups. The participants were highest in the 10–12 years age group which was 22%. The remaining distribution was 20.8% in 7 years of age, 20.4% in 9 years of age, 19.8% in 8 years of age, and 17% in 6 years of age. The participants were highest in the female, which was 54.8% and 45.2% in males. The participants were highest in V class which was 21.8%. The remaining distribution was 21% in II, 20.4% in IV, 19.8% in III, and 17% in I [Table 1].

The blurring of vision was the most common complaint reported by 40.2% of the study participants. Headache was reported by 30% of the participants. H/O excessive rubbing was found in 18.8% of the study participants, redness was reported by 15.2% of the participants. Other complaints such as eye discharge, swelling of lids, and watering of eyes were found in 11.4%, 6.6%, and 6.8% of the participants. About 15.4% did not report any specific complaints [Table 2].

Table 1: Sociodemographic profile

Sociodemographic profile	Frequency	Percentage
Age		
6 years	85	17
7 years	104	20.8
8 years	99	19.8
9 years	102	20.4
10–12 years	110	22
Gender		
Male	226	45.2
Female	274	54.8
Type of class		
1	85	17
2	105	21
3	99	19.8
4	102	20.4
5	109	21.8

Table 2: Presenting illness

Presenting illness	Frequency	Percentage
Blurring of vision	201	40.2
Excessive rubbing	94	18.8
Headache	149	30
Watering of eyes	34	6.8
Redness	76	15.2
Eye discharge	57	11.4
Swelling of lids	33	6.6
None	77	15.4

The prevalence of total ocular morbidity among our study participants was 15.4% [Table 3].

Among all reported ocular morbidities, refractive error was the leading cause of ocular morbidity, which formed 66% of the total morbidities. This was followed by blepharitis which accounted for 10.3%, conjunctivitis for 9.3%, stye for 5.2%, and squint 4.1% of total ocular morbidities. Other lesser common conditions such as Vitamin A deficiency, corneal opacity, ocular trauma, ptosis, chronic progressive external ophthalmoplegia, and amblyopia accounted for 1.3% in total ocular morbidity [Table 4].

Fourteen patients had myopia, 21 patients had simple myopic astigmatism, 6 patients had compound myopic astigmatism, 6 patients had simple HM, 1 patient had SHM astigmatism, and 1 patient had mixed astigmatism [Table 5].

DISCUSSION

The current study is a school-based cross-sectional study to estimate the prevalence of ocular morbidity and the distribution of various associated factors among school children. The number of study participants involved was 500 students. The age of the study participants ranged from 6 to 12 years. In my study, 45.2% (226) were male, and

Table 3: Prevalence of ocular morbidity

Ocular morbidity	Frequency	Percentage
Present	77	15.4
Absent	423	84.6

Table 4: Distribution of type of ocular morbidity

Ocular morbidity	Frequency	Percentage
Refractive error	49	63.6%
Blepharitis	8	10.3%
Conjunctivitis	7	9%
Stye	4	5.2%
Vitamin A deficiency	1	1.3%
Corneal opacity	1	1.3%
Ocular trauma	1	1.3%
PTOSIS	1	1.3%
Chronic progressive external ophthalmoplegia	1	1.3%
Squint	3	4.1%
Amblyopia	1	1.3%

Table 5: Distribution of type of refractive error

Type of refractive error	Frequency	Percentage
Simple myopia	14	28.5
Simple myopic astigmatism	21	43.1
Compound myopic astigmatism	6	12.2
Simple HM	6	12.2
SHM astigmatism	1	2
Mixed astigmatism	1	2

54.8% (274) were female, which is opposed to the survey by Kamath *et al.*[10] About 60.77% were male and 39.23% were female. No significant sex preponderance was noted.

In my study, the prevalence of ocular morbidity among children was 15.4%, which is similar to a survey done by Wedner *et al.*[11] in rural Tanzania, Africa, with 15.6% of ocular morbidity reported in children aged 7–19 years. The least prevalence of 13% was reported by Prajapati *et al.*[12] among adolescents of Gandhinagar district. In contrast, higher prevalence reported by Chaturvedi and Aggarwal[13] (more than 40%) in rural Delhi and Kalikivayi *et al.*[14] (43.5%) at Hyderabad and prevalence reported by Kumar *et al.*[15] (24.6%) from Delhi, Jayanth and Malathi (27.65%) from rural Maharashtra, and Madhu Gupta and others (31.6%) from Shimla.

The prevalence of ocular morbidity varies at different places due to various factors prevailing at other sites. The most typical cause of ocular morbidity in the present study was refractive errors with a prevalence of 63.6%, which is followed by blepharitis which accounted for 10.3%, conjunctivitis for 9.3%, stye for 5.2%, and squint 4.1% of total ocular morbidities, which is similar to a study done by

Dandona *et al*.[16] in which 61% had refractive error among children in rural population of India. Prajapati *et al*.[12] had observed it as the most common with a prevalence of 40.1% in their study at Gandhinagar. Kalikivayi *et al*.[14] have reported a prevalence of refractive error of 32% in a study from South India. Gupta *et al*.[17] at Shimla had identified refractive error as the most typical morbidity among children (22%) in their study. Refractive error is one of the most common causes of visual impairment worldwide and the second leading cause of treatable blindness.

In my study, the proportion of refractive error was more in 10 years age group which was 47%. This difference in the distribution of age was statistically significant with $P < 0.001$. Age was significantly associated with refractive error. This is similar to a study done by Sun *et al*.[18] in China which observed that as the age increases, it was closely associated with increased risk of refractive error in multivariate models. A similar pattern has been noted by Mahapatro *et al*.[17] at Bhubaneswar and Goh *et al*.[19] in Malaysia. Screening for refractive errors is an integral part of school health problem.

CONCLUSION

From this study, we concluded that refractive error was the leading cause in our study among all ocular morbidities, contributing 66%, which raises the need for prescription of glasses. Our analysis also correlates the associated factors in children with a positive parental history of refractive error, watching television, playing mobile games for more than 2 h with limited outdoor activities, and more likely to develop visual impairment.

REFERENCES

1. World Health Organization. Elimination of Avoidable Visual Disability due to Refractive Error. Report of an Informal Planning Meeting WHO/PBL/00.77. Geneva: World Health Organization; 2000. p. 6-10.
2. World Health Organization. Global Data on Visual Impairments 2010. Geneva: World Health Organization; 2010. Available from: http://www.who.int/blindness/globaldatafinalforwebpdf. [Last accessed on 2019 Feb 11].
3. World Health Organization. WHO disease control and prevention of visual impairment. In: Waddell A, Heseltine E, editors. Global Initiative for the Elimination of Avoidable Blindness: Action Plan 20062011. Geneva, Switzerland: World Health Organization; 2007. p. 9-39.
4. National Programme for Control of Blindness, Ministry of Health and Family Welfare, Government of India. NPCB; 2017. Available from: http://www.npcb.nic.in/index1.asp?linkid=29&langid=1. [Last accessed on 2019 Feb 05].
5. Bourne RR, Flaxman SR, Braithwaite T, Cicinelli MV, Das A, Jonas JB, *et al*. Magnitude, temporal trends, and projections of the global prevalence of blindness and distance and near vision impairment: A systematic review and meta-analysis. Lancet Glob Health 2017;5:e888-97.
6. Adhikari S, Shrestha MK, Adhikari K, Maharjan N, Shrestha UD. Factors associated with childhood ocular morbidity and blindness in three ecological regions of Nepal: Nepal pediatric ocular disease study. BMC Ophthalmol 2014;14:125.
7. Duke Elder S. Ophthalmic optics and refraction in System of ophthalmology. Vol. 5. St. Louis: C.V. Mosby; 1970.
8. Agrawal LP. Principles of optics and refraction. 2nd ed. New Delhi: CBS Publishers and Distributors; 1979.
9. Primrose J. In: Sorsby A, editor. Anomalies of Refraction and Accommodation in Modern Ophthalmology. Vol. 3. London: Butterworth; 1964.
10. Prasanna Kamath B, Bengalorkar GM, Prasad BG. Comparative study of prevalence of ocular morbidity among school going children of government and private schools in rural Karnataka, South India. Int J Curr Res Rev 2013;5:69-76.
11. Wedner SH, Ross DA, Balira R, Kaji L, Foster A. Prevalence of eye diseases in primary school children in a rural area of Tanzania. Br J Ophthalmol 2000;84:1291-7.
12. Prajapati P, Oza J, Prajapati J, Kedia G, Chudasama RK. Prevalence of ocular morbidity among school adolescents of Gandhinagar district, Gujarat. Online J Health Allied Sci 2011;9:4.
13. Chaturvedi S, Aggarwal OP. Pattern and distribution of ocular morbidity in primary school children of rural Delhi. Asia Pac J Public Health 1999;11:30-3.
14. Kalikivayi V, Naduvilath TJ, Bansal AK, Dandona L. Visual impairment in school children in Southern India. Indian J Ophthalmol 1997;45:129-34.
15. Kumar R, Mehra M, Dabas P, Raha R. A study of ocular infections amongst primary school children in Delhi. J Commun Dis 2004;36:121-6.
16. Dandona R, Dandona L, Srinivas M, Sahare P, Narsaiah S, Muñoz SR, *et al*. Refractive error in children in a rural population in India. Invest Ophthalmol Vis Sci 2002;43:615-22.
17. Gupta M, Gupta B, Chauhan A, Bhardwaj A. Ocular morbidity prevalence among school children in Shimla, Himachal, North India. Indian J Ophthalmol 2009;57:133.
18. Sun Y, Cao H, Yan ZG. Prevalence of refractive errors in middle school students in Lanzhou City. Int J Ophthalmol 2008;1:180-2.
19. Goh PP, Abqariyah Y, Pokharel GP, Ellwein LB. Refractive error and visual impairment in school-age children in Gombak District, Malaysia. Ophthalmology 2005;112:678-85.

How to cite this article: Kavitha S, Chandralekha M, Anandan H. A Study on Ocular Morbidity among School-Going Children (6–12 Years) – A Cross-Sectional Study. Int J Sci Stud 2021;9(1):163-166.

Source of Support: Nil, **Conflicts of Interest:** None declared.

Print ISSN: 2321-6379
Online ISSN: 2321-595X

Original Article

Evaluation of the Effectiveness of Modified Early Obstetric Warning System in a Tertiary Health Care Setup

R Radha[1], S Kokila[1], S Mukilvizhi[1], R Venkatesan[2]

[1]Assistant Professor, Department of Obstetrics and Gynaecology, Government Madurai Medical College, Madurai, Tamil Nadu, India, [2]Associate Professor, Department of Physiology, Government Medical College, Pudukkottai, Tamil Nadu, India

Abstract

Background: Approximately one-quarter of worldwide maternal deaths occur in India. Early intervention in correct time will result in an improved outcome in high-risk mothers. The Modified Early Obstetric Warning System (MEOWS) is a simple bedside screening tool for assessing maternal morbidity. Majority of the studies about MEOWS have come from the UK, where they have found to be a useful method of monitoring and targeting high-risk groups. We have made such an attempt in our institution to formulate and identify the high-risk groups with the usually used bedside and routine blood parameters.

Materials and Methods: This was a prospective study. After obtaining proper informed consent, those women who got admitted as inpatients to the maternity unit with gestation period between 20 weeks to term and followed postpartum up to the period of discharge were included in the study. MEOWS was used as a tool to monitor their well-being.

Results: Our study results revealed that using MEOWS for monitoring pregnant women led to a statistically significant improvement in maternal health care.

Conclusion: Our study has clearly brought out the significance and correlation of various parameters in relation to maternal morbidities. In a developing country like India, identification of high-risk cases with parameters such as blood pressure, heart rate, respiratory rate, temperature, and renal parameters would go a long way in preventing maternal mortality.

Key words: Modified Early Obstetric Warning System, Pregnant Women, Maternal Mortality Prevention

INTRODUCTION

The development of Maternal Early Obstetric Warning System (MEOWS) as a predictor of maternal morbidity from simple bedside observation charts arose from the knowledge that physiological abnormalities precede almost all critical illnesses which lead to maternal mortality. It is thought that early intervention on time will result in an improved outcome in high-risk mothers.[1,2]

Access this article online

www.ijss-sn.com

Month of Submission : 02-2021
Month of Peer Review : 03-2021
Month of Acceptance : 03-2021
Month of Publishing : 04-2021

The MEOWS is a simple bedside screening tool for assessing maternal morbidity. Screening identifies the individuals who are likely to have morbidity, while a diagnostic test seeks to confirm its presence definitively.[3] In the UK, there has been a small but welcome decline in maternal death rates against a backdrop of increasing birth rates and an older and less healthy population of mothers.[4,5] However for every maternal death, nine women developed major obstetric complications including hemorrhage, preeclampsia and its complications, sepsis, pulmonary edema, and thromboembolism. A confidential enquiry into the maternal deaths in the UK identified substandard care in a number of cases.[6,7] Many of the avoidable factors such as lack of routine observations and failure to recognize the significance of deteriorating vital signs remained the same as those identified in the previous enquiries. To

Corresponding Author: Dr. R Venkatesan, A-2, Teaching Staff Quarters, GMC, Pudukkottai - 622 004, Tamil Nadu, India.

reduce this delay, there have been calls for a "MEOWS" for routine use on all pregnant and postpartum women who have been admitted to hospital and require obstetric care.[8] Use of MEOWS is now included in maternity risk management standards set by the National Health System litigation authority.[9]

MEOWS was introduced to obstetric units in the United Kingdom to decrease maternal mortality by improving early detection by clinical signs of deterioration in women who were developing critical illnesses. Earlier warning scores have been used successfully in other areas, such as acute medicine, however, these scores could not be transferred to obstetric patients because of the normal physiological changes that occur during pregnancy. The MEOWS has been modified for the obstetric population needs to have predictive ability for conditions such as sepsis, hemorrhage, and preeclampsia, and to reflect the physiological changes associated with pregnancy and the early postnatal period.[10]

The existing Joint Commission standardized requirements of hospitals to have a protocol for identifying early warning signs of deterioration by the staffs and to seek assistance if this occurs. A sentinel event alert concerning increasing rates of maternal mortality in the United States recommends that specific changes in maternal vital signs and clinical condition should trigger a predetermined response.[11]

Several early warning tools are currently in use. "In Great Britain, the MEOWS has been proposed and in the United States the National Council for Patient Safety recently proposed the use of the maternal early warning criteria," they write. "Although the use of these tools is widely supported, there are no uniform criteria for inclusion or exclusion of various parameters, what degree of abnormality should be used to measure trigger as more severe or less, mode of treatment as aggressive or less and intervention at what time, and early warning tool was specifically designed to address the four most common causes of maternal morbidity (hemorrhage, preeclampsia, sepsis, and cardiovascular dysfunction). Only the MEOWS has been prospectively tested to evaluate if their use will result in decreased maternal morbidity.[12]" Critical illness in pregnancy is uncommon but potentially a devastating complication of pregnancy.[13] It may be devastating not only for the woman who is sick, but also for her family and for those health-care professionals who are responsible for her care. At its most extreme, critical illness if left unintervened may lead to the death of the woman during pregnancy or shortly afterward. The Confidential Maternal Deaths Enquiry published in 2012 confirmed that Ireland continues to have a low maternal mortality ratio (MMR) by international standards. However, they took efforts to improve the quality of clinical care further in the maternity services continuously.

Critical illness in pregnancy may be due to conditions unique to pregnancy, conditions exacerbated by pregnancy or due to coincidental conditions. This is reflected in the classification of maternal deaths into direct, indirect, and coincidental deaths (CMACE, 2011). The conditions unique to pregnancy include obstetric hemorrhage, preeclampsia/eclampsia, pulmonary embolism (venous and amniotic fluid), chorioamnionitis/endometritis, uterine rupture, placenta accreta, increta, and acute fatty liver of pregnancy.[14]

It has been estimated that for every maternal death, there are around nine women who develop severe maternal morbidity.[15] In a study of severe maternal morbidity for 2004 to 2005 in the three Dublin maternity hospitals, the rate of severe maternal morbidity was 3.2 per 1000 pregnancies.[16] The most common cause was hemorrhage. A national review of postpartum hemorrhage (PPH) in Ireland over 11 years between 1999 and 2009 found that there were increasing rates of atonic PPH.[17]

The MEOWS demonstrated a much higher sensitivity than non-obstetric early warning systems that are currently used in the adult population. MMRs are very high in Asia and Africa compared with North Europe's 4/100,000 live births. An Indian hospital study found the MMR to be 4.21/1000 live births. About 50–98% of maternal deaths are caused by direct obstetric causes (hemorrhage, infection, and hypertensive disorders, ruptured uterus, hepatitis, and anemia). About 50% of maternal deaths due to sepsis are related to illegal induced abortion. MMR in India has not declined significantly in the past 15 years. Age, primi and grand multipara, unplanned pregnancy, and related illegal abortion are the reproductive causes. In 1985, the WHO reported that 63–80% of maternal deaths due to direct obstetric causes and 88–98% of all maternal deaths could probably have been prevented with proper handling. In India, improper coordination between levels in the delivery system and fragmentation of care account for the poor quality of maternal health care.[18]

Gupta *et al.* conducted a study in Rajasthan to ascertain the magnitude of MMR and their causes. The study was conducted in the state of Rajasthan in India, covering

25,926 households in 411 villages. It has two major components: A community-based household survey and a case–control study with cases and controls sampled from the same population. A total of 32 maternal deaths and 6165 live births were identified. The group of women who died during pregnancy or delivery (cases) is compared with a group of women who gave birth and survived (controls). MMR was estimated to be 519 (95% confidence interval [CI], 477–561). Hemorrhage was the chief cause (31%) of maternal deaths; the other causes were obstructed labor, severe anemia, puerperal sepsis, and abortion. Young age at child birth (odds ratio [OR], 2.6; 95% CI, 1.9–3.2) and poverty (OR, 2.5; 95% CI, 1.6–3.4) were independently associated with increased risk of maternal death.[19]

Women in rural India are suffering primarily because of the inability of the people managing in rural health centers to recognize clinical symptoms in time, resulting in their failure to diagnose and delayed referral to a higher center contributes to majority of the maternal deaths. For every woman in India who die due to pregnancy-related complications, there are 20 who suffer from acute and chronic morbidity, some of them are life threatening.

Aims and Objectives

This study aims to evaluate the MEOWS as a tool for predicting maternal morbidity by measuring its sensitivity, specificity, and predictive value for various parameters which are used to assess various maternal morbidities diagnosed during this study period. This is to provide guidance to the healthcare personnel who are involved in the maternity services on recognizing and monitoring the obstetric patients using the MEOWS chart. This will enable early recognition of patient deterioration; advice on the level of monitoring required by each patient, facilitate better communication within the multidisciplinary team, and ensure prompt management of any women whose condition is deteriorating.

MATERIALS AND METHODS

This study is a prospective study carried out from November 2014 to April 2016 at K.A.P.V Medical College and M.G.M Government Hospital, Trichy, after getting approval from the Institutional Ethical Committee. Over a period of 9 months, 1000 parturient women, all women with gestation between 20 weeks to term were included in the study. They were admitted as inpatients to the maternity unit and followed up postpartum up to the period of discharge. All patients fulfilling the inclusion criteria were explained about the type of study and written informed consent was obtained.

Inclusion Criteria

The following subjects were enrolled for the study:

Women aged between 18 and 40 years, having gestational age from 20 weeks till term, were followed postnatal up to discharge. Pregnant women were enrolled irrespective of any gravida, any presentation, and single/multiple gestation.

Exclusion Criteria

Patients who were already diagnosed and treated with the following diseases/disorders were excluded from the study: Anemia, preeclampsia, chronic hypertension, overt diabetes mellitus, chronic medical disease, and thyroid dysfunctions.

Measurement of temperature (oral), blood pressure, heart rate (HR), respiratory rate (RR), oxygen saturation (pulse oximetry), conscious level, and pain score were documented every 12 h. Frequency of observations is determined by risk status, diagnosis, reason for admission, and initial observations on admission. An individual plan of care which specified the frequency of physiological observations was decided by the doctor.

The MEOWS has been designed to allow early recognition of deterioration in parturient women by monitoring variation in their physiological parameters. MEOWS is a way of formal measurement of physiological variables. The values of the observations are then translated into a summary score which has a critical threshold, above which medical review and intervention are required.

Guidelines for the Use of MEOWS in Detecting the Seriously Ill and Deteriorating Woman

Effective warning systems include clear expectations for observation, predefined criteria for an abnormality, and a protocol to trigger a response if an abnormality is detected.[20] The MEOWS was calculated by scoring the values of a full set of observations carried out routinely by staff which included the following:

i). Temperature ------ <35°C or >37.4°C[21]
ii). Systolic blood pressure (SBP) ----- <90 or >140 mmHg[22]
iii). Diastolic blood pressure (DBP)-------- <46 or>90 mmHg
iv). HR------- <51 or>100[23]
v). RR ------- <9 or >14
vi). Level of consciousness using AVPU scale
A – Alert and conscious
V – Responds to voice
P – Pain responds to pain
U – Unresponsive no response to voice or pain
vii). +/- urine output ------ <30 ml/ 2 h
viii). Oxygen saturation ----- <95%.

MEOWS Scoring

Score	3	2	1	0	1	2	3
Tempe rature		<35°c		35°-37.4°c		37.5-39°c	>39°c
Systolic BP	≤70	71-79	81-89	90-139	140-149	150-159	≥160
Diastolic BP			≤45	46-89	90-99	100-109	≥110
Pulse		≤40	40-50	51-100	101-110	111-129	≥130
Respiratory rate		≤8		9-14	15-20	21-29	≥30
APVU				alert	Responds to voice	Responds to pain	unconscious
U/O ml per hour	<10	<30		Not measured			

Triggering on MEOWS chart

A trigger was defined as a single markedly abnormal observation (red trigger) or a combination of two simultaneous mildly abnormal observations (two yellow triggers).

PARAMETER	RED TRIGGER	YELLOW TRIGGER
TEMPERATURE	< 35 or > 38	35–36
SYSTOLIC BP	<90 or>160	150-160 or 90-100
DIASTOLIC BP	>100	90-100
HEART RATE	<40 OR>120	100-120 OR 40-50
RESPIRATORY RATE	<10 OR >30	21-30
O2 SAT	<95	
NEUROLOGICAL SCORE	UNRESP,PAIN	VOICE

The examined subjects were classified into two groups: Those who triggered and those who did not trigger. A trigger is set to prompt urgent medical attention.

Any patient is said to have developed a trigger if she fulfills any of the criteria mentioned below: Hypertension (SBP >160 or DBP >100), hypotension (SBP <90), tachycardia (HR >120), bradycardia (HR <50), tachypnea (RR >30), bradypnea (RR <10), hypoxemia (SpO_2 <95% on room air), oliguria (<30 cc/h for >2 h), confusion, agitation, or unresponsiveness.

OBSERVATION AND RESULTS

Table 1 shows that primigravida formed the bulk (51.4%) of the cases while the multigravida formed the remaining cases. This is depicted in Figure 1.

Table 2 shows that out of 1000 cases examined, 131 cases triggered for parameter of tachycardia and the remaining 869 did not trigger for the same. This is depicted in Figure 2.

Table 3 shows that out of the 1000 cases, 14.7% of the cases triggered for increase in blood pressure and diagnosed hypertensive and the rest 85.3% did not trigger and remained normotensive is shown in Figure 3.

Table 1: Gravida status

	Frequency	Percent
PRIMI	514	51.4
MULTIGRAVIDA	486	48.6
Total	1000	100.0

Table 2: Heart rate

	Frequency	Percent
INCREASED	131	13.1
NORMAL	869	86.9
Total	1000	100.0

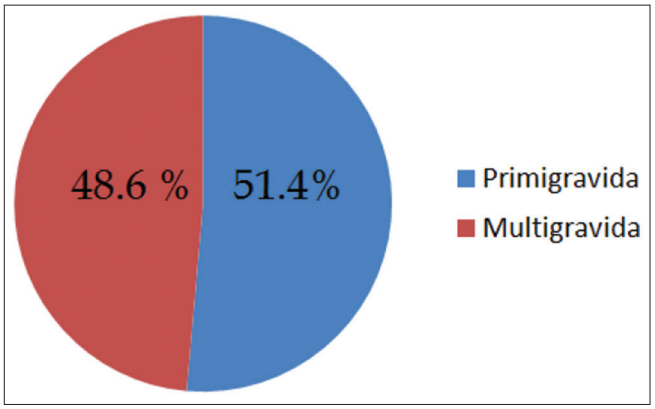

Figure 1: Gravida status

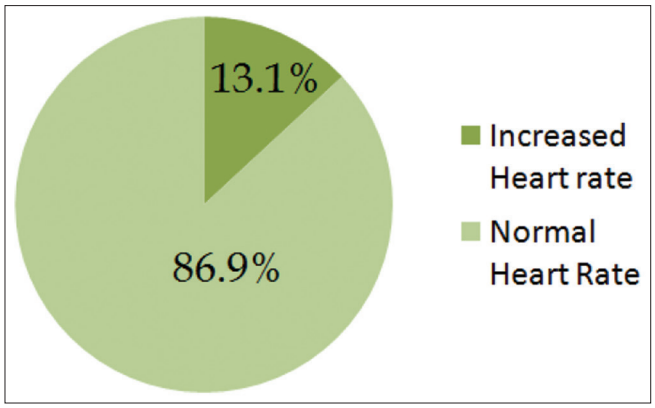

Figure 2: Heart rate

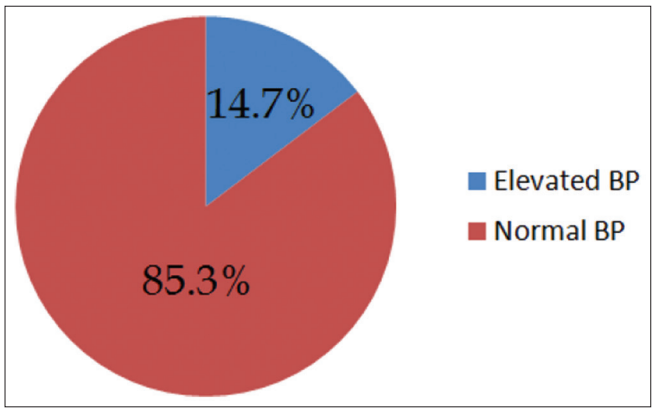

Figure 3: Blood pressure

Table 4 shows that of all the cases examined in the study, only six cases showed elevated renal parameters while 994 cases had normal renal parameters. This is depicted in Figure 4.

Table 5 shows that there was trigger for elevation in temperature in only nine cases that were studied. Remaining 991 cases had normal body temperature as shown in Figure 5.

Table 6 shows that out of the 1000 cases examined in the study, 23 cases showed the trigger for tachypnea while the remaining 977 cases recorded normal RR. This is depicted in Figure 6.

Table 7 shows the neurological score of the examined cases. About 98% of cases were neurologically normal and <2% of cases were found to have neurological instability. This is depicted in Figure 7.

Table 8 shows the magnitude of increase in the triggering parameters noted in the study. Of the 1000 cases examined, 796 cases showed normal parameters. Eighty-two cases showed only elevated blood pressure, 53 cases showed tachycardia, 5% (48) of cases showed elevation of both blood pressure and pulse rate, two cases showed abnormal renal parameters, abnormal blood pressure, abnormal HR, and abnormal RR, two cases showed abnormal renal

Table 3: Blood pressure

	Frequency	Percent
INCREASED	147	14.7
NORMAL	853	85.3
Total	1000	100.0

Table 4: Renal function tests

	Frequency	Percent
INCREASED	6	0.6%
NORMAL	994	99.4%
Total	1000	100.0

Table 5: Temperature

	Frequency	Percent
INCREASED	9	0.9%
NORMAL	991	99.1%
Total	1000	100.0

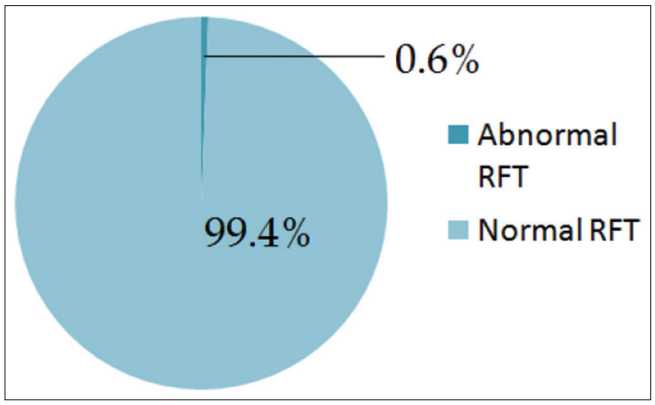

Figure 4: Renal function tests

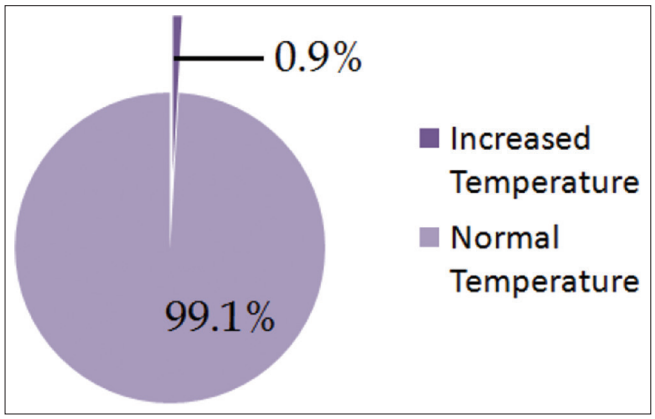

Figure 5: Temperature

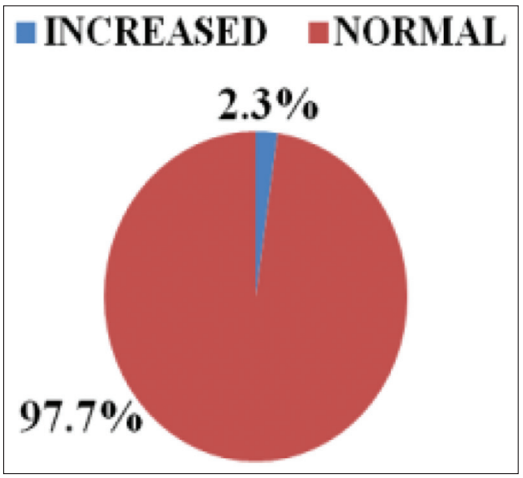

Figure 6: Respiratory rate

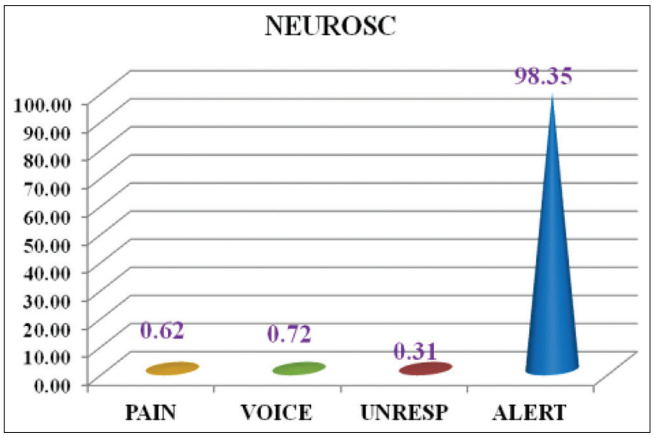

Figure 7: Neurological score

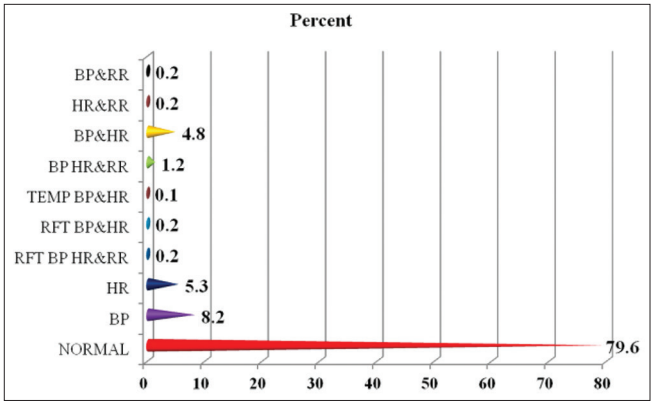

Figure 8: Triggering parameters and normal parameters

Table 6: Respiratory rate

	Frequency	Percent
INCREASED	23	2.3
NORMAL	977	97.7
Total	1000	100.0

parameters, abnormal blood pressure, and abnormal HR, two cases showed abnormal blood pressure and abnormal RR, and two cases showed abnormal blood pressure and abnormal RR. Twelve cases showed elevation of blood pressure, HR, and RR. Only one case showed elevated temperature, abnormal blood pressure, and abnormal HR. This is depicted in Figure 8.

Table 9 shows the spectrum of morbidities seen in the study. Of the 1000 cases examined, 96 cases were preeclamptic, 45 cases had PPH, 19 cases had PPH with preeclampsia, 15 cases were found to have eclampsia, and 2 of these cases with eclampsia developed cortical venous thrombosis (CVT). Wound infection was found in nine cases, three cases had pulmonary edema, and pulmonary thromboembolism was found in one case. This is depicted in Figure 9.

Table 10 shows the exact number of cases that had abnormal elevation of blood pressure with relation to

Table 7: Neurological score

NEUROLOGICAL SCORE	COUNT	PERCENT
PAIN	6	0.62
VOICE	7	0.72
UNRESPONSIVE	3	0.31
ALERT	984	98.35
TOTAL	1000	100

the morbidities recorded. Of the 45 cases recorded with PPH, only three cases had hypertension. Out 0f 96 cases with preeclampsia, 90 cases had elevated blood pressure. Of the 19 cases that had preeclampsia with PPH, 18 cases had hypertension. The correlation of blood pressure to various morbidities was found to be statistically significant.

Table 11 shows the exact number of cases that had abnormal HR in relation to the morbidities. Of 45 cases of PPH, 34 cases showed the trigger of tachycardia, of 96 cases of preeclampsia, 23 cases showed this trigger, of 19 cases of PPH with preeclampsia, 16 cases had the trigger, of nine cases of wound infection, five cases had the trigger, of 15 cases of eclampsia, 13 cases had the trigger, both cases of CVT had the trigger, all the cases of pulmonary edema and embolism had the trigger of tachycardia. The correlation of HR to various morbidities was found to be statistically significant.

Table 12 shows the relation of RR to various morbidities recorded in the study. Tachypnea was present in all cases of pulmonary edema and pulmonary thromboembolism. The correlation of RR with all morbidities was found to be statistically significant.

Table 13 shows the correlation of renal function tests and temperature in relation to the morbidities along with various other parameters such as blood pressure, HR, and RR in relation to the morbidities included in the study. Abnormalities in blood pressure, HR, and combination of both were sensitive in diagnosing morbidities. Other parameters such as RR and temperature too were sensitive in diagnosing morbidities. The correlation of these various parameters in relation to morbidities was found to be statistically significant.

Table 8: Triggering parameters and normal parameters

	Frequency	Percent
NORMAL	796	79.6
BP	82	8.2
HR	53	5.3
RFT BP HR&RR	2	.2
RFT BP&HR	2	.2
TEMP BP&HR	1	.1
BP HR&RR	12	1.2
BP&HR	48	4.8
HR&RR	2	.2
BP&RR	2	.2
Total	1000	100.0

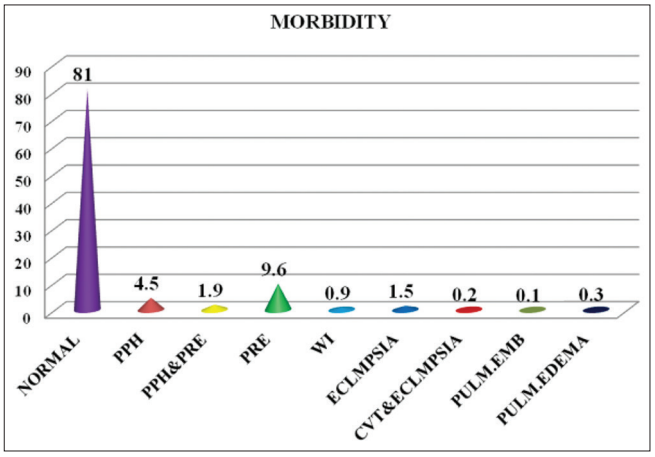

Figure 9: Morbidity spectrum

Table 9: Morbidity spectrum

MORBIDITY	Frequency	Percent
NORMAL	810	81.0
PPH	45	4.5
PPH&PRE	19	1.9
PRE	96	9.6
WI	9	.9
ECLAMPSIA	15	1.5
CVT&ECLAMPSIA	2	.2
PULM.EMB	1	.1
PULM.EDEMA	3	.3
Total	1000	100.0

Table 10: Correlation of blood pressure in relation to the morbidities

		MORBIDITY									Total	Sig
		NORMAL	PPH	PPH & PRE	PRE	WI	ECLAMPSIA	CVT& ECLAMPSIA	PULM. EMB	PULM. EDEMA		
BP	INCREASED	14	3	18	90	1	15	2	1	3	147	P=.000 Sig
		1.4%	.3%	1.8%	9.0%	.1%	1.5%	.2%	.1%	.3%	14.7%	
	NORMAL	796	42	1	6	8	0	0	0	0	853	
		79.6%	4.2%	.1%	.6%	.8%	.0%	.0%	.0%	.0%	85.3%	
Total		810	45	19	96	9	15	2	1	3	1000	
		81.0%	4.5%	1.9%	9.6%	.9%	1.5%	.2%	.1%	.3%	100.0%	

Table 14 **s**hows the occurrence of morbidities in relation to primigravida and multigravida women. Our study has shown that there is no statistical significance in the morbidities in relation to primi or multigravida women.

Table 11: Correlation of heart rate in relation to the morbidities

		MORBIDITY									Total	Sig
		NORMAL	PPH	PPH& PRE	PRE	WI	ECLAMPSIA	CVT& ECLAMPSIA	PULM. EMB	PULM. EDEMA		
HR	INCREASED	34	34	16	23	5	13	2	1	3	131	P=.000 Sig
		3.4%	3.4%	1.6%	2.3%	.5%	1.3%	.2%	.1%	.3%	13.1%	
	NORMAL	776	11	3	73	4	2	0	0	0	869	
		77.6%	1.1%	.3%	7.3%	.4%	.2%	.0%	.0%	.0%	86.9%	
Total		810	45	19	96	9	15	2	1	3	1000	
		81.0%	4.5%	1.9%	9.6%	.9%	1.5%	.2%	.1%	.3%	100.0%	

Table 12: Correlation of respiratory rate in relation to the morbidities

		MORBIDITY									Total	Sig
		NORMAL	PPH	PPH& PRE	PRE	WI	ECLAMPSIA	CVT&ECLAMPSIA	PULM .EMB	PULM. EDEMA		
RR	INCREASED	4	3	2	3	2	4	1	1	3	23	P=.001 Sig
		.4%	.3%	.2%	.3%	.2%	.4%	.1%	.1%	.3%	2.3%	
	NORMAL	806	42	17	93	7	11	1	0	0	977	
		80.6%	4.2%	1.7%	9.3%	.7%	1.1%	.1%	.0%	.0%	97.7%	
Total		810	45	19	96	9	15	2	1	3	1000	
		81.0%	4.5%	1.9%	9.6%	.9%	1.5%	.2%	.1%	.3%	100.0%	

Table 15 shows the diagnostic accuracy values of various parameters included in the study. Blood pressure was found to have highest sensitivity and specificity in relation to the morbidities recorded in our study. HR showed next highest specificity in picking up morbidity. Renal function tests and RRs showed next highest sensitivity in diagnosing morbidities. Blood pressure showed the highest positive predictive value and diagnostic accuracy followed by HR. Negative predictive value was highest with renal function test followed by RR and temperature.

DISCUSSION

Thousand consecutive antenatal cases who got admitted at K.A.P.V Government Medical College in the Department of Obstetrics were examined in a systematic way and findings were recorded. The aim of our study was to clinically evaluate these antenatal women by recording their HR, blood pressure, RR, oxygen saturation (SPO_2), and temperature along with neurological and pain scoring.

Table 13: Correlation of renal function tests and temperature in relation to the morbidities

		NORMAL	PPH	PPH&PRE	PRE	WI	ECLAMPSIA	CVT&ECLAMPSIA	PULM. EMB	PULM. EDEMA	TOTAL	SIGNIFICANCE
co	NORMAL	751	15	2	22	3	3	0	0	0	796	
		75.1%	1.5%	.2%	2.2%	.3%	.3%	.0%	.0%	.0%	79.6%	
	BP	20	11	6	36	4	4	0	0	1	82	
		2.0%	1.1%	.6%	3.6%	.4%	.4%	.0%	.0%	.1%	8.2%	
	HR	27	11	0	14	1	0	0	0	0	53	
		2.7%	1.1%	.0%	1.4%	.1%	.0%	.0%	.0%	.0%	5.3%	
	RFT BP HR&RR	0	0	0	2	0	0	0	0	0	2	
		.0%	.0%	.0%	.2%	.0%	.0%	.0%	.0%	.0%	.2%	
	RFT BP&HR	0	0	0	1	0	1	0	0	0	2	
		.0%	.0%	.0%	.1%	.0%	.1%	.0%	.0%	.0%	.2%	
	TEMP&HR	1	0	0	0	0	0	0	0	0	1	P=0.001
		.1%	.0%	.0%	.0%	.0%	.0%	.0%	.0%	.0%	.1%	Sig
	BP HR&RR	4	3	1	0	0	2	0	1	1	12	
		.4%	.3%	.1%	.0%	.0%	.2%	.0%	.1%	.1%	1.2%	
	BP&HR	6	5	8	20	1	5	2	0	1	48	
		.6%	.5%	.8%	2.0%	.1%	.5%	.2%	.0%	.1%	4.8%	
	HR&RR	1	0	0	1	0	0	0	0	0	2	
		.1%	.0%	.0%	.1%	.0%	.0%	.0%	.0%	.0%	.2%	
	BP&RR	0	0	2	0	0	0	0	0	0	2	
		.0%	.0%	.2%	.0%	.0%	.0%	.0%	.0%	.0%	.2%	
	Total	810	45	19	96	9	15	2	1	3	1000	
		81.0%	4.5%	1.9%	9.6%	.9%	1.5%	.2%	.1%	.3%	100.0%	

These women were allowed to undergo natural course of treatment in the hospital. Their mode of delivery (normal/LSCS) was decided by a competent authority. The morbidities were recorded in an unbiased manner.

Table 14: Occurrence of morbidities in relation to gravida status

		MORBIDITY									Total	Sig
		NORMAL	PPH	PPH&PRE	PRE	WI	ECLAMPSIA	CVT&ECLAMPSIA	PULM.EMB	PULM.EDEMA		
OBS CODE	PRIMI	417	21	7	54	2	10	1	1	1	514	P=.366 Non Sig
		41.7%	2.1%	.7%	5.4%	.2%	1.0%	.1%	.1%	.1%	51.4%	
	MULTIGRAVIDA	393	24	12	42	7	5	1	0	2	486	
		39.3%	2.4%	1.2%	4.2%	.7%	.5%	.1%	.0%	.2%	48.6%	
Total		810	45	19	96	9	15	2	1	3	1000	
		81.0%	4.5%	1.9%	9.6%	.9%	1.5%	.2%	.1%	.3%	100.0%	

Table 15: Diagnostic accuracy values of various parameters

	Sensitivity	Specificity	Positive Predictive Value	Negative Predictive Value	Diagnostic Accuracy
RFT	83%	81.39%	2.63%	99.88%	81.4%
TEMP	55.56%	81.33%	2.63%	99.51%	81.1%
BP	90.48%	93.32%	70%	98.27%	92.9%
HR	74.05%	89.3%	51.05%	95.8%	87.3%
RR	82.61%	82.5%	10%	99.51%	82.5%

Of the 1000 cases enrolled in the study, 514 cases were primigravida and the remaining 486 were multigravida. These multigravida mothers ranged from the second to sixth gravida. For our convenience, we have grouped them together as multigravida. Although the incidence of morbidities such as PPH and PPH with preeclampsia was higher in multigravida, *per se* PPH was most common among grand multigravidae, preeclampsia seems to be more common among very young individuals <21 years, and in multies who had last child birth >5 years and above. Eclampsia was found more often in primi, various other morbidities such as CVT, pulmonary edema, and pulmonary embolism were equal among both. No statistical significance was made out.

Of the 1000 cases that were examined, 131 cases showed the trigger of tachycardia, HR had sensitivity of 74%, specificity of 89%, PPV of 51%, NPV of 95.8%, and diagnostic accuracy of 87.3%.

One hundred and forty-seven women had trigger of elevation of blood pressure. Blood pressure as predictor of morbidity had the sensitivity of 90.5%, specificity of 93.3%, PPV of 70%, NPV of 98.3%, and diagnostic accuracy of 93%.

About 23 cases showed trigger of tachypnea. RR as a predictor of morbidity had sensitivity of 82.6%, specificity of 82.5%, PPV 10%, NPV of 99.5%, and diagnostic accuracy of 82.5%. Only nine women showed trigger of hyperthermia, as a predictor of morbidity, it had sensitivity of 55.6%, specificity of 81.3%, PPV of 2.6%, NPV of 99.5%, and diagnostic accuracy of 81%.

Neurological score was found to be abnormal only in <2% of cases, particularly in cases with eclampsia and CVT. Pain score was found to be normal in 98% of cases and abnormal in <1%.

Of the 1000 cases studied, 810 cases delivered and got discharged normally. Ninety-six cases developed preeclampsia while 45 cases developed PPH and 19 cases had both preeclampsia and PPH. About 15 cases developed eclampsia and two out of these 15 eclamptic cases developed CVT with neurological deficit. Nine cases developed wound infection and three cases developed pulmonary edema, all the three were preeclamptic. With MEOWS, we were able to identify these cases at the right time manage correctly and one case was found to have pulmonary thromboembolism, with timely intervention we are able to resuscitate the case promptly.

The data analysis shows that nearly one-fifth (190) of the cases enrolled in the study developed complications. Of these cases that developed complications, nearly >50% of them were preeclamptic. One-fourth of them had developed PPH.

Relationship of Parameters with Morbidity

The analysis of data further shows that 133 cases out of 147 that had elevated blood pressure developed complications, 97 cases out of 131 that had tachycardia developed complications. About 19 cases out of 23 cases that had elevation of RR developed complications. About five cases out of nine that had elevated temperature had developed complications and five cases out of six who had elevated renal parameters developed complications.

Relationship of Mode of Delivery and Morbidity

Out of 613 cases that underwent normal delivery, 75 cases developed morbidity. Of the 387 cases that had undergone LSCS as mode of delivery, 115 cases developed morbidity. There was a statistical significance of correlation in patients undergoing LSCS as a mode

of delivery developing complications when compared to normal delivery cases. Out of the 514 cases of primi, 97 cases developed morbidity, of the 486 multiparous cases, 93 cases developed morbidity. In our study, there was no significant difference in morbidity between multiparous and nulliparous women.

Parameters Analysis

Blood pressure has the highest sensitivity and specificity in detecting morbidities (90% and 93%, respectively). HR comes second and has a sensitivity and specificity of 74% and 89%. Renal function tests and RR had a sensitivity and specificity of 82%. Temperature had sensitivity and specificity of 55% and 81%, respectively, whereas RR had sensitivity and specificity of 82.6% and 82.5%, respectively.

The positive predictive value was highest with blood pressure 70% followed by HR 51%. The negative predictive value was found to be almost equal in all parameters. Diagnostic accuracy was found to be highest with blood pressure (93%) followed by HR (87%).

CONCLUSION

The MEOWS is a simple bedside screening tool for assessing maternal morbidity. Screening identifies individuals who are likely to have morbidity, while a diagnostic test confirms its presence definitively. We attributed to use morbidity as our primary end point, rather than death because of its rare occurrences in obstetric patients. In MEOWS, we applied the early signs of morbidity that was recognized as triggering criteria. In our hospital, every obstetric patient has a MEOWS chart started at the first visit and vital signs documented until discharge. The chart stays with the mother until postnatal discharge. This provides a visual trend of individual physiology and allows assessment and treatment based on what is abnormal for the patient, not for the population as a whole. There are some drawbacks to our study. The triggers that we used were set close to the values that define morbidity. Thus, a positive trigger, for example, high blood pressure, which is associated with morbidity, often becomes a self-fulfilling prophecy. This is a single-center based study in a tertiary referral center. Our definitions of morbidity have been incorporated from nationally accepted diagnostic criteria as far as possible, but there is no universal definition for obstetric morbidity, some of these definitions are slightly arbitrary, which will influence whether a woman enters the "morbidity" group or not. Despite these limitations, our results strongly support the use of the MEOWS chart for all obstetric patients.

REFERENCES

1. Center for Maternal and Child Enquiries. Saving mothers' lives: Reviewing maternal deaths to make motherhood safer: 2006-08. The Eighth report on confidential Enquiries into Maternal deaths in the United Kingdom. BJOG 2011;118:1-203.
2. Maternal Critical Care Working Group. Providing Equity of Critical and Maternity Care for the Critically Ill Pregnant or Recently Pregnant Woman. London: RCOG Press; 2011.
3. Stephanou AM. Validation of the modified early obstetric warning system (MEOWS). Anaesthesia conference: Association of Anaesthetists of Great Britain and Ireland, AAGBI Annual Congress 2012; Conference Publication No. 67,2012.
4. Mackintosh N, Watson K, Rance S, Sandall J. Value of a modified early obstetric warning systems (MEOWS) in managing maternal complications in the peripartum period: An ethnographic study. BMJ Qual Saf 2014;23:26-34.
5. Helme E, Why M, Comera S. Identifying sick obstetric postoperative patients using MEOWS. Anaesthesia 2012;67:566.
6. Swanton RD, Al-Rawi S. A national survey of obstetric early warning systems in the United Kingdom. Int J Obstet Anesth 2009;18:253-7.
7. Mullhall A. Nursing research. What difference does it make ? J Adv Nurs 1995;21:576-83.
8. Singh S, McGleenan A, England A, Simons R. A validation study of the CEMACH recommended modified early obstetric warning system (MEOWS). Anaesthesia 2012;67:12-8.
9. NHS Litigation Authority. Clinical Negligence Scheme for Trusts. Maternity Clinical Risk Management Standards. Version 1. NHSLA; 2012.
10. Lappen JR, Keene M, Lore M, Grobman WA, Gossett DR. Existing models fail to predict sepsis in an obstetric population with intrauterine infection. Am J Obstet Gynecol 2010;203:573.e1-5.
11. Cook CA. Implementing the modified early obstetric warning score (MEOWS) to detect early signs of clinical deterioration and decrease maternal mortality. J Obstet Neonatal Nurses 2014;43:S22.
12. Tory Brown RN. New maternal early warning tool reduces maternal morbidity. Am J Obstet Gynecol 2016;214:527.e1-6.
13. Baskett TF. Epidemiology of obstetric critical care. Best Pract 2008;22:763-74.
14. Nelligan PJ, Laffey JG. Clinical review: Special populations critical illness and pregnancy. Crit Care 2011;15:1014.
15. Platt F, Naik M. Critical care in pregnancy. Crit Care 2011;15:1014.
16. Murphy CM, Murad K, Deane R, Byrne B, Geary M, McAuliffe FM. Severe maternal morbidity for 2004-2005 in three Dublin maternity hospitals. Eur J Obstet Gynaecol Reprod Biol 2009;143:34-7.
17. Lutomski JE, Byrne B, Devane D, Greene RA. Increasing trends in atonic postpartum haemorrhage in Ireland: An 11 year population based cohort study. Br J Obstet Gynaecol 2012;119:306-14.
18. Prakash A, Swain S, Seth A. Maternal mortality in India: current status and strategies for reduction. Indian Pediatr 1991;28:1395-400.
19. Gupta SD, Khanna A, Gupta R, Sharma NK, Sharma ND. Maternal mortality ratio and predictors of maternal deaths in selected desert districts in Rajasthan a community-based survey and case control study. Womens Health Issues 2010;20:80-5.
20. Ivory CH. Standardizing the words nurses use to document elements of perinatal failure to rescue. J Obstet Gynecol Neonatal Nurs 2014;43:13-24.
21. Royal College of Physicians. National Early Warning Score (NEWS): Standardizing the Assessment of Acute Illness Severity in the NHS, Report of a Working Party. London: RCP; 2012.
22. BP Ranges Adapted from NICE Guidance on Hypertension in Pregnancy; 2010.
23. Pulse, Respiratory Rate, AVPU, Urine Output adapted from NNUH/NHS Trust Early Warning Score; 2010.

How to cite this article: Radha R, Kokila S, Mukilvizhi S, Venkatesan R. Evaluation of the Effectiveness of Modified Early Obstetric Warning System in a Tertiary Health Care Setup. Int J Sci Stud 2021;9(1):167-177.

Source of Support: Nil, **Conflicts of Interest:** None declared.

Print ISSN: 2321-6379
Online ISSN: 2321-595X

Original Article

Posterior Segment Changes in Myopic Patients – An Observational Study

S Kavitha[1], M Deepa[2], V Jeyanthi[2], Heber Anandan[3]

[1]Assistant Professor, Department of Ophthalmology, Tirunelveli Medical College Hospital, Tirunelveli, Tamil Nadu, India, [2]Postgraduate Scholar, Department of Ophthalmology, Tirunelveli Medical College Hospital, Tirunelveli, Tamil Nadu, India, [3]Senior Clinical Scientist, Department of Clinical Research, Dr. Agarwal's Eye Hospital, Chennai, Tamil Nadu, India

Abstract

Introduction: Myopia can be classified by etiology and by its clinical presentation. Pathological myopia forms a major component of the uncorrected refractive errors. The prevalence of pathological or degenerative myopia globally is unclear.

Aim: This study aimed to observe changes occurring in the posterior segment of the eye in high myopic patients and evaluate the correlation between the degree of myopia and the incidence of various posterior segment changes.

Materials and Methods: A hospital-based study was conducted on 100 patients between October 2018 and July 2020. Detail demographic data, ocular history, and family history were collected from patients. Data from all diagnostics investigations were obtained and analyzed.

Results: The study revealed that females showed an increased prevalence of myopia 1.3 times more than males. The prevalence of myopia was 95.6% bilateral and 4.4% unilateral in this study. Among the peripheral retinal changes, lattice degeneration is the most common manifestation noted in both eyes, accounting for 36%. Study results also showed that the severity of myopia is correlated with axial length and visual acuity.

Conclusions: Study findings revealed a strong correlation existed between the presence of parapapillary atrophy and high myopia. There was also a strong positive correlation between axial length and visual acuity in myopic patients.

Key words: Axial length, Myopia, Peripapillary atrophy, Posterior eye segment, Visual acuity

INTRODUCTION

Myopia in Greek words "muopia" is commonly known as nearsighted or short sighted. It is a condition of the eye where the light rays that should come directly on the retina do not directly focus on the retina but in front of the retina. Most professionals commonly correct myopia through the use of corrective lenses such as glasses or contact lens. Myopia is an important public health problem in Asian countries such as China, Japan, and Singapore, where myopia rates increase over the past few decades. This condition has become a benign ocular disorder associated with potentially blinding conditions such as pigmentary degeneration, retinal detachment, premature cataract, glaucoma, and macular choroidal degeneration.[1-3]

Access this article online

www.ijss-sn.com

Month of Submission : 02-2021
Month of Peer Review : 03-2021
Month of Acceptance : 03-2021
Month of Publishing : 04-2021

Uncorrected refractive errors account for almost 21% of the global burden of blindness, rising steadily from 19.9% in 1990. Along with South Asia, India shares a major part of this burden – 36% of blindness in South Asia is accounted for by uncorrected refractive errors.[4,5]

Myopia can be classified by etiology and by its clinical presentation. Pathological myopia forms a major component of the uncorrected refractive errors. The prevalence of pathological or degenerative myopia globally is unclear. A wide range has been reported, starting with a survey by Fuchs before 1960 that revealed the prevalence to be in the range of 0.2–9.6% with a higher prevalence in the Middle Eastern population. More recent studies show the prevalence to be in the range of 1–5%, with higher rates in Asians and much lower in those from the United

Corresponding Author: Dr. M Deepa, Department of Ophthalmology, Tirunelveli Medical College Hospital, Tirunelveli, Tamil Nadu, India.

States, perhaps suggesting the influence of geography or ethnicity.[4-6]

The study of the severest form of myopia, pathological or degenerative myopia, acquires a special significance given the high rates of myopia globally (80% worldwide in the general population) and the varied complications that can result in patients suffering from this dreaded condition. The numerous complications that can arise in pathological myopia include degenerative changes in the sclera, choroid and Bruch's membrane, damage to the retinal pigment epithelium and neural retina, glaucoma, retinal detachment, myopic maculopathy, myopic retinopathy, and premature cataracts.[7,8]

The clinical presentation of pathological myopia is complicated by the numerous changes in the posterior segment of the eye. Apart from the anticipated deterioration of vision, characteristic changes such as liquefaction, condensation, posterior vitreous disease, lacquer cracks, pigment epithelial atrophy, staphyloma, Fuchs spots, lattice degeneration, peripapillary changes, and many others are seen in typical cases of pathological myopia. However, the distribution, pattern, and frequency of these features can be varied in different populations.[5]

Aim

1. This study is intended to study the posterior segment changes of myopic patients
2. The study analyzes the correlation between the degree of myopia and the incidence of various posterior segment changes.

MATERIALS AND METHODS

This is a prospective, observational case series study design. This study was carried out at the Department of Ophthalmology Outpatient block of Government Tirunelveli Medical College and Hospital from October 2018 to July 2020. The patients were registered, detailed history taken, evaluated, and analyzed. Randomly selected 100 patients who fulfilled the inclusion and exclusion criteria were enrolled into the study after obtaining the written informed consent.

Inclusion Criteria

The following criteria were included in the study:

- Patients with myopic refractive error
- Patients in the age more than 5 years.

Exclusion Criteria

- The following criteria were excluded from the study: Subjects with index myopia (as seen in senile cataract)
- Other ocular associations such as microphthalmos, aniridia, megalocornea, and congenital separation of the retina
- Acquired causes of myopia such as post-traumatic, post-keratic, and drug induced
- Subjects with age <5 years who are not able to answer the Snellen's visual acuity charting.

The patients for the study are randomly selected from the general population. Informed consent regarding the study was obtained from the patient. History taking was done regarding the age, gender, occupation, family history, duration of spectacle usage, and frequency of spectacle change. Visual acuity was recorded in both eyes for the patient using a 6 m Snellen visual acuity chart.

Refraction was done for the patient based on retinoscopy and subjective correction given. Based on the degree of refractive error in spherical equivalent, the eyes are categorized as low myopia (−0.25 DS–−2.75 DS), moderate myopia (−3.00 DS–−6.00 DS), and high myopia (>−6.00 DS).

Ocular examination for squint, anterior segment examination to rule out other congenital anomalies was done.

Dilated fundus examination was done by slit-lamp biomicroscopy with +90 D lens and indirect ophthalmoscopy with +20 D lens. The findings were recorded in diagrammatic representation in pro forma. Cases that required diagnostic confirmation were further evaluated with fundus fluorescein angiography, optical coherence tomography, and ultrasound B-scan. All patients were done axial length measurement by A-scan.

RESULTS

A total of 100 patients were enrolled in this study. The majority of patients were from the age group above 45 (46%). About 43% were male and 57% were female. A slight female preponderance of high myopia was seen. It was found that 22% of patients had a positive family history, of which 96% of patients were affected by bilateral myopia. The study also showed that the duration of myopia increases with increasing age. The study shows that the visual impairment of myopic patients increases with the increasing degree of refractive error. Furthermore, the impairment is larger in the high myopia category [Table 1]. Table 1 shows the distribution of myopia based on the final visual outcome after the best correction of refractive error.

As the degree of myopia increases, disc changes were observed in both eyes. The most common disc finding was peripapillary atrophy (PPA) followed by myopic crescent in both eyes [Table 2]. Among the posterior pole changes,

tessellation (54% and 46% in the RE and LE, respectively) was the most common change, followed by chorioretinal atrophy (CRA) and posterior staphyloma in high myopia [Table 3]. The study showed that CRA was predominant among higher degrees of myopia and was absent in low myopia. The CRA was categorized based on different classifications. According to Tokaro's classification, in the RE, 20% had patchy CRA and 13% had diffuse CRA, whereas in the LE, 13% had patchy CRA and 15% had diffuse CRA among the high myopia category [Table 4].

Based on Steidl and Pruett's classification of CRA,[9] Grade-0 CRA (no atrophic changes) was present in 63% in the RE and 60% in the LE. The next common occurrence is Grade-2 CRA (total area of CRA ≤2 optic disc areas) which is 24% in the RE and 22% in the LE [Table 5].

Based on International Photographic Classification and Grading System for Myopic Maculopathy,[10] category-0 (no macular lesions) was found in 23% in the RE and 25% in the LE. Out of which 13% and 15% belonged to the low myopia category of the RE and LE, respectively [Table 6].

Among the peripheral retinal changes, lattice degeneration is the most common manifestation noted in both eyes, accounting for 36% in both eyes, followed by retinal tear, which was 5% in the RE and 3% in the LE [Table 7].

Various vitreous changes have been seen in the posterior segment of both eyes and posterior vitreous detachment was seen with high myopia [Table 8].

Axial length >30 mm was observed in 6% of high myopes in the RE and 2% of high myopes in the LE. Axial length >26.5 mm was observed in 43% of myopes in the RE and 33% of myopes in the LE.

DISCUSSION

One hundred subjects who were having myopia enrolled in the study. All subjects fulfilling the inclusion criteria and willingness to participate in the study were enrolled. In a study done by Venkatesan *et al.*,[11] the incidence of high myopia was seen highest in the 2nd decade. In contrast, in this study, the incidence increased steadily up to the 3rd decade. The highest incidence was seen in the age group of above 45 years. About 4% of cases had unilateral myopia, similar to 7% incidence seen in the study by Venkatesan *et al.*[11] The study revealed that females showed an increased prevalence of myopia 1.3 times more than males. Family history is present in only 22%, which was much higher than in the study by Venkatesan *et al.* (7%).[11]

About 80% of subjects had their uncorrected visual acuity between 1/60 and 6/60 of Snellen visual acuity chart in both the eyes. All patients belonging to the low myopia category had their best-corrected visual acuity improved to the category of 6/6–6/12 on the Snellen visual acuity chart. About 27% of subjects belonging to moderate myopia and 18% of subjects belonging to high myopia improved with refraction to the best-corrected visual acuity category of 6/6–6/12 in the RE. About

Table 1: Association of uncorrected and corrected visual acuity of the right and left eye (LE) with the degree of myopia

VA	Degree of myopia right eye (RE)			Degree of myopia LE		
	Low myopia	Moderate myopia	High myopia	Low myopia	Moderate myopia	High myopia
Uncorrected visual						
<1/60	0	0	1%	0	1%	3%
1/60–6/60	0	26%	54%	6%	31%	43%
6/18–6/36	11%	6%	0	8%	5%	0
6/6–6/12	2%	0	0	3%	0	0
Best-corrected visual acuity						
<1/60	0	0	0	0	1%	2%
1/60–6/60	0	0	12%	0	0	11%
6/18–6/36	0	5	25%	0	11%	17%
6/6–6/12	13%	27%	18%	17%	25%	16%

RE: Right eye, LE: Left eye

Table 2: Comparison of various disc changes with degree of myopia

Degree of myopia	Normal size disc		Large disc		PPA		Myopic crescent		Nasal super-traction	
	R	L	R	L	R	L	R	L	R	L
Low myopia	13	17	0	0	0	2	1	8	0	0
Moderate myopia	30	29	2	8	26	31	16	18	6	6
High myopia	22	21	33	25	49	41	23	20	12	13

25% of subjects belonging to moderate myopia and 16% of subjects belonging to high myopia improved with refraction to the best-corrected visual acuity category of 6/6–6/12 in the LE.

The most common disc finding in this study was PPA, seen in 49% in the RE and 41% in the LE of cases, while myopic crescent was seen in 23% RE and 20% in the LE. In contrast, in a study by Chang *et al.*,[12] the most common myopia-related macular finding in adults with high myopia was staphyloma (23%) followed by CRA (19.3%). Based on disc size comparison, 35% had a large disc in the RE and 33% had a large disc in the LE.

Table 3: Comparison between the various posterior pole changes and the degree of myopia

Degree of myopia	Tessellation		CRA		Myopic maculopathy		Posterior staphyloma	
	R	L	R	L	R	L	R	L
Low myopia	0	2	0	0	0	2	0	0
Moderate myopia	28	32	4	10	23	27	1	2
High myopia	54	46	32	26	54	46	22	21

CRA: Chorioretinal atrophy, PPA: Peripapillary atrophy

Table 4: Analysis of the different types of CRA in various degrees of myopia

Degree of myopia	Type of CRA RE (%)		Type of CRA LE (%)	
	Patchy	Diffuse	Patchy	Diffuse
Moderate myopia	4	0	9	1
High myopia	20	13	13	15

CRA: Chorioretinal atrophy, PPA: Peripapillary atrophy, RE: Right eye, LE: Left eye

Table 5: Analysis of various grades of CRA in the RE and LE according to Steidl and Pruett's classification

Degree of myopia	Grade of CRA									
	Grade-0		Grade-1		Grade-2		Grade-3		Grade-4	
	RE	LE	RE	LE	RE	LE	RE	LE	RE	LE
Low	13	15	0	2	0	0	0	0	0	0
Moderate	28	27	0	0	4	9	0	1	0	0
High	22	18	0	0	20	13	11	13	2	2

CRA: Chorioretinal atrophy, RE: Right eye, LE: Left eye

Among the posterior pole changes, tessellation was the most common change, followed by CRA, followed by posterior staphyloma. In mild degrees of myopia, the severity of retinal background tessellation was not prominent and as myopia increased, gross tessellation was noted. This may be due to the thinning of the retinal pigment epithelium, which exposes the underlying choroid secondary to the elongation of the globe.[5]

Based on Tokaro's classification of CRA, patchy atrophy was predominant than diffuse atrophy. In the RE, patchy atrophy was 64.86% and diffuse atrophy was 35.14%. In the LE, patchy atrophy was 57.9% and diffuse atrophy was 42.1%. The CRA was also analyzed based on Steidl and Pruett`s classification of CRA[9] and International Photographic Classification and Grading System for myopic maculopathy.[10]

Peripheral retinal degeneration changes were common in moderate to higher degrees of myopia in a cross-sectional study, up to 61.7% of highly myopic eyes were found to have peripheral retinal change.

Among the peripheral retinal changes, lattice degeneration is the most common manifestation noted in both eyes, accounting for 36% in both eyes, in contrast to a study done by Pierro *et al.*[13] Among the peripheral retinal changes, the second most common was retinal tear which was 5% in the RE and 3% in the LE. High myopia was also suggested to be associated with bilateral retinal detachment, a condition of very severe visual morbidity.[14] In the LE, 2% of subjects had retinal detachments along with retinal tear. Posterior vitreous detachment is found in 33% of patients in the RE and 34% of patients in the LE.

The study analysis showed the correlation between the degree of myopia and the range of axial length. With the increase in axial length, the degree of myopia increases.

Table 6: Analysis of various categories of myopic maculopathy in the RE and LE according to International Photographic Classification

Degree of myopia	Myopic maculopathy											
	Category-0		Category-1		Category-2		Category-3		Category-4		Category-4 plus disease	
	RE	LE	RE	LE	RE	LE	RE	LE	RE	LE	RE	LE
Low	13	15	0	2	0	0	0	0	0	0	0	0
Moderate	9	10	19	17	0	0	4	9	0	0	0	0
High	1	0	21	18	11	13	20	12	1	1	1	1

RE: Right eye, LE: Left eye

Table 7: Comparison between the various peripheral retinal changes and the degree of myopia

Degree of myopia	Lattice degeneration		Snail track degeneration		Retinal tear		Retinal hole		Retinal detachment	
	R	L	R	L	R	L	R	L	R	L
Low myopia	0	1	0	0	0	0	0	0	0	0
Moderate myopia	11	13	2	2	0	1	1	1	0	1
High myopia	25	22	2	3	5	3	1	3	0	2

Table 8: Analysis of posterior vitreous detachment in various degrees of myopia in the right and LE

Degree of myopia	Posterior vitreous detachment			
	RE		LE	
	Present	Absent	Present	Absent
Low	0	13	2	15
Moderate	6	26	11	26
High	27	28	21	25

RE: Right eye, LE: Left eye

CONCLUSIONS

This study concludes that females have an increased prevalence of myopia than males. Family history is not a significant correlation for myopia. Almost all cases report bilateral presentation of myopia. With the increase in the degree of myopia, the visual acuity worsens. The presence of posterior pole changes contributes to a significant reduction in visual acuity. Furthermore, the prolongation of axial length contributes to an increase in the degree of myopia and ocular morbidity.

REFERENCES

1. Tong L, Huang XL, Koh AL, Zhang X, Tan DT, Chua WH. Atropine for the treatment of childhood myopia: Effect on myopia progression after cessation of atropine. Ophthalmology 2009;116:572-9.
2. Anstice NS, Phillips JR. Effect of dual-focus soft contact lens wear on axial myopia progression in children. Ophthalmology 2011;118:1152-61.
3. Singh H, Hua XS, Ahmad R, Kumar P, Jian S. Observational study on myopia progression in children. IOSR J Dent Med Sci 2014;13:82-5.
4. Bourne RR, Stevens GA, White RA, Smith JL, Flaxman SR, Price H, *et al*. Causes of vision loss worldwide, 1990-2010: A systematic analysis. Lancet Glob Health 2013;1:339-49.
5. Pande C, Wairagade N, Kanse VS. Posterior segment changes in high myopic patients-an observational study. Int J Sci Healthc Res 2020;5:66-70.
6. Xu L, Wang Y, Li Y, Cui T, Li J, Jonas JB. Causes of blindness and visual impairment in urban and rural areas in Beijing: The Beijing eye study. Ophthalmology 2006;113:e1-11.
7. Louis DE. Pathological Refractive Errors: System of Ophthalmology, Ophthalmic Optics, and Refraction; 1970.
8. Young TL. Molecular genetics of human myopia: An update. Optom Vis Sci 2009;86:E8-22.
9. Steidl SM, Pruett RC. Macular complications associated with posterior staphyloma. Am J Ophthalmol 1997;123:181-7.
10. Ohno-Matsui K, Kawasaki R, Jonas JB, Cheung CM, Saw SM, Verhoeven VJ, *et al*. International photographic classification and grading system for myopic maculopathy. Am J Ophthalmol 2015;159:877-83.
11. Venkatesan MJ, Kumar NS, Vijayalakshmi C. Clinical analysis of fundus changes in myopia. Indian J Sci Technol 2015;8:1-6.
12. Chang L, Pan CW, Ohno-Matsui K, Lin X, Cheung GC, Gazzard G, *et al*. Myopia-related fundus changes in Singapore adults with high myopia. Am J Ophthalmol 2013;155:991-9.
13. Pierro L, Camesasca FI, Mischi M, Brancato R. Peripheral retinal changes and axial myopia. Retina 1992;12:12-7.
14. Ohno-Matsui K, Yoshida T, Futagami S, Yasuzumi K, Shimada N, Kojima A, *et al*. Patchy atrophy and lacquer cracks predispose to the development of choroidal neovascularisation in pathological myopia. Br J Ophthalmol 2003;87:570-3.

How to cite this article: Kavitha S, Deepa M, Jeyanthi V, Anandan H. Posterior Segment Changes in Myopic Patients – An Observational Study. Int J Sci Stud 2021;9(1):178-182.

Source of Support: Nil, **Conflicts of Interest:** None declared.