

Eyelid Lesions: A Clinical Study

L Nanda¹, Kaushal Kumar², Garima Singh Bali³

¹Senior Resident, Department of Ophthalmology, Rajarajeswari Medical College, Bengaluru, Karnataka, India, ²Professor and Head, Department of Ophthalmology, Rajarajeswari Medical College, Bengaluru, Karnataka, India, ³Postgraduate Student, Department of Ophthalmology, Rajarajeswari Medical College, Bengaluru, Karnataka, India

Abstract

Introduction: Eyelid lesions are very common. These can be inflammatory, infectious, or neoplastic. Diagnosis is made by history and clinical examination. In suspected lesions, biopsy has to be done.

Purpose: The aim of the study is to report the relative frequency of eyelid lesions.

Materials and Methods: A prospective cross-sectional clinical study was done in 140 patients with eyelid lesions. All patients underwent eye examination which included visual acuity assessment, anterior segment, and fundus examination. In suspected lesions, biopsy was done to rule out malignancy.

Results: Among 140 patients, external hordeolum was the most commonly seen with 64 cases (45.7%), followed by chalazion 50 cases (35.7%), nevus 7 cases (5%), xanthelasma 6 cases (4.3%), sebaceous cyst 4 cases (2.9%), cutaneous horn 3 cases (2.2%), squamous papilloma 2 cases (1.4%), dermoid cyst 3 cases (2.1%), and molluscum contagiosum 1 case (0.7%).

Conclusion: Eyelid lesions are common with most being benign. Each lesion carries a different line of treatment. Early diagnosis and timely intervention help to prevent serious complications.

Key words: Biopsy, Chalazion, Diagnosis, External hordeolum, Eyelid lesions, Nevus

INTRODUCTION

Eyelid lesions are commonly encountered during clinical practice.

Diagnosis of these lesions requires an understanding of the anatomy of the lids along with history, clinical examination, and appropriate investigation such as histopathological examination in cases of suspected malignancy where a diagnosis cannot be made with accuracy on clinical grounds alone.

The anatomy of lids consists of the structures from within outward as skin, layer of subcutaneous areolar tissue, layer of striated muscles, submuscular areolar tissues, fibrous layer, layer of non-striated muscle fibers, and conjunctiva.

Adnexal structures such as eyelashes, meibomian gland, gland of Zeis, gland of moll, vessels, and lymphatics also form a part of the eyelid structure.

A careful history taking which includes symptoms, chronicity, and progression along with a detailed examination of the lesion can help clinch a clinical diagnosis of the lesion.

Eyelid lesions can be categorized as follows:

- Inflammatory
 - Chalazion
- Infectious
 - External hordeolum
 - Hordeolum internum
 - Molluscum contagiosum.
- Neoplastic
 - Benign lesions: Squamous cell papillomas, epidermal inclusion cyst, acquired melanocytic nevi, seborrheic keratosis, hidrocystoma, and xanthelasma.
 - Premalignant lesions: Actinic keratosis and keratoacanthoma.
 - Malignant lesions: Basal cell carcinoma, squamous cell

Access this article online



www.ijss-sn.com

Month of Submission : 02-2018
Month of Peer Review : 03-2018
Month of Acceptance : 04-2018
Month of Publishing : 05-2018

Corresponding Author: Dr. Garima Singh Bali, Department of Ophthalmology, Rajarajeswari Medical College, Bengaluru, Karnataka, India. Phone: +91-07338008646. E-mail: garimabali248@gmail.com

carcinoma, sebaceous carcinoma, melanoma, Merkel cell carcinoma, lymphomas, and metastasis.

Objective

- The study was carried out to report the relative frequency of eyelid lesions.

MATERIALS AND METHODS

- Type: A prospective cross-sectional clinical study
- Duration: 6 months (November 1, 2016–April 30, 2017)
- Place of study: Rajarajeswari Medical College and Hospital
- Source of study: All patients attending the OPD of the hospital with eyelid lesions during the period extending from December 1, 2016 to April 30, 2017.
- Sample size: 140
- Method of collection of data: All patients underwent thorough examination including history. Followed by clinical examination which included visual acuity assessment using Snellen chart, detailed eyelid examination, anterior segment evaluation with slit lamp, and fundus examination. Histopathological study was done in suspected cases to rule out malignancy.

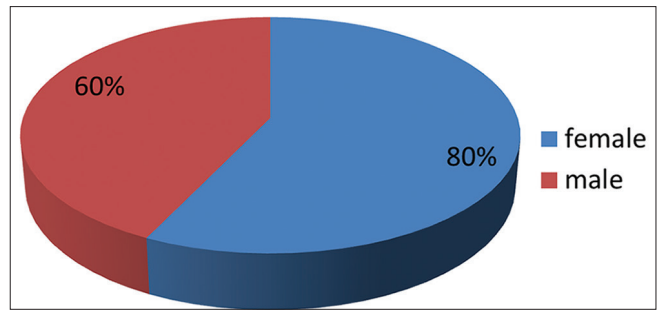
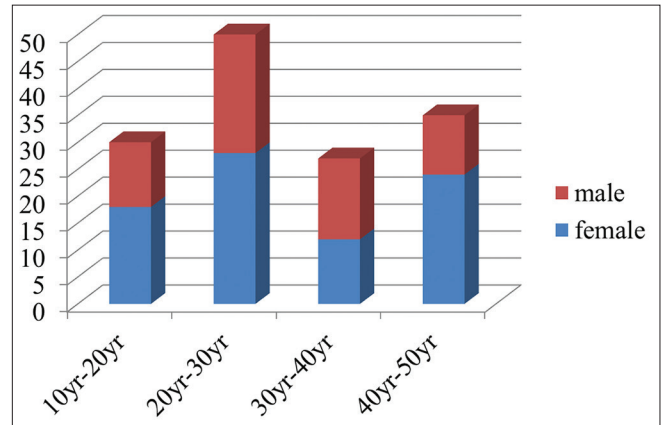


Figure 1: Sex distribution



Graph 1: Age and sex distribution

RESULTS

- A total of 140 patients were examined during a period of 6 months.
- All the cases were benign with histopathological confirmation in suspected cases.
- The study showed a female preponderance with 80 (57%) female patients and 60 (43%) male patients [Figure 1].
- The patients were between the age group of 10 and 50 years.
- 30 patients belonged to the age group of 10–20 years, 48 to 20–30 years, 27 to 30–40 years, and 35 to 40–50 years [Table 1].
- Maximum number of cases was seen in the age group of 20–30 years with the female preponderance in all the age groups [Graph 1].
- All the cases were benign, out of which external hordeolum was the most commonly seen with 64 cases (45.7%), followed by chalazion 50 cases (35.7%), nevus 7 cases (5%), xanthelasma 6 cases (4.2%), sebaceous cyst 4 cases (2.8%), cutaneous horn 3 cases (2.1%), squamous papilloma 2 cases (1.4%), dermoid cyst 3 cases (2.1%), and molluscum contagiosum 1 case (0.7%) [Table 2].

DISCUSSION

- Eyelid lesions are very common and most of them are benign. Deprez *et al.*^[1] studied 5504 cases over a period of 19 years and found 84% of benign tumors and rest malignant. The majority of eyelid lesions were benign eyelid tumors while malignant eyelid tumors contributed 10.8% of the total eyelid lesions.^[2] In some cases, malignant lesions have clinical features similar to that of benign lesions. Therefore, in suspected benign lesions, histopathological examination is mandatory. Histopathologic evaluation enforces our clinical diagnostic skills and is extremely important in early detection of tumors, particularly in masquerade syndromes.^[3]
- During the course of the study, maximum number of cases was of external hordeolum (45.7%). Also known as stye, it is an acute staphylococcal abscess of an eyelash follicle and its associated gland of Zeis. The patients in our study belonged to a younger age group and were treated with hot compresses, topical antibiotics, and epilation of associated cilia. In case of non-resolving lesions, incision and drainage can be done.
- In our study, the second most common lesion was of chalazion (35.7%). Chalazion is the most common lid lesion faced by the ophthalmologist.^[1,4,5] It is a

Table 1: Age distribution

Age distribution (years)	Number of cases
10–20	30
20–30	48
30–40	27
40–50	35

Table 2: Frequency of eyelid lesions

Benign lesions	Number of cases (%)
External hordeolum	64 (45.7)
Chalazion	50 (35.7)
Nevus	07 (5)
Xanthelasma	06 (4.2)
Sebaceous cyst	04 (2.8)
Cutaneous horn	03 (2.1)
Squamous papilloma	02 (1.4)
Dermoid cyst	03 (2.1)
Molluscum contagiosum	01 (0.7)
Total	140 (100)

chronic sterile lipogranulomatous inflammation of the meibomian glands and some cases the gland of Zeis. Cases of chalazion were seen mostly in the younger age group with 2 cases belonging to the older age group. Lesions were treated with incision and curettage. Rarely, the chalazion is injected with steroids; however, this may result in hypopigmentation of the overlying skin.^[6] Histopathological confirmation was made for the 2 suspected cases based on a history of recurrence. Recurrent chalazion was the most common indication for chalazion biopsy as sebaceous cell carcinoma (SGC) was always included as a differential diagnosis as some cases of SGC can mimic this lesion.^[7] One study reported as much as 20% of sebaceous carcinomas were initially misdiagnosed as recurrent chalazion.^[8]

- Cases of sebaceous cyst (2.8%), cutaneous horns (2.1%), squamous papilloma (1.4%), and molluscum contagiosum (0.7%) were diagnosed on the basis of their peculiar appearance. All the above lesions were

seen in adults except for molluscum contagiosum which was seen in the pediatric age group. The cases were treated by excision with histopathological confirmation of diagnosis and the benign nature of the lesions.

- Lesions such as nevus (5%), xanthelasma (4.2%), and dermoid cyst (2.1%) encountered during the study were managed on the basis of observation and specific investigations such as lipid profile in case of xanthelasmas and neurosurgical opinion in case of dermoid cyst to know the invasion into deeper structures.
- The study revealed that all the cases were benign with a female preponderance affecting patients between the age group of 10 and 50 years.

CONCLUSION

Eyelid lesions are common with most being benign. Each lesion carries a different line of treatment. Early diagnosis and timely intervention help prevent ocular complications that could compromise vision, comfort, and cosmesis.

REFERENCES

1. Yanoff M, Fine BS. Ocular Pathology. Ocular Melanocytic Tumors. 5th ed., Vol. 17. Maryland Heights Missouri: Mosby Inc.; 2002. p. 641-51, 6, 193-4.
2. Pompanich K, Chindasub P. Eyelid tumors in siriraj hospital from 2000-2004. J Med Assoc Thai 2005;88 Suppl 9:S11-4.
3. Kersten RC, Ewing-Chow D, Kulwin DR, Gallon M. Accuracy of clinical diagnosis of cutaneous eyelid lesions. Ophthalmology 1997;104:479-84.
4. Nerad JA. Oculoplastic Surgery: The Requisites in Ophthalmology. Vol. 10. St. Louis: C.V. Mosby Co.; 2005. p. 271-2.
5. Tran DT, Wolgamot GM, Olerud J, Hurst S, Argenyi Z. An 'eruptive' variant of juvenile xanthogranuloma associated with langerhans cell histiocytosis. J Cutan Pathol 2008;35 Suppl 1:50-4.
6. Mohan K, Dhir SP, Munjal VP, Jain IS. The use of intralesional steroids in the treatment of chalazion. Ann Ophthalmol 1986;18:158-60.
7. Ozdal PC, Codère F, Callejo S, Caissie AL, Burnier MN. Accuracy of the clinical diagnosis of chalazion. Eye (Lond) 2004;18:135-8.
8. Shields JA, Demirci H, Marr BP, Eagle RC Jr., Shields CL. Sebaceous carcinoma of the eyelids: Personal experience with 60 cases. Ophthalmology 2004;111:2151-7.

How to cite this article: Nanda L, Kumar K, Bali GS. Eyelid Lesions: A Clinical Study. Int J Sci Stud 2018;6(1):21-23.

Source of Support: Source of Support: Nil, Conflict of Interest: None declared.