International Journal of Scientific Study

General Information

About The Journal

International Journal of Scientific Study (IJSS) is a monthly journal publishing research articles after full peer review and aims to publish scientifically sound research articles in across all science like Medicine, Dentistry, Genetics, Pharmacy, etc.

Each article submitted to us would be undergoing review in three stages: Initial Review, Peer Review & Final Review.

Abstracting & Indexing Information

PubMed - Selected Citations (As Mentioned on National Library of Medicine Catalog Website) - www.ncbi.nlm.nih.gov/nlmcatalog/101729001, Index Medicus (IMSEAR), Global Index Medicus, Google Scholar, WorldCat, SafetyLit, Genamics Journal Seek Ulrichsweb Serials Solutions, International Committee of Medical Journal Editors (ICJME) Geneva Foundation for Medical Education & Research (GFMER), Socolar, Bielefeld Academic Search Engine (BASE), Research Bible, Academic Journals Database, J-Gate, Jour Informatics, Directory of Research Journal Indexing (DRJI), Scientific Indexing Services (SIS) Rubriq-Beta, SHERPA RoMEO, New Journal (EIJASR), IndianScience.in, CiteFactor, Scientific Journal Impact Factor (SJIF), Journal Index.net, ROAD, Global Impact Factor (GIF), International Society for Research Activity (ISRA), Advanced Science Index (ASI)

Information for Authors

The authors should follow "Instructions to Authors" which is available on website http://www.ijss-sn.com/instructions-to-authors.html. Authors should fill the Copyright Transfer form & Conflict of Interest form. Manuscripts should be submitted directly to: editor@ijss-sn.com.

Publication Charges

International Journal of Scientific Study aims to encourage research among all the students, professionals, etc. But due to costs towards article processing, maintenance of paper in secured data storage system, databases and other financial constraints, authors are required to pay. However discount will be provided for the non-funding quality research work upon request. Details about publication charges are mentioned on journal website at: http://www.ijss-sn.com/publication-charges.html.

Advertising Policy

The journal accepts display and classified advertising Frequency discounts and special positions are available. Inquiries about advertising should be sent to editor@ijss-sn.com.

Publishing Details

Publisher Name: International Research Organization for Life & Health Sciences (IROLHS)

Registered Office: L 214, Mega Center, Magarpatta, Pune - Solapur Road, Pune, Maharashtra, India – 411028. Contact Number: +919759370871.

Designed by: Sinjore Technologies (www.sinjore.com)

Disclaimer

International Journal of Scientific Study

Editorial Board

International Journal of Scientific Study
December 2021 • Vol 9 • Issue 9

Contents

CASE REPORTS

ORIGINAL ARTICLES

International Journal of Scientific Study

December 2021 • Vol 9 • Issue 9

International Journal of Scientific Study

December 2021 • Vol 9 • Issue 9

Print ISSN: 2321-6379
Online ISSN: 2321-595X

Case Report

Elderly Patient with Challenging Ipsilateral Neck of Femur and Compound Segmental Femur Shaft Fracture Managed in 2 Stages: A Rare Case Report

Neetin P Mahajan[1], Pranay Kondewar[2], Vaibhav Sakhare[2], Amey Sadar[2], B M Kiran[2]

[1]Head of Unit, Department of Orthopaedics, Grant Government Medical College and Sir JJ Hospital, Mumbai, Maharashtra, India, [2]Senior Resident, Department of Orthopaedics, Grant Government Medical College and Sir JJ Hospital, Mumbai, Maharashtra, India

Abstract

Femoral fractures are very common presentations in orthopedics, but Ipsilateral femoral neck and shaft fractures are uncommon injuries, occurring in 0.8–9% of femoral shaft fractures. Segmental injuries are very rare. Appropriate management of wound and timing of definitive surgery is very important. Choice of implant depends on the type of fracture and ease of surgeon it ranges from intramedullary nails to extra-medullary plates. A single intramedullary nail or intramedullary nail plus cc screw fixation can be done. In this case, intramedullary interlock nail was used with three separate cc screws for neck of femur fracture fixation. Segmental fracture was opened and held reduced in place with encirclage wire as it was long oblique type postoperatively weight bearing started as tolerated. At 1 year follow-up there is complete union at fracture sites and abundant callus formation.

Key words: Segmental Femur Fracture, Compound Fracture, Intramedullary Nailing, Neck of Femur Fracture, Ipsilateral Fractures

INTRODUCTION

Femoral fractures are very common presentations in orthopedics, but Ipsilateral femoral neck and shaft fractures are uncommon injuries, occurring in 0.8–9% of femoral shaft fractures.[1] Data about segmental femur fracture associated with pauwels type 3 neck of femur (NOF) fracture is very limited. In this particular case, compound diaphyseal fracture presents a difficult scenario to execute effective management plan to heal three fractures. Segmental fractures are known to have been associated with complications of nonunion at one of the fracture sites due to damage of blood supply from nutrient vessels. The hidden role of blood supply from nutrient vessel needs to be taken into consideration; fracture nearer to the nutrient foramen will undergo early healing as compared to far fracture site. The distal fracture site may undergo delayed healing or nonunion.

Access this article online

www.ijss-sn.com

Month of Submission : 10-2021
Month of Peer Review : 11-2021
Month of Acceptance : 11-2021
Month of Publishing : 12-2021

Vertical neck femur fracture due to intraarticular and intrasynovial location poses difficult challenging scenario for union. Segmental femur fractures are as a result of high energy trauma and involve injury to both the bone and soft tissue surrounding it. The soft tissue condition and status of blood supply to fractured segment determine the potential for healing; middle segment is more prone for devascularization.[2] The options for management of multifragmentory femur fracture include open or closed reduction and fixation with intramedullary nailing or open reduction and plating with bone grafting as needed. Intramedullary nailing has become the most preferred method for the management of segmental femur shaft fractures, intramedullary nails provided excellent fixation for the fractures of the femur, allow knee and hip motion, including early ambulation and has least complication or nonunion rate.[3,4] Segmental femur shaft fracture associated with distal or proximal femur fractures becomes very difficult to manage as in this case pull of iliopsoas and abductor on proximal segment and pull of gastrocnemius on distal fragment can make reduction difficult and open reduction might be needed.

There are high chances of nonunion of femur neck fracture and femoral head Avascular necrosis (AVN) when associated with femur shaft fractures, these fractures are

Corresponding Author: Pranay Kondewar, 300 Resident Hostel, JJ Hospital, Byculla, Mumbai - 400 008, Maharashtra, India.

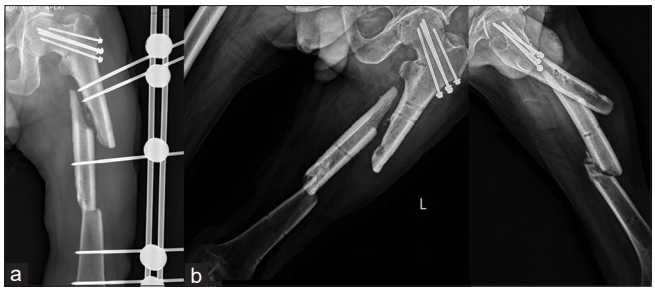

Figure 1: (a) Plain radiograph showing segmental femur shaft fracture with total 3 fragments held together by external fixator and neck of femur fracture fixed with cc screw. (b) Plain radiograph showing AP and lateral views after removal of the fixator

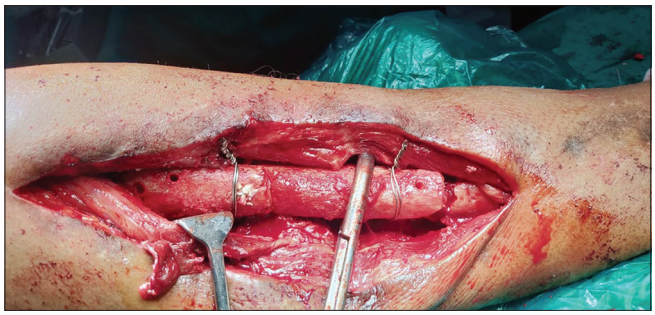

Figure 2: Intra-operative image showing fixation of segmental femur fracture with encirclage wiring

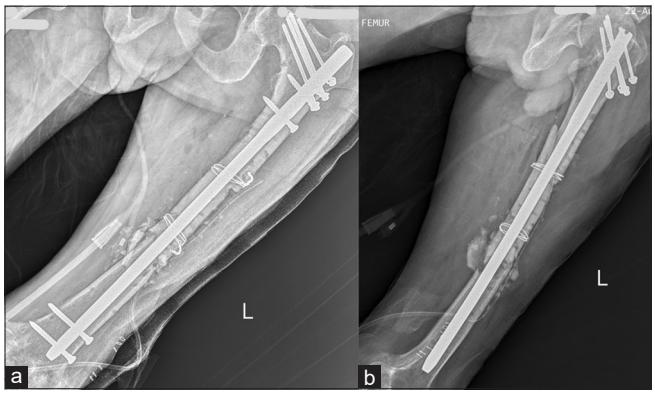

Figure 3: (a and b) Post-operative plain radiographs showing fixation of fracture using intramedullary interlock nail and encirclage wire

best managed with CC screw fixation and when needed pauwels osteotomy can be done.

CASE REPORT

A 65 years old male presented with the left sided gustilo-Anderson grade 3b compound segmental femur shaft fracture with pauwels type 3 NOF fracture after a road traffic accident, Patient was having wound over the anterolateral aspect of thigh 5 × 5 cm in size with bone exposed he was initially stabilized and vitals were

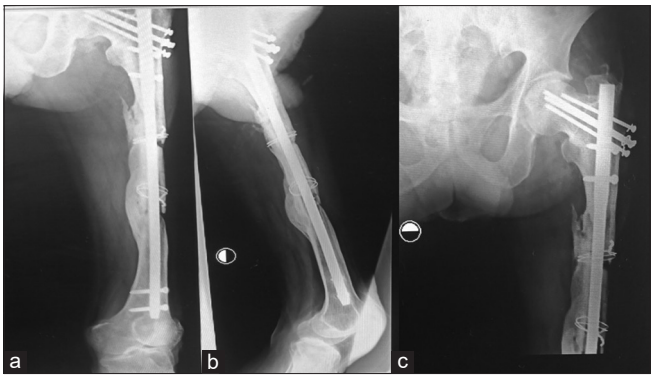

Figure 4: (a-c) Post-operative radiograph at 9 months post-operative showing union at NO fracture site and union of the segmental femur fracture with abundant of callus formation at both the fracture level

normalized then patient was operated with external fixator as a part of damage control regime for compound segmental femur fracture and cc screw fixation for NOF fracture wound was managed with local debridement and then Vacuum-Assisted Closure dressing was done intraoperative tissue samples were sent and intravenous antibiotics started immediately. After the wound is healed and soft tissue condition improved, fixator was removed 2 months post injury. Definitive fixation was planned using intramedullary interlock nail and encirclage wire for segmental femur fracture and bone grafting as an additive for healing.

Patient was operated on traction table and nail was inserted from a point posterior to the positions of cc screws. Open reduction was done, fragments reduced by putting reamer of size 12 mm and encirclage wiring was done. Then, nail was inserted. The segmental femur fracture are highly unstable because one fragment can rotate or axially move over the innerly place nail. Hence, stable fixation is necessarily achieved primarily during surgery to avoid nonunion. This is usually achieved using a large diameter nail. The medullary canal is reamed using the straight reamer and all membranous tissues formed within the medulla is scraped out. This is done to get fresh restoration of endosteal blood supply which usually gets restored in 3–6 weeks. In addition, iliac crest bone graft was used for improving the healing potential drain was put and was removed on post-operative day 3. Suture removal on day 10.

In post-operative period partial weight bearing was advised as tolerated for 8 weeks, Full weight bearing started at 4 months post-operative. At 10 months post-operative, there is a complete union at fracture site with bridging callus and NOF fracture is also united. Patient has gained full range of motion at hip and knee and is currently doing well with no difficulty in performing day today activities.

There is no evidence of infection or nonunion at 1 year follow-up [Figures 1-4].

DISCUSSION

In literature, there are many reports of similar ipsilateral fractures but not about the compound segmental fractures of femur with Ipsilateral NOF fracture. The mechanism of injury is being the typical velocity dashboard injury with longitudinal force on the flexed hip and knee. The multi-fragmentary trauma in single bone suggests high velocity trauma and soft tissue devastation. Such a heavy damage to soft tissue needed to be handle by damage control orthopedics methods. Hence, the initial external fixation was important choice. Definitive fracture management was done by open reduction of the fracture with encirclage wiring and intramedullary interlock nailing. Autologous bone grafting was done to avoid the chances of nonunion at femur shaft segmental fracture.

The presence of intraarticular NOF fracture poses difficult challenge to unite, as it demands primary anatomical reduction and compression across the fragments as well as stable internal fixation with multiple screws. Vertical fracture line causes displacement of head fragment due to forces acting around hip. The synovial fluid washes out the hematoma as well as lack of cambium layer in periosteum are responsible for complications especially nonunion.

A single implant for fixation of both the fractures can be done using a long cephalomedullary nail with proximal screws in the femur head also Fixation with interlock nail and cc screws (using miss a nail technique) gives better stability to fixation as it involves fixation shaft fractures with 2 proximal and 2 distal screws and fixation of NOF fracture independently with 3 cc screws. Another approach for these types of injuries is the "rendezvous" technique using dual implants in an overlapping fashion DHS fixation for NOF fracture and a retrograde nailing system for femur shaft fracture.[5]

A study by Jain *et al.* showed fixation of 23 cases of ipsilateral femur shaft and NOF fracture using single implant a cephalomedullary nail gives good outcome.[6] All the above options are available and can be used in such cases choice depends on the surgeons comfort and ease. We use dual implant fixation using anterograde interlock nail and cc screws. In a study of 108 femur fractures by Anostopaolous *et al.* including 16 segmental fractures showed excellent results with using interlock nail for fixation.

In a meta-analysis published by Antti Alho on ipsilateral NOF fracture and femur shaft fracture they reported total of 659 cases and compared various parameters, two-third of the patients had basicervical type of femur neck fracture and rate of AVN (3%) after fixation was also low compared to isolated femur neck fracture in literature. They also found that results were similar with single intramedullary second generation nail and interlock nail with separate cc screws fixation.[7]

The outcome of the fixed fractures is also variable specially NOF fractures.

In a paper by Wiss *et al.* Out of total 33 patients of NOF fracture with femur shaft fractures 27 healed with primary surgery and 6 patients developed varus nonunion for which osteotomy was done later.[8] Nonunions after the fixation can be managed with valgus osteotomy later.

Radiographic union score for tibial fractures is used to assess the union which involves defining union based on the X-ray finding in AP and LATERAL radiographs.[9] It includes appearance of callus and visibility of original fracture line on radiographs.

CONCLUSION

The management of segmental femur fracture with ipsilateral NOF fracture is always been debated and many options are available at present. Each one is technically demanding and success depends on various factors. In this case, good results are obtained by initially stabilizing fracture with external fixator and managing the wound. Later definitive surgery was done with bone grafting as an additional element for improving biology at fracture site.

REFERENCES

1. Barquet A, Guimaraes JM, Barrios E, Garau M, Zura RD, Eward WC. Epidemiology and diagnosis of ipsilateral femoral neck and shaft fractures: A systematic review of 1761 cases in 1758 patients (I.1990-VI.2015). Trauma Cases Rev 2015;1:015.
2. Babalola OM, Ibraheem GH, Ahmed BA, Olawepo A, Agaja SB, Adeniyi A. Open intramedullary nailing for segmental long bone fractures: An effective alternative in a resource-restricted environment. Niger J Surg 2016;22:90-5.
3. Jiang M, Li C, Yi C, Tang S. Early intramedullary nailing of femoral shaft fracture on outcomes in patients with severe chest injury: A meta-analysis. Sci Rep 2016;6:30566.
4. Watson JT, Moed BR. Ipsilateral femoral neck and shaft fractures: Complications and their treatment. Clin Orthop Relat Res 2002;399:78-86.
5. Harewood S, Mencia M, Harnarayan P. The rendezvous technique for the treatment of ipsilateral femoral neck and shaft fractures: A case series. Trauma Case Rep 2020;29:100346.
6. Jain P, Maini L. Cephalomedullary interlocked nail for ipsilateral hip and femoral shaft fractures. Injury 2004;35:1031-8.

7. Alho A. Concurrent ipsilateral fractures of the hip and femoral shaft: A meta-analysis of 659 cases. Acta Orthop Scand 1996;67:19-28.
8. Wiss DA, Sima W, Brien WW. Ipsilateral fractures of the femoral neck and shaft. J Orthop Trauma 1992;6:159-66.
9. Leow JM, Clement ND, Tawonsawatruk T. The radiographic union scale in tibial (RUST) fractures. Bone Joint Res 2016;5:116-21.

How to cite this article: Mahajan NP, Kondewar P, Sakhare V, Sadar A, Kiran BM. Elderly Patient with Challenging Ipsilateral Neck of Femur and Compound Segmental Femur Shaft Fracture Managed in 2 Stages: A Rare Case Report. Int J Sci Stud 2021;9(9):1-4.

Source of Support: Nil, **Conflicts of Interest:** None declared.

Print ISSN: 2321-6379
Online ISSN: 2321-595X

Case Report

Pouch and Tunnel Technique for Root Coverage Using Subepithelial Connective Tissue Graft: A Minimally Invasive Approach

Pooja A Shendge[1], Amit Chaudhari[2], Neelam Gavali[3], Shweta Bhole[1], Pratha Akolu[4]

[1]3rd Year Post Graduate, Department of Periodontology and Oral Implantology, Bharati Vidyapeeth Deemed University Dental College and Hospital, Pune, Maharashtra, India, [2]Associate Professor, Department of Periodontology and Oral Implantology, Bharati Vidyapeeth Deemed University Dental College and Hospital, Pune, Maharashtra, India,[3]Assistant Professor, Department of Periodontology and Oral Implantology, Bharati Vidyapeeth Deemed University Dental College and Hospital, Pune, Maharashtra, India, [4]2nd Year Post Graduate, Department of Periodontology and Oral Implantology, Bharati Vidyapeeth Deemed University Dental College and Hospital, Pune, Maharashtra, India

Abstract

One of the esthetic concerns emerging today is gingival recession. Smile is the best medicine as they say but due to gingival recession it may lead to nervousness and unpleasant appearance, especially in the anterior region due to compromised aesthetics. Thermal sensitivity, root caries are most commonly associated with gingival recession. Perio plastic procedures deal with the aim to reform the lost structure of periodontium and regain its original position, function, and esthetics. Subepithelial connective tissue graft has shown best predictability in Miller's Class I and Class II recession. The aim of this case report is to demonstrate a minimally invasive periodontal plastic procedure for the treatment of gingival augmentation coronal to the recession.

Key words: Gingival recession, Pouch and tunnel technique, Subepithelial connective tissue graft

INTRODUCTION

Periodontal plastic surgery is defined as the surgical procedures performed to correct or eliminate anatomic, developmental or traumatic deformities of the gingiva or alveolar mucosa.[1] Gingival recession is defined as the displacement of the gingival margin apical to the cemento-enamel junction (CEJ).[2] The main indication for root coverage is root hypersensitivity, root caries, aesthetic demands and cervical abrasion. Predisposing factors that lead to gingival recession are abberant frenal pull, minimal width of attached gingiva, tooth malpositioning.

"Envelope technique" was given in the year 1985 by Raetzke.[3] Allen in 1994 described the modified technique of Raetzke and named it as "Tunnel or Supraperiosteal envelope technique."[4]

Access this article online

IJSS

www.ijss-sn.com

Month of Submission : 10-2021
Month of Peer Review : 11-2021
Month of Acceptance : 11-2021
Month of Publishing : 12-2021

Indications for pouch and tunnel technique are-

1. Miller's Class I and Class II recession
2. Presence of multiple and wide recession in maxillary anterior regions
3. Where aesthetic concern is of prime importance
4. Root sensitivity.

The following case report explains the technique of gingival augmentation outlined by Allen in 1994.

CASE DESCRIPTION

A 43-year-old female patient reported with the complaint of sensitivity in upper anterior teeth region. On examination Miller's Class II gingival recession with respect to 11, 21 was observed. The width of attached gingiva was adequate in the region of 11 and 21. A pouch and tunnel technique using connective tissue graft from the palate was planned for root coverage [Figure 1].

PRE-SURGICAL PROTOCOL

The treatment protocol was explained to the patient and an informed consent was obtained for the same. Phase

Corresponding Author: Dr. Pooja A Shendge, Department of Periodontology and Oral Implantology, Bharati Vidyapeeth Deemed University Dental College and Hospital, Pune, Maharashtra, India.

1 Therapy that is scaling and root planning was carried out meticulously. Oral hygiene instructions were given to the patient and was recalled after 4 weeks for the surgical periodontal therapy.

SURGICAL TECHNIQUE

Recipient Site Preparation

Following local anesthesia administration, that is., 2% Lidocaine with a concentration of 1:200,000 epinephrine, sulcular incisions were given in the site of recession with No.15 blade. Care was taken not to extend the incison uptil interdental papilla. A full thickness flap was reflected extending beyond the mucogingival junction. This was done for easier coronal displacement of the graft. Undermining of each pedicle adjacent to the recession was done to create a tunnel, which was extended 3-5 mm laterally [Figure 2].

Donor Site Preparation

According to Lui's Class I incison subepithelial connective tissue graft (SCTG) was harvested from the palate. The incison was extended from distal of canine to mesial of 1st molar [Figures 3 and 4]. After the graft was harvested bleeding was controlled by direct application of pressure with gauze and 3-o silk suture interrupted suture were placed.

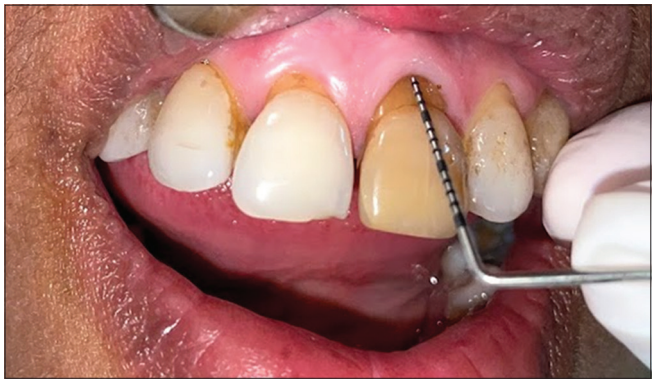

Figure 1: Miller's Class II gingival recession

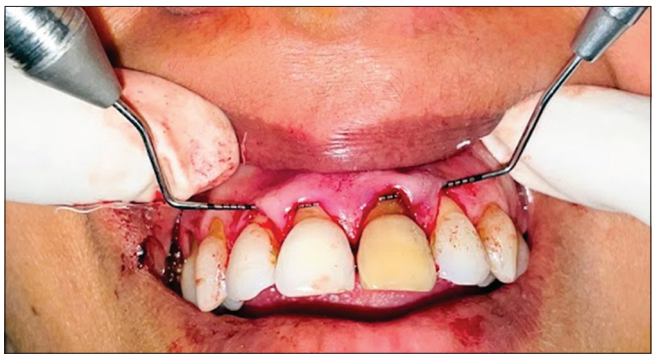

Figure 2: Full thickness mucoperiosteal pouch create

Graft Placement

The graft was secured with 5-o vicryl resorbable suture. The suture was placed from the mesial aspect of the tunnel and pushed to the distal aspect of the tunnel. The graft was pushed coronal to CEJ. After positioning, the graft was secured with sling sutures on both mesial and distal sides to prevent the dislodgement of the graft [Figure 5].

Post-operative Instructions

Patient was advised to refrain from brushing for the first 24 h. Patient was advised to rinse with 0.2% Chlorhexidine gluconate for 2 weeks. Post-operative antibiotics and analgesics were prescribed for 5 days. The patient was followed up at 7 days, 4 weeks, and 3 months until now. The healing was uneventful and an excellent color match was obtained. The patient reported satisfactory esthetic results [Figure 6].

DISCUSSION

Gingival recession is very common these days and requires treatment to avoid further complications. Periodontal

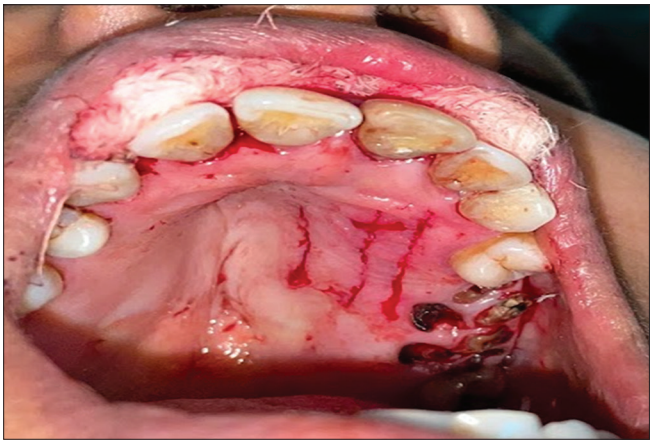

Figure 3: Incison site at the donor area

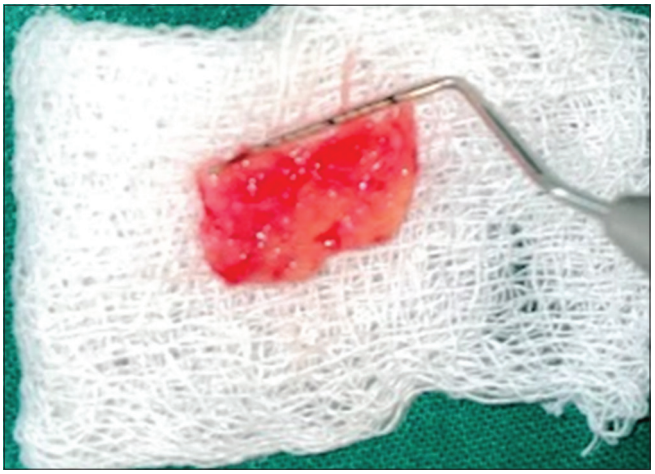

Figure 4: Subepithelial connective tissue graft procured from the palate

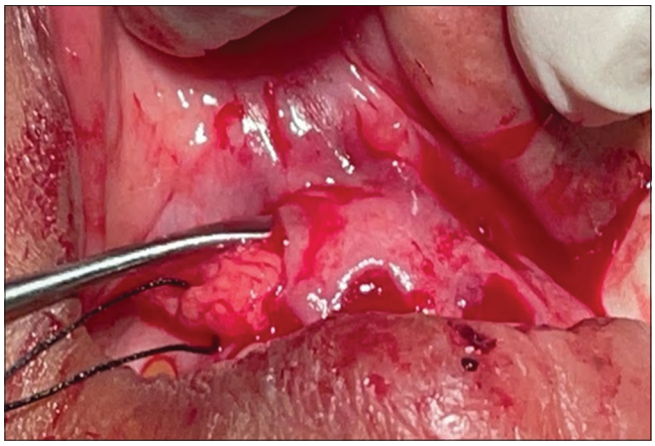

Figure 5: Graft secured with suture and placed in the tunnel

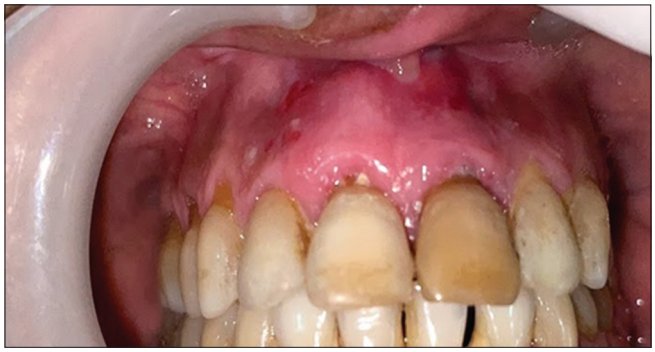

Figure 6: Post-operative healing after 4 weeks with complete root coverage

plastic surgery aims at treatment to enhance the esthetics. A number of treatment modalities are emerging for the treatment of Miller's Class I and Class II recession. SCTG has the best predictability of about 95% in root coverage.[5]

The case report demonstrates sites treated with pouch and tunnel technique which have given good predictable results. The result of the tunnel procedure demonstrated a good esthetic result with predictable root coverage. The use of the tunnel technique preserves the papillary height between two mucogingival defects and maintains the blood supply to the underlying graft. Increasing the thickness of the attached gingiva is also achieved with this technique.

CONCLUSION

Gingival recession concerns both aesthetically and functionally. Pouch and tunnel technique with SCTG produces highly superior results and excellent color match.

REFERENCES

1. American Academy of Periodontology. Proceedings of the world workshop in periodontics. Ann Periodontol 1996;1:37-215.
2. Wennstrom JL, Zucchelli G, Pini Prato GP. Mucogingival surgery. In: Lang NP, Karring T, editors. Clinical Periodontology and Implant Dentistry. 5th ed. Oxford, UK: Blackwell Munksgaard; 2008. p. 955-1011.
3. Raetzke PB. Covering localized areas of root exposure employing the "envelope" technique. J Periodontol 1985;56:397-402.
4. Allen AL. Use of the supraperiosteal envelope in soft tissue grafting for root coverage. I. Rationale and technique. Int J Periodontics Restorative Dent 1994;14:216-27.
5. Miller PD Jr. A classification of marginal tissue recession. Int J Periodontics Restorative Dent 1985;5:8-13.

How to cite this article: Shendge PA, Chaudhari A, Gavali N, Bhole S, Akolu P. Pouch and Tunnel Technique for Root Coverage Using Subepithelial Connective Tissue Graft: A Minimally Invasive Approach. Int J Sci Stud 2021;9(9):5-7.

Source of Support: Nil, **Conflicts of Interest:** None declared.

Print ISSN: 2321-6379
Online ISSN: 2321-595X

Case Report

Hemorrhagic Encephalitis in Dengue Virus Infection: A Rare Case Report

Aanchal Rana[1], Vishal Gupta[2], Amit Kumar Gupta[3], Saurav Bhagat[3], Tarun Goyal[4]

[1]Junior Resident, Department of Radiology, School of Medical Science and Research, Sharda University, Greater Noida, Uttar Pradesh, India, [2]Professor and Head, Department of Radiology, School of Medical Science and Research, Sharda University, Greater Noida, Uttar Pradesh, India, [3]Assistant Professor, Department of Radiology, School of Medical Science and Research, Sharda University, Greater Noida, Uttar Pradesh, India, [4]Senior Resident, Department of Radiology, School of Medical Science and Research, Sharda University, Greater Noida, Uttar Pradesh, India

Abstract

The dengue fever is caused by the dengue virus (DENV) which is a single-stranded RNA virus, belonging to the Flaviviridae family and consists of four serotypes; DENV-1, 2, 3, and 4. It is very commonly prevalent in tropical and subtropical countries mostly weighing down in Southeast Asia. The virus involves multiorgan system and symptoms can vary from simple flu to severe life-endangering complications. Hemorrhagic encephalitis is a very rare spectrum seen in dengue. We report a case of a 23-year-old male presented to the emergency department with the complaints of cough, fever, and altered sensorium. The investigations revealed non-structural 1 antigen to be reactive and magnetic resonance imaging brain suggestive of hemorrhagic encephalitis. Our case report reflects the rarely neurological presentation to a very common viral infection.

Key words: Dengue, Haemorrhagic Encephalitis, MRI

INTRODUCTION

Dengue virus (DENV) is an endemic arboviral infection mostly burdened in Southeast Asian countries, especially India and neighboring countries.[1] The central nervous system (CNS) involvement in the form of encephalitis is very rare in dengue but few cases have been reported.[2] However, encephalopathy is very commonly seen. Strains DENV-2 and 3 are mostly involved in neurological complications.[3] Here, we present a rare case of hemorrhagic encephalitis in serology proven dengue fever.

CASE HISTORY

A 23-year-old non-smoker, non-alcoholic, male student presented to the emergency department with fever, cough, and altered sensorium. There was no event of seizures or trauma at initial time of presentation. On examination, the patient was afebrile – 98.4F, drowsy, HR – 102 bpm, BP – 132/78 mmHg, RR – 18/min, SpO_2 98%, and Glasgow Coma Scale (GCS) $E_2V_2M_5$. There were no meningeal signs, bilateral plantar response was extensor, and systemic examination was within normal limit. However, on auscultation, bilateral chest showed conducting sounds and decreased air entry at bases. The patient suddenly collapsed within few minutes and was unconscious, not responding to verbal command beyond painful stimulus. The SpO_2 sudden dropped to 10% for which moist O_2 3 L support was advised to maintain SpO_2 ≥96% and later was intubated in view of poor GCS ($E_1V_1M_2$) to protect the airway.

Blood investigations, ultrasound (USG) whole abdomen, and non-contrast computed tomography (CT) head were requested (in view of involvement of neurological symptoms). Hemoglobin – 15.49 g/dl, total leukocyte count – 8520 cells/cumm^3, platelet count – 26,000 cells/cumm^3, hematocrit – 45.70, and liver transaminases showed 8–14-fold rise above the upper limit (serum glutamic oxaloacetic transaminase – 750 U/L and serum glutamic pyruvic transaminase – 417 U/L). Creatinine – 1.80 mg/dl and uric acid – 10 mg/dl were mildly raised. Reverse transcription polymerase chain reaction (RT-PCR) for COVID-19 was negative. Serum electrolytes were within the normal limit.

Access this article online

www.ijss-sn.com

Month of Submission : 10-2021
Month of Peer Review : 11-2021
Month of Acceptance : 11-2021
Month of Publishing : 12-2021

Corresponding Author: Saurav Bhagat, Department of Radiology, School of Medical Science and Research, Sharda University, Greater Noida, Uttar Pradesh, India

USG abdomen showed mild ascites and splenomegaly. CT showed ill-defined hypodense areas in bilateral gangliothalamic, midbrain, and pons region for which further evaluation of magnetic resonance imaging (MRI) brain was advised.

Further, cerebrospinal fluid (CSF) analysis was positive for dengue immunoglobulin (Ig) M antibodies and negative for JE virus titers. However, virus isolation was not possible. Malaria card test was negative, typhi dot – IgM and IgG both were negative. Hepatitis viruses were negative (HAV, HEV, HBsAg, and HCV), HIV I and II – non reactive, and serum lactate dehydrogenase – 697 (raised 3 times the normal upper limit).

MRI brain revealed increased signal intensity in bilateral thalami, posterior limb of bilateral internal capsule, right occipital, right parietal and periventricular deep white matter, posterior aspect of brainstem, and bilateral cerebellar peduncles on T2 and fluid-attenuated inversion recovery images. These lesions showed scattered areas of restriction on diffusion-weighted imaging. Findings were suggestive of hemorrhagic encephalitis [Figures 1-6]. With

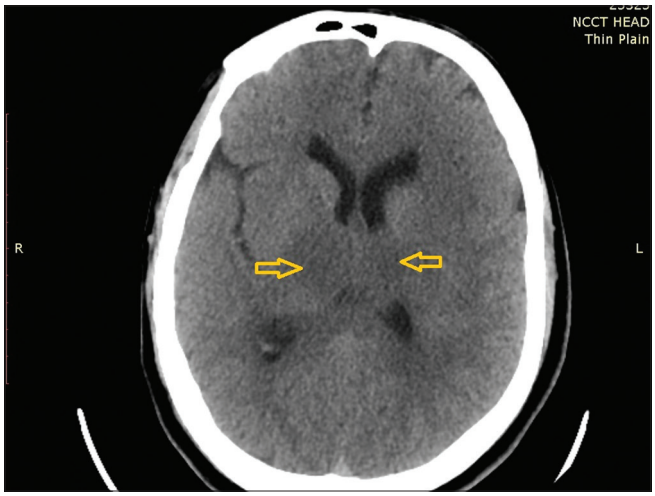

Figure 1: Plain computed tomography axial image showing hypodense appearance of the bilateral gangliothalamic region (marked with yellow arrows)

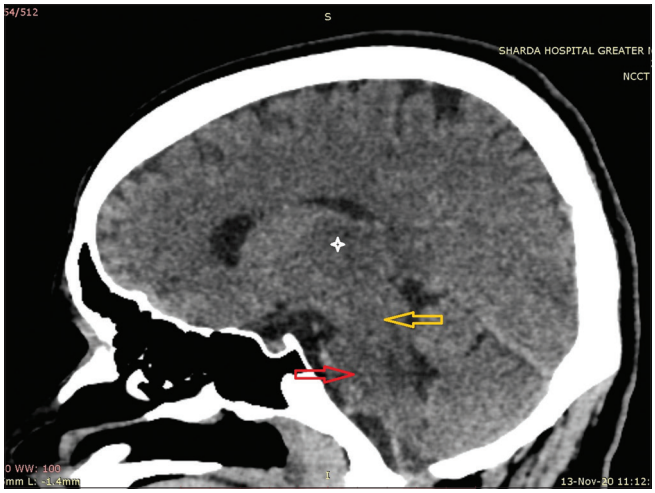

Figure 2: Plain computed tomography sagittal image shows hypodense appearance of Rt. Thalamus (marked with asterisk), midbrain (marked with yellow arrow), and Pons (marked with red arrow)

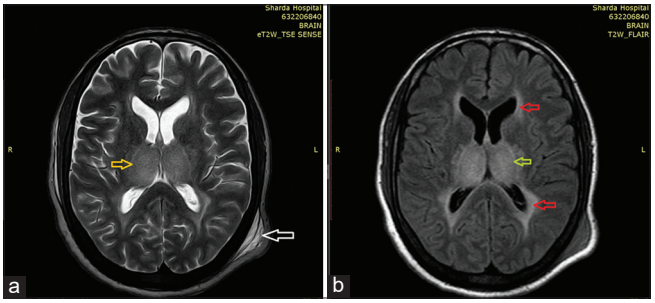

Figure 3: Magnetic resonance imaging axial T2W image (a) shows evidence of hypointense signal in the bilateral thalami (marked with yellow arrow) and axial fluid-attenuated inversion recovery image (b) shows the hyperintense signal in bilateral thalami (green arrow) and in periventricular deep white matter regions (marked with red arrows). The scalp edema is evident in both images shown with white arrow on image (a)

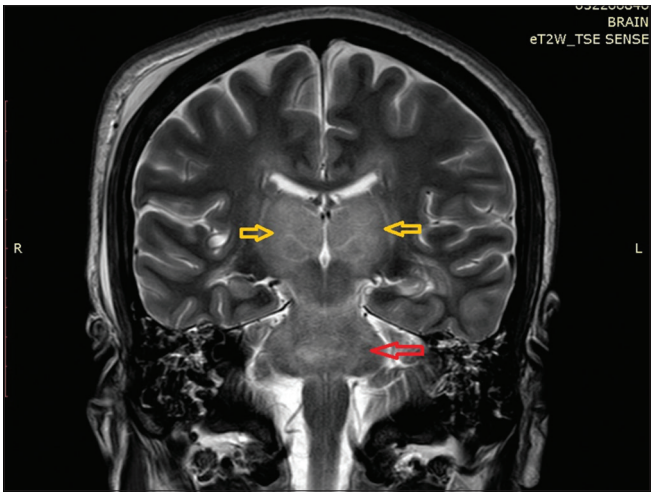

Figure 4: Magnetic resonance imaging coronal image shows hyperintense signal in bilateral thalami (yellow arrow) and midbrain (red arrow)

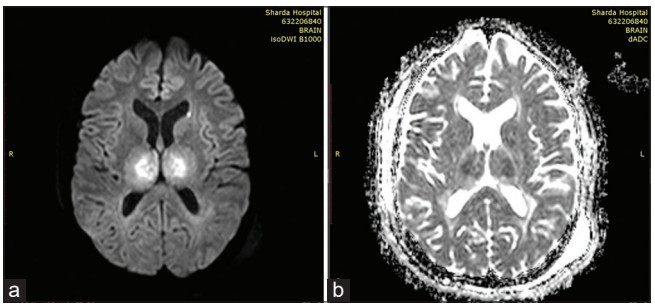

Figure 5: (a and b) Diffusion-weighted imaging and apparent diffusion coefficient with restricted diffusion in bilateral thalami are evident

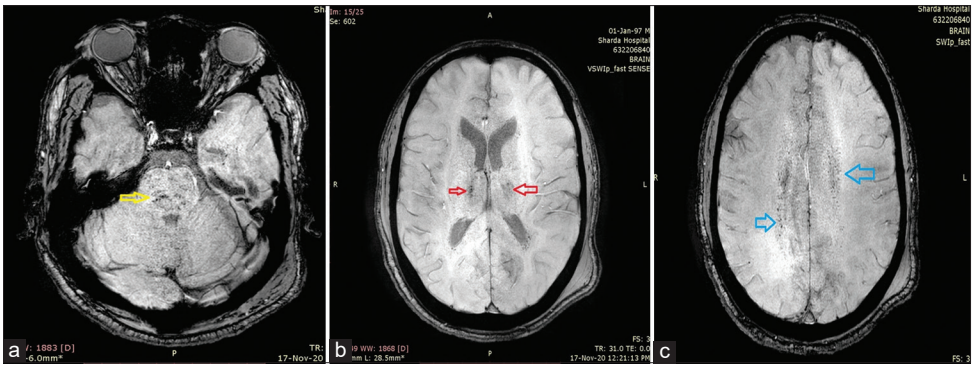

Figure 6: Magnetic resonance imaging brain images showing multiple scattered foci of blooming on susceptibility-weighted imaging sequence suggestive of bleed in midbrain (a marked with yellow arrow), in bilateral thalami (b marked with red arrows), and in subcallosal structures (c marked with blue arrows)

the extensive workup, the patient was diagnosed as a rare case of dengue hemorrhagic encephalitis.

The patient during the stay in hospital developed multiorgan dysfunction, shock and was managed intensively on intravenous fluids, antipyretics, broad-spectrum antibiotics, four units of platelet transfusions, steroids, and other supportive treatment along with physiotherapy. After 3 days, he was extubated and weaned off, as spontaneous breathing resumed. The patient improved day by day and was hemodynamically stable at the time of discharge on day 25.

DISCUSSION

Dengue is not classically a neurotropic virus, although recent evidence shows direct neuronal injuries. Dengue encephalopathy is a well-recognized and common entity; the incidence ranging from 0.5% to 6.2%.[4] The possible mechanisms are liver failure (hepatic encephalopathy), cerebral hypoperfusion (shock), cerebral edema (vascular leak), deranged electrolytes, and intracranial bleeding due to thrombocytopenia or coagulopathy, which is secondary to hepatic failure.[3]

Murthy JMK classified neurological manifestations in dengue infection into three categories: (1) CNS complications resulting from direct neurotropic effect such as meningitis, encephalitis, and myelitis, (2) CNS manifestations from systemic and metabolic complications such as encephalopathy, hypokalemic paralysis, and stroke, and (3) Post-viral infection CNS complications such as encephalomyelitis, optic neuritis, and Guillain-Barre syndrome.[5]

Multiple investigations for diagnosis of dengue infection are based on the detection of IgG, IgM antibodies, non-structural 1 (NS1) antigen, viral RNA in serum, and CSF. The IgM antibody detection is highly sensitive and specific. Detection using NS1 viral antigen is another widely used test. Dengue IgM detection in CSF has high specificity, but the gold standard is cell culture virus isolation. (Not used in clinical practice).

Cristiane and Marzia proposed 4-point definition criteria for dengue encephalitis as (1) presence of fever; (2) CNS complications such as altered sensorium, seizures, or any focal neurological signs; (3) reactive IgM antibody, NS1 antigen, DENV RNA detection in serum, and/or CSF; and (4) exclusion of other causes of encephalitis.[6]

MRI findings in dengue vary but major cases involve hemorrhages, focal abnormalities, edema in hippocampus, basal ganglia, and thalamic region. In few cases, extensive lesions in midbrain, cerebellum, and temporal region have also been seen.[4] Many studies suggest encephalitis in dengue as a benign condition while Misra *et al.* concluded encephalitis as a complicated condition with difficult recovery with significant mortality and morbidity.[4,7]

CONCLUSION

Haemorrhagic encephalitis in the patients of dengue is very rare. However in clinical setting where neurological involvement is suspected MRI serves as an excellent tool for the evaluation of haemorrhagic encephalitis. Restricted diffusion on Diffusion weighted images and blooming on Suscpetibility weighted images helps to reach the diagnosis on non contrast MRI scan.

REFERENCES

1. World Health Organization. Department of Control of Neglected Tropical Diseases and TDR: Dengue: Guidelines for Diagnosis, Treatment, Prevention and Control. Geneva, Switzerland: World Health Organization;

2009.
2. Borawake K, Prayag P, Wagh A, Dole S. Dengue encephalitis. Indian J Crit Care Med 2011;15:190-3.
3. Varatharaj A. Encephalitis in the clinical spectrum of dengue infection. Neurol India 2010;58:585-91.
4. Misra UK, Kalita J, Syam UK, Dhole TN. Neurological manifestations of dengue virus infection. J Neurol Sci 2006;244:117-22.
5. Murthy JM. Neurological complications of dengue infection. Neurol India 2010;58:581-4.
6. Cristiane S, Marzia PS. Diagnosis criteria of dengue encephalitis. Arq Neuropsiquiatr 2014;72:263.
7. Wiwanitkit V. Magnitude and pattern of neurological pathology in fatal dengue hemorrhagic fever: A summary of Thai cases. Neuropathology 2005;25:398.

How to cite this article: Rana A, Gupta V, Gupta AK, Bhagat S, Goyal T. Hemorrhagic Encephalitis in Dengue Virus Infection: A Rare Case Report. Int J Sci Stud 2021;9(9):8-11.

Source of Support: Nil, **Conflicts of Interest:** None declared.

Print ISSN: 2321-6379
Online ISSN: 2321-595X

Original Article

A Study to Evaluate the Spectrum of Tuberculosis in Newly Diagnosed People Living with HIV AIDS Attending Tertiary ART Centre at M.Y. Hospital Indore

Dharmendra Singh[1], Jitendra Rajput[2], Arvind Kumar Pandey[3], Ved Prakash Pandey[4], Ashok Thakur[5]

[1]Former Post Graduate resident, Department of General Medicine, MGM Medical College and M.Y. Hospital, Indore, Madhya Pradesh, India, [2]Senior Resident, Department of Respiratory Medicine, MGM Medical College and M.Y. Hospital, Indore, Madhya Pradesh, India, [3]Former Post Graduate resident, Department of General Medicine, MGM Medical College and M.Y. Hospital, Indore, Madhya Pradesh, India, [4]Professor and Head, Department of General Medicine, MGM Medical College and M.Y. Hospital, Indore, Madhya Pradesh, India, [5]Associate Professor, Department of General Medicine, MGM Medical College and M.Y. Hospital, Indore, Madhya Pradesh, India

Abstract

Background: Tuberculosis is the most common opportunistic infection among HIV-infected patients worldwide, who remain at the high risk for tuberculosis (TB) throughout the course of their disease. The HIV virus damages the body's natural defenses - the immune system and accelerates the speed at which TB progresses from a harmless infection to life-threatening condition. To mitigate the effect of dual burden of HIV and TB, Revised National Tuberculosis Control Programme and National AIDS Control Programme have developed a collaborative framework wherein intensified case-finding is done through screening all anti-retroviral therapy (ART) center attendees for TB.

Aims and Objectives: The present study was conducted with the aim to study spectrum of TB in newly diagnosed people living with HIV AIDS (PLHA) attending Tertiary ART Centre.

Material and Methods: The present study was conducted at Tertiary ART Centre and Department of Medicine, M.Y. Hospital, Indore, during the period January 2019–July 2020. We had screened 1610 patients with PLHA in the age group of 18–70 years for TB.

Results: Of these 1610, 200 patients were diagnosed with TB. Out of 200 TB-HIV patients, 63.0% patients were in the age group of 21–40 years, followed by 41–60 years. There was male predominance (74%). Out of 200 TB-HIV patients, 75 (37.5%) had pulmonary TB and 125 (62.5%) had extrapulmonary involvement. Out of 125 cases of extrapulmonary TB in 57 (45.6%) patients there was Koch's abdomen, in 48 (38.4%) patients there was lymph node TB, in 10 (8%) patients there was pleural effusion, and in 10 (8%) patients tubercular meningitis was seen.

Conclusion: TB is the major opportunistic infection in newly diagnosed PLHA. The prevalence of pulmonary TB is comparatively lower than the extrapulmonary TB in these patients and among the extrapulmonary TB patients, prevalence of Koch's abdomen is highest.

Key words: Opportunistic infection, People living with HIV AIDS, Tubercular meningitis, Tuberculosis

INTRODUCTION

Tuberculosis (TB) is the most common opportunistic infection among HIV-infected patients.[1] It is the most important cause of morbidity and mortality in people living with HIV.[2] India is the third-highest HIV burden country in the world, with an adult prevalence of 0.22%.[3] PLHIV are 20–21 times at the higher risk of developing TB. TB-HIV coinfection results in the higher mortality rates and nearly 25% of all deaths among people living with HIV AIDS (PLHA) are due to TB. In India, about 110,000 people are estimated to be HIV-TB coinfected annually, with the national average for HIV prevalence among incident TB cases at 5%. The mortality in this group is very high and 9700 people die every year among TB/HIV coinfected patients.[4-6]

The HIV virus damages the body's natural defenses, the immune system and accelerates the speed at which TB

Access this article online

IJSS
www.ijss-sn.com

Month of Submission : 10-2021
Month of Peer Review : 11-2021
Month of Acceptance : 11-2021
Month of Publishing : 12-2021

Corresponding Author: Dr. Ashok Thakur, Associate Professor, Department of General Medicine, MGM Medical College and M.Y. Hospital, Indore, Madhya Pradesh, India.

progresses from a harmless infection to life-threatening condition.

To overcome the effect of dual burden of HIV and TB, Revised National Tuberculosis Control Program and National AIDS Control Program have developed a collaborative framework. In which a single window for delivery of TB and HIV services is successfully developed for all people living with HIV in the anti-retroviral therapy (ART) centers. This window also provides intensified case-finding through screening all ART center attendees for TB, through offering rapid molecular testing to symptomatic patients and also provides anti-TB treatment.[4,5]

The aim of this study is to study the spectrum of TB in newly diagnosed PLHA attending Tertiary ART center.

MATERIALS AND METHODS

This is a prospective observation study was done among 18–70 years old patients with in a period of 17 months from February 2019 to July 2020 at Tertiary ART Centre and Department of Medicine, M.Y. Hospital, Indore, M.P. We had screened 1610 patients with PLHA. Out of which, 200 patients were diagnosed with TB. Patients with history of COPD, diabetes mellitus, chronic liver disease, who have already taken ART or ATT, prisoner, patient with unknown identity, pregnant women, and lactating mothers were excluded from the study.

First, a verbal approval for participation in the study, a voluntary written informed consent was obtained from patients for participation in the study.

A detailed medical and surgical history were obtained, followed by a detailed general and systemic examination. Following which blood samples were collected for routine laboratory investigations. Electrocardiogram was performed to assess the cardiac function. Radiological assessment included X-ray chest and ultrasound abdomen. CBNAAT of various body fluids and tissues was performed for confirmation of TB, adenosine deaminase and routine microscopy of various body fluids were also performed. A customized proforma was designed of the purpose of the study and all relevant information was captured in this pro forma.

Statistical Analysis

The data were initially entered into the Microsoft Excel for analysis. Online statistical software such as GraphPad and Epi Info was used for calculating the p values. Comparison of means between the groups was done using unpaired "*t*" test and within the group was done using paired "*t*" test. Association between two non-parametric variables was done using Pearson Chi-square test. $P < 0.05$ was taken as statistically significant. The final data were presented in the form of Tables 1-4 and Graphs 1-4.

Table 1: Distribution of patient

Category	No. of patients	Prevalence (%)
Total PLHIV patients at Tertiary ART Centre and M.Y. Hospital, during the study period	1610	
Tuberculosis patients	200	12.4
Pulmonary tuberculosis patients	75	4.6
Extrapulmonary tuberculosis patients	125	7.8

Table 2: Distribution of patients according to the age

Age	Number	Percentage
18–20 years	6	3.0
21–40 years	126	63.0
41–60 years	62	31.0
>60 years	6	3.0
Total	200	100.0

Table 3: Distribution of patients according to the gender

Sex	Number	Percentage
Female	52	26.0
Male	148	74.0
Total	200	100.0

Table 4: Distribution of patients according to the tuberculosis type

Tuberculosis type	Number	Percentage
Koch's abdomen	57	28.5
Lymph node	48	24.0
Pleural effusion	10	5.0
Pulmonary tuberculosis	75	37.5
Tubercular meningitis	10	5.0
Total	200	100.0

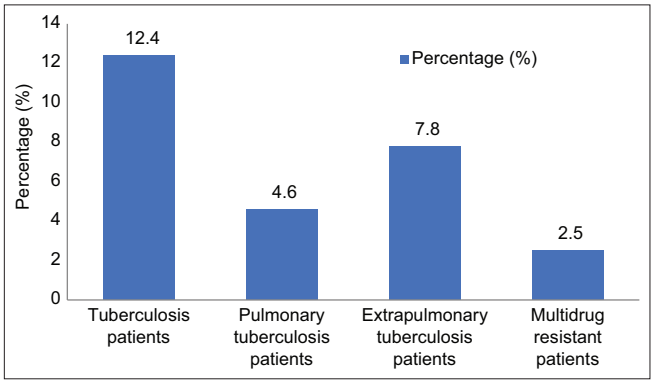

Graph 1: Bar diagram showing distribution of patients

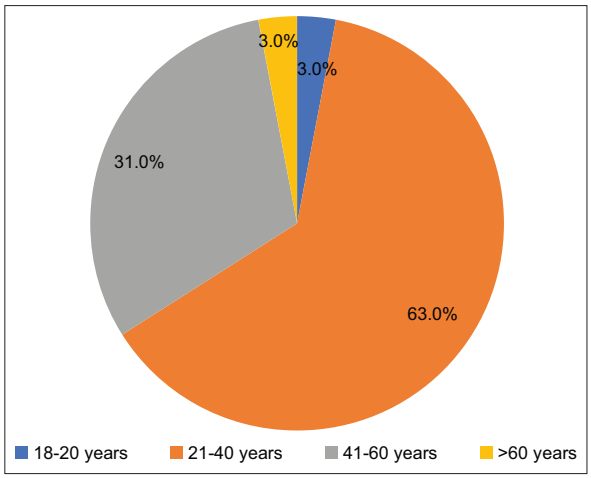

Graph 2: Pie diagram showing distribution according to the age

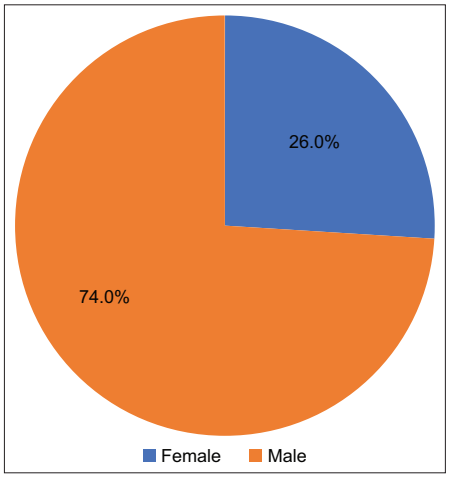

Graph 3: Pie diagram showing distribution according to the sex

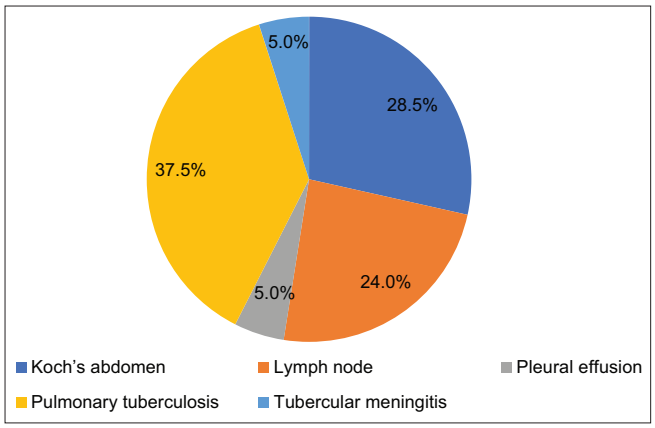

Graph 4: Pie diagram showing distribution according to the type of tuberculosis

RESULTS

A total of 1610 newly diagnosed PLHA were enrolled. Of these 1610 patients, 200 (12.4%) patients had TB. About 75 (4.6%) patients had pulmonary TB and 125 (7.8%) patients had extrapulmonary TB. Out of 200 TB-HIV patients, 63.0% patients were in the age group of 21–40 years, followed by 41–60 years. There was male predominance (74%). Out of 200 TB-HIV patients, 75 (37.5%) had pulmonary TB and 125 (62.5%) had extrapulmonary involvement. Multidrug resistance was seen in 5 (2.50%) patients, out of 200 patients with TB-HIV. Out of 125 cases of extrapulmonary TB in 57 (45.6%) patients, there was Koch's abdomen, in 48 (38.4%) patients there was lymph node TB, in 10 (8%) patients there was pleural effusion, and in 10 (8%) patients tubercular meningitis was seen.

DISCUSSION

Studies have reported that TB is the most common opportunistic infection seen in patients with HIV infection and TB may develop at any stage of the HIV disease.

In this study, there were 1610 patients who came to the Tertiary ART Centre, of these there were 200 (12.4%) patients had TB. In this study, the prevalence of pulmonary TB was 4.6% and extrapulmonary TB was seen in 7.8%. According to the National TB Elimination Program Annual Report, 2020,[4] the prevalence of TB in PLHA patients was approximately 5%, which is less in comparison to our study findings. In this study, 75 (37.5%) patients had pulmonary TB while 62.5% were developed extrapulmonary TB. According to the WHO index-TB guidelines for extrapulmonary TB in India, 2016,[8] the prevalence of pulmonary and extrapulmonary TB was 50–60% and 40–50%, respectively. Pulmonary TB among patients with newly diagnosed TB is comparatively lower in this study population.

There were 126 (63.0%) patients in the age group of 21–40 years and 6 (3.0%) patients in the age group 18–20 years. Jaryal *et al.*[8] in their study had included 87 HIV-infected patients. They found that the most commonly affected age group in their study was 31– 40 years. Leeds *et al.*[9] conducted a study with an aim to determine the risk factors associated with particular type of extrapulmonary TB. In their study, the mean age of the patients was 40 years with a range from 18 to 89 years.

Our results corroborate with the study done by Jaryal *et al.* and Leeds *et al.*, who also reported that the HIV/AIDS is more commonly seen in productive age group patients.

There were 52 (26.0%) females and 148 (74.0%) males in our study, showing a male preponderance, comparable with the study done by Leeds *et al.*[9]

Who also showed male predominance (67%) in their study.

In this study, 75 (37.5%) patients were having pulmonary TB, while the rest 125 (62.5%) patients were having

extrapulmonary TB. In 57 (28.5%) patients, there was Koch's abdomen, in 48 (24.0%) patients there was lymph node TB, in 10 (5.0%) patients there was pleural effusion, and in 10 (5.0%) patients tubercular meningitis was seen. The prevalence of Koch's abdomen is the highest in our study, followed by lymph node TB. Dharmshale *et al.*[10] conducted a study on patients with HIV and non-HIV patients. They found 47.5% of HIV patients had extrapulmonary TB and it was 35.86% in patients without HIV. In our study, we found a higher prevalence of extrapulmonary TB in comparison to the study done by Dharmshale *et al.*[10] Pulmonary TB incidence is very high in the study done by Dias *et al.*,[7] that is, 86.6%, while in our study we found its prevalence to be 37.5%. Study done by Leeds *et al.*[9] showed a prevalence of lymphatic TB to be 28%, which is quite comparable to our results, where in we found a prevalence of 24% in the present study, while study done by Dias *et al.*[7] showed lymphatic involvement in 31.3% patients, which is higher than that reported by our study.

Limitations

The most important limitation of this study is smaller sample size. Other than that, there should be longer follow-up of the newly diagnosed PLHA so that there would be estimation of the time period after which patients develop TB as an opportunistic infection.

CONCLUSION

This study concluded that TB is the major opportunistic infection in newly diagnosed PLHA and these patients should be definitely screened for TB at the time of diagnosis for early diagnosis and treatment. The prevalence of pulmonary TB is comparatively lower than the extrapulmonary TB in these patients and among the extrapulmonary TB patients, prevalence of Koch's abdomen is the highest.

REFERENCES

1. Kwan CK, Ernst JD. HIV and tuberculosis: A deadly human syndemic. Clin Microbiol Rev 2011;24:351-76.
2. da Silva Escada RO, Velasque L, Ribeiro SR, Cardoso SW, Marins LM, Grinsztejn E, *et al*. Mortality in patients with HIV-1 and tuberculosis co-infection in Rio de Janeiro, Brazil-associated factors and causes of death. BMC Infect Dis 2017;17:373.
3. HIV-Associated Tuberculosis on the Rise: India TB Report; 2010. Available from: https://www.downtoearth.org.in/news/health/hiv-associated-tuberculosis-on-the-rise-india-tb-report-66938 [Last accessed on 2019 Apr 02].
4. National Tuberculosis Elimination Programme, Central TB Division, Ministry of Health and Family Welfare; 2020. Available from: http://www.tbcindia.nic.in [Last accessed on 2020 May 10].
5. Sakula A. Robert Koch: Centenary of the discovery of the tubercle bacillus, 1882. Thorax 1982;37:246-51.
6. Tuberculosis (TB): Global Tuberculosis Report; 2019. Available from: https://www.who.int/tb/publications/global_report/en [Last accessed on 2019 Sep 10].
7. da Rocha Dias AP, Amman BV, Costeira J, Gomes C, Barbara C. Extrapulmonary tuberculosis in HIV infected patients admitted to the hospital. Eur Respir J 2016;48:PA2761.
8. Jaryal A, Raina R, Sarkar M, Sharma A. Manifestations of tuberculosis in HIV/AIDS patients and its relationship with CD4 count. Lung India 2011;28:263-6.
9. Leeds IL, Magee MJ, Kurbatova EV, del Rio C, Blumberg HM, Leonard MK, *et al*. Site of extrapulmonary tuberculosis is associated with HIV infection. Clin Infect Dis 2012;55:75-81.
10. Dharmshale SN, Bharadwaj RS, Gohil AH, Chowdhary AS. Extra-pulmonary tuberculosis in HIV and non-HIV patients in a tertiary care hospital, Mumbai. Indian J Basic Appl Med Res 2012;3:205-8.

How to cite this article: Singh D, Rajput J, Pandey AK, Pandey VP, Thakur A. A Study to Evaluate the Spectrum of Tuberculosis in Newly Diagnosed People Living with HIV AIDS Attending Tertiary ART Centre at M.Y. Hospital Indore. Int J Sci Stud 2021;9(9):12-15.

Source of Support: Nil, **Conflicts of Interest:** None declared.

Print ISSN: 2321-6379
Online ISSN: 2321-595X

Original Article

Morphometric Study of Sacral Hiatus in Adult Human Sacra and Its Clinical Insinuation in Caudal Epidural Anesthesia

Akhalaq Ahmed[1], Sameeullah Ben Azeem Haasan[1], Divasha[2], Sonia[1], Mukesh Singla[3], Kumar Satish Ravi[3]

[1]Post Graduate Student, Department of Anatomy, All India Institute of Medical Sciences, Rishikesh, Uttarakhand, India, [2]Senior Demonstrator, Department of Anatomy, University College of Medical Sciences, New Delhi, India, [3]Additional Professor, Department of Anatomy, All India Institute of Medical Sciences, Rishikesh, Uttarakhand, India

Abstract

Background: Sacrum is a large triangular bone formed by fusing five sacral vertebrae and forms the caudal end of the vertebral column. The sacral hiatus (SH) is formed by incomplete fusion of the posterior elements of the fourth or fifth sacral vertebra. It's an important landmark for inoculating caudal epidural anesthesia or analgesia in patients with low back pain, in obstetrics as well as in orthopedic surgeries.

Aim and Objective: To study the morphometric measurements of SH for inoculating caudal epidural anesthesia.

Materials and Methods: Forty-six dry human sacra of adults were studied. Various anatomical measurements were taken with the help of a digital Vernier caliper, accuracy (0.1 mm).

Results: Measurements and the shape of 46 SH were studied. V-Shaped hiatus was found predominantly followed by U shape. The maximum length of hiatus from the base to the apex was 3.9 cm and a minimum of 1.5 cm. The level of the apex of hiatus was found mostly at S-4 level (49%) followed by S-3 (18%). Level of the base of hiatus at S-5 (75%) followed by S4-S5 joint. Other measurements taken are the transverse, anteroposterior measurement of SH. Antero-posterior and transverse measurements of the spinal canal were also taken.

Conclusion: SH shows morphometric variations in various populations. Understanding and knowledge of these variations are essential. This will improve the success of caudal epidural anesthesia. Identification of a single bony landmark may not help in locating SH. These anatomical disparities may be a factor in caudal epidural anesthesia failure.

Key words: Caudal epidural block, Morphometry, Sacral Hiatus, Sacral Cornua, Sacrum

INTRODUCTION

The sacrum is a broad triangular bone present in the caudal end of the vertebral column. It helps in the formation of the posterior wall of the pelvic cavity. The sacrum is fixed between two innominate (hip) bones. Anatomists and anthropologists have since long acknowledged the importance of sacrum in determining the gender of a deceased person.[1] In the sacrum, hiatus is formed by incomplete fusion of the dorsal part of the fourth or fifth sacral vertebra. Sacral hiatus (SH) is a significant landmark for performing caudal epidural anesthesia or analgesia in various cases such as low backache, obstetrics well in orthopedic surgeries. Due to these variations, the SH has an appreciable difference in size and shape; it is hard to localize the hiatus during caudal epidural anesthesia. The surface landmark for SH is present at about 5 cm (2 inches) superior to the tip of fused coccygeal bones underneath the skin of the natal cleft. The SH carries the nerve roots, which include lower sacrum nerve fibers and coccygeal nerve roots. Various other structures are also found at this site, including filum terminale, Sacrum related fibro-fatty tissue covered by a superficial dorsal sacrococcygeal ligament. This sacrococcygeal ligament is also called a sacrococcygeal membrane. This membrane has to be pierced to reach the sacral canal during the same procedure caudal epidural block (CEB).[2] The sacrum also

Access this article online

www.ijss-sn.com

Month of Submission : 10-2021
Month of Peer Review : 11-2021
Month of Acceptance : 11-2021
Month of Publishing : 12-2021

Corresponding Author: Dr. Kumar Satish Ravi, Department of Anatomy, All India Institute of Medical Sciences, Rishikesh, Uttarakhand, India.

has other importance, and it helps in the identification of gender in the human skeleton. Because the sacrum is a part of an axial skeleton as well as also helps in the formation of the pelvic girdle, it has applied importance. The gender determination of males, as well as females with the help of Sacrum, is the sacral index (SI) which is the well-known method. SI has proven as an accurate parameter in identifying the sexual dimorphism.[3] The SH has a central part and lateral margins. These margins are formed by two sacral cornua and are the remnants of the inferior articular process and extend downward. These margins are important clinical landmarks during palpation of SH.[4]

It is essential to have detailed knowledge of SH for proper access into the caudal (sacral) epidural space. Considering these points, the present study was designed. Hence, the purpose of this study is to elucidate the various measurements of SH in human dry sacra as well as identification of nearest bony landmarks to permit correct and uncomplicated epidural accesses.

MATERIALS AND METHODS

In the present study, 45 intact human adult sacra were included, which were obtained from the Department of Anatomy AIIMS Rishikesh. All the collected sacra were undamaged with apparent SH. Sacra showing laceration, wear and tear, broken or fractured were excluded from the study. Under regular inspection and adequate care, bones were conserved in dry conditions, in a departmental museum free from any moisture, dust or insects, moth, etc. The following parameters were measured by using a digital vernier caliper considering all Standard anatomical landmarks.

Following measurements were taken:

- Length of hiatus—distance from apex to base
- Intercornual distance (transverse diameter)—the distance between inner surfaces of sacral cornu
- Anteroposterior diameter of hiatus at the apex of SH.

The other parameters include the level of apex of hiatus in relation to the sacral vertebra, level of the base of hiatus (tips of sacral cornu) in regard to sacral and coccygeal vertebra also studied.[5] Figure 1 shows the shape of the hiatus, defects in the dorsal wall of the sacrum, presence or absence of sacral cornu. sacral cornu of <3 mm was considered absent.[6]

RESULTS

The shape of SH of the total number of 45 human adult sacra was identified. Sex determination was done by calculating the SI. Twenty-eight female and 17 male sacra were measured. V-shaped SH was found commonly in 55.5% of sacra followed by U-shaped in 22.6%, irregular in

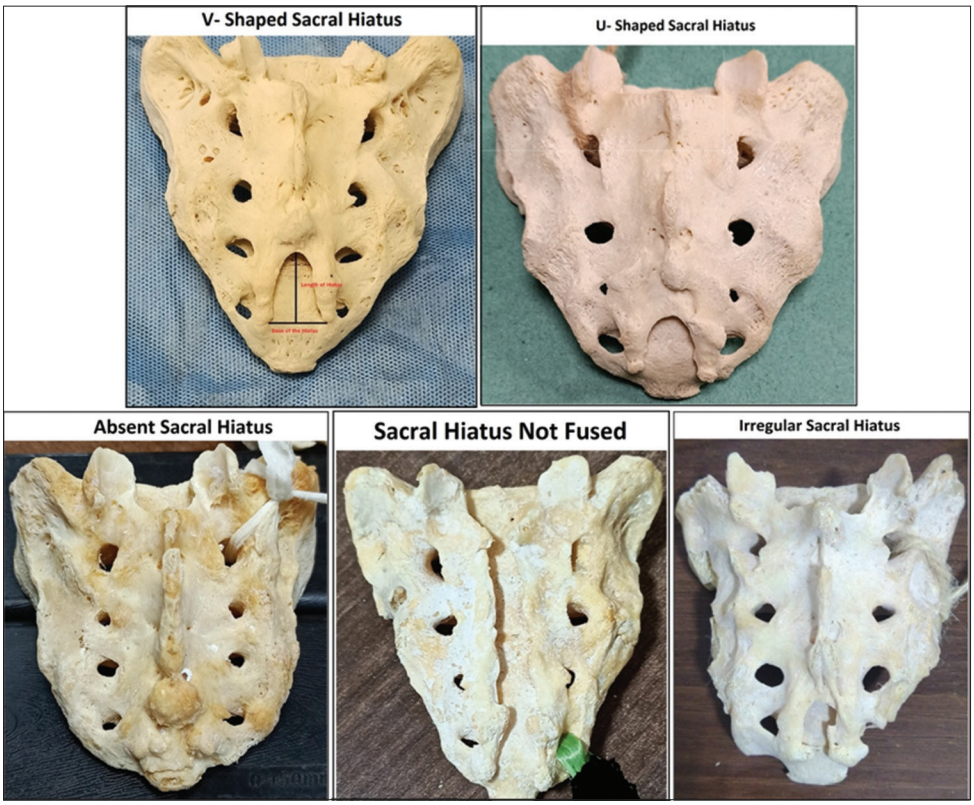

Figure 1: Showing various forms of sacral hiatus

11.1%, not fused in 2.2%, and absent in 4.4% [Table 1]. The maximum length of SH measured was 3.9 cm with a standard deviation of 2.26 ± 1.19 [Table 2]. The maximum transverse diameter of SH was found 2.1 cm and a minimum of 0.4 cm [Table 3]. The maximum anteroposterior diameter was found at 6 mm and a minimum of 0.3 mm [Table 4]. The base of SH is commonly found at S-5 in 75% of sacra, at S4-S5 in 11%, S-4 in 2%, 5% at coccygeal level, and absent in 5%, and not fused in 2% of sacra [Table 5]. Level of the apex of SH mainly was found at S4 in 49% of sacra followed by 18% at the S3 level, S3-S4 in 11%, S4-S5 in 7%, S-5 in 4%, S1 in 2%, not fused in 2% and absent in 7% of the sacra [Table 6].

Table 1: Shape, number and percentage of sacral hiatus

Shape of SH	Number of Sacra	Percentage
V Shaped	25	55.5
U Shaped	12	26.6
Irregular	5	11.1
Not Fused	1	2.2
Absent	2	4.4

SH: Sacral hiatus

Table 2: Sacral hiatus length

Length of SH				
Maximum	Minimum	Mean	Not fused	Absent
3.9 cm	0	2.26 cm±1.19 SD	1	2

SH: Sacral hiatus

Table 3: Sacral hiatus transverse diameter

Transverse diameter of SH				
Maximum	Minimum	Mean	Not fused	Absent
2.1 cm	0.4 cm	1.35	1	2

SH: Sacral hiatus

Table 4: Sacral hiatus anterior-posterior diameter

AP diameter of SH				
Maximum	Minimum	Mean	Not fused	Absent
6 mm	0.3 mm	3.026 mm±1.48 SD	1	2

SH: Sacral hiatus

Table 5: Percentage of sacral hiatus base

Level of base of hiatus (%)					
S-5	S4-S5	S4	CX-1	Absent	Not fused
75	11	2	5	5	2

Table 6: Percentage of sacral hiatus apex

Level of Apex (%)							
S3	S4	S3-S4	S4-S5	S5	S1	Not Fused	Absent
18	49	11	7	4	2	2	7

DISCUSSION

The feeling of the "pop" on penetrating the sacrococcygeal membrane has been the most routinely practiced technique for identifying the caudal epidural space after determining SH by palpating the sacral cornua. The success and failure rates have always been associated with the method and reported by several authors.[7] One factor behind the lack of successfulness in the CEB is its anatomical variation, so its knowledge in clinical situations is imperative for therapeutic and diagnostic procedures of the lumbosacral spine to avert any dural injury and failure.[2,8] In the present study, V-shaped SH was commonly found in 55% of sacra and U-shaped in 26%. These V and U shapes allow adequate space for needle access during the procedure of CEB. A study done by Nagar showed the U-shaped SH was found in (41.5%) and V-shaped in (27.0%) and were the most common shapes in the Indian population.[9] Mustafa *et al.* (2012) stated that the level of apex of SH is commonly found at the 4th sacral vertebral level (S4). In our study, the most typical level of SH was found at S4 (49%), followed by S3 (18%). A high level of SH apex (S3) is a dangerous site because of its immediate relation with the dura mater termination at S2.[3,7] Sometimes it is not easy even for experienced clinicians to locate the caudal epidural space due to its anatomical variation. SH and its apex palpation are possibly hard, particularly in obese patients, but it is a crucial bony landmark in the accomplishment of CEB.[8,10] In 3% of the cases, the sacral canal is entirely closed, making it impossible anatomically to insert a needle into the sacral canal, and cases of absence of hiatus, complete agenesis, and bony septum at SH make it hard to locate the opening of the sacral canal. Together these factors might increase the chances of the unsuccessful rate of CEB up to 7% of all cases.[4] A study on 104 human sacra showed common abnormalities which could influence the successes rate of caudal epidural anesthesia in 29.5% of cases. The common causes included SH of <8 mm in length, complete agenesis of SH, absent SH, angulation in Sacrum, presence of bony septum in the sacral canal, and severe infections.[11]

The sacrum and its hiatus is the crucial landmark and sometimes used for various purposes. With the help of SH, medication can be injected into the epidural space. This caudal epidural technique has been practiced since 1952 to anesthetize the appropriate dermatomes. It may also be used for symptomatic relief of low back pain by injecting various pain-relieving medications. Some authors believe that the apex of the SH is a critical point and landmark for the CEB; however, there may be difficulty in its palpation in some patients, especially in obese. Hence other bony landmarks can also be used in relation to SH.[12] Failure of a CEB is also seen due to variations in SH and its shapes.[13] Failure rate is observed by some authors- in

children 14.82% failure noted by Busoni and Sarti.[14] and in case of adult Wong *et al.* reported an excellent success rate 95.9% of CEB.[15] A study was done by Chen *et al.* and revealed that ultrasound-guided needle placement for the epidural block was 100% successful.[16]

CONCLUSION

The present study was performed to find out various sacral parameters and to emphasize variations in the shapes of SH. Variations in shapes as well as level of base and apex of SH may lead to failure of CEB.[13] In this study, we found that the maximum anteroposterior diameter was 6 mm, and the maximum transverse diameter was 2.1 cm, and it should be taken into consideration to prevent any damage to the other structures. We also found that 55.5% of sacra was V-shaped and base of SH at S-5 level in 75% cases. The base of the SH is an essential landmark for the insertion of the needle during an epidural block. But It should be kept in mind that hiatus may be present at S-4, S-5, coccygeal level or can be absent in a few cases. These anatomical variations may be one of the reasons behind the failure of epidural block. So only identification of a single point or landmark in bone may not be helpful in locating the SH. Understanding the variations in SH will improve the success rate of CEB.

REFERENCES

1. Shingare AK, Masaram NB, Dhapate SS. Morphometric analysis of human sacra. Med Pulse Int J Anat 2017;3:34-7.
2. Kothapalli J. Sacral hiatus-a morphometric and anatomical study. Texila Int J Basic Med Sci 2017;2:20-3.
3. Mustafa M, Mahmoud O, El Raouf H, Atef H. Morphometric study of sacral hiatus in adult human Egyptian sacra: Their significance in caudal epidural anesthesia. Saudi J Anaesth 2012;6:350-7.
4. Sekiguchi M, Yabuki S, Saton K, Kikuchi S. An anatomic study of the sacral hiatus: A basis for successful caudal epidural bloc. Clin J Pain 2004;20:51-4.
5. Aggarwal A, Aggarwal A, Harjeet K, Sahni D. Morphometry of sacral hiatus and its clinical relevance in caudal epidural block. Surg Radiol Anat 2009;31:793-800.
6. Saluja S, Agarwal S, Tuli A, Raheja S, Tigga SR, Paul S. Morphometric analysis of the sacrum and its surgical implications. J Clin Diagn Res 2018;12:AC01-6.
7. Senoglu N, Senoglu M, Oksuz H, Gumusalan Y, Yuksel KZ, Zencirci B, *et al*. Landmarks of the sacral hiatus for caudal epidural block: An anatomical study. Br J Anaesth 2005;95:692-5.
8. Ramamurthi KS, Anil KR. Anatomical study of sacral hiatus for successful caudal epidural block. Int J Med Res Health Sci 2013;2:496-500.
9. Nagar S. A study of sacral hiatus in dry human sacra peer teaching view project lumbosacral transitional vertebra view project. J Anat Soc India 2004;63:18-21.
10. Hegazy AE, Gamil NM. A morphological study of the sacral hiatus. Zagazig Univ Med J 2006;12:2877-86.
11. Black MG. Anatomic reasons for caudal anesthesia failure. Curr Res Anesth Analg 1949;28:33-9.
12. Singh A, Gupta R, Singh A. Morphological and morphometrical study of sacral hiatus of human sacrum. Natl J Integr Res Med 2018;9:65-73.
13. Bagoji IB, Bharatha A, Prakash KG, Hadimani GA, Desai V, Bulgoud RS. A morphometric and radiological study of sacral hiatus in human adult sacra and its clinical relevance in caudal epidural anaesthesia. Maedica (Bucur) 2020;15:468-76.
14. Busoni P, Sarti A. Sacral intervertebral epidural block. Anaesthesiology 1987;67:993-5.
15. Wong SY, Li JY, Chen C, Tseng CH, Liou SC, Tsai SC, Kau YC, *et al*. Caudal epidural block for minor gynecologic procedures in outpatient surgery. Chang Gung Med J 2004;27:116-21.
16. Chen CP, Tang SF, Hsu TC, Tsai WC, Liu HP, Chen MJ, *et al*. Ultrasound guidance in caudal epidural needle placement. Anesthesiology 2004;101:181-4.

How to cite this article: Ahmed A, Haasan SBA, Divasha, Sonia, Singla M, Ravi KS. Morphometric Study of Sacral Hiatus in Adult Human Sacra and Its Clinical Insinuation in Caudal Epidural Anesthesia. Int J Sci Stud 2021;9(9):16-19.

Source of Support: Nil, **Conflicts of Interest:** None declared.

Print ISSN: 2321-6379
Online ISSN: 2321-595X

Original Article

Role of Ultrasound in the Evaluation of Paediatric Rickets and its Association with Radiograph: A Cross-sectional Study

Hemangini Thakkar[1], Rajaram Sharma[2], Padma Badhe[3], Prateek Joshi[2], Diksha Rewal[4], Tapendra Tiwari[2], Saurabh Goyal[2]

[1]Professor and Head, Department of Radiodiagnosis, Seth Gordhandas Sunderdas Medical College and King Edward Memorial Hospital, Mumbai, Maharashtra, India, [2]Assistant Professor, Department of Radiodiagnosis, Pacific Institute of Medical Sciences, Udaipur, Rajasthan, India, [3]Professor, Department of Radiodiagnosis, Seth Gordhandas Sunderdas Medical College and King Edward Memorial Hospital, Mumbai, Maharashtra, India, [4]Senior Resident, Department of Transfusion Medicine, RNT Medical College, Udaipur, Rajasthan, India

Abstract

Introduction: Traditionally radiograph is used to diagnose rickets; however similar findings can also be seen on ultrasonography (USG) of the wrist joint and knee joint, such as widening of growth plates, frayed and cupped paintbrush metaphyses, bowing deformities, fractures, and pseudo-fractures.

Aim: The aim of the study is to evaluate the usefulness and diagnostic accuracy of USG for rickets as an isolated modality and in comparison with a radiograph.

Methodology: A cross-sectional study was conducted over a period of 10 months in the Department of Radiology. Thirty biochemically proven rickets patients and ten controls participants were assessed with bilateral wrist, knee, and trans-abdominal USG and compared to the latest radiograph for the following parameters: (1) Combined thickness of growth plate and unossified part of metaphysis was measured where it was maximum in both wrists and knee joints. (2) Presence or absence of cupping of physeal disc was assessed. (3) Metaphysis was evaluated for the presence of fraying and splaying. (4) If the unsharpness of cortex was present or not in the evaluated bones. The sensitivity, specificity, positive and negative predictive values (NPVs) of the above-mentioned variables were calculated for an USG and radiograph. Association between these was calculated.

Results: Sensitivity on radiograph for cupping, fraying, splaying, and unsharpness were 80%, 86.67%, 80%, and 10%, whereas on USG were 0%, 100%, 90%, and 10%, respectively. The specificity for these features were 100% on radiograph as well as USG. The positive predictive value of radiograph for these were 100%, while the for USG it was 0 for the cupping and 100% for rests of the features. The NPV for cupping, fraying, splaying, and unsharpness were 62.5%, 71.42%, 62.5%, and 27.02%, while on USG were 25%, 100%, 76.92%, and 27.02%, respectively.

Conclusions: USG is more sensitive in detecting rickets as compared to the radiograph. USG showed increase in the combined thickness of growth plate and unossified part of metaphysis more accurately than the radiograph. USG also depicted the fraying and splaying of metaphysis and unsharpness of the cortex in a greater number of cases as compared to the radiograph.

Key words: Bone, Growth plate, Musculoskeletal

Access this article online

IJSS

www.ijss-sn.com

Month of Submission : 10-2021
Month of Peer Review : 11-2021
Month of Acceptance : 11-2021
Month of Publishing : 12-2021

INTRODUCTION

Rickets is known as a defect in mineralization of bones before the closure of epiphysis in immature skeleton due to impaired metabolism of Vitamin D, Calcium or Phosphorus, causing fractures, and deformities.[1] Rickets is one of the most frequent diseases affecting childhood

Corresponding Author: Dr. Rajaram Sharma, Department of Radio-diagnosis, Pacific Institute of Medical Sciences, Udaipur, Rajasthan, India.

in developing countries. The commonest cause is Vitamin D deficiency, but lack of adequate dietary Calcium may also lead to rickets.[2] Although it can occur in adults, most cases occur in children suffering from severe malnutrition.

Ongoing back to the historical perspective, Greek physician Soranus of Ephesus had first reported deformation of the bones in infants in the first and second centuries AD. Diagnosis of rickets is established by clinical features (bony pain and muscle spasms, knock-knees, frontal bossing, soft skull, rickety rosary, i.e., costochondral swelling, Harrison's groove, widening of the wrist), radiological findings, and laboratory values. The biochemical analysis will show hypocalcemia, hypophosphatemia; serum elevated levels of alkaline phosphatize, and parathormone along with hyper aminoaciduria.[3-5]

Features on the radiograph include-Generalized osteopenia, coarse trabecular changes (cortical irregularity of the shaft), widening of the growth plate, frayed (irregularity of metaphysis) and cupped paintbrush metaphyses, absent zone of provisional calcification, bowing deformities, fractures, decreased bone length, scoliosis, and pseudo-fractures.[4,6]

Musculoskeletal ultrasonography (USG) is an emerging field of imaging. USG is a valuable and well-founded technique in musculoskeletal pathologies. Its role in imaging is continuing to evolve with the recognition of further clinical applications and improved USG technology. It is now a well-established first-line imaging modality in Europe to diagnose musculoskeletal pathologies and is rapidly gaining popularity in other parts of the world.[6,7]

The objectives of the study were to detect standard radiograph findings on USG of wrist and knee joints and evaluation of sensitivity, specificity, positive predictive value, and negative predictive value (NPV) of USG and radiograph for rickets using measurements of the thickness of the physeal plate and unossified part of epiphysis and metaphysic and observing for the cupping, fraying and splaying of the metaphysis.

USG was also evaluated if it can an idea about underlying etiology. However, it was not compared to radiograph, as radiograph cannot give an idea about underlying etiology. The statistical analysis was done using Graphpad prism software for various variables, and the association between the attributes was calculated.

SUBJECTS AND METHODS

It was a cross-sectional study conducted over a period of 10 months (From January 2018 to October 2018) in the Department of Radiology, Seth GS Medical College and KEM hospital, Mumbai, Maharashtra, India.

Inclusion Criteria

1. Newly biochemically proven rickets cases of age between 1 and 10 years
2. Already diagnosed cases, now on treatment were included
3. Patients having registration in our institute either as outdoor patients or indoor patients
4. Controls were the participants of age between 1 and 10 years who are not having rickets at present or had it in the past. Radiographs of the control were done for some other reasons such as trauma (however, no fracture) or skeletal survey for various other reasons such as bone age estimation in hypothyroidism. Controls were not subjected to additional radiographs from our side
5. Patient with the latest available digital radiograph of both wrist joint and knee joints (radiograph of within a week's duration).

Exclusion Criteria

1. Patient, not willing for the study
2. Patients where rickets was a clinical suspicion only.

Of all the participants referred to us over a period of 10 months, the patients meeting the inclusion criteria were evaluated.

This was a pilot study. The number of patients has been decided arbitrarily, keeping in mind a sufficient number of patients be included to evaluate the role of USG in the diagnosis of rickets with radiograph correlation. On the basis of this study, a larger sample size can be studied in the future. The sample size was 40 participants, including 30 rickets patients and ten controls.

Study Procedure

All participants (cases and controls) were scanned on Philips HD 11×E using a 5–12 MHz linear transducer and curvilinear transducer having color Doppler and spectral capabilities. All patients were assessed with bilateral wrists, knees, and trans-abdominal USG (for cases only).

The examination procedure was explained to the patient and relatives. With the patient lying down comfortably in a supine position, USG gel was spread over the wrist, knee, flank, right hypochondrium, and neck on the right side than on the left side in the same sequence. The transducer, held in the examiner's right hand, was moved across the joint from the top downwards and from right to left till the requisite structures were studied. Grayscale images were obtained. The depth and focus of the transducer were adjusted according to each patient.

The patient was kept in a supine position, and a rolled towel was placed behind the knee to achieve an approximately 10–15° of knee flexion for the USG scan.[7] USG of the wrist was performed in the supine position in the neutral orientation.[7]

Perpendicular maximum distance between the lateral or the medial most ends of the metaphysis to the ossified end of the epiphysis in both the knees and wrists was measured [Figures 1-4].

Routine USG examination included a complete morphological examination of wrist and knee joints, kidneys, liver, and parathyroid glands. During each examination, epiphyseal width measurement was obtained at the point of maximum width. Subjective assessment for the depth of disc cupping and structural abnormalities of joints in rickets were also assessed. All these findings were compared to the latest available radiograph (not older than a week) [Figure 5].

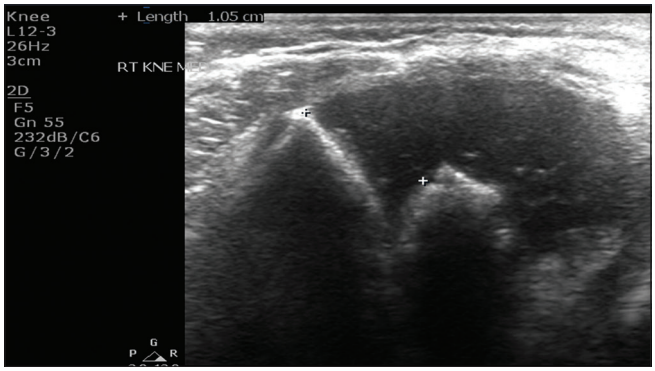

Figure 1: Greyscale ultrasound image of the right knee, showing femoral growth plate measurement at its maximum diameter at medial condyle. The hypoechoic part between the + sign is the growth plate or physeal plate

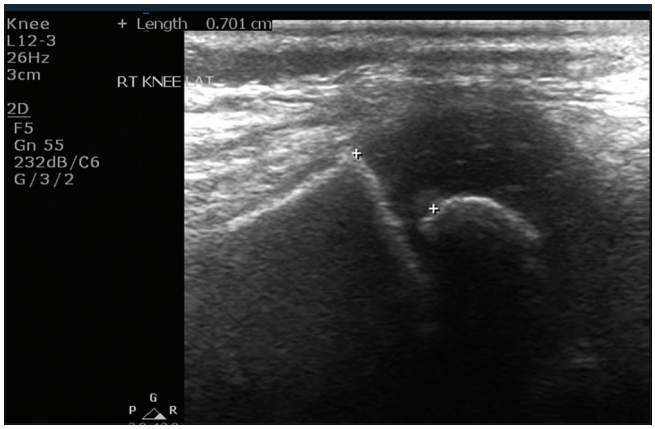

Figure 2: Greyscale ultrasound image of the right knee, showing femoral growth plate measurement at its maximum diameter at lateral condyle. The hypoechoic part between the + sign is the growth plate or physeal plate

USG for both kidneys was done to look for medullary and cortical calcinosis, of the liver to look for biliary atresia and cirrhosis, and of the parathyroid gland to look for enlargement or adenoma. (For cases only; not for controls).

The following parameters were evaluated:

1. Combined thickness of growth plate and unossified part of epiphysis and metaphysis where it is maximum in both wrists and both knee joints
2. Cupping of physeal disc and metaphysis - Present or not on radiograph and on USG. Cupping was defined as a concave radio-lucent margin in the metaphysis. It was a subjective assessment, and no actual measurements were done for this criterion

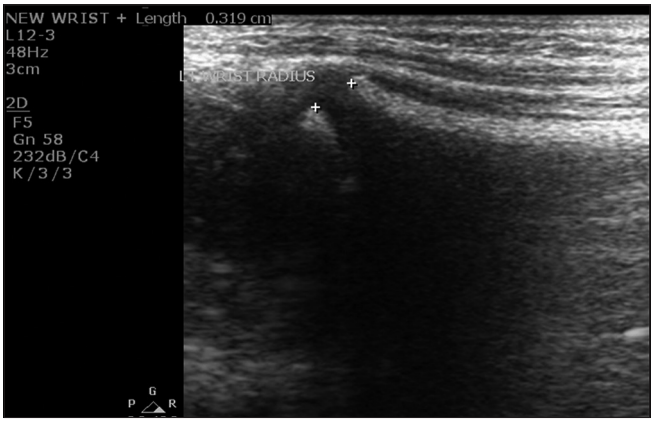

Figure 3: Greyscale ultrasound image of right wrist, showing radius growth plate measurement at its maximum diameter at the styloid process. The hypoechoic part between the + sign is the growth plate or physeal plate

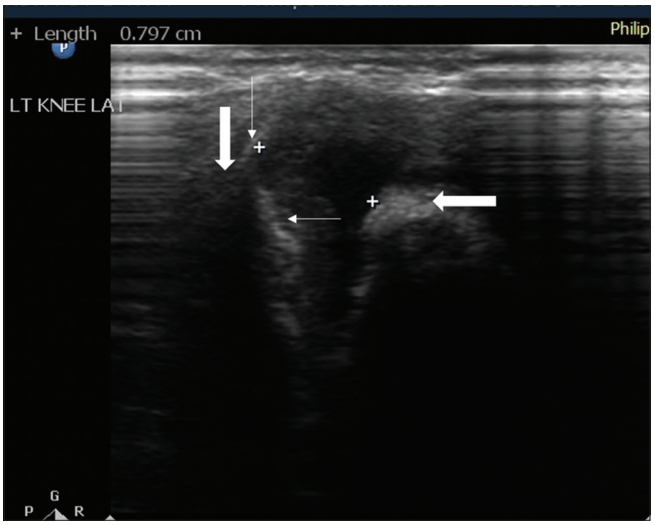

Figure 4: Greyscale ultrasound image of the left knee, showing splaying (thin vertical white arrow) and fraying (thin horizontal white arrow). There is a widening of growth seen. Cortical irregularity is also seen on both the epiphyseal (thick horizontal white arrow) and metaphyseal side (thick vertical white arrow)

3. In metaphysis, if
   - Fraying present or not
   - Splaying present or not
4. Unsharpness of cortex of both radius and femur. (Subjective criteria).

All these parameters were compared and analyzed with a previously available radiograph (not older than a week). In the case of asymmetry in involvement, joint with more severely involvement was used to compare the outcome. Any amount of fraying or splaying was considered abnormal.

The radiologist interpreting the radiograph and the radiologist doing USG were experienced (faculty members of the department), trained, and were blinded to each other's interpretation.

The data obtained from the study were tabulated in the excel sheet and the calculation was done using Graphpad prism and Statistical Package for the Social Sciences software. The frequency variables for attributes and *P*-value were calculated a $P < 0.01$ was considered significant.

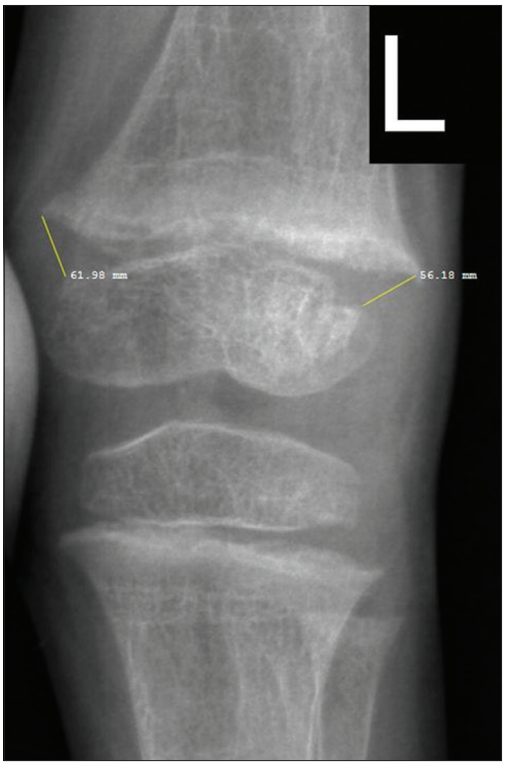

Figure 5: Anteroposterior radiograph of the left knee joint shows all typical features of rickets, i.e., growth plate widening, cupping, fraying and splaying of the metaphysis. There is coarsening of the trabeculae, and generalized osteopenia was noted. This image shows how the maximum diameter of the growth plate is taken on both the medial and lateral sides

RESULTS

The study included 30 rickets patients (14 males and 16 females) and ten normal participants as controls (five males and five females), and the *P*-value for the efficacy of USG in the diagnosis of rickets was calculated. Data obtained from the study is analyzed for age distribution, sex distribution to calculate sensitivity, specificity, positive and NPV of USG with radiograph correlation.

The radiograph demonstrated standard features, i.e., generalized osteopenia, coarse trabecular changes, widened growth plates, frayed and cupped paintbrush metaphyses, absent zone of provisional calcification, bowing deformities, fractures, decreased bone length, scoliosis, and pseudo-fractures. The USG on the other hand precisely illustrated widening of growth plates, frayed and cupped paintbrush metaphyses, fractures, and pseudo-fractures.

For cupping, fraying splaying and unsharpness of cortex the radiograph had sensitivity of 80%, 86.67%, 80% and 10%, while USG had 0%, 100%, 90% and 10%, respectively. The positive predictive value of radiograph for cupping, fraying splaying and unsharpness of cortex was 100% for each parameter, while for USG it was 0 for the cupping and 100% for rests of the evaluated features. The specificity for these features was 100% on both USG in this study. The NPV of radiograph for cupping, fraying splaying and unsharpness of cortex were 62.5%, 71.42%, 62.5% and 27.02% while on USG these were 25%,100%, 76.92% and 27.02% respectively [Tables 1-3].

Three out of the 30 rickets patients are having associated medullary nephrocalcinosis on USG, a finding which favors the diagnosis of Vitamin-D resistant renal rickets, thus assisting in evaluation of underlying etiology for the disease. Rest 27 cases had a normal USG of the kidneys. *P*-value was calculated for the thickness of physeal plate and unossified part of epiphysis and metaphysis at medial femoral condyle (on the medial side) on USG (tpmu) in rickets patients versus thickness of physeal plate and unossified part of epiphysis and metaphysis at medial femoral condyle (on the medial side) on a radiograph in rickets patients (tpmx) using Graphpad prism software (unpaired *t*-test). It was found to be <0.01, which is significant.

P-value was calculated for the thickness of physeal plate and unossified part of epiphysis and metaphysis at lateral femoral condyle (on lateral side) on USG (tplu) in rickets patients versus thickness of physeal plate and unossified part of epiphysis and metaphysis at lateral femoral condyle

Table 1: Contingency table for evaluated imaging features of rickets on radiograph and ultrasound

Feature	Number of cases in which the radiograph showed the finding	Number of cases in which the ultrasound showed the finding
Cupping	24	0
Fraying	26	30
Splaying	24	27
Unsharpness of cortex	3	3

Table 2: Calculated parameters for various rickets features on radiograph

Feature	Sensitivity (%)	PPV (%)	Specificity (%)	NPV (%)
Cupping	80	100	100	62.50
Fraying	86.67	100	100	71.42
Splaying	80	100	100	62.50
Unsharpness (Irregularity)	10	100	100	27.02

PPV: Positive predictive value, NPV: Negative predictive value

Table 3: Calculated parameters for various rickets features on ultrasound

Feature	Sensitivity (%)	PPV (%)	Specificity (%)	NPV (%)
Cupping	0	0	100	25
Fraying	100	100	100	100
Splaying	90	100	100	76.92
Unsharpness (Irregularity)	10	100	100	27.02

PPV: Positive predictive value, NPV: Negative predictive value

(on lateral side) on a radiograph in rickets patients (tprx) using Graphpad prism software (unpaired *t*-test). It was found to be <0.01, which is significant.

P-value was calculated for the thickness of physeal plate and unossified part of epiphysis and metaphysis of the radius of the right hand at styloid process on USG (tpru) in rickets patients and thickness of physeal plate and unossified part of epiphysis and metaphysis of the radius of the right hand at styloid process on a radiograph in rickets patients (tprx) using Graphpad prism software (unpaired *t*-test). It was found to be <0.01, which is significant.

This study suggests that USG has better chances of picking up the widening of growth plate, as it has consistently shown higher values for thickness of physeal plate and unossified part of epiphysis and metaphysis as compared to the radiograph. Rests of the statistical analysis details are provided in Table 4 below.

Table 4: Statistical calculation using Graphpad Prism for the cases-

Statistical variable	Tpmx	Tpmu	Tplx	Tplu	Tprx	Tpru
Number of values	30	30	30	30	4	4
Minimum	4.400	5.700	2.800	3.700	1.800	2.100
25% Percentile	7.400	8.475	4.600	6.150	1.975	2.300
Median	8.550	9.700	5.250	6.800	2.900	3.300
75% Percentile	9.200	11.28	6.275	7.525	4.425	5.125
Maximum	12.40	17.50	10.70	12.60	4.800	5.600
Mean	8.397	9.940	5.610	6.997	3.100	3.575
Std. Deviation	1.555	2.214	1.455	1.565	1.288	1.500
Std. Error of Mean	0.2838	0.4041	0.2656	0.2858	0.6442	0.7499
Lower 95% CI of mean	7.816	9.113	5.067	6.412	1.050	1.189
Upper 95% CI of mean	8.977	10.77	6.153	7.581	5.150	5.961

DISCUSSION

Rickets is a deforming and debilitating disease of the growing pediatric population in developing countries. As a traditionally established practice, the radiograph is the commonly prescribed imaging modality for rickets patients to date. As advancements are going on in biochemical testing and in treatment, soon, there will be an imaging modality that is more sensitive and specific for diagnosing rickets. Radiation protection in the pediatric group is a growing concern of the era. Musculoskeletal USG has evolved according to the need of the changing and developing clinical practices. USG is a radiation-free and yet reasonably cheaper alternative.

However, there is no literature available about USG in the imaging of rickets or its correlation with a radiograph. We propose that additional such studies should be done on this topic to arrive at a consensus.

Limitations and Future Recommendations

The limitations of the study are smaller sample size and inter-observer variability. As this was a pilot study only, purposefully, we omitted a few of the rickets features.

The same findings can be applied to adult rickets or osteomalacia; however, some differences will be there because the growth plate is fused till the adulthood. We have taken an initial step in this vast field of scope, which requires further investigation and applicability.

CONCLUSIONS

USG is more sensitive in detecting growth plate widening, fraying and splaying of the metaphysis. However, radiograph has an overhand in detecting cupping of metaphysis and deformities evaluation. Overall, USG is more sensitive in detecting rickets compared to the radiograph. We hope this pilot study will encourage further research in the subject, and over time some new guidelines will be made.

ACKNOWLEDGMENTS

Nil.

ETHICS APPROVAL AND CONSENT TO PARTICIPATE

Approval was taken from the institutional ethics committee before the start of the study. Written informed consent from the parents of the participants and assent from participants were obtained.

CONSENT FOR PUBLICATION

Not applicable.

REFERENCES

1. Munns CF, Shaw N, Kiely M, Specker BL, Thacher TD, Ozono K, *et al*. Global consensus recommendations on prevention and management of nutritional rickets. J Clin Endocrinol Metab 2016;101:394-415.
2. Ruangkit C, Suwannachat S, Wantanakorn P, Sethaphanich N, Assawawiroonhakarn S, Dumrongwongsiri O. Vitamin D status in full-term exclusively breastfed infants versus full-term breastfed infants receiving Vitamin D supplementation in Thailand: A randomized controlled trial. BMC Pediatr 2021;21:378.
3. Tan ML, Abrams SA, Osborn DA. Vitamin D supplementation for term breastfed infants to prevent Vitamin D deficiency and improve bone health. Cochrane Database Syst Rev 2020;12:CD013046.
4. Calder AD. Radiology of osteogenesis imperfecta, rickets and other bony fragility states. Endocr Dev 2015;28:56-71.
5. Klauser AS, Tagliafico A, Allen GM, Boutry N, Campbell R, Court-Payen M, *et al*. Clinical indications for musculoskeletal ultrasound: A Delphi-based consensus paper of the European society of musculoskeletal radiology. Eur Radiol 2012;22:1140-8.
6. Henderson RE, Walker BF, Young KJ. The accuracy of diagnostic ultrasound imaging for musculoskeletal soft tissue pathology of the extremities: A comprehensive review of the literature. Chiropr Man Therap 2015;23:31.
7. Özçakar L, Kara M, Chang KV, Ulaşlı AM, Hung CY, Tekin L, *et al*. EURO-MUSCULUS/USPRM basic scanning protocols for wrist and hand. Eur J Phys Rehabil Med 2015;51:479-84.

How to cite this article: Thakkar H, Sharma R, Badhe P, Joshi P, Rewal D, Tiwari T, Goyal S. Role of Ultrasound in the Evaluation of Paediatric Rickets and its Association with Radiograph: A Cross-sectional Study. Int J Sci Stud 2021;9(9):20-25.

Source of Support: Nil, **Conflicts of Interest:** None declared.

Print ISSN: 2321-6379
Online ISSN: 2321-595X

Original Article

Comparative Evaluation of Post-operative Sequelae Using Diode Laser and Conventional Scalpel Blade for Soft Tissue Incision in Impacted Mandibular Third Molar Surgery- A Prospective Split Mouth Study

Shubham Katariya[1], Rajshekhar Halli[2], Saurabh Khandelwal[3]

[1]Department of Oral and Maxillofacial Surgery, Bharati Vidyapeeth Dental College and Hospital, Pune, India, [2]Professor, Department of Oral and Maxillofacial Surgery, Bharati Vidyapeeth Dental College and Hospital, Pune, India, [3]Senior Lecturer, Department of Oral and Maxillofacial Surgery, Bharati Vidyapeeth Dental College and Hospital, Pune, India

Abstract

Aim: This studyb aims to compare the surgical outcome using diode laser with conventional scalpel blade for soft tissue management during surgical removal of impacted mandibular third molars.

Objective: The objective of the study is to compare soft tissue incision making by diode laser with conventional scalpel and blade, to evaluate the ease of surgical incision making using diode laser, to evaluate the post-operative sequel such as pain, swelling, and trismus in both groups, and to evaluate post-operative complication like incidence of dry socket.

Specifications of Efficacy Parameters: The intensity of post-operative pain, swelling, trismus, and incidence of dry socket: on post-operative days 3, 5, 7 and 15.

Study Group: The sample size estimated is 30 sites, that is, 15 in Group 1 (Conventional Scalpel Blade group) and 15 in Group 2 (Diode laser group). Since this research employs split mouth design, total subjects to be included will be 15.

Conclusion: Diode laser was well tolerated by the patients, and it is more successful than conventional treatment methods. Therefore, diode lasers treatment can form an integral part of oral surgery therapy in the future. However, further longitudinal studies are required to evaluate the long-term effects of diode laser on clinical as well as microbiological parameters.

Key words: Mandible, Molar, Surgery

INTRODUCTION

Third molar surgery is the most common procedure performed in oral and maxillofacial surgery practice. They are directly or indirectly, the underlying cause of numerous disorders in the jaw and facial regions. It has been well documented that impacted third molars, either partial or complete, are associated with several complications according to the work of Oikarinen in 1991 and Kim in 2006, including pericoronitis, regional pain, odontogenic abscesses, dry socket, trismus, distal caries in second molar, cysts, tumors, and arch crowding. The highest incidence of impaction has been shown in mandibular wisdom teeth. Early removal of these teeth to prevent the above mentioned problems is widely approved. Therefore, symptomatic or asymptomatic impacted third molars are often extracted to reduce the above mentioned clinical symptoms and complications.[1-5]

Diode lasers seem to be have numerous applications in the field of oral and maxillofacial surgery in view of soft

Access this article online

www.ijss-sn.com

Month of Submission : 10-2021
Month of Peer Review : 11-2021
Month of Acceptance : 11-2021
Month of Publishing : 12-2021

Corresponding Author: Dr. Shubham Katariya, Department of Oral and Maxillofacial Surgery, Bharati Vidyapeeth Dental College and Hospital, Pune, India.

tissue applications including incision, hemostasis, and coagulation. Many advantages of the laser vs. the scalpel blade have been discussed in the literature. These include a bloodless operating field, minimal swelling, scarring, and much less or no postsurgical pain.[5-8]

Due to its characteristics, as well as to other known advantages, the diode laser has been compared to the other conventional methods. It has been subject of a diversity of studies intended to evaluate its potential in relation to its biocompatibility.

Diode lasers have opened up a new age as an alternative to conventional blade scalpel in oral and maxillofacial surgery. As well as being selective, the incision performed through lasers maximizes surgical precision, resulting in minimal damage to soft tissue. In addition, a blood less surgical site provides maximum intraoperative visibility.[9-14]

Few studies compared**,** diode lasers with the conventional scalpel blade surgical technique and found that pain, swelling, trismus and incidence of dry docket were significantly decreased in the laser group patients but patients undergoing surgery with lasers experienced longer surgery time whereas significantly shorter time with conventional techniques.[15-19]

Aim

The study aims to compare the surgical outcome using diode laser with conventional scalpel blade for soft tissue management during surgical removal of impacted mandibular third molars.

MATERIALS AND METHODS

Local anesthesia with adrenaline in 1:200,000 will be administered by the inferior alveolar, lingual and long buccal nerve blocks.

Appropriate incision will be taken in conventional group by scalpel blade on one side of the jaw and in study group by diode laser on other side of the jaw and flap reflected. Impacted tooth will be surgically exposed. Straight handpiece will be used at 35,000 rpm for trephination and guttering at the buccal or distal aspect of the tooth, or both. A straight fissure bur will be used to section the tooth when needed. At all times cutting of bone and tooth will be accompanied by copious irrigation with saline solution. Tooth extracted by help of an appropriate forceps or luxator. Extraction socket irrigated and fresh bleeding induced. Flap will be sutured with non-resorbable (3-0) silk suture. Antibiotics and analgesics will be given in regular fashion. Patient will be recalled after 2 weeks for removal of the impacted tooth on the contra-lateral side.

RESULTS

A total of 15 patients with symmetrical bilateral impacted mandibular third molars requiring surgical removal were incorporated in the present study.

Various criteria's viz, ease of incision (Duration of the Surgery and Bleeding from Soft tissue), pain, swelling, trismus, and incidence of dry socket were assessed using statistical analysis through SPSS version 23. Descriptive statistics, Paired *t*-test was done for intergroup comparison at different time intervals and Independent *t*-test was done for intergroup comparison at different intervals.

Ease of Incision

Duration of surgery

Average duration of the surgery in control group (Group 1 = Conventional Group) mean 21.32 ± 9.02 and study group (Group 2 = Diode Laser) mean was 44.84 ± 10.54.

Inference: There is statistically highly significant difference present between both the groups ($P < 0.001$)

Bleeding from soft tissue

Average bleeding from bone in control group (Group 1 = Conventional Group) mean 4.60 ± 0.56 and study group (Group 2 = Diode Laser) mean was 2.52 ± 0.51.

PAIN (VISUAL ANALOGUE SCALE [VAS])

Average pain in control group (Group 1 = Conventional Group) mean on 3rd day was 3.68 ± 1.6, 5th day 1.68 ± 1.7, 7th day 0.32 ± 0.74, 15th day 0.00 ± 0.00 and study group (Group 2 = Diode Laser) mean on 3rd day was 1.60

Table 1: Intergroup comparison of duration of procedure

Parameter	n	Group 1		Group 2		Mean difference	*P* value
		Mean	SD	Mean	SD		
Duration	25	21.32	9.02	44.84	10.54	−23.52	<0.001**

**-Highly significant (*P*<0.001)

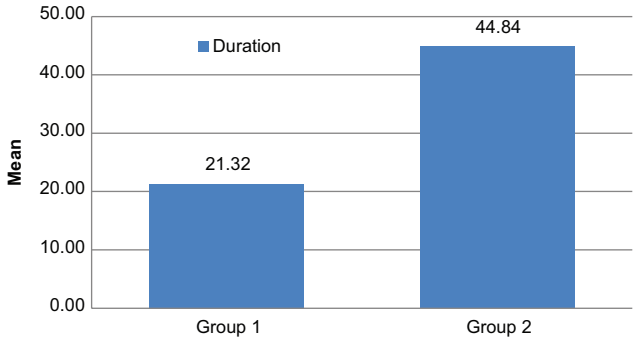

± 1.41, 5th day 0.48 ± 0.87, 7th day 0.00 ± 0.00, 15th day 0.00 ± 0.00.

Swelling (Digital Caliper/Manual Measuring Tape)

Average comparison of swelling in control group (Group 1 = Conventional Group) from lateral canthus of the eye to gonion (LCG) mean on 3rd day was 10.65 ± 1.22, 5th day 11.79 ± 0.73, 7th day 10.43 ± 1.44, 15th day 8.87 ± 1.19 and study group (Group 2 = Diode Laser) swelling measured from lateral canthus of the eye to gonion mean on 3rd day was 9.58 ± 1.07, 5th day 9.46 ± 0.96, 7th day 9.82 ± 1.25, 15th day 9.02 ± 1.13.

There is statistically significant difference present in mean distance from lateral canthus of eye to gonion in both the groups postoperatively at day 3, 5 with less swelling in Group 2 postoperatively when compared between both groups ($P < 0.05$), and statistically non-significant when compared between pre-operative, 7th day and 15th day ($P > 0.05$).

Average comparison of swelling in control group (Group 1 = Conventional Group) measuring from tragus to corner of the mouth (TM) mean on 3rd day was 13.16 ± 1.79, 5th day 14.47 ± 1.41, 7th day 13.64 ± 1.45, 15th day 11.89 ± 0.63 and study group (Group 2=Diode Laser) swelling measuring from tragus to corner of the mouth (TM) mean on 3rd day was 11.75 ± 1.02, 5th day 12.67 ± 1.04, 7th day 11.77 ± 0.74, 15th day 11.32 ± 1.18.

There is statistically highly significant difference present in mean distance from tragus to corner of the mouth in both the groups postoperatively at day 5 and 7 ($P < 0.001$) while statistically significant day 3 and 15 ($P < 0.05$) with less swelling in Group 2 postoperatively when compared between both the groups.

Table 2: Intergroup comparison bleeding index

Parameter	*n*	Group 1		Group 2		Mean Difference	*P* value
		Mean	SD	Mean	SD		
Bleeding index	25	4.60	0.56	2.52	0.51	2.08	<0.001**

**-Highly significant (*P*<0.001). Inference: There is statistically highly significant difference present between both groups in terms of bleeding from bone index

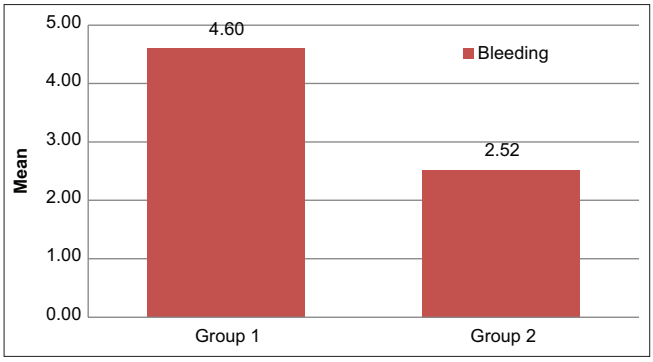

Average comparison of swelling in control group (Group 1=Conventional Group) measuring from tragus to pogonion (TP) mean on 3rd day was 16.07 ± 1.02, 5th day 17.33 ± 1.43, 7th day 15.41 ± 0.94, 15th day 14.59 ± 1.68 and study group (Group 2=Peizosurgery) swelling measuring from TP mean on 3rd day was 15.40 ± 0.86, 5th day 15.50 ± 2.16, 7th day 15.45 ± 1.40, 15th day 14.82 ± 1.60.

There is statistically highly significant difference present in mean distance from TP between both the groups postoperatively at day 7 ($P < 0.001$), statistically significant difference present on post-operative day 3 ($P < 0.05$) while nonsignificance difference seen on comparison of pre-operative day and day 7, 15 ($P > 0.05$) with less swelling in Group 2 postoperatively when compared between both the groups.

Trismus (Mouth Opening- Inter Incisal Distance)

Average comparison of Trismus (mouth opening) in control group (Group 1=Conventional Group) mean on 3rd day was 18.24 ± 4.59, 5th day 25.16 ± 4.54, 7th day 32.56 ± 5.01, 15th day 41.72 ± 3.48 and study group (Group 2 = Diode Laser) Trismus (mouth opening) mean on 3rd day was 28.80 ± 6.21, 5th day 35.48 ± 4.64, 7th day 40.52 ± 4.13, 15th day 41.88 ± 3.56.

There is statistically highly significant difference present in mean mouth opening on day 3, 5, 7 ($P < 0.001$) and nonsignificant difference seen on preoperative and day 15 postoperatively ($P > 0.05$) when compare between both groups [Tables 1-8].

DISCUSSION

An impacted tooth is one which is completely or partially unerupted and is positioned against another tooth, bone, or soft tissue so that its further eruption is unlikely described according to anatomic position. Among the human dentition mandibular third molar is the second most common tooth to be impacted, next to maxillary third molar.[20-24]

Impacted teeth are held responsible for spectrum of pathologies ranging from simple periodontal defects posterior to the second molar to odontogenic cysts and tumors, including caries in the second and third molars, pericoronitis, neurogenic pain, crowding of the dentition. Therapeutic or prophylactic indications make the surgical removal of the impacted third molar a commonest procedure performed in private Dental clinics, Dental colleges, or Hospital setting by an Oral and Maxillofacial Surgeon.

Some of the most frequent complaints following third molar surgery are pain, swelling and trismus. Few authors found that trismus and swelling are closely associated with acute inflammation following third molar surgery. Inferior

Table 3: Intragroup comparison of pain at various durations

Group	Parameter	Duration	Mean	*n*	std. deviation	Std. error mean	Mean difference	*P* value
Group 1	Pain	3rd day	3.68	25	1.6000	0.3200	2.0000	<0.001**
		5th day	1.68	25	1.7010	0.3402		
	Pain	3rd day	3.68	25	1.6000	0.3200	3.3600	<0.001**
		7th day	0.32	25	0.7483	0.1497		
	Pain	3rd day	3.68	25	1.6000	0.3200	3.6800	<0.001**
		15th day	0.00	25	0.0000	0.0000		
Group 2	Pain	3rd day	1.60	25	1.4142	0.2828	1.1200	<0.001**
		5th day	0.48	25	0.8718	0.1744		
	Pain	3rd day	1.60	25	1.4142	0.2828	1.6000	<0.001**
		7th day	0.00	25	0.0000	0.0000		
	Pain	3rd day	1.60	25	1.4142	0.2828	1.6000	<0.001**
		15th day	0.00	25	0.0000	0.0000		

**-Highly significant (*P*<0.001). Inference: There is statistically highly significant difference present in pain intensity at various durations. Group 2 has lower pain intensity in all durations than in Group 1

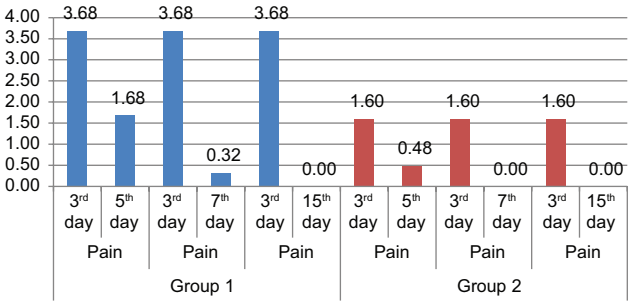

Table 4: Intergroup comparison of swelling distance between lateral canthus of eye to gonion (LCG)

Duration	Group	*n*	Mean	Std. deviation	Std. error mean	Mean difference	*P* value
Pre op	Group 1	25	8.61	1.1543	0.2309	0.0000	1 NS
	Group 2	25	8.61	1.1543	0.2309		
Day 3	Group 1	25	10.66	1.22582	0.24516	1.08200	0.002*
	Group 2	25	9.58	1.07714	0.21543		
Day 5	Group 1	25	11.79	0.73899	0.14780	2.33000	<0.001**
	Group 2	25	9.46	0.96195	0.19239		
Day 7	Group 1	25	10.43	1.4409	0.2882	0.6080	0.118 NS
	Group 2	25	9.82	1.2563	0.2513		
Day 15	Group 1	25	8.87	1.19442	0.23888	−0.15400	0.642 NS
	Group 2	25	9.02	1.13331	0.22666		

NS: Not significant (*P*>0.05),**-Highly significant (P<0.001), *-Significant (*P*<0.05)

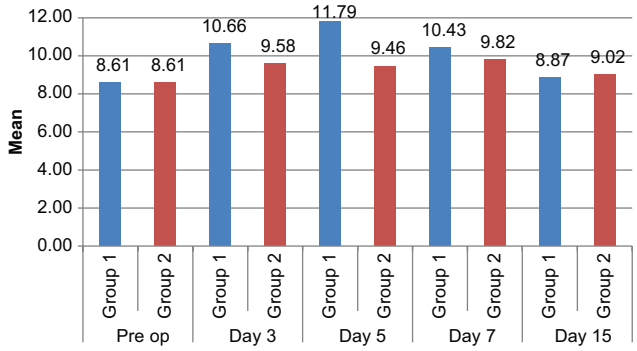

alveolar nerve injury is a well-documented complication of maxillofacial procedures viz. third molar surgery. Several therapeutic protocols have been evaluated to support improvements in the post-operative sequelae.[25-29]

Morbidity following surgery of lower third molar is always unpredictable and remains a greater concern to surgeon in the post-operative period. Surgical procedures may produce severe post-operative pain, edema, trismus, development of

Table 5: Intergroup comparison of distance between tragus of ear to corner of the mouth

Duration	Group	*n*	Mean	Std. deviation	Std. error mean	Mean difference	*P* value
Pre op	Group 1	25	11.6584	0.65084	0.13017	0.00000	1 NS
	Group 2	25	11.6584	0.65084	0.13017		
Day 3	Group 1	25	13.1636	1.79630	0.35926	1.40520	0.001*
	Group 2	25	11.7584	1.02945	0.20589		
Day 5	Group 1	25	14.4796	1.41465	0.28293	1.80000	<0.001**
	Group 2	25	12.6796	1.04143	0.20829		
Day 7	Group 1	25	13.6476	1.45710	0.29142	1.87560	<0.001**
	Group 2	25	11.7720	0.74471	0.14894		
Day 15	Group 1	25	11.892	0.6383	0.1277	0.5680	0.040*
	Group 2	25	11.324	1.1844	0.2369		

NS: Not significant (*P*>0.05),**-Highly significant (*P*<0.001), *-Significant (*P*<0.05)

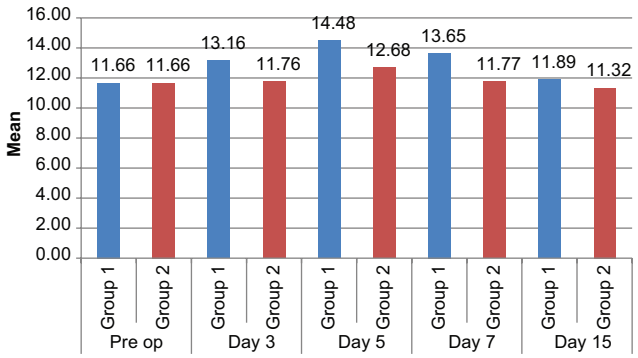

Table 6: Intergroup comparison of distance between tragus to pogonion

Duration	Group	*n*	Mean	Std. deviation	Std. error mean	Mean difference	*P* value
Pre op	Group 1	25	14.3316	1.58326	0.31665	0.00000	1 NS
	Group 2	25	14.3316	1.58326	0.31665		
Day 3	Group 1	25	16.0732	1.02815	0.20563	0.66880	0.016*
	Group 2	25	15.4044	0.86102	0.17220		
Day 5	Group 1	25	17.332	1.4300	0.2860	1.8320	0.001**
	Group 2	25	15.500	2.1645	0.4329		
Day 7	Group 1	25	15.412	0.9479	0.1896	−0.0400	0.906 NS
	Group 2	25	15.452	1.4036	0.2807		
Day 15	Group 1	25	14.5924	1.68965	0.33793	−0.23560	0.616 NS
	Group 2	25	14.8280	1.60503	0.32101		

NS: Not significant (*P*>0.05), *Significant (*P*<0.05), **Highly significant (*P*<0.001)

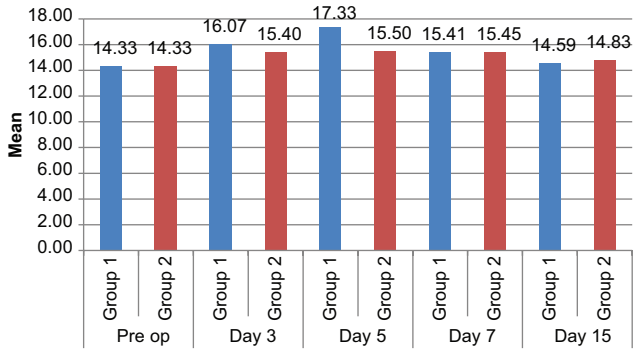

infections, dry socket, periodontal defects posterior to the second molar and other possible potential complications like temporomandibular joint dysfunction.

An otherwise uncomplicated surgical procedure will inflict surgical trauma which initiates a local inflammatory response. Inflammation commences the wound healing

Table 7: Intergroup comparison of mean mouth opening

Duration	Group	*n*	Mean	Std. deviation	Std. error mean	Mean difference	*P* value
Pre Op	Group 1	25	39.52	5.1730	1.0346	−0.0400	0.979 NS
	Group 2	25	39.56	5.3235	1.0647		
Day 3	Group 1	25	18.24	4.5942	0.9188	−10.5600	<0.001**
	Group 2	25	28.80	6.2183	1.2437		
Day 5	Group 1	25	25.16	4.5431	0.9086	−10.3200	<0.001**
	Group 2	25	35.48	4.6469	0.9294		
Day 7	Group 1	25	32.56	5.0173	1.0035	−7.9600	<0.001**
	Group 2	25	40.52	4.1344	0.8269		
Day 15	Group 1	25	41.72	3.4823	0.6965	−0.1600	0.873 NS
	Group 2	25	41.88	3.5628	0.7126		

NS: Not significant (*P*>0.05),** Highly significant (*P*<0.001)

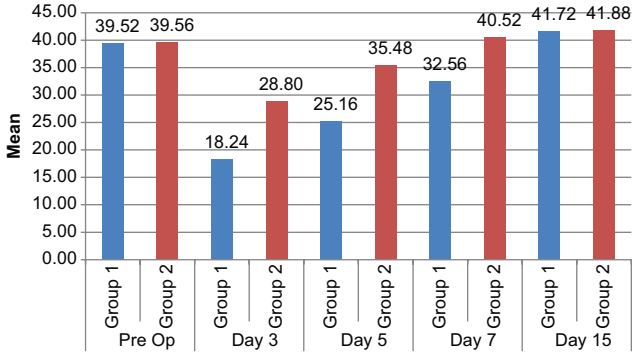

Table 8: Intergroup comparison of incidence of dry socket

Duration	Group 1	Group 2
3rd day	2	0
5th day	2	0
7th day	0	0
15th day	0	0

Inference: There is statistically non significance difference among both groups in relation to incidence of dry socket at different post-operative interval in group 1 3rd day (4%), 5th day (4%), and 7th day (0%), 15th day (0%) compared to group 2 (0%) at different post-operative interval

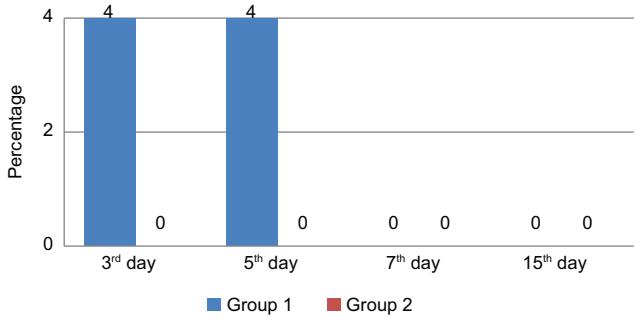

processes and protects the damaged tissues from the exposed environment. The product of inflammation is exudate which is a result of vascular changes and constituent of intravascular components, cellular elements and various growth factors, swept into the intercellular spaces. The clinical manifestation of this inflammatory process is swelling and pain in the operated region.

Trismus is due to inflammation around the masseter muscle, which is objectively seen as decrease in the inter-incisal distance. Amount of inflammation developed will govern the post-operative swelling, pain and trismus and is the index of surgical trauma inflicted to the tissue, so these parameters are taken into methodology of this study.

Pain and swelling are individual dependent variables correlated to body's response to tissue insult and type of wound. The severity and perception of pain might vary among individuals. Risk of error is present when later factors are compared in different individuals. The present study is of a split-mouth study design so that the subjects themselves will act as controls. The intensity of the inflammatory reaction depends on severity of tissue trauma, to avoid errors within the study, bilaterally symmetrical type of impacted mandibular third molar teeth, as assessed by radiographs, were considered. This study was aimed at evaluating the efficacy of two surgical techniques, one is the conventional scalpel blade instrument and another is diode laser device in surgical removal of impacted teeth. The surgical method should be one with minimum intraoperative and post-operative complications.

Diode lasers come in different wavelengths of 810, 940, and 980nm, and have become very popular in general dentistry because of their compact size, fiber-optic delivery, and ease of use for minor surgery of oral soft tissues. The energy from these lasers target pigments such as hemoglobin and melanin in the soft tissue.

The present study was done to compare soft tissue incision with diode laser and conventional scalpel blade in surgical removal of impacted mandibular third molar teeth. A study sample of 15 patients was selected, of which 8 were males and 7 females with mean age of 26 years and ranged from 18 to 40 years. Parameters taken for the study to achieve the aim are ease of incision making (duration of surgery, bleeding), pain (VAS), swelling, trismus, and incidence of dry socket.

Time taken for the operative procedure is the first parameter of the study and was recorded from the time of incision to last suture placed.

In our study, the mean of duration of surgery among conventional group (Group 1) was 21.32 ± 9.02 and study group (Group 2) mean was 44.84 ± 10.54. There is statistically highly significant difference present between both the groups ($P < 0.001$). It was found that diode laser group consumes more time for surgery as compared to conventional group

In our study, mean of bleeding from soft tissue among conventional group (Group 1) was 4.60 ± 0.56 and study group (Group 2) was 2.52 ± 0.51. There is statistically highly significant difference present between both the groups ($P < 0.001$). It was found that diode laser group has significantly less bleeding from tissue as compared to conventional group ($P < 0.001$).

Pain was second parameter of the present study. Level of pain was measured by asking the patients and was marked on a ten point VAS scoring scale.

In our study, on comparison of frequency of pain among conventional group and diode laser group using the VAS, it was found that in conventional group the mean on 3rd day was 3.68 ± 1.6, 5th day 1.68 ± 1.7, 7th day was 0.32 ± 0.74, 15th day was 0.00 ± 0.00 and study group mean on 3rd day was 1.60 ± 1.41, 5th day was 0.48 ± 0.87, 7th day was 0.00 ± 0.00, 15th day was 0.00 ± 0.00. As $P < 0.001$ which suggests statistically highly significant difference present in pain intensity at various durations. Group 2 has lower pain intensity in all durations than in Group 1.

Swelling is a clinical manifestation of the operative procedure because of the inflammatory exudate that had been escaped from the intravascular component. Cheek swelling was measured in three dimensions recorded from each patient, Tragus to Corner of the Mouth, TP and Corner of Eye to Soft tissue Gonion. These dimensions were recorded preoperatively and compared on the post-operative follow-up days.

In the present study, swelling parameter revealed statistically highly significant difference ($P < 0.001$) between the groups wherein diode laser group had lesser swelling compared to conventional group.

Trismus is the fourth parameter in this study which is inability to open the mouth following the surgical removal of impacted third molar and is due to the inflammation around the masseter muscle which produces this clinical manifestation.

In the present study, there is statistically highly significant difference present in mean mouth opening on day 3, 5, 7 ($P < 0.001$) and nonsignificant difference seen on day 15 postoperatively ($P > 0.05$) when compared between both groups.

In the present study, incidence of dry socket is the last parameter which is statistically non significance difference among both groups in relation to incidence of dry socket at different post-operative interval in group 1 3rd day (4%), 5th day (4%), and 7th day (0%), 15th day (0%) compared to group 2 (0%) at different post-operative interval.

The main results of our study were that the laser assisted surgery resulted in significant improvement in reducing swelling and pain and in reduction of dry socket incidence in the immediate postoperative period compared with control group. The response rate to the study was high, indicating the high feasibility of using patient-centered outcome measures in oral surgery.[30-34]

The use of diode laser has predictable results in oral surgery with certain advantages such as, ease of application, adequate coagulation, less inflammation and pain, better repair and recovery of tissues and rare intra- and post-operative complications. Our study revealed that it is an effective and predictable tool when performing surgeries in oral soft tissues, superior to the conventional scalpel blade with few limitations including longer duration of surgery and high cost. However, further comparative studies are needed with more number of samples to assess the efficacy.[35-38]

CONCLUSION

The diode laser as a modern therapeutic method proved to be a simple, elegant, and clean way for surgery with

minimum bleeding. It is far gentler than scalpel surgery; unlike electro surgery lasers do not require the placement of a grounding plate. Tissue separates gently and easily with the laser and hemostasis is achieved rapidly and there was minimal post-operative sequale and complications. Diode laser was well tolerated by the patients, and it is more successful than conventional treatment methods. Therefore, diode lasers treatment can form an integral part of oral surgery therapy in the future. However, further longitudinal studies are required to evaluate the long-term effects of diode laser on clinical as well as microbiological parameters.

REFERENCES

1. Archer WH. Textbook of Oral and Maxillofacial Surgery. 4th ed. Philadelphia, PA: WB Saunders; 1966. p. 250-390.
2. Andresasen JO. Textbook and Color Atlas of Tooth Imapctions Treatment Strategies for Eruption Disturbances. 1st ed. Mucks, Philadelphia, PA: Mosby; 1997. p. 66-93.
3. Ailing CC, Helfrick JF, Alling RD. Impacted Teeth the Pathology of Impacted Teeth. 1st ed. Philadelphia, PA: WB Saunders; 1993. p. 1-24.
4. Anderson L, Kahnberg KE, Pogrel MA. Oral and Maxillofacial Surgery current Concepts and Strategies for Third Molar Removal. 1st ed. Oxford: Wiley-Blackwell; 2010. p. 195-215.
5. Ruta DA, Bissias E, Osgston S, Ogden GR. Assessing health outcome after extraction of third molars: The postoperative symptom severity (PoSSe). Br J Oral Maxillofac Surg 2000;38:480-7.
6. Srinivas M, Dodson TB. Estimating third molar extraction difficulty: A comparison of subjective and objective factors. J Oral Maxillofac 2005;63:427-34.
7. Howe GL. Minor Oral Surgery Geoffrey. 3rd ed. Oxford: Butterworth-Heinemann Ltd.;1996. p. 109-43.
8. Carvalho RW, do Egito Vasconcelos BC. Assessment of factors associated with surgical difficulty during removal of impacted lower third molar extraction. J Oral Maxillofac Surg 2011;69:2714-1.
9. Linden WV, Cleaton JP, Lownie M, Hons BA. Diseases and lesions associated with third molars review of 1001 cases. Oral Surg Oral Med Oral Pathol Oral Radiol Endod 1995;79:142-5.
10. Chiapasco M, Crescentini M, Romanoni G. Germectomy or delayed removal of mandibular impacted third molar: The relationship between age and incidence of complications. J Oral Maxillofac Surg 1995;53:418-22.
11. Rakprasitkul S, Pairuchvej V. Mandibular third molar surgery with primary closure and tube drain. Int J Oral Maxillofac Surg 1997;26:187-90.
12. Garcia AG, Sasmpedro FG, Rey JG, Torreira MG. Trismus and pain after removal of impacted lower third molars. J Oral Maxillofac Surg 1997;55:1223-6.
13. Give O, Keskin A, Akal WK. The incidence of cysts and tumours around impacted third molars. Int J Oral Maxillofac Surg 2000;29:131-5.
14. Gulicher D, Gerlach KL. Sensory impairment of the lingual and inferior alveolar nerves following removal of impacted mandibular third molar. Int J Oral Maxillofac Surg 2001;30:306-12.
15. Benedoktsdottir IS, Wnezel A, Petersen JK, Hintze H. Mandibular third molar removal: Risk indicators for extended operation time, postoperative pain, and complications. Oral Surg Oral Med Oral Pathol Oral Radiol Endod 2004;97:438-46.
16. Yuasa H. Sugiura M. Clinical postoperative findings after removal of impacted mandibular third molars: Predication of postoperative facial swelling and pain based on preoperaltive variables. Br J Oral Maxillofac Surg 2004;42:209-14.
17. Sulieman MS. Clinical evaluation of the effect of four flap designs on the postoperative sequel (pain, swelling and trismus) following lower third molar surgery. AI-Rafidain Dent J 2005;5:24-32.
18. Pasqualini D, Cocero N, Castellan A, Mela L, Bracco P. Primary and secondary closure of the surgical wound after removal of impacted mandibular third molars: A comparative study Int. J. Oral maxillofac Surg 2005;34:52-7.
19. Wermeister R, Fillies T, Joos U, Smolka K. Relationship between lower wisdom tooth position and cyst development, deep abscess formation and mandibular angle fracture. J Craniomaxillofac Surg 2005;33:164-8.
20. Gomes AC, Vasconcelos BC, Silva ED, Silva LC. Lingual nerve damage after mandibular third molar surgery: A randomized clinical trial. J Oral Maxillofac Surg 2005;63:1443-6.
21. Adeyemo WL. Do pathologies associated with impacted impacted lower third molars justify prophylactic removal? A critical review of the literature. Oral Surg Oral Med Oral Radiol Endod 2006;102:448-52.
22. Karaca I, Simsek S. Ugar D, Bozkaya S. Review of flap design influence on the health of the periodontium after third molar surgery. Oral surg Oral Med Oral Pathol Oral Radio Endod 2007;104:18-23.
23. Almendros MN, Aejos AE, Quinteros B, Berini L, Escoda G. Factors influencing the prophylactic removal of asymptomatic impacted lower third molars. Int J Oral Maxillofac Surg 2008;37:29-35.
24. Polat BH, Ozan F, Kara I, Ozdemir H. Prevalence of commonly found pathoses associated with mandibular impacted third molars based on panoramic radiographs in Turkish population. Oral Surg Oral Med Oral Pathol Oral Radiol Endod 2008;105;e41-7.
25. Schutz S, Egger J, Kuhl S, Filippi A. Intraosseous temperature changes during the use of piezosurgical inserts *in vitro*. Int J Oral Maxillofac Surg 2012;41:1338-43.
26. Oikarinen K, Rasanen A. Complications of third molar surgery among university students. J Am Coll Health 1991;39:281-5.
27. Kim J, Choi S, Wang S, Kim S. Minor complications after mandibular third molar surgery: Type, incidence and possible prevention. Oral Surg Oral Med Oral Pathol Oral Radiol Endod 2005;102:4-11.
28. Fisher SE, Frame JW, Rout PG, Centegart DJ. Factors affecting the onset and severity of pain following the surgical removal of unilateral impacted mandibular third molar teeth. Br Dent J 1988;164:351-3.
29. Genu PR, Vasconcelos CE. Influence of the tooth section technique in alveolar nerve damage after surgery of impacted lower third molars. Int J Oral Maxillofac Surg 2008;37:933-28.
30. Sabra SM. Laser-aided for pericoronal bacterial load reduction and operculectomy healing of impacted mandibular molar, Taif, KSA. World Appl Sci J 2014;29:1-8.
31. Amid R, Kadkhodazadeh M, Talebi MR, Hemmatzadeh S, Refoua S, Iranparvar P, *et al*. Using diode laser for soft tissue incision of oral cavity. J Lasers Med Sci 2012;3:36-43.
32. Sagar K, Kaur A, Patel P, Kumar V, Narang S, Ranga P. Diode laser as an established tool in periodontics a review. Am J Oral Med Radiol 2015;2:54-60.
33. Golti SI, Vilardi MA. Pulsed laser beam effects on gingiva. J Clin Periodontol 1994;21:391-6.
34. Eshghpour M, Moradi A, Nejat AH. Dry socket following tooth extraction in an Iranian dental center: Incidence and risk factors. J Dent Mater Tech 2013;2:86-91.
35. Azma E, Safavi N. Diode laser application in soft tissue oral surgery. J Lasers Med Sci 2013;4:206-11.
36. Soliman MM, Sabra SM. The use of laser as a treatment modality for treatment of impacted mandibular wisdom among patients of Taif University KSA. IOSR J Dent Med Sci 2014;13:67-75.
37. Ortega-Concepción D, Cano-Durán JA, Peña-Cardelles JF, Paredes- Rodríguez VM, González-Serrano J, López-Quiles J. The application of diode laser in the treatment of oral soft tissues lesions. A literature review. J Clin Exp Dent 2017;9:e925-8.
38. Malik R, Chatra LK. Lasers an inevitable tool in modern dentistry: An overview. J Indian Acad Oral Med Radiol 2011;23:603-8.

How to cite this article: Katariya S, Halli R, Khandelwal S. Comparative Evaluation of Post-operative Sequelae using Diode Laser and Conventional Scalpel Blade for Soft Tissue Incision in Impacted Mandibular Third Molar Surgery- A Prospective Split Mouth Study. Int J Sci Stud 2021;9(9):26-33.

Source of Support: Nil, **Conflicts of Interest:** None declared.

Print ISSN: 2321-6379
Online ISSN: 2321-595X

Original Article

A Study of Phenylephrine versus Mephentermine during Subarachnoid Block for Cesarean Section

Sugatha Prakash[1], Xavier John[2]

[1]Professor, Department of Anaesthesia, Jubilee Mission Medical College and Research Institute, Thrissur, Kerala, India, [2]Junior Resident, Department of Anaesthesiology, Jubilee Mission Medical College and Research Institute, Thrissur, Kerala, India

Abstract

Introduction: Subarachnoid block for cesarean section can cause hypotension. In this study, we compared the effect of bolus dose of mephentermine and phenylephrine on maternal hemodynamics and neonatal outcome in patients undergoing cesarean section under subarachnoid block.

Materials and Methods: After approval from the Institutional Ethics Committee, 100 American Society of Anesthesiologists I and II patients, scheduled for elective cesarean section and who developed hypotension after subarachnoid block, were included in the study. The patients were randomized into two groups, Group M receiving inj. mephentermine 3 mg intravenously and Group P receiving inj. phenylephrine 50 mcg intravenously. Subarachnoid block was given using 2 ml of 0.5% heavy bupivacaine. Blood pressure was recorded every 2 min for 30 min, every 5 min for the next 30 min, and then every 15 min for the next 30 min. The time of hypotension was recorded and the vasopressor administered. Apgar scores at 1 min and 5 min and umbilical artery blood gas analysis were obtained after the delivery of the baby.

Results: The systolic blood pressure (SBP) at 2, 4, 6, 8, and 10 min after the administration of the drug was significant in both the groups ($P < 0.001$) when compared with the hypotensive value. The SBP was higher in phenylephrine group when compared to the mephentermine group up to 4 min after administration of the vasopressors ($P < 0.05$). The diastolic blood pressure was significantly higher in phenylephrine group occurring soon after the administration of the drug when compared to mephentermine group ($P < 0.05$). Apgar scores and umbilical arterial blood gas analysis of the newborn were comparable between the two groups.

Conclusion: Both phenylephrine and mephentermine maintained the SBP within 20% limit of baseline. Phenylephrine had a quicker peak effect. Neurobehavioral outcome in the neonate was comparable in both groups.

Key words: Cesarean section, Hypotension, Vasopressors

INTRODUCTION

With advancements in anesthetic techniques and better fetal monitoring systems, the anesthesiologists can now choose the best possible anesthetic technique for the parturient. Among the anesthetic techniques used for cesarean section, neuraxial anesthesia is preferred.[1] Subarachnoid block provides complete sensory and motor blockade, avoids the risk of pulmonary aspiration of gastric contents and the depressant effect of drugs on fetus associated with general anesthesia. However, there is a reported incidence of 76% of maternal hypotension.[2] This can have adverse effects both in the neonate and mother.

Access this article online

www.ijss-sn.com

Month of Submission : 10-2021
Month of Peer Review : 11-2021
Month of Acceptance : 11-2021
Month of Publishing : 12-2021

In the neonate fetal hypoxia, acidosis and neurological deficits due to decreased placental perfusion can occur. Hypotension can also result in maternal nausea, vomiting, and dizziness and, if severe, could result in loss of consciousness and sudden cardiac arrest.

Along with the left uterine displacement, Trendelenburg position, leg compression, and fluid coloading, administration of vasoconstrictors is used to offset maternal hypotension.[3-5] Phenylephrine has emerged a favorable vasopressor in recent times as it increases the maternal blood pressure by peripheral vasoconstriction. Phenylephrine has been associated with maternal bradycardia. Mephentermine has both direct and indirect sympathomimetic action and

Corresponding Author: Dr. Sugatha Prakash, AG 35. Alukkas Gardens, Nellikunnu, Thrissur, Kerala, India.

increases the maternal blood pressure by increasing the cardiac output. In our study, we compared the effects of bolus dosage of phenylephrine and mephentermine used to treat hypotension following spinal anesthesia in cesarean section patients. The effect of phenylephrine and mephentermine 3 mg on the maternal hemodynamics and neurobehavioral outcome in the newborn was studied.

MATERIALS AND METHODS

This randomized prospective study was carried out at Jubilee Mission Medical College, Thrissur, Kerala, India, between June 2014 and January 2016. After obtaining approval from the Institution Ethical Committee, singleton full-term pregnant women, aged 20–35 years, scheduled for elective cesarean section under spinal anesthesia and who developed hypotension after subarachnoid block, were taken for the study. Inclusion criteria were American Society of Anesthesiologists physical status 1 and 2, baseline systolic blood pressure (SBP) between 100 and 140 mmHg, diastolic blood pressure (DBP) between 70–89 mmHg, and a sensory block at T6 level. Patients with pre-term and post-term pregnancies, multiple pregnancies, diagnosed placental abnormalities, preeclampsia and eclampsia, hemoglobinopathies, coexisting neurologic, cardiopulmonary, cerebrovascular, renal, metabolic, and psychiatric disorders were excluded from the study. Pre-anesthetic evaluation was done and informed consent was taken. Hundred patients were allotted to two groups by consecutive sampling. Group M ($n = 50$) received injection mephentermine 3 mg intravenously and Group P ($n = 50$) received injection phenylephrine 50 mcg intravenously. Hypotension was defined as fall in SBP >20% from the baseline value or a value <90 mmHg. Bradycardia was defined as heart rate (HR) between 50 and 60 beats/min for fall in SBP >20% from baseline value, HR between 45 and 50 beats/min when SBP is above baseline value or HR <45 beats/min whatever be the SBP.

The patients were given oral ranitidine 150 mg the night before and the morning of the surgery. An 18G IV cannula was placed in the forearm under aseptic precautions. Pulse oximeter probe, electrocardiogram electrodes, and automated non-invasive blood pressure cuff were attached and all readings were taken before starting surgery. Subarachnoid block was given in the left lateral position using a fixed volume 2 ml of 0.5% heavy bupivacaine at L3-L4 or L2-L3 interspinous space using a 25G Quincke needle. The patient was coloaded with the recommended dose of 20 ml/kg of intravenous crystalloids over 10 min. A 15° wedge was placed under the right flank to provide left uterine displacement. Oxygen was administered at 3 L/min by a face mask. The level of sensory block was assessed by loss of cold sensation 5 min after spinal anesthesia. SBP and DBP were noted every 2 min after administration of spinal anesthesia till 30 min, every 5 min for the next 30 min, and then every 15 min for the next 30 min. HR and any cardiac rhythm disorders were monitored using Lead II. When the patient developed hypotension, she was given phenylephrine 50 mcg or mephentermine 3 mg, depending on the group, she was allotted. Time from intrathecal administration of bupivacaine to the development of hypotension (t_0) was noted. Time to delivery of baby after intrathecal bupivacaine and duration of surgery were also noted. Time of first dose of the vasopressor and number of subsequent doses were recorded. Bradycardia was treated with bolus IV atropine 0.6 mg. Nausea and vomiting was assessed by nausea vomiting score. Episodes of nausea and vomiting were noted and treated with IV ondansetron 4 mg. Neonatal cord blood from umbilical artery was obtained for analysis at the time of cutting of the cord. The cord was double clamped and umbilical artery blood gas analysis was done immediately. Apgar score for neurobehavioral assessment was noted at 1 min and 5 min of delivery.

The results on continuous measurements were presented on Mean ± standard deviation (min-max) and results on categorical measurements were presented in number (%). Significance was assessed at 5% level of significance ($P < 0.05$).

Student's *t*-test (two tailed, unpaired) had been used to find the significance of study parameters between the two groups and Student's *t*-test (two tailed, paired) was used within each group. For all statistical tests, $P < 0.05$ was taken as statistically significant. For statistical analysis, SPSS version 22, Med Calc 9.0.1, Systat 12.0, and R environment ver. 3.2.2 had been used.

RESULTS

Both the groups were comparable in their mean age, body weight, height, and body mass index (BMI). The baseline parameters recorded were SBP, DBP, HR, mean arterial pressure (MAP), respiratory rate (RR), and SpO_2. These were comparable between the two groups with the difference in mean values being statistically not significant ($P > 0.05$) as analyzed by Student's unpaired *t*-test [Table 1].

The mean time in minutes of subarachnoid block to onset of hypotension (t_0) in Group M and Group P was 6.51 ± 2.32 and 5.92 ± 1.94, respectively ($P > 0.05$). There was no significant difference between the two groups. The SBP, DBP, and HR, at the time of hypotension, were not statistically different between the two groups ($P > 0.05$) as analyzed by Student's unpaired *t*-test [Table 2].

Table 1: Baseline HR (beats per min), SBP, DBP, MAP (mmHg), RR (rate/min), and SpO_2 (%)

Group	*n*	Mean	Std. deviation	Std. error mean	*t*-value	*P* value
HR (baseline)						
M	50	82.78	7.68	1.08	1.68	0.095
P	50	80.22	7.50	1.06		
SBP (baseline)						
M	50	118.64	10.06	1.42	-0.17	0.872
P	50	118.96	9.66	1.36		
DBP (baseline)						
M	50	74.66	4.21	0.59	-1.92	0.058
P	50	76.38	4.73	0.67		
MAP (baseline)						
M	50	89.32	5.49	0.77	-1.13	0.261
P	50	90.58	5.65	0.799		
RR (baseline)						
M	50	20.44	1.71	0.24	0.61	0.548
P	50	20.24	1.59	0.22		
SpO_2 (baseline)						
M	50	100.0	0.0	0.0		
P	50	100.0	0.0	0.0		

SBP: Systolic blood pressure, DBP: Diastolic blood pressure, HR: Heart rate, MAP: Mean arterial pressure, RR: Respiratory rate

Table 2: Variables at the time of hypotension (t_0)

Variable	Group	*n*	Mean	SD	Min	Max	*P* value
SAB to t_0	M	50	6.51	2.32	2	16	0.167
	P	50	5.92	1.94	2	6	
HR at t_0	M	50	91.68	8.78	78	112	0.057
	P	50	88.60	7.09	68	106	
SBP at t_0	M	50	92.36	7.45	80	110	0.876
	P	50	92.58	6.57	84	104	
DBP at t_0	M	50	59.32	4.99	50	69	0.120
	P	50	61.01	5.69	40	72	
MAP at t_0	M	50	69.83	5.21	60	80	0.103
	P	50	71.53	5.13	55	79	

SBP: Systolic blood pressure, DBP: Diastolic blood pressure, HR: Heart rate, MAP: Mean arterial pressure, RR: Respiratory rate

Intraoperative SBP (mmHg) in Groups M and P

Basal SBP in mephentermine group was 118.64 ± 10.06 and that in phenylephrine group was 118.96 ± 9.66. Similarly, SBP during hypotension was 92.36 ± 7.45 and 92.58 ± 6.57 in mephentermine group and phenylephrine group, respectively, which was found to be statistically comparable in both the groups ($P > 0.05$). In our study, both the vasopressors maintained the SBP within 20% limit of baseline value. The mean SBP at 2 min in mephentermine and phenylephrine group was 97.24 ± 7.81 and 102.90 ± 5.84, respectively, which was significant ($P < 0.05$). The mean SBP at 4 min in mephentermine and phenylephrine group was 97.42 ± 6.79 and 104 ± 6.97, respectively, which was significant ($P < 0.05$).

There was a significant difference in SBP between the two groups till 4 min after administration of the vasopressors ($P < 0.05$) with the SBP being higher in phenylephrine group when compared to the mephentermine group. From 6 min onwards, the SBP was comparable between the two groups ($P > 0.05$) as analyzed by Student's unpaired *t*-test.

Statistical analysis of difference in mean SBP at different time points within the group was done by Student's paired *t*-test. The SBP after the administration of the drug at 2, 4, 6, 8, and 10 min was compared with the hypotensive value (t_0) and was significant in both the groups ($P < 0.001$). Within Group M, the SBP at 2 min was not statistically significant to SBP at 4 min ($P > 0.05$). However, the SBP at 2 min was statistically significant to the SBP at 6 min ($P < 0.05$). Within Group P, the SBP at 2 min was statistically significant to SBP at 4 min and 6 min ($P < 0.05$) [Figure 1].

Intraoperative DBP (mmHg) in Groups M and P

The difference in mean DBP between the two groups was analyzed by Student's unpaired *t*-test. The mean DBP at the time of hypotension was statistically not significant between the two groups at 59.32 ± 4.99 and 61.00 ± 5.69 in mephentermine and phenylephrine group, respectively ($P > 005$). There was a significant difference between the two groups in mean DBP till 35 min after the administration of the drug ($P < 0.05$). The mean DBP was significantly higher in phenylephrine group compared to mephentermine group till 35 min after the administration of the vasopressor [Figure 2].

Intraoperative MAP (mmHg) in Groups M and P

The difference in mean MAP between the two groups was analyzed by Student's unpaired *t*-test and the mean MAP at the time of hypotension was statistically not significant between the two groups. The mean MAP at time of hypotension was 69.83 ± 5.21 and 71.53 ± 5.13 in mephentermine and phenylephrine group, respectively

($P > 0.05$). There was a significant difference between the two groups in mean MAP after the administration of the drug ($P < 0.05$). The mean MAP was significantly higher in the phenylephrine group compared to mephentermine group up to 28 min after the administration of the vasopressor [Figure 3].

Intraoperative HR (Beats/Min) in Groups M and P

The difference in mean HR between the two groups was analyzed by Student's unpaired *t*-test. The mean HR at the time of hypotension was statistically not significant between the two groups at 88.80 ± 8.42 and 85.64 ± 7.74 in mephentermine and phenylephrine group, respectively ($P > 0.05$). There was a significant difference between the two groups in mean HR after the administration of the drug. The mean HR was significantly higher in mephentermine group compared to phenylephrine group at all the time points after the administration of the vasopressor ($P < 0.05$) [Figure 4].

In Group P, 4 patients (8%) experienced bradycardia after administration of vasopressor and was given IV atropine 0.6 mg. Bradycardia was not associated with hypotension. In Group M, none of the patients had bradycardia.

Intraoperative RR (Rate/Min) in Groups M and P

There was no significant difference between the mean RR between the two groups after the administration of the vasopressor ($P > 0.05$) as analyzed by Student's unpaired *t*-test.

Number of boluses of drug in Groups M and P

The number of boluses of vasopressors required in the two groups was analyzed by Student's unpaired *t*-test. The mean number of boluses in Group M and Group P was 2.54 ± 0.813 and 2.08 ± 0.528, respectively ($P < 0.05$), showing a significant difference between the number of boluses of vasopressors required in the two groups, with Group M receiving more than Group P [Table 3].

In Group M, four patients developed nausea as per the nausea vomiting score [Table 4]. None of the patients in Group P developed nausea.

The subarachnoid block to baby delivery time in Group M and Group P was 14.02 ± 3.30 and 15.02 ± 2.13,

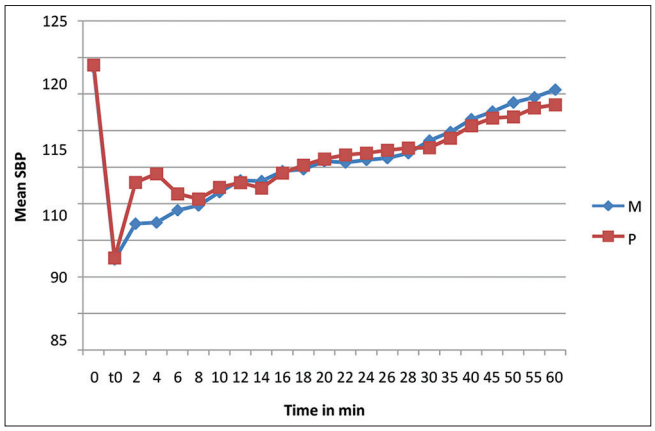

Figure 1: Intraoperative systolic blood pressure (mmHg) in Groups M and P

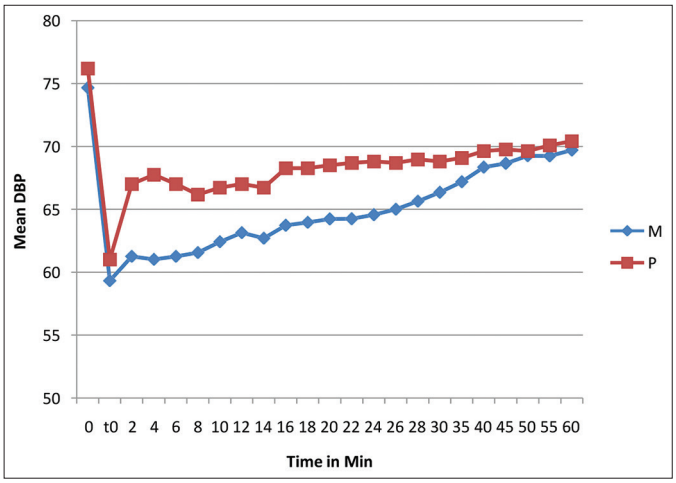

Figure 2: Intraoperative in diastolic blood pressure (mmHg) in Groups M and P

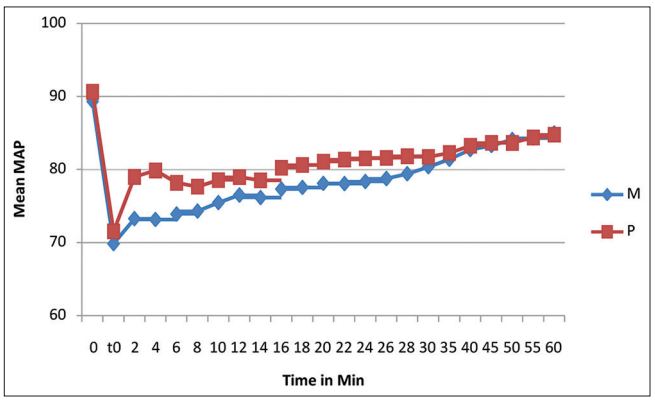

Figure 3: Intraoperative mean arterial pressure in Groups M and P

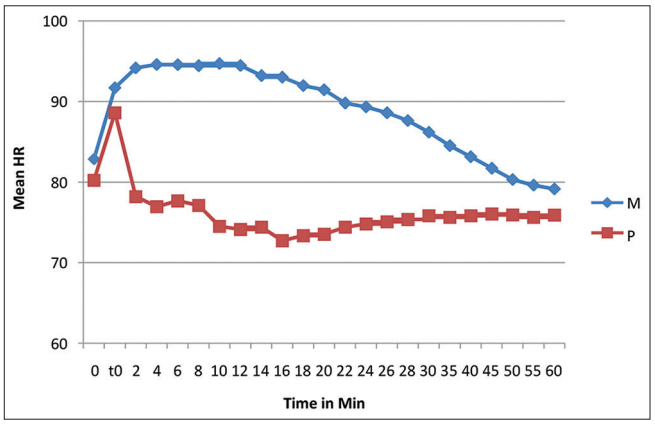

Figure 4: Intraoperative heart rate (beats per min) in Groups M and P

respectively ($P > 0.05$), which was comparable between the two groups as analyzed by Student's unpaired *t*-test.

Apgar score at 1 min and 5 min

The neonatal Apgar scores at 1 min and 5 min after delivery were comparable between the two groups ($P > 0.05$) by Student's unpaired *t*-test. The Apgar score was more than 8 in both groups at 1 min and 5 min after delivery of the baby [Figure 5].

Umbilical artery blood gas analysis

The umbilical artery blood gas analysis by Student's unpaired t-test showed comparable values of pH, PO_2, PCO_2, and HCO_3 [Table 5].

DISCUSSION

The incidence of hypotension has been shown to be higher in cesarean section done under spinal anesthesia.[6] Aortocaval compression and sympathetic blockade by the local anesthetic are the factors contributing to the higher incidence of hypotension in spinal anesthesia.[7] Sustained hypotension is deleterious for maternal and fetal well-being. Spinal anesthesia-induced sympathetic blockade will reduce the venous return to the heart and will affect the cardiac output producing hypotension. Severe hypotension will affect the uteroplacental blood flow. The umbilical artery blood pH and Apgar scores are good indicators of uteroplacental blood flow.

Various techniques have been adopted to counteract the effect of hypotension in the past. Early studies comparing preloading versus coloading by intravenous crystalloids have shown no significant advantage.[8-10] Lower limbs compression bandages were found to be of limited benefit. Hypotension has shown good response to vasopressors.[11]

The current study was conducted to compare the vasopressors, mephentermine and phenylephrine, for their efficacy to maintain maternal arterial blood pressure.

We compared the effect of bolus dosage of mephentermine and phenylephrine on maternal hemodynamics and fetal outcome. In this study, various demographic criteria and various parameters such as HR, SBP, DBP, MAP, SpO_2, RR, subarachnoid block to baby delivery time, Apgar scoring, and umbilical artery pH were compared among the two groups.

Demographic Data

In the present study, both the groups were comparable with respect to mean age (Group M 25.34 ± 3.11 and Group P 25.58 ± 2.84), mean height (Group M 156.82 ± 4.29 and Group P 157.88 ± 4.42), mean weight (Group M 61.34 ±3.98 and Group P 61.66 ± 4.26), and mean BMI (Group M 24.98 ± 1.95 and Group P 24.80 ± 2.28).

Baseline Parameters

The baseline HR, SBP, DBP, mean arterial blood pressure, RR, and peripheral oxygen saturation were comparable between the two groups ($P > 0.05$).

Subarachnoid block to baby delivery time was comparable between the two groups. The mean value of baby delivery time in Group M and Group P was 14.02 ± 3.30 and

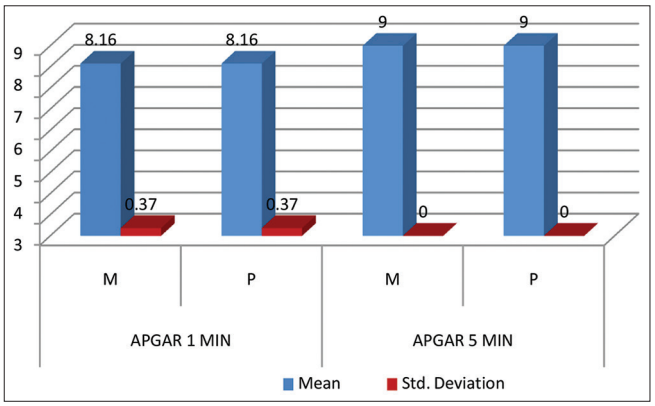

Figure 5: Apgar score at 1 min and 5 min in Groups M and P

Table 3: Number of boluses given in Groups M and P

Groups	*n*	Mean	Std. deviation	*t*-value	*P* value
No. of bolus					
M	50	2.54	0.813	3.35	0.0001
P	50	2.08	0.528		

Table 4: Nausea-vomiting score

Nausea-vomiting score			
Score 0	Score 1	Score 2	Score 3
No Nausea	Nausea	Retching or mild vomiting	Two or more vomiting episodes

Table 5: Umbilical artery blood gas analysis

Group	*n*	Mean	Std. deviation	*t*-value	*P* value
pH					
M	50	7.26	0.027		
P	50	7.26	0.021	-0.12	0.90
PO2					
M	50	17.37	2.085		
P	50	17.7	2.386	-0.72	0.47
HCO3					
M	50	20.84	1.351		
P	50	20.992	1.1248	-0.62	0.54
PCO2					
M	50	50.724	1.9910		
P	50	50.240	1.7207	1.30	0.20

15.02 ± 2.13, respectively ($P > 0.05$). The mean value of subarachnoid block to baby delivery time was comparable between the two groups.

Sensory block was at T6 level for all patients. The time of onset of hypotension after subarachnoid block was comparable between the two groups ($P > 0.05$). The SBP, DBP, mean arterial blood pressure, and HR at the time of onset of hypotension were comparable between the two groups ($P > 0.05$).

Study Parameters

SBP

In our study, both the vasopressors maintained the SBP within 20% limit of baseline value. There was a significant difference in SBP between the two groups at 2 min and 4 min after administration of the vasopressors. The SBP was high in phenylephrine group when compared to the Mephentermine group at 2 min–4 min after administration of vasopressors ($P < 0.05$). This may be due to quicker onset of action of phenylephrine when compared to mephentermine. From 6 min onwards, the SBP was comparable between the two drugs ($P > 0.05$). Within Groups M and P, the mean SBP at 2, 4, 6, 8, and 10 min, compared to the hypotensive value (t_0), was significant in both the groups ($P < 0.05$).

Sahu *et al.*[11] compared the effect of phenylephrine, mephentermine, and ephedrine on maternal blood pressure and showed that the SBP was significantly high in phenylephrine group at 2 min after bolus of the drugs. From 4 min onwards, the SBPs were comparable between the drugs in their study.

Sharma *et al.*[12] compared mephentermine and phenylephrine and found that SBP was significantly higher with phenylephrine at 6 min after administration compared to mephentermine. Within the groups, the mean SBP at 2, 4, 6, 12, and 30 min, compared to the hypotensive value (t_0), were significant in both the groups ($P < 0.05$).

DBP

The DBP was significantly high in phenylephrine group immediately after the administration of the drug when compared to mephentermine group and there was a statistical difference between the two groups up to 35 min ($P < 0.05$), with phenylephrine group having higher DBP. This may be due to the predominant α_1 action of phenylephrine, which increases the systemic vascular resistance (SVR). The DBPs were comparable between the two groups after 35 min.

Sharma *et al.*[12] in their study observed that at all intervals of time the DBPs were significantly higher in phenylephrine group compared to mephentermine group ($P < 0.05$).

Mean arterial blood pressure

The mean arterial blood pressure was significantly high in phenylephrine group when compared to the mephentermine group. The MAP was significantly higher in phenylephrine group up to 28 min after the administration of the vasopressor ($P < 0.05$) beyond which the values were comparable between both the two groups.

HR

In our study, phenylephrine group had significant fall in HR immediately after bolus dosage of the drug was administered, when compared to the baseline value. Bradycardia in phenylephrine group was probably a baroreceptor mediated reflex mechanism due to increased SVR after the drug bolus. In the mephentermine group, there was increase in HR after the bolus dosage of the drug which could be due to the beta-agonist action of mephentermine. There was a significant difference between the two groups in mean HR after the administration of the drug. The mean HR was significantly high in mephentermine group at all the time intervals after the administration of the vasopressor and stayed elevated till 40 min after the bolus administration of mephentermine.

Sahu *et al.*[11] in their study found significant decrease in HR in the phenylephrine group. In mephentermine group, the post-drug administration value of HR was high and remained statistically non-significant with values of onset of hypotension till the end of the surgery ($p>0.05$).

Sharma *et al.*[12] in their study found that after the administration of the drug, HR was significantly high in mephentermine group compared to phenylephrine group ($P < 0.05$). Within Group P, HR was significantly less at all time points after administration of the vasopressor ($P < 0.01$) compared to the value at the time of hypotension and even the baseline value, while in Group M, the mean HR at all time points was significantly higher after the administration of the vasopressor when compared to baseline value ($P < 0.05$).

Bradycardia

In our study, 4 patients (8%) in phenylephrine group had one episode of bradycardia, while none of the patients in mephentermine group had bradycardia. The four patients in the phenylephrine group were treated with atropine 0.6 mg IV. Bradycardia was not associated with hypotension in phenylephrine group and may have been caused by baroreceptor-mediated reflex to increased SVR. Hall *et al.*[13] had observed 20% incidence of bradycardia in patients who received bolus of phenylephrine 20 mcg and infusion of 10 mcg/min when compared to patients who received bolus of ephedrine 6 mg and infusion of 1 mg/min in his study.

Number of bolus of drugs

There was a significant difference between the number of boluses of vasopressors required in the two groups, with mephentermine group receiving more when compared to phenylephrine group. Sharma *et al.*[12] in their study observed that the mean number of doses was significantly more in mephentermine group when compared to phenylephrine group, 1.667± 0.83 and 1.289 ± 0.589, respectively ($P < 0.05$).

Nausea-vomiting score

In our study, none in the phenylephrine group experienced nausea and vomiting while four patients in the mephentermine group developed nausea. The nausea-vomiting score was one for each of these patients. The nausea was not associated with hypotension.

Sharma *et al.*[12] found the incidence of nausea and vomiting comparable between the mephentermine and phenylephrine groups ($P > 0.05$).

Neonatal outcome Apgar scores

The neonatal Apgar scores at 1 min and 5 min were comparable in both the groups in our study and never <8 in both groups at 1 min and 5 min. Mohta *et al.*[14] in their study had compared the Apgar score of the newborn at 1 min and 5 min, and found similar results in both the phenylephrine and mephentermine groups. Sharma *et al.*[12] in their study between phenylephrine and mephentermine for hypotension during spinal anesthesia for cesarean section, showed similar values for neonatal Apgar score in both the groups.

Neonatal umbilical artery blood gas analysis

In our study, the mean umbilical artery pH was comparable in Group M and P at 7.26 ± 0.027 and 7.26 ± 0.021, respectively. Mohta *et al.*[14] found similar umbilical artery blood gas analysis between the phenylephrine and mephentermine groups. Ngan *et al.*[15] studied the placental transfer and fetal metabolic effects of phenylephrine and ephedrine during spinal anesthesia for cesarean section and found a significant difference in the two groups. Ephedrine being more lipid soluble, stimulates fetal beta-adrenergic receptors increasing the metabolic activity with fetal oxygen demand exceeding fetal oxygen supply, resulting in anaerobic metabolism and a low umbilical artery pH. Mephentermine has not been reported to affect the umbilical artery pH.

Lee *et al.*[16] studied the effect of phenylephrine and ephedrine on maternal and neonatal outcome and concluded that phenylephrine may maintain the uterine blood flow better than ephedrine.

In our study, the umbilical artery blood gas analysis showed comparable values of mean PO_2, mean HCO_3, and mean PCO_2 values between the M and P groups.

The limitation in the study was that the hemodynamic variables were assessed at 2 min intervals, so the peak effect of the drugs may not be accurate.

CONCLUSION

Phenylephrine and mephentermine effectively maintained blood pressure during spinal anesthesia for cesarean section. Phenylephrine had a quicker peak effect after administration in comparison to mephentermine. Phenylephrine caused a reduction in HR while mephentermine increased HR. Phenylephrine increased DBP and the MAP**.** Repeat bolus doses of phenylephrine needed were significantly less. The effect of phenylephrine and mephentermine on umbilical artery pH and Apgar scores of the neonate were comparable.

We conclude from the study that phenylephrine and mephentermine maintained SBP above hypotensive range and that the effect on neonatal outcome was minimal and comparable, phenylephrine might be a better choice because number of repeat doses needed was less and it maintained the maternal DBP and mean arterial blood pressure better. Mephentermine increases the HR and so may be avoided in patients where the effect may be detrimental.

REFERENCES

1. Hughes SC, Levinson G, Rosen MA. Anaesthesia for caesarean section. In: Anaesthesia for Obstetrics. 4th ed. Philadelphia, PA: Lippincott, Williams and Wilkins; 1993. p. 201-36.
2. Chumpathong S, Chinachoti T, Visalyaputra S, Himmunngan T. Incidence and risk factors of hypotension during spinal anesthesia for cesarean section at Siriraj hospital. J Med Assoc Thai 2006;89:1127-32.
3. Kundra P, Khanna S, Habeebullah S, Ravishankar M. Manual displacement of the uterus during caesarean section. Anaesthesia 2007;62:460-5.
4. Rout CC, Rocke DA, Gouws E. Leg elevation and wrapping in the prevention of hypotension following spinal anaesthesia for elective caesarean section. Anaesthesia 1993;48:304-8.
5. Ayorinde BT, Buczkowski P, Brown J, Shah J, Buggy J. Evaluation of pre-emptive intramuscular phenylephrine and ephedrine for reduction of spinal anaesthesia-induced hypotension during caesarean section. Br J Anaesth 2001;86:371-6.
6. Rout CC, Rocke DA. Prevention of hypotension following spinal anaesthesia for caesaren section. Int Anaesthesiol Clin 1994;11:117-35 .
7. Marx GF. Aortocaval compression: Incidence and prevention. Bull NY Acad Med 1974;50:443.
8. Banerjee A, Stocche RM, Angle P, Halpern SH. Preload or coload for spinal anesthesia for elective cesarean delivery: A meta-analysis. Can J Anaesth 2010;57:24-31.
9. Nishikawa K, Yokoyama N, Saito S, Goto F. Comparison of effects of rapid colloid loading before and after spinal anesthesia on maternal hemodynamics and neonatal outcomes in cesarean section. J Clin Monit Comput 2007;21:125-9.

10. Teoh WH, Sia AT. Colloid preload versus coload for spinal anesthesia for cesarean delivery: The effects on maternal cardiac output. Anesth Analg 2009;108:1592-8.
11. Sahu D, Kothari D, Mehrotra A. Comparison of bolus phenylephrine, ephedrine, and mephentermine for maintenance of arterial pressure during spinal anesthesia in caesarian section-a clinical study. Indian J Anesth 2003;47:125-8.
12. Sharma R, Maitra N, Niyogi M. A comparative study of bolus phenylephrine and mephentermine for treatment of hypotension during spinal anesthesia for cesarean section. Internet J Anesthesiol 2009;19:1-10.
13. Hall PA, Bennett A, Wilkes MP, Lewis M. Spinal anaesthesia for caesarean section: Comparison of infusions of phenylephrine and ephedrine. Br J Anaesth 1994;73:471-4.
14. Mohta M, Janani SS, Sethi AK, Agarwal D, Tyagi A. Comparison of phenylephrine hydrochloride and mephentermine sulphate for prevention of post spinal hypotension. Anaesthesia 2010;65:1200-5.
15. Kee WD, Lee A, Khaw KS, Ng FF, Karmakar MK, Gin T. A randomized double-blinded comparison of phenylephrine and ephedrine infusion combinations to maintain blood pressure during spinal anesthesia for cesarean delivery: The effects on fetal acid-base status and hemodynamic control. Anesth Analg 2008;107:1295-302.
16. Lee A, Kee WD, Gin T. A quantitative, systematic review of randomized controlled trials of ephedrine versus phenylephrine for the management of hypotension during spinal hypotension. Anesth Analg 2002;94:920-6.

How to cite this article: Prakash S, John X. A Study of Phenylephrine versus Mephentermine during Subarachnoid Block for Cesarean Section. Int J Sci Stud 2021;9(9):34-41.

Source of Support: Nil, **Conflicts of Interest:** None declared.

Print ISSN: 2321-6379
Online ISSN: 2321-595X

Original Article

A Clinical Evaluation of Diabetic Foot Ulcer: Prospective Study

M Aparna[1], T Srinivas[2]

[1]Assistant Professor, Department of General Surgery, Government Medical College, Mahabubnagar, Telangana, India, [2]Associate Professor, Department of General Surgery, Government Medical College, Mahabubnagar, Telangana, India

Abstract

Background: Diabetic foot ulcer (DFU) is the most common complication among all diabetics. With progressing age and duration of diabetes the risk of developing DFU increases. This study was conducted to understand the course of DFU and its association.

Objectives: To study the risk factors and clinical course among DFU subjects and assesses the association between clinical course and outcome.

Methodology: This prospective study was conducted among 40 subjects who reported to S.V.S medical college and hospital surgery department with wound/s on the foot. The study period was for a year. The data was collected using a pretested questionnaire, analyzed, and presented.

Results: The study consisted of 18 males and 22 females. About 52.7% of the subjects were barefooted. The most common precipitating factor was trauma, abscess, and ulceration. Wagner classification system was used to grade the lesion in which 50% of the subjects belonged to grade 3 and the remaining grade 1 and 4. Most of the subjects had lesions at the toes, plantar and dorsum aspect of the foot, web-spaces, and lateral/medial borders of the foot. Culture and sensitivity were done to isolate various organisms and accordingly antibiotics were started. Surgery was done for 28 subjects and wound debridement was commonest. Wound healed and wound showed signs of healing in 90% of subjects were seen. The association between all the variables was significant ($P < 0.05$)

Key words: Diabetes mellitus, Diabetic foot ulcer, Precipitating factors, Lesions and antibiotics

INTRODUCTION

The most common precursor for lower extremity amputations among diabetics is foot ulceration.[1,2] About a quarter of all diabetic hospital admission is for the treatment of infected wounds.[3,4] Diabetic foot is multifactorial in nature which has been described in number of observational studies.[5-7] Risk factors identified include peripheral neuropathy, vascular diseases, foot deformity, minor and major trauma, ulceration, and amputation.[8-10] In the face of unobserved trauma peripheral sensory neuropathy is the primary factor leading to diabetic foot.[11,12] Nearly 45–60% ulcerations are neuropathic and up to 45% neuropathic and ischemic constituents.[11,13] Trauma of foot in the presence of sensory neuropathy is an important component cause of ulceration.[11] Dry skin with fissuring and cracking is a portal for bacteria entry resulting from autonomic neuropathy.[14] These variations can later embroil in the pathogenesis of ulceration.[14,15] Elevated plantar foot pressures are associated with amputations and neuropathic ulceration in a large population based study.[16] In this study the cause of ulceration, site of ulceration, most common organism found, treatment and outcome patterns are described.

Access this article online

www.ijss-sn.com

Month of Submission : 10-2021
Month of Peer Review : 11-2021
Month of Acceptance : 11-2021
Month of Publishing : 12-2021

METHODOLOGY

The present prospective study of 40 cases of diabetic foot disease was carried out in the department of General surgery, SVS medical college over a period of 1 year from July 2015 to June 2016. All patients admitted with foot infection found to have elevated blood sugar level or having previous history of diabetes mellitus. Patients

Corresponding Author: Dr M Aparna, Department of General Surgery, Flat # 301, Kamakshi Heights Apartments, Mettugadda, Mahabubnagar - 509 001, Telangana, India.

having specific infections of the foot (Mycetoma, actinomycosis, hansen's disease). After obtaining informed consent of the concerned patients data was collected using a pretested questionnaire. General assessment and systemic examination was done for all the patients are done. A detailed local examination of the diabetic foot lesion was also done. Complete blood investigations including Random blood sugar, Fasting blood sugar, Post-prandial blood sugar was done. Urine is examined for the presence of sugar, albumin, ketone, and any deposits. A plain X-Ray (both antero-posterior and lateral views) of the affected limb is done to find out the presence of any osteomyelitic changes and calcification of arteries. The discharge obtained from the site of diabetic foot lesion was sent for culture and sensitivity to find out the organism(s) responsible and to determine further therapeutic management with antibiotics. The data were compiled and analyzed and presented as tables and percentages. Keeping the significance level at $P = 0.05$ the association was assessed and tabulated.

RESULTS

Table 1 shows the distribution of subjects, this study consisted of 18 males and 22 females. The mean age among the subjects was 51.8 + 3.42. 50% of the subjects were above 60 years. Footwear is an important variable were 52.7% of subjects were barefooted and 47.5% wore footwear. Among the 40 subjects, the precipitating factor leading to foot ulcer was taken into consideration. Six subjects each had history of trauma, thorn prick, and previous surgeries respectively. Thirteen of the 40 subjects had a history of previous ulceration. Trauma with previous surgeries and thorn prick with previous ulcer were seen in five and four subjects respectively. Majority of the subjects, 32.5% presented with gangrene. The other presentations were in the form of abscess, ulcer with abscess and gangrene, cellulitis, and ulcer.

Wagner ulcer classification was used to classify subjects were half of the subjects belonged to Grade 3. Ten subjects each had Grade 1 and Grade 4, respectively. Grade 2 and 5 were not seen in this study as seen in Table 2.

Site of lesion was enlisted as shown in Table 3 were eight subjects each had lesion in the toes +lateral/medial borders of foot, plantar aspect of foot +toes and dorsum of foot +lateral/medial borders of the foot. Four subjects each had lesion on the lateral/medial borders of the foot, web spaces, and plantar aspect of foot + lateral/medial borders of the foot respectively.

Culture and sensitivity were done for all the subjects. The organisms isolated are as follows, 16 (40%) subjects had *Escherichia coli* and *Klebsiella*+*Enterococcus*. Seven (17.5%) subjects had no growth. Five (12.5%) had *Pseudomonas aeruginosa*. *Staphylococcus aureus* was seen in four subjects and only two subjects had *Klebsiella* and *Staphylococcus* together [Table 4].

Table 5 shows the usage of antibiotics based on the C and S report. In the present, 17 various antibiotics were used. In majority of the subjects, all the antibiotics were used.

Table 6 presents the surgical procedure done for the subjects. Twelve subjects did not need any surgical intervention. The remaining 28 subjects underwent surgical procedures as enumerated.

Table 1: Distribution of subjects according to age, sex, and clinical presentations

Characteristics	Number (%)	
Age		Mean
30–39 years	06 (15)	51.8+3.42
40–49 years	08 (20)	
50–59 years	06 (15)	
>60 years	20 (50)	
Sex		Ratio
Males	18 (45)	0.81:1
Females	22 (55)	
Footwear		
Barefooted patients	21 (52.7)	
Patients wearing footwear	19 (47.5)	
Precipitating factors		
No history of trauma/prick/previous lesion	0	
Positive history of trauma	06 (15)	
Positive history of thorn prick	06 (15)	
Positive history of trauma+previous surgeries/amputations for DFU	06 (15)	
Positive history of previous abscess/ulceration	13 (32.5)	
Positive history of trauma+previous abscess/ulceration	05 (12.5)	
Positive history of thorn prick+previous abscess/ulceration	04 (10)	
Presentation		
Ulcer	04 (10)	
Cellulitis	06 (15)	
Abscess	07 (17.5)	
Gangrene	13 (32.5)	
Ulcer+abscess	06 (15)	
Ulcer+gangrene	04 (10)	

DFU: Diabetic foot ulcer

Table 2: Distribution of subjects according to staging using WAGNER ulcer classification system

WAGNER classification	Grade	Number (%)
No open lesion; may have deformity or callus	0	
Superficial diabetic ulcer	1	10 (25)
Ulcer extension to ligament, tendon, joint capsule or Deep fascia without abscess or osteomyelitis	2	0
Deep ulcer without abscess, osteomyelitis, or joint sepsis	3	20 (50)
Gangrene localized to portion of forefoot/heel	4	10 (25)
Extensive gangrenous involvement of the whole foot	5	0

With regard to outcome post-surgery the subjects were evaluated after 4 weeks. Table 7 shows 67.5% showed signs of healing and 32.5% of subjects wound healed by the end of the 4th week.

The association between clinical onset, site of ulcer, and course of the disease with outcome was assessed. Taking the value of significance ($P < 0.05$) as significance high significance was seen between precipitating factor and site of lesion, subjects presentation, site of lesion, precipitating factors, antibiotics, and surgery with outcome was also significant [Table 8].

Table 3: Distribution of subjects according to site of lesion

Site of lesion	Number (%)
Plantar aspect of foot	2 (5)
Dorsum of foot	1 (2.5)
Toes	1 (2.5)
Lateral/medial borders of foot	4 (10)
Web spaces	4 (10)
Toes+web spaces	0
Plantar aspect of foot+web spaces	0
Plantar aspect of foot+lateral/medial borders of foot	4 (10)
Toes+lateral/medial borders of foot	8 (20)
Plantar aspect of foot+toes	8 (20)
Dorsum of foot+lateral/medial borders of foot	8 (20)

Table 4: Various organisms isolated from C and S

Organism	Number (%)
No growth	07 (17.5)
Staphylococcus aureus	04 (10)
Escherichia coli	08 (20)
Pseudomonas aeruginosa	05 (12.5)
Klebsiella+Staphylococcus aureus	02 (5)
Klebsiella+Enterococcus	08 (20)
Streptococcus species	06 (15)

Table 5: Antibiotics used based on the C and S report

Antibiotics	Number
Amoxycillin_clavulinic acid	27/40
Ampicillin cloxacillin	27/40
Cefoperazone sulbactam	27/40
Piperacillin tazobactum	33/40
Co trimoxazole	27/40
Tetracycline	27/40
Ciprofloxacin	30/40
Ofloxacin	37/40
Levofloxacin	33/40
Ceftriaxone	27/40
Amikacin	27/40
Gentamycin	30/40
Imipenam cilastin	37/40
Linezolid	26/40
Azithromycin	30/40
Clidamycin	32/40
Chloramphenicol	31/40

DISCUSSION

In our study of 40 subjects of Diabetic foot, maximum rate of 50% was seen in above 60 years age group, while it was 15% and 20% in the 50–59 and 40–49 years age- groups respectively. This study is similar to that reported by Hasbum *et al.*[17] from Mexico Hospital (Mean age 60 ± 4 years).

A study done in the USA in 2004 by Reed[18] suggested that elderly Diabetics had twice the risk of developing a foot ulcer, 3 times the risk of developing a foot abscess, and 4 times the risk of developing Osteomyelitis.

Sinnock[19] estimated that the amputation rates in diabetic subjects are higher for males than females which were evident in our study.

Footwear being a vital part for diabetics this study had 52.7% barefooted and 47.5% who used footwear. Ashry

Table 6: Surgical procedure among the subjects

Surgical procedure	Number (%)
Incision and drainage	07 (17.5)
Wound debridement	24 (60)
Toe amputation	13 (32.5)
Forefoot amputation	1 (2.5)
Below knee amputation	04 (10)
Above knee amputation	03 (7.5)
Split skin grafting	03 (7.5)
Incision and drainage+wound debridement	03 (7.5)
Wound debridement+toe amputation	03 (7.5)
No surgical procedure done	12 (30)

Table 7: Distribution of subjects according to progress of wound healing

Wound healing	Number (%)
Wound healed	11 (27.5)
Wound showing signs of healing	25 (62.5)
Non- healing wound	4 (10)
Total	40 (100)

Table 8: Association between clinical onset and course of disease with outcome among the subjects

Clinical onset and course	Mean	SD	95% CI		*P*-value
			Lower	Upper	
Precipitating factors *site of lesion	3.050	2.605	3.897	2.202	<0.001
Presentation * outcome	1.900	1.481	1.426	2.373	<0.001
Site of lesion * outcome	4.80	2.028	4.151	5.448	<0.001
Precipitating factor * outcome	1.750	1.597	1.239	2.260	<0.001
Antibiotics * outcome	2.488	1.051	2.182	3.179	<0.001
Surgery * outcome	2.724	3.356	0.675	2.724	<0.001

et al.[20] in their study noted that patients at high risk of diabetic foot ulceration benefit greatly from the use of footwear that corrects or least mitigates the biomechanical defects. Knowles and Boulton[21] found that patients suffering from diabetic foot problems often look for footwear that is presentable and fashionable as well as protective. They also on served that only 22% of their subjects wore their prescribed footwear all the day.

In our study, the most common cause of diabetic foot was trauma and a history of previous abscess or ulcer. There was high level of significance ($P < 0.001$) when compared with progress and outcome. In Nigeria study by Muhammad[22] variously suggested that trauma or complications of traditional bone setting and complications from Diabetes Mellitus are the most common causes

With regard to presentation our study showed various presentations such as gangrene, abscess, cellulitis, and ulceration. Linklater and Potter[23] noted that soft tissue abnormalities associated with the diabetic foot include soft-tissue edema, cellulitis, abscess, ulcers, sinus tracts, tenosynovitis, joint effusions, and arthritis. Our study showed strong significance ($P < 0.001$) when compared with progress of the ulcer.

In a study conducted by Treece *et al.*[24] in the UK among 389 diabetic ulcer patients, 78.4% were of Grade 2 type, 10.8% had Grade 3 type and rest Grade 4 which nearby to the present study findings based on Wagner ulcer classification system.

In the present study, diabetic foot lesions were found at multiple sites. Toes with web spaces and plantar and dorsum aspects of the foot were the most common sites found in 70% of the patients. Lesion and progress were assessed for association and noted highly significant ($P < 0.001$). Reiber *et al.*[25] noted that ulcer sites are predominantly under the plantar surface of the toes, forefoot, and midfoot followed by the dorsal surface of the toes and heel. Apelqvist *et al.*[26] cautioned that ulcer severity is more important than the ulcer site in determining the final outcome.

Chahne *et al.*[27] found that *S. aureus* and betahemolytic streptococci were the most common infecting organisms in patients with mild-to-moderate diabetic foot infections. They also noted that *P. aeruginosa* was associated with exposure to water and warm climate; obligate anaerobes were associated with necrotic, gangrenous, or ischemic tissue in chronic and severe infections. Patients who had recent antibiotic therapy or having chronic ulcers tend to develop mixed infection with Gram-positive cocci and Gram-negative bacilli with or without the presence of anaerobic organisms.

Lee *et al.*[28] in 2003 in a study of 13,271 patients with diabetes have shown 78.4% have fungal infection of the feet. Among these infections, 70.8% are Tinea pedis. The investigators, therefore, consider fungal infection a risk factor for foot ulcers.

In the treatment aspect, various antibiotics were used, cefoperazone-sulbactam was the most common used antibiotic in patients to combat both Gram-positive and Gram-negative organisms followed by clindamycin and ampicillin-cloxacillin and the third common antibiotic used was ciprofloxacin in. Many patients required treatment with more than one antibiotic drug. Antibiotics play a major role and combination of a couple of them yielded good progress ($P < 0.001$).

Twenty-four patients had underwent wound debridement (60%), 13 patients underwent toe amputation (32.5%), seven patients underwent incision and drainage (17.5%), four patients underwent below-knee amputation (10%), three patients underwent above-knee amputation (7.5%), only one patient underwent forefoot amputation (2.5%), 3 patients have split skin grafting out of which two had underwent wound debridement and one had underwent below-knee amputation. 12 patients had no surgical intervention. Surgical procedures on follow-up with regard to progress was fair and good and of high significance ($P < 0.001$). Hawkins and Brike[29] in their study of diabetic outpatients predicted that 6% to 43% (depending on ulcer severity) of patients with foot ulcers have the most severe diabetic foot outcome, amputation.

Garbalosa *et al.*[30] stated that despite everyone's best efforts in performing diabetic foot care, an amputation is occasionally the treatment of choice.

Eneroth[31] observed that debridement is also necessary in case of sepsis secondary to acute osteomyelitis, progression of infection despite antibiotics, and recurrent foot infections secondary to chronic osteomyelitis.

Pitei *et al.*[32] observed that the callus needs to be removed frequently, as it can build up quickly, with some patients needing debridement as often as every 3–4 weeks or sometimes even more frequently.

A study by Abbott *et al.*[33] involving 9700 patients showed that the presence of diabetic foot ulceration incurred an 80 to 85% risk of amputation.

Wrobel *et al.*[34] suggested that only four surgical procedures exhibit higher variation than major amputation in diabetes: lower extremity revascularization, carotid end arterectomy, back surgery, and radical prostatectomy.

It is seen that after 4 weeks of treatment 25 patients showed signs of wound healing (62.5%), wound had healed completely in 11 patients (27.5%) and only 4 patients had a non-healing wound (10%). Thus, 90% of patients in the study group had wound healing by the end of the 4th week.

Peter Sheehan *et al*.[35] predicted that the percentage of wound healing after 4 weeks of treatment was a significant predictor of wound healing after 12 weeks.

CONCLUSION

This study was conducted among 40 diabetic subjects. The study consisted of 18 males and 22 females. The mean age was 51.8 + 3.42. Footwear, precipitating factors, and presentation were taken into consideration. The lesions were graded using the Wagner ulcer classification system. The various site of lesion was elucidated. Culture and sensitivity were done for all the subjects and the most common organisms were identified and the treatment was given accordingly. Surgical procedures were carried out in 28 subjects. Healing and healed was 90% after 4 weeks at follow-up. There was a strong association observed in the study with regard to precipitating factors, presentation, site of lesion, role of antibiotics, and surgical procedures with outcome.

REFERENCES

1. Larsson J, Agardh CD, Apelqvist J, Stenstrom A. Long-term prog-nosis after healed amputation in patients with diabetes. Clin Orthop 1998;350:149-58.
2. American Diabetes Association. Consensus development conference on diabetic foot wound care. Diabetes Care 1999;22:1354.
3. Shaw JE, Boulton AJ. The pathogenesis of diabetic foot problems: An overview. Diabetes 1997;46 Suppl 2:S58-61.
4. Boulton AJ, Meneses P, Ennis WJ. Diabetic foot ulcers: A framework for prevention and care. Wound Repair Regen 1999;7:716.
5. Frykberg RG, Habershaw GM, Chrzan JS. Epidemiology of the diabetic foot: Ulcerations and amputations. In: Veves A, editor. Contemporary Endocrinology: Clinical Management of Diabetic Neuropathy. Totowa, NJ: Humana Press; 1998. p. 273.
6. Walters DP, Gatling W, Mullee MA, Hill RD. The distribution and severity of diabetic foot disease: A community study with comparison to a non-diabetic group. Diabet Med 1992;9:354-8.
7. Boyko EJ, Ahroni JH, Stensel V, Forsberg RC, Davignon DR, Smith DG. A prospective study of risk factors for diabetic foot ulcer. The seattle diabetic foot study. Diabetes Care 1999;22:1036-42.
8. Boulton AJ. The diabetic foot: From art to science. The 18th Camillo Golgi lecture. Diabetologia 2014;47:1343-53.
9. Edmonds ME, Blundell MP, Morris ME, Thomas EM, Cotton LT, Watkins PJ. Improved survival of the diabetic foot: The role of a specialized foot clinic. Q J Med 1986;60:763-71.
10. Frykberg RG, Lavery LA, Pham H, Harvey C, Harkless L, Veves A. Role of neuropathy and high foot pressures in diabetic foot ulceration. Diabetes Care 1998;21:1714-9.
11. Frykberg RG. Diabetic foot ulcers: Pathogenesis and management. Am Fam Physician 2002;66:1655-62.
12. Pecoraro RE, Reiber GE, Burgess EM. Pathways to diabetic limb amputation: Basis for prevention. Diabetes Care 1990;13:513-21.
13. Akbari CM, Macsata R, Smith BM, Sidawy AN. Overview of the diabetic foot. Semin Vasc Surg 2003;16:3-11.
14. Parkhouse N, Le Quesne PM. Impaired neurogenic vascular response in patients with diabetes and neuropathic foot lesions. N Engl J Med 1988;318:1306-9.
15. Frykberg RG. Biomechanical considerations of the diabetic foot. Lower Extrem 1995;2:207-14.
16. Cavanagh PR, Ulbrecht JS, Caputo GM. New developments in the bio mechanics of the diabetic foot. Diabetes Metab Res Rev 2000;16 Suppl 1:S6-10.
17. Hashum B. Descriptive study of Diabetic Foot Clinic, Internal Medicine, Mexico Hospital; 2017.
18. Reed JF. An audit of lower extremity complication in patients with diabetes mellitus. Int J Lower Extrem Wounds 2004;3:161-4.
19. Most RS, Sinnok P. The epidemiology of lower extremity amputations in diabetic individuals. Diabetes Care 1983;6;87-91.
20. Ashry HR, Lavery LA, Murdoch DP, Frolich M, Lavery DC. Effectiveness of diabetic insoles to reduce foot pressures. J Foot Ankle Surg 1997;36:268-71.
21. Knowles EA, Boulton AJ. Do people with diabetes were their prescribed footwear? Diabet Med 1996;13:1064-8.
22. Yakubu A, Muhammad I, Mabogunje OA. Major limb amputation in adults, Zaria, Nigeria. J R Coll Surg Edinb 1996;41:102-4.
23. Linklater J, Potter HG. Emergent musculoskeletal magnetic resonance imaging. Top Magn Reson Imaging 1998;9:238-60.
24. Treece. Descriptive study of Diabetic Foot Clinic, Internal Medicine, Mexico Hospital; 2017.
25. Reiber GE, Vileikyte L, Boyko EJ, del Aguila M, Smith DG, Lavery LA, *et al*. Causal pathways for incident lower extremity ulcers in patients with diabetes from two settings. Diebetes Car 1999;22:157-62.
26. Apelqvist J, Castenfors J, Larsson J, Stenström A, Agardh CD. Wound classification is more important than site of Ulceration in the outcome of diabetic foot ulcers. Diabetic Med 1989;6:526-30.
27. Chahine EB, Harris S, Williams R. Diabetic foot infections: An update on treatement. US Pharm 2013;38:23-6.
28. Lee J, Lu M, Lee VS, Russell D, Bahr C, Lee ET. Lower extremity amputation. Incidence, risk factors and mortality in Oklahoma Indian diabetes study. Diabetes 1993;42:876-82.
29. Hawkins ES, Brike JA. Diabetic foot ulcer healing rates. In: Personal Communication, Gillis W. Long Hansen's Disease Center; 1992.
30. Garbalosa PT, Cavanagh PR, Wu G, Ulbrecht JS, Becker MB, Alexander IJ, *et al*. Foot function in diabetic patients after partial amputation. Foot Ankle Int 1996;17:43-8.
31. Eneroth M, Apelqvist J, Stenström A. Clinical characteristics and outcome in 223 diabetic patients with deep foot infections. Foot Ankle Int 1997;18:716-22.
32. Pitei DL, Foster A, Edmonds M. The effect of regular callus on foot pressures. J Foot Ankle Surg 1999;38:251-5.
33. Abbott CA, Carrington L, Ashe H, Bath S, Every C, Griffiths J. The North-West diabetes foot care study: Incidence of, andrisk factors for, new diabetic foot ulcerationin a community-based patient cohort. Diabet Med 2002;19:377-84.
34. Wrobel JS, Mayfield JA, Reiber GE. Geographic variation of lower extremity major amputation in individuals with and without diabetes in the Medicare population. Diabetes Care 2001;24:860-4.
35. Sheehan P, Jones P, Caselli A, Giurini JM, Veves A. Percentage change in wound area of diabetic foot ulcers over a 4-week period is a robust predictor of complete healing in a 12 week-prospective trial. Diabetes Care 2006;26:1879-82.

How to cite this article: Aparna M, Srinivas T. A Clinical Evaluation of Diabetic Foot Ulcer: Prospective Study. Int J Sci Stud 2021;9(9):42-46.

Source of Support: Nil, **Conflicts of Interest:** None declared.

Print ISSN: 2321-6379
Online ISSN: 2321-595X

Original Article

Correlation between Computed Tomography Scan Findings and Middle Meatal Antrostomy Findings in Cases of Maxillary Sinusitis – A Study on 50 Cases

Perla Ambika

Assistant Professor, Department of ENT and Head and Neck Surgery, Gandhi Hospital, Secunderabad, Telangana, India

Abstract

Background: Sinusitis is a leading health-care problem believed to be increasing in both incidence and prevalence. Among chronic rhinosinusitis (CRS), maxillary sinusitis is more commonly seen due to the peculiar anatomical nature of the maxillary sinus and its close relation with other sinuses. Specific diagnosis is by computed tomography (CT) scan of paranasal sinuses (PNS). Controversy exists whether the CT scan findings are reliable with the surgical findings in middle meatal antrostomy (MMA) or not. Hence, estimation of the accuracy of CT PNS scan in maxillary sinusitis cases is quite reasonable. Prevalence and incidence in India are 15% of the total population. Air pollution, fumes from the industries, allergic factors, etc., are the risk factors for the increase in incidence.

Aim: This study aims to study the clinical presentation of maxillary sinusitis by history, to know the supportive or misguiding role of CT scan while dealing with the sinus pathology by surgery, and to identify the causative organism by microbiological study.

Materials and Methods: Patients attending to ENT OP with clinical features of maxillary sinusitis such as headache and nasal discharge preferably >3 months above 15 years of age were randomly selected and admitted for CT scan and included in the study, posted for endoscopic sinus surgery and CT scan findings were compared.

Results: CT scan findings were compared with MMA findings and MMA specimens were sent for culture sensitivity. The most common symptoms were nasal obstruction (70%) and headache (56%). In the CT scan, 38% antra showed haziness, 24% showed mucosal thickening, and 19% showed clear antra. After surgery MMA, radiologically hazy antra showed 81.57% positive results and polypoidal change antra showed 100% positive results.

Conclusion: Highest incidence of maxillary sinusitis is in the 3rd decade, male population is affected more 66%, the most common symptom is nasal obstruction. Radiologically opaque, hazy antra gave reliable (90.9%) MMA findings, sensitivity is 100% with CT scan examination, and specificity is 56.25%.

Key words: Chronic rhinosinusitis, Computed tomography scan, Culture sensitivity, Middle meatal antrostomy, Paranasal sinuses

INTRODUCTION

Maxillary sinusitis is the most common among the other sinus infections and a leading health problem. Due to its peculiar anatomical nature, maxillary sinus is more prone to infections. First clear existence of paranasal sinuses (PNS) was provided by Beranger Del Carpi, anatomist at Bologna in early 16th century. Messerklinger (1984) and Stammburger (1985) opened the antral cavity if indicated by individual radiological findings. First modern and accurate descriptions of PNS can be dated back to the works of the 19th century Austrian anatomist Emil Zuckerkandl. Rhinosinusitis refers to a group of diseases mainly the inflammation and infection which affects the mucosa of nose and PNS. Impairment in the mucociliary clearance pathway leads to obstruction and sinusitis which is due to host and environmental factors. Both prevalence and incidence account to 31 million people in the USA, In India, it is seen in 15% of population. Chronic

Access this article online

www.ijss-sn.com

Month of Submission : 10-2021
Month of Peer Review : 11-2021
Month of Acceptance : 11-2021
Month of Publishing : 12-2021

Corresponding Author: Perla Ambika, Department of ENT and Head and Neck Surgery, Gandhi Hospital, Secunderabad, Telangana, India.

rhinosinusitis (CRS) is a multifactorial disease, the most common include nasal obstruction, headache, and nasal discharge. There is a role of anatomical abnormalities, infections, superantigens, biofilms, fungi, and allergy in CRS. Other causes are trauma, dental extraction, and cystic fibrosis. Cells and inflammatory markers which play a role in CRS are eosinophils, neutrophils, mast cells, T and B cells, interleukins (ILs), tumor necrosis factor, mean blood pressure, etc. The most common bacteria isolated from culture are *Staphylococcus* 55% and *Streptococcus* 30.43%. First radiological description of maxillary sinuses was done by Leonardo da Vinci (1489). While doing the computed tomography (CT) scan PNS, typically axial and coronal sections are obtained, important parameters being prone position, angulation. In axial scan, CT scanner is perpendicular to patient's hard palate, field view – 14 cm, slice thickness – 3 mm, contiguous, 125 Kup, and 80–160 ma/s. Lund Mackay staging system for CRS for maxillary sinus disease S1 -mucosal thickening,S2-less than 50% sinus opacification,S3-greater than 50% sinus opacification,S4-complete snus opacification. In pre-antibiotic era, the main aim of sinus surgery was removal of pus from sinuses as a life-saving measure. In modern method, Messerklinger and Stammburger described the basic endoscopic sinus surgery (ESS), the role of removal of disease from the ostiomeatal complex (OMC) was popularized by Kennedy. Middle meatal antrostomy (MMA) is performed by Messerklinger method. A->P approach, uncinectomy was first done, followed by MMA. Enlargement of ostium, collection of specimens for culture sensitivity (C/S) to detect the causative organism, and the CT scan findings are compared with MMA findings. C/S reports are also compared in tabulated forms.

Aim

This study aims to know the authenticity of CT scan in dealing with the sinus pathology by surgery, to study the clinical presentation of maxillary sinusitis by history, and to identify the causative organism by microbiological study.

Inclusion Criteria

1. Patients attending to the outpatient department of Gandhi Hospital for a period of 2 years selected
2. Patients with symptoms of headache, nasal obstruction, and nasal discharge preferably >3 months were selected
3. Selected patients were sent for radiological examination CT scan PNS
4. Patients admitted for performing surgery (MMA).

Exclusion Criteria

1. Patients in acute stage <3 months were excluded
2. Patients <15 years age group were excluded
3. Patients with risk factors (chronic illness) excluded.

All the 50 patients are examined clinically, plain CT PNS findings are considered positive (abnormal) if maxillary sinus shows (1) complete opacity, (2) haziness, (3) mucosal thickening, and (4) polypoidal change and surgery was performed. MMA findings are considered positive (abnormal) if purulent or mucopurulent discharge obtained as aspirate.

MATERIALS AND METHODS

Patients attending the outpatient department of Gandhi Hospital with symptoms of chronic sinusitis, >15 years were randomly selected, and radiological examination (CT PNS) was done. Surgery (MMA) was done, and results were compared. Total no. of patients studied – 50, total no. of maxillary antra examined radiologically and surgically – 100.

OBSERVATION AND RESULTS

From the patients attending to the ENT Department, Gandhi Hospital, Secunderabad, patients above 15 years age group with clinical features suggestive of maxillary sinusitis were chosen [Tables 1-8]. They were subjected to CT PNS scan, 50 patients with positive CT scan findings were taken into study and admitted and posted for MMA, the findings were compared, and observations are tabulated as follows:[1-5]

Table 1: Age incidence

Group	Age in years	No. of patients	Percentage
I	16–19	7	14
II	20–29	22	44
III	30–39	9	18
IV	40–49	9	18
V	>50	3	6

Table 2: Sex incidence

Sex	No. of patients	Percentage
Male	33	66
Female	17	34

Table 3: Symptomatology index

Symptoms	No. of patients	Percentage
Nasal obstruction	35	70
Headache	28	56
Sore throat	13	26
Hyposmia	10	20
Nasal discharge	7	14
Sneezing	6	12
Ear complaints	3	6
Epistaxis	2	4
Dental complaints	2	4
Difficulty in breathing	1	2
Watering from eyes	1	2

DISCUSSION

A total of 100 antra belonging to 50 patients were subjected to radiological examination (CT scan), MMA surgery done. Results of the present study are compared with the findings of previous studies. In the present study, highest incidence of age was found to be the 3rd decade followed by the 4th and 5th decade. Similar results were seen in a study conducted by Manuseth and Patil (2005), maximum age of incidence was 3rd decade. In a study conducted by Shrestha *et al.* (2010), maximum incidence was in the 3rd decade; male: female ratio 66%:34%. Symptomatology wise nasal obstruction 70%, headache 56%, sore throat 26%. In a study of Zojaji *et al.*, 2008, common complaint was nasal obstruction. DNS was the most common presenting sign (74%) and hypertrophied inferior turbinate (58%). In the study of Manuseth and Patil (2005); hypertrophied inferior turbinate 34% was the most common presenting sign. In the study of Shrestha *et al.*, 2016, pus in the middle meatus (88%) was the common sign. On comparison of CT appearance with MMA findings in the present study, hazy antra showed positive MMA findings in CT 81.57%, mucosal thickening of antra showed positive MMA findings in 58.35%, and polypoidal changes in antra showed positive MMA findings in 100% of patients. In a study conducted by Zojaji *et al.*, 2008, 29 patients with mucosal thickening showed positive results un-ESS and all the patients with polyps in CT scan showed positive findings in ESS. According to the study conducted by Manuseth and Patil (2005), CT scan showed highest sensitivity for maxillary sinus 92% with operative findings. Results of C/S of MMA specimen in the present study, 28% of patients showed no growth, frequent organisms isolated were staphylococci (16%) and *Klebsiella* (8%). In the study of Gokhale and Suligavi (2010), *Staphylococcus aureus* (24%) was the most common organism in 48 patients. Probably, *Staphylococcus* may be a commensal.[6-10]

Table 4: ENT examination

Signs	No. of patients	Percentage
Deviated nasal septum	37	74
Hypertrophied inferior turbinate	29	58
Congested nasal mucosa	16	32
Pale nasal mucosa	15	30
Pharyngitis	12	24
Retracted tympanic membrane	8	16
Postnasal drip	7	14
Tonsillitis	6	12
Central perforation	5	10
Concha bullosa	3	6
Hypertrophied middle turbinate	2	4
External deviation of nose	1	2
Discharge in middle meatus	1	2
Paradoxical middle turbinate	1	2

Table 5: CT appearance of antra

Group	CT scan appearance	Number of antra	Percentage
I	Clear	19	19
II	Opaque	11	11
III	Hazy	38	38
IV	Mucosal thickening	24	24
V	Polypoidal change	8	8

CT: Computed tomography

Table 6: MMA findings

Group	MMA finding	No. of antra	Percentage
I	Clear antra	32	32
II	Purulent discharge	26	26
III	Polypoidal change of sinus mucosa	16	16
IV	Mucopurulent discharge	14	14
V	Thickening of sinus mucosa	12	12

MMA: Middle meatal antrostomy

CONCLUSION

This study was conducted in the ENT outpatient and inpatient department in Gandhi Hospital, Secunderabad,

Table 7: Comparison of CT scan findings with MMA findings

Group	CT scan appearance of antra	No. of maxillary antra	No. of antra showing positive MMA findings	Percentage
I	Clear	19	0	0
II	Opaque	11	10	90.9
III	Hazy	38	31	81.57
IV	Mucosal thickening	24	14	58.33
V	Polypoidal change	8	8	100

MMA: Middle meatal antrostomy

Table 8: Sensitivity and specificity

CT scan findings	Abnormal MMA findings	Normal MMA findings	Total
CT scan abnormal	65 (a)	17 (b)	82
CT scan normal	0 (c)	18 (d)	18
Total	65	35	100

MMA: Middle meatal antrostomy

for a period of 2 years in 50 patients with clinical features of nasal obstruction, headache, facial pain, and nasal discharge for >3 months by random selection and was subjected to CT PNS scan, patients with positive CT findings were admitted and posted for MMA, specimens collected from MMA sent for C/S, and results are compared.

Highest age incidence of maxillary sinusitis was found to be in the 3rd decade, males are affected more 66% in the present study, the most common symptoms are nasal obstruction 70% and headache 50%, DNS is the common clinical finding in 74% of patients, hypertrophied inferior turbinate in 58% of patients, and pharyngitis in 24%. Out of 50 radiologically abnormal CT PNS scans, 19% maxillary antra were clear,11% were opaque, 38% were hazy, 24% revealed mucosal thickening, and 8% showed polypoidal changes. In comparison of CT scan with operative findings (MMA), out of 11 radiologically opaque antra, 10 showed positive MMA findings, accuracy is 81.57%, only 14 antra showed positive MMA findings out of 24 antra which had mucosal thickening radiologically; polypoidal change in CT scan showed 100% positive MMA findings. C/S of MMA specimen showed 28% yield organism staphylococci, 28% no organism was detected. Hence, we concluded that radiologically clear, opaque, hazy, and polypoidal antra showed reliable MMA findings and antra with mucosal thickening showed less reliability. Hence, we concluded that sensitivity of CT scan was found to be 100% and specificity was found to be 56.25%.

REFERENCES

1. Messerklinger W. Endoscopy technique of the middle nasal meatus (author's transl). Arch Otorhinolaryngol 1978;221:297-305.
2. Stammberger H. Endoscopic surgery for mycotic and chronic recurring sinusitis. Ann Otol Rhinol Laryngol Suppl 1985;119:1-11.
3. Isaacs S, Falkhri S, Luong A, Citardi. Intraoperative imaging for otorhinolaryngology-head and neck surgery. M J Otolaryngology 2009;42:765-79.
4. Manuseth BM. Patil-Radiological Appearances in Paranasal Sinus Disease: A Comparative Study-2005. Bijapur: Bildia's Shri B M Patil Medical College; 2005. p. 31-2.
5. Shrestha D, Yadav LK, Thapa P. Chronic maxillary sinusitis: Clinical and microbiological evaluation. J Coll Med Sci Nepal 2011;7:17-22.
6. Zojaji. CT in comparision with sinus endoscopy in CRS. Iron J Radiol 2008;5:79-80.
7. Suligavi SS, Gokale SK. Bacteriological study of chronic maxillary sinusitis with special reference to anaerobes. Clin Rhinol 2010;3:141-4.
8. Report of the rhinosinusitis task force committee meeting. Alexandria, Virginia, August 17, 1996. Otolaryngol Head Neck Surg 1997;117:S1-68.
9. Marrack P, Kappler J. The staphylococcal enterotoxins and their relatives. Science 1990;248:705-11.
10. Lanza DC, Kennedy DW. Adult rhinosinusitis defined. Otolaryngol Head Neck Surg 1997;117:S1-7.

How to cite this article: Ambika P. Correlation between Computed Tomography Scan Findings and Middle Meatal Antrostomy Findings in Cases of Maxillary Sinusitis – A Study on 50 Cases. Int J Sci Stud 2021;9(9):47-50.

Source of Support: Nil, **Conflicts of Interest:** None declared.

Print ISSN: 2321-6379
Online ISSN: 2321-595X

Original Article

A Study of Surgical Management of Abdominal Tuberculosis in Tertiary Care Centre

T Shalini[1], H Swamy Rajesh[2], S Lakshmi Kalyani[3]

[1]Associate Professor, Department of General Surgery, Government Medical College, Hyderabad, Telangana, India, [2]Assistant Professor, Department of General Surgery, ESI Medical College and Hospital, Hyderabad, Telangana, India, [3]Senior Resident, Department of General Surgery, GGH Mancherial, Hyderabad, Telangana, India

Abstract

Introduction: Tuberculosis (TB) has been one of the oldest diseases known to mankind. Along with AIDS, it has acquired the "Deadly duo" status. The role of surgery in abdominal TB is diagnostic: For etiopathological, microbiological diagnosis, therapeutic: For complications such as intestinal obstruction, perforation, and peritonitis.

Materials & Methods: This study was conducted to evaluate the surgical management of abdominal TB. Aclinical study of fifty cases of abdominal TB in Osmania General Hospital was undertaken from January 2019 to January 2021. The different surgical procedures were evaluated and results analyzed. The most common presenting complaint was abdominal pain (90%) and the most common sign was abdominal tenderness (56%).

Results: As a result, laparotomy and histopathological examination were frequently necessary to establish confirmatory diagnosis. Most of the cases were anemic and poorly nourished. The age distribution ranged from 16 to 60 years with the mean age of 32.68 years. Most common age group being the 2nd, 3rd, and 4th, decades of life contributing 74% of the total sample size. 60% were males and 40% were females with M: F ratio of 1.5:1. Radiological evidence was associated with Pulmonary TB in four patients. Abdominal ultrasound, Barium studies, CT scan, and colonoscopy were used in most of the cases. Diagnostic laparoscopy was done in nine of the cases. The most common diagnosis made was that of Sub-acute intestinal obstruction (40%). The most common site involved was the ileocecal region, in 44% of cases. Approach to the treatment was conservative, limited resection was the most common surgery performed (46%) in the present series while only 18% of cases underwent right hemicolectomy, and stricturoplasty (12%) was preferred over resection anastomosis (6%) in cases of stricture. 49 cases underwent definitive operative procedures. In one case only, biopsy was taken. One with Mesenteric cold abscess was drained.Wound infection is common (10%) in five cases. Out of the five one had burst abdomen. One patient developed fecal fistula but most of them respond well to anti-tubercular treatment (ATT), so all patients should be started on 6 months of ATT, post-operatively, and showed good results.

Conclusion: Mortality is high following surgery (8%), especially in emergency cases. All the cases that died in the present series were those who underwent any emergency procedure. The results were compared with previously published studies, with respect to objectives.

Key words: Tuberculosis, Intestinal obstruction, Stricturoplasty, Cold abscess, Fecal fistula

INTRODUCTION

Tuberculosis (TB) has been one of the oldest diseases known to mankind. Along with AIDS, it has acquired the "Deadly duo" status. Abdominal TB is a highly endemic entity. In our country, intestinal TB is the single largest cause of intestinal obstruction. The prevalence of abdominal TB could not be determined due to the lack of adequate samples from the population. Primary TB of the intestine without antecedent or associated pulmonary TB is fairly common.[1-6]

Access this article online

www.ijss-sn.com

Month of Submission : 10-2021
Month of Peer Review : 11-2021
Month of Acceptance : 11-2021
Month of Publishing : 12-2021

Abdominal TB represents the 6th most frequent form of extrapulmonary TB after lymphatic, genitourinary, bone and joint, military and meningeal TB.[7-9] Abdominal TB involves the gastrointestinal tract, peritoneum, solid viscera such as liver, spleen, pancreas., and lymph nodes. The gastrointestinal tract is involved in 65–78% of patients with peritoneal and lymph node involvement. Tuberculous bacteria will reach the gastrointestinal tract through the

Corresponding Author: Dr. H Swamy Rajesh, Department of General Surgery, ESI Medical College and Hospital, Hyderabad, Telangana, India.

blood-hematogenous spread, either ingestion of infected sputum or contiguous spread from adjacent organs.[7-15]

Perforation is a serious complication of abdominal TB associated with high morbidity and mortality.[7-23] However, in recent years, intestinal perforation, which was relatively rare in the past, has been reported more frequently.

The role of surgery in abdominal TB is:

i. Diagnostic: For etiopathological, microbiological diagnosis
ii. Therapeutic: For complications such as intestinal obstruction, perforation, and peritonitis.

Aims and Objectives

Aim

The aim of this study is to evaluate the surgical management of abdominal TB.

Objectives of the study

1. To study the various clinicopathological manifestations of abdominal TB
2. To study the various surgical treatment modalities, their complications, and their outcome in the management of abdominal TB.

MATERIALS AND METHODS

A clinical study of fifty cases of abdominal TB treated surgically in different surgical units of Osmania General Hospital, Afzal Gunj was undertaken from January 2019 to January 2021.

A collection of common and rare manifestations of abdominal TB is presented hereunder. A thorough history taking and physical examination were done. The different surgical procedures were evaluated. All the routine investigations concerning the disease were done; a few patients were subjected to special investigations. The ensuing complications of the treatment were studied and the cases were followed up.

RESULTS

Age Incidence

In this study, the age of the patients varied from 16 to 60 years. The mean age in the present series was 32.68 years. Most of the cases were in the 2nd 3rd and 4th decades of life contributing 74% of the total.

Sex Incidence

In the present series of fifty cases, 60% of cases were males and the remaining 40% formed by the females. No age difference was seen between males and females. Male: Female ratio was found to be 1.5:1.

Socio-economic Status

In the present study, except two all the patients belonged to lower socioeconomic strata of the society.

History of Pulmonary TB

In the present series, six cases had a history of pulmonary TB. One was on treatment while he presented with abdominal TB and three had discontinued the treatment the after intensive phase of DOTS.

Symptomatology

The symptoms in the present series had a duration ranging between 1 day and few years. 42% had one or more symptoms for a duration of more than 3 months. In the present series, abdominal pain was the most common presenting complaint, present in 90 % of cases. Lower abdominal pain was the commonest followed by periumbilical and generalized abdominal pain. In most cases, pain was described as colicky and intermittent. Other common symptoms were vomiting seen in 46% of patients, relief of pain on vomiting was found in most cases after vomiting. Altered bowel habits, especially constipation, were found in 52% of patients, diarrhea was found in two cases. In the present series, fever was present in 28% of cases; fever was mild to moderate, with evening rise of temperature. Abdominal distension was the presenting complaint in 44% of cases, which was generalized in ten cases and lower abdominal distension was seen in twelve cases.

Anorexia and weight loss were found in 30% of cases, most of these cases were that of sub-acute intestinal obstruction with duration of more than 2 months of complaints. Menstrual irregularities were a major complaint in 10%.

Physical Findings

In the present study, abdominal tenderness was the most common finding being seen in 56% of cases. Rebound tenderness was present in 14%, all were cases of perforative peritonitis. Abdominal distension was seen in 48% of cases, generalized distension was present in ten number of patients and lower abdomen distension was found in 12 patients. Guarding and rigidity were present in 14% of cases and all of them were cases of hollow viscus perforation and were all associated with rebound tenderness. In the present study, mass was found in 26% of cases, in most cases it was found in the right iliac fossa and only one was in the right lumbar region.

Hyperperistalasis was found in 18% of cases. Active pulmonary TB was found in four cases, one of them had extensive miliary mottling. No physical findings were found in two (4%) patients.

Mode of Presentation

In the present series of fifty cases, the most common diagnosis was that of Intestinal obstruction contributing

Table 1: Age distribution

Age in years	15–20	21–30	31–40	41–50	51–60	Total
Numbers	9	18	10	9	4	50
Percentage%	18	36	20	18	8	100%
Mean Age (in years)				32.68		

Table 2: Sex distribution

Sex	Number	Percentage
Male	30	60
Female	20	40

M: F Ratio: 1.51

Table 3: Symptoms

Symptoms	Numbers	Percentage
Abdominal pain	45	90
Altered bowel habits	26	52
V omiting	23	46
Distension	22	44
Fever	14	28
Abdominal mass	4	8
Anorexia/Weight loss	15	30
Menstrual Irregularities	5	10

Table 4: The physical findings

Signs	Numbers	Percentage
Abdominal tenderness	28	56
Distension	24	48
Mass in RIF	13	26
Hyperperistlatic bowel sounds	9	18
Guarding	7	14
Rigidity	7	14
Mass other than RIF	1	2
No findings	2	4

Table 5: Mode of presentation

Diagnosis	Numbers	Percentage
Sub-acute intestinal obstruction	20	40
Acute intestinal obstruction	10	20
Mass per abdomen	12	24
Perforative peritonitis	7	14
Acute appendicitis	1	2

60% of the total, of these, in 20% Acute intestinal obstruction was the diagnosis and in the rest of the cases, Subacute intestinal obstruction was the diagnosis, making it the single most common mode of presentation (40%).

Mass per abdomen was the modes of presentation in 24% of cases. Hollow viscus perforation with peritonitis secondary to small bowel perforation was the diagnosis in 14% of cases. One case was preoperatively diagnosed as acute appendicitis. The preoperative diagnosis was more accurate in cases with ileocecal mass and sub-acute obstruction than in cases that underwent emergency laparotomy for acute intestinal obstruction or perforative peritonitis. The most common diagnosis made other than TB was intestinal obstruction of undetermined cause or carcinoma of large bowel.

Table 6: Surgical options

Procedure	Number	Percentage
Resections in		
Limited (segmental)	23	46
Right hemicolectomy	9	18
Small bowel	6	12
Stricturoplasty	6	12
Perforation closure	2	4
Adhesionolysis	2	4
Only bypass	2	4
Only biopsy	1	2
Mesentric cold abscess drainage	1	2
Appendisectomy	1	2

Table 7: Histopathological diagnosis

Site	Pathological type	Numbers	Percentage
Intestinal	Hyperplastic	31	62
	Ulcerative	12	24
Peritoneal	Ascitic	Nil	-
	Caseous	Nil	-
	Plastic	1	2
	Mixed	Nil	-
Mesentric node		6	12

Table 8: Age incidence

Age (in years)	Bhansali (*n*=310)* (%)	Islam *et al.* (60)* (%)	Forrest *et al.* (137)* (%)	Present series (50)* (%)
15–20	16	15	16	18
21–30	41	40	35	36
31–40	25	35	20	20
41–50	8	6.6	11	18
51–60	5	3.3	5	8

Table 9: Sex incidence

Studies	Males	Females	Ratio
Bhansali (310)	150	160	1:1
Islam *et al.* (60)	25	35	0.7:1
Forrest *et al.* (137)	77	60	1.28:1
Present series (50)	30	20	1.5:1

Investigations

Blood investigations

Hemoglobin estimation was done in all cases. It ranged from 6.7 gm% to 13gm%. Of all the fifty patients in the present series, 41 cases were having hemoglobin of <11 g %. Erythrocyte sedimentation rate (ESR) was done for all the fifty cases, it ranged from 20 mm to 81 mm after 1 h. Sputum AFB was done for 10 patients, four of them showed a positive report.

Table 10: Symptomatology findings

Symptoms	Forrest *et al.* (137) (%)	Islam *et al.* (60) (%)	Present study (50) (%)
Abdominal pain	86	83.3	90
Altered bowel habits	50	71.6	52
V omiting	47	25	46
Distension	31	63	44
Fever	29	60	28
Abdominal mass	9	40	8
Anorexia/Weight loss	10	60	30
Menstrual irregularities	12	8	10

Table 11: Physical findings

Signs	Forrest *et al.* (%)	Present series (%)
Abdominal Tenderness	28	56
Distension	41	48
Mass in RIF	14	26
Hyper peristlatic Bowel Sounds	14	18
Guarding	15	14
Rigidity	15	14
Mass other than RIF	10	2
No findings	3	4

Table 12: Surgical procedures

Procedure	Forrest *et al.* (%)	Islam *et al.* (%)	Present study (%)
Resections			
Limited (segmental)	18	10	46
Right Hemicolectomy	12	63.3	18
Small bowel	31	6.6	12
Stricturoplasty	36	3.3	12
Perforation closure	5	Nil	4
Adhesionolysis	20	Nil	4
Onlybypass	18	16.6	4
Only biopsy	18	Nil	2
Others	1	Nil	2

Radiological investigations

Chest- X-ray was done for 40 cases; four of them showed features of pulmonary TB, one of them showed miliary mottling. Erect-X-ray abdomen was done for all 50 cases, of which 22 cases showed multiple air-fluid levels suggesting obstruction, seven cases had gas under diaphragm, and 21 had a normal X-ray. Barium study was done for 16 cases, of which 3 showed narrowing of ileocecal junction, third showed strictures, five showed pulled up cecum, third had ascending colon narrowing. In two cases studies were normal.

Ultrasound of the abdomen was done for cases, sonological findings were that of mass in 9, mesenteric lymph node enlargement was seen in three, 13 showed dilated air-filled bowel loops, free fluid was seen in 4 and in one case USG showed features of acute appendicitis. In nine cases USG showed no abnormality. CT scan abdomen was done for 15 cases, 13 showed ileocecal and ascending colon thickening, out of those which showed mural thickening, eight showed significant luminal narrowing.

In the present series, seven cases showed fat stranding, omental thickening and five showed mesenteric or para-aortic lymph node enlargement.

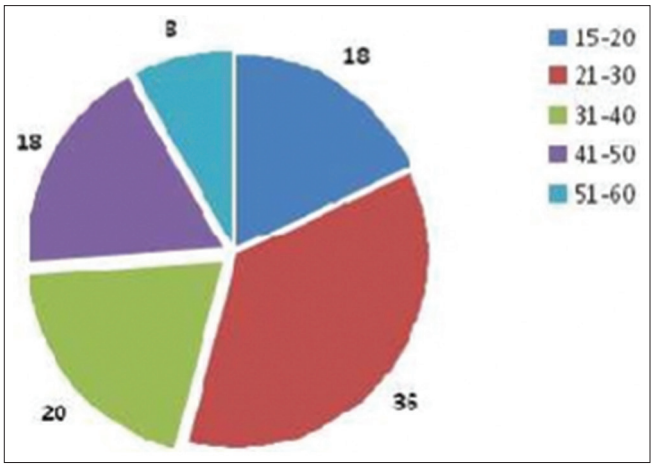

Figure 1: Chart 1: Age distribution

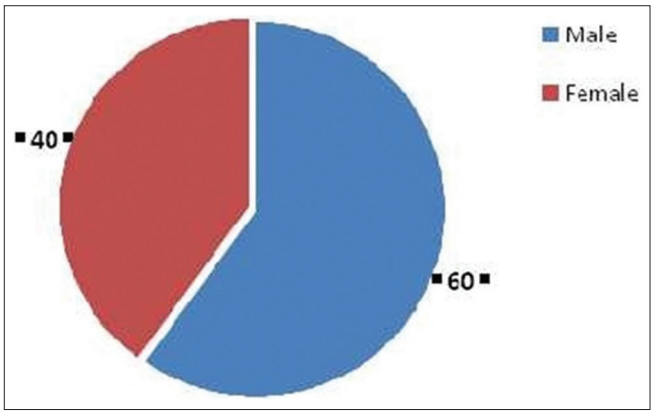

Figure 2: Chart 2: Sex distribution

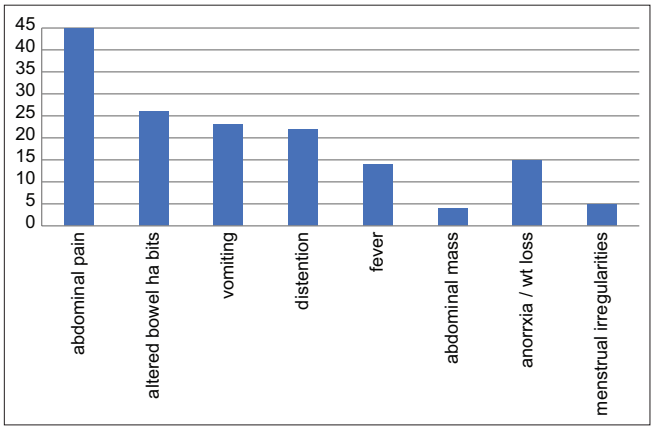

Figure 3: Graph 1 showing symptoms

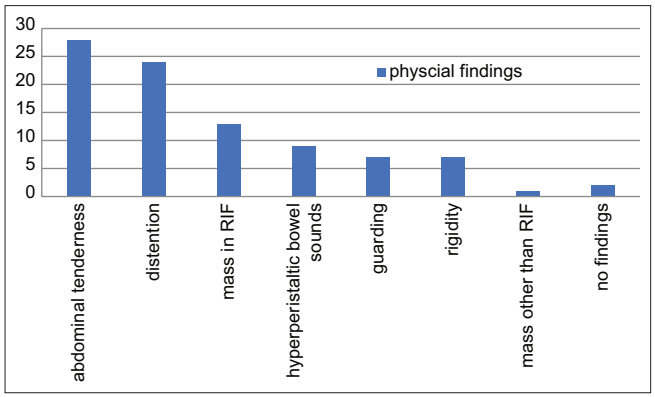

Figure 4: Graph 2-Physical findings

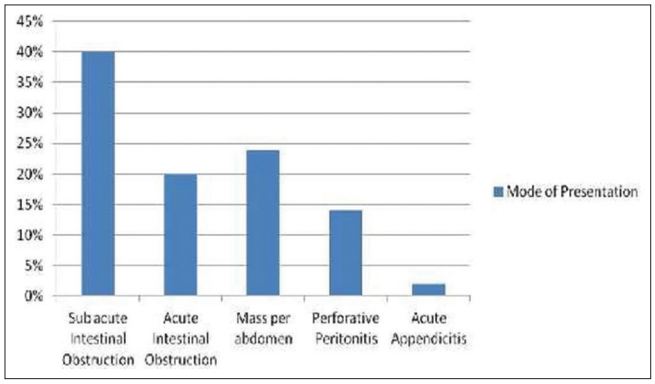

Figure 5: Graph 3: Mode of presentation

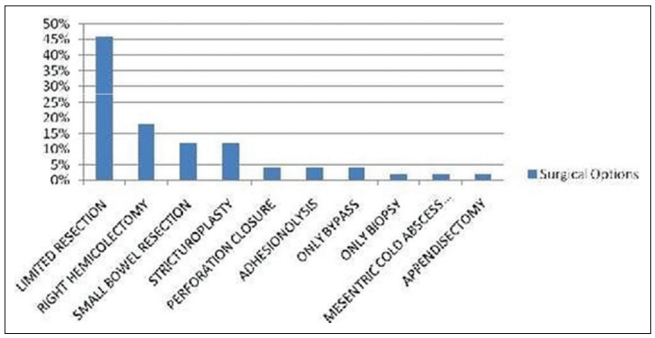

Figure 6: Graph 4: Surgical options

Other investigations

In the present series eight cases underwent colonoscopy, biopsy was taken in three, all confirming the diagnosis of TB, ascending colon narrowing was seen in seven cases, out of these three showed multiple mucosal nodules and fibrosis as well, and in one case only mucosal nodules were seen. Of the fifty cases, nine patients underwent Diagnostic Laparoscopy, and biopsy was taken in five of these cases. Small multiple whitish nodules are scattered all over the peritoneum (tubercles) were seen in four, variable degrees of omental thickening were seen in four. Ileocecal and ascending colon thickening seen in seven cases and mesenteric lymph node enlargement was seen in six of the cases who underwent the procedure, adhesions were seen in one.

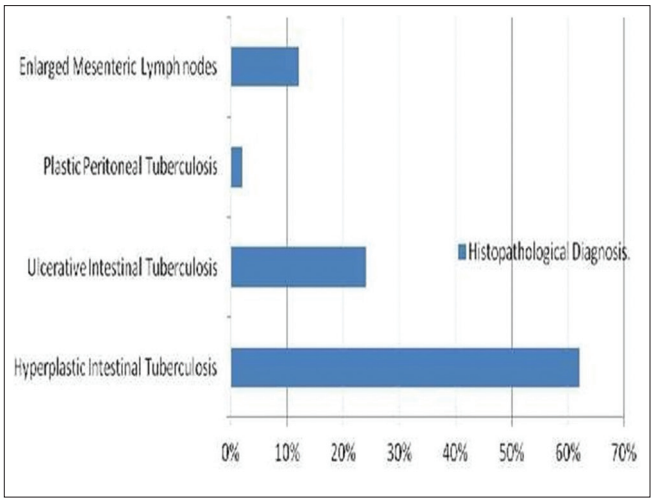

Figure 7: Graph 5: Histopathological diagnosis

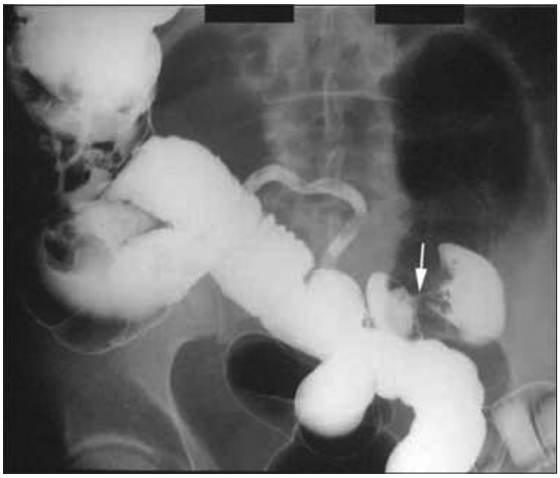

Figure 8: Barium study showing ileal stricture

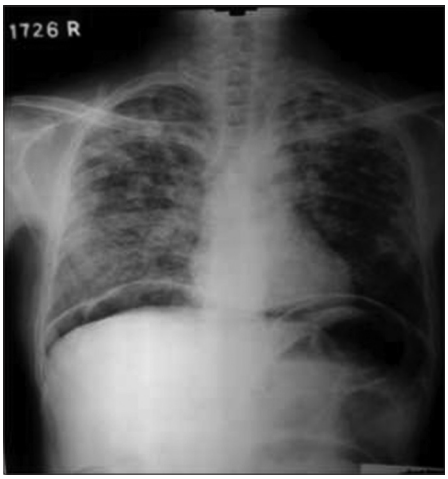

Figure 9: CXR showing B/L tuberculosis and air under diaphragm

Operative Findings

In the present series of 50 cases, forty-seven cases 94%, showed features of intestinal TB; in the remaining three, one was a case of mesenteric cold abscess at the root of

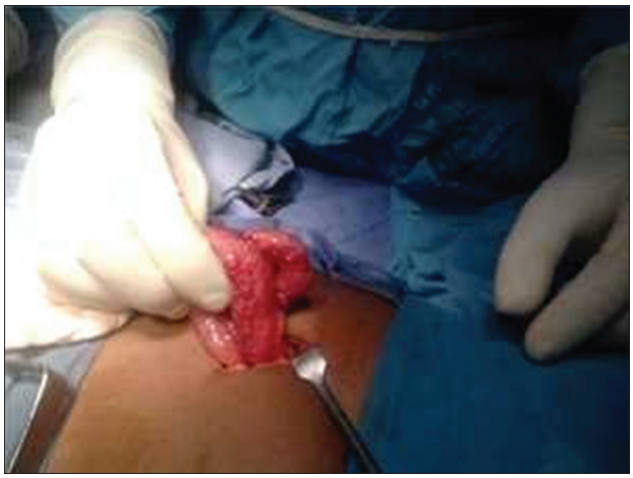

Figure 10: Tuberculosis of appendix

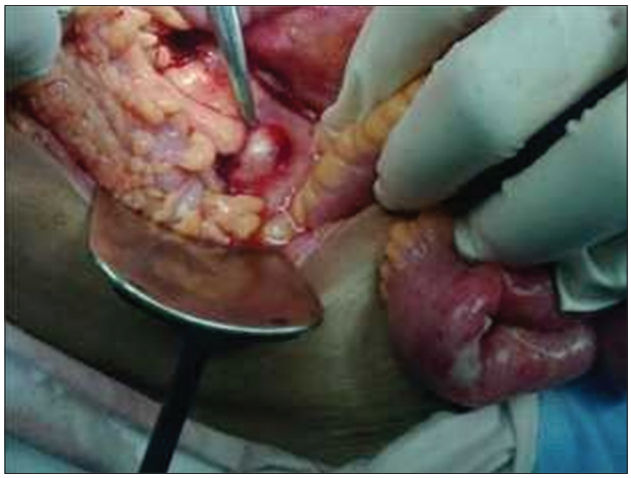

Figure 13: Mesenteric LN enlargement

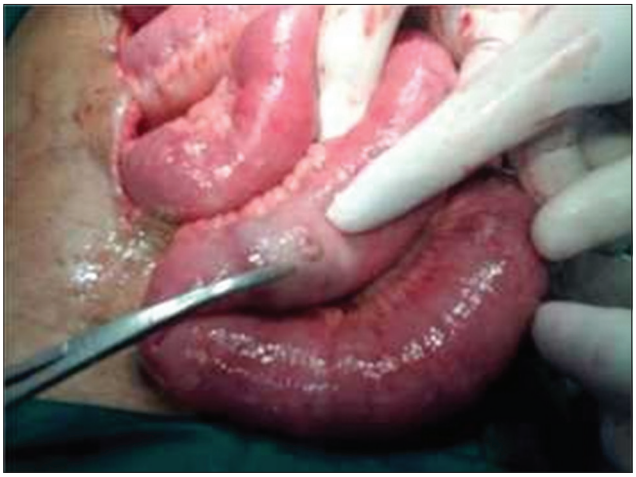

Figure 11: Tubercular ileal perforation

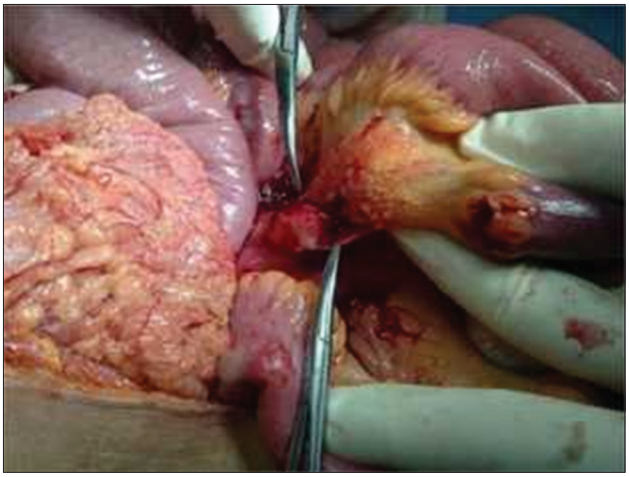

Figure 14: Mesenteric LN excision

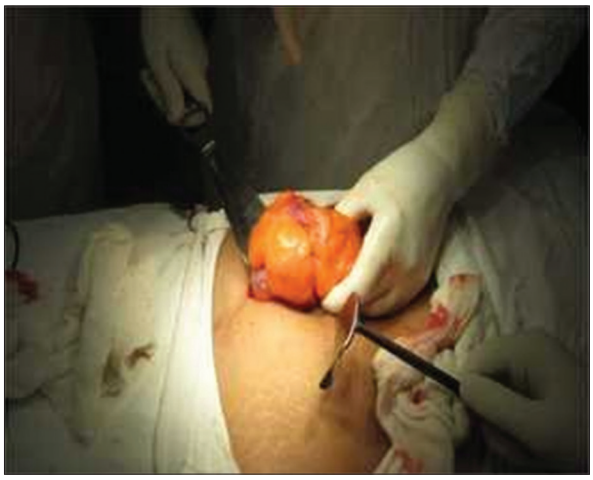

Figure 12: Ileocecal tuberculosis

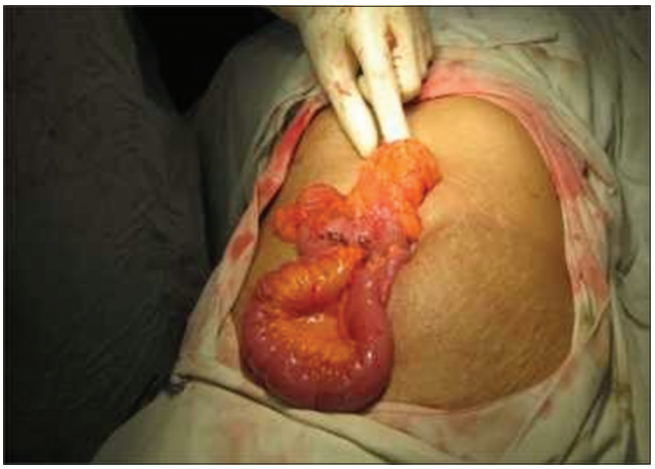

Figure 15: Right hemicolectomy

mesentery pressing on jejunum, one showed features of acute appendicitis, with severely inflamed appendix and one was a case of plastered abdomen secondary to peritoneal TB, surgery was abandoned in this case. Most of the cases had multiple findings. Of the forty-seven cases of intestinal TB, ileocecal thickening was the most common finding, present in 22 cases (44%), caecal thickening with or without ascending colon strictures was present in nine

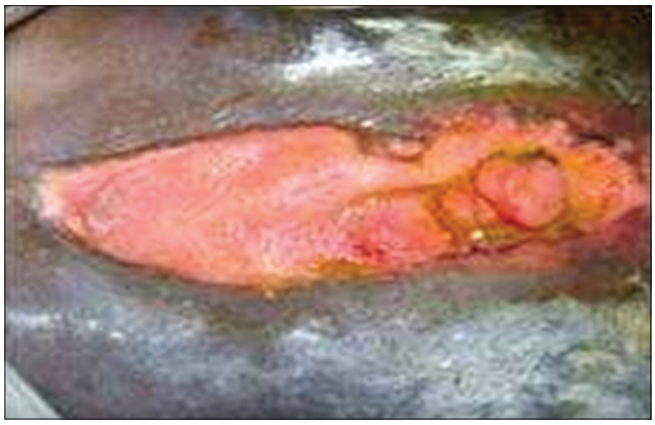

Figure 16: Faecal fistula

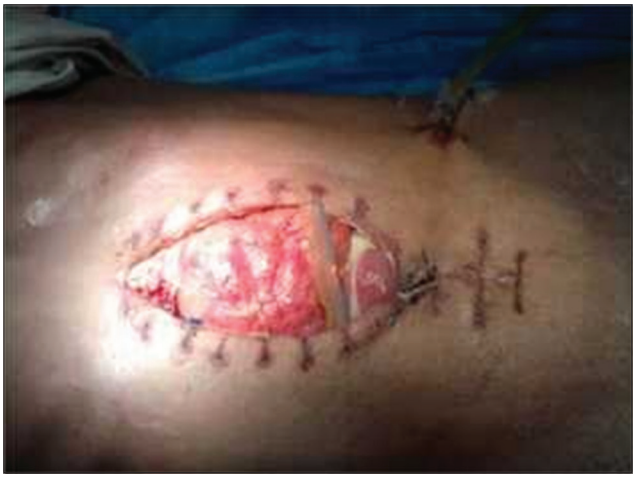

Figure 17: Burst abdomen

cases. Pulled up caecum with narrow ileocecal valve was present in three cases. One case showed sigmoid colon thickening and in one case appendicectomy was done and was later diagnosed to be TB. Small bowel strictures were found in 12 cases, two were in the jejunum, rest all were in the ileum. Ileal perforation was found in seven cases, adhesions were found in two cases. Other common findings were enlarged mesenteric lymph nodes in 14 cases and omental thickening in three cases.

Operative Management

In the present series of fifty cases, forty-nine cases underwent definitive procedure; one patient in the obstructive group had obstruction with extensive matting of the bowel. In addition, he had massive adhesions, probably from tubercular peritonitis, and was inoperable. However, operation was abandoned and only biopsy was taken. The reason for surgery in most cases was either persistent pain with suspicion of tumoral lesion, intestinal obstruction, or preoperative diagnosis of perforative peritonitis.

Most common procedure that was done, was limited (segmental) resection, including only 5 cms of ascending colon, with ileoascending colostomy, in 46% of cases. One case underwent Limited resection for sigmoid colon TB. Right Hemicolectomy was done for 18% of cases. Six cases (12%) underwent resection anastomosis of these three were having multiple strictures involving the ileum and three had perforative peritonitis.

Stricturoplasty was done for 12% of cases; one case was that of jejuna stricture and rest were of ileal stricture.

Primary closure of perforation was done in (4%) cases rest all the perforative peritonitis cases underwent resections. Adhesiolysis was done for two cases (4%). In one (2%) cases, no procedure could be done due to extensive peritoneal TB. Mesenteric lymph node biopsy was taken in14% of cases, one case underwent mesenteric cold abscess drainage and deroofing, one case underwent appendisectomy and was subsequently diagnosed to be TB, in histopathology. In two cases (4%) of ileocaecal mass, ileotransverse bypass was done.

Complications

Operative morbidity was 12%, with one or more complications. These were more frequent in patients undergoing emergency surgery. The most common complications were wound infections (10%) and pulmonary infections. One patient (2%) developed fecal fistula and one (2%) developed burst abdomen requiring re-operation. In this series of fifty cases, four patients died (8%). All four deaths occurred, are those who underwent emergency procedures and the following operation they had multiple complications.

Follow-up

All the cases had a regular follow-up at 1, 3, 6, 12, 18 months; 96% of them were relieved of the symptoms. General condition of the patients improved with weight gain and correction of anemia. All the cases were discharged on 6 months of the anti-TB treatment regimen as per the RNTCP schedule.

Pathological Consideration

In the present series of 50 cases, 48 cases were that of intestinal TB. Intestinal (including appendix) specimens were available for histopathological diagnosis in 43 cases; histopathological diagnosis was made by lymph node biopsy specimens in five cases, which showed caseation and granulomas, suggestive of TB. One case was diagnosed using Mesenteric cold abscess aspirate, and one was diagnosed using peritoneal specimen. Most common pathological diagnosis was that of hyperplastic type of intestinal TB, in 62% of cases, of which 19 presented with features of intestinal obstruction and 12 presented with mass per abdomen.

Ulcerative type of intestinal TB was found in 24% of cases, five cases had ileal perforation, six presented with intestinal obstruction, of which one had jejunal stricture and rest had ileal strictures and one case presented as mass per abdomen.

Peritoneal involvement was seen in only one case which was a case of plastic type of Tubercular peritonitis [Tables 1-12] and [Figures 1-17].

DISCUSSION

TB is still a highly prevalent disease in India like other developing countries of the world where malnutrition, overcrowding, and poor sanitary conditions exist. Intestinal TB also represents a relatively common health problem. As symptoms and signs of intestinal TB are nonspecific and there are no unequivocal diagnostic features either clinically and radiologically, many a times laparotomy and histopathological examination is needed to establish the diagnosis. In this series, 50 cases of intestinal TB with various symptoms and signs have been reported. The main focus of this study was the epidemiological observation, clinical manifestation, diagnosis, and surgical treatment of patients with intestinal TB.

The results are analyzed in comparison to various studies done on abdominal TB.

Age Incidence

About 74% cases were in 2nd, 3rd, and 4thdecades of life in the present study, while Forrest *et al.*[24] reported 71 % in the same age group, while Bhansali[25] and Islam *et al.*[26] reported 82% and 81.6%, respectively, in the same age group.

Sex Incidence

In the present series the M: F ratio was 1.5:1, while Bhansali[25] Reported a ratio of 1:1, while Forrest *et al.*[24] reported a ratio of 1.28:1, Islam *et al.*[26] reported a female preponderance with a ratio of 0.7:1.

Symptomatology

Pain abdomen was the most common symptom in the present study, present in 90% of cases. In Forrest *et al.* series,[24] it was present in 86% of subjects, while in Islam *et al.* series[26] it was present in 83.3% of subjects. Altered bowel habits were the second most significant complaint in the present series, 52% of cases had it as a presenting complaint. Forrest *et al.*[24] reported it to be present in 50% of cases, while Islam *et al.*[26] reported the symptom in 71.6% of cases in both the studies it was the second most common presenting complaint.

The other common symptoms in the present series and series by Forrest *et al.*[24] and Islam *et al.*[26] were distension, vomiting, mass per abdomen, fever, and anorexia with weight loss.

Physical Findings

Abdominal tenderness was the most common sign in this study and was present in 56% of cases, while in Forrest *et al.* series,[24] abdominal distension was the common finding being present in 41% of subjects, distension was present in 48% cases in present series. Mass per abdomen was present in 26% of subjects in the present series, while it was present in 14% of cases in Forrest *et al.* series.[24] Other findings of hyper peristaltic bowel sounds, rigidity, guarding mass other than RI F were comparable in both the series. Table 11 shows comparisons of physical findings with Forrest *et al.* series. No physical findings were found in 3% of cases in Forrest *et al.* series[24] in the present series 4% of cases had no physical findings.

Diagnosis

Diagnosis is difficult because of the presence of vague symptoms and signs with no pathognomic investigations. Das and Shukla working in an endemic area reported that diagnosis was made only in 50% of cases. Forrest *et al.*[24] reported preoperative diagnosis was made in 69% of the cases. In the present study correct preoperative diagnosis was made in 60% of cases, diagnosis was more often correct in sub-acute intestinal obstruction or mass per abdomen, than in acute obstruction or atypical presentation.

Operative Management

When surgery is done, it must suite the pathological findings (Pujari, 1979).[27] Resection of an ileocecal mass can be of limited extent rather than the classical hemicolectomy because extensive resection of bowel can lead to malabsorption (Prakash *et al.*, 1975)[28] and strictures can be treated by stricturoplasty (Katariya *et al.*, 1977)[29] can be done even in emergency (Parikh). Perforations are better handled by resection rather than oversewing (Eggleston *et al.*, 1983).[30]

In the present study of 50 cases, the approach to surgery was conservative, 49 Cases underwent surgery, of which 46% of cases underwent Limited resection and 18% cases underwent right hemicolectomy. As compared to the present study, in Forrest *et al.* series[24] 18% of the cases underwent Limited resection, while in Islam *et al.* series[26] only 10% underwent Limited resection. In Forrest *et al.* series[24] and Islam *et al.* series,[26] 12% and 63.3%, respectively, underwent right hemicolectomy. Stricturoplasty was done in12% of cases in the present series, while it was done in 36% of cases in Forrest *et al.* series,[24] while only 3.3% of patients underwent the same procedure in Islam *et al.* series.[26] Only ileotransverse by pass was done in 4% cases in the present series, while it

was done for 18% cases in Forrest *et al.* series[24] and 16.6% cases in Islam *et al.* series. Bhansali[25] even suggested that bypass patient should be subjected to a secondary excisional procedure when conditions are favorable.

Morbidity and Mortality

In the present series operative morbidity was 12%, most common complication being wound infection (10%). Wound infection is common (Pujari, 1979)[27] Forrest *et al.*[24] reported a morbidity of 36%, while Islam *et al.*[26] reported a morbidity of 8%. Mortality in the present series was low, in total four patients died (8%), all underwent emergency procedures, and no deaths were reported in elective cases. Only Islam *et al.*[26] reported mortality lower than the present study, no cases died in their study. In Forrest *et al.*[24] series, it was 3% In elective surgery and 18% in emergency, while Bhansali[25] reported it as 2% and 24% respectively.

Follow-up with 6 months of antitubercular treatment gave excellent results in 90% of patients after surgery.

CONCLUSION

A study on surgical management of abdominal TB was done on 50cases. The following conclusion can be obtained from the study.

1. The signs and symptoms of intestinal TB are protean and nonspecific, and there are non-equivocal diagnostic features either clinically or radiologically. The most common presenting complaint was abdominal pain (90%) and the most common sign was abdominal tenderness (56%). As a result, laparotomy and histopathological examination were frequently necessary to establish confirmatory diagnosis. Most of the cases were anemic and poorly nourished
2. Most common age group being the 2nd, 3rd, and 4th, decades of life contributing 74% of the total sample size
3. The M: F ratio in the present series was 1.5:1
4. Diagnosis is difficult in absence of active pulmonary disease, four patients had active pulmonary disease, and accuracy of diagnosis was 60%. It was more difficult in cases of emergency laparotomy, the nature of the obstruction may go unrecognized, particularly in patients having acute symptoms or caecal masses may be thought to be malignant. The most common diagnosis made was that of sub-acute intestinal obstruction (40%)
5. The most common site involved was the ileocecal region, in 44% of cases
6. The approach to surgery should be conservative, with the aim of saving maximum bowel length, so limited resection was the most common surgery performed (46%) in the present series while only 18% of cases underwent right hemicolectomy, and stricturoplasty (12%) was preferred over resection anastomosis (6%) in cases of stricture
7. Wound infection is common (10%), but most of them respond well to anti-tubercular treatment (ATT), so all patients should be started on 6 months of ATT, post-operatively. Mortality is high following surgery (8%), especially in emergency cases. All the cases that died in the present series were those who underwent any emergency procedure.

SUMMARY

1. Fifty cases of abdominal TB were studied between January 2019 and January 2021 in different surgical units of Osmania General Hospital (Tertiary Care Centre) Afzalgunj
2. The results were compared with previously published studies, with respect to objectives
3. The age distribution ranged from 16 to 60 years with the mean age of 32.68 years. 74% of cases were in second, third, and fourth decades of life. About 60% were males and 40% were females with M: F ratio of 1.5:1
4. Abdominal pain was the most common manifestation in the present series found in 90% of cases. Abdominal distention, vomiting, mass per abdomen, loss of weight, loss of appetite, and fever were the other common complaints
5. Abdominal tenderness was the most common physical finding (56%), followed by distention (48%) and mass per abdomen (26%). Most patients were anemic. 82% of the cases had Haemoglobin levels <11 g/dl. Raised ESR above 20mm at the end of 1 h was found in all cases. Radiological evidence was associated with pulmonary TB in four patients. Abdominal ultrasound, Barium studies, CT scan, and colonoscopy were used in most of the cases. Diagnostic laparoscopy was done in nine of the cases
6. The most common site was the intestine and the ileocecal region (44%) being the most common site in the intestine
7. Approach to the treatment was conservative, where Limited (Segmental) resection (46%) was preferred over right hemicolectomy (18%). 49 cases underwent definitive operative procedures. In one case only, biopsy was taken. One with Mesenteric cold abscess was drained
8. Five cases devoloped post-operative wound infection, out of the five one had burst abdomen. One patient developed fecal fistula. Four patients (8%) died in the post-operative period. All the cases that were

discharged were advised 6 months of ATT, and showed good results.

REFERENCES

1. Addison NV. Abdominal tuberculosis--a disease revived. Ann R Coll Surg Engl 1983;65:105-11.
2. Paustian FF. Tuberculosis of the intestine. In: Bockus H, editor. Gastroenterology. Philadelphia, PA: Saunders; 1976. p. 750-74.
3. Hunter J. From: works of John Hunter. In: Lectures on Surgery. Vol. 1. Cambridge: Cambridge University Press; 1835. p. 567.
4. Abercrombie J. Pathological and Practical Researches on Diseases of the Stomach, the Intestinal Canal, the Liver and Other Viscera of the Abdomen. Edinburgh: Read Books Design; 1928. p. 191-4.
5. Boyd WV. Surgical Pathology. London. Saunders Co.; 1925. p. 306.
6. Stewart MJ. The pathology of intestinal tuberculosis. Tubercle 1928;13:409-13.
7. Marshall JB. Tuberculosis of the gastrointestinal tract and peritoneum. Am J Gastroenterol 1993;88:989-99.
8. Aston NO. Abdominal tuberculosis. World J Surg 1997;21:492-9.
9. Kapoor VK. Abdominal tuberculosis: The Indian contribution. Indian J Gastroenterol 1998;17:141-7.
10. Kapoor VK. Abdominal tuberculosis. Postgrad Med J 1998;74:459-67.
11. Das P, Shukla HS. Clinical diagnosis of abdominal tuberculosis. Br J Surg 1976;63:941-6.
12. Bhansali SK. Abdominal tuberculosis: Experience with 300 cases. Am J Gastroenterol 1971;67:324-37.
13. Prakash A. Ulcero-constrictive tuberculosis of the bowel. Int Surg 1978;63:23-9.
14. Horvath KD, Whelan RL. Intestinal tuberculosis: Return of an old disease. Am J Gastroenterol 1998;93:692-6.
15. Tandon HD. The pathology of intestinal tuberculosis and distinction from other diseases causing stricture. Trop Gastroenterol 1981;2:77-93.
16. Paustian FF, Bockus HL. So-called primary ulcero hypertrophic ileocecal tuberculosis. Am J Med 1959;27:509-18.
17. Paustian FF, Marshall JB. Intestinal tuberculosis. In: Berk JE, editor. Bockus Gastroenterology. 4th ed. Philadelphia, PA: WB Saunders; 1985. p. 2018-36.
18. Prakash A, Tandon HD, Nirmala L, Wadhwa SN, Prakash O, Kapur M. Chronic ulcerative lesions of the bowel. Indian J Surg 1970;32:1-14.
19. Tandon HD, Prakash A. Pathology of intestinal tuberculosis and its distinction from Crohn's disease. Gut 1972;13:260-9.
20. Howell JS, Knapton PJ. Ileocaecal tuberculosis. Gut 1964;5:524-9.
21. Talwar S, Talwar R, Prasad P. Tuberculous perforations of the small intestine. Int J Clin Pract 1999;53:514-8.
22. Seabra J, Coelho H, Barros H, Alves JO, Gonçalves V, Rocha-Marques A. Acute tuberculous perforation of the small bowel during anti-tuberculosis therapy. J Clin Gastroenterol 1993;16:320-2.
23. Wig JD, Malik AK, Chaudhary A, Gupta NM. Free perforations of tuberculous ulcers of the small bowel. Indian J Gastroenterol 1985;4:259-61.
24. Ecgleston FC, Deodhar MC, Kumar A. Surgery in abdominal tuberculosis results in 137 cases. Ind J Tub 1983;30:139-45.
25. Bhansali SK. Abdominal tuberculosis: Experience with 300 cases. Am J Gastroenterol 1971;67:324-37.
26. Islam MB, Rahman MK, Islam MK, Mahmudul Haq SM, *et al*. Clincopathological study of abdominal tuberculosis and its management. TAJ 2003;16:24-7.
27. Pujari BD. Modified surgical procedures in intestinal tuberculosis. Br J Surg 1979;66:180-1.
28. Prakash A. Ulcero-constrictive tuberculosis of the bowel. Int Surg 1978;63:23-9.
29. Katariya RN, Sood S, Rao PG, Rao PL. Stricturoplasty for tubercular strictures of the castro-intestinal tract. Br J Surg 1977;64:496-8.
30. Eggleston FC, Deodhar MC, Kumar A. Tuberculous perforation of the bowel-results in 21 cases. Trop Gastroenterol 1983;4:164-7.

How to cite this article: Shalini T, Rajesh S, Kalyani SL. A study of surgical management of abdominal tuberculosis in Tertiary Care Centre. Int J Sci Stud 2021;9(9):51-60.

Source of Support: Nil, **Conflicts of Interest:** None declared.

Print ISSN: 2321-6379
Online ISSN: 2321-595X

Original Article

A Comparative Study of Modified Bauermeister Grading System and Semiquantitative Bone Marrow Fibrosis Grading System by WHO (2016)

Amandeep Kaur[1], Sarita Nibhoria[2], Shaminder Kaur[3]

[1]Senior Resident, Department of Pathology, Guru Gobind Singh Medical College, Faridkot, Punjab, India, [2]Professor and Head, Department of Pathology, Guru Gobind Singh Medical College, Faridkot, Punjab, India, [3]Associate Professor, Department of Medicine, Guru Gobind Singh Medical College, Faridkot, Punjab, India

Abstract

Introduction: Bone marrow (BM) fibrosis is defined as an increase in BM stromal fiber content resulting from an abnormal and excessive deposition of collagen and reticulin fibers. In BM biopsies, stromal structural fibers are detected by special stains such as reticulin and masson's trichrome stains. Increased reticulin staining is associated with many benign and malignant conditions while increased masson's trichrome staining is prominent in late stages of severe myeloproliferative diseases or following tumor metastasis to BM.

Objectives: This study was done to study BM fibrosis by Modified Bauermeister Grading System and Semiquantitative BM Fibrosis Grading System by WHO (2016).

Materials and Methods: This study was conducted over a period of 1 year and included all the patients coming to the Department of Pathology, GGS Medical College, Faridkot for BM examination. BM biopsies were subjected to routine H&E staining along with reticulin and masson's trichrome staining to assess the grade of BM fibrosis. The completed proforma was compiled and data obtained were presented and statistically analyzed.

Results: (1) The study comprised 300 cases of hematological disorders. (2) Majority of the cases were of erythroid hyperplasia, followed by myeloproliferative neoplasms (MPN) and lymphoproliferative disorders. (3) Significant fibrosis was seen in 107 cases (35.6%).

Conclusion: High Grades of fibrosis (Modified Bauermeister Grade 3 and 4, WHO Grade 2 and 3) were seen in Metastatic deposits (5 out of 6 cases) and MPN (28 out of 77 cases). Our results obtained for grading of fibrosis in BM were almost similar by Modified Bauermeister Grading System as well as by Semiquantitative BM Fibrosis Grading System by the WHO. Modified Bauermeister Grading System is complex and time-consuming in contrast to the WHO Grading system which is much simpler. Therefore, we conclude that WHO Grading System should be widely used in grading BM Fibrosis.

Key words: Bone marrow, Bone marrow fibrosis, Myelofibrosis, Reticulin, Collagen

INTRODUCTION

Bone marrow (BM) fibrosis is defined as an increase in BM stromal fiber content resulting from an abnormal and excessive deposition of collagen and reticulin fibers derived from marrow fibroblasts.[1-3] BM fibrosis is a common morphological finding in trephine biopsies that carries diagnostic and prognostic significance in various hematological and non-hematological disorders. Elevation of cytokines such as IL-6, IL-2, IL-8, tumor necrosis factor-α, γ-interferon, and profibrogenic growth factors such as transforming growth factor β, basic fibroblast growth factor,and vascular endothelial growth factor are thought to mediate BM fibrosis.[4-7]

In BM biopsies, stromal structural fibers are not well appreciated on routine hematoxylin and eosin stain and are detected by special stains such as Reticulin and Masson's trichrome stains. BM biopsy sections can be stained for reticulin using a silver impregnation

Access this article online

www.ijss-sn.com

Month of Submission : 10-2021
Month of Peer Review : 11-2021
Month of Acceptance : 11-2021
Month of Publishing : 12-2021

Corresponding Author: Dr. Sarita Nibhoria, Department of Pathology, Guru Gobind Singh Medical College, Faridkot, Punjab, India,

technique.[8] Masson's trichrome stain can be used to identify collagen.[9,10]

Increased reticulin staining (reticulin fibrosis) is associated with many benign and malignant conditions while increased masson's trichrome staining (collagen fibrosis) is prominent in late stages of severe myeloproliferative diseases or following tumor metastasis to BM.[11]

The clinical significance of reticulin fibrosis is well established in primary myelofibrosis (PMF).[12] BM fibrosis has also been evaluated in other myeloproliferative neoplasms (MPN), in particular chronic myeloid leukemia.[13,14] Moderate to marked reticulin fibrosis, which correlates with increased numbers of megakaryocytes and may be associated with an enlarged spleen has been reported in 30–40% cases of CML at diagnosis.[15,16]

Significant degrees of myelofibrosis (corresponding to grade 2 or 3 of the WHO grading scheme) are observed in 10-15% of MDS cases and these cases have been referred to as MDS with fibrosis.[17]

An increase in BM stromal fibers has also been reported in children and adults with acute lymphoblastic leukemia and in adults with acute myeloid leukemia.[18,19]

Lymphoid myelofibrosis represents a particular and rare entity in which medullary fibrosis associated with abnormal lymphoproliferation replaces normal hematopoiesis. Hairy cell leukemia is one of the most known lymphoma in which MF is frequently encountered and often results in a so-called dry tap (i.e. failure to obtain aspirate on attempted BM aspiration); however, the association with other lymphoproliferation is rarely described. Rare cases have been reported in multiple myeloma, T-cell lymphoma, marginal cell, and lymphoplasmacytic lymphoma.[20-23] In very few cases of chronic lymphocytic leukemia (CLL), there may be associated marrow fibrosis.

Several grading systems have been developed over the years to evaluate the severity of BMF. The two most widely used systems include the Bauermeister system, subsequently modified by Manoharan *et al.* and Bain *et al.*, which assesses fibrosis on a scale of 0–4, and the revised European Consensus system, which uses a 0–3 scale to provide a semiquantitative assessment of BMF.[9,19,24,25] Revised European consensus system proposed by Thiele *et al.* has been accepted in the WHO classification of tumors of hematopoietic and lymphoid tissues.

Modified Bauermeister Grading System[9]

- Grade 0 - No reticulin fibers demonstrable
- Grade 1 - Occasional fine individual fibers and foci of a fine fibre network
- Grade 2 - Fine fiber network throughout most of the section; no coarse fibers
- Grade 3 - Diffuse fiber network with scattered, thick, coarse fibers but no mature collagen (negative trichrome staining)
- Grade 4 - Diffuse, often coarse fiber network with areas of collagenization (positive trichrome staining).

Semiquantitative BM Fibrosis Grading System by the WHO[26]

- Grade 0 (MF-0) - Scattered linear reticulin with no intersections (cross-overs), corresponding to normal BM
- Grade 1 (MF-1) - Loose network of reticulin with many intersections, especially in perivascular areas
- Grade 2 (MF-2) - Diffuse and dense increase in reticulin with extensive intersections, occasionally with focal bundles of thick fibers mostly consistent with collagen and/or associated with focal osteosclerosis
- Grade 3 (MF-3) - Diffuse and dense increase in reticulin with extensive intersections and coarse bundles of thick fibers consistent with collagen usually associated with osteosclerosis.

Accurate assessment of the fibrous BM matrix is clinically important for staging of MPN and MDS.[27-30] Convincing evidence has been produced by several groups that the degree of BM fibrosis is linked to overall survival in patients with MPN.[31,32]

The present study was done to study BM fibrosis by Modified Bauermeister Grading System and Semiquantitative BM Fibrosis Grading System by the WHO (2016).

MATERIALS AND METHODS

This present study was conducted over a period of 1 year from Nov 2019 to Nov 2020 in the Department of Pathology, GGS Medical College, Faridkot (Punjab) with the aim to study BM fibrosis pattern in various hematological disorders.

Study Design

Prospective study.

Inclusion Criterion

All patients were referred to the Department of Pathology for BM studies during the study period.

Sample Size

In this study, 300 cases were taken.

Methodology

All patients who were referred to the Department of Pathology in Guru Gobind Singh Medical College for BM studies were included in the study.

The data of the patients were obtained from the patient's case sheets, BM report forms, and histopathology forms. They were clinically examined for any positive clinical signs such as organomegaly and lymphadenopathy.

The patient's details were recorded with respect to age, gender, occupation, presenting features, or clinical features. In this study, investigations done were blood counts, peripheral blood smear findings, BM studies along with special stains. Initially, complete blood counts and PBF examination were done on each and every patient followed by BM studies (aspiration as well as biopsy).

BM biopsies were subjected to routine H&E staining along with reticulin and masson's trichrome staining to assess the grade of BM fibrosis.

The completed proforma was compiled and data obtained were presented and statistically analyzed and valid conclusions were drawn. Appropriate statistical methods were applied as per requirement.

Statistics

All characteristics were summarized descriptively. For continuous variables, the summary statistics of mean ± standard deviation were used. For categorical data, the number and percentage were used in the data summaries and diagrammatic presentation. Chi-square test was used for the association between two categorical variables and McNemar's Test for exploring the difference across paired observations.

RESULTS

1. The study comprised of 300 cases of hematological disorders. The majority of the patients were in the age group of 51–60 years
2. The majority of the patients were males constituting 58.7% of the total with M: F ratio of 1.42:1
3. Fever was the chief clinical feature in majority of cases (58%) followed by splenomegaly (42.3%). Splenomegaly (61.7%) was significantly more common in patients presenting with bone marrow fibrosis ($P < 0.001$)
4. Of 300 cases, 100 cases (33.3%) were of erythroid hyperplasia, 77 cases (25.7%) of MPN, 63 cases (21%) of lymphoproliferative disorders, 16 cases (5.3%) of ITP, 12 cases (4%) of acute leukemia, 11 cases (3.7%) of aplastic anemia, 6 cases (2%) of metastatic deposits, 4 cases (1.3%) of storage disorder, and 4 cases (1.3%) of MDS, 3 cases (1%) of granulomatous pathology, 2 cases (0.7%) of idiopathic hypereosinophilia, 1 case (0.3%) each of haemophagocytic lymphohistiocytosis and leukemoid reaction
5. Peripheral blood analysis showed mean Hb of 9.2 g/dl, mean TLC of 51900/mm^3, and mean Platelets of 229786.7/mm^3
6. Out of 300 cases, Modified Bauermeister Grade 0 was seen in 103 cases (34.3%), Grade 1 in 90 cases (30%), Grade 2 in 59 cases (19.7%), Grade 3 in 16 cases (5.3%), and Grade 4 in 32 cases (10.7%). Significant fibrosis (more than or equal to Grade 2) was seen in 107 cases (35.6%) [Table 1 and Figures 1 and 2].
7. Out of 300 cases, the WHO Grade 0 was seen in 193 cases (64.3), Grade 1 in 61 cases (20.3%), Grade 2 in 34 cases (11.3%), and Grade 3 in 12 cases (4%). According to WHO grading, bone marrow fibrosis (more than or equal to Grade 1) was seen in 107 cases constituting upto 35.6% of total cases [Table 2 and Figures 1 and 2].
8. High grades of fibrosis (MB Grade 3 and 4, WHO Grade 2 and 3) were seen in Metastatic deposits (5 out of 6 cases) and MPN (28 out of 77 cases) [Figure 3]
9. The early and late stages of bone marrow fibrosis graded by Modified Bauermeister and WHO grading systems yielded a statistically non-significant ($P = 0.48$) difference in the bone marrow biopsy specimens [Table 3].

DISCUSSION

The present study was conducted over a period of 1 year on 300 patients referred to the Department of Pathology, Guru Gobind Singh Medical College, Faridkot for bone marrow studies.

In our study, the patients belonged to all age groups with the majority of patients in the age group of 51–60 years. The mean age was 42.4 years. Mean age of the patients presenting with bone marrow fibrosis was 46.5 years. Similar findings were reported in a study conducted by Kazi *et al.* on 160 cases where the patients belonged to all age groups with a mean age of 43.5 years.[33]

In the present study, the majority of the patients were males constituting 58.7% of the total with M: F ratio of 1.42:1. Out of 107 patients presenting with bone marrow fibrosis, 67 were male (62.6%) and 40 were female (37.4%), and M: F ratio was 1.7:1. Kazi *et al.* in their study reported a slightly higher male: female ratio of 4.5:1.[33] M: F ratio was 4:5 in a study conducted by Priyathersini *et al.* in contrast to our study.[34]

The majority of patients in our study presented with fever (58%) followed by splenomegaly (42.3%). Splenomegaly (61.7%) was significantly more common in patients presenting with bone marrow fibrosis ($P < 0.001$) as

Table 1: Distribution of Haematological disorders according to Modified Bauermeister grading system

Haematological disorders	Total cases	MB Grade									
		Grade 0		Grade 1		Grade 2		Grade 3		Grade 4	
		n	%	*n*	%	*n*	%	*n*	%	*n*	%
Erythroid hyperplasia	100	51	51.0	37	37.0	10	10.0	2	2.0	0	0.0
Myeloproliferative neoplasms	77	10	13.0	16	20.8	23	29.9	8	10.4	20	26.0
Lymphoproliferative disorders	63	17	27.0	20	31.7	16	25.4	4	6.3	6	9.5
ITP	16	11	68.8	4	25.0	1	6.3	0	0.0	0	0.0
Acute leukemia	12	2	16.7	4	33.3	3	25.0	2	16.7	1	8.3
Aplastic anaemia	11	6	54.5	3	27.3	2	18.2	0	0.0	0	0.0
Metastatic deposits	6	0	0.0	1	16.7	0	0.0	0	0.0	5	83.3
Storage disorder	4	1	25.0	0	0.0	3	75.0	0	0.0	0	0.0
Granulomatous pathology	3	0	0.0	2	66.7	1	33.3	0	0.0	0	0.0
MDS	4	3	75.0	1	25.0	0	0.0	0	0.0	0	0.0
Idiopathic hypereosinophilia	2	1	50.0	1	50.0	0	0.0	0	0.0	0	0.0
Haemophagocytic lympho-histiocytosis	1	1	100.0	0	0.0	0	0.0	0	0.0	0	0.0
Leukemoid reaction	1	0	0.0	1	100.0	0	0.0	0	0.0	0	0.0
Total	300	103	34.3	90	30.0	59	19.7	16	5.3	32	10.7

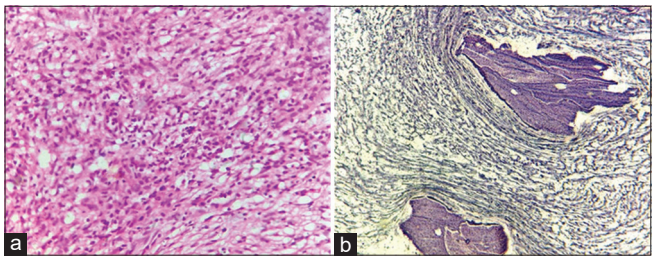

Figure 1: (a) Bone marrow biopsy section of hairy cell leukemia demonstrating fried egg appearance. (H&E stain: ×400). (b) Bone marrow biopsy section of hairy cell leukemia demonstrating MB Grade 3 and WHO Grade 2 (Reticulin stain: ×400)

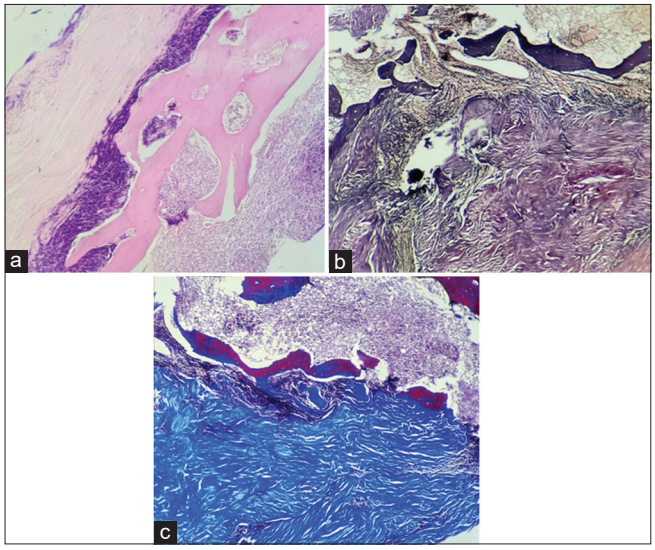

Figure 2: (a) Bone marrow biopsy section of CLL with myelofibrosis. (H&E stain: ×100). (b) Bone marrow biopsy section of CLL with Myelofibrosis demonstrating MB Grade 4 and WHO Grade 3 (Reticulin stain: ×100). (c) Bone marrow biopsy section of CLL with myelofibrosis demonstrating Collagen Grade 3 and Osteosclerosis Grade 2 (Masson's Trichrome stain: ×100)

compared to patients without bone marrow fibrosis. Splenomegaly (59%) was also the most common clinical presentation in a study conducted by Kazi *et al.*[33]

Distribution of Haematological Disorders

On stratification of the hematological disorders in the current study, it was found that out of 300 cases, 100 cases (33.3%) were of erythroid hyperplasia, 77 cases (25.7%) of MPN, 63 cases (21%) of lymphoproliferative disorders, 16 cases (5.3%) of ITP, 12 cases (4%) of acute leukemia, 11 cases (3.7%) of aplastic anemia, 6 cases (2%) of metastatic deposits, 4 cases (1.3%) of storage disorder, 4 cases (1.3%) of MDS, 3 cases(1%) of granulomatous pathology, 2 cases (0.7%) of idiopathic hypereosinophilia, 1 case (0.3%) each of haemophagocytic lymphohistiocytosis and leukemoid reaction. In accordance with our results, maximum cases were of erythroid hyperplasia (18.75%) in a study conducted by Kazi *et al.*[33] Shehata *et al.* in their study on 50 BM biopsy samples included maximum of 22 cases (44%) of reactive bone marrow, 14 cases of lymphoproliferative disorders (24%), 7 cases (14%) of MPN, 4 cases of metastasis (8%), and 3 cases (6%) of acute leukemia.[35]

Modified Bauermeister Grading in Haematological Disorders

In the present study, Grade 0 was seen in 103/300 cases (34.3%), Grade 1 in 90/300 cases (30%), Grade 2 in 59/300 cases (19.7%), Grade 3 in 16/300 cases (5.3%), and Grade 4 in 32/300 cases (10.7%). Significant fibrosis was seen in 107 cases constituting 35.6% (MB grade more than or equal to 2). In a study conducted by Shehata *et al.*, grade 0 was noted in 56% of cases, Grade 1 in 6% of cases, Grade 2 in 18% of cases, and Grade 3 in 12% cases, and Grade 4 in 8% cases. Significant fibrosis was noted in 38% of cases.[35] These findings were nearly parallel to the observations in our study.

Table 2: Distribution of haematological disorders according to semiquantitative bone marrow fibrosis grading system by WHO (2016)

Haematological disorders	Total cases	WHO Grade							
		Grade 0		Grade 1		Grade 2		Grade 3	
		n	%	*n*	%	*n*	%	*n*	%
Erythroid hyperplasia	100	88	88.0	12	12.0	0	0.0	0	0.0
Myeloproliferative neoplasms	77	26	33.8	23	29.9	24	31.2	4	5.2
Lymphoproliferative disorders	63	37	58.7	16	25.4	7	11.1	3	4.8
ITP	16	15	93.8	1	6.3	0	0.0	0	0.0
Acute leukemia	12	6	50.0	3	25.0	3	25.0	0	0.0
Aplastic anaemia	11	9	81.8	2	18.2	0	0.0	0	0.0
Metastatic deposits	6	1	16.7	0	0.0	0	0.0	5	83.3
Storage disorder	4	1	25.0	3	75.0	0	0.0	0	0.0
Granulomatous pathology	3	2	66.7	1	33.3	0	0.0	0	0.0
MDS	4	4	100.0	0	0.0	0	0.0	0	0.0
Idiopathic hypereosinophilia	2	2	100.0	0	0.0	0	0.0	0	0.0
Haemophagocytic lympho-histiocytosis	1	1	100.0	0	0.0	0	0.0	0	0.0
Leukemoid reaction	1	1	100.0	0	0.0	0	0.0	0	0.0
Total	300	193	64.3	61	20.3	34	11.3	12	4.0

Table 3: Association of modified Bauermeister grading system with semiquantitative bone marrow fibrosis grading system by WHO (2016)

MB Grade	WHO Grade		
	Early Fibrosis (Grade 0, 1)	Late Fibrosis (Grade 2, 3)	Total
Early Fibrosis (Grade 0, 1, 2)	252	0	252
Late Fibrosis (Grade 3, 4)	2	46	48
Total	254	46	300

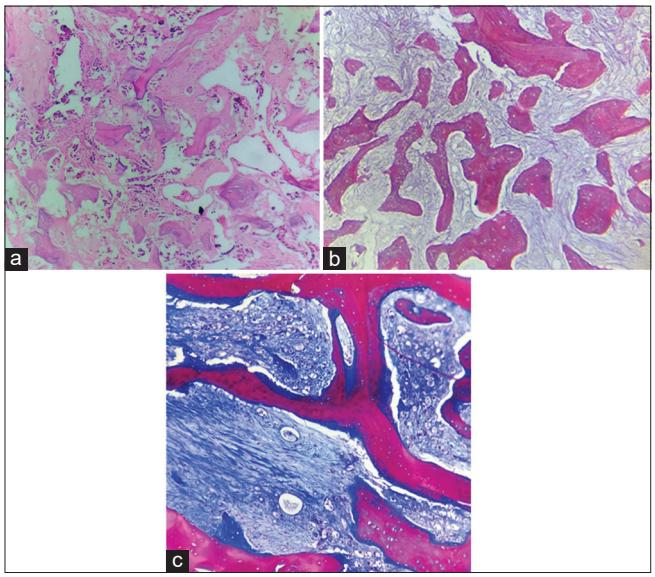

Figure 3: (a) Bone marrow biopsy section of Metastatic Deposits. (H&E stain: ×100). (b) Bone marrow biopsy section of metastatic deposits demonstrating MB Grade 4 and WHO Grade 3 (Reticulin stain: ×100). (c) Bone marrow biopsy section of Metastatic Deposits demonstrating Collagen Grade 3 and Osteosclerosis Grade 3 (Masson's Trichrome stain: ×100)

MPN constituted 77 cases (25.7%) out of 300 cases. On further stratification, 69 cases (89.6%) were of CML, 3 cases (3.9%) of PMF-overt fibrotic stage, 2 cases (2.6%) each of essential thrombocythemia and polycythemia vera, and 1 case (1.3%) of PMF-Pre fibrotic stage. MB Grade 0 was seen in 10 cases (13%), Grade 1 in 16 cases (20.8%), Grade 2 in 23 cases (29.9%), Grade 3 in 8 cases (10.4%) and Grade 4 in 20 cases (26%). In accordance with our study showing 66.3% of cases with significant fibrosis, Shehata *et al.* also found that significant fibrosis was present in 71.4% of cases. Grade 2, 3 and 4 were given in 14.3%, 42.8% and 14.3% of cases, respectively.[35] Our study reported significant fibrosis (Grade 2, 3, and 4) in 43/69 cases (62.3%) of CML. Grade 2 and Grade 4 were the most evident grades present in 26.08% and 24.63% of cases, respectively. Similar results were reported in a study conducted by Jesus *et al.* in 22 patients with CML, who reported significant fibrosis in 59.09% of samples.[36]

The present study concluded 63 cases (21%) of lymphoproliferative disorders out of 300 cases. On further stratification, 38 cases were of CLL constituting 60.3%, followed by 14 cases (22.2%) of Multiple myeloma, 8 cases (12.7%) of NHL, 2 cases (3.2%) of Hairy cell leukemia, and 1 case (1.6%) of Plasma cell leukemia. MB Grade 0 and Grade 1 were seen in majority of cases (37/63) constituting upto 58.7%, Grade 2 in 16 cases (25.4%), Grade 3 in 4 cases (6.3%), and Grade 4 in 6 cases (9.5%). Concordant results were obtained by Shehata *et al.*, who assessed BM fibrosis in 14 cases with LPDs, Grade 0 was reported as the most evident grade in 71.5% of cases, and Grade 3 and 4 were seen only in 14.3% of cases.[35] The present study reported significant fibrosis in 11 out

of 38 cases of CLL constituting 28.94%. Our results are discordant with Kazi *et al.*, who found fibrosis in all the 7 cases (100%) of CLL.[33]

In our study, out of 6 cases of metastatic deposits, MB Grade 1 was seen in 1 case (16.7%) and Grade 4 in 5 cases (83.3%). In accordance with our results, many studies documented the presence of high grades of fibrosis in BM metastasis. Boman *et al.* reported reticulin and/or collagen fibrosis in 32/35 BM biopsies of patients with neuroblastoma.[37] Another study performed by Kaur *et al.* on nine patients with BM metastasis found BM fibrosis in 66.6% of cases and osteosclerosis in 22.2% of cases, as detected by reticulin and trichrome staining.[38]

Semiquantitative Bone Marrow Fibrosis Grading by WHO in Haematological Disorders

The current study showed Grade 0 fibrosis in 193 cases (64.3), Grade 1 in 61 cases (20.3%), Grade 2 in 34 cases (11.3%) and Grade 3 in 12 cases (4%). Bone Marrow Fibrosis was seen in 107 cases constituting upto 35.6% of total cases.

In present study, out of 77 cases of MPN, WHO Grade 0 was seen in 26 cases (33.8%), Grade 1 in 23 cases (29.9%), Grade 2 in 24 cases (31.2%) and Grade 3 in 4 cases (5.2%). Pozdnyakova *et al.* evaluated a total of 728 bone marrow biopsies with MPN and graded bone marrow fibrosis. Grade 0 was seen in 3.2%, Grade 1 in 13.5%, grade 2 in 35.2% and grade 3 in 48.1% of cases, in contrast to our study.[39] The maximum number of cases were of PMF, while in our study majority of the cases comprised of CML. WHO Grade 0 was seen in 26 cases (37.68%) out of 69 cases of CML in our study. Grade 1 in 18 cases (26.08%), Grade 2 in 23 cases (33.33%) and Grade 3 in 2 cases (2.89%). Similar observations were reported by Hamid *et al.* in their study on 82 patients with CML. Advanced fibrosis (Grade 2 and 3) was seen in 35% of cases which in our study constituted upto 36.22%.[40]

The present study concluded 63 cases of lymphoproliferative disorders, WHO Grade 0 was seen in 37 cases (58.7%), Grade 1 in 16 cases (25.4%), Grade 2 in 7 cases (11.1%) and Grade 3 in 3 cases (4.8%). In our study, out of 38 cases of CLL, WHO Grade 0 and 1 were seen in 35/38 cases constituting upto 92.1%. Similar results were seen in a study conducted by Tadmor *et al.*, who studied BM fibrosis in 173 cases diagnosed as CLL and reported that a total of 129/173 cases (74.56%) had WHO Grade 0 and 1.[41]

Our study recorded significant marrow fibrosis in 83.3% cases (5/6) of metastatic deposits. WHO Grade 0 was seen in 1 case (16.7%) and Grade 3 in 5 cases (83.3%).

CONCLUSION

Our results obtained for grading of fibrosis in bone marrow were almost similar by modified Bauermeister grading system as well as by Semiquantitative bone marrow fibrosis grading system by WHO. Modified Bauermeister grading system is complex and time consuming in contrast to WHO grading system which is much simpler. Therefore, we conclude that WHO grading system should be widely used in grading Bone Marrow Fibrosis. The study of bone marrow fibrosis is important in evaluation of diagnosis as well as prognosis. Advanced fibrosis is associated with disease progression and poor prognosis.

REFERENCES

1. McCarthy DM. Annotation. Fibrosis of the bone marrow: Content and causes. Br J Haematol 1985;59:1-7.
2. Kimura A, Katoh O, Hideo H, Kuramoto A. Transforming growth factor-β regulates growth as well as collagen and fibronectin synthesis of human marrow fibroblasts. Br J Haematol 1989;72:486-91.
3. Terui T, Niitsu Y, Mahara K, Fujisaki Y, Urushizaki Y, Mogi Y, *et al*. The production of transforming growth factor-beta in acute megakaryoblastic leukemia and its possible implications in myelofibrosis. Blood 1990;75:1540-8.
4. Schmitt A, Jouault H, Guichard J, Wendling F, Drouin A, Cramer EM, *et al*. Pathologic interaction between megakaryocytes and polymorphonuclear leukocytes in myelofibrosis. Blood 2000;96:1342-7.
5. Spivak JL. The chronic myeloproliferative disorders: Clonality and clinical heterogeneity. Semin Hematol 2004;41:1-5.
6. Xu M, Bruno E, Chao J, Huang S, Finazzi G, Steven M, *et al*. Constitutive mobilization of CD34+ cells into the peripheral blood in idiopathic myelofibrosis may be due to the action of a number of proteases. Blood 2005;105:4508-15.
7. Tefferi A. Pathogenesis of myelofibrosis with myeloid metaplasia. J Clin Oncol 2005;23:8520-30.
8. Puchtler H, Waldrop FW. Silver impregnation methods for reticulum fibers and reticulin: A re-investigation of their origins and specificity. Histochemistry 1978;57:177-87.
9. Bain BJ, Clark DM, Wilkins BS. Bone Marrow Pathology. 4th ed. London: Blackwell Science Ltd.; 2010.
10. Bancroft JD, Suvarna SK, Layton C. Theory and Practice of Histological Techniques. 7th ed. London: Elsevier; 2013.
11. Kuter DJ, Bain BJ, Mufti G, Bagg A, Hasserjian RP. Bone marrow fibrosis: Pathophysiology and clinical significance of increased bone marrow stromal fibres. Br J Haematol 2007;139:351-62.
12. Thiele J, Kvasnicka HM. Grade of bone marrow fibrosis is associated with relevant hematological findings-a clinicopathological study on 865 patients with chronic idiopathic myelofibrosis. Ann Hematol 2006;85:226-32.
13. Beham-Schmid C, Apfelbeck U, Sill H, Tsybrovskyy O. Treatment of chronic myelogenous leukemia with the tyrosine kinase inhibitor STI571 results in marked regression of bone marrow fibrosis. Blood 2002;99:381-3.
14. Hasserjian RP, Boecklin F, Parker S, Chase A, Dhar S, Zaiac M, *et al*. ST1571(imatinib mesylate) reduces bone marrow cellularity and normalizes morphologic features irrespective of cytogenetic response. Am J Clin Pathol 2002;117:360-7.
15. Buesche G, Hehlmann R, Hecker H, Heimpel H, Heinze B, Schmeil A, *et al*. Marrow fibrosis, indicator of therapy failure in chronic myeloid leukemia-prospective long-term results from a randomized-controlled trial. Leukemia 2003;17:2444-53.
16. Thiele J, Kvasnicka HM, Schmitt-Graeff A, Zirbes TK, Birnbaum F, Kressmann C, *et al*. Bone marrow features and clinical findings in chronic myeloid leukemia-a comparative, multicenter, immunohistological and morphometric study on 614 patients. Leuk Lymphoma 2000;36:295-308.

17. Lambertenghi-Deliliers G, Orazi A, Luksch R, Annaloro C, Soligo D. Myelodysplastic syndrome with increased marrow fibrosis: A distinct clinico-pathological entity. Br J Haematol 1991;78:161-6.
18. Hann IM, Evans DI, Marsden HB, Jones PM, Palmer MK. Bone marrow fibrosis in acute lymphoblastic leukaemia of childhood. J Clin Pathol 1978;31:313-5.
19. Manoharan A, Horsley R, Pitney WR. The reticulin content of bone marrow in acute leukaemia in adults. Br J Haematol 1979;43:185-90.
20. Riccardi A, Ucci G, Coci A, Ascari E. Bone marrow fibrosis in multiple myeloma. Am J Clin Pathol 1988;90:753-4.
21. Orth T, Treichel U, Mayet WJ, Storkel S, Buschenfelde KH. Reversible myelofibrosis in angioimmunoblastic lymphadenopathy. Dtsch Med Wochenschr 1994;119:694-8.
22. Weirich G, Sandherr M, Fellbaum C, Richter T, Schmidt L, Kinjerski T, *et al*. Molecular evidence of bone marrow involvement in advanced case of Tγδ lymphoma with secondary myelofibrosis. Hum Pathol 1998;29:761-5.
23. Okabe S, Miyazawa K, Iguchi T, Sumi M, Takaku T, Ito Y, *et al*. Peripheral T-cell lymphoma together with myelofibrosis with elevated plasma transforming growth factor-β1. Leuk Lymphoma 2005;46:599-602.
24. Bauermeister DE. Quantitation of bone marrow reticulin-a normal range. Am J Clin Pathol 1971;56:24-31.
25. Thiele J, Kvasnicka HM, Facchetti F, Franco V, van der Walt J, Orazi A. European consensus on grading bone marrow fibrosis and assessment of cellularity. Haematol 2005;90:1128-32.
26. Thiele J, Barbui T, Orazi A, Tefferi A, Barosi G, Kvasnicka HM, *et al*. Primary myelofibrosis. In: Swerdlow SH, Campo E, Harris NL, Jaffe ES, Pileri SA, Stein H, *et al*, editors. WHO Classification of Tumours of Haematopoietic and Lymphoid Tissues. 4th ed. France: IARC; 2017.
27. Buhr T, Busche G, Choritz H, Langer F, Kreipe H. Evolution of myelofibrosis in chronic idiopathic myelofibrosis as evidenced in sequential bone marrow biopsy specimens. Am J Clin Pathol 2003;119:152-8.
28. Kvasnicka HM, Thiele J. Classification of Ph-negative chronic myeloproliferative disorders-morphology as the yardstick of classification. Pathobiology 2007;74:63-71.
29. Thiele J, Kvasnicka HM, Orazi A. Bone marrow histopathology in myeloproliferative disorders-current diagnostic approach. Semin Hematol 2005;42:184-95.
30. Buesche G, Teoman H, Wilczak W, Ganser A, Hecker H, Wilkens L, *et al*. Marrow fibrosis predicts early fatal marrow failure in patients with myelodysplastic syndromes. Leukemia 2008;22:313-22.
31. Vener C, Fracchiolla NS, Gianelli U, Calori R, Radaelli F, Iurlo A, *et al*. Prognostic implications of the European consensus for grading of bone marrow fibrosis in chronic idiopathic myelofibrosis. Blood 2008;111:1862-5.
32. Gianelli U, Vener C, Bossi A, Cortinovis I, Iurlo A, Fracchiolla NS, *et al*. The European consensus on grading of bone marrow fibrosis allows a better prognostication of patients with primary myelofibrosis. Mod Pathol 2012;25:1193-202.
33. Kazi BM, Kazi F, Anwar M. Bone marrow fibrosis (BMF): A new proposal for grading system. Int J Pathol 2003;1:25-30.
34. Priyathersini N, Thanka J, Gayathri SS, Kanimozhi G, Arthi M, Suman FR. Bone marrow fibrosis condition with various underlying disorders. Int Med J 2016;3:2348-516.
35. Shehata AM, Kandel SM, Rizk SM, Khalifa KA, Fouad AS. Collagen I and III expression in fibrotic bone marrow. Menoufia Med J 2016;29:360-6.
36. Jesus CR, I-Ching L, Neiv TJ, Vituri CL. Assessment of fibrosis and vascularization of bone marrow stroma of chronic myeloid leukemia patients treated with imatinib mesylate and their relationship with the cytogenetic response. Braz J Pharm Sci 2011;47:313-22.
37. Boman F, Chastagner P, Floquet J, Sommelet D, Aymard B, Palau R, *et al*. Histological and immunohistochemical diagnosis of bone marrow metastases of neuroblastomas. Bull Cancer 1991;78:943-51.
38. Kaur G, Basu S, Kaur P, Sood T. Metastatic bone marrow tumors: Study of nine cases and review of the literature. J Blood Disord Transfus 2011;2:1-3.
39. Pozdynyakova O, Wu K, Patki A, Rodig SJ, Thiele J, Hasserjian RP. High concordance in grading reticulin fibrosis and cellularity in patients with myeloproliferative neoplasms. Mod Pathol 2014;27:1447-54.
40. Hamid A, Ashraf S, Qamar S, Naveed MA, Hameed A, Farooq MA. Myelofibrosis in patients of chronic myeloid leukemia in 101 chronic Phase at presentation. J Coll Physicians Surg Pak 2019;29:1096-100.
41. Tadmor T, Shvidel L, Aviv A, Ruchlemer R, Bairey O, Yuklea M, *et al*. Significance of bone marrow reticulin fibrosis in chronic lymphocytic leukemia at diagnosis: A study of 176 patients with prognostic implications. Cancer 2013;119:1853-9.

How to cite this article: Kaur A, Nibhoria S, Kaur S. A Comparative Study of Modified Bauermeister Grading System and Semiquantitative Bone Marrow Fibrosis Grading System by WHO (2016). Int J Sci Stud 2021;9(9):61-67.

Source of Support: Nil, **Conflicts of Interest:** None declared.

Print ISSN: 2321-6379
Online ISSN: 2321-595X

Original Article

Management of Retrosternal Goitre: A Single Institute Experience

Lakkanna Suggaiah[1], Syeda Siddiqua Banu[2], Usharani Ratnam[3], S Praveen[4]

[1]HOD, Professor, Department of General Surgery, ESIC PGIMSR MH, Bengaluru, Karnataka, India, [2]Associate Professor, Department of Paediatrics Surgery, ESIC PGIMSR MH, Bengaluru, Karnataka, India, [3]Associate Professor, Department of General Surgery, ESIC PGIMSR MH, Bengaluru, [4]Final Year Resident, Department of General Surgery, ESIC PGIMSR MH, Bengaluru, Karnataka, India

Abstract

When a portion of the mass of a goiter ≥50% extends into the mediastinum, it is called as retrosternal goiter (RSG), which is managed by surgical removal either by cervical approach alone or in combination with sternotomy. This is a retrospective analysis of our personal experience in the management of RSG, in terms of its demographics, clinical features, diagnostic considerations, and surgical approach defining, in particular, the cases requiring sternotomy. A total of 307 patients underwent thyroidectomy in the Department of General Surgery at ESIC Medical College and PGIMSR Model hospital, Rajajinagar, Bangalore over a period of 10 years (2011–2021), out of which seven cases had retrosternal extension. Five underwent surgical excision via cervical collar incision alone and two required a combined approach. Thus our experience states that though the management of RSG is technically demanding, a cervical approach is a feasible and safe option. Sternotomy should be reserved for a carefully selected set of patients.

Key words: Goitre, Mediastinum, Sternotomy, Thyroidectomy

INTRODUCTION

Retrosternal goiter (RSG) was first described by Albrecht von Haller in 1749, as the extension of the thyroid tissue below the upper opening of the chest.[1] RSG is characterized by the presence of ≥50% portion of the goiter extending into the mediastinum[2,3] and is documented in 2–19% of all thyroidectomies.[4-6] It can either be "Primary" –arising from aberrant thyroid tissue ectopically located in the mediastinum supplied by mediastinal vessels and having no connection with the cervical thyroid tissue seen in <1% cases[7] or "Secondary"- a more common variety wherein there is extension or downward migration of thyroid tissue being supplied via branches of inferior thyroid artery. It can be retrosternal, substernal, intrathoracic, or mediastinal based on its location.

RSG are extremely slow growing with female preponderance and remain asymptomatic often detected incidentally on radiologic examination.[8] Diagnosis of RSG is most frequently made in the fifth or sixth decade of life. However, there can be sudden enlargement of RSG owing to hemorrhage, cystic degeneration, or rarely malignant change seen in 3–21% patients[9] - giving rise to symptoms often due to compressive effects on underlying structures like:

1. Airways - dyspnea, choking, inability to sleep comfortably.
2. Oesphagus- dysphagia and hoarseness
3. Vascular structures-SVC syndrome
4. Sympathetic chain-Horner's syndrome.

The diagnosis of RSG is based upon clinical history, physical examinations, and imaging findings on CT. Surgery is the mainstay of management but surrounded with controversies. A majority of surgeons suggest that all RSG should be operated,[4,5-16] however a small minority prefer surgery only in symptomatic/malignant RSG's.[17] This paper highlights our experience in managing the RSG.

Access this article online

www.ijss-sn.com

Month of Submission : 10-2021
Month of Peer Review : 11-2021
Month of Acceptance : 11-2021
Month of Publishing : 12-2021

MATERIALS AND METHODS

This is a retrospective study from 2011 to 2021 comprising 307 patients who underwent Thyroidectomy in the department of General Surgery at ESIC Medical College and PGIMSR Model hospital, Rajajinagar, Bangalore. RSG was

Corresponding Author: S Praveen, Department of General Surgery, ESIC PGIMSR MH, Bengaluru, Karnataka, India.

noted in seven patients. The medical records of these patients were retrospectively studied. All patients had undergone; thyroid function tests, ultrasonography, chest X-ray, indirect laryngoscopy, fine-needle aspiration (FNA), and CT scan of the neck and chest and a few had been subjected to Thyroid scintigraphy and were managed by surgical excision. All the data obtained were analyzed in terms of its demographics, clinical features, diagnostic considerations, and surgical approach defining in particular the cases requiring sternotomy.

RESULTS

A total of 307 thyroidectomies were performed in the Department of General Surgery at ESIC Medical College and PGIMSR Model hospital, Rajajinagar, Bangalore. RSG was noted in seven patients. The mean age at presentation was 50.8 years, Male: Female ratio was 4:3. Abnormal thyroid profile was seen in two patients. The most common mode of presentation was swelling in front of the neck followed by neck discomfort. Comorbidities were seen in two patients. All patients were surgically managed. Five underwent only Transcervical approach, whereas combined approach was used in two patients. Difficult anesthesia was encountered in 1 patient.

Mean hospital stay was 12 days. No major postoperative complications were seen. Final histopathology report was Colloid goiter in five patients. Malignant change was noted in 2 patients and there were managed accordingly. All patients received thyroid-stimulating hormone -suppressive treatment with the thyroid hormone post-operatively. No recurrences were noted in our study.

Consolidated results	
Total thyroidectomies	307
RSG cases	07
Male: Female ratio	4:3
Median age at presentation	50.8
Presenting Complaint	
1. Neck swelling	7
2. Dyspnea	2
3. Neck discomfort	7
4. Hoarseness of voice	1
5. Asymptomatic	None
Deranged thyroid profile	2 (Hyperthyroid)
Characteristic CT finding	Heterogeneously enhancing mass arising from the thyroid lobes extending below the manubrium sterni
Anaesthetic considerations	1 (need for Fibro optics for intubation as trachea was near complete collapsed)
Surgical procedure	
Cervical collar incision	5
Combined approach (with Sternotomy)	2
Mean duration of surgery	3.07 h
Mean hospital stay	12 days
Post op complications	Minor-2
	Major-None
Final HPE	Colloid Goitre
Malignant changes	2
	1. Papillary Carcinoma
	2. Hurthle cell variant of Papillary carcinoma

DISCUSSION

As mentioned earlier the management of RSG has been a topic of debate. All patients who presented to us with thyroid swellings were clinically examined and the patients in whom lower border of the swelling was not palpable were considered to have retrosternal extension and were evaluated further [Figure 1]. Several factors favor the descent of the goitre into the mediastinum: Downward traction caused by normal swallowing, strong neck muscles, respiration creating negative intrathoracic pressure, and the pull of gravity on the goitre.[18] Although the epidemiology of the RSG varies according to the definition, the incidence, sex ratio, and mean age in our series are in-keeping with other reports.[19,20]

A classical chest X-ray finding of the RSG includes a mediastinal mass with tracheal deviation and compression, and visualization of the smooth or nodular outline of the tumor, however, all of our patients had only deviation of the trachea and no mediastinal mass noted on CXR [Figures 2 and 3]. Ultrasound suspected the retrosternal extension, however, did not provide detailed information about the RSG. CT scan [Figure 4] is the ideal and superior investigation as it provides a detailed anatomy of RSG and its relationship with the surrounding structures, and it was a source of major information in all our RSG patients. Nuclear imaging/Oesophagogram was not done in any of our patients, as it doesn't have any added advantage nor does it affect the course of management as described in few earlier studies.[21,22] FNAC of thyroid swelling was done in all patients however the FNAC of RSG was not

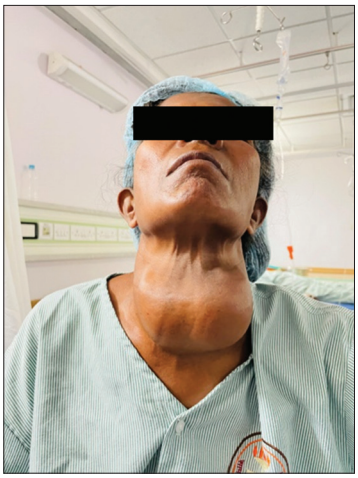

Figure 1: Picture showing a huge thyroid swelling with inconspicuous lower border

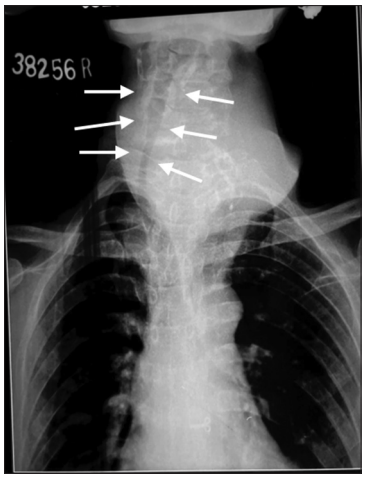

Figure 2: Chest X-ray showing huge mass with tracheal compression and shift to right

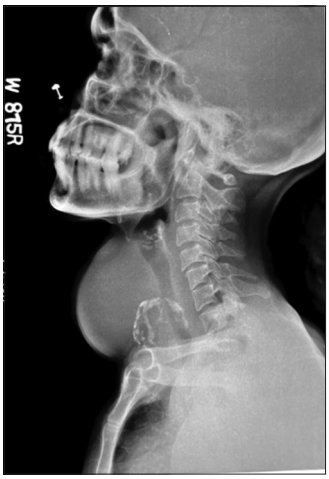

Figure 3: Lateral view of neck X-ray showing the neck mass with intra glandular calcification

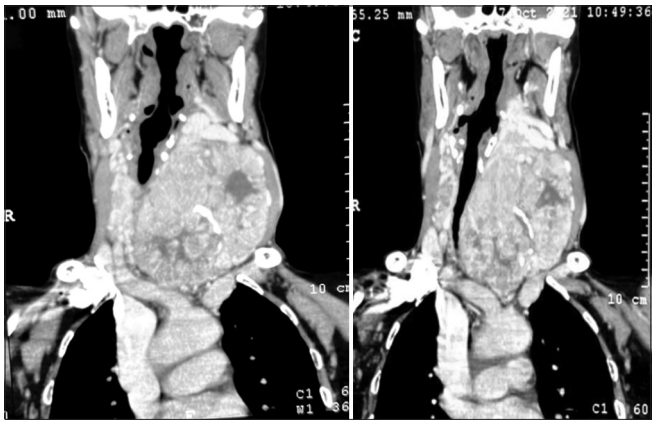

Figure 4: CT film of the neck and upper chest showing diffuse swelling of the thyroid gland and substernal goiter, which extends to left side of thorax. The goiter extended upto the right brachiocephalic vein with both trachea and esophagus shifted to right

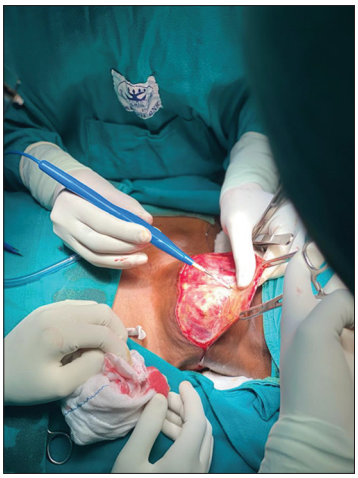

Figure 5: Intraoperative picture showing transcervical approch

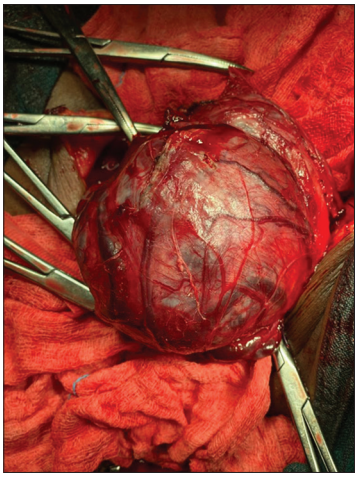

Figure 6: Intraoperative picture showing extraction of mass via Transcervical approach alone

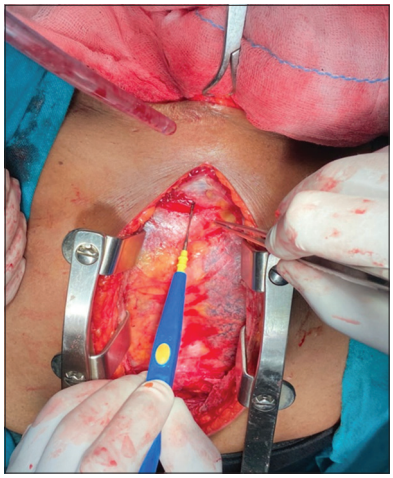

Figure 7: Figure showing midline sternotomy

done, because it is technically difficult, may be dangerous to perform, and can miss the true pathology.[23,24] In our series only two patients presented with toxic goiter. The reported incidence of hyperthyroidism in patients with RSG varies widely from 0 to 50%.[25] None of our patients with RSG was treated medically.

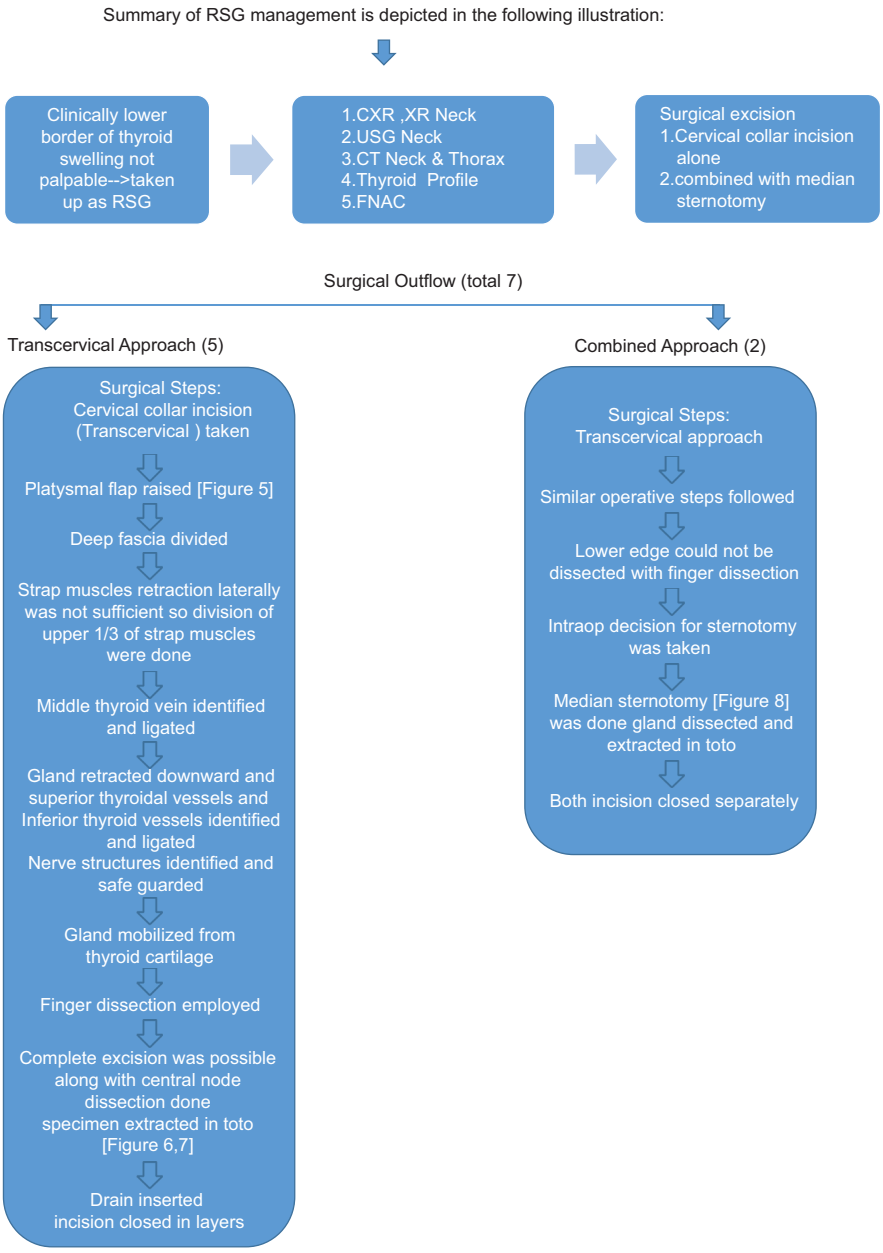

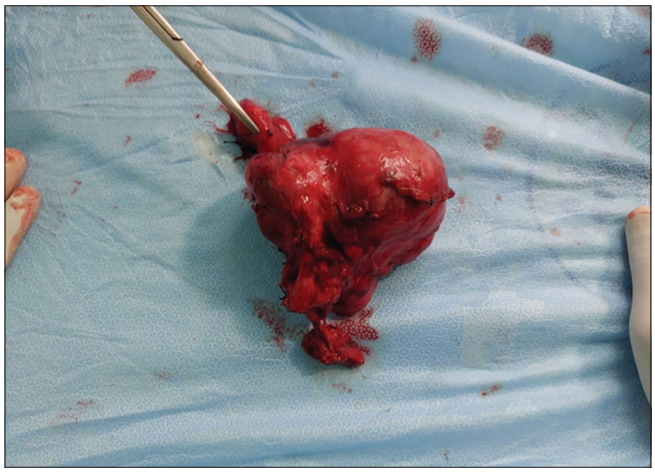

Figure 8: Figure showing RSG extracted in toto

CONCLUSION

Most of the patients with retrosternal goiter can be managed with the Transcervical approach alone, but few selected cases require sternotomy. There are no fixed preoperative criteria or guidelines for sternotomy. Careful intraoperative finger dissection should be tried. In cases where the dissection is not possible or if the goiter is large enough or when a substernal goiter extends to either sides of the thorax and suspicious of malignancy in RSG or it has a larger diameter than the thoracic inlet or airway constriction is revealed, then sternotomy should be done which provides excellent exposure and can help reduce the risk of complications, such as a recurrent laryngeal nerve palsy and injuries to major blood vessels.

REFERENCES

1. Haller A. Disputatones Anatomica Selectae. Gottingen: Vendenhoceck; 1749. p. 96.
2. DeSouza FM, Smith PE. Retrosternal goiter. J Otolaryngol 1983;12:393-6.
3. Katlic MR, Wang CA, Grillo HC. Substernal goiter. Ann Thorac Surg 1985;39:391-9.
4. Allo MD, Thompson NW. Rationale for the operative management of substernal goiters. Surgery 1983;94:969-77.
5. Hsu B, Reeve TS, Guinea AL, Robinson B, Delbridge L. Recurrent substernal nodular goiter: Incidence and management. Surgery 1996;120:1072-5.
6. Netterville JL, Coleman SC, Smith JC, Smith MM, Day TA, Burkey BB. Management of substernal goiter. Laryngoscope 1998;108:1611-7.
7. Wu MH, Chen KY, Liaw KY, Huang TS, Lee PH. Primary intrathoracic goiter. J Formos Med Assoc 2006;105:160-3.
8. Shen WT, Kepebew E, Duh QY, Clark OH. Predictors of airway complications after thyroidectomy for substernal goiter. Arch Surg 2004;139:656-60.
9. Nervi M, Iacconi P, Spinelli C, Janni A, Miccoli P. Thyroid carcinoma is intrathoracic goiter. Langenbecks Arch Surg 1998;383:337-9.
10. Torre G, Borgonovo G, Amato A, Arezzo A, Ansaldo G, de Negri A, *et al*. Surgical management of substernal goiter: Analysis of 237 patients. Am Surg 1995;61:826-31.
11. Rodríguez JM, Hernandez Q, Piñero A, Ortiz S, Soria T, Ramirez P, *et al*. Substernal goiter: Clinical experience of 72 cases. Ann Otol Rhinol Laryngol 1999;108:501-4.
12. Erbil Y, Bozbora A, Barbaros U, Ozarmağan S, Azezli A, Molvalilar S. Surgical management of substernal goiters: Clinical experience of 170 cases. Surg Today 2004;34:732-6.
13. Chauhan A, Serpell JW. Thyroidectomy is safe and effective for retrosternal goiter. ANZ J Surg 2006;76:238-42.
14. Hashmi SM, Premachandra DJ, Bennett AM, Parry W. Management of retrosternal goiters: Results of early surgical intervention to prevent airway morbidity, and a review of the English literature. J Laryngol Otol 2006;120:644-9.
15. Pieracci FM, Fahey TJ 3rd. Substernal thyroidectomy is associated with increased morbidity and mortality as compared with conventional cervical thyroidectomy. J Am Coll Surg 2007;205:1-7.
16. Hardy RG, Bliss RD, Lennard TJ. Retrosternal Goiter: The case for operation in all patients. Ann R Coll Surg Engl 2009;91:8-9.
17. Balasubramanian SP, Harrison BJ. Asymptomatic retrosternal goiter-a case for primum non nocere? Ann R Coll Surg Engl 2009;91:10-1.
18. Sianesi M, Del Rio P, Arcuri MF, Soliani P, Rusca M. Cervicomediastinal goiter. Chir Ital 2002;54:15-8.
19. Maruotti RA, Zannini P, Viani MP. Surgical treatment of substernal goiters. Int Surg 1991;76:12-7.
20. Katlic MR, Grillo HC, Wang C. Substernal goiter (analysis of 80 patients from Massachusetts general hospital). Am J Surg 1985;149:283-7.
21. Porzio S, Marocco M, Oddi A, Lombardi V, Porzio O, Calvelli C, *et al*. Endothoracic goiter: Anatomoclinical and therapeutic consideration. Chir Ital 2001;53:453-60.
22. Alfonso A, Christoudias G, Amaruddin Q. Tracheal or esophageal compression due to benign thyroid disease. Am J Surg 1981;142:350-4.
23. Armour RH. Retrosternal goiter. Br J Surg 2000;87:519.
24. Singh B, Lucente FE, Sahara AR. Substernal goiter: A clinical review. Am J Otolaryngol 1994;15:409-16.
25. Madjar S, Weisberg D. Retrosternal goiter. Chest 1995;60:207-12.

How to cite this article: Suggaiah L, Banu SS, Ratnam U, Praveen S. Management of Retrosternal Goitre: A Single Institute Experience. Int J Sci Stud 2021;9(9):68-72.

Source of Support: Nil, **Conflicts of Interest:** None declared.

Print ISSN: 2321-6379
Online ISSN: 2321-595X

Original Article

Comparative Study between Omentopexy and Omental Plugging in Management of Giant Peptic Perforation

Mohammad Farooque[1], Param Shah[2], Tirth Joshi[2], Labdhi Shah[3], Priyanshi Sheth[3]

[1]Assistant Professor, Department of General Surgery, Dhiraj Hospital, Vadodara, Gujarat, India, [2]Post Graduate, Department of General Surgery, Dhiraj Hospital, Vadodara, Gujarat, India, [3]MBBS Intern, Department of General Surgery, Dhiraj Hospital, Vadodara, Gujarat, India

Abstract

Introduction: Peptic perforation is a life threatening surgical emergency often associated with high mortality.

Aim: This study aims to compare the success rate between omental plugging (OP) and omentopexy (OX) in the emergency management of large peptic perforations.

Materials and Methods: A prospective non-randomized study of 25 patients with large peptic perforation (≥2 cm in diameter) was done over a period of 18 months.

Results: The highest incidence was seen in the age group of 41–50 years. Intestinal fistula occurred in 23.08% of the OX group compared to none in the OP group. The mean hospital stay was slightly higher in the OX group. Three patients died in the OX group postoperatively after 24 h compared to none in the OP group which was statistically significant ($P < 0.05$).

Conclusion: OP is associated with lesser morbidity and lesser mortality compared to OX in the management of large peptic perforations.

Key words: Giant peptic perforation, Omental plugging, Omentopexy

INTRODUCTION

Perforation is one of the most catastrophic and dreaded complications of peptic ulcer.[1] Although it is a common, surgical emergency literature is silent on the exact definition, incidence, management, and complications of large perforations of peptic ulcers.[2] Giant/large peptic perforations are defined as perforations of size equal to or greater than 2 cm in diameter.[1] These perforations are considered particularly dangerous because of the extensive duodenal tissue loss, friability of the ulcer margins, surrounding tissue inflammation, poor general condition of the patient, and overwhelming sepsis due to bacterial peritonitis.

Access this article online

www.ijss-sn.com

Month of Submission : 10-2021
Month of Peer Review : 11-2021
Month of Acceptance : 11-2021
Month of Publishing : 12-2021

These factors are said to preclude simple closure using omental patch, often resulting in post-operative leak or gastric outlet obstruction.[2-4] Various methods apart from standard omentopexy (OX) have been described for the management of giant perforations which include partial gastrectomy, jejunal serosal patch, jejunal pedicled graft, omental plugging (OP), and proximal gastrojejunostomy.[2] Apart from OP, all other methods are more elaborate, time consuming, and technically difficult to perform.[1] The present study was done to compare the success rate between OP and standard OX in the emergency management of giant and large peptic perforations.

MATERIALS AND METHODS

The present study is a prospective and non-randomized case series report comparing the efficacy of OP (described by Karanjia *et al.* in 1993) and OX (first described by Cellen Jones in 1929 and later modified by Graham in 1937) in the repair of giant peptic perforations (≥2 cm in diameter).

Corresponding Author: Dr. Mohammad Farooque, Dhiraj General Hospital, SBKS Medical Institute and Research Centre, Vadodara, Gujarat, India.

This study was undertaken in the Department of General Surgery of Dhiraj General Hospital, Sumandeep Vidyapeeth, Pipariya between March 2019 and September 2021. Two hundred and eighteen patients undergoing emergency surgery for peptic perforation were included in the study. Subsequently, only those patients who were found to have giant peptic perforations during laparotomy were selected for the study.

Patients repaired by OP were taken as cases and patients repaired by OX were taken as controls.

Apart from routine investigations, pre-operative straight X-ray of the abdomen in the erect posture was done in every case. Patients from both groups received the same standard pre- and post-operative procedures and medications including antibiotics and post-operative H2 blockers. Diagnosis was confirmed at laparotomy. The abdomen was opened by an upper midline incision in each case. After confirmation of the diagnosis, the amount of fluid in the peritoneal cavity, peritoneal soiling, the size, site, shape, and margins of the perforation was noted. The perforations with size >2 cm were allocated into two groups, cases and controls. In the first group, OP was done while in the control group, standard OX was done.

OP

The anesthetist/assistant was asked to insert the nasogastric tube further and the surgeon guided the tip of the tube so that it came out into the peritoneal cavity through the perforation. The free end of the greater omentum was sutured to the tip of the nasogastric tube using 1–0 rapidly absorbable (chromic catgut) suture. Then, the anesthetist/assistant was asked to withdraw the tube. As the tip went inside the stomach, so did the omentum. The tube was withdrawn until the omentum occluded the perforation. About 5–6 cm length of omental plug generally sufficed. The omentum was then fixed to the perforation site with 5–6 interrupted sutures of 2–0 chromic catgut taken between omentum and serosa of healthy duodenum and/or stomach.

OX

The perforation was sutured in one layer by three interrupted Lambert sutures with 2–0 polyglactin using a patch of pedicled omentum to reinforce the suture line.

A thorough peritoneal toileting was then done in all the cases. A tube drain was put inside the peritoneal cavity at the hepato renal pouch through a separate stab incision in the right flank. The patients were examined at about 4–6 weeks, at 10–12 weeks, and again between 24 and 26 weeks after operation. All patients underwent barium meal study 12 weeks after discharge to see if any patient developed features of delayed gastric outlet obstruction. Parameters compared between the two groups were mean operative time, intra-operative and post-operative mortality within 30 days of operation, development of biliary fistula, development of septicemia, development of intra-abdominal abscess, development of wound infection, development of lung complication, commencement of oral feeding from day of operation, duration of hospital stay, and development of post-operative gastric outlet obstruction.

RESULTS

Of the 218 patients, 23 (10.5%) had a giant perforation. All were males. OP was done in ten patients (cases) and OX in 13 (controls). The age ranged from 33 to 73 years, the mean age being 52.5 years. The highest incidence was seen in the age group of 41–50 years. The age incidence of the two groups is given in Table 1. Seven patients had hypertension, five in the (OX) group and three in the (OP) group. One patient in the OP group had diabetes mellitus. The time since perforation is given in Table 2. The mean operative time was 108 min in the OP group compared to 83 min in the OX group. The mean operative time, though slightly higher in OP group, is probably due to inexperience of the surgeons in this particular procedure. It was seen that with experience, the operative time became shorter. The slightly higher time taken did in no way affect the outcome and was not statistically significant.

Intestinal fistula formation was 0% in OP group while 3 (23.08%) patients developed intestinal (duodenal) fistula in the OX group. Of these three patients, two were reoperated and partial gasterectomy was done in both cases. Unfortunately, all three patients died. The above data, when calculated on standard error of proportion, were significant at 5% level. Thus, it can be concluded that OP is a better operation in preventing intestinal fistula formation in giant peptic perforations.

Table 1: Age distribution

Age group	OP	OX	Total (%)
≤30	-	-	-
31–40	3	3	6 (26)
41–50	4	5	9 (39)
≥50	3	5	8 (35)

Table 2: Duration of symptoms

Time (h) (since pain started)	OP	OX	Total
<6	-	-	-
6–24	-	1	1
24–48	7	9	16
>48	3	3	6

Wound infection occurred in 20% of patients of the OP group compared to 30.76% in the OX group. Intra-abdominal abscess occurred in 20% of the OP group compared to 15.4% of the OX group. Lung complications and septicemia occurred in 20% of the OP group compared to 30.76% of the OX group. All the above data were statistically insignificant at 5% limit ($P < 0.05$) and no conclusive evidence can be drawn from this study that any of the two procedures is better in preventing wound complication, intra-abdominal abscess or lung complications, and septicemia Table 3.

Oral feeding in OX was started as soon as peristalsis occurred, which usually varied between 3 and 4 days. In OP, as it was a new procedure and as omentum was sutured with the nasogastric tube, initially people were skeptical to start oral feeding early. In the remaining eight cases, oral feeding was started in about 4–5 days.

The mean hospital stay was 12.6 days for the OP group compared to 14.2 days for the OX group. It is slightly higher in OX group because three patients in that group developed bile leak and intestinal fistula, resulting in increased hospital stay. The above data are statistically insignificant.

Among the 23 patients, six patients died. The mortality of the two groups is shown in Table 4. Among the six patients, three died in the immediate post-operative period, that is, within 24 h of surgery. This included two patients in the OX group and one in the OP group. The patients were aged >50 years, had features of septicemia and two patients were in shock when they attended the hospital. All three patients had duration of symptoms for more than 48 h.

Table 3: Morbidity

Parameter	OP	OX	Significance
Mean operative time	108 min	83 min	Not significant
Intestinal fistula	-	3	Significant
Wound infection	2	4	Not significant
Intra-abdominal abscess	2	2	Not significant
Lung complication/septicemia	2	4	Not significant
Mortality	1	5	Not significant
Mean hospital stay	12.6 days	14.2 days	Not significant
Oral feeding	4.8 days	3.46 days	Not significant
Gastric outlet obstruction	-	-	Not significant

Table 4: Mortality

Total no of cases		Death		Total
		Within 24 h of surgery	>24 h	
OP	10	1	-	1
OX	13	2	3	5

Statistically when we consider total deaths, the data are not significant, that is, from the number of total mortality, we cannot conclude that either OP or OX is a better procedure, though apparently it appears that death is much lower in OP group. However, if we consider deaths that occurred >24 h after surgery, the data become statistically significant and show that OP causes lesser mortality than OX at 5% level ($P < 0.05$). In fact, this data are more important than total number of deaths, because death within 24 h of surgery is mostly due to pre-existing physiologic disturbances rather than due to the operative procedure.

Five patients were lost in post-operative follow-up at 3 months and six patients died; in the remaining 12 barium meal X-ray was done.

No case of gastric outlet obstruction was detected. These 12 patients were followed up for 6 months. None of them developed any clinical signs of gastric outlet obstruction.

DISCUSSION

Peptic perforation is a common disease in the general population. There is a sharp decrease in elective peptic ulcer surgery but the emergencies such as perforation are on rise in some studies.[5] The size of perforation in a peptic ulcer varies from 3 mm to over 3 cm in diameter, which adversely affects the prognosis. If the perforation is <5 mm in diameter, there is a 6% mortality rate, when it is between 5 and 10 mm, the mortality goes up to 19% and when it is more than 10 mm, the mortality rate is around 24%.[6] There is a paucity of data in the literature regarding giant peptic ulcer perforation management. The overall incidence of 2 cm or more diameter perforation is about 3%.[1] In our study, the incidence was 3.2%. In our study, the highest incidence was seen in the 5th decade which is similar to other studies in the literature.[1,7,8] All our patients were males which is in sharp contrast to other studies where the male to female ratio is between 9:1 and 7.5:7.[1,7,9,10] It may be said that since the number of patients in our study is small, the ratio is not relevant. However, even in the 218 patients of peptic perforation initially included in our series, all were males.

Duration of perforation along with the size of the opening in most cases determines the extent of peritoneal

contamination. In the present study, the most of the patients had severe amount of contamination (60.87%), in two patients it was minor whereas in seven only the supra colic compartment of abdomen was involved. Three patients among the severely contaminated group died in the immediate post-operative period.

In the present series, post-operative complications were encountered in 11 patients (47.8%). The complications were wound infection, respiratory tract infection and pulmonary infection, burst abdomen, intra-abdominal abscess, and most importantly intestinal fistula formation. Wound infection (26%) and respiratory tract infection (26%) were the most common complications. These figures correspond to the available literature. Hastings and Machida[11] reported post-operative complications in 86 patients, comprising 24%, the most common of which was wound complications followed by those of respiratory tract. Giant perforations are technically difficult to repair due to the duodenum's complex anatomy and marginal blood supply shared with the pancreas. High intra-luminal pressure, tendency of the mucosa to extrude through the suture line and autodigestive enzymes of the pancreas, and bile acid add to the risk of breakdown of the suture line.[12]

Conventional wisdom dictates that healthy vascularized tissue should be incorporated in the repair of any defect with tissue loss or with friable edges.[12] Several elaborate surgeries have been devised to manage complicated giant peptic ulcers.[1] These include resection of the perforation bearing duodenum and gastric antrum in the form of a partial gasterectomy, conversion of the perforation into a pyloroplasty, or the closure of the perforation using a serosal patch or pedicled graft of the jejunum.[2] However, as can be appreciated, each of these procedures not only prolong the operating time, but also require a level of surgical expertise that may not be available in the emergency.[2,13]

In contrast to these elaborate measures, the omental plug is a simple procedure which does not require significant expertise and can even be performed in a very short time by a trainee general surgeon in a seriously ill patient in an emergency situation.[1,13] In this study, intestinal fistula formation in control group was 23.08% and 0% in study group. The above data correspond well to that obtained by Jani and Saxena[14] in a randomized control trial. The possible explanation for this phenomenon may be sought from the basic principle of physics. In the OP group, as a part of the omentum is taken inside the stomach, even with rise of intra-gastric pressure, the omentum is always kept in contact with gastric mucosa. In contrast, in OX, the repair is done from outside and so with rising intra-gastric pressure; the patch could be easily disturbed. In our study, the overall mortality rate was 26%. The death in the OP group was 10% and that in the OX group was 38.5%. Three patients died within 24 h of operation due to pre-existing septicemia. Another three patients, all in the OX group, developed intestinal fistula and died at a later stage. Mortality rates were higher in the OX group and the data are statistically significant if we only consider deaths 24 h after surgery.

The average stay of patients in the OP group was 12.6 days and in those who underwent OX it was 14.2 days. The slightly higher hospital stay in the control group was due to the fact that three patients developed intestinal fistula of whom two were re-operated, increasing the mean hospital stay of that group.

CONCLUSION

Giant perforations are rare, about 3–4% of total perforations, but are associated with significantly higher mortality and morbidity when compared to smaller perforations. OP for giant perforations, a relatively newer and less utilized technique, is associated with lesser cases of intestinal fistula formation when compared to the standard method of OX. Our results show that the mortality rate excluding pre-existing septicemia is lower in the OP group, making it a better choice of technique for repair of giant perforations. One particular point that needs to be mentioned here is that as this is a non-randomized study and due to a small sample size and short period of follow-up, the conclusions must be considered with caution.

REFERENCES

1. Jani K, Saxena AK, Vaghasia R. Omental plugging for large sized duodenal peptic perforation: A prospective randomized study of 100 patients. South Med J 2006;99:467-71.
2. Gupta S, Kaushik R, Sharma R, Attri A. The management of large perforations of duodenal ulcers. BMC Surg 2005;5:15.
3. Chaudhary A, Bose SM, Gupta NM, Wig JD, Khanna SK. Giant perforations of duodenal ulcer. Indian J Gastroenterol 1991;10:14-5.
4. Karanjia ND, Shanahan DJ, Knight MJ. Omental patching of a large perforated duodenal ulcer: A new method. Br J Surg 1993;80:65.
5. Rajes V, Chandra SS, Smile SR. Risk factors predicting operative mortality in perforated peptic ulcer disease. Trop Gastroenterol 2003;24:148-50.
6. Hennessy E. Perforated peptic ulcer mortality and morbidity in 603 cases. Aust N Z J Surg 1969;38:243-52.
7. Khalil AR, Yunas M, Jan QA, Nisar W, Imran M. Grahm's omentopexy in closure of perforated duodenal ulcer. J Med Sci 2010;18:87-90.
8. Gupta BS, Talukdar RN, Neupane HC. Cases of perforated duodenal ulcer treated in college of medical sciences, Bharatpur over a period of 1 year. Kathmandu Univ Med J (KUMJ) 2003;1:166-9.
9. Ahmad W, Qureshi H, Alam AC, Zubair JS. Perforated duodenal ulcer, a long term follow up. J Pak Med Assoc 1990;40:258-9.

10. Taj MH, Muhammad D, Qureshi SA. Outcome of omentopexy as primary repair in perforated duodenal ulcer. JCPSP 2007;17:731-5.
11. Hastings N, Machida R. Perforated peptic ulcer: Results after simple surgical closure. Am J Surg 1961;102:136-42.
12. Agarwal P, Sharma D. Repair of duodenal fistula with rectus abdominis musculo-peritoneal (RAMP) flap. Indian J Gastroenetrol 2004;23:143-4.
13. Sharma D, Saxena A, Rahman H, Raina VK, Kapoor JP. 'Free Omental Plug': A nostalgic look at an old and dependable technique for giant peptic perforations. Dig Surg 2000;17:216-8.
14. Jani K, Saxena AK. Management of large sized duodenal peptic perforations by omental plugging-a new technique: A prospective randomized study of 100 patients. Indian J Surg 2000;62:134-8.

How to cite this article: Farooque M, Shah P, Joshi T, Shah L, Sheth P. Comparative Study between Omentopexy and Omental Plugging in Management of Giant Peptic Perforation. Int J Sci Stud 2021;9(9):73-77.

Source of Support: Nil, **Conflicts of Interest:** None declared.

Print ISSN: 2321-6379
Online ISSN: 2321-595X

Original Article

A Quantitative Comparative Pharmacovigilance Scoring of Causality Assessment Grading and Staging of Delamanid and Ofloxacin, Among Global Multidrug-Resistant Tuberculosis Patients, and a Molecular Pharmacological Analysis of Delamanid, as an Antitubercular Drug

Moumita Hazra[1,2,3,4,5,6,7]

[1]Medical Director, Consultant Multi-Specialist Clinical Pharmacological Physician, Consultant Clinical Pathologist, Consultant Rational Pharmacotherapeutic Physician, Pharmaco-Haemo-Materio-Vigilance Specialist, Head Hospital Operations Management, Chief Executive Officer, Medical Superintendent, Dr. Moumita Hazra's Polyclinic and Diagnostic Centre, Hazra Nursing Home, Howrah, West Bengal, India, [2]Associate Professor, Head of Department in Charge, Department of Pharmacology, Pharmaco-Haemo-Materio-Vigilance Specialist, Pharmacovigilance Committee, Mamata Medical College and Hospitals, Khammam, Telangana, India; Former Associate Professor, Head of Department in Charge, Department of Pharmacology, Rama Medical College Hospital and Research Centre, Rama University, Hardaspur, Uttar Pradesh, India, [3]Former Resident and Tutor, Departments of Pharmacology and Pathology, J. J. M. Medical College and Hospitals, Davanagere, Karnataka, India, [4]Former Academic and Research Scholar, Department of Business Administration, Sikkim Manipal University (DE); Department of Clinical Research, Symbiosis International University (DE); Departments of Zoology, Physiology and Chemistry, Presidency College, West Bengal; Former Senior Research Fellow, Department of Paediatrics, All India Institute of Medical Sciences, New Delhi, India, [5]Former Assistant Director, Medical Editor, GIOSTAR Institute of Regenerative Medicine, Institutes, Hospitals and Laboratories, New Delhi, Ahmedabad, India, United States of America, World, [6]Former Assistant Professor, Head of Department, Department of Pharmacology, Hi-Tech Medical College and Hospital, Rourkela, Odisha, India, [7]Consultant Pathologist, Former Laboratory Director, Indus Nursing Home and Diagnostic Center, Indus Diagnostic Center and Polyclinic, Mahuya Diagnostic Centre and Doctors' Chamber, General Patho Clinic, Medilab Pathology Laboratory, India

Abstract

Introduction: Delamanid, a nitro-dihydro-imidazoxazole, is a bactericidal cell wall methoxy-mycolic and keto-mycolic acids biosynthesis inhibitor in actively replicating, dormant, and intracellular *Mycobacterium tuberculosis*, and both drug-susceptible and drug-resistant strains of *M. tuberculosis* and *Mycobacterium kansasii*, decreasing hydrophobicity, and facilitating better bacterial drug penetration. Delamanid promotes intracellular generation of microbiocidal nitrogen oxidative intermediaries including nitric oxide, toxic even to dormant *M. tuberculosis*. Ofloxacin, the racemic mixture, is bactericidal to *M. tuberculosis*, *Mycobacterium avium* complex, *Mycobacterium fortuitum*, and other atypical mycobacteria, with inhibitory effect on DNA gyrase, DNA topoisomerase IV, and IL-1α, IL-6, and IL-8.

Objectives: A quantitative comparative pharmacovigilance scoring of causality assessment grading and staging of delamanid and ofloxacin, among global multidrug-resistant (MDR) tuberculosis patients, and a molecular pharmacological analysis of delamanid, as an antitubercular drug.

Methods: A multicenter, prospective, comparative, randomized, and single-blinded study of 100 MDR tuberculosis patients and a molecular pharmacological analytical study were performed. For 24–48 weeks, Group A patients were prescribed oral delamanid 100 mg twice daily, and Group B patients were prescribed oral ofloxacin 400 mg twice daily, in accordance with the followed anti-MDR tubercular treatment regimens and the respective tuberculosis patient category. The comparative antitubercular pharmacotherapeutic occurrence of adverse effects, due to oral delamanid therapy and oral ofloxacin therapy, was thoroughly analyzed, by performing the causality assessment score estimation, deduced from the grading and staging of the adverse drug reactions, sequentially. The pharmacovigilance safety assessment was done by the monitoring of adverse drug reactions, such as nausea, vomiting, headache, insomnia, dizziness, tinnitus, hypokalemia, gastritis, decreased appetite, and asthenia,

Access this article online

IJSS

www.ijss-sn.com

Month of Submission : 10-2021
Month of Peer Review : 11-2021
Month of Acceptance : 11-2021
Month of Publishing : 12-2021

Corresponding Author: Dr. Moumita Hazra, Dr. Moumita Hazra's Polyclinic and Diagnostic Centre, Hazra Nursing Home, Jagadishpur Road, P.O. Domjur, Howrah - 711 405, West Bengal, India.

among Group A patients (delamanid therapy), and monitoring of adverse drug reactions, such as nausea, vomiting, diarrhea, pruritis, insomnia, headache, vaginitis, and dizziness, among Group B patients (ofloxacin therapy), with Adverse Event Case Report Forms, on days 0, 30, 60, 90, 120, 150, 180, 210, 240, 270, 300, 330, and 360 and on further follow-ups. Evaluation of the patient compliance and molecular pharmacological analysis of delamanid were also performed. The quantitative data recordings were statistically analyzed.

Results: The safety assessment showed that both in Group A and Group B patients, the occurrence of adverse effects was statistically non-significant. For both delamanid and ofloxacin, the causality grading was "No" = –1, with causality staging of "None," for all the causality assessment attributes, as there were no occurrence of any adverse effect, with delamanid or ofloxacin. The causality assessment scoring for delamanid: –12, none on average = unlikely causality of adverse drug reaction, and the causality assessment scoring for ofloxacin: –12, none on average = unlikely causality of adverse drug reaction. All the patients completed the treatment thoroughly, with no dropout patients due to adverse effects, no lost to follow-up patients, and no voluntarily withdrawn patients. The molecular pharmacological analysis of delamanid depicted its molecular efficiency in MDR antitubercular pharmacotherapeutic applications.

Conclusions: Both delamanid and ofloxacin were safe and tolerable among MDR tuberculosis patients; with nil causality association of adverse drug reactions. The patients' adherence to antitubercular treatment was very high. The molecular pharmacological analysis of delamanid depicted its molecular efficiency in MDR antitubercular pharmacotherapeutic applications.

Key words: Causality assessment grading and staging score, Delamanid, Fluoroquinolones, Molecular pharmacotherapeutics, Multidrug-resistant tuberculosis, Nitroimidazoles, Ofloxacin, Pharmacovigilance.

INTRODUCTION

The World Health Organization (WHO) estimated that over 480,000 cases of multidrug-resistant (MDR) tuberculosis occur every year globally, 9% of them being affected by extensively drug-resistant (XDR) strains of *Mycobacterium tuberculosis*. MDR, to at least rifampicin and isoniazid, is mainly acquired by alteration of the bacilli or by alteration of drug target through mutation or bacilli titration of the drug through overproduction of target. The treatment of MDR/XDR TB is unfortunately long, expensive, producing further resistance, with increased occurrence of adverse events, and the success rate largely unsatisfactory (<20% among cases with resistance patterns beyond XDR), mostly due to the insufficient number of active drugs during both intensive and continuation phases.[1-4] Delamanid, a nitro-dihydro-imidazoxazole, is a bactericidal cell wall methoxy-mycolic and keto-mycolic acids biosynthesis inhibitor in actively replicating, dormant, and intracellular *M. tuberculosis*, and both drug-susceptible and drug-resistant strains of *M. tuberculosis* and *Mycobacterium kansasii*, decreasing hydrophobicity, and facilitating better bacterial drug penetration. Delamanid promotes intracellular generation of microbiocidal nitrogen oxidative intermediaries including nitric oxide, toxic even to dormant *M. tuberculosis*.[5] Ofloxacin, the racemic mixture, is bactericidal to *M. tuberculosis*, *Mycobacterium avium* complex, *Mycobacterium fortuitum*, and other atypical mycobacteria, with their inhibitory effect on DNA gyrase, DNA topoisomerase IV, and pro-inflammatory cytokines interleukins: IL-1α, IL-6, IL-8, and tumor necrosis factor α, along with their superinducing effect on IL-2.[5-11]

Objective

The objective of this quantitative comparative study was the pharmacovigilance scoring of causality assessment grading and staging of delamanid and ofloxacin, among global MDR tuberculosis patients, and a molecular pharmacological analysis of delamanid, as an antitubercular drug.

METHODS

Ethical Approval

At first, the Institutional Ethics Committee clearance and approval was taken. The study was conducted in accordance with the ethical principles of the Declaration of Helsinki and Good Clinical Practices contained within the International Council for Harmonization of Technical Requirements for Pharmaceuticals for Human Use (ICH-E6) and in compliance with the global regulatory requirements. The patients who were included in the study were assured confidentiality, and an informed consent was obtained from each patient.

Study Design

It was a global, multicenter, prospective, comparative, randomized, and single-blinded study and a molecular pharmacological analytical study.

Study Population

The study population consisted of 100 global multidrug-resistant tuberculosis patients.

Selection Criteria of the Study Population

Inclusion criteria

The following criteria were included in the study:

(i) Patients of any gender, (ii) patients within 18 and 55 years, (iii) patients presenting with multi drug-resistant

tuberculosis with a baseline drug susceptibility testing result confirming MDR-TB (sample collected either before starting MDR-TB treatment or ≤1 month after commencement), (iv) the WHO definitions, criteria, and categorizations for tuberculosis, (v) cooperative and conscious patients, (vi) patients willing to undergo all pre- and post-treatment investigations and willing to complete the entire course of treatment, (vii) patients who have given consent and are willing to go for a follow-up, (viii) patients not taking any previous antitubercular drug, and (ix) patients not taking any concomitant medication.

Exclusion criteria

The following criteria were excluded from the study:
(i) Uncooperative or unconscious patients, (ii) patients below 18 and above 55 years, (iii) patients presenting with any category other than multidrug-resistant tuberculosis, (iv) patients with a history of hypersensitivity to any of the study drugs, (v) patients with high-risk diseases or comorbidities, (vi) cardiac, renal, or any other associated complications or comorbidities, (vii) any chronic disease intervening with the study data, (viii) immunocompromised patients, (ix) patients suffering from gastrointestinal diseases such as peptic ulcer, regional enteritis, and ulcerative colitis, (x) pregnant or lactating women (women of child-bearing potential are required to have a negative urine pregnancy test result and to agree to use an effective form of contraception for the duration of study), (xi) children or very old patients, (xii) other associated medical illness or disorders having impact on study results, and (xiii) female patients using hormonal contraceptives.

Study Period

The study period, comprising the periods for the research study and the compilation of the study literature, was 2 years 1 month, from September 1998 to December 1998; December 2012 to April 2013; December 2016; and October 2020 to December 2021.

Place of Study

The research study and the compilation of the study literature were done in the Departments of Pharmacology, Clinical Pharmacology, Molecular Pharmacology, Rational Pharmacotherapeutics, Pharmacoepidemiology, Pharmacovigilance, Pharmacogenomics, Pathology, Clinical Pathology, Molecular Diagnostics, Internal Medicine, Tuberculosis, Chest Diseases and Respiratory Medicine, Cardiology, Clinical Research, in global multicenter tertiary care hospitals: Dr. Moumita Hazra's Polyclinic and Diagnostic Centre, Hazra Nursing Home, Mamata Medical College and Hospitals, Rama Medical College Hospital and Research Centre, Rama University, J. J. M. Medical College and Hospitals, Presidency College, All India Institute of Medical Sciences, and GIOSTAR Institute of Regenerative Medicine Institutes, Hospitals and Laboratories.

Study Procedure

In this study, 100 global MDR tuberculosis patients were randomly allocated into Group A (delamanid therapy) = 50 patients and Group B (levofloxacin therapy) = 50 patients. The study patients were single blinded, regarding the allotted drug therapy being administered. For 24–48 weeks, Group A patients were prescribed antitubercular drug oral delamanid 100 mg twice daily, and Group B patients were prescribed antitubercular drug oral ofloxacin 400 mg twice daily, in accordance with the MDR-TB treatment regimens, recommended by the WHO, The American Thoracic Society, U.S. Centers for Disease Control and Prevention, European Respiratory Society, Infectious Diseases Society of America and similar associations, ratified by Grading of Recommendations, Assessment, Development, and Evaluation methodology, and the respective tuberculosis patient category.[12,13] From the 100 multidrug-resistant tuberculosis patients, thorough patients' history with complete examination details, before and after the administration of the study drugs therapy, was obtained with the study pro forma, thoroughly analyzed and the following details were recorded: The patients' participation assessment and adherence to treatment (including patients who completed the study thoroughly), patients who were dropout patients due to adverse effects, lost to follow-up patients, and patients who withdrew voluntarily; the demographic characteristics, including age, gender, race, duration of symptoms of tuberculosis, severity of tuberculosis symptoms, present controller medications, the patients' present and past history, smoking history, respiratory history including respiratory infection and immunological history, chronic obstructive pulmonary disease, history of MDR-TB contacts, past TB treatment history, defined as new cases (≤1 month of antituberculosis treatment), previously treated cases (first and second line antituberculosis drugs), presence of cavities on chest radiograph, sputum smear microscopy results (negative, low [scanty or 1+] and high bacillary load [2+ or 3+]), and drug susceptibility testing results, cardiac history, history of comorbidities, family history, personal history, socioeconomic history, reproductive history, concomitant medication history, surgical history, and the symptomatic effect of treatment on tuberculosis. Details of complete general physical examination, including body mass index, pulse rate, respiratory rate, oxygen saturation, and systemic examination, including oto-rhino-laryngo-tracheal, respiratory, and cardiopulmonary examinations, were recorded. The WHO definitions of treatment outcomes requiring at least five consecutive

negative culture results during the final 12 months of treatment were to be classified as cured, and either two positive results among the five cultures recorded in the final 12 months, one positive in any one of the final three cultures, or a clinical decision, was to be considered, to continue or discontinue treatment depending on the treatment success or failure respectively. Favorable outcome was defined as a combination of cured and treatment completed, and unfavorable outcome as a combination of death and failure. Multidrug resistance was defined as resistance to at least rifampicin and isoniazid that had been detected at baseline. The details of the suspected drug causing adverse effects, drug dose, route of administration, drug frequency, drug starting date, drug stopping date, expiry date of the drug, batch no./lot no. of the drug, drug manufacturer's name, brand/generic name of the drug, indications for the usage of the suspected drug, any concomitant medicines, and description of adverse reaction: Clinical and pharmacological, supporting laboratory investigation results, treatment given for the adverse drug reaction, any specific antagonistic drug given to treat the adverse reactions, and clinical outcomes, were recorded and thoroughly analyzed.

The comparative antitubercular pharmacotherapeutic occurrence of adverse effects, due to oral delamanid therapy and oral ofloxacin therapy, was thoroughly analyzed, with adequate consideration of causality assessment grading and staging. The causality assessment score estimation was deduced from the grading and staging of the adverse drug reactions, sequentially (Sources of Excerpts: Naranjo Algorithm – Adverse Drug Reactions Probability Scale [Table 1] and WHO – Uppsala Monitoring Centre Causality Categories [Table 2] modified and adapted, in the compilation of Causality Assessment Score Estimation Methodology, by Grading and Staging of the Causality of Adverse Drug Reactions).[14,15] The causality assessment attributes analyzed and graded were as follows: (i) History of hypersensitivity to the same drug administered; (ii) history of hypersensitivity to the same generic category of drug administered; (iii) history of adverse drug reaction-like symptoms previously; (iv) occurrence of adverse drug reaction after the suspected drug administration; (v) improvement of adverse drug effects after discontinuation of the drug, modification of drug dose, alternate drug administration, or specific antagonist administration; (vi) appearance of adverse drug effects after recontinuation of the drug, reversal to previous drug dose on patient stabilization, reversal to previous drug administration, or discontinuation of antagonist administration; (vii) alternative coexisting sources, like disease or medications, causing adverse drug effect-like reaction; (viii) false adverse drug effect mimicking reactions; (ix) appearance of adverse drug effect with a placebo; (x) detection of the suspected drug in body fluids in toxic concentrations; (xi) severity of adverse drug reactions with increase or decrease of drug dose; and (xii) occurrence of adverse drug reactions with the suspected drug in a time-variant or place-variant manner, along with the grading of "Yes" = +1, "No" = -1, and "Uncertain" = 0. The causality assessment grades were subsequently staged into none, mild, moderate, or severe stages. Then, the causality assessment scores were derived from the recorded grading and staging, as follows:

a. ≥9, severe on average = Definite causality of adverse drug reaction
b. 5–8, moderate-severe on average = Probable causality of adverse drug reaction
c. 1–4, mild-moderate on average = Possible causality of adverse drug reaction
d. ≤0, mild or none on average = Doubtful/unlikely causality of adverse drug reaction
e. ≤0–>0 variable, variable on average = Conditional/unclassified causality of adverse drug reaction
f. ≥0 variable, variable on average = Unassessable/unclassifiable causality of adverse drug reaction

Finally, the pharmacovigilance safety assessment was done by the monitoring of adverse drug reactions, such as nausea, vomiting, headache, insomnia, dizziness, tinnitus,

Table 1: Naranjo algorithm – adverse drug reaction probability scale[14]

Score	Adverse drug reaction categories	Interpretation of scores
Total score: ≥9	Definite	The reaction (1) followed a reasonable temporal sequence after a drug or in which a toxic drug level had been established in body fluids or tissues, (2) followed a recognized response to the suspected drug, and (3) was confirmed by improvement on withdrawing the drug and reappeared on re-exposure
Total score: 5–8	Probable	The reaction (1) followed a reasonable temporal sequence after a drug, (2) followed a recognized response to the suspected drug, (3) was confirmed by withdrawal but not by exposure to the drug, and (4) could not be reasonably explained by the known characteristics of the patient's clinical state
Total score: 1–4	Possible	The reaction (1) followed a temporal sequence after a drug, (2) possibly followed a recognized pattern to the suspected drug, and (3) could be explained by characteristics of the patient's disease
Total score: ≤0	Doubtful	The reaction was likely related to factors other than a drug

hypokalemia, gastritis, decreased appetite, and asthenia among Group A patients (delamanid therapy), and monitoring of adverse drug reactions, such as nausea, vomiting, diarrhea, pruritis, insomnia, headache, vaginitis, and dizziness, among Group B patients (ofloxacin therapy), with Adverse Event Case Report Forms, on days 0, 30, 60, 90, 120, 150, 180, 210, 240, 270, 300, 330, and 360 and on further follow-ups. The adverse drug reactions listed by MedDRA System Organ Class and Preferred Term were taken into consideration, along with emphasis on the adverse reactions, within each System Organ Class, under frequency categories of very common (≥1/10), common (≥1/100–<1/10), uncommon (≥1/1000–<1/100), rare (≥1/10,000–<1/1000), very rare (<1/10,000), and not known (cannot be estimated from the available data). The analysis of different attributes of patient compliance was also performed.

The molecular pharmacological basis of the antitubercular pharmacotherapeutic drug delamanid was also thoroughly analyzed from wide ranged molecular pharmacological research, review, and case presentation study literature to illuminate on the antimycobacterial rationale of the clinical pharmacotherapeutic use of this nitroimidazole delamanid, among MDR tuberculosis patients.

Statistical Analysis

The statistical analyses were made by unpaired *t*-test, Chi-square test, one-way ANOVA test, two samples Z-test, and test of significance with p values, with subsequent tabular representations.

RESULTS

All the patients completed the treatment thoroughly. There were no dropout patients due to adverse effects, no patients were lost to follow-up and no patients voluntarily withdrew. The patients' adherence to antitubercular treatment was very high. The demographic characteristics of the patients receiving antitubercular delamanid and ofloxacin therapies were comparable. Adverse effects were negligible in either group. Thus, the safety assessment showed that both in Group A [Table 3] and Group B [Table 4] patients, the occurrence of adverse effects was statistically non-significant. Tolerability was good for both delamanid and ofloxacin, among MDR tuberculosis patients.

Table 5 depicts that for both delamanid and ofloxacin, the causality grading was "No" = –1, with causality staging of "None," for all the causality assessment attributes, as there were no occurrence of any adverse effect, with delamanid or ofloxacin. Therefore, the causality assessment scorings were as follows:

- Causality assessment scoring for delamanid: –12, none on average = unlikely causality of adverse drug reaction
- Causality assessment scoring for ofloxacin: –12, none on average = unlikely causality of adverse drug reaction.

Causality Grading

Yes = +1, no = −1, uncertain = 0.

Table 2: World Health Organization – Uppsala monitoring center causality categories[15]

Causality term	Assessment criteria
Certain	• Event or laboratory test abnormality, with plausible time relationship to drug intake • Cannot be explained by disease or other drugs • Response to withdrawal plausible (pharmacologically, pathologically) • Event definitive pharmacologically or phenomenologically (i.e., an objective and specific medical disorder or a recognized pharmacological phenomenon) • Rechallenge satisfactory, if necessary
Probable/likely	• Event or laboratory test abnormality, with reasonable time relationship to drug intake • Unlikely to be attributed to disease or other drugs • Response to withdrawal clinically reasonable • Rechallenge not required
Possible	• Event or laboratory test abnormality, with reasonable time relationship to drug intake • Could also be explained by disease or other drugs • Information on drug withdrawal may be lacking or unclear
Unlikely	• Event or laboratory test abnormality, with a time to drug intake that makes a relationship improbable (but not impossible) • Disease or other drugs provide plausible explanations
Conditional/ unclassified	• Event or laboratory test abnormality • More data for proper assessment needed, or • Additional data under examination
Unassessable/ unclassifiable	• Report suggesting an adverse reaction • Cannot be judged because information is insufficient or contradictory • Data cannot be supplemented or verified

Table 3: Group A: The occurrence of adverse effects with delamanid therapy

Serial No.	Adverse effects	Number of patient occurrence	Z-value	*P*-value
1.	Nausea	0	-	Non-significant
2.	Vomiting	0	-	Non-significant
3.	Headache	0	-	Non-significant
4.	Insomnia	0	-	Non-significant
5.	Dizziness	0	-	Non-significant
6.	Tinnitus	0	-	Non-significant
7.	Hypokalemia	0	-	Non-significant
8.	Gastritis	0	-	Non-significant
9.	Decreased appetite	0	-	Non-significant
10.	Asthenia	0	-	Non-significant

Staging of Causality Grades

None, mild, moderate, and severe.

Causality Assessment Scoring

- ≥9, severe on average = Definite causality of adverse drug reaction
- 5–8, moderate-severe on average = Probable causality of adverse drug reaction
- 1–4, mild-moderate on average = Possible causality of adverse drug reaction
- ≤0, mild or none on average = Doubtful/unlikely causality of adverse drug reaction
- ≤0–>0 variable, variable on average = Conditional/unclassified causality of adverse drug reaction
- ≥0 variable, variable on average = Unassessable/unclassifiable causality of adverse drug reaction.

Table 4: Group B: The occurrence of adverse effects with ofloxacin therapy

Serial No.	Adverse effects	Number of patient occurrence	Z-value	*P*-value
1.	Nausea	0	-	Non-significant
2.	Vomiting	0	-	Non-significant
3.	Diarrhea	0	-	Non-significant
4.	Headache	0	-	Non-significant
5.	Dizziness	0	-	Non-significant
6.	Skin rash	0	-	Non-significant
7.	Arthralgia	0	-	Non-significant

The molecular pharmacological analysis of delamanid, as derived from the evidence-based medical databases, illuminated on its systematic functional synchrony in the antimycobacterial pharmacodynamic and pharmacotherapeutic response mechanisms, and established that the clinical pharmacotherapeutic applications of delamanid are very beneficial among MDR and extensively drug-resistant tuberculosis patients, mostly, because of its unique activities of facilitation of better bacterial drug penetration, owing to decreased hydrophobicity; accompanied by its promotion of intracellular generation of microbiocidal nitrogen oxidative intermediaries, which supplements its efficacy, among MDR and extensively drug-resistant tuberculosis patients.

DISCUSSION

Delamanid needs mycobacterial F420 system for its activation. This system is the analog of flavin mononucleotide complex and composed of two enzymes, deazaflavin-dependent nitroreductase (Ddn, Rv3547) and F420-dependent glucose-6-phosphate dehydrogenase (G6PD; FGD1, Rv0407), as well as four coenzymes, *Fbi*A (Rv3361), *Fbi*B (Rv3261), *Fbi*C (Rv1173), and Rv0132c. All of these genes and coenzymes are involved in the synthesis and recycling of cofactor F-420. Delamanid has undergone the influence of the Ddn enzyme for converting into its active and inactive forms, an unknown reactive intermediate metabolite that is active against

Table 5: Pharmacovigilance causality assessment grading and staging scores

Serial No.	Causality assessment attributes	Causality grading for delamanid	Causality grading for ofloxacin	Staging of causality grades for delamanid	Staging of causality grades for ofloxacin
1.	History of hypersensitivity to the same drug administered	–1	–1	None	None
2.	History of hypersensitivity to the same generic category of drug administered	–1	–1	None	None
3.	History of adverse drug reaction-like symptoms previously	–1	–1	None	None
4.	Occurrence of adverse drug reaction after the suspected drug administration	–1	–1	None	None
5.	Improvement of adverse drug effects after discontinuation of drug, modification of drug dose, alternate drug administration, or specific antagonist administration	–1	–1	None	None
6.	Appearance of adverse drug effects after recontinuation of drug, reversal to previous drug dose on patient stabilization, reversal to previous drug administration, or discontinuation of antagonist administration	–1	–1	None	None
7.	Alternative coexisting sources, such as disease or medications, causing adverse drug effect-like reaction	–1	–1	None	None
8.	False adverse drug effect mimicking reactions	–1	–1	None	None
9.	Appearance of adverse drug effect with a placebo	–1	–1	None	None
10.	Detection of the suspected drug in body fluids in toxic concentrations	–1	–1	None	None
11.	Severity of adverse drug reactions with increase or decrease of drug dose	–1	–1	None	None
12.	Occurrence of adverse drug reactions with the suspected drug in a time-variant or place-variant manner	–1	–1	None	None

M. tuberculosis and a desnitro (inactive) form, respectively. The main function of delamanid in preventing mycolic acid biosynthesis is attributed to the reactive intermediate metabolite. The removal of this major compound from *Mycobacterium* cell wall leads to the destruction of this bacterium. G6PD is also responsible for returning the F420 to the reduced form.

During dose-escalation studies, administration of higher oral doses was associated with a less than proportional increase in plasma exposure.[16]

In one study, the safety assessments were performed by the different safety tests, including the following: Monthly physical examinations, weekly assessment of vital signs, standard 12-lead ECG, clinical laboratory tests (including a hematologic profile, coagulation measurements, a urinalysis, and measurements of hepatic aminotransferase and thyroid and adrenal hormone levels), and baseline audiometry. The QT interval duration for each ECG was corrected with the use of Fridericia's formula: Corrected QT interval = QT × (1000 ÷ RR interval in milliseconds) 0.33. Use of concomitant medications was recorded daily, and adverse events were documented; immediately reportable events and clinically significant abnormal laboratory results were evaluated as appropriate. The microbiologic assessments were performed with morning sputum specimens obtained during the 8-week treatment period and during the 4-week post-treatment period on days 0.1, 1, 8, 15, 22, 29, 36, 43 50, 57, 63, 70, 77, and 84. If patients were unable to expectorate sputum, attempts were made to induce sputum expectoration with the use of aerosol inhalation. Sputum samples were deemed unobtainable if no sputum could be obtained after induction. Samples were cultured in liquid broth medium (in an automated mycobacterial growth indicator tube system) and in solid mycobacteriological culture medium (with the use of egg-based Lowenstein Jensen medium for 90% of the patients). Mycobacterial cultures were identified according to the growth and morphologic characteristics of the colony and with the use of commercial identification methods, including DNA hybridization systems, DNA amplification methods and GenoType MTBDRplus, or other standardized methods. Microbiological tests were performed in local laboratories in accordance with guidelines from the Clinical and Laboratory Standards Institute for sputum processing, smear microscopy, culture techniques, drug-susceptibility testing, and identification of mycobacteria.[17]

Delamanid's activity requires the mycobacterial deazaflavin F420-dependent G6PD, Fgd 1, and resistance to delamanid is conveyed by mutations of either F420 or Fgd 1. Delamanid is a prodrug that must be reduced by the deazaflavin-dependent nitroreductase to its desnitro metabolite to be active. Mutations of Rv3547, the gene coding for the deazaflavin-dependent nitroreductase, also convey mycobacterial resistance to delamanid. The early bacterial activity of delamanid, 400 mg daily, was modest for the first 4 days but subsequently the number of CFU in cultured sputum decreased progressively to day 14. In another pulmonary TB study in man, the number of MTB colonies declined steadily with all doses of delamanid over 14 days. Although the differences were not statistically significant, there was a trend to a greater effect with increasing daily doses between 100 mg and 300 mg.[5]

In another study, it was found that mutations in *fbi*C and *ddn* gene may be conferred to delamanid resistance on *M. tuberculosis* isolates.[18]

With the advent of quinolones, and later the fluorinated 4-quinolones, the fluoroquinolones, the medical world has certainly taken long strides in treating enormous number of diseases.

Fluoroquinolones are chemical derivatives of quinoline, the prodrome of chloroquine. Fluoroquinolones, a family of 6-fluoro-7-piperazinyl-4-quinolones, are broad-spectrum synthetic antimicrobial agents derived from quinolones with the addition of a fluorine atom attached to the central ring.

Substitution at C-7 or its N-4-piperazinyl moiety was found to affect potency, bioavailability, and physicochemical properties. Furthermore, it can increase the affinity towards mammalian topoisomerases that may shift quinolones from antibacterial to anticancer candidates. Moreover, the presence of DNA topoisomerases in both eukaryotic and prokaryotic cells makes them excellent targets for chemotherapeutic intervention in antibacterial and anticancer therapies.

Fluoroquinolones are quite significantly efficacious for their bactericidal inhibitory effect on:

1. DNA gyrase caused by the binding of fluoroquinolones to the A subunits (gyr A), thus inhibiting the replication and transcription of bacterial DNA, responsible for the proper functioning of the cell, and the subsequent change of conformity of DNA gyrase molecule caused by the binding of fluoroquinolones to the DNA-binding groove between A (gyr A) and B (gyr B) subunits
2. Par C subunits (par C) and Par E subunits (par E) of DNA topoisomerase IV, thus inhibiting decatenation and relaxation of DNA and segregation of replicating chromosomes or plasmids in bacteria
3. Pro-inflammatory cytokines, such as interleukins: IL-1α, IL-6, IL-8, and tumor necrosis factor-α, leading to

attenuation of inflammatory response and exhibiting multiple immunomodulatory actions.

Fluoroquinolones also have superinducing effect on interleukin IL-2.

The first-generation quinolones (e.g., nalidixic acid) achieve minimal serum levels. The second-generation quinolones (e.g., ciprofloxacin) have increased Gram-negative and systemic activity. The third-generation quinolones (e.g., levofloxacin) have expanded activity against Gram-positive bacteria and atypical pathogens. The fourth-generation quinolones (e.g.: trovafloxacin) have significant activity against anaerobes. The fifth-generation quinolones (e.g.: aravofloxacin) have activity against multi-resistant pathogens.

They are characterized by advantageous pharmacokinetic properties; higher concentrations in the lungs; and an excellent safety profile comparable to other antibiotics used to treat respiratory infections, such as macrolides and β-lactams.

The newer fluoroquinolones have broad-spectrum bactericidal activity, excellent oral bioavailability, good tissue penetration, and favorable safety and tolerability profiles.[19-24]

In this study, the safety assessment showed that both in Group A and Group B patients, the occurrence of adverse effects was statistically non-significant. For both delamanid and ofloxacin, the causality grading was "No" = –1, with causality staging of "None," for all the causality assessment attributes, as there was no occurrence of any adverse effect, with delamanid or ofloxacin. The causality assessment scoring for delamanid: –12, none on average = unlikely causality of adverse drug reaction, and the causality assessment scoring for ofloxacin: –12, none on average = unlikely causality of adverse drug reaction. All the patients completed the treatment thoroughly, with no dropout patients due to adverse effects, no lost to follow-up patients, and no patients who voluntarily withdrew. The molecular pharmacological analysis of delamanid depicted its molecular efficiency in MDR antitubercular pharmacotherapeutic applications.

CONCLUSIONS

The patients' adherence to antitubercular treatment was very high. Both delamanid and ofloxacin were safe and tolerable among MDR tuberculosis patients; with nil causality association of adverse drug reactions. The molecular pharmacological analysis of delamanid depicted its efficiency in the pharmacotherapeutic application among global MDR and extensively drug-resistant tuberculosis patients.

ACKNOWLEDGMENTS

My profound gratitude to the Departments of Pharmacology, Clinical Pharmacology, Molecular Pharmacology, Rational Pharmacotherapeutics, Pharmacoepidemiology, Pharmacovigilance, Pharmacogenomics, Tuberculosis, Chest Diseases, Respiratory Medicine, Cardiology, Internal Medicine, Pathology, Clinical Pathology, Molecular Diagnostics, and Clinical Research, in Dr. Moumita Hazra's Polyclinic and Diagnostic Centre, Hazra Nursing Home, West Bengal, India, World, J. J. M. Medical College and Hospitals, Karnataka, India, GIOSTAR IORM Institutes, Hospitals and Laboratories, New Delhi, India, United States of America, World, Rama Medical College Hospital and Research Centre, Rama University, Uttar Pradesh, India, and Mamata Medical College and Hospitals, Khammam, Telangana, India, for the successful completion of this research project.

REFERENCES

1. Falzon D, Schünemann HJ, Harausz E, González-Angulo L, Lienhardt C, Jaramillo E, *et al*. World Health Organization treatment guidelines for drug-resistant tuberculosis, 2016 update. Eur Respir J 2017;49:1602308.
2. D'Ambrosio L, Centis R, Sotgiu G, Pontali E, Spanevello A, Migliori GB. New anti-tuberculosis drugs and regimens: 2015 update. ERJ Open Res 2015;1:00010.
3. Pontali E, Sotgiu G, Tiberi S, Tadolini M, Visca D, D'Ambrosio L, *et al*. Combined treatment of drug-resistant tuberculosis with bedaquiline and delamanid: A systematic review. Eur Respir J 2018;52:1800934.
4. Sapkal PM, Pantwalawalkar JR. Tuberculosis drug resistance: An overview. Int J Res Methodol 2015;1:8-18.
5. Field SK. Safety and efficacy of delamanid in the treatment of multidrug-resistant tuberculosis (MDR-TB). Clin Med Insights Ther 2013;5:137-49.
6. Chang KC, Yew WW. Management of difficult multidrug-resistant tuberculosis and extensively drug-resistant tuberculosis: Update 2012. Respirology 2013;18:8-21.
7. Tiberi S, Scardigli A, Centis R, D'Ambrosio L, Muñoz-Torrico M, Salazar-Lezama MÁ, *et al*. Classifying new anti-tuberculosis drugs: Rationale and future perspectives. Int J Infect Dis 2017;56:181-4.
8. Migliori GB, Tiberi S, Zumla A, Petersen E, Chakaya JM, Wesje C, *et al*. MDR/XDR-TB management of patients and contacts: Challenges facing the new decade. The 2020 clinical update by the global tuberculosis network. Int J Infect Dis 2020;92S: S15-25.
9. Gupta R, Wells CD, Hittel N, Hafkin J, Geiter LJ. Delamanid in the treatment of multidrug-resistant tuberculosis. Int J Tuberc Lung Dis 2016;20:S33-7.
10. Sotgiu G, D'Ambrosio L, Centis R, Mura I, Castiglia P, Spanevello A, *et al*. The multidrug-resistant tuberculosis threat: Old problems and new solutions. J Thorac Dis 2015;7:E354-60.
11. Mohammed HH, Abuo-Rahma GE, Abbas SH, Abdelhafez EM. Current trends and future directions of fluoroquinolones. Curr Med Chem 2019;26:3132-49.
12. Nahid P, Mase SR, Miglior GB, Sotgiu G, Bothamley GH, Brozek JL, *et al*. Treatment of drug-resistant tuberculosis. An official ATS/CDC/ERS/IDSA clinical practice guideline. Am J Respir Crit Care Med 2020;201:500-1.
13. World Health Organization. 2020. Global Tuberculosis Report. Geneva, Switzerland: World Health Organization; 2020. Available form: https://

www.who.int/teams/global-tuberculosis-programme/tb-reports. [Last accessed on 2021 Sep 21].
14. Naranjo CA, Busto U, Sellers EM, Sandor P, Ruiz I, Roberts EA, Janecek E, *et al*. A method for estimating the probability of adverse drug reactions. Clin Pharmacol Ther 1981;30:239-45.
15. WHO-UMC System for Standardized Case Causality Assessment. Geneva: World Health Organisation (WHO)-Uppsala Monitoring Centre. Available from: http://www.who-umc.org/Graphics/24734.pdf [Last accessed on 2021 Nov 30].
16. Khoshnood S, Taki E, Sadeghifard N, Kaviar VH, Haddadi MH, Farshadzadeh Z, *et al*. Mechanism of action, resistance, synergism, and clinical implications of delamanid against multidrug-resistant *Mycobacterium tuberculosis*. Front Microbiol 2021;12:717045.
17. Zheng H, He W, Jiao W, Xia H, Sun L, Wang S. Molecular characterization of multidrug resistant tuberculosis against levofloxacin, moxifloxacin, bedaquiline, linezolid, clofazimine, and delamanid in Southwest of China. BMC Infect Dis 2021;21:330.
18. Gler MT, Skripconoka V, Sanchez-Garavito E, Xiao H, Cabrera-Rivero JL, Vargas-Vasquez DE. Delamanid for multidrug-resistant pulmonary tuberculosis. N Engl J Med 2021;366:2151-60.
19. Hazra M. A multivariate comparative clinical pharmacotherapeutic efficacy and chronopharmacovigilance assessment study of ofloxacin, one of the commonplace TGFβ1 inducing and telomerase impairing fluoroquinolones, in treating acute gastroenteritis, chronic obstructive pulmonary disease, new drug-sensitive tuberculosis, recurrent mixed cutaneous infections, and post-surgical refractory wound infections, among the global patients, with heterogenous pharmacogeographic and pharmacogenomic constitution. Int J Basic Clin Pharmacol 2021;10:270-80.
20. Karampela I, Dalamaga M. Could respiratory fluoroquinolones, levofloxacin and moxifloxacin, prove to be beneficial as an adjunct treatment in COVID-19? Arch Med Res 2020;51:741-2.
21. Brar RK, Jyoti U, Patil RK, Patil HC. Fluoroquinolone antibiotics: An overview. Adesh Univ J Med Sci Res 2020;2:26-30.
22. World Health Organization. 2020. Differences Among Fluoroquinolones in the Treatment of MDR-TB. Geneva: World Health Organisation Archives. https://www.archives.who.int. [Last accessed on 2021 Sep 21].
23. Tripathi KD. Antitubercular Drugs. In: Tripathi M, editor. Essentials of Medical Pharmacology. 7th ed. New Delhi, London, Philadelphia, PA: Jaypee Brothers Medical Publishers Ltd.; 2013. p. 765-79.
24. Gumbo T. Chemotherapy of tuberculosis, *Mycobacterium avium* complex disease, and leprosy. In: Brunton LB, Hilal-Dandan R, Knollmann BC, editors. Goodman and Gilman's the Pharmacological Basis of Therapeutics. 13th ed. New York, Chicago: McGraw-Hill; 2018. p. 1067-86.

How to cite this article: Hazra M. A Quantitative Comparative Pharmacovigilance Scoring of Causality Assessment Grading and Staging of Delamanid and Ofloxacin, Among Global Multidrug-Resistant Tuberculosis Patients, and a Molecular Pharmacological Analysis of Delamanid, as an Antitubercular Drug. Int J Sci Stud 2021;9(9):78-86.

Source of Support: Nil, **Conflicts of Interest:** None declared.

Print ISSN: 2321-6379
Online ISSN: 2321-595X

Original Article

Breakthrough Coronavirus Disease Infection after Vaccination among Type 2 Diabetes Mellitus Patients in a Tertiary Care Hospital in India

Balaji Vijayam[1], Taarika Balaji[2], Madhuri S Balaji[3], Seshiah Veerasamy[3], A Anitha Rani[4]

[1]Chairman and Managing Director, Senior Consultant, Department of Diabetology, Dr. V Balaji Dr. V Seshiah Diabetes Care and Research Institute, Aminjikarai, Chennai, Tamil Nadu, India, [2]Student, Saveetha Institute of Technical and Medical Sciences, Chennai, Tamil Nadu, India, [3]Senior Consultant, Department of Diabetology, Dr. V Balaji Dr. V Seshiah Diabetes Care and Research Institute, Aminjikarai, Chennai, Tamil Nadu, India, [4]Research Scientist, Dr. V Balaji Dr. V Seshiah Diabetes Care and Research Institute, Aminjikarai, Chennai, Tamil Nadu, India

Abstract

Aim: Globally, pandemic coronavirus 2019 has gained attention for its rapid and exponential diffusion. In India, coronavirus disease (COVID-19) vaccination has become available to all adults, yet the disease continues to spread. The current study aimed to determine the breakthrough of the COVID-19 infection after vaccination among type 2 diabetes mellitus (T2DM) patients in a tertiary care hospital.

Materials and Methods: The retrospective, observational study was conducted among post-vaccinated T2DM patients infected with COVID-19 from May 2021 to October 2021. The specific vaccination details for COVID-19, along with vaccination date, 1st or 2nd dose, symptoms, onset of symptoms after vaccinations (in days), and severity of infection were recorded accordingly.

Results: Out of 3243 vaccinated patients, 36 were reported to be infected with COVID-19, post any dose of vaccine (Covaxin = 14; CoviShield = 22). The second dose was completed in 24 (66.66%) patients. Symptomatic COVID infection was observed in 97.2% (n = 35) and 2.77% (n = 1) showed asymptomatic infection. Infection occurred any time after 14 days of post-vaccination was observed in 23 patients, of which 16 patients (5 Covaxin and 11 CoviShield) were vaccinated completely and considered to have a breakthrough infection of COVID-19. Mild-to-moderate infection was observed in 25 (39.44%) patients and was home quarantined and 11 (30.5%) patients had severe to critical illness and required hospitalization.

Conclusion: The current study finding highlighted that the symptomatic breakthrough infections are observed in T2DM patients. Further research on breakthrough infections in Indian population is required to obtain the larger data set to work with it.

Key words: Coronavirus disease-19, Vaccination, Breakthrough infection

INTRODUCTION

Worldwide, the coronavirus disease (COVID-19) pandemic alert is a major challenge confronted and many efforts have been initiated to prevent and control the infection. In recent times, many efficient vaccines have been discovered[1-4] and showed significant protection against the infection. In India, the vaccination campaign starts from January 2021 and used CoviShield (AstraZeneca) and Covaxin (Bharat Biotech). Till now, 4,136,000 individuals have been fully vaccinated. From May 1 onwards, vaccination is open to all individuals (>18 years of age) in India to all general public. Perhaps, the real-life studies revel the major challenges among the general population.

Access this article online

www.ijss-sn.com

Month of Submission : 10-2021
Month of Peer Review : 11-2021
Month of Acceptance : 11-2021
Month of Publishing : 12-2021

Even though COVID-19 vaccines are effective and are being used to control/halt the spread of the pandemic, no vaccine is completely effective in preventing the illness. Even people who are fully vaccinated may get sick, and some may even be hospitalized or die as a result of COVID-19. Perhaps, evidences suggested that vaccination may lessen the severity of the illness, thus lower the risk of infection, hospitalization, and mortality in vaccinated individuals when compared to their counterparts. The vaccine breakthrough infection is defined as COVID

Corresponding Author: Dr. Balaji Vijayam, Diabetes Care and Research Institute, Chennai, Tamil Nadu, India.

infection in the collected specimen from the individual greater than 14 days after the completion of recommended dose of an authorized COVID-19 vaccine.[5]

The findings of the recent study[6] and a Phase 3 clinical trial[3,7,8] highlighted the robust vaccine efficiencies which are greater than 85% in preventing the severe COVID disease. Perhaps, the unusual emerging evidences show the breakthrough COVID-19 infections among fully vaccinated persons.[9] A recent study conducted among the health care workers report symptomatic breakthrough infections.[10] Similarly, another breakthrough infection study was reported recently.[11] Thus, the current study focused to determine the breakthrough of COVID-19 infection after vaccination among type 2 diabetes mellitus (T2DM) patients in a tertiary care hospital.

MATERIALS AND METHODS

The present retrospective, observational study was conducted among T2DM patients infected with COVID-19 after vaccination in a tertiary care hospital. In the present study, we carefully examined and reviewed the patients who were registered for the regular check-up for diabetes for COVID infection after vaccination between May 2021 and October 2021. The study subjects were recruited base on inclusion and exclusion criteria, T2DM patients with COVID-19 infection after 1st or 2nd dose of vaccination who were mentally oriented, persons of both the genders aged between 18 and 80 years and took treatment for COVID-19, and T2DM patients with or without pre-existing comorbid conditions were included in the study. Those individuals who were on alternative treatment for COVID-19 and other serious illness, pregnant women, and COVID-19 infection before COVID vaccination were excluded from the study. The specific vaccination details for COVID-19, along with vaccination date, 1st or 2nd dose, symptoms, onset of symptoms after vaccinations (in days), and severity of infection were recorded accordingly. Telephonic interview was conducted with the affected individuals to obtain the relevant data. The clinical and demographic characteristics such as age, gender, and pre-existing conditions such as dyslipidemia, cardiovascular disease, hypertension, and thyroid were recorded, respectively. Descriptive statistics were used.

RESULTS

A total of 10,805 patients stepped in to the hospital during the study period, fairly 3243 (30%) patients were vaccinated either partially or completely. Of 3243 patients who were vaccinated (partially or completely), 36 (1.11%) patients were reported to be infected with COVID after vaccination. Majority of the study participants were male (58.33%). The mean age of the study participants was 60.22 ± 8.56 years, and the age ranged between 40 and 75 years. In the present study, 38.88% of the individuals were under the age group of 60–70 years. Clinical data and demographic characteristics are summarized in Table 1.

The study participants were vaccinated with either Covaxin (n = 14) or CoviShield (n = 22). Of 36 patients, 12 (33.33%) have received partial vaccination (1st dose) and 24 (66.66%) received complete course of vaccination (2nd dose) at the time of COVID-19 infection. The symptomatic COVID-19 was observed in 97.22% of the study participants, whereas 2.7% (n = 1) of the patients did not experience any symptoms (admitted to hospital for a non-COVID-19-related diagnosis but with an incidental positive polymerase chain reaction test). COVID infection was observed in 12 individuals after the first dose (Covaxin n = 5; CoviShield n = 7), whereas 24 participants had tested positive after the second dose (Covaxin n = 9; CoviShield n = 15) of vaccine. The symptomatic COVID infection occurred in 13 (36.11%) individuals less than 14 days after the vaccination of which majority (n = 8) of the individuals completed 2st dose of vaccination. Likewise, 63.66% (n = 23) of the post-vaccinated individuals showed infection any time after 14 days (mean days 31.5 days) which includes both 1st (n = 7) and 2nd (n = 16) dose of vaccination. Thus, these 16 patients (5 Covaxin and 11 CoviShield) considered to have a breakthrough infection of COVID-19. Mild-to-moderate infection was observed in 25 (39.44%) patients and was home quarantined and 11 (30.5%) patients had severe to critical illness and required hospitalization.

The pre-existing comorbidities apart from diabetes such as cardiac problem (n = 8), hypertension (n = 26), dyslipidemia (n = 21), and thyroid (n =7) were observed in the study population. The common symptoms and signs during the onset of infection include fever, cough, breathlessness, sputum, body pain, and few have experienced loss of smell and taste. The symptoms lasted for about 4–10 days.

DISCUSSION

The breakthrough infection can be recognized as the variant of COVID which detour vaccine-induced immunity,[12] which is an area need to be explored in near future. In addition, special concern has to be given to the asymptomatic COVID-infected patients who might likely to spread the viral infection. New variants of COVID-19 pose a clinical concern. Two areas of concern relate to

Table 1: Demographic characteristics of Post Vaccinated and COVID 19 infected T2DM patients.

Variables				N (%) n= 36		
Age	40 - 50			8 (22.22%)		
	50 - 60			10 (27.77%)		
	60 - 70			14 (38.88%)		
	70 - 80			4 (11.11%)		
Gender	Male			21 (58.33%)		
	Female			15 (41.66%)		
Type of Vaccine	Covaxin			14 (38.88%)		
	Covishield			22 (61.11%)		
No of dose	1st	Covaxin		5 (41.66%)		12 (33.33%)
		Covishield		7 (58.33%)		
	2nd	Covaxin		9 (37.5%)		24 (66.66%)
		Covishield		15 (62.5%)		
COVID -19 incidence (no of days Post vaccination)	≤ 14 days	Covaxin	1st dose	2 (33.3%)	6 (46.15%)	13 (36.11%)
			2nd Dose	4 (66.66%)		
		Covishield	1st dose	3 (42.85%)	7 (53.15%)	
			2nd Dose	4 (57.14%)		
	≥ 14 days	Covaxin	1st dose	3 (37.5%)	8 (34.78%)	23 (63.66%)
			2nd Dose	5 (62.56%)		
		Covishield	1st dose	4 (26.6%)	15 (65.21%)	
			2nd Dose	11 (73.33%)		
Severity of COVID-19 infection	Home quarantine	Covaxin		10 (40%)		25 (69.44%)
		Covishield		15 (60%)		
	Hospitalization	Covaxin		4 (36.33%)		11 (30.5%)
		Covishield		7 (63.63%)		
Co morbid conditions	Hypertension			26 (72.22%)		
	Dyslipidemia			21 (25.33%)		
	Cardiac problem			8 (22.22%)		
	Thyroid			7 (19.44%)		
	Others (Heart, Liver, kidney problem/ wheezing/ migraine)			14(38.8%)		
Presence of Symptoms	Symptomatic			35 (97.22%)		
	Asymptomatic			1 (2.77%)		
Common symptoms & signs during onset of infection	Fever			30 (93.75%)		
	Cough			29 (90.62%)		
	Breathlessness			25 (78.12%)		
	Sputum			26 (81.25%)		
	Body pain			28 (87.5%)		

the ability of variants to evade vaccine-induced immunity and cause asymptomatic infection (and thereby promote viral spread) or illness. Both consequences are important, both need to be considered independently, and both are largely unknown. Recent statement from Indian Council of Medical Research (ICMR) states that 2–4/10,000 got infected with COVID-19 after vaccinations in India.[13] Further a recent ICMR study also highlighted that the breakthrough cases were infected with the variants and only 9.8% of the infected individuals required hospitalization[14] and 0.4% fatality, thus vaccination reduces hospitalization. In a recent study conducted among the skilled nurses, 22 were infected with COVID-19 after receiving their vaccination. Further, the infection was detected any time after 14 days of second dose of vaccine and two-third of the breakthrough infection were asymptomatic.[15] Further reports highlight the mild or asymptomatic[10] and symptomatic breakthrough infection among the health care.[16] Another study highlighted that more than a quarter of completely vaccinated individuals were hospitalized due to COVID-19 infection and some were severely or critically ill.[11] A study conducted by Jain *et al.*,[17] discussed various

causes for COVID-19 infection and mortality following COVID-19 vaccination.

Thus, the critical aspect of pandemic management is preventing vaccine failures due to variants. It is important to be aware of the mechanisms by which variants may escape vaccine-induced immunity and cause asymptomatic infection (which can lead to viral spreading) or illness, which has to be focused independently. In the meantime, the public health measures such as mandatory wearing of mask and hand wash techniques remain essential to control outbreaks.

Although the incidence of COVID-19 illness remains low in completely vaccinated patients, we observed that a number of patients were also experienced severe illness and were hospitalized due to COVID-19, this might be due to other factors such as emerging variants of COVID, individual's immune response against the vaccine, decreased effectiveness of vaccine, pre-existing comorbid conditions, and the use of immune suppressants. Although the vaccines are extremely effective against the COVID-19 infection, there exists a rare breakthrough infection which carries an infectious potential and poses a greater challenge in the vulnerable population.

The sample size is the major limitation of the present study, even though we have extensive documentation details of vaccinated individuals, the number of reported cases was relatively less. The comorbid conditions which also determined the severity of the COVID infection should also be considered with larger study population.[18] The current study does not focused on the immunological aspects such as COVID specific T-cell responses. Further asymptomatic individuals would create a greater impact on the study finding. Hence, the findings do not allow to derive the conclusion. Despite these limitations, the current study findings provide data on COVID-19 infection after vaccination among Indian population.

CONCLUSION

The prevalence of breakthrough infection in individuals completed the full dose of vaccination, would be the prime research area in the near future. In nutshell, even though the vaccination provides a widespread protection against COVID infection globally, further research is required in this line to detect the alleviating factor associated with the inadequate vaccine response in individuals with breakthrough infection.

REFERENCES

1. Polack FP, Thomas SJ, Kitchin N, Absalon J, Gurtman A, Lockhart S, *et al*. Safety and efficacy of the BNT162b2 mRNA Covid-19 vaccine. N Engl J Med 2020;383:2603-15.
2. Baden LR, El Sahly HM, Essink B, Kotloff K, Frey S, Novak R, *et al*. Efficacy and safety of the mRNA-1273 SARS-CoV-2 vaccine. N Engl J Med 2021;384:403-16.
3. Sadoff J, Gray G, Vandebosch A, Cárdenas V, Shukarev G, Grinsztejn B, *et al*. Safety and efficacy of single-dose Ad26.COV2.S vaccine against Covid-19. N Engl J Med 2021;384:2187-201.
4. Voysey M, Clemens SA, Madhi SA, Weckx LY, Folegatti PM, Aley PK, *et al*. Safety and efficacy of the ChAdOx1 nCoV-19 vaccine (AZD1222) against SARS-CoV-2: An interim analysis of four randomised controlled trials in Brazil, South Africa, and the UK. Lancet 2021;397:99-111.
5. Available from: https://www.cdc.gov/vaccines/covid-19/health-departments/breakthrough-cases.html [Last accessed on 2021 Nov 20].
6. Shrotri M, Krutikov M, Palmer T, Giddings R, Azmi B, Subbarao S, *et al*. Vaccine effectiveness of the first dose of ChAdOx1 nCoV-19 and BNT162b2 against SARS-CoV-2 infection in residents of long-term care facilities in England (VIVALDI): A prospective cohort study. Lancet Infect Dis 2021;2021:21254391.
7. Dagan N, Barda N, Kepten E, Miron O, Perchik S, Katz MA, *et al*. BNT162b2 mRNA COVID-19 vaccine in a nationwide mass vaccination setting. N Engl J Med 2021;384:1412-23.
8. Sadoff J, Le Gars M, Shukarev G, Heerwegh D, Truyers C, de Groot AM, *et al*. Interim results of a phase 1-2a trial of Ad26.COV2.S COVID-19 vaccine. N Engl J Med 2021;384:1824-35.
9. Keehner J, Horton LE, Pfeffer MA, Longhurst CA, Schooley RT, Currier JS, *et al*. SARS-CoV-2 infection after vaccination in health care workers in California. N Engl J Med 2021;384:1774-5.
10. Tyagi K, Ghosh A, Nair D, Dutta K, Bhandari PS, Ansari IA, *et al*. Breakthrough COVID19 infections after vaccinations in healthcare and other workers in a chronic care medical facility in New Delhi, India. Diabetes Metab Syndr Clin Res Rev 2021;15:1007-8.
11. Juthani PV, Gupta A, Borges KA, Price CC, Lee AI, Won CH, *et al*. Hospitalisation among vaccine breakthrough COVID-19 infections. Lancet Infect Dis 2021;21:1485-6.
12. Hacisuleyman E, Hale C, Saito Y, Blachere NE, Bergh M, Conlon EG, *et al*. Vaccine breakthrough infections with SARS-CoV-2 variants. N Engl J Med 2021;384:2212-8.
13. Available from: https://economictimes.indiatimes.com/news/india/only-2-4-per-10000-gotinfected-after-vaccination-not-worrisome-balram-bhargava-dg-icmr/videoshow/82181979.cms [Last accessed on 2021 Nov 20].
14. Gupta N, Kaur H, Yadav PD, Mukhopadhyay L, Sahay RR, Kumar A, *et al*. Clinical characterization and genomic analysis of samples from COVID-19 breakthrough infections during the second wave among the various states of India. Viruses 2021;13:1782.
15. Teran RA, Walblay KA, Shane EL, Xydis S, Gretsch S, Gagner A, *et al*. Postvaccination SARS-CoV-2 infections among skilled nursing facility residents and staff members Chicago, Illinois, December 2020-March 2021. MMWR Morb Mortal Wkly Rep 2021;70:632-8.
16. Bergwerk M, Gonen T, Lustig Y, Amit S, Lipsitch M, Cohen C, *et al*. Covid-19 breakthrough infections in vaccinated health care workers. N Engl J Med 2021;385:1629-30.
17. Jain VK, Iyengar KP, Ish P. Elucidating causes of COVID-19 infection and related deaths after vaccination. Diabetes Metab Syndr 2021;15: 102212.
18. Pal R, Bhadada SK, Misra A. COVID-19 vaccination in patients with diabetes mellitus: Current concepts, uncertainties and challenges. Diabetes Metab Syndr 2021;15:505-8.

How to cite this article: Vijayam B, Balaji T, Balaji MS, Veerasamy S, Rani AA. Breakthrough Coronavirus Disease Infection after Vaccination among Type 2 Diabetes Mellitus Patients in a Tertiary Care Hospital in India. Int J Sci Stud 2021;9(9):87-90.

Source of Support: Nil, **Conflicts of Interest:** None declared.

Print ISSN: 2321-6379
Online ISSN: 2321-595X

Original Article

Comparative Evaluation of Pre-operative Thickness of Keratinized Soft Tissue with the Changes in the Level of Hard Tissue in Relation to Implant Platform within 6 Months after the Implant Placement

Shashwat Ram Thombare[1], Amit Chaudhari[2], Amita Mali[3], Vishakha Patil[4], Neelam Gavali[5], Shweta Bhole[1]

3rd Year Post Graduate Student, Department of Periodontology, Bharati Vidyapeeth Deemed to be University Dental College and Hospital, Pune, Maharashtra, India, [2]Associate Professor, Department of Periodontology, Bharati Vidyapeeth Deemed to be University Dental College and Hospital, Pune, Maharashtra, India, [3]Head, Department of Periodontology, Bharati Vidyapeeth Deemed to be University Dental College and Hospital, Pune, Maharashtra, India, [4]Professor, Department of Periodontology, Bharati Vidyapeeth Deemed to be University Dental College and Hospital, Pune, Maharashtra, India, [5]Assistant Professor, Department of Periodontology, Bharati Vidyapeeth Deemed to be University Dental College and Hospital, Pune, Maharashtra, India

Abstract

Context: The primary goal of the implant placement is maintenance of stable connection between the bone and the implant. There is controversy in literature whether thickness of soft tissue around dental implants has any role in stabilization of the hard tissue around implant.

Aims: The study aims to evaluate and compare pre-operative thickness of keratinized soft tissue with the changes in the level of hard tissue in relation to implant platform within 6 months after the implant placement.

Materials and Methods: About 15 patients were selected with missing single tooth. Transgingival probing was done to evaluate pre-operative thickness of keratinized soft tissue. Using cone beam computed tomography (CBCT) implant was planned and placed. CBCT was taken immediately after implant placement and hard tissue levels around implant were measured. After 6 months, thickness of keratinized soft tissue was measured on implanted tooth and CBCT was taken to measure the hard tissue levels around implant.

Statistical Analysis Used: IBM Statistical Package for the Social Sciences statistical software 20.0 was used for the analysis.

Results: Significant reduction in the keratinized soft tissue thickness and highly significant reduction in level of hard tissue 6 months postoperatively. No significant correlation was found between pre-operative thicknesses of keratinized soft tissue with changes in level of hard tissue in relation to implant platform 6 months after implant placement.

Conclusions: There was reduction in level of keratinized soft tissue and in level of hard tissue around implant within 6 months after placement of the implant. However, there was no correlation found between soft and hard tissue changes.

Key words: Cone beam computed tomography, Dental implants, Hard tissue levels, Soft tissue thickness, Transgingival probing

INTRODUCTION

Primary goal of implant installation is osseointegration.[1] It has been suggested that good amount of keratinized soft tissue is the pre-requisite for stable hard tissue around implant. One among all influencing factors for initial crestal bone loss is the biotype of soft tissue. To cover the interdental bone, soft tissue surgery can be done. Although, there is still controversy in literature if soft tissue augmentation around implants is needed to be performed to obtain added band of keratinized tissue. Few studies have attempted to evaluate direct co-relation of thickness of keratinized soft tissue with crestal bone loss, so the aim is to evaluate changes and co-relation in thickness of keratinized soft tissue and hard tissue following implant placement during the initial healing period of 6 months.

Access this article online

www.ijss-sn.com

Month of Submission : 10-2021
Month of Peer Review : 11-2021
Month of Acceptance : 11-2021
Month of Publishing : 12-2021

Corresponding Author: Dr. Shashwat Ram Thombare, 07, Nisarg Nagari, Priyadarshini College Road, Nalwadi, Wardha - 442001, Maharashtra, India.

MATERIALS AND METHODS

All the individuals visiting outpatient department (OPD) of Periodontology department were subjected to clinical examination by following all the personal protective protocol. Subjects volunteering in this study were checked for all the criterion.

The inclusion criterion are presence of healed bone sites (at least 4 months after tooth extraction), no bone augmentation procedures before or during implant placement, Subjects with healthy periodontal status, Age group: 20–40 years, Subjects with minimum alveolar bone height of 11 mm above inferior alveolar canal as estimated by cone beam computed tomography (CBCT), Subjects with minimum crestal bone width of 5.5 mm as estimated by CBCT, Subjects with 5 mm of minimum interocclusal space were considered, Subjects with mesio distal edentulous space >6.5 mm were considered. The exclusion criterion were subjects with history of systemic diseases, Subjects with oral habit of smoking and smokeless tobacco, Subjects with periodontal diseases, Subjects who had undergone surgical intervention 6 months before the start of study, subjects who are on systemic or topical medication or had taken medications in the past 6 months, poorly motivated or subject unable to come for follow-up, Irradiation in implant area, subjects with poor oral hygiene maintenance.

A total of 15 subjects were selected from the OPD in Postgraduate clinic of Department of Periodontology. Written informed consent was provided for participation and permission was taken to use data for research. Placement of implant was planned after the clinical and CBCT evaluation. Proper measurements were taken from the CBCT for evaluation of placement of the implant in given space. Bone quantity was measured to ensure that an implant at least 9 mm in length could be placed without bone augmentation. Transgingival probing was done to measure the pre-operative thickness of keratinized soft tissue on the mid-buccal region of edentulous area. Measurements were carried out with calibrated University of North Carolina (UNC) 15 periodontal probe. After local anesthesia was secured, the thickness of keratinized soft tissue was calculated with the help of periodontal probe (UNC-15) in millimetres till osseous tissue was felt. The tooth adjacent to the operative site was used as a reference point to measure the buccal keratinized soft tissue thickness. The point 3 mm apical to the gingival margin of the adjacent tooth was marked. From this point, a reference line to the midbuccal side of the operative site was marked using a second probe. UNC-15 probe was then used to measure the keratinized soft tissue thickness on mid- buccal side of the operative site and was advanced until osseous tissue was felt. This was considered the pre-operative thickness of keratinized soft tissue. After the transgingival probing was done and once the bone volume was assessed and the implant surgical option was identified, the implant procedure was commenced. CBCT of the specific region was taken after the implant was placed immediately and measurements were taken. After 3 months, the hard and soft tissues were adequately healed and the prosthetic restoration was commenced. Thickness of keratinized soft tissue was again measured 6 months after implant placement on the mid-buccal side of the implanted tooth. Same reference point was used to measure the mid-buccal keratinized soft tissue thickness after 6 months of implant placement. This was considered the post-operative measurement of thickness of mid-buccal keratinized soft tissue. Both measurements were later used for comparison. CBCT measurements were also calculated immediately after implant placement and after 6 months to check any changes in surrounding bone of the implant. The pre- and post-operative measurements of the levels of hard tissue were used for comparison.

Statistical Analysis

Student *t*-tests (two tailed, paired) and Spearman's rank Correlation coefficient along with the statistical software was used for the analysis. $P = 0.05$ was set as level of significance and value less or equal to this was said to be statistically significant.

RESULTS

About 15 individuals with age group ranging from 20 to 40 years were included in this study. Table 1 and Graph 1

Table 1: Comparison of the soft tissue thicker at baseline and 6 months after implant placement

Soft tissue thickness	*n*	Mean	Std. Deviation	*t*-value	*P*-value
At baseline	15	1.60	0.507	3.055	0.009*
6 months after implant	15	1.20	0.414		

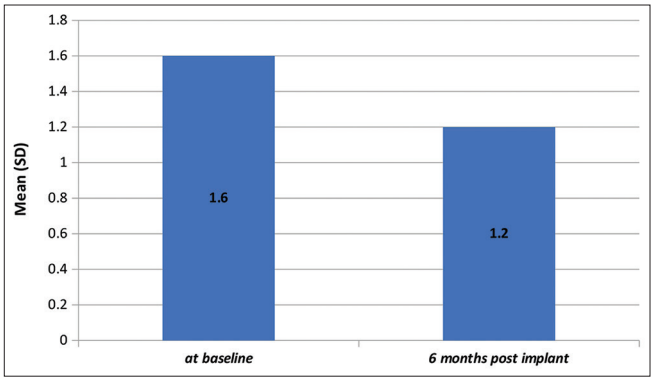

Graph 1: Comparison of the keratinised soft tissue thickness at baseline and 6 months after implant placement

represent the mean value at baseline of soft tissue thickness before implant placement was 1.60 ± 0.507 and the mean value after 6 months of implant placement was 1.20 ± 0.414. After applying student paired *t*-test, the *t*-value obtained was 3.055. Thus, statistically there was significant reduction in the soft tissue thickness ($P = 0.009$).

Table 2 and Graph 2 represent the mesial, distal, buccal and lingual sites:

Mesial Site

The mean value of the hard tissue levels immediately after implant placement was –0.1393 ± 1.06014 from the implant platform and the mean value of the hard tissue thickness after 6 months of implant placement was 0.7720 ± 0.93843 from the implant platform. The value of Student paired *t*-test for this comparison was 2.696. Thus, there was statistically significant reduction in the bone level ($P = 0.003$).

Distal Site

The mean value of the hard tissue levels immediately after implant placement was 0.4047 ± 1.69374 from the implant platform and the mean value of the hard tissue thickness after 6 months of implant placement was 1.0867 ± 0.75355 from the implant platform. The value of Student paired *t*-test for this comparison was 2.402. Thus, there was statistically significant reduction in the bone level ($P = 0.016$).

Lingual Site

The mean value of the hard tissue levels immediately after implant placement was 0.8940 ± 1.00782 from the implant platform and the mean value of the hard tissue thickness after 6 months of implant placement was 1.0400 ± 1.15931 from the implant platform. The value of student paired *t*-test for this comparison was 1.387. Thus, there was statistically no significant reduction in the bone level ($P = 0.165$).

Buccal Site

The mean value of the hard tissue levels immediately after implant placement was 0.5980 ± 0.73742 from the implant platform and the mean value of the hard tissue thickness after 6 months of implant placement was

Table 2: comparison of the hard tissue levels immediately and 6 months after implant placement At different sites

Hard tissue level	Time intervals	*n*	Mean	Std. Deviation	Z-value	*P*-value
Mesial	Immediately after implant placement	15	-0.1393	1.06014	2.696	0.003*
	6 months post implant	15	0.7720	0.93843		
Distal	Immediately after implant placement	15	0.4047	1.69374	2.402	0.016*
	6 months post implant	15	1.0867	0.75355		
Palatal	Immediately after implant placement	15	0.8940	1.00782	1.387	0.165
	6 months post implant	15	1.0400	1.15931		
Buccal	Immediately after implant placement	15	0.5980	0.73742	2.428	0.015*
	6 months post implant	15	0.9073	1.03865		

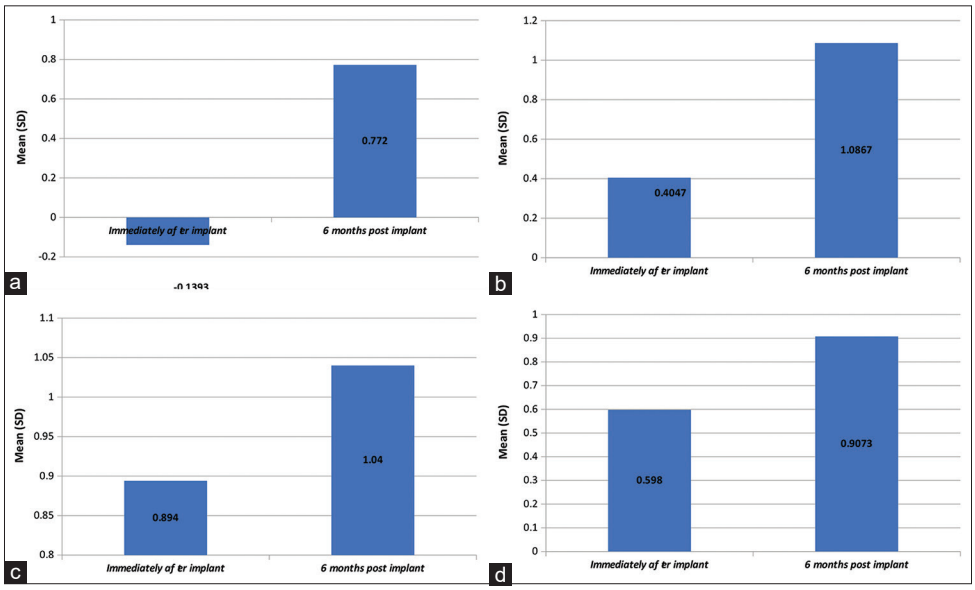

Graph 2: Comparison of the hard tissue levels immediately and 6 months after implant placement at different sites. (a) Mesial, (b) Distal, (c) Palatal, (d) Buccal

0.9073 ± 1.03865 from the implant platform. The value of Student paired t-test for this comparison was 2.428. Thus, there was statistically significant reduction in the bone level ($P = 0.015$).

Table 3 and Graph 3 represents the mean value of the hard tissue levels immediately after implant placement was 0.4393 ± 0.98877 from the implant platform and the mean value of hard tissue thickness after 6 months of implant placement was 0.9515 ± 0.94389 from the implant platform. The value of Student paired *t*-test for this comparison was 3.431. Thus, there was statistically highly significant reduction in the bone level ($P < 0.001$).

Table 4 and Graph 4 represent the mean value of the Spearman's rank coefficient correlation of difference between thickness of soft tissue and levels of hard tissue with respect to implant platform was 0.260. Thus, there was no statistically significant correlation between the two ($P = 0.349$).

Table 3: Comparison of the hard tissue levels immediately and 6 months after implant placement

Hard tissue level (Total)	*n*	Mean	Std. Deviation	Z-value	*P*-value
Immediately after implant placement	15	0.4393	0.98877	3.431	<0.001**
6 months post implant	15	0.9515	0.94389		

Table 4: Correlation of the soft tissue thickness changes (at baseline-6 months after implant placement) with the hard tissue levels (immediately after implants- 6 months after implant placement)

Correlation between soft tissue thickness and hard tissue levels	Soft tissue thickness	
	Spearman's rho (correlation coefficient)	*P*-value
Hard tissue level	0.260	0.349

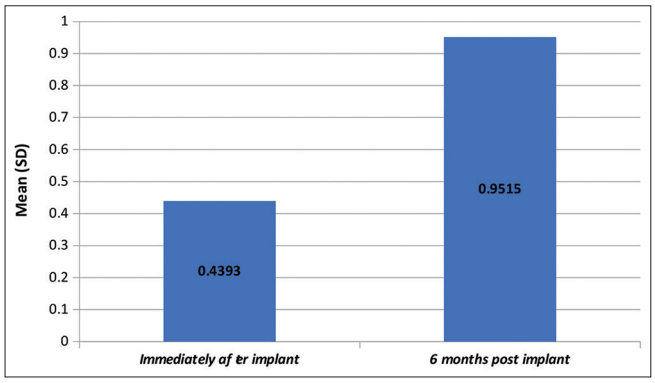

Graph 3: Comparison of the hard tissue levels immediately and 6 months after implant placement

DISCUSSION

The observations of the present study showed statistically significant reduction in the keratinized soft tissue thickness 6 months after implant placement when compared to the pre-operative thickness of the keratinized soft tissue. Similar results were shown by Cardaropoli *et al.* in 2006 they demonstrated that after implant surgery remodelling occurs, they observed that esthetics can be affected by alterations in soft tissue after crown placement.[2] Berglundh and Lindhe in 1996 they found that although the tissue thickness at abutment connection was significantly different, the combined dimensions of the junctional epithelium and the supra-alveolar connective tissue (i.e., biologic width) around the implants at test and control sites were similar 6 months later. They suggested that the soft tissue attachments (biologic width), once established, were natural mechanism for protecting the osseointegration zone from the bacterial and mechanical factors of the oral cavity. This study proves the clinical rationale for soft tissue augmentation before abutment attachment or nonsubmerged implant placement when there in presence of thin mucosal tissues.[3] Nabil *et al.* in 2015 concluded that the interproximal reduction protocol resulted in acceptable soft tissue and esthetic outcomes.[4]

Observation for hard tissue levels showed highly significant reduction in the level of hard tissue 6 months after the implant placement when compared to the pre-operative level of the hard tissue in relation to prosthetic platform. Similar results were shown by Hermann *et al.* in 2000 in a comparison examined histometrically bone dimensional changes crestally around submerged and non-submerged

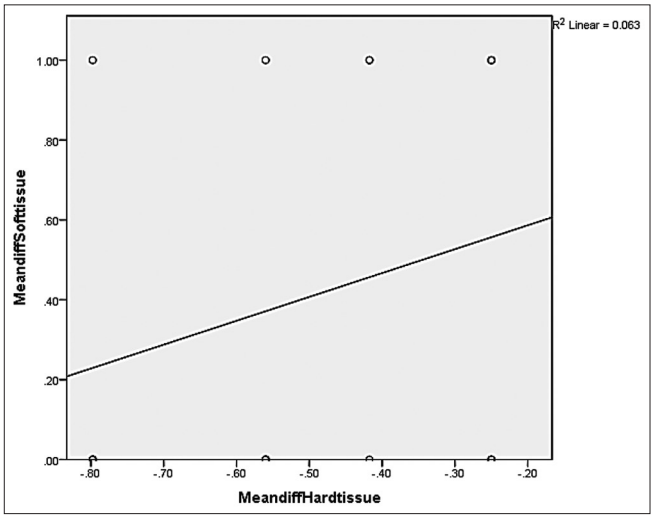

Graph 4: Correlation of the soft tissue thickness changes (at baseline-6 months after implant placement) with the hard tissue levels (immediately after implants- 6 months after implant placement)

implants. Histologically in unloaded conditions, they showed that in early phase of healing bone changes occurs crestally after placement of implants.[5] Uppala *et al.* in 2020 compared bone loss crestally around the implants that were placed with platelet concentrates and beta-tricalcium phosphate bone grafts and they concluded that after 9 months of placement of implants average crestal bone loss in both groups was 2.75 mm and 2.23 mm which was statistically significant.[6]

Another observation showed that there was no significant correlation found between keratinized thicknesses of soft tissue pre-operatively with changes in hard tissue levels in relation to implant platform at 6 months after implant placement. Similar results were shown by Savita *et al.* in 2016 they assessed and compared gingival thickness in maxillary anterior region using paralleling technique with the help of two techniques that is CBCT and the radiovisiography and correlated them with the underlying thickness of the alveolar bone. This study failed to prove that there is significant correlation in gingival width and underlying bone in anterior maxilla. They concluded that within the limitations of the study, both the radiology techniques are important equipments for assessing the dimensions of soft and hard tissues.[7] Himanshu and Saso in 2017 in maxillary anterior region evaluated the correlation between pre-operative cortical bone thickness (buccal) and peri-implant tissue response followed by immediate implant placement. They concluded that no significant correlation was found between both.[8]

From above observation, it can be said that although there is reduction in the thickness of soft tissue and also reduction in the hard tissue level; there is no statistical correlation between the two. There are many other factors which influence the hard tissue levels after implant placement that is available bone around implant, status of oral hygiene, elevation of the periosteum while performing surgery, osteonecrosis caused due to instrument overheating, trauma from occlusion due to prosthesis, bone remodelling process, events in the inflammatory and healing process.

Future studies in this regard should be planned with larger sample size and above mentioned factors also should be given a consideration in the study design.

CONCLUSIONS

After 6 months of implant placement, there was reduction seen in the level of the keratinized soft tissue and in the level of the hard tissue around the implant. Furthermore, no co-relation was seen between the pre-operative levels of keratinized soft tissue with the levels of the hard tissue in relation to the implant platform.

ACKNOWLEDGMENT

We thank all the participants who were a part of present study and sincerely acknowledge their efforts in complying with the requirements of the study.

REFERENCES

1. Kan JY, Rungcharassaeng K, Umezu K, Kois JC. Dimensions of peri-implant mucosa: An evaluation of maxillary anterior single implants in humans. J Periodontol 2003;74:557-62.
2. Cardaropoli G, Lekholm U, Wennstrom JL. Tissue alterations at implant-supported single-tooth replacements: A 1-year prospective clinical study. Clin Oral Implants Res 2006;17:165-71.
3. Berglundh T, Lindhe J. Dimension of the periimplant mucosa. Biological width revisited. J Clin Periodontol 1996;23:971-3.
4. Nabil K, Himanshu A, Paul K. Systematic review of soft tissue alterations and esthetic outcomes following immediate implant placement and restoration of single implants in the anterior maxilla. J Periodontol 2015;86:1321-30.
5. Hermann JS, Buser D, Schenk RK, Cochran DL. Crestal bone changes around titanium implants. A histometric evaluation of unloaded non-submerged and submerged implants in the canine mandible. J Periodontol 2000;71:1412-24.
6. Uppala S, Parihar AS, Modipalle V, Manual L, Oommen VM, Karadiguddi P, *et al*. Crestal bone loss around dental implants after implantation of tricalcium phosphate and platelet-rich plasma: A comparative study. J Family Med Prim Care 2020;9:229-34.
7. Savita M, Harsha MB, Sreedevi D, Abhilash N, Charu D, Sachin VS. Comparative evaluation of soft and hard tissue dimensions in the anterior maxilla using radiovisiography and cone beam computed tomography: A pilot study. J Indian Soc Periodontol 2016;20:174-7.
8. Himanshu A, Saso I. Correlation between pre-operative buccal bone thickness and soft tissue changes around immediately placed and restored implants in the maxillary anterior region: A 2-year prospective study. Clin Oral Implants Res 2017;28:1188-94.

How to cite this article: Thombare SR, Chaudhari A, Mali A, Patil V, Gavali N, Bhole S. Comparative Evaluation of Pre-operative Thickness of Keratinized Soft Tissue with the Changes in the Level of Hard Tissue in Relation to Implant Platform within 6 Months after the Implant Placement. Int J Sci Stud 2021;9(9):91-95.

Source of Support: Nil, **Conflicts of Interest:** None declared.

Print ISSN: 2321-6379
Online ISSN: 2321-595X

Original Article

Comparative Evaluation of Three Pre-cleaning Protocols in the Elimination of Biologic Debris on Rotary Nickel Titanium Endodontic Instruments Prior to Sterilization

Sushmita Deshpande[1], Aniket Jadhav[2], Hrishita Mujumdar[3]

[1]3rd Year Post Graduate Student, Department of Conservative Dentistry and Endodontics, Bharathi Vidyapeeth Dental College and Hospital, Pune, Maharashtra, India, [2]Associate Professor, Department of Conservative Dentistry and Endodontics, Bharathi Vidyapeeth Dental College and Hospital, Pune, Maharashtra, India, [3]2nd Year Post Graduate Student, Department of Conservative Dentistry and Endodontics, Bharathi Vidyapeeth Dental College and Hospital, Pune, Maharashtra, India

Abstract

Introduction: In endodontics, re-use of sterilized instruments is a common practice. The presence of biologic debris reduces the efficacy of sterilization by autoclaving. Thus, pre-cleaning of re-usable endodontic instruments before sterilization is essential.

Aim: Comparative evaluation of three pre-cleaning protocols in the elimination of biologic debris on rotary nickel-titanium endodontic instruments before sterilization.

Materials and Methods: Thirty used rotary S1 Protaper Universal files were randomly divided into three groups for pre-cleaning before sterilization. Group A: 2% sodium hypochlorite + manual brushing, Group B: Ultrasonic bath + Distilled water, Group C: Ultrasonic bath + BIB forte, and Group D: Control group where no pre-cleaning protocol was followed. Following pre-cleaning of endodontic instruments, they were immersed in Rhodamine B dye for 24 h and were mounted on a square block. All the instruments were examined for the presence of residual biologic debris under a stereomicroscope at 30× magnification.

Statistical Analysis: Analysis of variance and *post-hoc* Tuckey's test. The level of significance was fixed at $P = 0.05$, and any value ≤0.05 was statistically significant.

Results: There was a statistically significant difference in the mean value of residual biologic debris between all the groups except Group A and Group D. The mean value of Group C was the lowest.

Conclusion: The combined use of ultrasonic energy and a special enzyme BIB Forte removed the biologic debris to the maximum level.

Key words: BIB forte, Biologic debris, Infection control, Pre-cleaning, Stereomicroscope, Ultrasonic cleaning

INTRODUCTION

Infection control is an important part of every health care unit. With the increasing knowledge of various infectious diseases, the awareness regarding various protocols to achieve optimum infection control is also rising. Dentistry is one of the fields where the operator, the supporting staff and also the patients are exposed to many infectious agents, so proper infection control is paramount.[1,2]

Access this article online

www.ijss-sn.com

Month of Submission : 10-2021
Month of Peer Review : 11-2021
Month of Acceptance : 11-2021
Month of Publishing : 12-2021

Root canal treatment is routinely performed in every dental clinic. The basic goal of endodontic treatment is the complete removal of all pathogenic debris from the infected root canal. This is achieved with the help of various endodontic instruments and irrigation. In this process, the complex structure of endodontic instruments is accumulated with debris consisting of blood, necrotic tissue, dentinal chips, and numerous infection-causing

Corresponding Author: Dr. Sushmita Deshpande, Department of Conservative Dentistry and Endodontics, Bharathi Vidyapeeth Dental College and Hospital, Pune, Maharashtra, India.

microbes. Thus, if the same endodontic instrument is used in other individuals, there is a definite risk of cross-infection.[2] Hence, it is recommended to use the instrument only once (single use) to achieve appropriate infection control. However, the cost of the instrument being a significant factor, re-use of the instrument is very common, indicating the importance of cleaning the instruments before use and re-use.[3]

Sterilization by autoclaving is the key to achieve optimum infection control. The presence of debris on the surface of the instrument hampers the efficacy of sterilization.[4,5] Thus, pre-cleaning of endodontic instruments before subjecting them to autoclaving is important. At present, used methods for pre-cleaning include manual cleaning with brush, sponge, or gauze. Chemicals such as sodium hypochlorite, chlorhexidine, glutaraldehyde, glass bead sterilizer, and enzymatic cleaners are routinely used. These conventional methods are either cumbersome to perform or do not render the instrument completely free of debris.[6-9] Literature has documented the use of ultrasonic energy as a pre–cleaning method before sterilization. Ultrasonic bath releases acoustic energy and cavitation responsible for the removal of debris from the complex structure of the endodontic file.[6] Considering the limitations of traditional methods and acknowledging the recent devices introduced for pre-cleaning, the vision of the present study was to introduce a pre-cleaning protocol before sterilization which is easy to perform and simultaneously causes near-total cleaning of endodontic instruments.

The aim of the study was to assess the efficacy of ultrasonic bath alone and ultrasonic bath combined with an enzyme BIB Forte in the elimination of biologic debris on rotary nickel- titanium endodontic instruments before sterilization.

MATERIALS AND METHODS

Forty clinically used rotary S1 Protaper Universal files (Dentsply Maillefer, Switzerland) were collected in the following manner. The study was approved by the Institutional Ethical Committee. Participants scheduled for root canal treatment of the mandibular molar having three root canals and vital tooth were selected. Written informed consent was taken from the participants and confidentiality regarding the same was maintained.

Routine endodontic treatment was initiated. Vitality of the tooth was ensured by fresh bleeding from the canals after access opening, failure of which led to exclusion of the participant. Following access cavity preparation and working length determination the glide path was established using the No. 10, 15, and 20 k-file (MANI Inc., Japan) Biomechanical preparation was completed with rotary Protaper Universal files (Dentsply Maillefer, Switzerland) up to F2 sequence installed in an Endomotor (Endo-mate TC2, NSK, Japan) with a speed of 300 rpm and 3 N/m torque. The rotary Protaper Universal files (Dentsply Maillefer, Switzerland) were used in brushing motion with a 3 mm amplitude limit along with gentle apical and lateral pressure. Chemical irrigation was performed with 25 mL of 2.5% NaOCl using a 30 gauge needle inserted up to 1 mm short of working length. 3 mL of 17% EDTA (Prime Dental Products Pvt. Ltd., India) was used for smear layer removal followed by a final rinse with saline. During the biomechanical preparation, all the endodontic instruments were kept on the endodontic stand. Root canal treatment was completed of every participant with F2 Gutta-percha cones (Dentsply Sirona, USA) and AH-Plus sealer (Dentsply, DeTrey, and Konstanz, Germany). Broken, deformed rotary S1 Protaper Universal files were excluded from the study.

Thirty clinically used rotary S1 Protaper Universal files were randomly divided into three groups depending on the pre-cleaning protocol before sterilization and remaining 10 served as a control group.

In Group A, 10 rotary S1 Protaper Universal files (Dentsply Maillefer, Switzerland) were immersed in commercially available 2% sodium hypochlorite (Prime Dental Products Pvt. Ltd., India) for 10 min followed by manual cleaning with 20 strokes of nylon brush (Prime Dental Products Pvt. Ltd., India).

In Group B, 10 rotary S1 Protaper Universal files (Dentsply Maillefer, Switzerland) were immersed in ultrasonic bath (CD-4820 Pvt. Ltd., India) containing distilled water for 15 min. The ultrasonic baths worked at a temperature of 65°C at a power of 160 W.

In Group C, 10 rotary S1 Protaper files (Dentsply Maillefer, Switzerland) were immersed in an ultrasonic bath (CD -4820 Pvt. Ltd., India) containing an enzymatic solution BIB forte (Prime Dental Products Pvt. Ltd. India) for 15 min. 50 ml of commercially available BIB forte was diluted in 950 ml of potable water and was introduced in an ultrasonic bath. The ultrasonic bath worked at temperature of 65°C at a power of 160 W.

In Group D, 10 rotary S1 Protaper Universal files (Dentsply Maillefer, Switzerland) served as a control group. Clinically used S1 Protaper files (DENSTPLY) were not subjected to any pre-cleaning protocol.

After cleaning of instruments in each group, the rotary S1 Protaper Universal files (Dentsply Maillefer, Switzerland)

were kept in covered Petri-dish to minimize exposure to any other contamination. Following this, rotary S1 Protaper Universal files (Dentsply Maillefer, Switzerland) were immersed in Rhodamine B dye (Prime Dental Products Pvt. Ltd., India) for 24 h.

A special holder made of rubber with a square shape was prepared [Figure 1]. The rubber holder had an opening in the center to facilitate easy placement of the rotary S1 Protaper Universal files. The sides of the holder were marked as 1, 2, 3, and 4 corresponding to all four sides of the rotary S1 Protaper Universal file. The holder provided a stable platform and proper positioning of rotary S1 Protaper Universal file under stereomicroscope during the examination of residual biologic debris.

All the rotary S1 Protaper Universal files were examined for the presence of residual biologic debris under a stereomicroscope (SZTP; Olympus Optical Co., Tokyo, Japan) at 30× magnification. The files were divided longitudinally into three sections of equal length with a ruler i.e. coronal, middle, and apical third. All four sides of the rotary S1 Protaper Universal files were examined by sequential rotation through 90°. Digital images of rotary S1 Protaper Universal files were captured with a camera (Nikon Coolpix 950, Nikon, Japan) attached to the stereomicroscope (30× magnifications). Figure 2 is the stereomicroscopic picture of residual biologic debris

Figure 1: File mounted on the rubber block



Figure 2: Rotary S1 protaper universal files evaluated for presence of residual biologic debris under stereomicroscope

present on the rotary S1 Protaper Universal file following pre-cleaning. The residual biologic debris on every section was scored as follows:

Score 1- organic film (file covered with a thin unstructured layer), Score 2- slight staining (single separated particles of debris seen scattered over the surface of the file), Score 3- moderate staining (particles of debris seen as a continuous layer over the surface of the file), Score 4- high level of staining (flutes of the file thoroughly covered with debris all over). This criteria of debris classification is same as given by Ziauddin *et al.*[9] Twelve measurements for each instrument were obtained. The minimum value obtained was zero (clean surface with no organic material present) and the maximum was 48 (surfaces of the files were wholly contaminated with debris). All the measurements were added up and the mean value of residual biologic debris was calculated and subjected to statistical analysis.

Statistical Analysis

Analysis of variance and *post-hoc* Tukey's tests were performed using Statistical Package for Social Science (SPSS, version 20.0, USA). The Level of significance was fixed at $P = 0.05$, and any value ≤ 0.05 was considered to be statistically significant.

RESULTS

There was a statistically significant difference in the mean value of residual biologic debris between the pre-cleaning protocols applied in respective groups. The mean value of residual biologic debris for Group A-NaOCl + manual brushing (mean = 2.390) was higher than Group B and C denoting statistically significant difference between Group A, B, and C. $P = 0.05$. However, the mean value of residual biologic debris of Group A was not statistically significant with Group D: control (mean = 2.6420) [Tables 1 and 2].

The mean value of residual biologic debris for Group B- ultrasonic energy (mean = 1.3990) was lower than Group A and D but higher than Group C- ultrasonic energy with BIB Forte (mean = 0.350). There was statistically significant difference between Group B and other groups. $P = 0.05$ [Tables 1 and 2] Lowest mean was obtained in Group C- ultrasonic energy with BIB Forte (mean = 0.350) which was statistically lower than other groups [Tables 1 and 2]. $P = 0.05$ Thus, the combined use of ultrasonic energy with BIB Forte (Group C) was most effective than use of ultrasonic energy alone (Group B).

The mean value of Group D-control (mean = 2.6420) was statistically higher when compared with Group B

Table 1: Comparison of residual biologic debris values in terms of (Mean [SD]) among all the 4 groups using ANOVA test

Group	n	Mean	Std. Deviation	F-value	*P*-value
Group A	10	2.3910	0.42323	77.562	<0.001**
Group B	10	1.3990	0.36452		
Group C	10	0.3750	0.16318		
Group D	10	2.6420	0.46192		
Total	40	1.7017	0.97506		

P<0.05: Significant*, *P*<0.001: Highly significant*, ANOVA: Analysis of variance

Table 2: Tukey's *post-hoc* analysis

Group	Group A	Group B	Group C	Group D
Group A	–	<0.001**	<0.001**	0.442
Group B	<0.001**	–	<0.001**	<0.001**
Group C	<0.001**	<0.001**	–	<0.001**
Group D	0.442	<0.001**	<0.001**	–

(mean = 1.3990) and Group C (mean = 0.350). $P = 0.05$. There was no statistically significant difference between Group A and Group D [Tables 1 and 2].

DISCUSSION

Endodontic files are instruments used during root canal treatment. Procedures carried out in the oral cavity result in the contamination of instruments. The contaminated files can facilitate the transmission of infectious diseases. Hence, it is crucial that efficient infection control practices are implemented before their re-use. Sterilization by autoclaving is considered a fundamental way to achieve infection control. The presence of biologic debris on the surface of endodontic files decreases the efficacy of autoclaving. This highlights the importance of removing debris and bio-burden from the surface of endodontic files. Hence, the pre-cleaning of re-usable files and other instruments is important before presenting them for autoclaving.[1,7]

Soaking instruments in sodium hypochlorite before autoclaving is done since time immemorial. NaOCl dissolves the debris present on the fluted surface of a clinically used instrument.[8] In Group A, the pre-cleaning protocol followed was rotary S1 Protaper universal files were immersed in 2% sodium hypochlorite for 10 min followed by manual cleaning with 20 strokes of nylon brush. This is the easiest and clinically feasible pre-cleaning protocol. Pre-soaking in NaOCl loosens the debris and there is enhanced cleaning by mechanical brushing with a nylon brush.[8]

There were large amounts of residual biologic debris remaining after pre-cleaning protocol followed in this group and this agrees with the study conducted by Parashos *et al*.[6] This may be due to restricted access of bristles to all surfaces of the file blade. The brush is larger than the width of the file flutes. It is unpredictable as to whether the entire circumference of the file is being contacted by the brush.[4] This method is dependent on the human factor and commitment toward making the instrument free of biologic debris leading to the presence of more residual debris.[10]

Rhodamine B dye was used to stain the residual biologic debris. This led to an easy appreciation of debris under a stereomicroscope. In Group B, the clinically used rotary S1 Protaper Universal files were immersed in an ultrasonic bath containing distilled water for 15 min. Ultrasonic cleaning produces high-frequency sound waves which are transferred to the cleaning liquid. This results in the generation and a collapse of a large number of minute bubbles throughout the liquid.[11] Subsequently; these bubbles burst creating water waves that impact the solid surfaces. This effect is known as cavitation which facilitates the cleaning of the instrument.[12]

The pre-cleaning protocol followed in Group B consisted of an Ultrasonic bath and distilled water, while in Group C it was the ultrasonic bath with BIB forte. This was done to assess the efficacy of ultrasound alone and ultrasound combined with an enzymatic solution.

The mean value of residual biologic debris in Group B is lower than Group A and Group D, but the mean value was higher than Group C. This suggests that ultrasound combined with the special enzyme is effective in the removal of debris from clinically used endodontic instruments. This was not in agreement with the study done by Filho *et al*. who concluded that High-Med detergent combined with an ultrasound did not provide greater cleaning efficacy than ultrasonic bath with distilled water indicating that cleaning of endodontic files was due to the ultrasonic energy.[12] The difference in the results can be attributed to different enzymatic solutions and differences in methodology used in these two studies.

The pre-cleaning protocol followed in Group C was rotary S1 Protaper Universal files were immersed in an ultrasonic bath containing enzymatic solution (BIB forte) for 15 min. The lowest values of residual biologic debris were demonstrated in this group. This can be attributed to the synergistic effect of ultrasonic energy and the chemical action of BIB Forte. The ultrasonic bath generates acoustic streaming and cavitation resulting in mechanical flushing of the debris from the complex structure of rotary S1 Protaper Universal files.[13] BIB Forte is active against microbes. It is bactericidal, Tuberculocidal, Mycobactericidal,

fungicidal, and virucidal. It contains special enzymes which are 2.2 g dodecyidipropylenetriamine and 1.7 g of trialkyethoxyammoniumproprionate. It contains surfactant and anticorrosion substance. The chemical action of BIB Forte removes proteins, lipids, and carbohydrates from the instrument surface.[13] Similar findings were obtained by Margana *et al.* who suggested that the enzymatic solution Biosonic due to its chemical action, removes the debris from the surface of the contaminated instrument when used along with ultrasound.[4] Thus, the combined effect of ultrasonic energy and BIB Forte renders the instrument clean prior to sterilization as compared to other pre-cleaning protocols evaluated.

However, accurate quantitative and qualitative analysis of residual biologic debris was not conducted in this study, hence, further research in this regard is needed.

CONCLUSION

The combined use of ultrasound and a special enzyme BIB Forte removed the biologic debris to the maximum level. Further studies with the larger sample using different chemical and mechanical methods for pre-cleaning of instruments before sterilization are warranted. Accurate methods to qualitatively and quantitatively determine the amount of residual biologic debris that are not subjected to human errors are required.

REFERENCES

1. Messer H, Parashos P, Moule A. Should endodontic files be single-use only? Aust Endod J 2003;29:143-5.
2. Bryson L, Rivas DF, Boutsioukis C. Cleaning of used rotary nickel-titanium files in an ultrasonic bath by locally intensified acoustic cavitation. Int Endod J 2017;51:457-68.
3. Khullar P, Raisingani D, Gupta S, Bishen K. Evaluation of biological debris on reusable endodontic instruments subjected to different cleaning methods prior to sterilization. Int J Infect Control 2013;9:35.
4. Margana P, Yenni M, Bandi S, Avula S, Kakarla P, Amrutavalli A. Comparative evaluation of four different sterilization methods on contaminated endodontic files. CHRISMED J Health Res 2017;4:194.
5. Popovic J, Gasic J, Zivkovic S, Petrovic A, Radicevic G. Evaluation of biological debris on endodontic instruments after cleaning and sterilization procedures. Int Endod J 2010;43:336-41.
6. Parashos P, Linsuwanont P, Messer H. A cleaning protocol for rotary nickel-titanium endodontic instruments. Aust Dent J 2004;49:20-7.
7. Gnau H, Goodell G, Imamura G. Rapid chair-side sterilization of endodontic files using 6% sodium hypochlorite. J Endod 2009;35:1253-4.
8. Barbosa FO, da Cunha Ponciano Gomes JA, de Araújo MP. Influence of sodium hypochlorite on mechanical properties of K3 nickel-titanium rotary instruments. J Endod 2007;33:982-5.
9. Ziauddin S, Bhandary S, Pramod J, Srinivasan R, Mahesh MC. A comparative evaluation of the effectiveness of different cleaning protocols on removal of biological debris on endodontic instruments-an *in vitro* study. Endodontology 2013;25:19-26.
10. Sajjanshetty S. Sterilization of dental burs and endodontic files. Dent Abstr 2009;54:212.
11. Jatzwauk L, Schöne H, Pietsch H. How to improve instrument disinfection by ultrasound. J Hosp Infect 2001;48:S80-3.
12. Filho MT, Leonardo M, Bonifácio K, Dametto F, Silva L. The use of ultrasound for cleaning the surface of stainless steel and nickel-titanium endodontic instruments. Int Endod J 2001;34:581-5.
13. Vassey M, Budge C, Poolman T, Jones P, Perrett D, Nayuni N, *et al*. A quantitative assessment of residual protein levels on dental instruments reprocessed by manual, ultrasonic and automated cleaning methods. Br Dent J 2011;210:E14.

How to cite this article: Deshpande S, Jadhav A, Mujumdar H. Comparative Evaluation of Three Pre-cleaning Protocols in the Elimination of Biologic Debris on Rotary Nickel Titanium Endodontic Instruments before Sterilization. Int J Sci Stud 2021;9(9):96-100.

Source of Support: Nil, **Conflicts of Interest:** None declared.

Print ISSN: 2321-6379
Online ISSN: 2321-595X

Original Article

Forgotten Double-J Stent: Evaluation and Management in a Tertiary Hospital in the North East India

Nawaz Ali[1], Khumukcham Somarendra[2], Abass Ali[3]

[1]Senior Resident, Department of Urology, Regional Institute of Medical Sciences, Imphal, Manipur, India, [2]Assistant Professor, Department of Urology, Regional Institute of Medical Sciences, Imphal, Manipur India, [3]Senior Resident, Department of Anesthesia, Government Medical College, Jammu, Jammu and Kashmir, India

Abstract

The objectives of this study were to evaluate the clinical profile, the management and complications of the 16 cases of forgotten double-J stent. Cases with more than 6 months duration of the stent without prolonged stenting indication were included. The following parameters (such as age, sex, literacy, socioeconomic status, stenting indication, duration of the indwelling stent, presenting complaints, various treatments given, and their management and eventual outcome) were recorded and analyzed. The mean age was 59.12 ± 9.8 years (34–70). Most commonly found in females 9 (56.25%). Most of the patients 11 (68.75%) were illiterate and common in the lower socioeconomic class group 10 (62.50%). The mean age of the stent indwelling time was 1.73 ± 0.9 (0.11–3.4) years. The most common reason for stenting was ureteroscopic lithotripsy 7 (43.75%) cases. The most common presenting complaint was flank pain with lower urinary tract symptoms in 9 (56.25%) patients, recurrent urinary tract infections in 2 (12.5%) patients, and 4 (25%) cases were asymptomatic. Severe stent encrustation with stone formation was seen in ten cases, urinary obstruction in two cases, stent migration in one case, and stent fragmentation was seen in two cases. Cystoscopy with stent removal was done in four patients, cystolithotripsy (CLT) four patients, three patients underwent initially CLT followed by PCNL. Two fragmented stents were retrieved by ureteroscopy and one patient underwent open pyelolithotomy.

Key words: Forgotten double-J stent, North East India, Cystolithotripsy, Percutaneous Nephrolithotomy

INTRODUCTION

Since 1967, ureteric stent has been using routinely and widely in urological procedures. They are mainly used after any elective ureteric surgery of ureteric obstruction due to intrinsic or extrinsic causes such as stones, strictures, ureteropelvic junction obstruction, retroperitoneal fibrosis, malignancies, and congenital anomalies.[1]

It is usually safe and well-tolerated; however, it is associated with complications which can be mild to severe complications such as encrustation, urinary tract obstructions, and renal failure. The most common factors responsible for the encrustation include the stent indwelling time, urinary tract infection (UTI), and history of concomitant stone disease.[2]

The removal of encrusted stents is one of the most complicated endourological procedures as the loss of tensile strength due to neglected may lead to its breakage and fragmentation. The various methods of treatment such as shock wave lithotripsy (SWL), cystolithotripsy (CLT), ureteroscopic lithotripsy (URSL), percutaneous nephrolithotomy (PCNL), and open surgery methods have been used for the treatment of encrusted stents.[3]

MATERIALS AND METHODS

This was a prospective study conducted at the Regional Institute of Medical Science Imphal Manipur India. All the patients with an age of more than 18 irrespective of sex, who came to the urology outpatient department/causality with forgotten double-J (DJ) stent from September 2019 to 31 August 2021 were included. The inclusion criteria were cases with more than 6 months duration of the stent without prolonged stenting indication.

Access this article online

www.ijss-sn.com

Month of Submission : 10-2021
Month of Peer Review : 11-2021
Month of Acceptance : 11-2021
Month of Publishing : 12-2021

Corresponding Author: Nawaz Ali, Department of urology RIMS Imphal - 795 001, Manipur, India.

Written informed consent was obtained from all the patients. The study was conducted after getting clearance from the Ethical Board Committee of our institute.

The education and socioeconomic status of the patients were calculated by the modified Kuppuswamy scale. The education status ranged from score 1 to score 7. The patients were classified under Class 1 – upper, Class 2 – upper middle, Class 3 – lower-middle, Class 4 – upper-lower, and Class 5 – lower according to socioeconomic status.

After getting admitted to the ward, all the patients were evaluated with all basic routine preoperative investigations. The demography, educational/socioeconomic status, the indication of stenting, duration of stenting, presenting complaint was recorded as per the Performa of the study. Ultrasound abdomen and pelvis, Plain X-ray kidney, ureter, and bladder (KUB), non-contrast computed tomography (NCCT KUB/CT Urogram) were done to evaluate for stent-related complications. The treatment decision was taken from the clinical and radiological findings.

The patients with minimal encrustation were planned for cystoscopy and gentle traction was used for stent removal under C arm guidance. The procedure was abandoned if found resistance during retrograde extraction. The patients with severe encrustation and stone formation on lower coil only were managed by cystoscopic lithotripsy (CLT) using pneumatic lithotripter. The patients with failed retrograde extraction and large stones in the upper coil were managed by percutaneous lithotripsy (PCNL). Rarely pyelolithotomy and ureterolithotomy were required in some cases. Finally, we also evaluated the correlation of stent duration with the complications and need for multiple procedures. Re-stenting was done in patients with complicated encrustation. All the findings were recorded as per the Performa of our study.

Statistical Analysis

Descriptive analysis was done for various clinical parameters. All data were expressed as a percentage, mean ± standard deviation. To test the correlation of stent duration with the complications and need for multiple procedures, the independent *t*-test was used. A $P < 0.05$ was considered significant.

RESULTS

A total of 16 patients were included in our study. The mean age of the patient was 59.12 ± 9.8 years with a range of 34–70 years. Out of sixteen patients, 7 (56.25%) patients were males and 9 (56.25%) patients were female. Most of the patients 11 (68.75%) were illiterate and belongs to the lower socioeconomic class group 10 (62.50%). Right side 9 (56.25%) was more commonly involved [Table 1].

The mean age of the stent indwelling time was 1.73 ± 0.9 years, and the maximum stent duration was for 3.4 years (0.11–3.4). The reason for stenting was post URSL in 7 (43.75%) cases, pre-stented ESWL in 3 (18.75%) cases, post PCNL in 2 (12.50%) cases, post open pyelolithotomy in 2 (12.5%) cases, one patient was emergency stenting for pyonephrosis, and one case was in a pregnant lady during the antenatal period at 32-week amenorrhea for severe hydronephrosis [Table 2].

The most common presenting complaint was flank pain with lower urinary tract symptoms (LUTS) in 9(56.25%)

Table 1: Patient demographics

Patient demographics	Number of patients (*n*=16)
(Mean age±SD*)	59.12±9.8
IQR*	53.50–65.50
Age (years)	
<60	5 (31.25%)
≥60	11 (68.75%)
Sex	
Male	7 (43.75%)
Female	9 (56.25%)
Educational status	
Illiteracy	11 (68.75%)
Educated	5 (31.25%)
Socioeconomic status	
Upper	0
Upper middle 2	1 (6.25%)
Lower middle 3	1 (6.25%)
Upper lower 4	4 (25%)
Lower 6	10 (62.50%)
Site of involvement	
Right	9 (56.25%)
Left	7 (43.75%)

SD: Standard deviation, IQR: Inter quartile Range

Table 2: Indication of stenting

Indication of stenting	Number of patients (*n*=16)
*ESWL	
*PCNL	3 (18.75%)
*URSL	2 (12.50%)
Emergency stenting for	7 (43.75%)
Pyonephrosis	1 (6.25%)
Open surgery	2 (12.5%)
Pregnancy	1 (6.25%)
Duration of stenting (years)	
Range	0.11–3.4
Mean±SD*	1.73 ± 0.9
*IQR	1.100–2.550
Presenting complaints	
LUTS*+flank pain	9 (56.25%)
Flank pain and fever	1 (6.25%)
Recurrent UTI*	2 (12.5%)
Asymptomatic	4 (25%)

ESWL: Extracorporeal shockwave lithotripsy, PCNL: Percutaneous nephrolithotomy URSL: Uretoscopic lithotripsy, UTI: Urinary tract infection, LUTS: Lower urinary tract infection, SD: Standard deviation, IQR: Inter quartile Range

patients, recurrent UTI in 2(12.5%) patients, and 4(25%) cases were asymptomatic [Table 3].

Case Presentations

A 60-year-old female patient presented with right flank pain and severe dysuria. She underwent right-side DJ stenting following URSL 2.3 years back. The patient did not come for follow-up because of some familial issues and then forgotten. USG KUB was showing a stent with large calculus at the lower ends of the DJ stent. The patient underwent CLT with pneumatic lithotripter and stent removal was done [Figure 1a-c].

Another patient 52-year female, with a history of left-forgotten DJ stent post URSL for 3 years, was admitted with obstructive uropathy with a deranged kidney function test. X-ray KUB shows encrusted stent with the stone formation on both ends of the stent. The patient underwent CLT followed by PCNL under regional anesthesia [Figure 2a and b].

Urinary obstruction was seen in two cases and one of the patients had elevated serum creatinine. Stent migration was present in one case, stent fragmentation in two cases [Figure 3a and b], and severe stent encrustation with stone formation was seen in ten cases [Table 4].

Table 3: Preoperative diagnosis

Preoperative diagnosis	Number of patients (*n*=16)
Bladder stone+FS*	4 (25%)
Stone on both ends+FS*	3 (18.75%)
Ureteric calculi+moderate HDN*+FS*	1 (6.25%)
Stent migration	1 (6.25%)
Stent fragmentation	2 (12.5%)
Pyonephrosis+ureteric calculi+AKI*+ FS*	1 (6.25%)
Asymptomatic with minimal+FS*	4 (25%)

FS: Forgotten stent, HDN: Hydronephrosis, AKI: Acute kidney injury

Cystoscopy with stent removal was done in four patients, four patients underwent CLT with stent removal, three patients with stone on both ends of the forgotten stent underwent initially CLT followed by PCNL, and the stent was removed. Two patients with ureteric obstruction with stone were managed by URSL. Two fragmented stents were retrieved by URS and one patient with a large stone in the pelvis with forgotten stent was managed by open pyelolithotomy [Table 4].

Re-stenting was done in all patients with complicated encrustation with stone formation.

DISCUSSION

Different studies have defined forgotten DJ stent differently, as there is no appropriate definition. Monga *et al.*[3] and Tang *et al.*[4] defined forgotten DJ stents as those used for anticipated extraction.[5] Lin *et al.*[6] classified forgotten DJ stent into 3-month, 6-month,

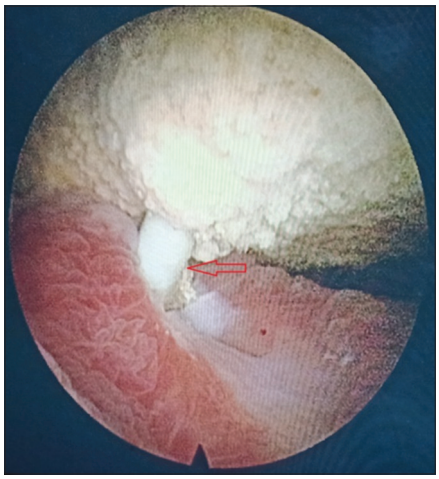

Figure 1b: Cystoscopy showing bladder stone with forgotten double-J stent *in situ*

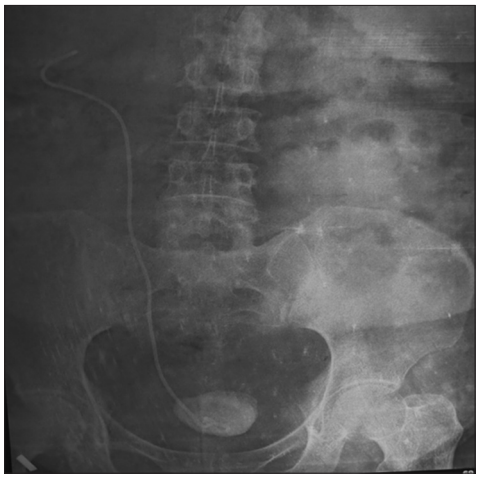

Figure 1a: X-ray ray kidney, ureter, and bladder showing right Forgotten double-J stent with bladder stone

Figure 1c: Post cystolithotripsy with stone fragments and forgotten double-J stent

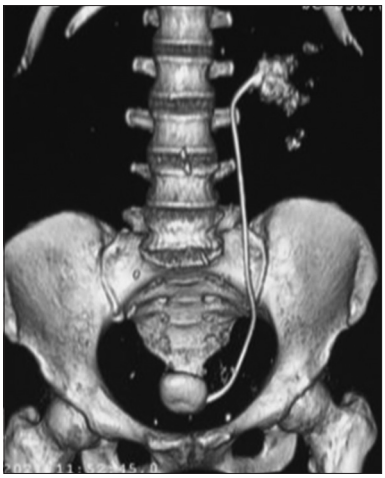

Figure 2a: X-ray kidney, ureter, and bladder showing Left forgotten double-J stent with the stone formation on both ends of the stent

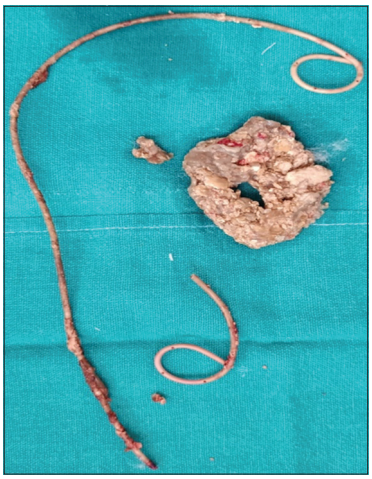

Figure 2b: Encrusted stent with stone after the operation with the fragmentation of upper coil of double-J stent

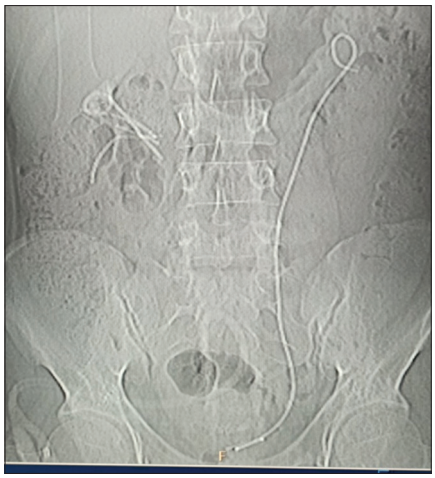

Figure 3a: X-ray kidney, ureter, and bladder showing right fragmented upper stent with left stent

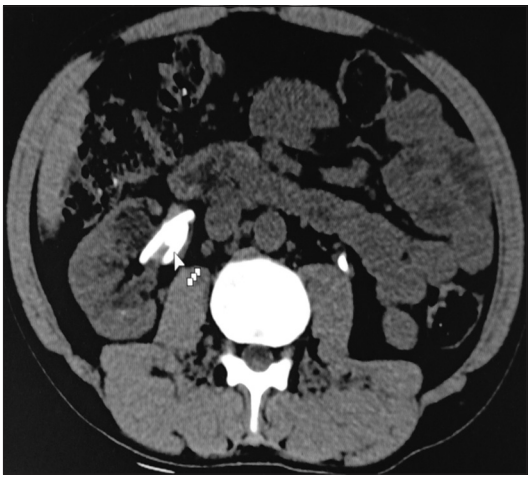

Figure 3b: Axial computerized tomography showing right fragmented stent in the pelvis with left stent *in situ*

and 12-month groups based on their maximal stent life (MSL). In our study, we defined forgotten DJ stents as an indwelling time of more than 6 months.

As the use of DJ stenting is a routine urological surgical practice in endourology and forgotten ureteric stents can be present because of the failure of the physician to adequately counsel the patient or because of poor patient compliance. We evaluated the education and socioeconomic status of the patients in these patients and found forgotten DJ stent was more common in the illiterate 11 (68.75%) and low socioeconomic groups 10 (62.5%) of patients. This can be one of the patient-related reasons for the forgotten stent in our study.

The forgotten DJ stent has a variable presentation, which includes irritative voiding symptoms, flank pain, hematuria, fever, stent fragmentation, and migration. In our study, we found LUTS and flank pain 9 (56.25%) were the most common symptoms which bring the patient to the hospital. Agarwal *et al.*[7] also found LUTS was the most common symptom followed by hematuria and flank pain in their study. Damiano *et al.*[8] observed flank pain in 25.3%, irritative bladder symptoms in 18.8%, hematuria in 18.1%, and fever in 12.3%, of the patients.

Table 4: Procedures

Nature of procedures	Number of patients (*n*=16)
Cystoscopy+stent removal	4 (25%)
CLT*+stent removal	4 (25%)
CLT*+PCNL*+stent removal	3 (18.75%)
*URS+stent removal	2 (12.5%)
*URSL+stent removal	2 (12.5%)
Open Pyelolithotomy+stent removal	1 (6.25%)

CLT: Cystolithotripsy, PCNL: Percutaneous nephrolithotomy, URS: Ureteroscopy, URSL: Uretoscopic lithotripsy

The etiology of encrustation and stone formation on a stent is multi-factorial, and it includes long indwelling time, urinary stone disease, pregnancy, metabolic, and congenital abnormalities.[9] the mean stent indwelling duration was 1.73 ± 0.9 years, and the maximum stent duration was for 3.4 years. The maximum duration of indwelling stent till recorded is 23 years.[10] The most common indication for stenting in our study group was stenting post-URSL 7(43.75%) for ureteric stone. The reason for increased incidence may be because of doing the URSL procedure in females on minor operation theatre (OT) day and we used to have a high patient load and very little time for proper counselling of the patients regarding placement of the stent and associated complications.

Stent-related complications such as encrustation, fragmentation, and obstructions were usually found in asymptomatic patients.[11] In our study, stent fragmentation was found in two patients, one was found preoperatively, and another was fragmented intraoperatively during retrograde stent removal. Both cases were removed by a semi-rigid ureteroscope.

The patients of a forgotten DJ stent should be managed with investigations including routine blood, urine culture, KUB film, ultrasonography of the KUB region. We conducted NCCT KUB to look for severity of encrustation and stone formation and CT urography was done in patients with a high stone burden to look for the functional status of the kidney. Imaging plays an important role in evaluating the patient and determining appropriate surgical management of the encrusted and retained stent. Very rarely nephrectomy is required in a poorly functioning kidney with significant stone burden, rather than going for multiple procedures to clear the stones.[12]

The management of the forgotten DJ stents depends on multiple factors such as the site of encrustation, the size of the stone burden, and the function of the affected kidney. The management often requires multiple endourological approaches and/or open surgeries. As there is no definitive algorithm, some investigators have reported high success rates in managing calcified stents using endourologic techniques in a single anesthetic setting.[13] However to render the patient stent and stone-free completely, usually multiple treatment sessions are required.[14]

If no encrustation is visible on plain radiography, removal of the stent in a retrograde fashion should be attempted gently and if there is any resistance while attempting to remove, one should stop immediately to prevent stent fragmentation and ureteric injury. In patients with severe encrustations and stone, different treatment modalities were used such as CLT, URSL, PCNL, and open pyelolithotomy depending on the location and burden of the stone. The calcification along the ureter can be managed with retrograde ureteroscopy following guide wire insertion and laser lithotripsy. In our cases, the encrustations and stone were free from the ureteric wall, so we could easily negotiate the ureteroscope and broke the stone with a holmium laser. If the encrustations involve the stent circumferentially and extensive edema is present, the surgeons should be very cautious while pulling or pushing manoeuvres, as it may perforate or avulse the ureter. PCNL is the preferred approach in proximal larger stent encrustation/stone and a case of simultaneous large proximal and distal stones, PCNL in the Galdakao-Valdivia supine position had been a preferred choice as it can address both the encrustations simultaneously.[15,16] ESWL can be an option in cases of proximal encrustation and lower stone burden, but as monotherapy may not be appropriate or recommended. In our study, we have not used ESWL in any of our cases as the stone burden was very high.

The indwelling time was found to affect the infection, as more the indwelling time; there is more liability to have complications. We also found a significant correlation between the duration of stent indwelling time and complications like encrustations/stone and the requirement of multiple procedures for complete clearance of the stone ($P = 0.017$) [Table 5]. In our study, all the patients were discharged within due course of time with no mortality and the outcome was satisfactory.

Management of forgotten DJS is time-consuming, difficult, complicated, risky, and costly. Therefore; financial burden, increased labor loss, and impaired quality of life brought by the application of these modalities must not be forgotten.

So how to avoid a catastrophe like a forgotten stent remains still elusive! The underprivileged sections of the society and

Table 5: Correlation between stent duration and complications/requirement of multiple procedures

	Complications		*P*-value	Test performed
	No	Yes		
Age				
Sample size	8	8	0.082	*t*-test; 1.873
Mean±SD*	54.88±11.59	63.38±5.5		
Median	57.5	64		
Min-Max	34-69	52-70		
Inter quartile Range	47–63.500	61.500–67		
Duration of stenting (years)			0.017	*t*-test; 2.698
Sample size	8	8		
Mean±SD*	1.21±0.63	2.24±0.87		
Median	1.2	2.4		
Min-Max	0.11–2.3	1.2–3.4		
IQR*	0.950–1.500	1.350–2.900		

SD: Standard deviation, IQR: Inter quartile Range

the people belonging to low socioeconomic status were most commonly involved and these sections of society should be our priority.[17] In this group of patients, it is the responsibility of the treating urologist to adequately counsel the patient or the patient party. Patient compliance is equally important to decrease this complication. Maintaining a simple stent registry can achieve removal of DJ stent at the due date and prevent this complication.[18] To overcome the retained/forgotten stent problem, several strategies have been developed such as a ureteric stent card registry, e-mail reminder, and a letter of reminder based on billing information.[5,19] however, a long-term prospective trial is still needed for their efficacy.

This is the only institute where urology facility is available in this region. This study is done for the 1st time in the whole northeast region India. Most people of this region especially in Manipur region lives in rural area, have low socioeconomic status and far from adequate primary health service. Further studies are needed in future to know the actual incidence as our sample size was very small, and finally, stone analysis was not performed to study the types of stone encrustation.[20]

CONCLUSION

The forgotten DJ stent is associated with significant morbidity and complications. Usually, the lower socioeconomic class and old age groups were predominantly affected, so Ignorance and lack of proper understanding by the patient were the most common reasons in our study groups. By maintaining a simple stent registry after the procedure can achieve removal of DJ stent on time and prevent its complications.

REFERENCES

1. Saltzman B. Ureteral stents. Indications, variations, and complications. Urol Clin North Am 1988;15:481-91.
2. Ekrem G, Kamil SK. Comparison of two different scoring systems in encrusted ureteral stent management: A single-center experience. Urol J 2020;17:248-51.
3. Monga M, Klein E, Castañeda-Zúñiga WR, Thomas R. The forgotten indwelling ureteral stent: A urological dilemma. J Urol 1995;153:1817-9.
4. Tang VC, Gillooly J, Lee EW, Charig CR. Ureteric stent card register-a 5-year retrospective analysis. Ann R Coll Surg Engl 2008;90:156-9.
5. Ziemba JB, Ludwig WW, Ruiz L, Carvalhal E, Matlaga BR. Preventing the forgotten ureteral stent by using a mobile point-of-care application. J Endourol 2017;31:719-24.
6. Lin TF, Lin WR, Chen M, Yang TY, Hsu JM, Chiu AW. The risk factors and complications of forgotten double-J stents: A single-center experience. J Chin Med Assoc 2019;82:767-71.
7. Agarwal S, Sarpal R, Pathak P, Biswas M, Mittal A, Rathore K, *et al*. Tricks and tacks in the management of the forgotten double J stent. Int Surg J 2018;5:792-5.
8. Damiano R, Oliva A, Esposito C, DeSio M, Autorino R, Armiento M. Early and late complications of double pigtail ureteral stent. Urol Int 2002;69:136-40.
9. Ahallal Y, Khallouk A, El Fassi MJ, Farih MH. Risk factor analysis and management of ureteral double-J stent complications. Rev Urol 2010;12:e147-51.
10. Sohrab A, Aneesh S, Sureka SK, Varun M, Nitesh P, Manoj K, *et al*. Forgotten reminders: An experience with managing 28 forgotten double-J stents and management of related complications. Indian J Surg 2015;77:1165-71.
11. Leibovici D, Cooper A, Lindner A, Ostrowsky R, Kleinmann J, Velikanov S, *et al*. Ureteral stents: Morbidity and impact on quality of life. Isr Med Assoc J 2005;7:491-4.
12. Singh I, Gupta NP, Hemal AK, Aron M, Seth A, Dogra PN. Severely encrusted polyurethane ureteral stents: Management and analysis of potential risk factors. Urology 2001;58:526-31.
13. Alnadhari I, Alwan MA, Salah MA, Ghilan AM. Treatment of retained encrusted ureteral double-J stent. Arch Ital Urol Androl 2019;90:265-9.
14. Weedin JW, Coburn M, Link RE. The impact of a proximal stone burden on the management of encrusted and retained ureteral stents. J Urol 2011;185:542-7.
15. Lopes RI. Patients with encrusted ureteral stents can be treated by a single-session combined endourological approach. Int Braz J Urol 2021;47:574-83.
16. Valdivia JG, Gerhold JV, López JA, Rodriguez SV, Navarro CA, Fabián MR, *et al*. Technique and complications of percutaneous nephroscopy: Experience with 557 patients in the supine position. J Urol 1998;160:1975-8.
17. Sancaktutar AA, Söylemez H, Bozkurt Y, Penbegül N, Atar M. Treatment of forgotten ureteral stents: How much does it really cost? A cost-effectiveness study in 27 patients? Urol Res 2012;40:317-25.
18. Vajpeyi V, Chipde S, Khan FA, Parashar S. Forgotten double-J stent: Experience of a tertiary care center. Urol Ann 2020;12:138-43.
19. Lynch MF, Ghani KR, Frost I, Anson KM. Preventing the forgotten ureteral stent: Implementation of a web-based stent registry with automatic recall application. Urology 2007;70:423-6.
20. Lam JS, Gupta M. Tips and tricks for the management of retained ureteral stents. J Endourol 2002;16:733-41.

How to cite this article: Ali N, Somarendra K, Ali A. Forgotten Double-J Stent: Evaluation and Management in a Tertiary Hospital in the North East India. Int J Sci Stud 2021;9(9):101-106.

Source of Support: Nil, **Conflicts of Interest:** None declared.

Print ISSN: 2321-6379
Online ISSN: 2321-595X

Original Article

A Comprehensive Review of Imaging Features of Neurocutaneous Syndromes

Manisha Lokwani[1], Suraj Makhija[2], Sunit Lokwani[3]

[1]Assistant Professor, Department of Radiodiagnosis, Netaji Subhash Chandra Bose Medical College, Jabalpur, Madhya Pradesh, India,
[2]Post Graduate Student, Department of Radiodiagnosis, Netaji Subhash Chandra Bose Medical College, Jabalpur, Madhya Pradesh, India,
[3]Assistant Professor, Department of Medicine, Sukh Sagar Medical College, Jabalpur, Madhya Pradesh, India

Abstract

Neurocutaneous syndromes, also known as phakomatoses, represent a diverse group of congenital disorders that encompass abnormalities of neuroectodermal and, at times, mesodermal development, hence preferentially manifesting as malformations in the skin, eye, and central nervous system (CNS).[1] In this article, we review the imaging features of the most common neurocutaneous syndromes.

Key words: Neurocutaneous syndromes, NF1, NF2, Tuberous sclerosis, Sturge Weber syndrome

INTRODUCTION

Neurocutaneous syndromes, also known as phakomatoses, represent a diverse group of congenital disorders that encompass abnormalities of neuroectodermal and, at times, mesodermal development, hence preferentially manifesting as malformations in the skin, eye, and central nervous system (CNS).[1]

While a lot of syndromes have been identified and placed in this group, we review in this article the imaging findings of intracranial manifestations of the most common neurocutaneous syndromes, namely, neurofibromatosis 1 and 2, tuberous sclerosis, Sturge-Weber syndrome, and von Hippel-Lindau disease. In this article, we briefly review the imaging features of the commonly seen neurocutaneous syndromes as knowledge of the manifestations is essential not only in diagnosis but follow-up and care of patient.

NEUROFIBROMATOSIS TYPE-1 (NF1)

NF1, also known as von Recklinghausen disease, is the most common of the neurocutaneous syndromes. NF1 is inherited in an autosomal dominant fashion with variable pathological and clinical expression. Approximately half of all cases result from spontaneous mutations of the NF1 gene located on chromosome 17q11.2. The disease affects the brain, skull, orbits, spine, musculoskeletal system, and skin/integumentary system, although there is a significant variability in the type and severity of clinical manifestations.[2]

Diagnosis of NF-1 requires presence of two or more criteria [Table 1][8].

INTRACRANIAL FINDINGS IN NF-1

Optic pathway gliomas are the most common intracranial manifestation. Majority of them are juvenile pilocytic astrocytomas. They appear as either a focal mass on the optic nerve or as a diffuse enlargement of a long segment. The mesencephalic tectum is the most common site of glioma after the optic pathways.

Multiple waxing and waning dysplastic white matter lesions on T2/FLAIR are identified commonly in NF-1. Common locations are basal ganglia (globus pallidus), thalamus, cerebellar peduncles and dentate nuclei, centrum semi-ovale, and brainstem.

Dural ectasia causing dilatation of optic nerve sheaths, Meckel cave, or internal auditory canal may be present in some cases.

Other presentations might include sphenoid wing hypoplasia [Figure 1] with subsequent pulsating exophthalmos, arteriopathy causing progressive intimal fibrosis of

Access this article online

www.ijss-sn.com

Month of Submission : 10-2021
Month of Peer Review : 11-2021
Month of Acceptance : 11-2021
Month of Publishing : 12-2021

Corresponding Author: Dr. Manisha Lokwani, 35, APR Colony, Katanga, Jabalpur - 482 001, Madhya Pradesh, India.

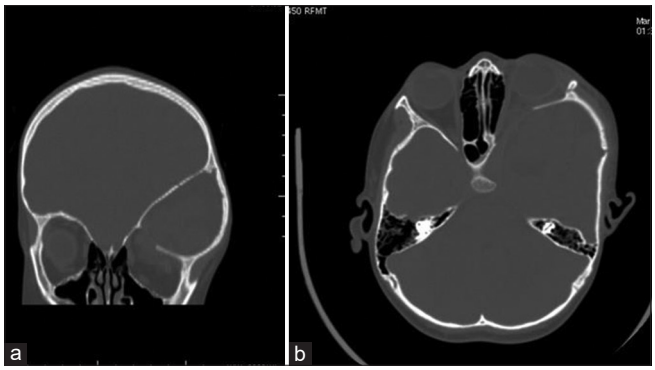

Figure 1: A 16-year-old patient with NF-1. NECT head (bone window) axial (a) and coronal (b) images demonstrate dysplastic left-sided greater wing of sphenoid and enlarged left middle cranial fossa and left orbital fissure with associated left-sided exophthalmos

Table 1: Diagnostic criteria of neurofibromatosis Type 1[3]

Clinical diagnosis of NF1 is established when two or more of the following are present

1. Six or more cafe-au-lait macules with size over 5 mm in prepubertal individuals and over 15 mm in post-pubertal individuals.
2. Two or more neurofibromas of any type or one plexiform neurofibroma
3. Two or more Lisch nodules (iris hamartomas)
4. Freckling in the axillary or inguinal region
5. Optic nerve glioma
6. One or more distinctive osseous lesions such as sphenoid dysplasia and pseudoarthrosis
7. First-degree relative with NF1 by the above criteria

the supraclinoid internal carotid arteries (resulting in moyamoya), and cranial nerve tumors (rarely).[4,5]

NEUROFIBROMATOSIS TYPE-2 (NF2)

This is an autosomal dominant disorder caused by mutations of the NF2 gene on chromosome 22q12. It is characterized by multiple cranial, spinal, and cutaneous nerve schwannomas, intracranial and intraspinal meningiomas, and ependymomas [Figures 2 and 3]. The most common NF-2-related schwannomas include vestibular schwannomas. Non-vestibular schwannomas are seen in 50% of patients and involve trigeminal and oculomotor nerve. The most common sites for NF-2 associated meningiomas include falx and cerebral convexities.[5] Diagnostic criteria for NF-2 are elucidated in Table 2[6].

TUBEROUS SCLEROSIS

Tuberous sclerosis complex (TSC), also known as Bourneville disease, is an autosomal dominant heritable

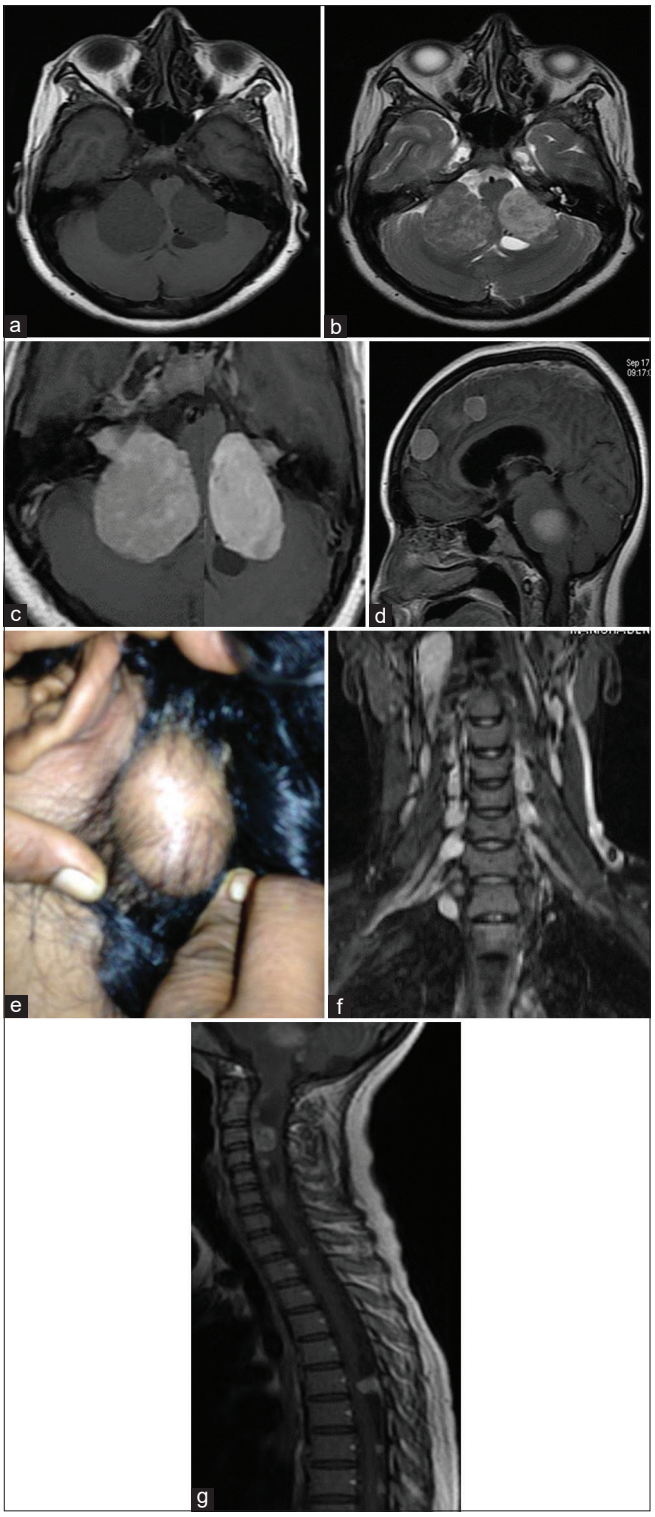

Figure 2: Neurofibromatosis 2. A 21-year-old girl with progressive hearing loss and difficulty in speech and walking with NF-2. T1W (a) and T2W (b) images show bilateral acoustic schwannomas in CP angles. The mass appears hypointense on T1 and heterogeneously hyperintense on T2, and shows avid post-contrast enhancement on T1 C+ images (c). Sag post-contrast images (d) show falcine meningiomas. (e) A cutaneous schwannoma. (f) Multiple spinal nerve schwannomas arising from bilateral spinal nerves of brachial plexus. (g) A heterogeneously enhancing intramedullary lesion in cervical cord (ependymoma) with polar cysts and an intraspinal meningioma in thoracic region

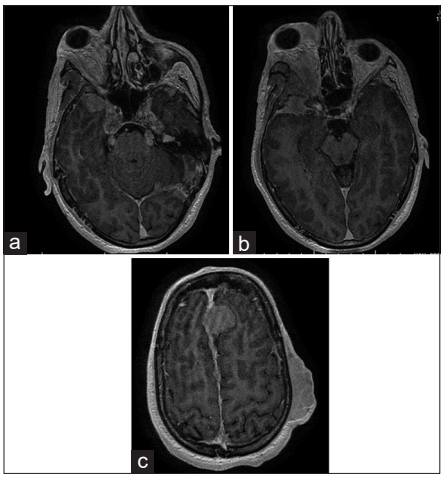

Figure 3: Neurofibromatosis 2. (a) CEMRI brain axial images in another patient with NF 2 with bilateral trigeminal schwannomas in prepontine cisterns and Meckel's cave. (b) The right-sided sphenoid wing meningioma causing right-sided exophthalmos and hyperostosis of the right greater wing of sphenoid, meningioma along the right anterior temporal dura and a small posterior falcine meningioma. (c) Anterior falcine meningioma in the left parasagittal location and a cutaneous schwannoma in the left parietal scalp

Table 2: Diagnostic criteria of NF-2

1. Bilateral vestibular schwannomas
2. A first-degree relative with NF2 AND
   - Unilateral vestibular schwannoma OR
   - ANY TWO of the following: meningioma, schwannoma, glioma, neurofibroma, cataract in the form of posterior subcapsular lenticular opacities or cortical wedge cataract
3. Unilateral vestibular schwannoma AND ANY TWO of the following: meningioma, schwannoma, glioma, neurofibroma, cataract in the form of posterior subcapsular lenticular opacities or cortical wedge cataract
4. Multiple meningiomas AND
   - Unilateral vestibular schwannoma OR
   - ANY TWO of the following: schwannoma, glioma, neurofibroma, cataract in the form of posterior subcapsular lenticular opacities or cortical wedge cataract

neurocutaneous disorder that is caused by mutations in TSC1 and TSC2 tumor suppressor genes.

The classic clinical triad (i.e., Vogt triad) comprises seizures, intellectual disability, and facial angiofibromas [Figure 4a and 5a]; however, this triad is seen in less than 50% of cases.[7]

Clinical diagnostic criteria of tuberous sclerosis involve features mentioned in Table 3[8].

Common intracranial manifestations of tuberous sclerosis involve cortical and subcortical tubers, white matter lesions, subependymal nodules [Figure 4], and subependymal giant cell astrocytoma (SEGA).

Cortical tubers are T2 hyperintense and T1 hypointense cortical subcortical nodules that may or may not demonstrate calcification [Figure 5].

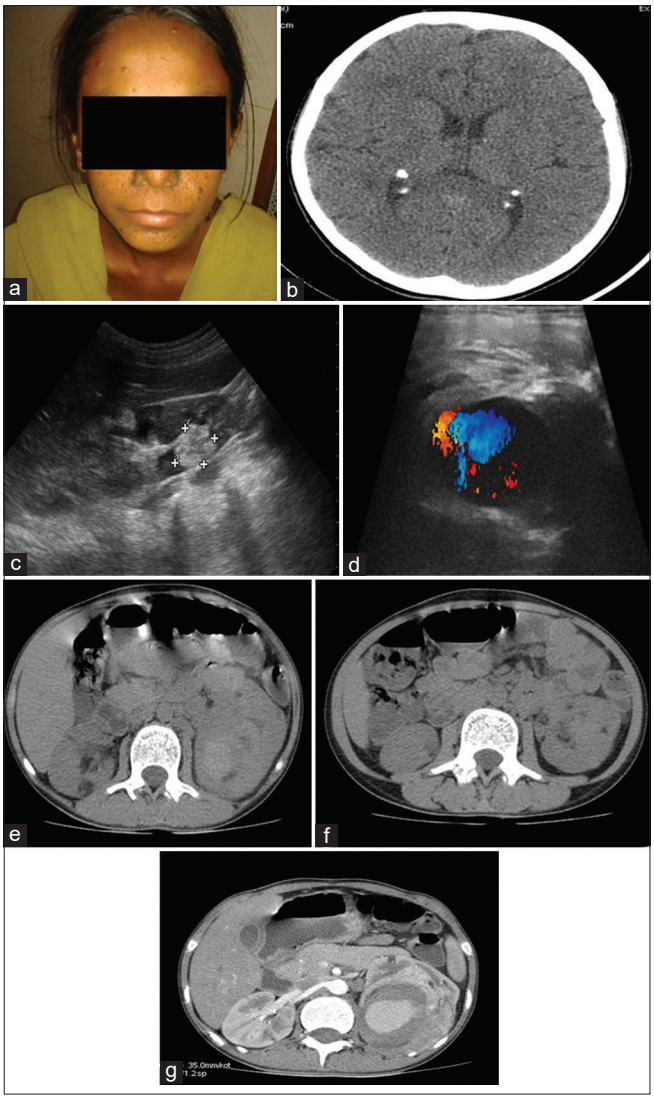

Figure 4: Tuberous sclerosis in a 14-year-old female (a) demonstrates bilateral facial adenoma sebaceum. (b) NCCT head axial scan shows calcified subependymal nodules in bilateral lateral ventricles. Renal ultrasonography (c) shows a hyperechoic lesion at mid-lower pole (angiomyolipoma) and a cystic lesion (d) with internal bidirectional flow at upper pole (aneurysm formation in angiomyolipoma). (e and f) NCCT abdomen shows fat containing lesions in B/L kidneys – angiomyolipomas. (g) Contrast-enhanced CT shows an aneurysmal AML in the rt. kidney as seen on ultrasound

White matter heterotopia on MRI may appear as nodules, cysts, and areas of gliosis (radial bands) extending from ventricle to cerebral cortex that is T1 isointense or hypointense and T2 hyperintense.

Subependymal tubers are seen as nodules along the ependymal surface of lateral ventricles with or without dense calcification [Figure 4b and c and 5f]. SEGAs are similar to subependymal nodules but larger and with more avid enhancement, seen often near the foramen of Monro, and may cause obstructive hydrocephalus.[7,9]

Table 3: Clinical diagnostic criteria of tuberous sclerosis

Major features
1. Hypomelanotic macules (≥3, at least 5 mm diameter)
2. Angiofibromas (≥3) or fibrous cephalic plaque
3. Ungual fibromas (≥2)
4. Shagreen patch
5. Multiple retinal hamartomas
6. Cortical dysplasias
7. Subependymal nodules
8. Subependymal giant cell astrocytoma
9. Cardiac rhabdomyoma
10. Lymphangioleiomyomatosis (LAM)
11. Angiomyolipomas (≥2)
Minor features
1. "Confetti" skin lesions
2. Dental enamel pits (>3)
3. Intraoral fibromas (≥2)
4. Retinal achromic patch
5. Multiple renal cysts
6. Non-renal hamartomas
Definite diagnosis: Two major features or one major feature with ≥2 minor features
Possible diagnosis: Either one major feature or ≥2 minor features

Renal involvement of TS includes renal angiomyolipoma (AML), renal cysts, and renal cell carcinoma [Figure 4d-g]. Renal AML is one of the common manifestations, with a frequency of 55–75% in patients with TS (7) conversely, approximately 20% of patients with AML have TS. The second most common renal manifestation of TS is renal cysts. In contrast to renal AMLs, renal cysts occur in younger children and can result in subsequent renal failure and hypertension.[7]

STURGE-WEBER SYNDROME

Sturge-Weber syndrome, also known as encephalotrigeminal angiomatosis, is one of few neurocutaneous syndrome that is sporadic; not familial and not inherited.

Its hallmarks are variable combinations of[5] –

- Capillary malformation of skin (port wine stain) in the distribution of trigeminal nerve [Figure 6a]
- Retinal choroidal angioma (with or without glaucoma)
- Cerebral capillary-venous leptomeningeal angioma [Figure 6b-f and 7a and b].

The major pathological abnormality in Sturge-Weber disease is a meningeal tangle of vessels, commonly referred to as an angioma, which is usually confined to the pia mater. Contrast-enhanced MR is the single most accurate imaging for showing the extent of pial angioma. On a post-contrast MR image, angiomas appear as an area of enhancement in subarachnoid space covering the surfaces of gyri, filling in the cortical sulci.

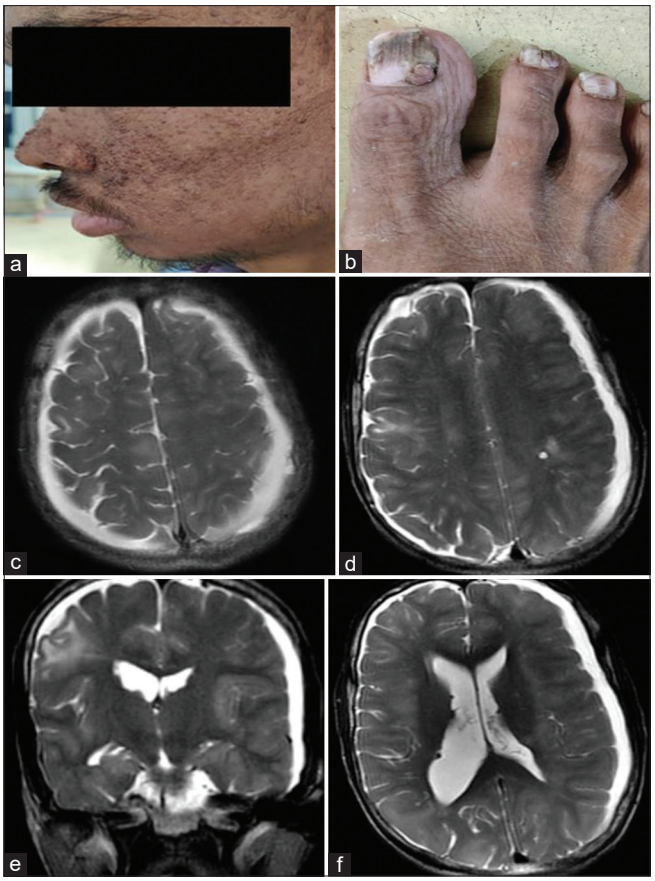

Figure 5: A 33-year-old male with tuberous sclerosis. The patient had facial adenoma sebaceum (a) and multiple periungual fibromas (b). (c) MRI brain T2W image shows presence of multiple T2 hyperintense cortical tubers. (d and e) MRI brain T2W image shows presence of white matter heterotopias extending from ventricles to cortex. (f) Small subependymal nodules can be noted in bilateral lateral ventricles

The choroid plexus is frequently enlarged in patients with SWS, which is proportional to the extent of the leptomeningeal angioma on the same side.

Cortical calcifications in SWS occur in areas of the brain adjacent to the angioma [Figure 6c and d and 7a and b].

They can be depicted on CT and susceptibility-weighted imaging (SWI) or T*-weighted gradient echo images.

The affected hemisphere undergoes progressive atrophy.[10]

VON HIPPEL-LINDAU (VHL) DISEASE

VHL disease is a rare, autosomal dominantly inherited multisystem disorder characterized by the development of a variety of benign and malignant tumors.

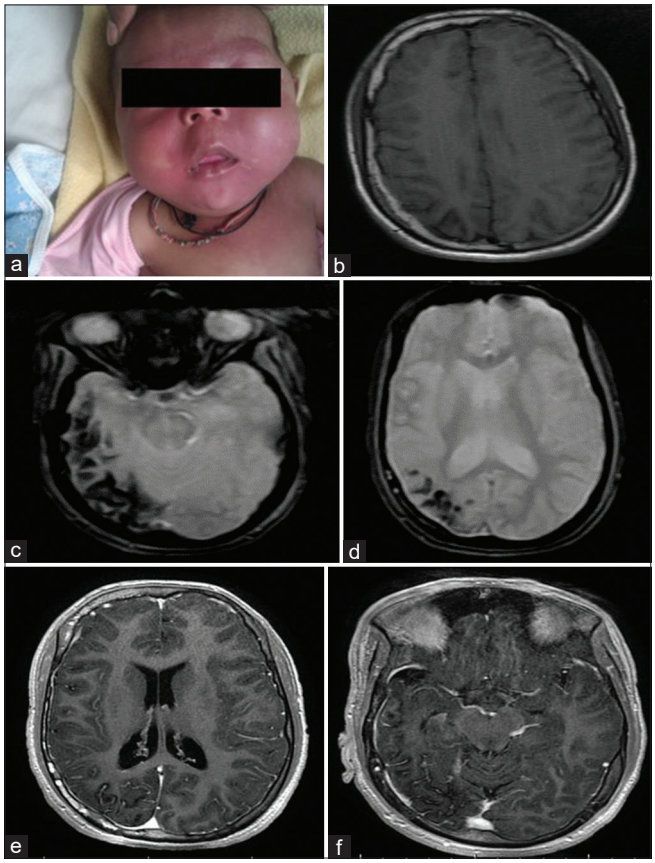

Figure 6: A 6-month-old child with Sturge-Weber syndrome. The child had facial port-wine stain (a). (b) Axial T1W MR image demonstrates right-sided cerebral hemiatrophy. (c and d) Gyral calcifications in parieto-occipito-temporal region are seen as tram-track hypointensities on SWI. (e and f) Post-contrast axial T1W images demonstrate gyral enhancement along the right cerebral convexities

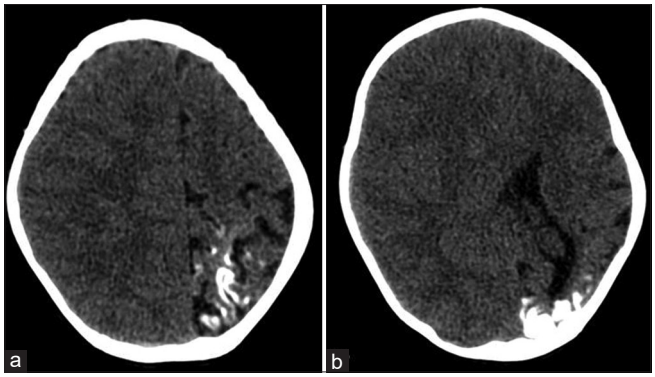

Figure 7: A 4-year-old female child with Sturge-Weber syndrome had a history of convulsions. Axial CT (a and b) shows left-sided cerebral hemiatrophy with gyral calcifications and associated enlargement of ipsilateral choroid plexus

The spectrum of clinical manifestations of the disease is broad and includes retinal and CNS hemangioblastomas, endolymphatic sac tumors, renal cysts and tumors, pancreatic cysts and tumors, pheochromocytomas, and epididymal cystadenomas.

Diagnostic criteria are given in Table 4.

CNS hemangioblastoma is one of the most common manifestations of VHL disease. Typical sites are the cerebellum (44–72%), spinal cord (13–59%), and medulla (5%) (11). Supratentorial lesions are less common. They may be solid, cystic, hemorrhagic, or mixed. They are often cystic with a solid enhancing mural nodule [Figure 8]. Spinal cord lesions may be associated with a syrinx.

Endolymphatic sac tumors occur sporadically, but an association with VHL disease has been reported rarely. They are located in the posterior part of the petrous temporal bone and cause local bone destruction as well as new bone formation.[5,11]

Table 4: Diagnostic criteria of VHL

1. More than 1 CNS hemangioblastoma
2. One CNS hemangioblastoma and visceral manifestations of VHL disease
3. Any manifestation and a known family history of VHL disease

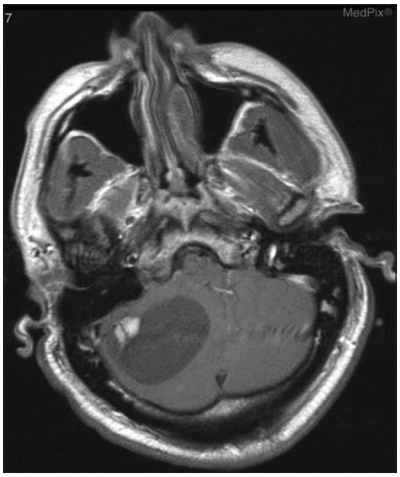

Figure 8: A right cerebellar hemangioblastoma in an adult with VHL – a cyst with an enhancing eccentric mural nodule

CONCLUSION

About 30 or more syndromes are included in the list of phakomatoses but the common ones which are encountered in day to day practice have been reviewed here. Imaging plays an important role in early identification of abnormalities , complications, diagnosis, follow up and prognostication in known cases of such syndromes.

REFERENCES

1. Klar N, Cohen B, Lin DD. Neurocutaneous syndromes. Handb Clin Neurol 2016;135:565-89.
2. O'Brien WT. Neuroimaging manifestations of NF1-A pictorial review. J Am Osteopath Coll Radiol 2015;4:16-21.
3. National institutes of health consensus development conference statement: Neurofibromatosis. Bethesda, Md., USA, July 13-15, 1987. Neurofibromatosis 1988;1:172-8.
4. Herron J, Darrah R, Quaghebeur G. Intra-cranial manifestations of the neurocutaneous syndromes. Clin Radiol 2000;55:82-98.
5. Osborne AG. Brain Imaging, Pathology and Anatomy. 2nd ed. Amsterdam, Netherlands: Elsevier; 2018. p. 1241-94.
6. Evans DG. Neurofibromatosis 2. In: GeneReviews. Seattle, WA: University of Washington; 1998.
7. Umeoka S, Koyama T, Miki Y, Akai M, Tsutsui K, Togashi K. Pictorial review of tuberous sclerosis in various organs. Radiographics 2008;28:e32.
8. Northrup H, Krueger DA, International Tuberous Sclerosis Complex Consensus Group. Tuberous sclerosis complex diagnostic criteria update: Recommendations of the 2012 iinternational tuberous sclerosis complex consensus conference. Pediatr Neurol 2013;49:243-54.
9. Baron Y, Barkovich AJ. MR imaging of tuberous sclerosis in neonates and young infants. AJNR Am J Neuroradiol 1999;20:907-16.
10. Vézina G, Barkovich AJ. Neurocutaneous disorders. In: Barkovich AJ. Pediatirc Neuroimaging. 6th ed. Philadelphia, PA: Lippincott Williams & Wilkins; 2019. p. 904-11.
11. Leung RS, Biswas SV, Duncan M, Rankin S. Imaging features of von Hippel-Lindau disease. Radiographics 2008;28:65-79.

How to cite this article: Lokwani M, Makhija S, Lokwani S. A Comprehensive Review of Imaging Features of Neurocutaneous Syndromes. Int J Sci Stud 2021;9(9):107-112.

Source of Support: Nil, **Conflicts of Interest:** None declared.

Print ISSN: 2321-6379
Online ISSN: 2321-595X

Original Article

Evaluation of Primary and Secondary Stability and Crestal Osseous Changes in Short Implants: A Prospective Clinicoradiograhic Study

Prasamita Mishra[1], Rajesh Kshirsagar[2], Pratik Warade[3]

[1]Post Graduate Student, Department of Oral and Maxillofacial Surgery, Bharati Dental College and Hospital, Pune, Maharashtra, India, [2]Professor and HOD, Department of Oral and Maxillofacial Surgery, Bharati Dental College and Hospital, Pune, Maharashtra, India, [3]Post Graduate Student, Department of Oral and Maxillofacial Surgery, Bharati Dental College and Hospital, Pune, Maharashtra, India

Abstract

Introduction: Alveolar ridges with reduced alveolar bone height are challenging to rehabilitate for many clinicians. Surgical procedures to compensate for tissue deficiency considered, although successful, come with a host of complications. Short dental implants, therefore, offer the clinicians a pragmatic option to facilitate prosthetic restoration in such conditions.

Materials and Methods: Short dental implants (n = 10) placed in edentulous mandibular posterior region were evaluated in this study. Primary and secondary implant stability were measured using resonance frequency analysis, and crestal osseous changes were compared using preoperative and postoperative Cone-beam computed tomography data. Statistical analysis was performed using SPSSv20 software and statistical significance was assessed using paired t-test ($P < 0.05$ was considered significant).

Results: The increase in implant stability quotient from primary to secondary stability in buccolingual (59.7–80.6 ISQ) and apical (61.2–79.3 ISQ) directions were deemed significant. There was a non-significant reduction in crestal bone level at all the sides.

Discussion: Although this study did not follow the short implants through phase of loading, they exhibited satisfactory gradual osseointegration and minimal peri-implant boss loss from the time of its placement to abutment attachment. Short implants may be considered a viable alternative to augmentation procedures in ridges with reduced alveolar height.

Key words: Alveolar bone loss, Dental implant, MegaISQ, Resonance frequency analysis

INTRODUCTION

Over the past two decades, implants have been routinely used to rehabilitate partial and complete edentulous patients due to their biocompatibility and high survival rates. Implants inserted into jawbones can support a prosthesis through osseointegration, the functional and structural connection between bones and implant surface. Implant treatment becomes more challenging to the clinicians when the alveolar bone height is insufficient. The condition is more common in the posterior jaws due to the resorption of alveolar bone and pneumatization of the maxillary sinus.[1,2] Reduced alveolar bone height not only limits the implant placement but also increases the chances of damaging the inferior alveolar nerve, the maxillary sinus, and the nasal cavity. Various procedures such as maxillary sinus floor elevation, bone grafting, guided bone regeneration, distraction osteogenesis, nerve lateralization, and vertical bone augmentation are being used to address the difficulties associated with reduced height in atrophied ridges.[3,4] However, problems associated with these augmentation techniques are high cost and longer treatment time, increased postoperative morbidity, and increased risk of complications.[1,2] Therefore, short implants, tilted implants, zygoma, or pterygoid implants have been proposed as alternatives to avoid bone augmentation. Agreement is lacking about the definition of "short implant" in the literature.

Access this article online

www.ijss-sn.com

Month of Submission : 10-2021
Month of Peer Review : 11-2021
Month of Acceptance : 11-2021
Month of Publishing : 12-2021

Corresponding Author: Dr. Rajesh Kshirsagar, Department of Oral and Maxillofacial Surgery, Bharati Dental College and Hospital, Pune, Maharashtra, India.

In the past, short implants were associated with lower survival rates and with unpredictable long-term results. However, recent clinical studies indicate that short implants may adequately support most prosthetic restorations. This is due to improved surgical techniques and advances in implant characteristics, such as implant design, surface, and implant microgeometry. Short implants come with promising advantages of decreased contact possibility with adjacent tooth roots, lower risk of surgical paraesthesia, less bone overheating, and reduced time and cost. Although studies have revealed that the failure rate of short implants was no higher than that of longer implants[5-11] challenges such as less bone to implant contact due to reduced implant surface, more crestal bone resorption due to a reduced surface over which to distribute forces, and the increased crown-to-implant (CI) ratio still exists.

Since more than a decade, resonance frequency analysis (RFA)[12-14] has been used as an objective method of quantifying implant stability. It is a non-invasive, easily predictable system with reliable inter-clinician reproducibility. RFA has been widely used to determine the effects of immediate or early loading and assess changes instability over time. To further study stability of short implants at the time of placement and placement of healing abutment 3 months later, we used RFA.

The objective of this *in vitro* study is to ascertain the primary and secondary stability of ten short implants in the mandibular posterior region as measured by RFA, and osseous changes at the alveolar crest associated with short implants. Understanding these changes will give an insight into the prognosis of short implants as well as their comparative performance to conventional length implants, in terms of osseointegration achieved from time of placement to abutment placement.

MATERIALS AND METHODS

The procedures followed were in accordance with the ethical standards of the responsible committee on human experimentation (institutional or regional) and with the Helsinki Declaration of 1975, as revised in 2000. Data shall be obtained from patients reporting at:

1. Department of Oral and Maxillofacial Surgery, Bharati Vidyapeeth Deemed University, Dental College and Hospital, Pune
2. Bharati Hospital, Pune.

Inclusion Criteria

1. Patient's age: 18 years and/or above, male/female
2. Follow-up: <6 months
3. Alveolar bone dimensions (< 9 mm in length)
4. D1, D2, D3 quality of bone
5. Patients without willingness to accept vertical bone augmentation
6. Patients demonstrating good general health with no local or systemic contraindications to oral surgery and implant placement.

Exclusion Criteria

1. Poorly motivated or patients unable to keep the follow-up.
2. Chronic smokers and alcohol abuse
3. Severe intermaxillary skeletal discrepancy
4. Bruxism or TMJ dysfunction.
5. Radiotherapy to the head and neck region for malignancy. (Radiotherapy = 50 Gy)
6. Comorbidity ASA category = III, systemic uncontrolled disease or patients under the medication of intravenous bisphosphonate with significant risk of developing osteoradionecrosis
7. Pregnancy.

MegaISQ utilizes the RFA technology which was originally developed by Osstell.[15] The system [Figure 1] comprises (1) A small L-shaped transducer (SmartPeg) that is tightened to the implant or abutment by a screw, and (2) a handheld probe (3) a display monitor.

The SmartPeg is a small, precision-crafted metal rod that should be assembled with the implant or abutment while a measurement is being performed. It's easy to mount and requires minimal space in the patient's mouth. It is for a single-use. In non-homogenous bone, the SmartPeg automatically resonates in two perpendicular directions - thus providing a value for the highest as well as the lowest stability direction of the implant. It comprises two ceramic elements, one of which is vibrated by a sinusoidal signal (5–15 kHz) while the other serves as a receptor. The

Figure 1: MegaGen ISQ Machine

hand-held probe stimulates the SmartPeg magnetically. An ISQ value is generated and shown on the display [Figure 2]. It reflects the level of stability on the universal ISQ scale from 1 to 100. The higher the ISQ value, the more stable the implant, stronger the bone-implant interface [Figure 3]. It provides plan for postsurgical placement of the implant. RFA has emerged as a useful tool in clinical assessment of osseointegration and prognostic evaluation.[16,17]

Originally, 13 patients were included to be in this prospective experimental study, two of whom were not allowed to participate further as the Insertion Torque Value was achieved to be lower than 25 Ncm and one patient could not be followed up after the implant placement at the first appointment. Ten patients have been a part of this study [Table 1].

Variables such as single operator's surgical technique, the limited numerosity of the sample, and the choice of the surgical site (limited to the posterior mandible) must be taken into account.

Some of the confounding factors that may affect implant stability measurement are patient-specific characteristics (age, sex, bone quality and bone-healing capacity, general health condition, and habits), and implant-related (implant location, design, geometry, and thread exposure).

RESULTS

Of the ten patients included in the study, five were male and five were female [Figure 4]. All patients were between the ages of 50–75 years, with edentulous sites in the mandibular posterior region [Figure 5]. Bone density of these edentulous sites was either D2 or D3 [Figure 6]. Short implants placed were all of the height 7 mm and varying diameters ranging from 3.5mm to 5.5mm [Figure 7]. Statistical software used was SPSSv20, and level of significance was kept at 5%.

At buccolingual direction, there was an increase in implant stability quotient from S0 to S1 and this difference was

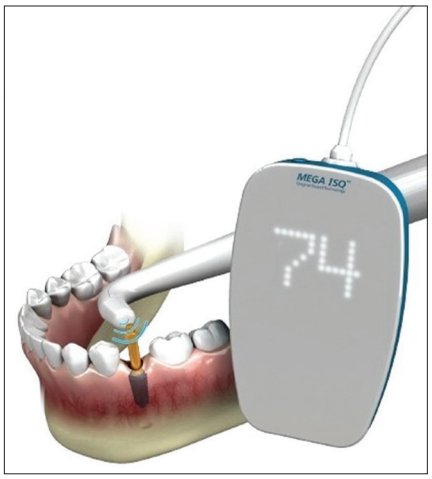

Figure 2: Hand-held probe stimulating the SmartPeg that is attached to the implant magnetically

Figure 3: ISQ Value Interpretation Chart (As provided by MegaGen)

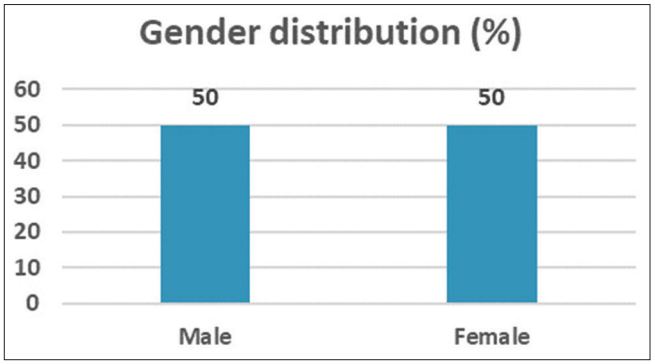

Figure 4: Graph showing the distribution in the gender of the subjects in this study

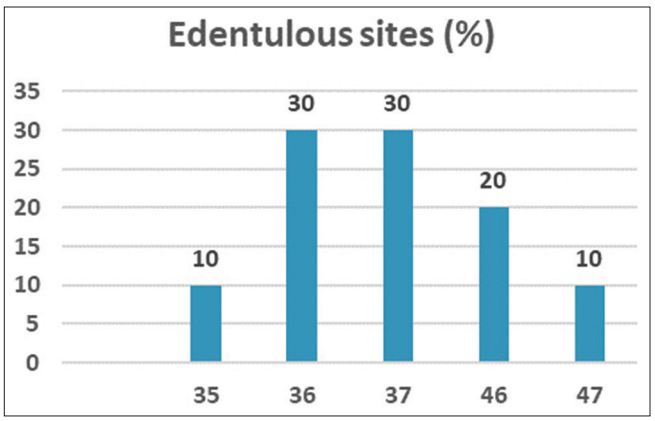

Figure 5: Graph showing the distribution in edentulous sites of the subjects in this study

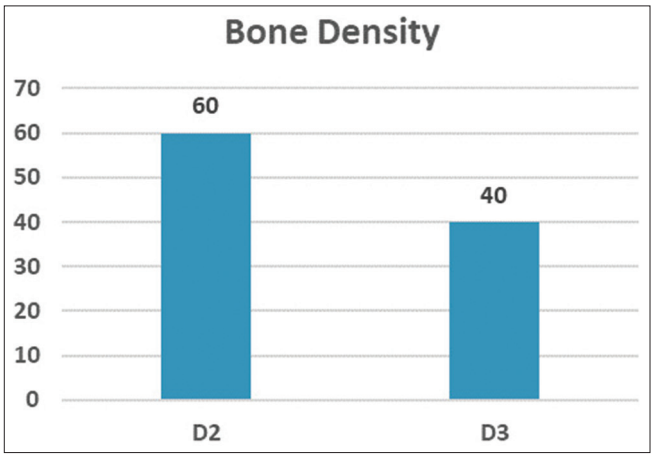

Figure 6: Graph showing the distribution in bone density of the edentulous sites in this study

significant. At apical direction, there was an increase in implant stability quotient from S0 to S1 and this difference was significant [Figure 8].

It was observed that short implants have an average of 59.7 ISQ (when measured buccolingually) and 61.2 ISQ (when measured apically) recorded immediately after implant placement and an average value of 80.6 ISQ (when measured buccolingually) and 79.3 ISQ (when measured apically) 3 months later at the time of placing healing abutment.

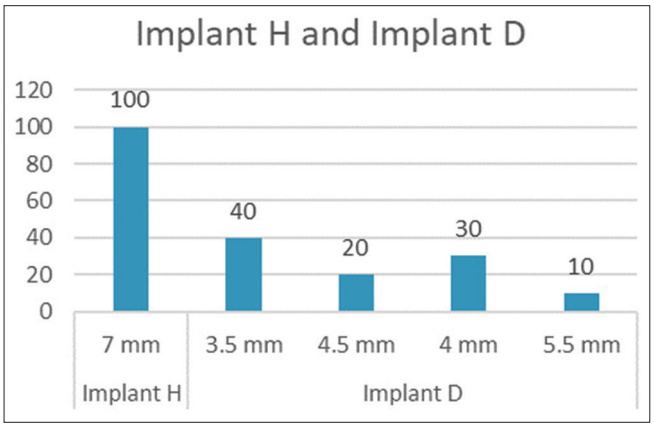

Figure 7: Graph showing the distribution in the dimensions of the implants laced in this study

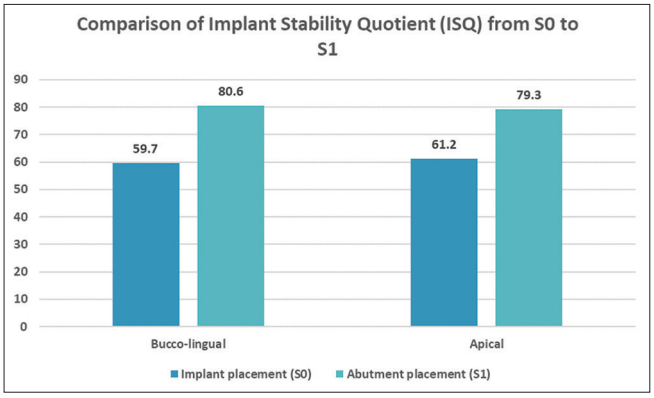

Figure 8: Graph showing the increase in implant stability from the time of implant placement to the time of abutment placement, measured in buccolingual as well apical directions

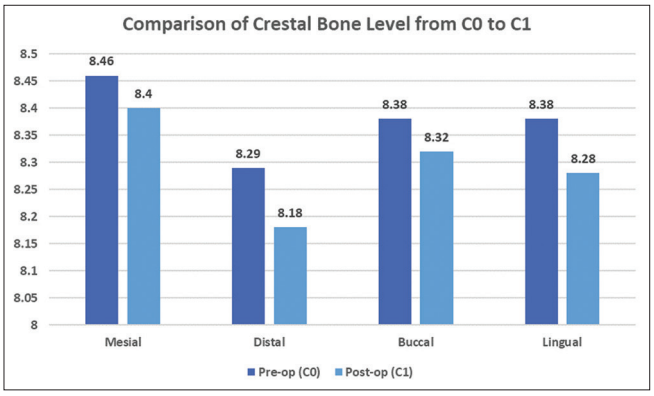

Figure 9: Graph showing the decrease in crestal osseous level from the time of implant placement to the time of abutment placement, measured in 4 aspects of the implant i.e. mesial, distal, buccal, lingual

The increase in stability according to ISQ tester when measured buccolingually is by 20.9 ISQ, and when measured apically is by 18.1 ISQ [Table 2].

The mean crestal osseous changes from the time before the implants were placed to the time of abutment placement was 0.06 mm on the buccal aspect, 0.11 on distal aspect, 0.06 mm on the mesial, and 0.10 mm on the lingual aspect of the bone around the implant [Figure 9]. There was a non-significant reduction in crestal bone level at all the sides [Table 3-5].

DISCUSSION

The use of conventional length implants has been defended based on the principle they would exhibit higher survival rates and hence, more favorable prognosis.[2] However, several recent studies have consistently showed that short dental implants pose no more of a risk of failure compared to longer implants.[5,18,19]

Finite element analysis performed by Pierrisnard *et al.* showed that maximum stress in the implant area was largely independent of the implant length.[10,11] Some important factors noted throughout literature that affect survival rates of short implants are bone quality and quantity, CI ratio, surface topography of the implant, prosthesis type, occlusal/parafunctional loads, and splinting to other implants, diameter and length of the implant, and overheating during surgical preparation.[20,21] Furthermore, additional influences such as systemic factors, smoking

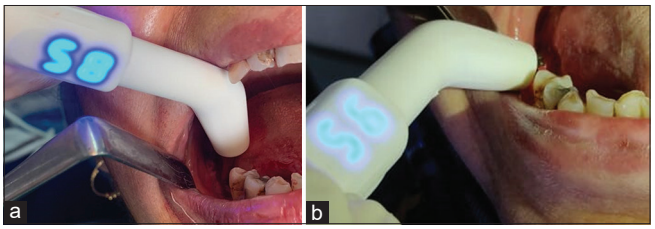

Figure 10: (a and b) Measurement of implant stability using the handheld probe at the time of implant placement

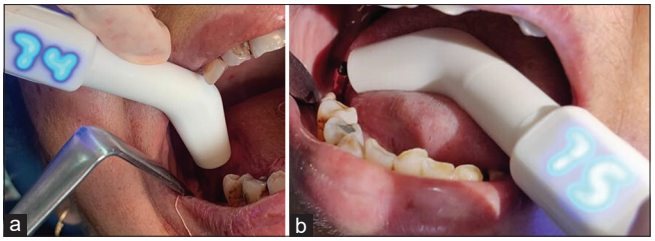

Figure 11: (a and b) Measurement of implant stability using the handheld probe at the time of abutment placement

Table 1*: Implant stability quotient values of 10 subjects using Implant Stability Tester

Sr. No.	Pt Details	Edentulous Site	Implant H (mm)	Implant D (mm)	Bone Density	S_0 BL	S_0 A	S_1 BL	S_1 A	S_2 BL	S_2 A
1.	56y/F	46	7	4	D2	56	58	75	74	19	16
2.	46y/M	37	7	4	D3	62	66	86	83	24	17
3.	54y/M	36	7	4.5	D2	60	67	87	89	27	22
4.	52y/M	37	7	5.5	D3	58	54	78	76	20	22
5.	48y/F	36	7	3.5	D2	67	61	83	84	16	23
6.	51y/F	35	7	3.5	D2	53	59	80	78	27	19
7.	53y/M	36	7	3.5	D2	60	64	89	73	29	09
8.	53y/M	37	7	4	D2	55	51	64	65	09	14
9.	59y/F	46	7	3.5	D3	62	62	83	85	21	23
10.	62y/M	47	7	4.5	D3	64	70	81	86	17	16

*Measured at the time of implant (So) and abutment placement (S1) in apical (A) and buccolingual directions (BL)

Table 2*: Increase in implant stability quotient value from the time of implant placement (S0) to abutment placement (S1)

	Implant placement (S_0)	Abutment placement (S_1)	Difference	t value	p value
BL	59.70±4.07	80.60±6.82	–20.90	–10.133	0.001**
A	61.20±5.60	79.30±7.01	–18.10	–12.8	0.001**

*Comparison of implant stability quotient from S_0 to S_1. Paired *t*-test; **Indicates significant difference at $P \leq 0.05$

habits, and implant placement in host versus grafted bone have also been observed to be contributing factors [Figures 10 and 11]. Östman *et al.*[22] discovered higher stability with increased implant width yet diminishing stability with increasing implant length.

Successful osseointegration from the clinical standpoint is a measure of implant stability, which occurs after implant integration. Primary stability refers to the mechanical engagement of an implant with the surrounding bone, whereas bone regeneration and remodeling phenomena determine the secondary (biological) stability of the implant. A secure primary stability has been noted to be positively associated with a secondary stability. Bone quantity and quality, implant geometry, and surgical technique adopted are some of the clinical factors that affect implant stability.[12] It was hypothetized that primary stability may be more difficult to achieve with short implants due to decreased bone-implant contact.[23] The contact area is determined by length, taper, diameter, and the surface texture.[24] Therefore, osseointegration of the bone-implant interface has been suggested to be increased using wide-diameter or rough-surface implants.[6,25]

Meredith *et al.*,[13] and Sennerby and Meredith[14] were the first to propose RFA as a highly effective qualitative method to assess implant stability. In 2000, the results of a study on the biological, biomechanical, and clinical aspects of measuring implant stability by RFA were reported. The stability of various types of implants as well as their behavior under different bone and loading conditions can be analyzed quantitatively and qualitatively using the RFA.[26]

Alonso *et al.*[27] assessed the effect of bone quality on the primary and secondary stability of 39 single short implants (4.1 × 6-mm long) placed in the posterior region of the maxilla or mandible in 18 patients. The mean ISQ values were higher at abutment installation than at implant placement ($P < 0.05$), regardless the bone type. They concluded that bone quality influences both the primary and secondary stability of single short implants in the posterior region.

Kim *et al.*[28] evaluated the clinical prognoses of 46 short implants (7-mm long) in the mandible of 20 study subjects. Primary and secondary implant stability, and marginal bone loss, and peri-implant soft-tissue index 12 months after the final prosthetic delivery were assessed. The short implants in this study categorized as Group 1 (Two-stage and submerged placement) and Group 2 (One-stage and non-submerged placement). The authors of this study found no statistically significant differences in the primary and secondary stability between the two groups ($P > .05$).

Balleri *et al.*[29] studied stability of 45 implants were placed in 14 patients after 1 year of loading, using RFA measurements using Osstell (Integration Diagnostics, Savedalen, Sweden) after 1 year of loading. Implant stability levels were in the range of 57–82 ISQ units. No correlation could be found between implant length and stability, and only minor marginal bone resorption was observed.

Marginal bone loss is considered a biological complication[30] and a consistent parameter to rate the success of an implant.[31] The success criteria proposed by Albrektsson *et al.*[32] states MBL as the first parameter, wherein an implant losing 1 mm MBL after the 1st year of implant placement and 0.2 mm in the following years was considered successful.[33] Studies across literature have shown a great range of values with mean marginal bone loss varying from 0 to 2 mm after 1-year follow-

Table 3*: Crestal osseous level values of 10 subjects at the time of implant placement (C0)

Sr. No.	Pt Details	Edentulous Site	Implant H (mm)	Implant D (mm)	Bone Density	C_0			
						M	D	B	P
1.	56y/F	46	7	4	D2	8.91	8.49	8.64	8.25
2.	46y/M	37	7	4	D3	8.50	8.55	8.44	8.49
3.	54y/M	36	7	4.5	D2	8.68	7.37	8.82	8.98
4.	52y/M	37	7	5.5	D3	8.56	8.37	8.98	8.04
5.	48y/F	36	7	3.5	D2	8.63	8.08	7.79	8.64
6.	51y/F	35	7	3.5	D2	8.32	8.49	8.10	8.56
7.	53y/M	36	7	3.5	D2	8.19	8.68	8.55	8.36
8.	53y/M	37	7	4	D2	8.45	8.80	8.83	8.72
9.	59y/F	46	7	3.5	D3	8.47	8.74	8.35	8.19
10.	62y/M	47	7	4.5	D3	7.98	7.33	7.30	7.56

*Evaluation of Crestal Bone Levels using Cone-beam computed tomography at the time of implant placement (Co)

Table 4*: Crestal osseous level values of 10 subjects at the time of abutment placement (C1)

Sr. No.	Pt Details	Edentulous Site	Implant H (mm)	Implant D (mm)	Bone Density	C_1			
						M	D	B	L
1.	56y/F	46	7	4	D2	8.58	8.23	8.29	8.20
2.	46y/M	37	7	4	D3	8.74	8.19	8.06	8.04
3.	54y/M	36	7	4.5	D2	8.39	7.30	8.34	8.69
4.	52y/M	37	7	5.5	D3	8.25	8.57	8.59	8.99
5.	48y/F	36	7	3.5	D2	8.35	8.44	7.53	8.35
6.	51y/F	35	7	3.5	D2	7.93	8.14	8.31	8.06
7.	53y/M	36	7	3.5	D2	8.42	8.36	8.24	8.13
8.	53y/M	37	7	4	D2	8.17	8.47	8.58	8.59
9.	59y/F	46	7	3.5	D3	8.25	8.42	8.09	8.47
10.	62y/M	47	7	4.5	D3	7.70	7.69	7.07	7.30

*Evaluation of crestal bone levels using cone-beam computed tomography at the time of abutment placement (C1)

Table 5*: Decrease in crestal osseous level values from the time of implant placement (C0) to abutment placement (C1)

	Pre-op (C_0)	Post-op (C_1)	Difference	t value	p value
Mesial	8.46±0.26	8.40±0.25	0.06	1.194	0.263 (NS)
Distal	8.29±0.54	8.18±0.40	0.11	1.143	0.283 (NS)
Buccal	8.38±0.52	8.32±0.50	0.06	2.045	0.071 (NS)
Lingual	8.38±0.40	8.28±0.46	0.10	0.717	0.492 (NS)

*Comparison of Crestal Bone Level from C_0 to C_1. Paired *t*-test; NS: Non-significant

up. These differences may be attributed to the limits used as a reference to measure the marginal bone loss or the placement of the implants at different levels of the crestal bone.[32,34,35]

The initial bone loss occurring during the 3 months after placement can be explained as result of early remodeling. Nonetheless, in a study performed by Isidor,[36] a bone gain occurred after the implants were loaded. Most of the peri-implant bone loss changes occur during the 1st year after implant placement.[32,36,37]

Zadeh *et al.*[38] compared the marginal bone loss (MBL) changes and survival of 6- and 11-mm implants in 95 patients receiving a total of 209 dental implants. Radiographic assessment of marginal bone loss (MBL) 3 years after loading revealed the MBLs for test and control groups were significantly different in favor of short implants. The cumulative survival rates from placement after 3 years were 96% and 99% for the 6- and 11- mm implants, respectively, with no statistical significance.

Anitua *et al.*'s[39] study evaluated the influence of CI on marginal bone loss (MBL) in 168 short implants (<8.5 mm in length) placed in posterior areas of maxilla and mandible of 63 patients. The data were split into two groups according to the value of CI ratio (CI <2 and CI ≥2). 86 implants (67.2%) had a CI ratio of <2, whereas it was ≥2 in 42 implants (32.8%). The study concluded that CI ratio had not a significant influence on MBL.

A study by Nunes *et al.*[40] evaluated the influence of CI in implants on MBL using Periapical radiographs considering 111 dental implants measuring 4 × 7 mm in 59 patients, in function for 36 months. A weak non-significant correlation was registered between CI and MBL.

The deficiency of this prospective study lies in a small sample size, and lack of long-term follow-up. In addition to inconsistencies across literature regarding the definition of short implants, dearth of data assessing the stability and crestal osseous changes of short implants necessitates further trials involving a larger sample size.

SUMMARY AND CONCLUSION

Our study suggests that short implants may prove to be a reliable and predictable alternative to conventional implants at edentulous sites with reduced alveolar height. Short implants will reduce the number of surgical interventions, total treatment time, and expenses related to augmentation procedures involving increase in alveolar height. Our prospective study used the most accurate methods available today to objectively measure implant stability as well as osseous crestal changes in the peri-implant region. Although the results of our study are encouraging, the small sample size, the lack of exposure of short implants to masticatory loads, and the limited duration of our study limits the significance of our study. This necessitates further clinical research in this aspect of dental implantology.

REFERENCES

1. Esposito M, Hirsch JM, Lekholm U, Thomsen P. Biological factors contributing to failures of osseointegrated oral implants. (1) Success criteria and epidemiology. Eur J Oral Sci 1998;106:527-51.
2. Chiapasco M, Zaniboni M. Methods to treat the edentulous posterior maxilla: Implants with sinus grafting. J Oral Maxillofac Surg 2009;67:867-71.
3. Lee JH, Frias V, Lee KW, Wright RF. Effect of implant size and shape on implant success rates: A literature review. J Prosthet Dent 2005;94:377-81.
4. Birdi H, Schulte J, Kovacs A, Weed M, Chuang SK. Crown-to-implant ratios of short-length implants. J Oral Implantol 2010;36:425-33.
5. Wyatt CC, Zarb GA. Treatment outcomes of patients with implant supported fixed partial prostheses. Int J Oral Maxillofac Implants 1998;13:204-11.
6. Kotsovilis S, Fourmousis I, Karoussis IK, Bamia C. A systematic review and meta-Analysis on the effect of implant length on the survival of rough-surface dental implants. J Periodontol 2009;80:1700-18.
7. Carr B. Survival of short implants is improved with greater implant length, placement in the mandible compared with the maxilla, and in nonsmokers. J Evid Based Dent Pract 2012;12:18-20.
8. Romeo E, Bivio A, Mosca D, Scanferla M, Ghisolfi M, Storelli S. The use of short dental implants in clinical practice: Literature review. Min Stomatol 2010;59:23-31.
9. Telleman G, Raghoebar GM, Vissink A, den Hartog L, Slater JJ, Meijer HJ. A systematic review of the prognosis of short (<10 mm) dental implants placed in the partially edentulous patient. J Clin Periodontol 2011;38:667-76.
10. Shah AK. Short implants when, where and how? J Int Clin Dent Res Organ 2015;7:132-7.
11. Pierrisnard L, Renouard F, Renault P, Barquinis M. Influence of implant length and bicortical anchorage on implant stress distribution. Clin Implant Dent Relat Res 2003;5:254-62.
12. Javed F, Ahmed HB, Crespi R, Romanos GE. Role of primary stability for successful osseointegration of dental implants: Factors of influence and evaluation. Intervent Med Appl Sci 2013;5:162-7.
13. Meredith N, Shagaldi F, Alleyne D, Sennerby L, Cawley P. The application of resonance frequency measurements to study the stability of titanium implants during healing in the rabbit tibia. Clin Oral Implants Res 1997;8:234-43.
14. Sennerby L, Meredith N. Resonance frequency analysis: Measuring implant stability and osseointegration. Compend Contin Educ Dent. 1998;19:493-504.
15. Blázquez-Hinarejos M, Saka-Herrán C, Diez-Alonso V, Ayuso-Montero R, Velasco-Ortega E, López-López JA. Reliability and agreement of three devices for measuring implant stability quotient in the animal *ex vivo* model. *Appl Sci* 2021;*11*:3453.
16. Swami V, Vijayaraghavan V, Swami V. Current trends to measure implant stability. J Indian Prosthodont Soc 2016;16:124-30.
17. Mall N, Dhanasekar B, Aparna IN. Validation of implant stability: A measure of implant permeance. Indian J Dent Res 2011;22:462-7.
18. Atieh MA, Zadeh H, Stanford CM, Cooper LF. Survival of short dental implants for treatment of posterior partial edentulism: A systematic review. Int J Oral Maxillofac Implants 2012;27:1323-31.
19. Szmukler-Moncler S, Bernard JP. Short Implants in the Posterior Region. Films, Swizerland: Proceedings of the Annual ITI Meeting; 1999.
20. Anitua E, Orive G, Aguirre JJ, Andía I. Five-year clinical evaluation of short dental implants placed in posterior areas: A retrospective study. J Periodontol 2008;79:42-8.
21. Romeo E, Chiapasco M, Ghisolfi M, Vogel G. Long-term clinical effectiveness of oral implants in the treatment of partial edentulism. Seven-year life table analysis of a prospective study with ITI dental implants system used for single-tooth restorations. Clin Oral Implants Res 2002;13:133-43.
22. Ostman PO, Hellman M, Wendelhag I, Sennerby L. Resonance frequency analysis measurements of implants at placement surgery. Int J Prosthod 2006;19:77-83; discussion 84.
23. Kennedy KS, Jones EM, Kim DG, McGlumphy EA, Clelland NL. A prospective clinical study to evaluate early success of short implants. Int J Oral Maxillofac Implants 2013;28:170-7.
24. Morand M, Irinakis T. The challenge of implant therapy in the posterior maxilla: Providing a rationale for the use of short implants. J Oral Implantol 2007;33:257-66.
25. Mertens C, Meyer-Bäumer A, Kappel H, Hoffmann J, Steveling HG. Use of 8-mm and 9-mm implants in atrophic alveolar ridges: 10-year results. Int J Oral Maxillofac Implants 2012;27:1501-8.
26. Chung S, McCullagh A, Irinakis T. Immediate loading in the maxillary arch: Evidence-based guidelines to improve success rates: A review. J Oral Implantol 2011;37:610-21.
27. Alonso FR, Triches DF, Mezzomo LA, Teixeira ER, Shinkai RS. Primary and secondary stability of single short implants. J Craniofac Surg 2018;29:e548-51.
28. Kim YK, Yun PY, Yi YJ, Bae JH, Kim SB, Ahn GJ. One-year prospective study of 7 mm long implants in mandible: Installation technique and crown/implant ratio of 1.5 or less. J Oral Implantol 2015;41:e30-5.
29. Balleri P, Cozzolino A, Ghelli L, Momicchioli G, Varriale A. Stability measurements of osseointegrated implants using Osstell in partially edentulous jaws after 1 year of loading: A pilot study. Clin Implant Dent Relat Res 2002;4:128-32.
30. Pjetursson BE, Tan K, Lang NP, Brägger U, Egger M, Zwahlen M. A systematic review of the survival and complication rates of fixed partial dentures (FPDs) after an observation period of at least 5 years. Clin Oral Implants Res 2004;15:667-76.
31. Mericske-Stern R, Oetterli M, Kiener P, Mericske E. A follow-up study of maxillary implants supporting an overdenture: Clinical and radiographic results. Int J Oral Maxillofac Implants 2002;17:678-86.
32. Albrektsson T, Zarb G, Worthington P, Eriksson AR. The long-term efficacy of currently used dental implants: A review and proposed criteria of success. Int J Oral Maxillofac Implants 1986;1:11-25.
33. Thoma DS, Haas R, Sporniak-Tutak K, Garcia A, Taylor TD, Hämmerle CH. Randomized controlled multicentre study comparing short dental implants (6 mm) versus longer dental implants (11-15 mm) in combination with sinus floor elevation procedures: 5-Year data. J Clin Periodontol 2018;45:1465-74.
34. Corrente G, Abundo R, Cardaropoli D, Cardaropoli G, Martuscelli G. Long-term evaluation of osseointegrated implants in regenerated and nonregenerated bone. Int J Periodontics Restorative Dent 2000;20:390-7.
35. Perelli M, Abundo R, Corrente G, Saccone C. Short (5 and 7 mm long) porous implant in the posterior atrophic mandible: A 5-year report of a prospective study. Eur J Oral Implantol 2011;4:363-8.
36. Nielsen HB, Schou S, Isidor F, Christensen AE, Starch-Jensen T. Short implants (≤8 mm) compared to standard length implants (>8 mm) in conjunction with maxillary sinus floor augmentation: A systematic review and meta-analysis. Int J Oral Maxillofac Surg 2018;48:239-49.
37. Insua A, Monje A, Wang HL, Miron RJ. Basis of bone metabolism around dental implants during osseointegration and peri-implant bone loss. J Biomed Mater Res Part A 2017;105:2075-89.
38. Zadeh HH, Guljé F, Palmer PJ, Abrahamsson I, Chen S, Mahallati R, *et al*. Marginal bone level and survival of short and standard length implants after

3 years: An open multi-center randomized controlled clinical trial. Clin Oral Impl Res 2018;29:894-906.
39. Anitua E, Piñas L, Begoña L, Orive G. Long-term retrospective evaluation of short implants in the posterior areas: Clinical results after 10-12 years. J Clin Periodontol 2014;41:404-11.
40. Nunes M, Almeida R, Felino A, Maló P, De Araújo Nobre M. The influence of crown-to-implant ratio on short implant marginal bone loss. Int J Oral Maxillofac Implants 2016;31:1156-63.

How to cite this article: Mishra P, Kshirsagar R, Warade P. Evaluation of Primary and Secondary Stability and Crestal Osseous Changes in Short Implants: A Prospective Clinicoradiograhic Study. Int J Sci Stud 2021;9(9):113-120.

Source of Support: Nil, **Conflicts of Interest:** None declared.

Print ISSN: 2321-6379
Online ISSN: 2321-595X

Original Article

Comparison of Surgical Incision Outcome in Scalpel Incisions and High Frequency Electrocautery in a Tertiary Care Hospital

B M Pavan[1], Meghana Manjunath[2], T Nandini[3], T Indushree[4], T Shivakumar[1], G N Prabhakara[1], S Srinath[1]

[1]Professor, Department of Surgery, Sri Siddhartha Medical College, Tumkur, Karnataka, India, [2]Medical Student, Department of Surgery, Sri Siddhartha Medical College, Tumkur, Karnataka, India, [3]Associate Professor, Department of Pharmacology, Sri Siddhartha Medical College, Tumkur, Karnataka, India, [4]Assisstant Professor, Department of Pharmacology, Sri Siddhartha Medical College, Tumkur, Karnataka, India

Abstract

Introduction: Scalpels have been the gold standard for skin incisions despite having disadvantages like lack of hemostasis which can be overcome with the use of electrocautery. Since, its introduction elctrocautery has been indispensible in the operating room. Despite this major advantage of electrocautery, beliefs exist that it can cause devitalization of tissues leading to wound infection, delayed wound healing and scar formation.

Purpose: The purpose of this study is to evaluate the efficacy of electrocautery over scalpel in making skin incisions.

Materials and Methods: Eighty cases requiring surgical incisions were enrolled and divided into two groups- scalpel group and electrocautery group. Post-operatively the two groups were compared on the basis of intra-operative bleeding, pain, complications, and scar formation.

Results: There was no significant difference in pain, 6 h post-operatively, between the two groups. While, intra-operative bleeding and complications like serous discharge was found to be more in the scalpel group. Skin incisions made with electrocautery produced cosmetically acceptable scar.

Conclusion: Skin incisions with high frequency electrocautery are more advantageous than using a traditional scalpel for the same.

Key words: Electrocautery, Post-operative complications, Scalpel incisions

INTRODUCTION

The first surgery using electrocautery was performed by Dr. Harvey Cushing in 1926. Ever since, irrespective of the procedure, electrosurgical instruments have become indispensible in the operating room.[1] Before this, scalpel was considered the gold standard for surgical incisions, but it came with its own set of disadvantages. Electrosurgical instruments like high frequency electric knife, obviates these inherent disadvantages of scalpel, that is, lack of hemostasis, accidental injury to surgeon, infection risk, pain, fear of burns, and scarring.[2,3]

Access this article online

www.ijss-sn.com

Month of Submission : 10-2021
Month of Peer Review : 11-2021
Month of Acceptance : 11-2021
Month of Publishing : 12-2021

Numerous studies have been done that shows benefits of use of electrocautery in skin incision.[4-7] This study was done to assess the same by comparing outcome of electrosurgical and scalpel incision.

MATERIALS AND METHODS

A prospective study was conducted under surgery department of a tertiary care hospital. 80 cases requiring surgical intervention (hernia, thyroid, varicose veins, and fibroadenoma) were enrolled for the study which was done during the period of June 2015 to October 2016 following ethics committee approval.

Patients between 18 and 60 years of age, requiring all clean wound surgery cases were included following Informed consent. Clean contaminated and complicated cases and those with severe/uncontrolled comorbid medical conditions (severe hepatic/renal/cardiovascular

Corresponding Author: Meghana Manjunath, NRI Girls Hostel, Sri Siddhartha Medical College, Tumkur, Karnataka, India.

dysfunction, diabetes mellitus, hypertension, and immunocompromised status) were excluded from the study.

The 80 study subjects were then randomized into two groups, that is, Group A and Group B each containing 40 subjects. Where, Group A (study group) included skin incision made with electrocautery needle using pulse sine wave current and power setting of 70 watts and Group B (control group) included skin incision made with scalpel; bleeding controlled by forceps coagulation using pulse sine wave on power supply 30 watts. Hemostasis achieved with forceps coagulation.

The patient's characteristics of the two groups were well matched. All the procedures were carried out under standardized spinal/general anesthesia according to the procedure. Intravenous Cefotaxime 1 g was given 2 h before procedure and just before incision as a premedication.

Post-operative pain was measured using pictorial visual analog scale at 6, 12, 24, and 48 h.[4] If pain score was more than 4, injection Diclofenac 50 mg intramuscular was given.

Pain Score Cautery Group

- 5 ± 1(moderate) pain score experienced in first 6 h post op
- 3 ± 1(mild) pain score experienced in 12 h
- 0 ± 1 pain score is experienced in 24–48 h.

Pain Score in Scalpel Group

- 7 ± 1 (severe) pain score experienced in first 6 h
- 4 ± 1(moderate) pain score experienced in 12 h
- 2 ± 1(mild) pain score experienced in 24 h
- 1 (mild) pain experienced even after 48 h in scalpel group.

Bleeding at the time of incision was observed. Post-operative complications were noted during hospital stay and measured. At 1 month post-operative period, surgical scars were evaluated by using the Vancouver scar scale (VSS) to evaluate the cosmesis of the scar.[6]

The results were finally analyzed and compared for the two groups using Mann-Whitney U Test in Quasi Experimental study and percentage and type of complication at incision site were noted.

RESULTS

The age of the patients varied from 20 to 60 years. Maximum number of cases belonged to the age group of 30–60 years. The mean age in study group was 40.4 ± 8.58 years and in control group was 41.8 ± 10.6 years. In both study and control group, males were predominant that is 76.67% of the patients while 23.33% were female [Table 1].

Comparison of post-operative pain between scalpel group and cautery group was done by visual analogue scale. Larger difference in average pain score among cautery group and scalpel group was seen at 6 h, 5 ± 1 and 7 ± 1, respectively. Overall, patients in cautery group had less pain than those in scalpel group [Table 2].

Intra-operative bleeding at time of incision as observed by the surgeon was seen to be more in scalpel group than the cautery group. In the cautery group, bleeding was minimal to absent.

There were no major complications in either group. Patients with minor complications, like serous fluid collection, were seen. There were 04 (7.2 %) such patients in cautery group with average discharge of 5 ml and 22 (60.6 %) patients with an average of 15 ml serous discharge in scalpel group [Table 3].

Table 1: Age and sex distribution

	Scalpel	Cautery
No of patients	40	40
Range of age in years	20–60	20–60
Male: Female ration	31:9	3:1
Age Distribution		
Age in years		
20–30	6	8
30–40	19	12
40–60	15	20
Total	40	40

Table 2: Post-operative pain assessed using visual analogue scale

Pain score	Cautery	Scalpel
6 h	5±1	7±1
12 h	3±1	4±1
24 h	1±1	2±1
48 h	0	1

Table 3: Post-operative complications

	Post-operative discharge from wound	
	Cautery	Scalpel
Collection in wound		
Present	4	22
Absent	36	18
Discharge type	Serous	Serous
Amount	5ml	15 ml
Infection	Nil	Present
Total	40	40

One-month post-operative scar was assessed using the VSS. All cases from cautery group healed by primary intention while two cases of scalpel group healed by secondary intention. In scalpel group, two cases of hypopigmentation and six cases of hyperpigmentation were seen whereas only of each were seen in the cautery group [Table 4].

DISCUSSION

Scalpels have been considered as the gold standard for making surgical incisions as it allowed surgeons to make incision of desired depth without damaging neighboring tissues.[8,9] Scalpel use came with a number of disadvantages like lack of hemostasis, accidental injury to surgeon, risk of infection, and pain.[2-4] Electrocautery obviates these drawbacks of scalpel and also reduces intra-operative time, avoids use of foreign material (ligatures), and potential for tumor metastasis through lymphatic channels.[10] Electrocautery is mainly used for hemostasis and less often for skin incision due to the belief that electrosurgical instruments can cause devitalization of tissue which can subsequently lead to wound infection, delayed wound healing and scar formation.[5] Numerous studies were undertaken to evaluate the efficacy of electrocautery over scalpel in making skin incision and the results were varying.

According to, systematic review and meta-analysis of cutting diathermy versus scalpel for skin incision, which included 416 cases in electrocautery group and 414 in the scalpel group, there was no significant difference in post-operative scores at 24 h.[11] Even in our study, at 24 h, there was no noteworthy difference. Although in our study, we did note a larger difference in average score for pain at 6 h [Table 2].

In our study, intra-operative bleeding assessment was based on observation by the surgeon, according to which bleeding was significantly lesser among the electrocautery group when compared to scalpel group. Similar results were seen in studies by Ly *et al.* and Siraj *et al.*[11,12]

Table 4: Post-operative scar assessment

	Scar score in 1 month post-operative	
	Cautery	Scalpel
Vascularity	Normal	Normal
Pigmentation		
Normal	38	32
Hypopigmentation	1	2
Hyperpigmentation	1	6
Pliability	normal	normal
Height	flat	Flat<2 mm in 3 cases
Primary intension	40	38
Secondary intension	0	2

As mentioned earlier, no major complications were seen in either of the groups. Minor complications, like serous fluid collection, were seen more in the scalpel group with respect to both incidence and amount of fluid collected [Table 3]. A similar result was obtained in a study by Priya *et al.* in Maharashtra, India.[13]

Post-operative scar assessment in our study found not much of a significant difference in electrocautery and scalpel group [Table 4]. Comparable results were reported by Kumar *et al.* and Priya *et al.*[9]

Numerous studies done suggested that wounds created with electrocautery have reduced tensile strength, increased infection rate and a bigger zone of wound necrosis than those made with scalpel. This assumption was squashed by a multicenter collaborative trial that was conducted in 2001, included 964 patients found no difference in rate of wound complications between scalpel and electrocautery use.[11]

CONCLUSION

Skin incisions made with electrocautery are quicker and associated with less bleeding than those by scalpel. It is also a cosmetically acceptable technique. Use of electrocautery shows no increased risk of infection and also has benefits with respect to post-operative pain. All of this along with safety advantage to the surgeon makes electrocautery an attractive option.

ACKNOWLWDGMENT

We would like to extend our gratitude to Sri Siddhartha Medical College and Hospital for supporting and providing us the platform for this study to be successful.

REFERENCES

1. Prakash LD, Balaji N, Kumar SS, Kate V. Comparison of electrocautery incision with scalpel incision in midline abdominal surgery-a double blind randomized controlled trial Int J Surg 2015;19:78-82.
2. Glover JL, Bendick PJ, Link WJ. The use of thermal knives in surgery: Electrosurgery, lasers, plasma scalpel. Curr Probl Surg 1978;15:1-78.
3. Murthy SM, Goldschmidt RA, Rao LN, Ammitati M, Buchmann T, Scanlon EF. The influence of surgical trauma on experimental metastasis. Cancer 1989;64:2035-44.
4. Kearns SR, Connoly EM, McNally S, McNamara DA, Deasy J. Randomized clinical trial of diathermy versus scalpel incision in elective midline laparotomy. Br J Surg 2001;88:41-4.
5. Johnson CD, Serpell JW. Wound infection after abdominal incision with scalpel or diathermy. Br J Surg 1990;77:626-7.
6. Gupta AK, Dall TS, Bansal D. A prospective study of diathermy versus scalpel skin incision in abdominal surgery. Int Surg J 2019;6:3554-8.
7. Wilson AP, Gibbons C, Reeves BC, Hodgson B, Liu M, Plummer D, *et al*. Surgical wound infection as a performance indicator: Agreement of common

definitions of wound infection in 4773 patients. BMJ 2004;25:720-4.
8. Sharma N, Chauhan A, Sharma V, Gupta A, Pathania S. Harmonic scalpel, the tool for new age laparoscopic cholecystectomy. Int Surg J 2018;5:2327-30.
9. Shahmoradi MK, Mehri J, Taheri HR. Comparison of hemorrhoidectomy using harmonic scalpel and electrocautery: A randomized controlled trial. Int J Surg Open 2020;27:39-42.
10. Kumar V, Tewari M, Shukla HS. A comparative study of scalpel and surgical diathermy incision in elective operations of head and neck cancer. Indian J Cancer 2011;48:216-9.
11. Ly J, Mittal A, Windsor J. Systematic review and meta-analysis of cutting diathermy versus scalpel for skin incision. Br J Surg 2021;99:613-20.
12. Siraj A, Farooqdar M, Gilani AA, Raziq S. A study on comparison of diathermy and scalpel incisions in elective midline laparotomy. Prof Med J 2011;18:106-11.
13. Priya N, Lamture YR, Luthra L. A comparative study of scalpel versus surgical diathermy skin incisions in clean and clean-contaminated effective abdominal surgeries in AVBRH, Wardha, Maharashtra, India. J Datta Meghe Inst Med Sci Univ 2017;12:21-5.

How to cite this article: Pavan BM, Manjunath M, Nandini T, Indushree T, Shivakumar T, Prabhakara GN, Srinath S. Comparison of Surgical Incision Outcome in Scalpel Incisions and High Frequency Electrocautery in a Tertiary Care Hospital. Int J Sci Stud 2021;9(9):121-124.

Source of Support: Nil, **Conflicts of Interest:** None declared.

Print ISSN: 2321-6379
Online ISSN: 2321-595X

Original Article

High-resolution Computed Tomography Chest: A Preferred Modality Over Spirometry in Chronic Obstructive Pulmonary Disease among Smokers

Sanjay Kumar[1], Nilesh Gupta[2], C D Sahu[3], R K Panda[3], Savitri Thakur[4], S B S Netam[5]

[1]Associate Professor, Department of Radiodiagnosis, Pt. Jawahar Lal Nehru Memorial Medical College and Dr. Bhim Rao Ambedkar Memorial Hospital, Raipur, Chhattisgarh, India, [2]Assistant Professor, Department of Radiodiagnosis, Pt. Jawahar Lal Nehru Memorial Medical College and Dr. Bhim Rao Ambedkar Memorial Hospital, Raipur, Chhattisgarh, India, [3]Associate Professor, Department of Radiodiagnosis, Pt. Jawahar Lal Nehru Memorial Medical College and Dr. Bhim Rao Ambedkar Memorial Hospital, Raipur, Chhattisgarh, India, [4]Resident Department of Radiodiagnosis, Pt. Jawahar Lal Nehru Memorial Medical College and Dr. Bhim Rao Ambedkar Memorial Hospital, Raipur, Chhattisgarh, India, [5]Professor and HOD, Department of Radiodiagnosis, Pt. Jawahar Lal Nehru Memorial Medical College and Dr. Bhim Rao Ambedkar Memorial Hospital, Raipur, Chhattisgarh, India.

Abstract

Introduction: Chronic obstructive pulmonary disease (COPD) in smokers is a large burden among chest diseases. IT can be evaluated by spirometry, chest X-ray, and high-resolution computed tomography (HRCT) chest. Spirometry pulmonary function test (PFT) can be done as a screening test of COPD. PFT only tells the airflow limitation, both in restrictive and obstructive lung pathology. Chest radiographs are usually normal in milder forms. Although with the radiation exposure risk, HRCT chest is another modality that can be utilized, even in patients who are unfit for PFT.

Materials and Methods: We studied 100 smokers diagnosed with COPD initially by spirometry. Parameters of forced expiratory volume (FEV)1/forced vital capacity (FVC), FEV1 and FVC were observed. Subsequently, HRCT chest was done, who has been referred from chest outpatient department and variables of emphysema and bronchitis were looked upon – tracheal index (TI), thoracic cage ratio (TCR), sterno-aortic distance (SAD), hyperinflation, tubular heart, types of emphysema and mosaic attenuation. The minimum and maximum values in the data were also tabulated. Calculation of correlation, and their significance done. Data were analyzed with various scatter graph, pie charts, and correlations done using Karl Pearson's method. Descriptive statistics included calculation of mean, median, and standard deviation for various data including age distribution of the study population, range of FEV1, grading of severity of COPD as per global initiative for chronic obstructive lung disease 2019 Guidelines, HRCT parameters including.

Results: CT is more sensitive to diagnose milder forms of emphysema and to determine the type and its extent. Karl's Pearson's correlation results show that there is a high degree of positive correlation between TI and FEV1, moderate negative correlation between TCR and FEV1, high degree of negative correlation between SAD and FEV1 ($P < 0.001$). Using Chi-square test, TI has a moderate degree of positive correlation with FEV1/FVC with $P < 0.001$ HS.

Conclusion: In the present study, HRCT chest can be a great tool to evaluate the COPD at an early stage apart from the level of obstruction, extent of involvement, and characterizing the disease. PFT is not possible in uncooperative patients and less sensitive in early stages. HRCT chest is problem solving tool in such scenario and helps to reduce to disease burden by early intervention, thereby reducing the prevalence of terminal lung failure cases.

Key words: Chronic obstructive pulmonary disease, Emphysema, High-resolution computed tomography, Hyperinflation, Spirometry

Access this article online

www.ijss-sn.com

Month of Submission : 10-2021
Month of Peer Review : 11-2021
Month of Acceptance : 11-2021
Month of Publishing : 12-2022

INTRODUCTION

Smoking is the biggest risk factor for chronic obstructive pulmonary disease (COPD) which causes chronic inflammation and structural changes resulting from repeated injury and repair. Apart from chest X-ray,

Corresponding Author: Dr. Nilesh Gupta, Department of Radiodiagnosis, Pt. Jawahar Lal Nehru Memorial Medical College and Dr. Bhim Rao Ambedkar Memorial Hospital, HIG 68 Jainam Vihar Lalpur, Raipur, Chhattisgarh - 492001, India.

which usually shows insignificant findings in milder degree, Spirometry pulmonary function test (PFT) can be done as a screening test of COPD. PFT only tells the airflow limitation, both in restrictive and obstructive lung pathology. Furthermore, it helps in differentiating Asthma from COPD. Physiologic indices include forced expiratory volume (FEV), forced vital capacity (FVC), maximum mid-expiratory flow, residual volume, and nitrogen washout tests, to study the physiologic expression of lesions of the small airways (Petty *et al.* 1980, 1984, 1987). Progressive grades of emphysema were associated with reductions in FEV. The lesion of mucous gland hyperplasia (i.e., the Reid index; Reid 1960) did not have a close correlation with airflow measurements. Dynamic airway collapse of the central airways was related to reductions in FEV1. Another imaging modality is high-resolution computed tomography (HRCT) scan which helps to support the diagnosis of COPD or determine if the disease has worsened. CT images can identify emphysema better and at an earlier stage than a chest X-ray. They can also identify other changes of COPD such as enlarged arteries in the lungs. CT is sometimes used to measure the extent of emphysema within the lungs. It can also help determine if the symptoms are the result of another disease of the chest. Two phenotypes are seen on HRCT in patients of COPD-emphysema predominant disease and airways disease. Most common lung findings noted on the HRCT scan is emphysema. It is divided into three types: Centrilobular emphysema, Panlobular type and Paraseptal type.

"Bullous emphysema" is another variant larger than 1 cm. COPD is a highly heterogenous disease in terms of clinical presentation and diseases characteristics. Defining it by spirometry alone is difficult as it tells only the airflow limitation, hence HRCT scan is needed to see the level of obstruction, extent of involvement and disease characteristic. Furthermore, it rule out the other diagnosis and helps us reach at specific diagnosis.[1-7]

Aims and Objectives

- To determine Spirometric finding in smokers with COPD
- To evaluate HRCT finding in smokers with COPD
- To establish the correlation between the two modalities.

MATERIALS AND METHODS

The present study is a Cross-sectional descriptive type on 100 patients in the 1.8 years among smokers diagnosed with COPD on spirometry (screening test) who were referred from the department of tuberculosis and Chest to the Department of Radiodiagnosis of Dr. B.R.A.M Hospital for HRCT scan. All patients of age group >40 years were included with a history of smoking for at least 10 years and diagnosed as COPD on spirometry, giving written consent for HRCT scan. Patients <40 years, unstable cyclic vomiting syndrome status, acute symptoms were excluded from the study.

Step 1 - Spirometry

On spirometry:

- FEV1/FVC <0.70 (Post bronchodilator) confirms the air flow limitation
- FEV1-Volume of air exhaled in the 1st s of this maneuver
- FVC-Maximum volume of air that can be exhaled after full inspiration
- Ratio of this parameter is calculated.

Then COPD is graded as per global initiative for obstructive lung disease (GOLD) 2019 guidelines.

Step 2 – HRCT Scan

- The study was carried out on "Siemens Somatome Definition as + 128 Slice Single Source Computed Tomography Scanner and Easy On-PC Spirometer 2700-1-01, SN-211811 TO Flow/NDD Medintednik Switzerland" in the Department of Radiodiagnosis, Pt. J. N. M. Medical College, Raipur (C.G.).

Technique

- Slice thickness: Thinnest available (0.5–1.5 mm)
- Reconstruction algorithm: High spatial frequency or sharp algorithm
- Kvp 120, 250 mAs, rotation scan time of 0.3–0.5 s, Pitch of 1–1.5, in the supine position and full inspiration, axial plane acquisition with (recon) reconstruction in MPR, MIP and in oblique planes.
- Expiratory imaging: Post expiratory scans at three or more levels in patient with obstructive disease
- window mean/width value of -600–700 HU/1000–1500 HU.

Parameters

- Tracheal index (TI): (Ratio of transverse to anteroposterior [AP] diameter of trachea 1 cm above the aortic arch). When TI is <0.67, it is known as saber sheath trachea
- Thoracic cage ratio (TCR): (Ratio of AP to transverse diameter at carina) and 5 cm below the carina. It is usually >0.75 in emphysema.
- Sterno-aortic distance (SAD): (Distance from the posterior surface of the sternum to anterior margin of the aorta at the level of the carina. It is ≤4
- Mosaic attenuation
- Other features such as bronchiectasis, cysts, bullae, pulmonary hypertension, evidence of fibrosis, and mediastinal lymphadenopathy, etc. are assessed.

Step 3 - Data Collection Done on Excel Sheet

Values were then filled in an 'Excel Sheet'. These values are then selected and formatted in table forms for further analysis. Tables 1-3.

Step 4 - Statistic Analysis

Calculation of correlation, and their significance done. Various scatter graphs and pie charts are obtained showing the correlations using Karl Pearson's correlation. Descriptive statistics included calculation of mean, median, and standard deviation for various data including age distribution of the study population, range of FEV1, grading of severity of COPD as per GOLD 2019 Guidelines, HRCT parameters including TI, TCR, SAD, hyperinflation, tubular heart, types of emphysema and mosaic attenuation [Bar Graph 1]. The minimum and maximum values in the data were also tabulated.

RESULTS AND OBSERVATIONS

The age group of patients who participated in the study ranges from 44 to above 85 years with Mean ± SD (62.08 ± 9.88). Maximum patients fall in the age group of 51–70 years followed by 41–50 years [Pie Chart 1] and [Table 1]. In the age group of 51–60 years, maximum patient comes under moderate grade of COPD and in the age group of 61–70 years, maximum patients were in grade IV of GOLD guideline. Age is significantly associated with severity of FEV1 [Bar Graph 2].

Statistical representation of chi-square test in relation to Karl Pearson coefficient showing Pearson Chi-square (0.6702) with coefficient of 0.80, $P < 0.001$ HS indicating high degree of positive correlation between age and TI.

Statistical representation of Chi-square test in relation to Karl Pearson coefficient showing Pearson Chi-square (0.4861) with coefficient of –0.70, $P < 0.001$ HS indicating high degree of negative correlation FEV1 and SAD.

Statistical representation of Chi-square test in relation to Karl Pearson coefficient showing Pearson Chi-square (0.1972) with correlation coefficient of –0.440, $P < 0.001$[Bar Graph 3] HS indicating moderate degree of negative correlation FEV1 and TCR Table 4.

DISCUSSION

COPD is an old age disease associated with prolonged exposure to smoke and noxious particles. Breathlessness is

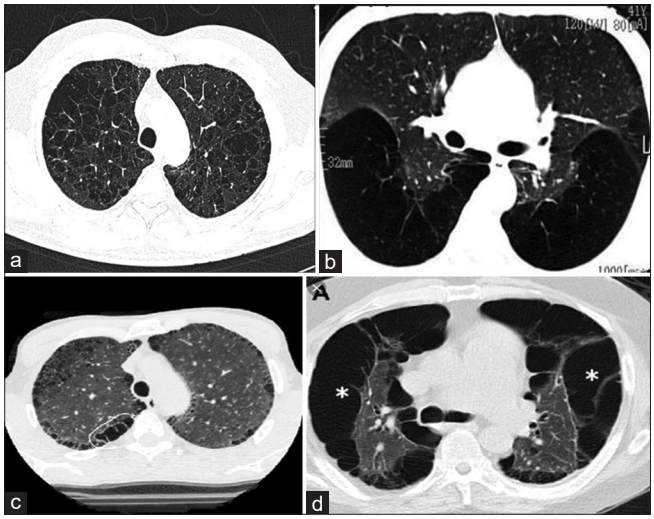

Figure 1: Showing different types of emphysema (a) Centrilobular type. (b) Panacinar type. (c) Paraseptal type. (d) Scan showing bullous predominant emphysema

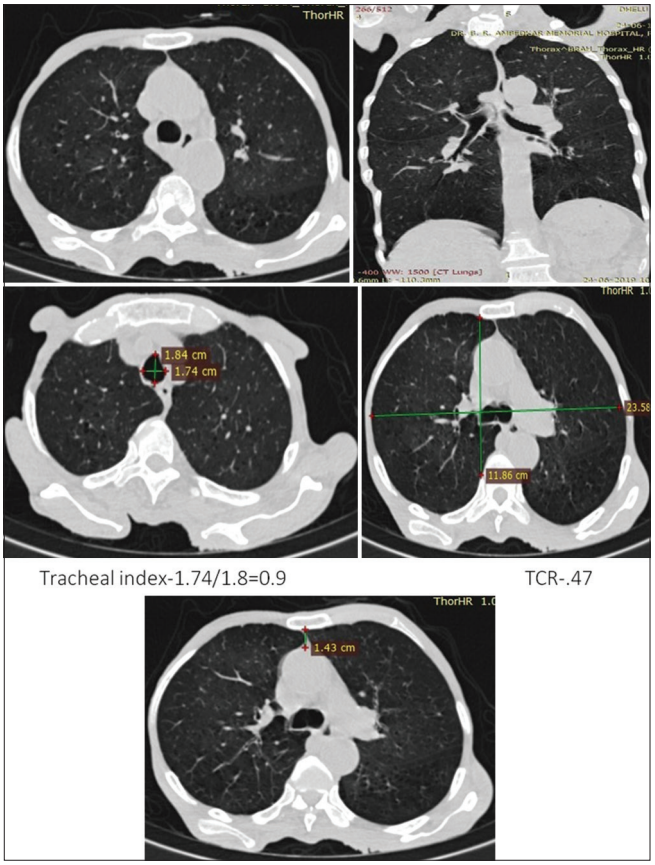

Figure 2: 70-year male with shortness of breath and cough with sputum production since 1 month. On spirometry-forced expiratory volume (FEV)1 is 85% of predicted value and FEV1/ forced vital capacity -0.68, came under global initiative for obstructive lung disease (GOLD) stage 1 under GOLD 2019 guideline. High-resolution computed tomography shows diffuse bilateral centriacinar emphysema with hyperinflation

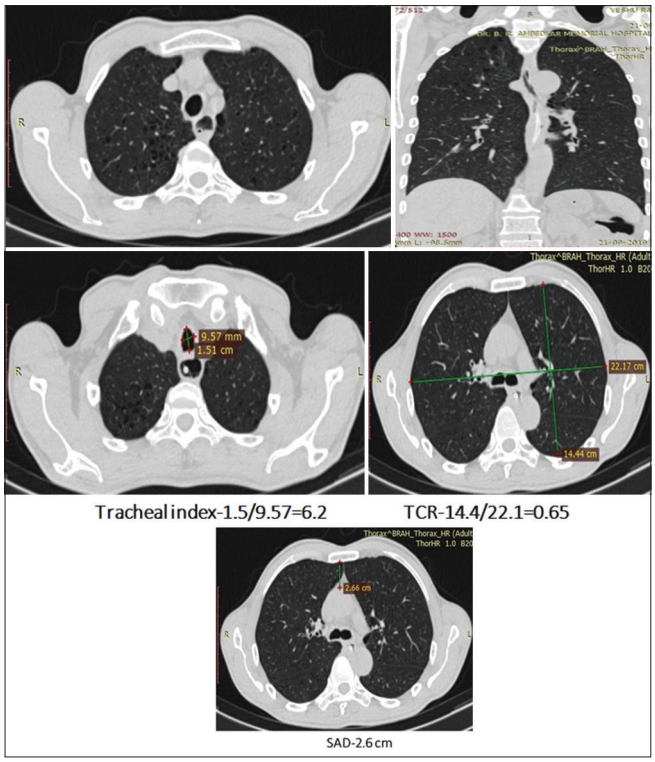

Figure 3: A 60 year male with history of smoking for 20 years, came with shortness of breath at rest and on exertion. On pulmonary function test-forced expiratory volume (FEV) 1–45%, FEV1/forced vital capacity-55%, graded as global initiative for obstructive lung disease stage 3. High-resolution computed tomography shows hyperinflation with bilateral centrilobular emphysema

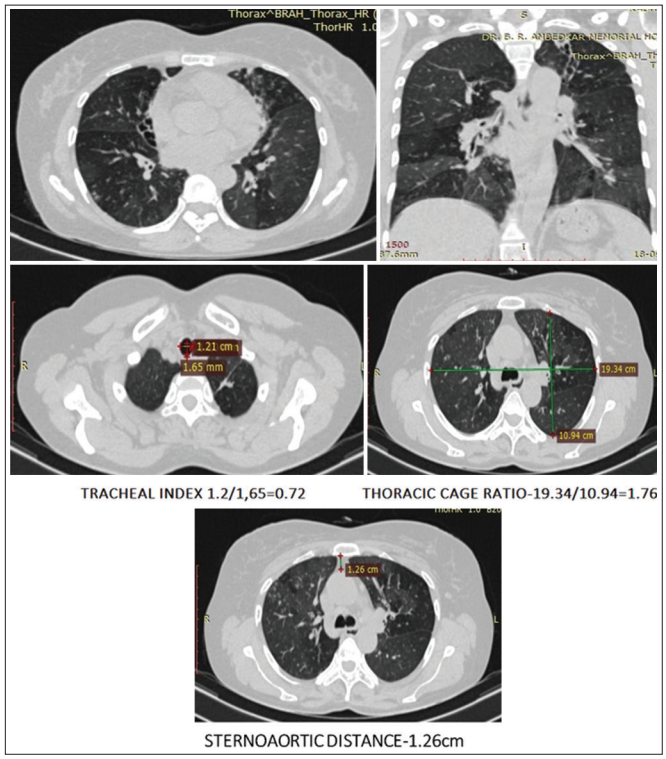

Figure 4: A 40 year male, with history of smoking since 10 year, now complain of shortness of breath since 1 week. On pulmonary function test-forced expiratory volume (FEV) 1–75%, FEV1/forced vital capacity -0.66. High-resolution computed tomography shows para septal emphysema with diffuse mosaic attenuation

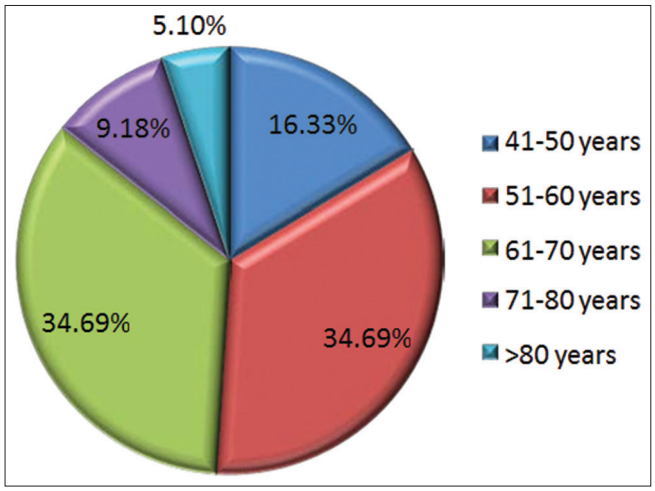

Pie Chart 1: Age wise distribution of forced expiratory volume 1/forced vital capacity

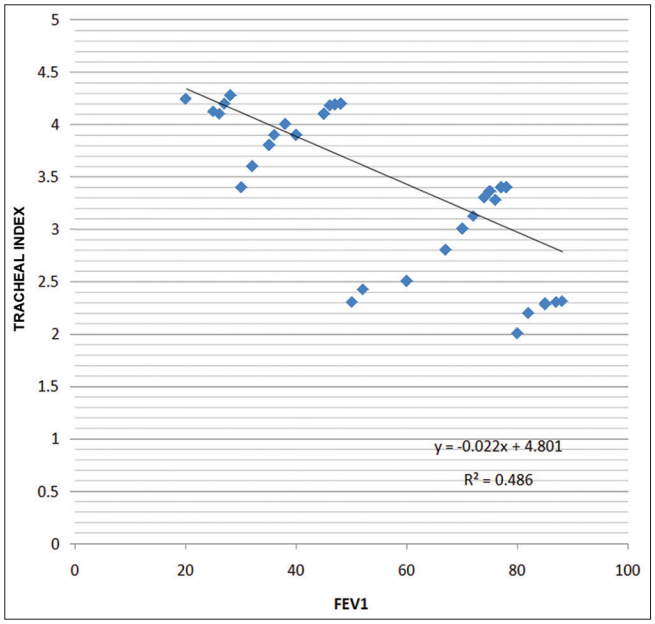

Bar Graph 1: Distribution of range of age group of patient participated, forced expiratory volume 1, tracheal index, thoracic cage ratio and sterno-aortic distance

found to be the most common presenting complaint and was present in all the patients. Although a chest radiograph is not essential in the diagnosis of COPD and has limited sensitivity and specificity.[7,8] HRCT is preferred modality in COPD in which emphysema/low attenuation and airway destruction are important features.

In the present study, 90 patients had hyperinflation, and only 40 patients showed bullae [Figure 1]. Saber sheath

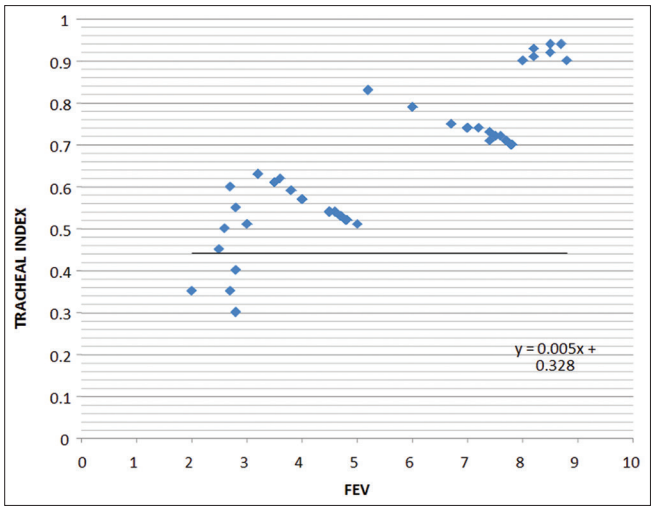

Bar Graph 2: Showing the age wise distribution of disease with forced expiratory volume 1, Blue: Mild; Red: Moderate; Green: Severe; Purple: Very severe

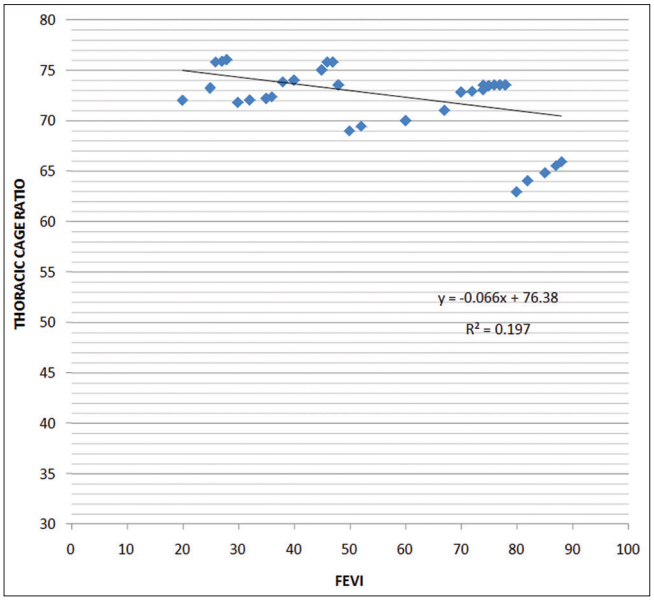

Bar Graph 3: Graph showing the minimum range of forced expiratory volume 1/forced vital capacity is 45 and maximum is 70, with Mean±SD (59.41±7.68)

Table 1: Distribution of HRCT parameter with grading of COPD on basis of FEV1

HRCT parameter	Grade I (8)	Grade II (40)	Grade III (45)	Grade IV (7)
Tracheal Index	0.90–0.94	0.70–0.84	0.51–0.64	0.29–0.63
Thoracic cage ratio	62.9–66.0	69–73.6	71.8–76.2	74.6–76.4
Sterno-aortic distance	1.97–2.31	2.38–3.5	3.4–4.35	4.0–4.36

HRCT: High-resolution computed tomography, COPD: Chronic obstructive pulmonary disease, FEV: Forced expiratory volume

trachea is a basically a sign of hyperinflation. Most common type of emphysema noted in the present study was centrilobular[Table 2] type (89%) followed by paraseptal

Table 2: Qualitative and quantitative parameter related to different grades of COPD

Parameters	Mild (8)	Moderate (40)	Severe (45)	Very severe (7)
Hyperinflation	5	38	40	7
Tubular heart	2	37	39	7
Mosaic attenuation	1	11	15	3
Centriacinar	6	37	40	6
Paraseptal	5	35	20	5
Panacinar	4	10	15	4
bullae	0	10	25	5

COPD: Chronic obstructive pulmonary disease

Table 3: Percentage distribution of severity of COPD in the study

Severity	*n*	%
Mild	8	8
Moderate	40	40
Severe	45	45
Very severe	7	7
Total	100	100

Table 4: Comparison of age distribution of patient and their correlation studied.

COPD severity	Mild	Moderate	Severe
Age group (44-85 years)	41-50 years	61-70 years	51-70 years

type (67%) of patients, favoring smoking as most common etiology.[9-15]

Upper lobes predominance was in agreement with Wright *et al.* and centriacinar emphysema is the commonest type. Increased TCR was found in 11 patients. Significant SAD [Figures 2 and 3] was presented in 30 patients. Thirty patients showed mosaic attenuation which was more [Figure 4] pronounced on scans obtained at end expiration compared to that found at end inspiration. Richard Webb mentioned that pulmonary function tests (PFT) are insensitive for the early diagnosis of emphysema. Similarly, CT is a more sensitive measure of mild emphysema than conventional lung function tests. CT is undoubtedly more sensitive in diagnosis emphysema and in determining its type and extent. If significant emphysema is found on HRCT, no further evaluation is necessary specifically, lung biopsy is not needed. Karl's Pearson's correlation results show that there is a high degree of positive correlation between TI and FEV1, moderate negative correlation between TCR and FEV1, high degree of negative correlation between SAD and FEV1 ($P < 0.001$).

Mean FEV1 in the present study was 56.17 ± 19.32 (range from 20% to 88%). Reduced FEV1/FVC noted in the study[Table 3] is 45 patients with a maximum of 70% with

Mean ± SD is 59.41 ± 7.68. Using Karl Pearson coeffecient using Chi-square test, TI has moderate degree of positive correlation with FEV1/FVC with $P < 0.001$ HS.[16-23]

CONCLUSION

- In advanced stage of COPD, significant extrapulmonary effect adds on to severity of the patients. When diagnosed early, the disease burden can be minimized. In such scenarios, HRCT stands is the modality of choice in early detection and assessing the severity of COPD
- Spirometry offers a convenient tool for earlier screening of moderate to severe disease however the heterogeneity of diseases cannot be defined by FEV1 alone. HRCT may be an important additional tool in holistic evaluation of COPD and can be a substitute to spirometry in patient unfit for spirometry. HRCT can well be correlated with the spirometry finding
- In the present study, the quantitative parameter including TI, TCR, SAD, thoracic cross-sectional area showed positive correlation with (FEV1) and (FEV1)/FVC in spirometry.

Teaching Point

1. Late stages of COPD can be screened by spirometry
2. Early stages need more sensitive modality: HRCT chest
3. HRCT can detect as well as characterize the disease condition and helps in early treatment intervention. Hence, it is great tool to reduce the disease burden, especially if diagnosed early.

REFERENECES

1. Kongstad T, Green K, Buchvald F, Skov M, Pressler T, Nielsen KG. Association between spirometry controlled chest CT scores using computer-animated biofeedback and clinical markers of lung disease in children with cystic fibrosis. Eur Clin Respir J 2017;4:1318027.
2. Otjen JP, Swanson JO, Oron A, DiBlasi RM, Swortzel T, van Well JA, *et al*. Spirometry-assisted high resolution chest computed tomography in children: Is it worth the effort? Curr Probl Diagn Radiol 2018;47:14-8.
3. Xaubet A, Agustí C, Luburich P, Roca J, Montón C, Ayuso MC, *et al*. Pulmonary function tests and CT scan in the management of idiopathic pulmonary fibrosis. Am J Respir Crit Care Med 1998;158:431-6.
4. Mcleana AN, Sprouleb MW, Cowanb MD, Thomsona NC, Mclean AN. High resolution computed tomography in asthma. BMJ 1998;53(4):308-14.
5. Devi YG, Kumar AP, Rani NU, Joshua S. Correlation between HRCT chest findings, Spirometry, ABG and 2D ECHO in patients with bronchiectasis. IOSR J Dent Med Sci 2015;14:62-7.
6. Di Fregab GS, Fiorentinob G. Pulmonary Interstitial Emphysema Following Spirometry in combination Syndrome of pulmonary fibrosis with emphysema.Arch Bronconeumol 2015; 51: 602-3.
7. Ruppel GL. What is the clinical value of lung volumes? Respir Care 2012;57:26-38.
8. Singh P, Katoch CD, Vardhan V, Chopra M, Singh S, Ahuja N. Functional Impairment in Bronchiectasis: Spirometry Parameters Versus St. George's Respiratory Questionnaire Scores: Any co Relation? Alphen aan den Rijn, Netherlands: Indian Chest Society Wolters Kluwer; 2021.
9. Gold. Global Strategy for the Diagnosis, Management, and Prevention of COPD; 2017.
10. Alwan A. Global Status Report on Non-Communicable Diseases. Geneva: World Health Organization; 2010.
11. Lange P, Celli B, Agusti A, Jensen GB, Divo M, Faner R, *et al*. Lung-function trajectories leading to chronic obstructive pulmonary disease. N Engl J Med 2015;373:111-22.
12. Raad D, Gaddam S, Schunemann HJ, Irani J, Jaoude PA, Honeine R, *et al*. Effects of water-pipe smoking on lung function: A systematic review and meta-analysis. Chest 2011;139:764-74.
13. She J, Yang P, Wang Y, Qin X, Fan J, Wang Y, *et al*. Chinese water-pipe smoking and the risk of COPD. Chest 2014;146:924-31.
14. Gunen H, Tarraf H, Nemati A, Al Ghobain M, Al Mutairi S, AounBacah Z. Waterpipe tobacco smoking. TuberkToraks 2016; 64(1): 94-6.
15. Paulin LM, Diette GB, Blanc PD, Putcha N, Eisner MD, Kanner RE, *et al*. Occupational exposures are associated with worse morbidity in patients with chronic obstructive pulmonary disease. Am J Respir Crit Care Med 2015;191:557-65.
16. Townend J, Minelli C, Mortimer K, Obaseki DO, Al Ghobain M, Cherkaski H, *et al*. The association between chronic airflow obstruction and poverty in 12 sites of the multinational BOLD study. Eur Respir J 2017;49:1601880.
17. Gershon AS, Warner L, Cascagnette P, Victor JC, To T. Lifetime risk of developing chronic obstructive pulmonary disease: A longitudinal population study. Lancet 2011;378:991-6.
18. Kim V, Han MK, Vance GB, Make BJ, Newell JD, Hokanson JE, *et al*. The chronic bronchitic phenotype of COPD: An analysis of the COPDGene study. Chest 2011;140:626-33.
19. de Marco R, Accordini S, Marcon A, Cerveri I, Antó JM, Gislason T, *et al*. Risk factors for chronic obstructive pulmonary disease in a European cohort of young adults. Am J Respir Crit Care Med 2011;183:891-7.
20. Koch A, Pizzichini E, Hamilton A, Hart L, Korducki L, De Salvo MC, *et al*. Lung function efficacy and symptomatic benefit of olodaterol once daily delivered via Respimat(R) versus placebo and formoterol twice daily in patients with GOLD 2-4 COPD: Results from two replicate 48-week studies. Int J Chron Obstruct Pulmon Dis 2014;9:697-714.
21. Mahler DA, Kerwin E, Ayers T, FowlerTaylor A, Maitra S, Thach C, *et al*. FLIGHT1 and FLIGHT2: Efficacy and safety of QVA149 (indacaterol/glycopyrrolate) versus its monocomponents and placebo in patients with chronic obstructive pulmonary disease. Am J Respir Crit Care Med 2015;192:1068-79.
22. Bai C, Ichinose M, Lee SH, Lee KH, Jöns O, Bothner U, *et al*. Lung function and long-term safety of tiotropium/olodaterol in East Asian patients with chronic obstructive pulmonary disease. Int J Chron Obstruct Pulmon Dis 2017;12:3329-39.
23. Calverley PM, Anderson JA, Brook RD, Crim C, Gallot N, Kilbride S, *et al*. Fluticasone furoate, vilanterol, and lung function decline in patients with moderate chronic obstructive pulmonary disease and heightened cardiovascular risk. Am J Respir Crit Care Med 2018;197:47-55.

How to cite this article: Kumar S, Gupta N, Sahu CD, Panda RK, Thakur S, Netam SBS. High-resolution Computed Tomography Chest: A Preferred Modality Over Spirometry in Chronic Obstructive Pulmonary Disease among Smokers. Int J Sci Stud 2021;9(9):125-130.

Source of Support: Nil, **Conflicts of Interest:** None declared.

Print ISSN: 2321-6379
Online ISSN: 2321-595X

Original Article

A Correlational Research Study on Diurnal Chronopharmacovigilance Characterization of Levofloxacin, with Molecular Pharmacokinetics and Structural Variations, among Worldwide Respiratory Patients in Tertiary Healthcare Hospitals

Moumita Hazra[1,2,3,4,5]

[1]Medical Director, Medical Superintendent, Consultant Multi-Specialist Clinical Pharmacological Physician, Consultant Clinical Pathologist, Consultant Rational Pharmacotherapeutic Physician, Pharmaco-Haemo-Materio-Vigilance Expert, Consultant Respiratory Pharmacological Physician, Dr. Moumita Hazra's Polyclinic And Diagnostic Centre, Hazra Nursing Home, West Bengal, India, World, [2]Former Associate Professor, Head of Department In Charge, Department of Pharmacology, Rama Medical College Hospital and Research Centre, Rama University, Uttar Pradesh, India, [3]Associate Professor, Head of Department In Charge, Department of Pharmacology, Pharmaco-Haemo-Materio-Vigilance Specialist, Pharmacovigilance Committee, Mamata Medical College and Hospitals, Khammam, Telangana, India, [4]Former Resident and Tutor, Departments of Pharmacology and Pathology, J. J. M. Medical College and Hospitals, Chigateri General Hospital, Karnataka, India, [5]Former Assistant Medical Director, Medical Editor, GIOSTAR Institute of Regenerative Medicine, Institutes, Hospitals and Laboratories, New Delhi, Ahmedabad, India, United States of America

Abstract

Introduction: Levofloxacin, the S- or levorotatory isomer of racemic mixture of ofloxacin, has an inhibitory effect on DNA gyrase, DNA topoisomerase IV and interleukin (IL)-1α, IL-6, IL-8, Tumor necrosis factor-α (TNFα); and a super inducing effect on IL-2.

Objective: The objective of this study is a correlational research on diurnal chronopharmacovigilance characterization of levofloxacin, with molecular pharmacokinetics and structural variations, among worldwide respiratory patients in tertiary healthcare hospitals.

Methods: A worldwide, multi-center, prospective, open-labeled study was conducted, with 100 respiratory tertiary healthcare patients, who were prescribed oral levofloxacin 750 mg once daily for 5–7 days, depending on their disease severity and their suitable treatment regimen. The safety assessment of levofloxacin was done by adverse drug reactions (ADR) monitoring, of diarrhea, nausea, dizziness, arthralgia, headache, vomiting, rashes, hemoptysis, and chest pain, occurring due to levofloxacin therapy, with Adverse Event Case Report Forms. A chronopharmacotherapeutic pharmacovigilance analysis of the occurrence of the adverse effects, was also conducted, on diurnal basis, and subsequently correlated with molecular pharmacokinetics and structural variations. These research findings were thoroughly analyzed, along with statistical interpretations.

Results: The adverse effects were statistically non-significant, as there were no occurrence of any ADR. Levofloxacin was a safe respiratory tertiary healthcare drug, with sufficient tolerability found among the patients. This study delineated quite a predictable chronopharmacovigilance illustration, with clearly demarcated day-wise appearance of adverse reactions, if at all, any, without any variability in the pattern of any adverse reaction occurring; along with distinctly logical correlations with the molecular pharmacokinetics and structural variations of levofloxacin.

Conclusions: Levofloxacin demonstrated pharmacotherapeutic safety and tolerability among worldwide respiratory tertiary healthcare patients, with an anticipated chronopharmacovigilance presentation, correlated well with the molecular pharmacokinetics and structural variations.

Key words: Chronopharmacovigilance, Fluoroquinolones, Levofloxacin, Molecular pharmacokinetics, Respiratory tertiary healthcare, Structural variations

Access this article online

IJSS

www.ijss-sn.com

Month of Submission : 10-2021
Month of Peer Review : 11-2021
Month of Acceptance : 11-2021
Month of Publishing : 12-2021

INTRODUCTION

Levofloxacin, the S- or levorotatory isomer of racemic mixture of ofloxacin, has an inhibitory effect on DNA gyrase, DNA topoisomerase IV and interleukin (IL)-1α, IL-6, IL-8, Tumor necrosis factor-α (TNFα); and a super inducing effect on IL-2. Certain commonplace

Corresponding Author: Dr. Moumita Hazra, Dr. Moumita Hazra's Polyclinic and Diagnostic Centre, Hazra Nursing Home, Jagadishpur Road, Opposite Domjur Football Ground, P.O. Domjur, District Howrah, West Bengal, India.

fluoroquinolones have profound bactericidal, antitubercular, antileprotic, antiviral including anticoronavirus, antifungal, antiprotozoal, comedolytic, anticomedogenic, anti-inflammatory, immunomodulatory, and antimalignant: pro-apoptotic and antiproliferative potential, including transforming growth factor beta 1 (TGFβ1) targeted G2 phase cell cycle arrest.[1-3]

According to the structure activity relationship studies of quinolones as antitubercular agents, the β-keto carboxylic acid moiety is required for hydrogen bonding interactions with DNA bases, and therefore, it is essential for their anti-tubercular activity. The substituent at N-1 and C-8 positions should be relatively small and lipophilic to enhance the activity. Fluorine at C-6 is the best substituent, and it improves cell penetration and gyrase affinity. Substituents at the C-7 position are very essential for the different physicochemical as well as pharmacological properties of levofloxacin.[4]

Objectives

The objective of this study was a correlational research on diurnal chronopharmacovigilance characterization of levofloxacin, with molecular pharmacokinetics and structural variations, among worldwide respiratory patients in tertiary healthcare hospitals.

METHODS

Ethical Approval

At first, the Institutional Ethics Committee clearance and approval was taken. The study was conducted in accordance with the ethical principles of Declaration of Helsinki and Good Clinical Practices contained within the International Council for Harmonization of Technical Requirements for Pharmaceuticals for Human Use, ICH-E6 and ICH-E17, and in compliance with the global regulatory requirements. The patients who were included in the study were assured confidentiality, and an informed consent was obtained from each patient.

Study Design

This study was a worldwide, multi-center, prospective, open-labeled, correlational study.

Place of Study

This research study and the compilation of study literature was conducted at the Departments of Pharmacology, Clinical Pharmacology, Molecular Pharmacology, Rational Pharmacotherapeutics, Pharmacovigilance, Clinical Pathology, Respiratory Medicine, Tuberculosis (TB) and Chest Diseases, in multi-center, tertiary care hospitals, medical colleges and laboratories: Dr. Moumita Hazra's Polyclinic And Diagnostic Centre, Hazra Nursing Home, Rama Medical College Hospital and Research Centre, Rama University, Mamata Medical College and Hospitals, J. J. M. Medical College and Hospitals, GIOSTAR Institute of Regenerative Medicine Institutes, Hospitals and Laboratories.

Study Period

The total study period for this research study and the compilation of the study literature was for 5 months, from January, 2015 to March, 2015; July, 2021; and November, 2021 to December, 2021.

Study Population

The study population consisted of a total of 100 patients, in respiratory tertiary healthcare.

Selection Criteria of the Study Population

Inclusion criteria

The inclusion criteria were as following: (i) patients of any gender, (ii) patients within 18 and 55 years, (iv) co-operative and conscious patients, (v) patients willing to undergo all pre- and post- treatment investigations and willing to complete entire course of treatment, (vi) patients who have given consent and are willing to go for a follow-up, (vii) patients not taking any concomitant medication.

Exclusion criteria

The exclusion criteria were as following: (i) uncooperative or unconscious patients, (ii) patients below 18 and above 55 years, (iii) patients with a history of hypersensitivity to any of the study drugs, (iv) patients with high risk diseases or co-morbidities, (v) cardiac, renal or any other associated complications or co-morbidities, (vi) any chronic disease intervening with the study data, (xi) children or very old patients, (xii) other associated medical illness or disorders having impact on study results.

Study Procedure

About 100 respiratory tertiary healthcare patients were prescribed oral levofloxacin 750 mg once daily for 5–7 days, depending on their disease severity and their suitable treatment regimen. The following data of the patients' thorough history with complete examination details were obtained: The patients' participation assessment and adherence to treatment, including patients who completed the study thoroughly, number of drop-out patients to adverse effects, patients who were lost to follow-up and patients who withdrew voluntarily; the demographic characteristics, including age, gender, race, body mass index (BMI), duration of symptoms of the respiratory diseases; severity of disease symptoms, present controller medications, the patients' present and past history, gastrointestinal history, respiratory history including

respiratory immunological history and history of allergy, chronic obstructive pulmonary disease and asthma, history of multidrug-resistant TB (MDR-TB) contacts, past TB treatment history, and drug susceptibility testing results, cardiac history, history of co-morbidities, family history, personal history, socioeconomic history, metabolic history, history of any chronic disease, reproductive history, concomitant medication history, and surgical history, and the findings were recorded.

The details of complete general physical examination, and systemic examination, including oto-rhino-laryngo-tracheal, respiratory including obstructive pulmonary and tubercular, and cardio-pulmonary examinations, were recorded. Blood pressure, pulse rate, oxygen saturation of arterial hemoglobin (SpO2) measurements, and respiratory rate were recorded. Antibiotic culture and sensitivity were done for each patient.

The safety assessment of levofloxacin was done by monitoring any adverse drug reactions (ADRs), such as, diarrhea, nausea, dizziness, arthralgia, headache, vomiting, rashes, hemoptysis, and chest pain, that had occurred due to the drug therapy, witnessed by the patient or the doctor, during the treatment period or during the follow-up, with Adverse Event (AE) Case Report Forms, on days 0, 3, 5, 7, 10, 15, 21, 30 and on further follow-ups. A chronopharmacotherapeutic pharmacovigilance analysis was also done by the day-wise appearance of various potential adverse effects, that is, any occurrence of diarrhea on day 2, nausea on day 3, dizziness on day 4, arthralgia on day 4, headache on day 5, vomiting on day 5, rashes on day 6, hemoptysis on day 7, and chest pain on day 7. The analytical findings were correlated with the molecular pharmacokinetics and structural variations of levofloxacin.

Complete blood examination, complete respiratory diseases examinations including Mantoux test, chest X-ray, sputum examination, coronavirus reverse transcription polymerase chain reaction examination, respiratory spirometry variables, lesion biopsies, routine metabolic examinations, and imaging examinations were performed, for (i) the baseline assessment values on day 0, (ii) the values after the completion of the required prescribed regimens administration, (iii) the values after the complete recovery, and (iv) the values on each follow-up visit.

Statistical Analysis

The research findings were thoroughly analyzed, along with statistical interpretations, and subsequent tabular illustrations, along with the test of significance, being denoted by the *P*-value.

RESULTS

All 100 patients had participated and adhered to levofloxacin treatment and had subsequently completed the study thoroughly. There were no drop-out patients due to any ADRs, no patients who were lost to follow-up and no patients who withdrew voluntarily. The demographic characteristics of the patients were comparable.

There was no occurrence of any ADR among the patients, with oral levofloxacin treatment. Therefore, the occurrence of adverse effects was statistically non-significant. Levofloxacin was a safe respiratory tertiary healthcare drug, with sufficient tolerability found among the patients. This study delineated quite a predictable chronopharmacovigilance illustration, as depicted in Table 1, with clearly demarcated day-wise appearance of adverse reactions, if at all, any, without any variability in the pattern of any ADR occurring; along with distinctly logical molecular pharmacokinetic correlations and structural variations of levofloxacin.

DISCUSSION

With the advent of quinolones, and later the fluorinated 4-quinolones, the fluoroquinolones, the medical world has certainly taken long strides in treating enormous number of maladies.[1]

Fluoroquinolones, like levofloxacin, are chemical derivatives of quinoline, the prodrome of chloroquine. Fluoroquinolones, a family of 6-fluoro-7-piperazinyl-4-quinolones, are broad spectrum synthetic antimicrobial agents derived from quinolones with the addition of a fluorine atom attached to the central ring.[2,5]

Substitution at C-7 or its N-4-piperazinyl moiety was found to affect physicochemical properties, potency, bioavailability, lipophilicity, and safety of fluoroquinolones, like levofloxacin. The presence of DNA topoisomerases in both eukaryotic and prokaryotic cells makes them excellent targets for chemotherapeutic intervention in antibacterial therapies.[4]

Fluoroquinolones, like levofloxacin, are quite significantly efficacious for their bactericidal inhibitory effect on:

1. DNA gyrase, caused by the binding of fluoroquinolones to the A subunits (gyr A), thus inhibiting the replication and transcription of bacterial DNA, responsible for the proper functioning of the cell, and the subsequent change of conformity of DNA gyrase molecule caused by the binding of fluoroquinolones to the DNA binding groove between A (gyr A) and B (gyr B) subunits

Table 1: The chronopharmacological representation of the occurrence of adverse drug reactions with oral levofloxacin administration, among the patients

Adverse drug reactions due to levofloxacin therapy	Average day of occurrence from initiation of levofloxacin therapy	Number of patients having adverse reactions	*Z*-value	*P*-value
Diarrhea	Day 2	0	–	Non-significant
Nausea	Day 3	0	–	Non-significant
Dizziness	Day 4	0	–	Non-significant
Arthralgia	Day 4	0	–	Non-significant
Headache	Day 5	0	–	Non-significant
Vomiting	Day 5	0	–	Non-significant
Rashes	Day 6	0	–	Non-significant
Hemoptysis	Day 7	0	–	Non-significant
Chest Pain	Day 7	0	–	Non-significant

2. Par C subunits (par C) and Par E subunits (par E) of DNA topoisomerase IV, thus inhibiting decatenation and relaxation of DNA and segregation of replicating chromosomes or plasmids in bacteria
3. Pro-inflammatory cytokines, like ILs: IL-1α, IL-6, IL-8, and tumor necrosis factor α, leading to attenuation of inflammatory response and exhibiting multiple immunomodulatory actions.[1-3]

Fluoroquinolones also have super inducing effect on IL-2.[1] Third-generation quinolones, for example, levofloxacin, have expanded activity against gram-positive bacteria and atypical pathogens.[1]

In this study, there was no occurrence of any ADR among the patients, with oral levofloxacin treatment. Therefore, the occurrence of adverse effects was statistically non-significant. Levofloxacin was a safe respiratory tertiary care drug, with sufficient tolerability found among the patients. This study delineated quite a predictable chronopharmacovigilance illustration, with clearly demarcated day-wise appearance of adverse reactions, if at all, any, without any variability in the pattern of any adverse reaction occurring; along with distinctly logical molecular pharmacokinetic correlations and structural variations of levofloxacin.

Figure 1 depicts the pharmacokinetics of quinolones as improved by the modifications of different substituents in different positions. The development of quinolones, like levofloxacin, in terms of pharmacokinetics and pharmacodynamics, relates to improvements in metabolism, elimination, and transportation, leading to improved antibiotic dosing strategies to enhance the efficacy and prevention of resistant mutations. Use of the very first quinolone agent, nalidixic acid, was limited because it had low serum levels; therefore, it was used as a urinary agent only. The modifications in the structure of later generations of quinolones led to improved oral absorption as well as larger area under the curve (AUC) and/or maximum serum concentrations (Cmax) compared to nalidixic acid. Those modifications also produced longer elimination half-lives, which permitted once-daily dosing for some agents of the second generation and all agents of later generations. Since most of the earlier quinolones had low serum levels and moderate potency, they required frequent doses, with the once-daily dosing of latter agents resulting not only from better exposure but also from their significantly enhanced potency. They also had better tissue penetration. There is no trend in the extent of protein binding related to the structural modifications. This parameter varies between agents, with some <30% (norfloxacin, lomefloxacin, and gatifloxacin) and others >80% (nalidixic acid, trovafloxacin, and garenoxacin).

Gradually, changes in the metabolism of quinolones were observed; although earlier quinolones were primarily eliminated by metabolism and renal clearance, later quinolones were modified to become non-renal clearance agents (sparfloxacin, moxifloxacin, gemifloxacin, trovafloxacin, and garenoxacin). The quinolones show concentration-dependent killing with persistent post-antibiotic effect, and the therapeutic outcomes of this group are based on either the AUC/minimum inhibitory concentration (MIC) ratio or the Cmax/MIC ratio. Thus, a high AUC or Cmax value combined with low MIC is ideal for increasing the ratio and thereby improving the efficacy. The increase in resistance to ciprofloxacin when treating infections with common low-dose regimens, ultimately led to innumerous clinical studies to define the pharmacodynamic parameters for predicting efficacy, and this finally concluded the prolonged deliberations regarding the quantitative indicators, like ratio, of microbiological, as well as, clinical outcomes of quinolones. According to several studies, the second-generation quinolones did not obtain a high Cmax/MIC ratio, with the AUC/MIC ratio more accurately reflecting their efficacy. It was shown that an AUC/MIC ratio of >125 indicated the best therapeutic outcomes, and any agent with a Cmax/MIC ratio lower than four indicated

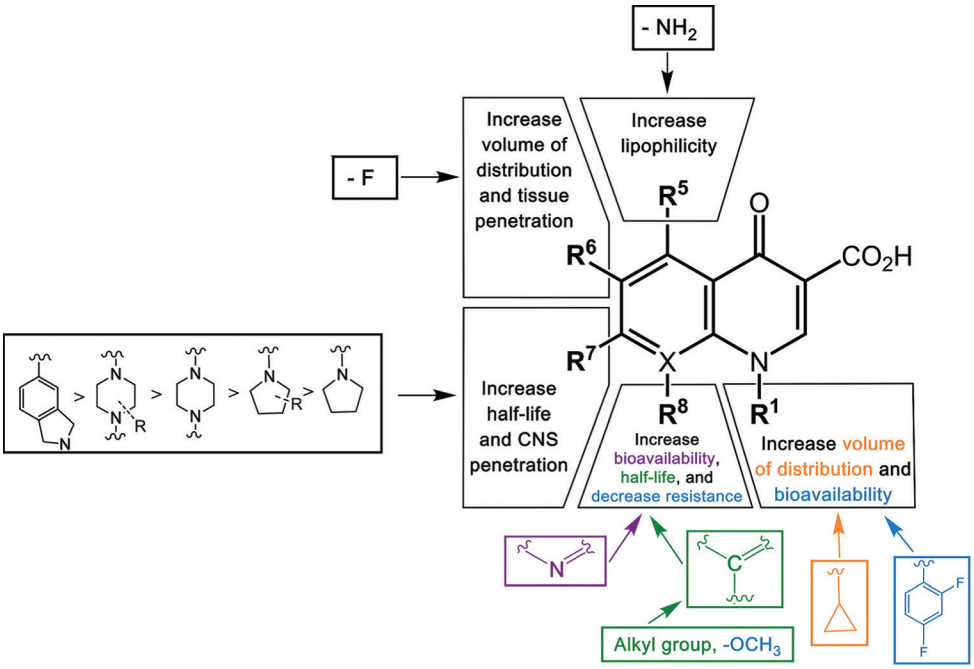

Figure 1: The structure–pharmacokinetic relationship of quinolones[6]

suboptimal outcomes. However, the minimum acceptable AUC/MIC ratio is still uncertain. Some researchers have proposed that an AUC/MIC ratio of 25 is appropriate for use in mild infections and immunocompetent patients, while a value of ≥100 is needed for serious infections and immunocompromised patients. While the AUC/MIC ratio is used to determine the microbiological outcome of quinolone treatment, the Cmax/MIC ratio has been determined to be a factor for preventing the emergence of resistance to quinolones. A higher Cmax is preferable for lower resistance occurrence. Many *in vitro* studies showed that a low AUC/MIC ratio will increase the selection of resistant mutants, even if this ratio is clinically effective for the infections. Combined with the Cmax/MIC ratio, a "mutant prevention concentration" (MPC) was developed for prevention of resistance. It is the concentration necessary to prevent the growth of the least susceptible, single step mutants, with 1010 bacteria incubated in the presence of different increasing concentrations of the antibiotics. The MPC is the concentration in which there is no observation of growth of those bacteria. This MPC is used to prevent resistance during therapy, suggesting a minimum serum concentration to be achieved. This target was used during the development of the third generation of quinolones (gatifloxacin, gemifloxacin, moxifloxacin); they exert lower MPC values than the earlier quinolones when used against *Streptococcus pneumoniae*. Accordingly, the MPC of ciprofloxacin for *Pseudomonas aeruginosa* is lower than that of levofloxacin. Key structural modifications for improving the pharmacokinetics of quinolones are presented at the R5, R6, R7, and R8 positions, which result in longer elimination half-life, better tissue penetration, increased volume distribution, and better bioavailability. The addition of an amino group at R5 increased the quinolones' lipophilicity, which can be seen from the structure of sparfloxacin. The fluorine substituent at position R6 proved to facilitate penetration into the bacterial cell and also improve the volume of distribution of the drug. This improvement was observed during the development of the second-generation of quinolones and was retained until the latest agent of the fourth generation, garenoxacin. The addition of substituents at the R7 position mediated the improvement of the half-life and bacterial tissue penetration. The azabicyclic group and piperazine group at R7 extended the agents' half-life to >10 h by increasing the lipophilicity. Another substituent at this position is the pyrrolidine rings; while this modification is critical for enhancing the potency of quinolones; it was associated with unfavorable water solubility and oral bioavailability. To overcome these physical properties, subsequent generations of quinolones introduced a methyl group into the rings, which can be seen from the examples of gemifloxacin and trovafloxacin. Furthermore, the alkylation of the rings at the R7 position increased the elimination half-life and bioavailability of the agents. The addition of a methyl group to the piperazine rings significantly increased the elimination half-life of ofloxacin, lomefloxacin, sparfloxacin, grepafloxacin, and gatifloxacin compared to enofloxacin, norfloxacin, and ciprofloxacin, which have only the piperazine group in the structure. Alkylation at the R8 position increased the elimination half-life. The latest key modification is

a methoxy group at this position, which lowered the development of resistance to quinolones.

The most common adverse effects of the quinolones are gastrointestinal effects and, less commonly, arthralgia (or joint pain), which are associated with the structural feature of the quinolone pharmacophore. Due to these primary adverse effects, this class is limited for pediatric prescriptions. On account of these class-related ADRs, quinolones are usually clinically prescribed less commonly. These disadvantages were reported to be dependent on the substituents in different positions on the pharmacophore and specific to particular agents. Very rarely, QTc prolongation and cardiac arrhythmia might occur in patients using sparfloxacin and grepafloxacin. Infrequently, phototoxicity was observed when using clinafloxacin and sparfloxacin. There were very rare, transient occurrences of tendon rupture, nerve damage, and fluoroquinolone-associated disability syndrome, only with prolonged use of fluoroquinolones. Other rare adverse effects included hematological toxicity with temafloxacin, hepatitis with trovafloxacin, and hypoglycemia effects with clinafloxacin and gatifloxacin. Immunological side effects, central nervous system (CNS) effects and genotoxicity, were also rarely observed. The genotoxicity of quinolones is only seen in some fluoroquinolones when exposed to ultraviolet light, such as lomefloxacin, ciprofloxacin, and moxifloxacin. Numerous and varied types of recent structural modifications of quinolones, have caused an adequate reduction in these ADRs, and some recent quinolones, like garenoxacin and others, have proved to cause negligible adverse effects. The safety profile of quinolones is being updated constantly. The substituent at the R1 position was shown to be related to the inhibition of cytochrome P450, with cyclopropyl and the alkyl groups at this position affected more than when substituted with a 2,4-difluorophenyl group. Other modifications leading to cytochrome P450 interactions were the replacement of the carbon atom with nitrogen at the X position, and the addition of a bulky side chain into the X8 of quinolones. Genotoxicity, which does not occur in usual clinical treatment, was shown to occur rarely, if at all, in agents with –NH2 and –CH3 substituents at the R5 position, fluorine (F) at the R6 and R8 positions, and chlorine (Cl) at the R8 position. Another specific structural change associated with the genotoxicity was modifications of the group at position 7, with a decrease in severe effects by pyrrolidinyl, piperazine, and alkyl groups, respectively. Phototoxicity is also a rare adverse effect caused by the accumulation of susceptible drugs in the skin where they can be activated by exposure to sunlight, causing damage to the skin. This was observed in agents with an –NH2 group at the R5 position and fluorine (F) or chlorine (Cl) at the R8 position. Quinolones possessing this adverse effect include lomefloxacin, sparfloxacin, and clinafloxacin. CNS reactions including dizziness, insomnia, and headache have been induced by some quinolones, although very infrequently. This adverse effect has been shown to be associated with the inhibition of GABA receptors, a major inhibitory neurotransmitter, and was observed in agents with additional groups at position R7.[6]

Yet, as applicable to any clinical pharmacotherapeutic characterization of drug efficacy and safety, the extensive and infinite spectrum of the clinical pharmacotherapeutic uses of quinolones, for example, levofloxacin, included extremely complicated, recurrent, relapsing and refractory diseases and disorders, complemented with highly efficacious clinical pharmacotherapeutic outcomes, from time immemorial; and quinolones have always very efficiently overwhelmed the minimal ADRs observed, with these extensive range of pharmacotherapeutic applications, thus retaining the unyielding efficacy of this clinical pharmacotherapeutically successful drug category, to remain a novel pharmacotherapeutic, as always. Moreover, throughout the continuing clinical trials, conducted on quinolones, from time even more than the decades, the occurrence of ADRs were almost always statistically non-significant, along with statistically highly significant efficacy levels, thus concluding the immense significance of the quinolones, as a multi-dimensional pharmacotherapeutic agent.

As an anti-microbial agent, fluoroquinolones are active against *Haemophilus influenzae*, *Moraxella catarrhalis*, *Mycoplasma* species, *Chlamydia* species, *Chlamydophila* species, *Legionella* species, *Enterobacteriaceae*, *P. aeruginosa* (particularly ciprofloxacin), *Mycobacterium* TB, some atypical mycobacteria, some methicillin-sensitive Staphylococci, *Campylobacter* species, Salmonellae, *Shigella*, Vibrios, *Yersinia enterocolitica*, *Chlamydia trachomatis*, *Legionella*, and are also indicated in anthrax prophylaxis and meningococcal prophylaxis. The dual inhibitory activity of fluoroquinolones against the bacterial replication enzymes, DNA gyrase and topoisomerase IV, protects them from the development of resistance. For *Mycobacterium* TB, the MPC90 (MPC for 90% of strains) for fluoroquinolones have been found to be ciprofloxacin >levofloxacin >gatifloxacin >moxifloxacin respectively. Hence, gatifloxacin and moxifloxacin are less likely to provoke the development of resistance. Several studies have recommended that levofloxacin is the first-choice fluoroquinolone for MDR-TB. Ofloxacin is also effective for MDR-TB, being the racemic mixture of the S- or levorotatory isomer of ofloxacin: levofloxacin.[7]

Fluoroquinolones, like of loxacin, levofloxacin, ciprofloxacin and moxifloxacin, are relatively new potent oral bactericidal drugs for TB, that have gained prominence

as well tolerated alternatives to first line anti-tubercular drugs. They are active against *Mycobacterium avium* complex, *Mycobacterium fortuitum* and some other atypical mycobacteria as well. Moxifloxacin is the most active fluoroquinolone against *Mycobacterium* TB, while levofloxacin is more active than ofloxacin and ciprofloxacin. Fluoroquinolones are a key component of all regimens for MDR-TB, except when the bacilli are found to be resistant to them. The Revised National TB Control Program of India has included ofloxacin or levofloxacin in the standardized regimen for MDR-TB. If used alone, mycobacterial resistance to ofloxacin, levofloxacin and ciprofloxacin develops rapidly by the mutation of DNA gyrase gene. Experimental data indicates that the resistance against moxifloxacin is slow to develop.[8]

Fluoroquinolones have early bactericidal activity, which is the decline in colony-forming units in sputum over the first 2 days of treatment, reflecting rapid killing of metabolically active organisms, an important factor in interrupting transmission, over days 2–7.

Experimental studies have demonstrated that levofloxacin exerts antioxidative and nitric oxide (NO) regulatory effects in an animal model of H1N1 influenza virus induced lung injury, and significantly improves survival. In particular, levofloxacin exhibited scavenging actions against neutrophil-derived hydroxyl radicals and suppressed NO production, leading to decreased markers of oxidative stress and NO metabolites in the lungs of H1N1 influenza virus infected animals. A recent *in silico* study demonstrated that the fluoroquinolones, ciprofloxacin and moxifloxacin, exert strong capacity for binding to SARS-CoV-2 main protease (Mpro), indicating that fluoroquinolones may inhibit SARS-CoV-2 replication.[5]

Ofloxacin has more potent gram-positive activity; separation of the more active S- or levo rotatory isomer yields levofloxacin, which has even better anti-microbial activity. Bioavailability of both of these drugs is excellent, such that intravenous (IV) and oral doses are the same; levofloxacin is dosed once daily as opposed to twice daily dosing for ofloxacin.[9]

Fluoroquinolones are active against Gram-negative and Gram-positive bacteria, anaerobes, mycobacteria and atypical pathogens. Respiratory fluoroquinolones, levofloxacin and moxifloxacin, constitute fist line therapeutic agents for the management of severe community-acquired pneumonia, according to the treatment guidelines.[1,2]

In yet another study, the add-on dry powder inhaler of combined anti-TB therapy (each capsule contained isoniazid 5 mg, rifampicin 2 mg, pyrazinamide 16 mg, and levofloxacin 2 mg) was administered throughout the course of the standard oral anti-TB treatment. The percentage of patients achieving primary outcome of *Mycobacterium* TB sputum culture conversion measured after receiving treatment for 8 weeks, were similar in both study and control groups; and the study group patients seemed to achieve the primary outcome earlier, along with lessened cough, than the control group; at the end of week 4 of treatment; and reduced hemoptysis in the study group at week 2 of treatment. Secondary outcomes were clinical signs and symptoms of pulmonary TB and ADRs related to anti-TB agents. Regarding safety outcomes, no dyspnea or severe ADRs were reported. AEs related to oral anti-TB agents, (e.g. liver function tests) were in normal ranges in most patients in both groups during the treatment. The incidences of common AEs reported (e.g., anorexia, dizziness, numbness, arthralgia, rash, and itching) were similar between the two groups, while the incidences of nausea and vomiting were significantly lower in the study group than the control group.[10]

In a study, the efficacy of inhaled levofloxacin solution in 86 patients with cystic fibrosis (CF) in terms of the following outcome parameters: changes in %-predicted forced expiratory volume in 1 s (FEV1), BMI, and exacerbation rate, was evaluated, and an intraindividual analysis of patients who received levofloxacin inhalation solution twice daily 240 mg for at least 4 weeks, was done. Change in FEV1% predicted for the treatment period was +2.27% after 4 weeks; there was no change in BMI for overall group, but exacerbation rate compared to 1 year before initiation of inhaled levofloxacin decreased significantly after 1 year of treatment. In patients with CF, inhaled levofloxacin solution has the potential to improve FEV1 and to reduce the number of bronchopulmonary exacerbations.[11]

Levofloxacin inhaled solution (LIS) joins the limited number of antimicrobials with evidence to support their use in CF. Among oral and IV use, the European Medical Association has confirmed that there is a positive benefit–risk ratio for the use of inhaled levofloxacin in adult patients with CF with chronic *P. aeruginosa* lung infections. LIS provides antimicrobial therapy at high concentrations topically, reducing systemic exposure compared with oral or IV levofloxacin administration. The overall efficacy and safety data suggest that LIS is a viable therapy for patients with CF and is a valuable addition to the toolbox clinicians possess to manage chronic *P. aeruginosa* infection in adults with CF, particularly with the potential to penetrate the biofilm and the positive effect on exacerbations; the broad spectrum of action that it offers in comparison to existing inhaled antimicrobials might be of additional interest considering the growing appreciation of the prevalence and complex nature of coinfections such as *Staphylococcus aureus*.[12]

This research study on molecular pharmacokinetics, correlated with the diurnal chronopharmacovigilance of levofloxacin, would remain a milestone in the development of yet more efficacious and safe pharmacotherapeutic agents for respiratory diseases, while improvising the respiratory health, for every generation.

CONCLUSIONS

Levofloxacin demonstrated pharmacotherapeutic safety and tolerability among worldwide respiratory tertiary healthcare patients, with an anticipated chronopharmacovigilance presentation, correlated well with molecular pharmacokinetics and structural variations.

ACKNOWLEDGMENTS

My sincere gratitude to the Departments of Pharmacology, Clinical Pharmacology, Molecular Pharmacology, Rational Pharmacotherapeutics, Pharmacovigilance, Clinical Pathology, Respiratory Medicine, TB and Chest Diseases, at Dr. Moumita Hazra's Polyclinic And Diagnostic Centre, Hazra Nursing Home, Rama Medical College Hospital and Research Centre, Rama University, Mamata Medical College and Hospitals, J. J. M. Medical College and Hospitals, GIOSTAR Institute of Regenerative Medicine Institutes, Hospitals and Laboratories for the successful completion of this research work.

REFERENCES

1. Hazra M. A multivariate comparative clinical pharmacotherapeutic efficacy and chronopharmacovigilance assessment study of ofloxacin, one of the commonplace TGFβ1 inducing and telomerase impairing fluoroquinolones, in treating acute gastroenteritis, chronic obstructive pulmonary disease, new drug-sensitive tuberculosis, recurrent mixed cutaneous infections, and post-surgical refractory wound infections, among the global patients, with heterogenous pharmacogeographic and pharmacogenomic constitution. Int J Basic Clin Pharmacol 2021;10:270-80.
2. Petri WA Jr. Sulfonamides, trimethoprim-sulphamethoxazole, quinolones, and agents for urinary tract infections. In: Laurence LB, Bruce AC, Bjorn CK, editor. Goodman and Gilman's The Pharmacological Basis of Therapeutics 12th ed. United States: McGraw Hill; 2011. p. 1463-76.
3. Brar RK, Jyoti U, Patil RK, Patil HC. Fluoroquinolone antibiotics: An overview. Adesh Univ J Med Sci Res 2020;2:26-30.
4. Mohammed HH, Abuo-Rahma GE, Abbas SH, Abdelhafez EM. Current trends and future directions of fluoroquinolones. Curr Med Chem 2019;26:3132-49.
5. Karampela I, Dalamaga M. Could respiratory fluoroquinolones, levofloxacin and moxifloxacin, prove to be beneficial as an adjunct treatment in COVID-19? Arch Med Res 2020;51:741-2.
6. Pham TD, Ziora ZM, Blaskovich MA. Quinolone antibiotics. Med Chem Commun 2019;10:1719-39.
7. World Health Organization. Differences among Fluoroquinolones in the Treatment of MDR-TB. Geneva, Switzerland: World Health Organization Archives; 2020. Available from: https://www.archives.who.int [Last accessed on 2021 Sep 21].
8. Tripathi KD. Antitubercular drugs. In: Tripathi M, editor. Essentials of Medical Pharmacology. 7th ed. New Delhi, London: Jaypee Brothers Medical Publishers Ltd.; 2013. p. 765-79.
9. Gumbo T. Chemotherapy of tuberculosis, Mycobacterium avium complex disease, and leprosy. In: Brunton LB, Hilal-Dandan R, Knollmann BC, editors. Goodman and Gilman's the Pharmacological Basis of Therapeutics. 13th ed. New York, Chicago: McGraw-Hill; 2018. p. 1067-86.
10. Laohapojanart N, Ratanajamit C, Kawkitinarong K, Srichana T. Efficacy and safety of combined isoniazid-rifampicin-pyrazinamide-levofloxacin dry powder inhaler in treatment of pulmonary tuberculosis: A randomized controlled trial. Pulm Pharmacol Ther 2021;70:102056.
11. Schwarz C, Grehn C, Temming S, Holz F, Eschenhagen PN. Clinical impact of levofloxacin inhalation solution in cystic fibrosis patients in a real-world setting. J Cyst Fibros 2021;20:1035-9.
12. Elborn JS, Flume PA, Van Devanter DR, Procaccianti C. Management of chronic *Pseudomonas aeruginosa* infection with inhaled levofloxacin in people with cystic fibrosis. Future Microbiol 2021;16:1087-104.

How to cite this article: Hazra M. A Correlational Research Study on Diurnal Chronopharmacovigilance Characterization of Levofloxacin, with Molecular Pharmacokinetics and Structural Variations, among Worldwide Respiratory Patients in Tertiary Healthcare Hospitals. Int J Sci Stud 2021;9(9):131-138.

Source of Support: Nil, **Conflicts of Interest:** None declared.