

Primary Leiomyosarcoma of Liver: A Rare Clinical Presentation

Rahul Chowdhry Kongara¹, K Vengadkrishnan²

¹Resident, Department of General Medicine, Sri Ramachandra Medical College, Porur, Chennai, Tamil Nadu, India, ²Professor, Department of General Medicine, Sri Ramachandra Medical College, Porur, Chennai, Tamil Nadu, India

Abstract

Primary hepatic leiomyosarcoma are rare tumors with <30 cases reported in the English literature. Non-specific presentations and often diagnosis delayed until they reach a large size is the norm with therapy leading to an often dismal prognosis. A 67-year-old man presented complaining of abdominal pain and a palpable abdominal mass. Abdominal ultrasonography and abdominal computed tomography revealed a large tumor in the left lobe of the liver. Surgical exploration was undertaken, and an extended left hepatectomy with extension onto the dorsal part of segment 8 preserving the middle hepatic vein with partial resection of segment 6 was undertaken. The weight of the resected specimen was 1300 g of the left lobectomy specimen and 8 g of the segment 6 partial resection specimen. The pathology report confirmed the diagnosis of leiomyosarcoma. On immunohistochemistry, the tumor cells were positive for smooth muscle actin stain. The patient is on regular follow-up. We report the case of a resected primary hepatic leiomyosarcoma and emphasize the need for a global database for these rare tumors to promote a better and broader understanding of this less understood subject.

Key words: Hepatectomy, Primary hepatic leiomyosarcoma, Smooth muscle actin, Smooth muscle

INTRODUCTION

Primary hepatic leiomyosarcoma are rare tumors with <30 cases reported in the English literature. Primary hepatic mesenchymal tumors are rare tumors. Sarcomas constitute only 1–2% of all primary malignant tumors of the liver with the majority being either hepatocellular carcinoma or cholangiocarcinoma.^[1] Nearly, all primary sarcomas of the liver are angiosarcomas, epithelioid hemangioendotheliomas, or undifferentiated embryonal sarcoma constituting nearly 70% with leiomyosarcoma being a modest 8–10% of all sarcomas.^[2] Most hepatic leiomyosarcoma are metastatic from other sites of leiomyosarcoma including the gastrointestinal tract, uterus, retroperitoneum, and lung.^[3] Hence, exclusion of metastatic leiomyosarcoma in the liver is an essential event in diagnosing a primary lesion. Leiomyosarcoma

are malignant neoplasms that arise from smooth muscle. Hepatic leiomyosarcoma may arise from intrahepatic vascular structures, bile ducts, or ligamentum teres. Tumors arising from the hepatic veins may develop Budd–Chiari syndrome and have a worse prognosis with tumors arising from the ligamentum teres having a better prognosis due to its increased respectability.^[4] No underlying etiologic factors are known, although thorotrast, acquired immunodeficiency syndrome, Epstein–Barr virus,^[5] prior history of immunosuppression in the form of post renal transplant^[6] and previously treated Hodgkin’s lymphoma,^[7] and the rare association with hepatitis C virus liver cirrhosis which was not directly implicated,^[8] have all been described in the literature. The median age of diagnosis is 58 years with sporadic occurrence of the tumor in the younger age group.^[9]

Primary hepatic leiomyosarcoma present a clinical dilemma: Not only are they unusual and rare with <50 cases described in the literature but also they are often asymptomatic until they become large, and even then they produce nonspecific symptoms. Patients may be afflicted with a wide spectrum of symptoms such as abdominal pain, weight loss, anorexia, vomiting, jaundice, and rarely acute intra-abdominal bleeding secondary to

Access this article online



www.ijss-sn.com

Month of Submission : 12-2017
Month of Peer Review : 01-2018
Month of Acceptance : 01-2018
Month of Publishing : 02-2018

Corresponding Author: Dr. K Vengadkrishnan, Sri Ramachandra Medical College, Porur, Chennai, Tamil Nadu, India.
Phone: +91-9840131997. E-mail: Drkvk1975@gmail.com

tumor rupture.^[10] Tenderness of the upper abdomen, hepatomegaly, and mass may be the main signs. Some patients may have abnormal liver function tests, but essentially the α -fetoprotein and other serological markers are normal. The non-specific nature of symptoms and the lack of serological markers make the diagnosis of hepatic leiomyosarcoma challenging.

Non-specific presentations and diagnosis often delayed until they reach a large size is the norm with therapy leading to an often dismal prognosis. The rarity of these tumors has precluded our understanding of them, and therefore, the standard of care has not been well defined. We herein report a case of primary hepatic leiomyosarcoma, which was treated surgically and reviews the English literature with an emphasis on management outcomes.

CASE REPORT

A 67-year-old man was presented with chief complaining of pain in the abdomen and a palpable abdominal mass since 6 years. He had no history of liver disease or alcohol abuse. His past medical history and family history were unremarkable. Physical examination revealed marked hepatomegaly extending 6 cm below the right costal margin. Laboratory analysis revealed normal liver function tests including serum albumin level and prothrombin time. White blood cell count, platelet, α -fetoprotein, CA 19-9, and carcinoembryonic antigen were normal. Antibody to hepatitis C virus and hepatitis B surface antigen were negative. Impedance cardiogram clearance at 15 min was 10%. Abdominal ultrasonography revealed a hypoechoic mass, measuring 14 cm in diameter, in the left lobe of the liver. Abdominal computed tomography (CT) showed a hypodense lesion on plain scans, heterogeneous enhancing lesion on arterial phase and delayed washout on portal venous phase occupying segments 2, 3, 4, and 8 [Figure 1]. CT arterio-portalography revealed a hypodense lesion. Selective angiography of the celiac trunk and superior mesenteric artery showed a faint tumor stain in the left lobe of the liver and stenosis of the left portal vein. Chest CT, upper gastrointestinal and lower gastrointestinal endoscopy were within normal limits.

Pre-operative diagnosis was unconfirmed, written informed consent was obtained, and surgical exploration was undertaken. A huge tumor, measured 17 cm \times 7 cm \times 14 cm, occupying almost the whole left lobe of the liver was found [Figure 2]. Intraoperative ultrasound revealed that the tumor also extended into the dorsal aspect of segment 8 and another small hypoechoic lesion in segment 6. An extended left hepatectomy with

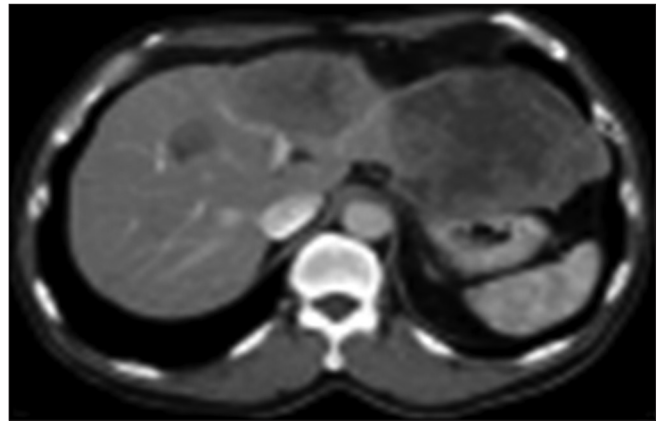


Figure 1: Computed tomography scan showing a large heterogeneously enhancing tumor in the left lobe of the liver

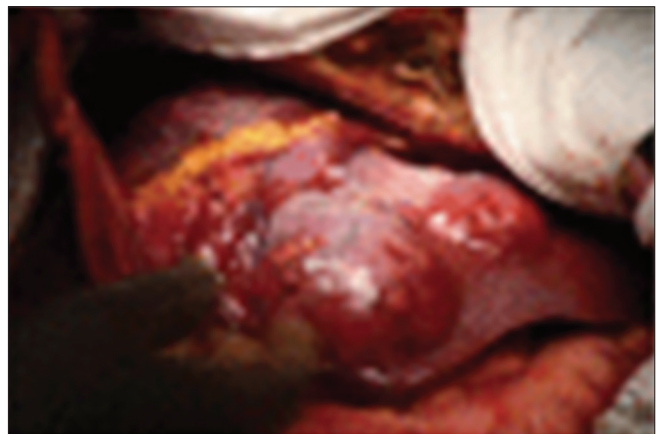


Figure 2: Intraoperative photo showing the large left lobe tumor

extension onto the dorsal part of segment 8 preserving the middle hepatic vein with partial resection of segment 6 was undertaken. The pringle time was 60 min, and the operative blood loss was 520 mL. The weight of the resected specimen was 1300 g of the left lobectomy specimen and 8 g for the segment 6 partial resection specimen. Careful inspection of the abdominal and pelvic contents did not reveal any other mass or lesions. Grossly, the tumor was lobulated, well encapsulated, and prominent in fibrotic bands. The pathology report confirmed the diagnosis of leiomyosarcoma. Light microscopy demonstrated the typical pattern of growth of leiomyosarcoma, predominantly fascicular, with tumor bundles intersecting each other at wide angles and merging of tumor cells with blood vessel walls, an important diagnostic clue [Figure 3]. The individual cells had elongated, blunted nuclei and acidophilic fibrillary cytoplasm. Numerous mitoses were present. On immunohistochemistry, the tumor cells were positive for the smooth muscle actin (SMA) stain [Figure 4]. The patient is on regular follow-up and referred to an oncologist for further care.

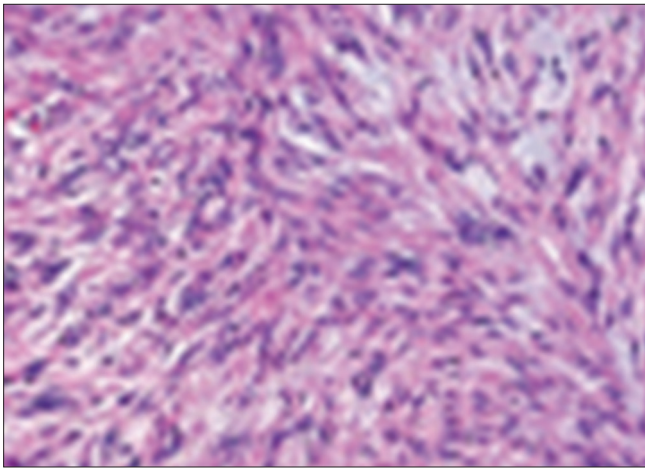


Figure 3: Histomicrograph showing fascicular growth pattern with tumor bundles intersecting each other at wide angles and merging of tumor cells with blood vessel walls

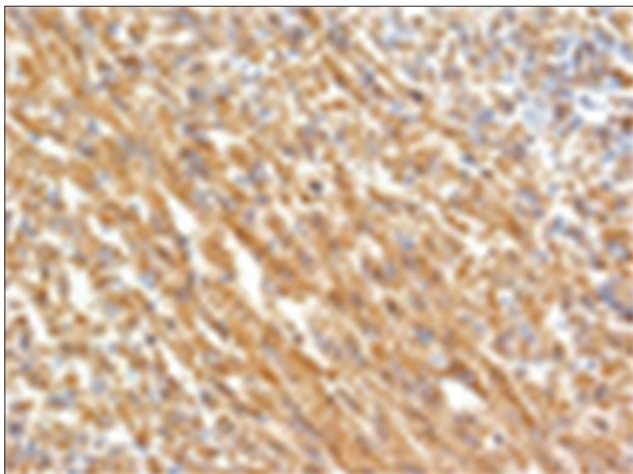


Figure 4: Tumor cells are positive for smooth muscle actin by immunohistochemical stain

DISCUSSION

Primary hepatic mesenchymal tumors are rare tumors. Sarcomas constitute only 1–2% of all primary malignant tumors of the liver with the majority being either hepatocellular carcinoma or cholangiocarcinoma.^[1] Nearly, all primary sarcomas of the liver are angiosarcomas, epithelioid hemangioendotheliomas, or undifferentiated embryonal sarcoma constituting nearly 70% with leiomyosarcoma being a modest 8–10% of all sarcomas.^[2] Most hepatic leiomyosarcoma are metastatic from other sites of leiomyosarcoma including the gastrointestinal tract, uterus, retroperitoneum, and lung.^[3] Hence, exclusion of metastatic leiomyosarcoma in the liver is an essential event in diagnosing a primary lesion.

Histological pre-operative diagnosis of hepatic leiomyosarcoma is controversial as with other liver tumors, as most of the tumors are treated presuming to

be hepatocellular carcinoma with its inherent propensity for needle track seeding. Histological examination reveals tumor composed of intersecting bundles of spindle-shaped cells. Immunohistochemistry is positive for desmin, vimentin, and SMA but negative for keratin, S-100 protein, and neuron-specific enolase and FNA biopsy will allow for specific FNA diagnosis in most cases.^[11]

CT findings of primary hepatic leiomyosarcoma have been described as a large, well-defined, heterogeneous-hypodense mass with internal and peripheral enhancement or cystic mass with an enhancing thick wall. Cystic variant of leiomyosarcoma may be misdiagnosed as hydatid cyst or liver abscess.^[12] On magnetic resonance imaging, the tumor displays homogenous or heterogeneous hypointensity on T1-weighted images and hyperintensity on T2-weighted images with the occasional observation of encapsulation.^[13] Due to the rarity of primary hepatic sarcomas in general, and primary hepatic leiomyosarcoma in particular, the standard of care has not been defined. However, surgical resection followed by adjuvant chemotherapy is being widely followed in an empirical manner.^[2]

Resection surgery forms the cornerstone of successful management of primary hepatic leiomyosarcoma with the intention of R0 resection. All patients with potentially resectable tumors with adequate remnant liver volume should undergo surgical exploration and liver resection. The surgical outcome for R0 resection extrapolated from 2 large series was 67% disease-specific survival at 5 years with 0% 3 years survival for patients who underwent R1+ resection.^[2,14] Age was another major prognostic factor with patients <50 years achieving better survival. The role of adjuvant chemotherapy/chemoradiotherapy is not well defined. Adjuvant chemotherapy in the form of doxorubicin and ifosfamide seems to slow the course of the disease and may prolong survival in R1 resections, but the evidence is lacking as the data are extrapolated from the unresectable or metastatic leiomyosarcoma setting.^[15]

CONCLUSION

Primary hepatic leiomyosarcoma are a rare tumor with often delayed diagnosis and poor prognosis. This case highlights the need for swift early diagnosis with aggressive management. This also raises the question of the possibility of an unidentified factor, making apparently healthy patients susceptible to this malady.

REFERENCES

1. Maki HS, Hubert BC, Sajjad SM, Kirchner JP, Kuehner ME. Primary hepatic leiomyosarcoma. *Arch Surg* 1987;122:1193-6.

Kongara and Vengadkrishnan: Primary Leiomyosarcoma of Liver

- Weitz J, Klimstra DS, Cymes K, Jarnagin WR, D'Angelica M, La Quaglia MP, *et al.* Management of primary liver sarcomas. *Cancer* 2007;109:1391-6.
- Cioffi U, Quattrone P, De Simone M, Bonavina L, Segalin A, Masini T, *et al.* Primary multiple epithelioid leiomyosarcoma of the liver. *Hepatogastroenterology* 1996;43:1603-5.
- Yamaguchi J, Azuma T, Fujioka H, Tanaka K, Furui J, Tomioka T, *et al.* Leiomyosarcoma occurring in the ligamentum teres of the liver: A case report and a review of seven reported cases. *Hepatogastroenterology* 1996;43:1051-6.
- Brichard B, Smets F, Sokal E, Clapuyt P, Vermeylen C, Cornu G, *et al.* Unusual evolution of an epstein-barr virus-associated leiomyosarcoma occurring after liver transplantation. *Pediatr Transplant* 2001;5:365-9.
- Fujita H, Kiriya M, Kawamura T, Ii T, Takegawa S, Dohba S, *et al.* Primary hepatic leiomyosarcoma in a woman after renal transplantation: Report of a case. *Surg Today* 2002;32:446-9.
- Giuliante F, Sarno G, Ardito F, Pierconti F. Primary hepatic leiomyosarcoma in a young man after Hodgkin's disease: Diagnostic pitfalls and therapeutic challenge. *Tumori* 2009;95:374-7.
- Tsuji M, Takenaka R, Kashihara T, Hadama T, Terada N, Mori H, *et al.* Primary hepatic leiomyosarcoma in a patient with hepatitis C virus-related liver cirrhosis. *Pathol Int* 2000;50:41-7.
- Shamseddine A, Faraj W, Mukherji D, El Majzoub N, Khalife M, Soubra A, *et al.* Unusually young age distribution of primary hepatic leiomyosarcoma: Case series and review of the adult literature. *World J Surg Oncol* 2010;8:56.
- Jeong TY, Kim YS, Park KJ, Lee JS, Huh JG, Ryu SH, *et al.* A case of primary leiomyosarcoma of the liver presenting with acute bleeding. *Korean J Gastroenterol* 2008;51:194-8.
- Smith MB, Silverman JF, Raab SS, Towell BD, Geisinger KR. Fine-needle aspiration cytology of hepatic leiomyosarcoma. *Diagn Cytopathol* 1994;11:321-7.
- Gates LK Jr., Cameron AJ, Nagorney DM, Goellner JR, Farley DR. Primary leiomyosarcoma of the liver mimicking liver abscess. *Am J Gastroenterol* 1995;90:649-52.
- Yu RS, Chen Y, Jiang B, Wang LH, Xu XF. Primary hepatic sarcomas: CT findings. *Eur Radiol* 2008;18:2196-205.
- Matthaei H, Krieg A, Schmelzle M, Boelke E, Poremba C, Rogiers X, *et al.* Long-term survival after surgery for primary hepatic sarcoma in adults. *Arch Surg* 2009;144:339-44.
- Oosten AW, Seynaeve C, Schmitz PI, den Bakker MA, Verweij J, Sleijfer S, *et al.* Outcomes of first-line chemotherapy in patients with advanced or metastatic leiomyosarcoma of uterine and non-uterine origin. *Sarcoma* 2009;2009:348910.

How to cite this article: Kongara RC, Vengadkrishnan K. Primary Leiomyosarcoma of Liver – A Rare Clinical Presentation. *Int J Sci Stud* 2018;5(11):187-190.

Source of Support: Nil, **Conflict of Interest:** None declared.