

Chronic Uterine Inversion Secondary to Submucous Fibroid: A Rare Case Report

Archana Kumari¹, Anubha Vidhyarathi², K M Salini³

¹Assistant Professor, Department of Obstetrics and Gynaecology, RIMS, Ranchi, Jharkhand, India, ²Associate Professor, Department of Obstetrics and Gynaecology, RIMS, Ranchi, Jharkhand, India, ³Junior Resident, Department of Obstetrics and Gynaecology, RIMS, Ranchi, Jharkhand, India

Abstract

Nonpuerperal uterine inversion is a rare condition. As nonpuerperal uterine inversion is rarely encountered by the gynecologist thus diagnosis and management could be challenging. We describe a case report of chronic inversion of nonpuerperal uterus secondary to submucous fibroid associated with severe anemia. A 45-year-old lady presented with menorrhagia and copious vaginal discharge followed by acute retention of urine. Diagnosis of partial inversion of the uterus was made, which was confirmed at laparotomy. Treatment of anemia was done and then she underwent abdominal hysterectomy with bilateral salpingo-oophorectomy after correction of inversion.

Key words: Fibroid, Inversion, Menorrhagia, Puerperal

INTRODUCTION

Uterine inversion refers to the descent of the uterine fundus to or through the cervix so that uterus is turned inside out. Uterine inversion is a rare condition that occurs usually as a complication of deliveries.¹ Nonpuerperal inversion is extremely rare representing about one-sixth of all inversion.² Prolapsed fibroids tend to be the most common inciting factors with an occasional report of inversion associated with uterine neoplasm and endometrial polyp. Three contributing factors proposed for uterine inversion are (1) sudden emptying of the uterus which was previously distended by a tumor (2) thinning of the uterine walls due to an intrauterine tumor and (3) dilatation of cervix.³⁻⁶ We report a case of chronic inversion of the nonpuerperal uterus due to large submucous fibroid with severe anemia.

CASE REPORT

A 45-year-old lady, P₃₊₀L₃ all vaginal deliveries (last child birth - 14 years back) presented to the RIMS gynecological

outpatient on 6 August 2015 with a complaint of menorrhagia and congestive dysmenorrhea for last 8 months followed by copious foul-smelling vaginal discharge for last 6 months. On general examination, she had severe pallor and tachycardia (pulse rate - 112/min), blood pressure was in normal range. On P/A examination nothing was remarkable. On P/S examination-cervix was not visualized. A pink colored polyp of 8 cm × 8 cm with few necrotic area was seen in vagina (Figure 1). On bimanual pelvic examination - A large polypoidal mass of 8 cm × 8 cm felt in upper part of vagina, firm in consistency, smooth surfaced with bleeds on touch. Cervical lip could not be felt with distinction, and uterine size could not be assessed properly. A clinical diagnosis of submucous fibroid polyp with severe anemia was made. After 2 days of admission, she suddenly developed acute retention of urine, for which was put on the indwelling catheter. Except of severe anemia (hemoglobin-6 g%), all routine pre-operative investigations were within normal range. Her ultrasound (USG) revealed inversion of uterus with a right simple ovarian cyst of 5 cm × 4 cm. Clinical diagnosis was revised to inversion of the uterus with fibroid polyp and was posted for abdominal hysterectomy after correction of anemia (4 unit of packed cell volume transfusion done). On laparotomy, there was the typical appearance of uterine inversion, i.e., broad ligament, round ligament, and other associated structures were stretched due to uterine inversion (Figure 2). Uterine reposition was done by giving a vertical incision into

Access this article online



www.ijss-sn.com

Month of Submission : 12-2015
Month of Peer Review : 01-2016
Month of Acceptance : 01-2016
Month of Publishing : 02-2016

Corresponding Author: Dr. K M Salini, Room No 34, New PG Girls Hostel, RIMS Campus, Bariyatu, Ranchi - 834 009, Jharkhand, India. Phone: +91-7761820740. E-mail: shalinisappu@gmail.com

posterior portion of the cervical ring and gentle traction on round ligaments (Haultain's method), with the simultaneous gentle pushing of fundus through vagina by an assistant (Figure 3). A sessile submucous fibroid of 8 cm × 8 cm size was attached to fundus which was

removed by enucleation. After correction of uterine inversion total abdominal hysterectomy and bilateral salpingo-oophorectomy done. Her post-operative period was uneventful and was discharged on 10th post-operative day in healthy condition. Histopathology of the excised polypoidal mass showed a picture of fibromyoma.

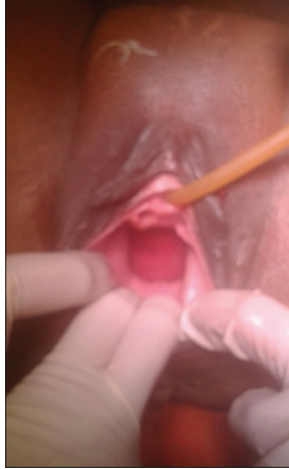


Figure 1: Perineal examination showing fibroid polyp

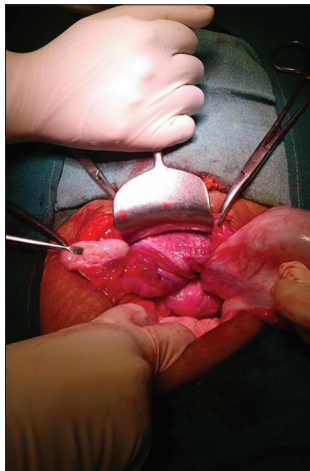


Figure 2: Laparotomy showing cupping of fundus of uterus

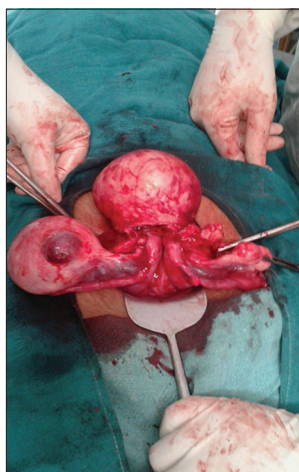


Figure 3: Repositioning of uterus

DISCUSSION

Uterine inversion can be classified into four stages as Stage 1: The inverted uterus remains in the uterine cavity, Stage 2: Complete inversion of the fundus through the cervix, Stage 3: The inverted fundus protrudes through vulva, and Stage 4: Inversion of the uterus and vaginal wall through the vulva.⁷ Inversion can also be classified as acute and chronic. With acute inversion, the patient may have severe pain in lower abdomen or excessive bleeding whereas chronic inversion may be insidious or patient may have lower abdominal discomfort, vaginal discharge, irregular vaginal bleeding, or anemia.⁸ In chronic inversion with sloughing of endometrium diagnosis, it is not very easy so detailed abdominal, and vaginal USG or Doppler may be required to confirm the diagnosis.^{9,10}

As nonpuerperal uterine inversion is rarely encountered by the gynecologist thus diagnosis and management could be challenging.¹¹ In our case, on clinical examination, the diagnosis was not clear, so detailed ultrasound of abdomen and pelvis was done to confirm the diagnosis. Repositioning of the uterus can be done manually in acute cases but in chronic nonpuerperal case, manual repositioning is not possible, especially in those cases associated with tumors. In chronic nonpuerperal cases, surgery is imperative. Considering patient's age, reproductive desire and associated conditions, surgical repositioning, or hysterectomy can be done.

Surgical repositioning can be done vaginally or through abdominal route. In vaginal route approach (Spinelli's method), incision is given anteriorly in the constriction ring and bladder dissection is required; while in Kustner's method, posterior uterine wall incision is given which make it bit easier and safer.¹² Abdominal route repositioning can be done either using Huntington's procedure¹³ (cup of inversion is identified, dilating the cervical ring digitally and gently pulling out round ligaments) or by Haultain's method¹⁴ where a vertical incision is given in the posterior wall of the cervical ring, and gentle traction is given on round ligaments. We repositioned the uterus using Haultain's technique. Following that total abdominal hysterectomy with bilateral salpingo-oophorectomy was performed. The other methods include laparoscopic reduction,¹⁵ the use of obstetrics ventouse at laparotomy¹⁶ and robotically assisted laparoscopic correction.¹⁷

CONCLUSION

Chronic uterine inversion is a rare condition that is difficult to diagnose even for the experienced gynecologists. Uterine inversion has a good prognosis when managed in timely correct manner. The treatment for chronic uterine inversion is surgical that includes both abdominal and vaginal approaches.

REFERENCES

1. Baskett TF. Acute uterine inversion: A review of 40 cases. *J Obstet Gynaecol Can* 2002;24:953-6.
2. Krenning RA. Nonpuerperal uterine inversion. Review of literature. *Clin Exp Obstet Gynecol* 1982;9:12-5.
3. Takano K, Ichikawa Y, Tsunoda H, Nishida M. Uterine inversion caused by uterine sarcoma: A case report. *Jpn J Clin Oncol* 2001;31:39-42.
4. Lascarides E, Cohen M. Surgical management of the nonpuerperal inversion of the uterus. *Obstet Gynaecol* 1968;32:376-81.
5. Das P. Inversion of uterus. *J Obstet Gynaecol* 1940;47:525-48.
6. Rattray CA, Parris CN, Chisholm G, Coard KC. Complete non-puerperal uterine inversion as a result of a uterine sarcoma. *West Indian Med J* 2000;49:245-7.
7. Spinelli PG. Inversion of uterus. *Riv Ginec Comtemp* 1897;11:567-70.
8. Foulifack F, Nana P, Fouedjio JH, Bechem E. Non-puerperal uterine inversion following a prolapsed leiomyoma in a Cameroonian woman. *Clin Mother Child Health* 2011;8:1-3.
9. Krissi H, Peled Y, Efrat Z, Goldshmit C. Ultrasound diagnosis and comprehensive surgical treatment of complete non-puerperal uterine inversion. *Arch Gynecol Obstet* 2011;283 Suppl 1:111-4.
10. Chen YL, Chen CA, Cheng WF, Huang CY, Chang CY, Lee CN, *et al.* Submucous myoma induces uterine inversion. *Taiwan J Obstet Gynecol* 2006;45:159-61.
11. Omololu OM, Rabiu KA, Quadri MA, Oyedeko MO, Fatogun YM. Non puerperal uterine inversion due to Submucous fibroid: A case report. *Niger Postgrad Med J* 2011;18:158-60.
12. Fofie CO, Baffoe P. Non-puerperal uterine inversion: A case report. *Ghana Med J* 2010;44:79-81.
13. Huntington JL. Abdominal reposition in acute inversion of the puerperal uterus. *AM J Obstet Gynaecol* 1928;15:34-40.
14. Haultain F. The treatment of chronic uterine inversion by uterine hysterectomy. *BMJ* 1901;2:974-80.
15. Vijayaraghavan R, Sujatha Y. Acute postpartum uterine inversion with haemorrhagic shock: Laparoscopic reduction: A new method of management? *BJOG* 2006;113:1100-2.
16. Antonelli E, Irion O, Tolck P, Morales M. Subacute uterine inversion: Description of a novel replacement technique using the obstetric ventouse. *BJOG* 2006;113:846-7.
17. Zechmeister JR, Levey KA. Successful robotically assisted laparoscopic correction of chronic uterine inversion. *J Minim Invasive Gynaecol* 2011;18:671-3.

How to cite this article: Kumari A, Vidhyarthi A, Salini KM. Chronic Uterine Inversion Secondary to Submucous Fibroid: A Rare Case Report. *Int J Sci Stud* 2016;3(11):302-304.

Source of Support: Nil, **Conflict of Interest:** None declared.