Print ISSN: 2321-6379
Online ISSN: 2321-595X
DOI: 10.17354/ijss/2017/133

Original Article

Microvascular Reconstruction in the Revascularized Diabetic Foot

K Adhil Ahamed Yameen[1], T Chenthil Sivamuthu[2], Heber Anandan[3]

[1]Tutor, Department of Plastic Surgery, Tirunelveli Medical College Hospital, Tirunelveli, Tamil Nadu, India, [2]Assistant Professor, Department of Plastic Surgery, Tirunelveli Medical College Hospital, Tirunelveli, Tamil Nadu, India, [3]Senior Clinical Scientist, Department of Clinical Research, Dr. Agarwal's Healthcare Limited, Tirunelveli, Tamil Nadu, India

Abstract

Introduction: The reconstruction of diabetic foot after the revascularization is a challenge. Functional reconstruction means to reconstruct the mechanical design to bear weight. This includes reconstruction of skin to the bone of the foot.

Aim: The aim of this study is to study the methods of foot salvage by reconstruction procedures instead of amputation in diabetic foot patients.

Methods: This is the retrospective study of the diabetic foot patients who had undergone revascularization and subsequent reconstruction of foot from January 2003 to February 2014 in Rajiv Gandhi General Hospital and Madras Medical College, Chennai.

Results: Diabetic foot patients who underwent revascularization (angioplasty/bypass) were subjected to debridement (2-3) and followed up after an average latency period of 35-day with appropriate reconstruction procedures.

Conclusion: Following revascularization of the diabetic foot, infection is controlled by debridement and antibiotics. Vacuum-assisted closure therapy is also used in the latency period followed by microvascular free flaps or local flaps to provide stable cover for the diabetic foot. Patient education and orthotic footwear help in preventing recurrences.

Key words: Autonomic neuropathy, Callus formation, Free flaps, Functional microangiopathy, TA Lengthening, Subtotal calcanectomy, Tendo achilles

INTRODUCTION

Diabetes mellitus is diseases with metabolic, vascular, and neuropathic components that are interrelated.[1] One of the largest populations of diabetics in the world is currently in India.[2] Diabetic foot infections are a frequent clinical problem. About 50% of patients with diabetic foot infections who have foot amputations die within 5 years. Properly managed most can be cured, but many patients needlessly undergo amputations because of improper diagnostic and therapeutic approaches.[3] The reconstruction of the diabetic foot after the revascularization is a challenge. Functional reconstruction means to reconstruct the mechanical design to bear weight. This includes reconstruction of skin to the bones of the foot. The decreased vascularity of the foot should be recognized first as this delays the normal healing of the wound. Next step is revascularization and establishment of wound healing potential. Revascularization is done by endovascular or surgical techniques.[4,5] The first option is endovascular. Regional vascular deficiency following revascularization is corrected, and then the functional reconstruction is carried out.[6]

Access this article online

www.ijss-sn.com

Month of Submission : 01-2017
Month of Peer Review : 02-2017
Month of Acceptance : 02-2017
Month of Publishing : 03-2017

Aim

The aim of this study is to study the methods of foot salvage by reconstruction procedures instead of amputation in diabetic foot patients.

MATERIALS AND METHODS

Retrospective study was conducted in Department of Plastic and Reconstructive Surgery, Rajiv Gandhi Government

Corresponding Author: Heber Anandan, No. 10, South By-pass Road, Vannarpettai, Tirunelveli - 627 003, Tamil Nadu, India.
Phone: +91-9894067910. E-mail: clinicalresearch@dragarwal.com

General Hospital and Madras Medical College, Chennai, over a period from January 2003 to February 2014. All the diabetic foot patients who got admitted and had undergone revascularization, and subsequently, had foot defects in need of reconstruction of foot or foot remnants were included. Eexclusion criteria: Those who have undergone revascularization but with comorbid illness complicating anesthesia for foot reconstruction. Patients with renal failure, age more than 70 years were excluded from the study. A detailed proforma was made which includes general information of the patient, any comorbid illness, smoking history, treatment history, provisional diagnosis, general and local examination and investigations undergone. Following information are noted from the case records: type of revascularization procedure, latency period (period before embarking on reconstruction following revascularization), number of debridement done before reconstruction, adjuvant procedures performed, foot reconstruction procedure.

RESULTS

Out of 78 patients included in the study, maximum number of patients, i.e., 34 (43.58%) were in the age group between 56 and 60 years, 27 (34.6%) were in the age group of 51-55 years, 10 (12.82%) were in the age group of 45-50 years, and the remaining 7 (8.97%) fall in the age group between 61 and 65 years. Mean age found in the study is 57.2 years. In our study, the majority of the patients, i.e., 68 (87%) were males and the rest 10 (13%) were females. The majority of the patients were smokers, i.e., 49 (62.82%) and 29 (37.17%) were nonsmokers.

Of the 78 patients, 42 (53.84%) underwent angioplasty and 36 (46.15%) underwent bypass procedures for revascularization (Table 1).

Most of the patients in our study have undergone two debridements 54 (69.23%), while 22 (28.2%) has underwent 3 debridements and 2 of them has undergone single debridement (Table 2).

The average latency period found in our study is 35.36 days. Most of the patients 28 (35.89%) in our study show a latency period between 21 and 30 days (Table 3). In our study, 42 (53.8%) of the cases underwent negative pressure wound therapy in the latency period.

Of the 78 patients - 19 (24.35%), 12 (15.38%), 6 (7.69%), 5 (6.41%), 4 (5.12%), 2 (2.56%), 11 (14.10%), 9 (11.53%), 5 (6.41%), 5 (6.41%) underwent latissimus dorsi flap, radial free forearm flap, gracilis flap, para scapular flap, anterolateral thigh flap, medial plantar artery flap, superior fasciocutaneous flap, reverse superficial sural artery flap, inferiorly based fasciocutaneous flap, perforator flap (Figure 1).

Of the 78 cases, 59 did not undergo any adjuvant procedures, while 7 (8.97%), 9 (11.53%), 3 (3.84%) has undergone tendo-Achilles lengthening, osteotomy, tenotomy (Table 4).

Complications were found in 7 (9%) of the patients, of which 2 of them had ulcer recurrence, 2 of them had hematoma, 1 had wound dehiscence, 1 had partial flap necrosis, and 1 had flap necrosis (Table 5).

DISCUSSION

The mean age found in our study group is 57.2 years. This is similar to other studies such as Oh *et al.*, Randon *et al.*, and Lee *et al.*, conducted a study in 121 patients which

Table 1: Type of revascularization

Type of revascularization	*N* (%)
Angioplasty	42 (53.84)
Bypass	36 (46.15)

Table 2: Number of debridements

Number of debridement	*N* (%)
1	2 (2.56)
2	54 (69.23)
3	22 (28.2)

Table 3: Latency period

Latency period in days	*N* (%)
≤20	2 (2.56)
21-30	28 (35.89)
31-40	27 (34.61)
41-50	13 (16.66)
51-60	8 (10.25)

Table 4: Adjuvant procedures

Adjuvant procedures	Number of patients (%)
TAL	7 (8.97)
OST	9 (11.53)
TEN	3 (3.84)
Nil	59 (75.64)

TAL: Tendo-Achilles lengthening, OST: Ostectomy, TEN: Tenotomy

Table 5: Complications

Complications	*N*
Hematoma	2
Flap necrosis	1
Partial flap necrosis	1
Wound dehiscence	1
Ulcer recurrence	2
Total	7

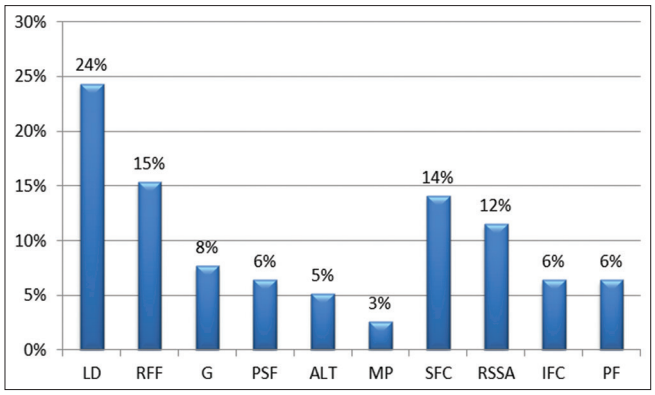

Figure 1: Reconstruction procedures

included the patients of age group 26-78 years and found the mean age to be 54.6 years in their study on diabetic foot reconstruction using free flaps. This is in correlation with the factor that most of the people with diabetes develop peripheral neuropathy 10 years after the onset of the disease leading to the maximum incidence of diabetic ulcers from 50 years onward.[7-9]

The majority of the patients were males 68 (87.17%) and 10 (12.82%) were females in our study. This is in accordance with Randon *et al.* study. In Indian scenario, males are mostly the breadwinners working in fields or as laborers mostly barefoot predisposing to repeated trauma in the neuropathic foot leading to ulcerations.[8]

Majority of the patients, i.e., 49 (62.82%) are found to be smokers in our study. In the study conducted by Oh *et al.*, 34.25% were found to be smokers. Smoking habits are higher in Indian men which predisposes to the peripheral arterial disease, more so in diabetic patients leading to ulcerations.[7]

Revascularization procedures are needed to improve the vascularity to the critically ischemic limb in the diabetics. In non-healing ulcers failing conservative therapy revascularization aids in limb salvage. In our study of the 78 patients, 42 (53.84%) had undergone angioplasty and 36 (46.15%) had undergone bypass procedures. Revascularization improves the limb salvage rate by more than 50%, Illig *et al.*[10]

In our study, the majority of patients underwent two or more debridement to achieve a good wound bed and to reduce infection preceding the reconstructive procedure (Picture 2). The latency period is the time period between the revascularization and reconstruction. This is the period in which wound healing is established due to the improvement in vascularity of the foot. In our study, the average latency period is 35.36 days ranging between 20 and 60 days.

Picture 1: Latissimus dorsi flap

Picture 2: Complex composite reconstruction. Debridement done. 3rd toe removed. Instability of tarsum fixed by external fixator

Negative pressure wound therapy was used in our study in 42 (53.8%) of patients. Negative pressure wound therapy was found to reduce the time taken for wound closure and increase healing (Picture 3).

Reconstruction of the foot after the revascularization is necessary as revascularization alone is not sufficient for the healing and to prevent limb loss. In our study, the reconstruction was carried out by locoregional flaps and free flaps. Microvascular free flap surgery is proven to be safe procedure for providing stable cover to the wounds after revascularization. In our study, 30 patients underwent locoregional flaps and 48 of them underwent free flaps for reconstruction. L. Scott Lewin, Duke University Medical Center, Durham, have found regional flaps to be viable option in treating foot defects with impaired vascularity.[11] In our study, the locoregional flaps done were superiorly based fasciocutaneous flaps were done in 11 cases, inferiorly based fasciocutaneous flaps were done in 5 cases, reverse superficial sural artery flap in 9 cases, perforator flap in 5 cases.

de Blacam *et al.* in her study conducted in Royal College of Surgeons, Dublin, found a flap loss of about 3.2%

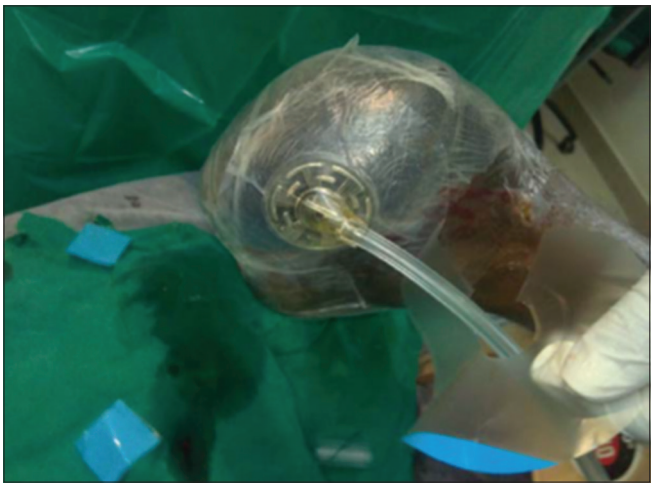

Picture 3: Wound treated with vacuum-assisted closure

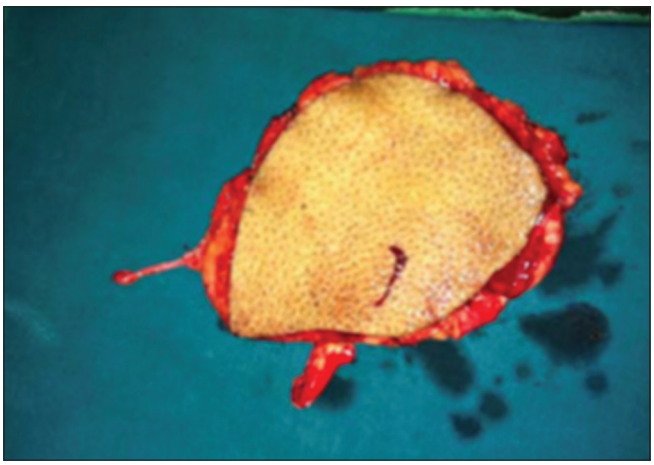

Picture 4: Free anterolateral thigh flap with pedicle and lateral cutaneous nerve forneurotization

Picture 5: After anterolateral thigh transfer (4th post operative day)

with reverse superficial sural artery flap. They also found that distal tip necrosis problem in the reverse superficial sural artery flap in 15.3%.[12] Cohen *et al.* conducted a study in 33 patients with medial plantar artery flap and found that it provides excellent like tissue reconstruction of the foot providing good weight bearing ability. 6 cases had complications in their study.[13]

Free flaps used for reconstruction in our study are free latissimus dorsi muscle flap used in 19 cases (Picture 1), free gracilis muscle flap in 6 cases, radial free forearm flap in 12 cases, para scapular free flap in 5 cases, and free anterolateral thigh flap in 4 cases (Picture 4). Free medial plantar artery flap taken as a free flap from the opposite foot was used in 2 cases to give a like tissue reconstruction. Sunar *et al.* in the study conducted in Trakya University, Turkey, found that the free flap done after revascularization in a delayed setting had benefits like assessment of the patency of the grafts improving wound conditions and reducing the operating time.[14] Oh *et al.* conducted a study of 121 cases with 90 free anterolateral thigh flaps and reported a complication rate of 9% (Picture 5).[7] Prantl *et al.* conducted a study in University of Regensburg, Germany, found that the para scapular flap to be useful to cover defects in the weight bearing area.[15] Czerny *et al.*, University Medical School, Vienna, Austria, conducted a study and found the gracilis muscle flap to be a good option as it can be done under regional anesthesia and minimal morbidity of the donor site.[16] In case of large foot defects latissimus dorsi free muscle flap is the preferred flap.

In our study, complications like hematoma were seen in 2 cases; flap necrosis is seen in reverse superficial sural artery flap. Partial flap necrosis is seen in 1 anterolateral thigh flap, wound dehiscence in 1 perforator flap, ulcer recurrence was found in 2 latissimus dorsi flaps. The overall complication rates were 9%. This is similar to the study done by Oh *et al.*[7]

CONCLUSION

Revascularization of the diabetic foot which is the key to establish the vascularity in ischemic foot also helps in controlling the infection. Infection is also controlled by appropriate antibiotics and wound debridement to remove the necrotic tissues which help in the healing by the formation of granulation tissue. Negative pressure wound therapy is used in the latency period to help in the faster healing. Microvascular free flaps bring in well-vascularized tissue for the stable cover of the diabetic foot with minimal complications where there is a paucity of locally available flaps. Handheld Doppler is adequate for the planning of the reconstructive procedures. Angiogram may not be needed. Adjuvant procedures form an important part in the reconstruction process. Prevention of recurrences is by proper education is the most important. The use of orthotic footwear, silicone gel insoles, and proper off-loading helps in preventing the recurrences.

REFERENCES

1. Holt R. Textbook of Diabetes. 1st ed. Chichester, West Sussex: Wiley-Blackwell; 2010.
2. International Diabetes Federation. IDF Diabetes Atlas, 4th edn. Brussels, Belgium: International Diabetes Federation: 8, 2009. http://archive.diabetesatlas.org/sites/default/files/Figure%202.1_Diabetes%20per%20region_2010-2030.pdf.
3. Diaz JG, Gentry L, Pankey G. Contemporary Diagnosis and Management of Diabetic Foot Infections (Diabetic Foot Infections). 1st ed. Pennsylvania: Associates in Medical Marketing Co., Inc.; 2006.
4. Fisher T, Scimeca C, Bharara M, Mills J, Armstrong D. A step-wise approach for surgical management of diabetic foot infections. J Vasc Surg 2010;52:72S-5.
5. Sheahan M, Hamdan A, Veraldi J, McArthur C, Skillman J, Campbell D, *et al*. Lower extremity minor amputations: The roles of diabetes mellitus and timing of revascularization. J Vasc Surg 2005;42:476-80.
6. Gibbons GW. The diabetic foot: Amputations and drainage of infection. J Vasc Surg 1987;5:791-3.
7. Oh TS, Lee HS, Hong JP. Diabetic foot reconstruction using free flaps increases 5-year-survival rate. J Plast Reconstr Aesthet Surg 2013;66:243-50.
8. Randon C, Jacobs B, De Ryck F, Van Landuyt K, Vermassen F. A 15-year experience with combined vascular reconstruction and free flap transfer for limb-salvage. Eur J Vasc Endovasc Surg 2009;38:338-45.
9. Lee YK, Park KY, Koo YT, Baek RM, Heo CY, Eun SC, *et al.* Analysis of multiple risk factors affecting the result of free flap transfer for necrotising soft tissue defects of the lower extremities in patients with Type 2 diabetes mellitus. J Plast Reconstr Aesthet Surg 2014;67:624-8.
10. Illig KA, Moran S, Serletti J, Ouriel K, Orlando G, Smith A, *et al.* Combined free tissue transfer and infrainguinal bypass graft: An alternative to major amputation in selected patients. J Vasc Surg 2001;33:17-23.
11. Levin LS. Regional flap alternatives to microsurgery in the dysvascular extremity. Oper Tech Plast Reconstr Surg 1997;4:236-49.
12. de Blacam C, Colakoglu S, Ogunleye AA, Nguyen JT, Ibrahim AM, Lin SJ, *et al.* Risk factors associated with complications in lower-extremity reconstruction with the distally based sural flap: A systematic review and pooled analysis. J Plast Reconstr Aesthet Surg 2014;67:607-16.
13. Cohen BK, Zabel DD, Newton ED, Catanzariti AR. Soft-tissue reconstruction for recalcitrant diabetic foot wounds. J Foot Ankle Surg 1999;38:388-93.
14. Sunar H, Aygit CA, Afsar Y, Halici U, Duran E. Arterial and venous reconstruction for free tissue transfer in diabetic ischemic foot ulcers. Eur J Vasc Endovasc Surg 2004;27:210-5.
15. Prantl L, Babilas P, Roll C, Jung M, Nerlich M, Kinner B, *et al.* The use of 'fasciocutaneous' and 'osteofasciocutaneous' parascapular flaps for lower limb reconstruction: A retrospective study of 20 patients. J Plast Reconstr Aesthet Surg 2009;62:973-80.
16. Czerny M, Trubel W, Zimpfer D, Grimm M, Koller R, Hofmann W, *et al.* Limb-salvage by femoro-distal bypass and free muscle flap transfer. Eur J Vasc Endovasc Surg 2004;27:635-9.

How to cite this article: Yameen KA, Sivamuthu TC, Anandan H. Microvascular Reconstruction in the Revascularized Diabetic Foot. Int J Sci Stud 2017;4(12):229-233.

Source of Support: Nil, **Conflict of Interest:** None declared.