

Management of Comminuted Distal Humerus Fracture by Minimal Internal Fixation and External Fixation in the Form of Joshi's External Stabilization System in Older Individual: A Prospective Study

Prasanta Kumar Saha¹, Swagnik Ray², Sudarshan Behara²

¹Associate Professor, Department of Orthopaedics, Calcutta National Medical College and Hospital, Kolkata, West Bengal, India,

²Post-graduate Trainee, Institute of Post Graduate Medical Education and Research, Kolkata, West Bengal, India

Abstract

Introduction: Treatment of fractures of the distal humerus after the age of 60 years is challenging due to osteoporotic bone and comminution of the articular surface. The problem increases several times in the presence of an open fracture or severe soft tissue injury. We present a novel method of surgical treatment of distal humerus fractures in the elderly population by closed reduction or minimal exposure internal fixation with Joshi's external stabilization system (JESS) external fixator to achieve a mobile, functioning elbow joint.

Materials and Methods: This was an institution based, prospective study. Patients with Gustilo Type IIIB and Type IIIC open fracture were excluded. Fractures were reduced and fix with K-wire and finally JESS was applied. Patients were followed up for 1 year and evaluated clinically with Mayo's elbow performance score.

Results: About 75 patients in the age group of more than 60 years were included (35 male and 40 female). 20 patients had the open fracture. Complications included osteomyelitis in 7 cases, iatrogenic radial nerve palsy in 3 cases, and 15 cases of minor pin tract infection. The final recorded range of movement was (10°-100°). Mayo's score at 12 months was excellent in 53.33% (40 cases) and good in 46.67% (35 cases).

Discussion: There are several methods of treatment of distal humerus fracture. Olecranon pin traction or collar and cuff method result in quite good result. In open fracture, total elbow replacement (TER) or open reduction and internal fixation (ORIF) is contraindicated. Very few studies were published regarding JESS management. Our study shows good result both in open and close fracture according to Mayo score.

Conclusion: We recommend this procedure as an alternative to total elbow arthroplasty and ORIF, especially in the open fracture. Our study population is small. Further study with large population and control group is needed.

Key words: Distal humerus fracture, Joshi's external stabilization system, Old patient

INTRODUCTION

Approximately 7% of all adult fractures involve the elbow. Of these, approximately one-third involves the distal

humerus. Distal humerus fracture, therefore, comprises approximately 2% of all fractures with equivalent male to female ratio with bimodal age distribution 12-19 years and >80 years.¹ Incidence of partial articular distal humerus fractures is 1.5/100,000 population with a marked female predominance.^{1,2}

The management of distal humerus fractures produces significant challenges due to extensive soft tissue dissection and blood loss. Reduced bone stalk due to the amount of used implants (especially in osteoporotic bones and small fragments), prolonged surgery and tourniquet time,

Access this article online



www.ijss-sn.com

Month of Submission : 03-2016

Month of Peer Review : 04-2016

Month of Acceptance : 05-2016

Month of Publishing : 05-2016

Corresponding Author: Dr. Prasanta Kumar Saha, Golden View Apartment, 2nd Floor, Room No. 305, T. N Mukherjee Road, Monoharpur, (Near HDFC Bank), Dankuni, Hoogly – 712 311, West Bengal, India. Phone: +91-9903151908.

E-mail: prasantakumarsahaortho@gmail.com

common occurrence of post-operative elbow stiffness, neurovascular injury (especially ulnar nerve), increased chance of post-operative infection, and problem in soft tissue healing lead to suboptimal result.³⁻⁸

These challenges become more significant in the pretext of the elderly with compromised soft tissue and medical comorbidity, so much so that some authors have advocated conservative managements of such fractures in the past.⁵⁻⁷ The treatment options of a distal humerus comminuted fracture includes the following method: Conservative, olecranon pin traction, K-wire fixation, open reduction and internal fixation (ORIF), and elbow spanning external fixation (this method is only preferred for open fractures).¹⁻¹⁰ Total elbow replacement (TER) is contraindicated in an open fracture. Conservative treatment leads to nonunion and stiff elbow because reduction and early movement are nearly impossible. Olecranon pin traction usually leads to a bag of bones.

Among these, open reduction internal fixation with plating is well accepted as the standard treatment for these fractures because it is based on AO principles of intra-articular fracture fixation-absolute anatomic reduction, rigid fixation, and early mobilization.^{1,2} However, this technique is often associated with inferior post-operative results in older osteoporotic patients due to increased OT time, increased chance of infection, increased bleeding, if tourniquet is applied - tourniquet-related complications, post-operative adhesion – decreased mobility - elbow stiffness, in osteoporotic bones hardware loosening.^{3,8} Joshi's external stabilization system (JESS) appears to be an interesting option in such cases.

This randomized prospective study evaluates the results of intercondylar comminuted fractures treated with minimal internal fixation with 4 mm CC screws and external fixation with K-wires, connecting rods, and JESS distractors.¹¹⁻¹⁴

MATERIALS AND METHODS

This was an institution based, prospective longitudinal study. The study was conducted in our institution after getting ethical permission. All the patients were counseled about the advantages, disadvantages, and complications of the procedure. After getting written consent from patients, we performed JESS procedure. The study period from January 2014 to January 2015 (24 months duration).

Inclusion criteria of our study were AO/ASIF fracture Type 13- A to C. Patients above age 60 years with osteoporotic bone and significant medical comorbidity demanding short surgery time were included. Open

fractures up to Gustillo-Anderson Type IIIA and Tscherne Grade II-III soft tissue injury in closed fractures were also included. Exclusion criteria were age below 60 years, Gustillo Anderson Type IIIB and IIIC fractures, Tscherne Grade I soft tissue injury for closed fractures, and patients having additional fractures on the same limb.

Patients were operated either in the supine position with limb placed on side table or in lateral position secured with side guards and sand bags under general anesthesia/ brachial block. Closed reduction of the articular fragments was attempted under fluoroscopic guidance on each step by traction and counter traction with an elbow in 30° flexion. One K-wire was partially inserted under fluoroscopic guidance from the medial side into the condyle and then used as a joystick to reduce the medial fragment with respect to the lateral through a small stab wound, the ulnar nerve was protected by retracting it under the thumb. Percutaneous pointed reduction clamp was used to maintain the temporary reduction; the same K-wire was then advanced through and through to hold the two distal fragments together. In some cases, another K-wire or 3 mm cannulated cancellous screw was introduced for better hold on the distal articular fragments parallel to the first one. Two parallel diaphyseal K-wires were introduced medial to lateral parallel to the joint line and intercondylar K-wires. One lateral and one medial pillar K-wires were introduced through stab wounds to hold any additional fragments and to make a temporary hold of the condylar fragment with the diaphyseal fragment taking proper precautions (Figure 1). The K-wires are then connected with one medial and one lateral connecting rod through clamps; JESS distractors are used in some cases in place of connecting rods if compression to one side or the other is required (Figure 2).

Patients are encouraged to actively flex and extend the elbow from the third post-operative day. Post-operative antibiotic prophylaxis was continued up to day 3. The patients were discharged after the subsidence of the initial swelling with training on proper pin tract care. Patients were followed up on the 4th week and then at 2, 3, 6, and 12 months and evaluated clinically with Mayo's elbow performance score and radiologically for quality and time for union and range of movement (ROM). The implants were removed after viewing early signs of fracture union on X-ray plates and after clinically evaluating the distal humerus for the absence of local tenderness.

The short- and long-term benefits of minimum intervention fixation in the form of JESS in open and close comminuted distal humerus fracture with the help Mayo's elbow performance score, duration of Hospital stay, surgery time,

time taken for the union of fractures and removal of the external fixator.

RESULTS

About 75 patients in the age group of more than 60 years were included in this study (35 male and 40 female). 20 patients had the open fracture. According to Gustilo Anderson classification, 12 cases were Type II and 8 cases were Type IIIA. Among 55 closed fractures, 30 patients had soft tissue injury. According to Tschernke classification of soft tissue injury in closed fracture, 20 cases were Grade – II and 10 cases were Grade – III. The fracture patterns according to AO (Arbeitsgemeinschaft für Osteosynthesefragen) classification were 13-A2) 10 cases, (13-B2) 15 cases, (13-C1) 25 cases, (13-C2) 15 cases, (13-C3) 10 cases, respectively.

All patients with distal humerus comminuted fracture were treated by JESS fixation. The average follow-up period was

16 months (minimum 12 months and maximum 2 years). The minimum hospital stay was 10 days and maximum 60 days (≤ 14 days in 53.3% and >28 days in 20%). Longer hospital stay was observed in open fracture group. The shortest recorded surgery time was 20 min and the longest recorded surgery time was 90 min (Table 1). The surgery time was ≤ 30 min in 66.67% patients. 60 cases (80%) required no blood transfusion. 8 cases (10.67 %) required 2 unit of blood transfusion (fracture Type Gustillo IIIA) and 7 cases (9.3%) required 1 unit of blood transfusion (fracture Type Gustillo II). The earliest external fixator removal time was 60 days and the longest recorded time was 140 days. In 73% of cases, the external fixator was removed by 90 days. All fractures were united. Earliest recorded time of union as determined by clinical and radiological evaluation was 3 months and the longest recorded time was 6.5 months. 66% cases were united by 3.5 months. 13.3% cases demonstrated infected union at 6.5 months belonging to the open fracture category. Seven fractures later need bone grafting. The patients (46.67% cases) with mean time of union 3.2 months demonstrated excellent results in Mayo’s elbow performance score in comparison to the patients (53.3% cases) with mean time of union 3.8 months who demonstrated a good score.

Complications included osteomyelitis (9.3%) in 7 cases of open fractures (GA Type IIIA -5 cases, Type II- 2 cases), iatrogenic radial nerve palsy in 3 cases (4%) that resolved after 3 months of conservative management. 15 cases (20%) of minor pin tract infection which resolved after conservative management without any residual damage.

The final recorded ROM was 10° - 100° , whereas the best recorded ROM was 0° - 120° . In 66.67% cases, the mean ROM was $\geq 100^{\circ}$. Mayo’s score at 3 months was excellent in 46.67%, good in 46.67%, fair in 6.67%. Mayo’s score at 12 months was excellent in 53.33 % (40 cases) and good in 46.67 % (35 cases). 80% of fractures (60 cases) were united without any complications (Figure 3).

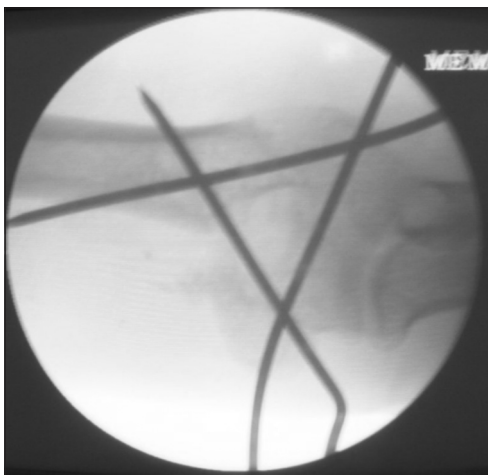


Figure 1: Fixation of articular fragments with diaphyseal fragments with the help of pins placed on medial and lateral pilla

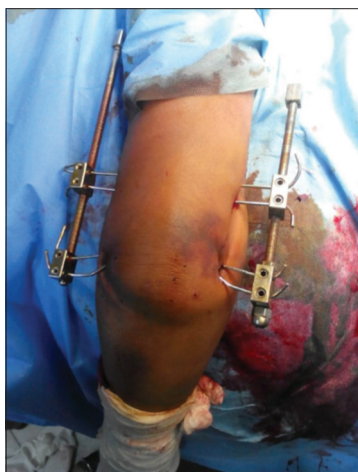

Figure 2: Final construct

DISCUSSION

The goal of intra-articular fractures management is to achieve early motion of anatomically aligned joint. The

Table 1: Comparing mean surgery time with AO type of fracture patterns in the study group

AO fracture type	Number of patients	Mean surgery time
13-A2	10	60.00
13-B2	15	81.66
13-C1	25	58.00
13-C2	15	60.00
13-C3	10	70.00

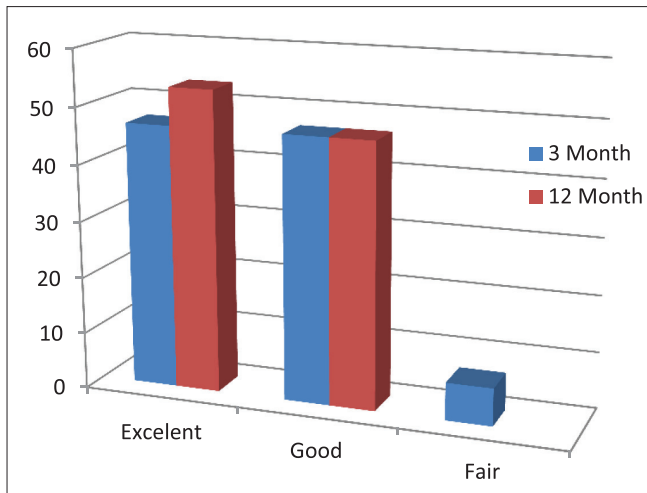


Figure 3: Mayo elbow score

surgical principle is anatomical reduction and fixation with the absolute stability of the articular fragments and attachment of the congruent aligned joint block to the diaphysis using relative or absolute stability according to the fracture pattern. Therefore, ORIF is the mainstay treatment of comminuted distal humerus fracture even though the challenges it present can be quite significant, especially in elderly/comorbid/compromised patients. Soft tissue damage, prolonged surgical time, prolonged tourniquet time, fracture comminution, coupled with osteopenic bone and poor compliance with post-operative physical therapy programs have contributed to suboptimal results. Studies published by authors recognize these difficulties and has often recorded results less than satisfactory in these particular groups of patients.² Controversy exists regarding the ability of internal fixation to achieve excellent outcomes predictably in these patients. Since 2008, numerous authors have published their findings on external fixation as an alternate management mode for this complex group of fractures.^{1,3}

Non-operative treatment is based on “bag of bone” principal. Two common methods include olecranon pin traction and collar and cuff. In olecranon pin traction method, traction continues until the fractures are sufficiently “sticky” and then convert to a functional cast, cast brace, or hinged brace and controlled motion is encouraged. In collar and cuff method, the limb is suspended in a collar and cuff in as much flexion as possible. The principal is ligamentotaxis effect by gravity. The cuff is removed after 6 weeks, and the elbow is then mobilized. Good results have been reported using this method in the osteoporotic setting.⁷ It often results either in a united fracture with joint stiffness and poor function or in nonunion of the fracture with a painful pseudarthrosis. In the presence of open fracture, the “bag of principal” is not working.

Although ORIF is the gold standard in distal humerus fractures, in elderly osteoporotic patient pose a treatment challenge. Pajarinen and Bjorkenheim found that age over 50, poor bone quality, and immobilization was poor prognostic factors for success of ORIF.¹⁵ Korner *et al.* says screw loosening and implant failure at the lateral column are predominantly post-operative complication in a retrospective study of 45 patients over age 60 years. They observe joint immobilization longer than 14 days and severe joint involvement (previous arthritis of joint, severe comminution) are the main factors for poor outcome. However, they found good to excellent functional results in ORIF of distal humerus fractures in elderly patients. They conclude that ORIF should be the first choice unless otherwise contraindicated since good elbow function can be achieved in the majority of patients.¹⁶ Jupiter and Ring recommended found full range of motion intraoperatively, and they recommend a period of cast immobilization.¹⁷ In contrast, other authors reported worse results on non-operated patients versus operated patients in terms of pain, function, and range of motion.¹⁸ From the literature, it is evident that anatomical reduction of the articular fragment and early movement is the keystone for good result. However, in the case of open fracture, no standard treatment has been advised in literature.

Other authors suggested spanning hinged external fixators to allow immediate movement of the elbow joint. Stavlas *et al.* reported using hinged external fixators for the treatment of osteoporotic fractures and fracture dislocation as a salvage procedure with good results.¹⁹ Lerner *et al.*²⁰ reported using a hinged hybrid external fixator in seven young patients with high-energy trauma and a floating elbow. They found the results to be excellent in two patients; good in one patient and fair in four patients. Although this method is similar to our method, the indication is quite different. The external fixator, although hinged, crosses the elbow joint. Zhao *et al.* reported 24 patients with comminuted intra-articular fractures (Type C on AO/ASIF classification) treated with crossed K-wires for the condylar metaphysis and double tension band osteosynthesis for fixation of the metaphysis block to the shaft. Excellent or good results were achieved in 83% of patients with comparable complications.²¹

Another mode of treatment in severely comminuted, osteoporotic fracture is TER. Several authors have reported good to excellent results with elbow arthroplasty with none to mild pain postoperatively.²² In a study, comparing primary total elbow arthroplasty (TEA) versus primary osteosynthesis of Type C distal humerus fractures in

female patients above age 65, 11 of 12 patients undergoing TER had excellent results, whereas only 4 patients of 12 treated with ORIF were excellent, and three required revision to TER.²³ No patients with TER required revision surgery. Garcia *et al.*, after treating 19 consecutive patients, concluded that “primary TEA is an acceptable option for the management of comminuted fractures of the distal humerus in elderly patients when the configuration of the fracture and the quality of the bone make reconstruction difficult.”²⁴

Our described method of treatment answers all the principals of the fracture management goals. Anatomical joint surface reduction is achieved and fixed with absolute stability by 4 mm cancellous screw. The joint block is re-attached to the diaphysis with JESS fixator. This method has the advantages of minimal collateral soft tissue damage, minimal disturbing of fracture hematoma and preserving blood supply of fragments. This encourages early healing of the fracture. An added benefit is early unlimited range of motion is possible as the assembly is very stable as a result chance of joint stiffness is very less even in the open fracture.

Our study has several limitations. First, the study population is relatively very small and absence of control group. We find the results are good enough to recommend its use, especially in open fracture or fracture with severe soft tissue injury, considering the other alternatives. We did not conduct a prospective, randomized study comparing our method with ORIF, TER, or non-operative management.

CONCLUSION

Our experience shows good results using this minimally invasive technique. The advantages of this technique are the immediate mobilization of the elbow joint and the rapid return to activities of daily living.

There is no published data about results of closed reduction and external fixation of distal humerus fractures in elderly patients using JESS external fixation. Komurco *et al.* described method Ilizarov external fixator as a treatment option for open, comminuted gunshot wound of the elbow with about 42% good results.²⁵ Lerner *et al.* described Ilizarov method on high energy, floating elbow in young adults with good results.²⁰

We recommend this treatment as an alternative to ORIF and TEA in elderly, osteoporotic patients due to its simplicity, short hospitalization, low complication rate, low costs, and good functional results.

REFERENCES

1. Buchholz RW. Rockwood and Green's Fractures in Adults. 8th International Edition. Pennsylvania, PA: Wolters Kluwer Health; 2014.
2. Canale TS. Campbell's Operative Orthopaedics. 12th ed. St Louis: Mosby; 1998.
3. Södergård J, Sandelin J, Böstman O. Postoperative complications of distal humeral fractures 27/96 adults followed up for 6 (2-10) years. Acta Orthop Scand 1992;63:85-9.
4. Kundel K, Braun W, Rüter A, Wieberneit J. Intraarticular distal humerus Fractures: Factors Affecting Functional Outcome. Clin Orthop Relat Res 1996;332:200-8.
5. Eastwood WJ. The T-shaped fracture of the lower end of the humerus. J Bone Joint Surg 1937;19:364-9.
6. Riseborough EJ, Radin EL. Intercondylar T fractures of the humerus in the adult: A comparison between operative and non-operative treatment in 29 cases. J Bone Joint Surg Am 1969;51:130-41.
7. Brown RF, Morgan RG. Intercondylar T-shaped fractures of the humerus. Results in ten cases treated by early mobilisation. J Bone Joint Surg Br 1971;53:425-8.
8. Babhulkar S, Babhulkar S. Controversies in the management of intra-articular fractures of distal humerus in adults. Indian J Orthop 2011;45:216-25.
9. Saragaglia D, Rouchy RC, Mercier N. Fractures of the distal humerus operated on using the Lambda® plate: Report of 75 cases at 9.5 years follow-up. Orthop Traumatol Surg Res 2013;99:707-12.
10. McKee MD, Veillette CJ, Hall JA, Schemitsch EH, Wild LM, McCormack R, *et al.* A multicenter, prospective, randomized, controlled trial of open reduction--internal fixation versus total elbow arthroplasty for displaced intra-articular distal humeral fractures in elderly patients. J Shoulder Elbow Surg 2009;18(1):3-12.
11. Joshi BB. Joshi's external stabilization system- controlled differential fractional distraction for correction of talipesequinovarus” and “Basic techniques of Jess system” 1st International Edition written by Dr. B.B. Joshi.
12. Burg A, Berenstein M, Engel J, Luria T, Salai M, Dudkiewicz I, *et al.* Fractures of the distal humerus in elderly patients treated with a ring fixator. Int Orthop (SICOT) 2011;35:101-6.
13. Chaudhary S, Patil N, Bagaria V, Harshavardhan NS, Hussain N. Open intercondylar fractures of the distal humerus: Management using a mini-external fixator construct. J Shoulder Elbow Surg 2008;17:465-70.
14. Ghosh S, Patar M. Management of supracondylar fracture of humerus with JESS in adults. J Sci Study 2015;42:16-20.
15. Pajarinen J, Björkenheim JM. Operative treatment of type C intercondylar fractures of the distal humerus: Results after a mean follow-up of 2 years in a series of 18 patients. J Shoulder Elbow Surg 2002;11:48-52.
16. Korner J, Lill H, Muller LP, Hessmann M, Kopf K, Goldhahn J, *et al.* Distal humerus fractures in elderly patients: Results after open reduction and internal fixation. Osteoporos Int 2005;16:S73-9.
17. Ring D, Jupiter JB. Fractures of the distal humerus. Orthop Clin North Am 2000;31:103-13.
18. Srinivasan K, Agarwal M, Matthews SJ, Giannoudis PV. Fractures of the distal humerus in the elderly: Is internal fixation the treatment of choice? Clin Orthop Relat Res 2005;434:222-30.
19. Stavlas P, Gliatis J, Polyzois V, Polyzois D. Unilateral hinged external fixator of the elbow in complex elbow injuries. Injury 2004;35:1158-66.
20. Lerner A, Stahl S, Stein H. Hybrid external fixation in high-energy elbow fractures: A modular system with a promising future. J Trauma 2000;49:1017-22.
21. Zhao J, Wang X, Zhang Q. Surgical treatment of comminuted intra-articular fractures of the distal humerus with double tension band osteosynthesis. Orthopedics 2000;23:449-52.
22. Lee KT, Lai CH, Singh S. Results of total elbow arthroplasty in the treatment of distal humerus fractures in elderly Asian patients. J Trauma 2006;61:889-92.
23. Frankle MA, Herscovici D Jr, DiPasquale TG, Vasey MB, Sanders RW. A comparison of open reduction and internal fixation and primary total elbow arthroplasty in the treatment of intra-articular distal humerus fractures in women older than age 65. J Orthop Trauma 2003;17:473-80.

24. Garcia JA, Mykula R, Stanley D. Complex fractures of the distal humerus in the elderly. The role of total elbow replacement as primary treatment. *J Bone Joint Surg Br* 2002;84:812-6.
25. Komurcu M, Yanmis I, Atesalp AS, Gur E. Treatment results for open comminuted distal humerus intra-articular fractures with Ilizarov circular external fixator. *Mil Med* 2003;168: 694-7.

How to cite this article: Saha PK, Ray S, Behara S. Management of Comminuted Distal Humerus Fracture by Minimal Internal Fixation and External Fixation in the Form of Joshi's External Stabilization System in Older Individual: A Prospective Study. *Int J Sci Stud* 2016;4(2):34-39.

Source of Support: Nil, **Conflict of Interest:** None declared.