Original Article

DOI: 10.17354/ijss/2016/291

Diagnostic Evaluation of Articular Cartilage of the Knee Joint: Value of Adding T2 Mapping Sequence to a Routine Magnetic Resonance Imaging Protocol

Abdul Khader Farook[1], Lakshmi Aparna Kandru[2], Vivek Elangovan[3], Abubacker Sulaiman Farook[4], Praveen Kumar Magudeeswaran[3]

[1]Assistant Professor, Department of Orthopaedics, Shri Sathya Sai Medical College and Research Institute, Kanchipuram, Tamil Nadu, India, [2]Under-graduate, Department of Radiology and Imaging Sciences, Chettinad Hospital and Research Institute, Kelambakkam, Kanchipuram, Tamil Nadu, India, [3]Post-graduate, Department of Radiology and Imaging Sciences, Chettinad Hospital and Research Institute, Kelambakkam, Kanchipuram, Tamil Nadu, India, [4]Associate Professor, Department of Radiology and Imaging Sciences, Chettinad Hospital and Research Institute, Kelambakkam, Kanchipuram, Tamil Nadu, India

Abstract

Introduction: Hyaline cartilage defects are one of the causes of knee pain. Articular cartilage pathology may be the result of degeneration or due to acute injury. Magnetic resonance imaging (MRI) is a non-invasive technique for the evaluation of degenerative changes in the articular cartilage of knee and articular cartilage pathology.

Aim: The aim of this study is assessing the value of adding T2 mapping sequence to a routine MRI protocol of knee for the diagnostic evaluation of articular cartilage of the knee joint.

Materials and Methods: A retrospective analysis of the patients with the history of knee injury and features suggestive of osteoarthritis referred to MRI knee has been taken for the study. Informed consent will be obtained from the participating subjects before any study related procedure. Patients will be imaged in GE signa 1.5 Hdxt MRI modality equipped with transmit-receive knee coil with the routine MRI knee protocol and with add up to T2 mapping sequence. The results obtained were subjected for radiological interpretation.

Result: In this imaging study of hyaline cartilage, the early degenerative changes in cartilage and other defects in cartilage were successfully demonstrated with T2 mapping sequence. The majority of the patients had cartilage defects which were due to early degenerative changes in cartilage and any injury to the cartilage were clearly demonstrated by T2 mapping sequence.

Conclusion: Addition of an extra sequence called T2 Mapping to a routine MRI protocol of knee at 1.5 tesla improved the sensitivity for the detection of cartilage defects and early degenerative changes in cartilage of knee.

Key words: Cartilage defects, Degeneration, Magnetic resonance imaging, Osteoarthritis, T2 Mapping

INTRODUCTION

Osteoarthritis is an important cause of disability in our society and marked by degeneration of articular cartilage. Articular cartilage pathology may be the result of degeneration or due to acute injury. Imaging of the hyaline cartilage of knee has become an essential part of magnetic resonance imaging (MRI). MRI is a non-invasive technique for the evaluation of degenerative changes in the articular cartilage of knee and articular cartilage pathology.[1-3] Whereas routine MRI techniques provide an accurate evaluation of the lesions of the articular cartilage as compared to the arthroscopy. With the development of the advanced pharmacologic therapies and surgical methods for cartilage repair, there is a raising demand in developing quantitative MRI techniques that are sensitive to early structural degeneration in articular cartilage.[4-5]

T2 mapping of hyaline cartilage is an imaging technique for the qualitative and quantitative detection of the cartilage.

Access this article online

www.ijss-sn.com

Month of Submission : 03-2016
Month of Peer Review : 04-2016
Month of Acceptance : 05-2016
Month of Publishing : 05-2016

Corresponding Author: Dr. Abubacker Sulaiman Farook, Department of Radiology and Imaging Sciences, Chettinad Hospital and Research Institute, Kelambakkam, Kanchipuram - 603 103, Tamil Nadu, India. Phone: +91-9710754999. E-mail: fasulaiman@hotmail.com

The articular cartilage is composed of cartilage cell and extracellular matrix including water, type II collagen, and proteoglycan. The collagen has layer-dependent structure spherical cells with vertical direction against the subchondral bone plate in deep zone, flatter cell more rounded random in direction and thick collagen fibrils in the middle zone, and flat cell in parallel direction to the articular surface in the superficial zone.

Water content is high in the superficial zone and low in deep zone. In contrast, proteoglycan content is low in the superficial zone and high in the deep zone. T2 mapping can detect the changes in water content and collagen matrix ultra-structure associated with early cartilage degeneration. T2 mapping can detect the changes in the chemical composition and structure of the cartilage and can serve as image markers of cartilage degeneration.

Cartilage T2 mapping is one of the major quantitative techniques and provides convincing color mapping and quantitative detection of the cartilage mainly regarding architecture and volume of collagen fiber and water distribution.

In the early stage of degenerative changes, pathological changes with decrease of proteoglycan, disruption of collagen structure, and increase/decrease of water distribution are observed.

In normal cartilage of the adult human, cartilage T2 is approximately 35 ms to 70 ms at 1.5T MRI. The abnormal T2 increase is seen in the elderly population and patients with osteoarthritis. Detection of pathology and treatment planning in consideration of biomechanical environment is important. The main purpose of this study is to add up an extra sequence called T2 mapping with the routine MR sequences of knee to find out the diagnostic value of articular cartilage of knee.[6-7]

MATERIALS AND METHODS

MRI of 34 patients from January 2016 to April 2016 (retrospective analysis) with clinical suspicion of osteoarthritis and with the history of knee injuries from Chettinad Hospital and Research Institute, were included in the study. Informed consent will be obtained from the participating subjects before any study related procedure. Patients referred to MRI knee were imaged in GE Signa 1.5 Hdxt scanner with the routine knee protocol (proton-density-weighted sagittal and axial series, T2-weighted sagittal and coronal series, and T1-weighted coronal series) and with add up sequence axial multislice multi-echo spin-echo measurement to determine the T2 relaxation time of the patellar cartilage. MR images and T2 maps of patellar cartilage were assessed for focal lesions. The lesions were assessed for lesion width (mm), lesion depth (1/3, 2/3, or 3/3 of cartilage thickness), and T2 value (20-40 ms, 40-60 ms, or 60-80 ms) based on visual evaluation. Lesions are classified into 3 grades according to the T2 relaxation time within the lesion: First grade 20-40 ms, second grade 40-60 ms, and third grade 60-80 ms. The images obtained were subjected to radiological analysis and interpretation.

Sample Selection

Inclusion criteria

Patients referred for MRI knee study with the history of knee injury and features suggestive of osteoarthritis.

Exclusion criteria

- Patients with any H/O Metallic implants
- Patients with known cardiac pacemaker
- Pregnant women
- Claustrophobic patients.

Statistical Analysis

Articular cartilage assessment in 34 patients, using multi-echo sequence was evaluated by 2 radiologists. (Sensitivity, specificity, and accuracy were 84%, 90%, and 96%, respectively, for observer A and 78%, 92%, and 90%, respectively, for observer B), so based on clinical findings, the sensitivity and specificity of MRI in articular cartilage assessment were 97.4% and 100%, respectively. Grading between the multi-echo method of the cartilage relative to the routine sequence with MRI was excellent ($K = 0.82$; 95% confidence interval, 0.66-1.00). A statistically significant difference was found between the routine sequence and the cartilage mapping (Fisher's exact test, $P < 0.001$).

RESULT AND DISCUSSION

In this imaging study of hyaline cartilage, the early degenerative changes in cartilage and other defects in cartilage were successfully demonstrated with T2 mapping sequence. The majority of the patients had cartilage defects which were due to early degenerative changes in cartilage

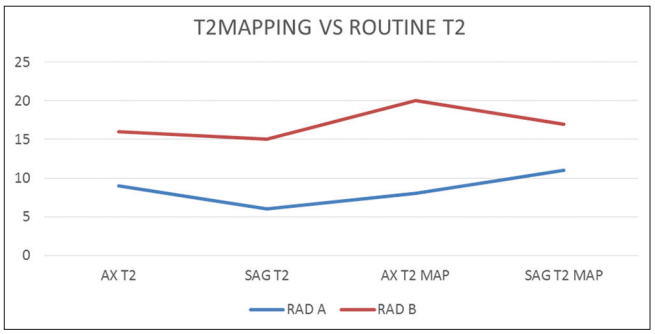

Figure 1: Line graph demonstrating radiologist comparison between two sequences

and any injury to the cartilage were clearly demonstrated by T2 mapping sequence.

In this study, T2 mapping was capable of diagnosing all lesions that were visible on routine knee MRI protocol. However, generally the T2 lesions appeared wider, and some T2 lesions were not revealed on the routine knee MRI protocol. This indicates that T2 mapping is reasonable in the clinical setting and may detect cartilage lesions not seen in routine knee MRI protocol.

T2 mapping revealed important cartilage changes below the defects. T2 mapping is helpful in determination of the exact lesion size when considering cartilage repair operations. T2 mapping does not need any particular patient preparation or administration of contrast agents. The imaging of T2 mapping can be held at a common clinical 1.5T scanner and T2 maps were calculated. Multislice T2 relaxation time mapping with its 5 min imaging time in one plane makes it attractive and reasonable addition to the clinical knee MRI protocol. Therefore, T2 mapping provides important additional information on cartilage lesions visible in routine knee MRI and may serve to denote the nature of cartilage lesions.

Cartilage is important factor in any joint disease. Indications for MRI of the cartilage include both the detection of cartilage damage and monitor treatment such as cartilage repair procedures and pharmacological therapies. Early identification of cartilage damage, either post traumatic or degenerative, is indispensable for treatment at an early stage of osteoarthritis. Both quantitative and qualitative measurements of the cartilage are needed for the follow-up of disease progression and its response to treatment.[8-10]

Conventional MRI scan of the cartilage allows quantitative evaluation. It provides information about the shape and thickness of the cartilage and gives information about the cartilage defects. Currently used conventional MR cartilage imaging techniques such as proton density and 3D spoiled gradient echo sequences with or without fat suppression are insensitive to intra-substance alterations of cartilage composition. This is an important early marker for degenerative joint disease and suggests that qualitative assessment of cartilage is necessary. T2 mapping defined the sensitivity to the biochemical and structural changes in the extracellular cartilage matrix and thus have the potential to serve as image markers of cartilage degeneration.[11-12]

Cartilage T2 mapping has been used to diagnose cartilage at risk and cartilage with irreversible damage. It is extremely useful in the evaluation of functional potential, especially in young patients and sportsmen. Therefore, it can be used as a non-invasive tool to study cartilage composition of repair tissue post cartilage repair procedures or to monitor the effect of chondroprotective therapy. Cartilage T2 mapping of knee joint may also have clinical research applications in the study of arthritis and may give novel information that improves understanding of the pathophysiology of generalized osteoarthritis. (Figures 1-5)

LIMITATIONS

The limitation of this study is that the cartilage findings at T2 mapping and standard MRI knee were not confirmed with arthroscopy. While arthroscopy could be used to detect cartilage defects, it would be inadequate to assess

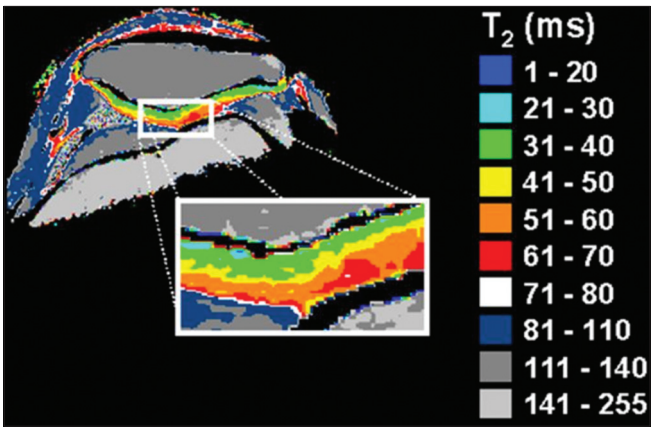

Figure 2: Normal cartilage mapping color coding with various echo-time

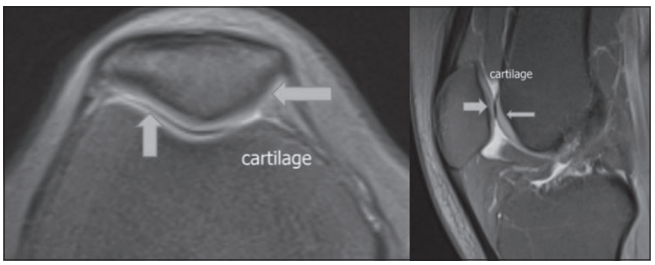

Figure 3: Axial and sag PD FS images of normal patellar cartilage indicated in green arrow

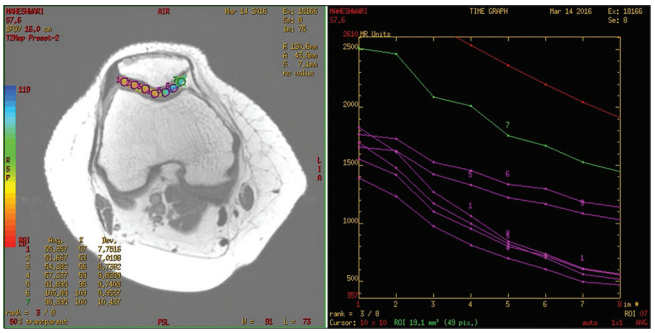

Figure 4: Axial multi-echo sequence with multiple regions of interest and the values demonstrated in the graph

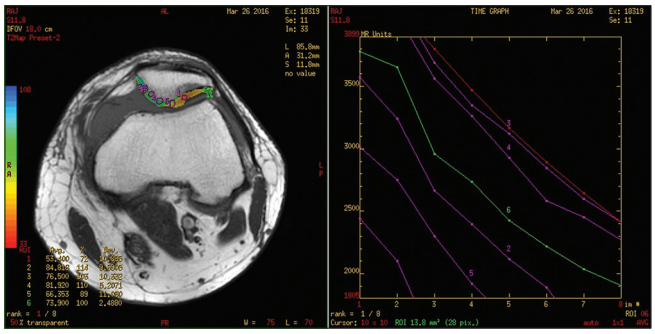

Figure 5: Axial multi-echo sequence with multiple regions of interest and the values demonstrated in the graph

for early or subtle intrinsic cartilage abnormalities as shown on T2 maps.

CONCLUSION

Diagnosis of early cartilage degeneration and evaluation of defects of cartilage in knee are helpful for patients and clinician in understanding, monitoring, and treatment of disease. T2 mapping sequence is useful for better detection of cartilage pathology. Finally, our study shows that better diagnostic information of hyaline cartilage can be obtained by adding up an extra sequence called T2 mapping to the routine MRI protocol of knee.

REFERENCES

1. Xia Y, Moody JB, Burton-Wurster N, Lust G. Quantitative *in situ* correlation between microscopic MRI and polarized light microscopy studies of articular cartilage. Osteoarthritis Cartilage 2001;9:393-406.
2. Smith HE, Mosher TJ, Dardzinski BJ, Collins BG, Collins CM, Yang QX, *et al.* Spatial variation in cartilage T2 of the knee. J Magn Reson Imaging 2001;14:50-5.
3. Mosher TJ, Smith H, Dardzinski BJ, Schmithorst VJ, Smith MB. MR imaging and T2 mapping of femoral cartilage: *In vivo* determination of the magic angle effect. AJR Am J Roentgenol 2001;177:665-9.
4. Kneeland JB. Articular cartilage and the magic angle effect. AJR Am J Roentgenol 2001;177:671-2.
5. Mlynárik V. Magic angle effect in articular cartilage. AJR Am J Roentgenol 2002;178:1287.
6. Goodwin DW, Dunn JF. MR imaging and T2 mapping of femoral cartilage. AJR Am J Roentgenol 2002;178:1568-9.
7. Xia Y. Magic-angle effect in magnetic resonance imaging of articular cartilage: A review. Invest Radiol 2000;35:602-21.
8. Bashir A, Gray ML, Burstein D. Gd-DTPA2 - As a measure of cartilage degradation. Magn Reson Med 1996;36:665-73.
9. Bashir A, Gray ML, Boutin RD, Burstein D. Glycosaminoglycan in articular cartilage: *In vivo* assessment with delayed Gd(DTPA)(2-)-enhanced MR imaging. Radiology 1997;205:551-8.
10. Trattnig S, Mlynárik V, Breitenseher M, Huber M, Zembsch A, Rand T, *et al.* MRI visualization of proteoglycan depletion in articular cartilage via intravenous administration of Gd-DTPA. Magn Reson Imaging 1999;17:577-83.
11. In den Kleef JJ, Cuppen JJ. RLSQ: T1, T2, and rho calculations, combining ratios and least squares. Magn Reson Med 1987;5:513-24.
12. Deoni SC, Rutt BK, Peters TM. Rapid combined T1 and T2 mapping using gradient recalled acquisition in the steady state. Magn Reson Med 2003;49:515-26.

How to cite this article: Farook AK, Kandru LA, Elangovan V, Farook AS, Magudeeswaran PK. Diagnostic Evaluation of Articular Cartilage of the Knee Joint: Value of Adding T2 Mapping Sequence to a Routine Magnetic Resonance Imaging Protocol. Int J Sci Stud 2016;4(2):233-236.

Source of Support: Nil, **Conflict of Interest:** None declared.