Original Article

DOI: 10.17354/ijss/2015/501

Management of Simple Ovarian Cyst with Ultrasonography Guided Aspiration and Sclerotherapy with Tetracycline

Vivek Patre[1], Abha Singh[2], Tripti Nagaria[2], Renuka Gahine[3], Satya Bhuwan Singh Netam[1], Vibha Patre[4], Naresh Vatwani[5]

[1]Associate Professor, Department of Radio-Diagnosis, Pt. Jawahar Lal Nehru Memorial Medical College, Raipur, Chhattisgarh, India, [2]Professor, Department of Obstetrics and Gynaecology, Pt. Jawahar Lal Nehru Memorial Medical College, Raipur, Chhattisgarh, India, [3]Professor, Department of Pathology, Jawahar Lal Nehru Memorial Medical College, Raipur, Chhattisgarh, India, [4]Senior Registrar, Department of Radio-Diagnosis, Jawahar Lal Nehru Memorial Medical College, Raipur, Chhattisgarh, India, [5]Junior Registrar, Department of Radio-Diagnosis, Jawahar Lal Nehru Memorial Medical College, Raipur, Chhattisgarh, India

Abstract

Introduction: The majority of ovarian cysts are symptomless and regress spontaneously. Until recent times, surgery has been the first treatment of choice. Cyst aspiration without the use of a sclerosing agent results in a higher recurrence rate, and hence the use of a sclerosing agent, such as tetracycline, methotrexate, or ethanol, is preferred.

Purpose: To evaluate the feasibility, efficacy and safety of tetracycline as a sclerosing agent in the management of simple ovarian cyst.

Materials and Methods: A total of 70 women having simple ovarian cyst were subjected to transabdominal cyst aspiration followed by 5% tetracycline sclerotherapy under ultrasonography guidance. Under local anesthesia, the cysts were punctured using spinal needle (18-gauge) and the contents aspirated. The aspirate was sent for cytological examination in all cases. Approximately, one-tenth of the aspirated cyst fluid volume was replaced with 5% tetracycline. Follow-up of the women was done clinically and using ultrasound initially twice weekly until the tetracycline is absorbed and then every 3 months for a period of 12-month to look for recurrence.

Results: Out of the 70 women all had serous aspirate. The result of cytological evaluation demonstrated benign lesion. On follow-up, 60 women showed complete resolution of cysts on ultrasonography. 10 women showed recurrence at various intervals which were then subsequently reaspirated. On follow-up, no recurrence was noted in them. χ^2 test shows that size of the cyst has a significant association ($P = 0.01$) with recurrence of cyst.

Conclusion: Management of simple ovarian cyst with ultrasonography guided aspiration and sclerotherapy with tetracycline is a safe, feasible and effective with minimal chances of recurrence and is a valid alternative to surgery.

Key words: Aspirations, Ovarian cysts, Sclerotherapy, Tetracycline, Ultrasonography

INTRODUCTION

An ovarian cyst is a thin walled collection of fluid which is larger than 2-3 cm.[1] The majority of them are symptomless and regress spontaneously. Some of them require treatment in the form of oral contraceptive pills. If untreated complications such as rupture, torsion, malignant transformation may occur.[2] Hence, surgical or interventional treatment is recommended. Until recent times, surgery in the form of laparotomy or laparoscopy has been the first choice.[3] However, ultrasonography guided aspiration of the cysts as an alternative treatment is the fast catching up and may even be procedure of choice in the management of ovarian cysts in a selected group of women as it has low recurrence rate, low risk, less cost and in most cases no hospital stay.[4] Surgery may even be considered Asan over treatment as most cysts

Access this article online

www.ijss-sn.com

Month of Submission : 08-2015
Month of Peer Review : 09-2015
Month of Acceptance : 10-2015
Month of Publishing : 11-2015

Corresponding Author: Dr. Vivek Patre, Department of Radio Diagnosis, Jawahar Lal Nehru Memorial Medical College and Dr B R Ambedkar Hospital, Raipur, Chhattisgarh - 492 001, India. Phone: 91-7712889161, 91-9329399994. Fax: 91-771-2523919. E-mail: vivek_patre@yahoo.com

are either benign or functional.[5,6] Cyst aspiration without the use of a sclerosing agent results in a higher recurrence rate and hence the use of a sclerosing agent, such as tetracycline, methotrexate, or ethanol, is preferred. Various studies have evaluated the feasibility of tetracycline as a sclerosing agent with good results.[7-9] The current study is to evaluate the therapeutic efficacy of aspiration and sclerotherapy with tetracycline of ovarian cyst.

MATERIALS AND METHODS

The prospective study was conducted in the Department of Radio diagnosis, Pt. J. N. M. Medical College, Raipur, India from August 2004 to July 2014. After obtaining a fully informed written consent, all women who fulfilled the inclusion criteria were included in the study.

The inclusion criteria for simple ovarian cystic were as follows:

- Unilocular
- Anechoic
- Wall thickness (<5 mm)
- Size >5.0 cm
- Without septations
- Without papillary projections or mural nodule
- Persistence of the cyst for at least 2 months.

The exclusion criteria were:

- Multilocular cysts
- Cysts with echoes and septations
- Ovarian cysts which were having papillary projection or mural nodule
- Cyst wall thickness > 5 mm
- Size <5 cm
- Tumor marker result (CA 125 > 35 ml/U per l)
- Pregnant women
- Women having known allergy to tetracycline.

After an overnight, fasting patients were taken for the procedure. The part preparation was done followed by painting and draping with betadine and spirit. Local anesthesia (2% xylocaine) was infiltrated at puncture site. An 18-gauge lumbar puncture needle was directed under sonographic guidance using 3.5 MHz transducers (Prosound 4000, Aloka, Japan); transabdominally to punctured ovarian cysts by freehand technique (Figures 1 and 2). The contents of the cyst were aspirated. The aspirated contents were sent for cytological examination. Then, 5% tetracycline was injected into cyst cavity, which was 10% of the aspirated volume (Figure 3). The women were managed on an out-patient basis, and all women received post-procedure analgesic and antibiotic coverage for a period of 3-day. The women were advised to attend regular follow-up visits (Figure 4). An ultrasound examination was performed twice weekly until tetracycline was absorbed, and then every 3 months for a year to check for recurrence. A cyst was considered to be recurrent if it was of diameter more than 5.0 cm.

RESULTS

The study included 70 women in the age group of 16-52 years with mean age 25.6 years. The mean size of cysts

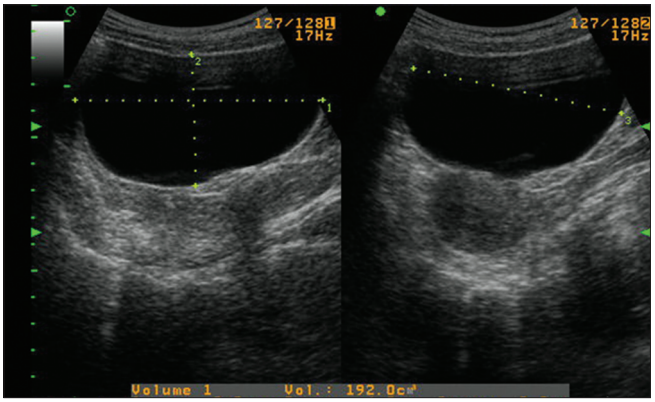

Figure 1: Transabdominal Ultrasound image of left ovary shows unilocular, anechoic simple ovarian cyst

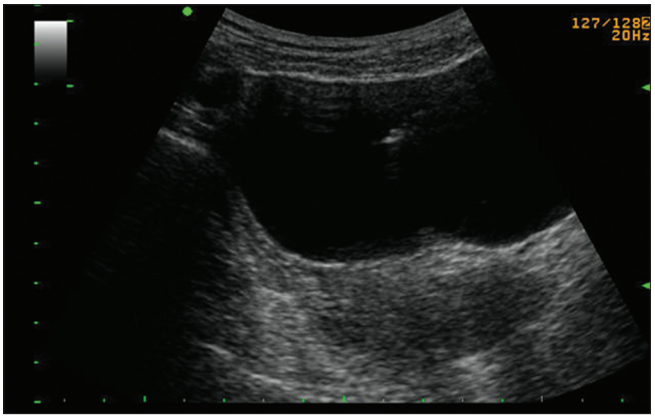

Figure 2: Tip of 18-gauge lumber puncture needle inside the left ovarian cyst

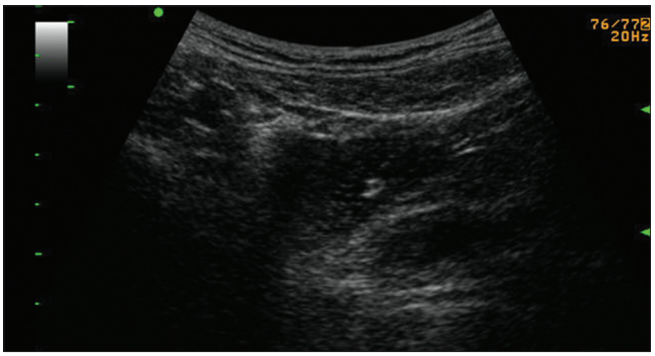

Figure 3: Ultrasound image shows post aspiration of cyst and injection of tetracycline producing internal echoes in the cyst

was 7.0 cm with range from 5.5 to 13.0 cm. The volume of the cysts ranged from 75 to 640 cc. The aspirate was serious in all women. The result of cytological evaluation demonstrated benign lesion in serious aspirates. The procedure of aspiration was performed once in 60 (85%) women and twice in 10 (15%) women. No immediate or post-procedural complications were noted. Follow-up after 3 months showed recurrence in six cysts of larger size (Tables 1 and 2). Rest of the women showed a significant reduction in size of cyst as compared to pre-procedural state. 6 months follow-up showed recurrence in none of the women; however at 12 months follow-up four cysts having larger size showed recurrence. Overall, resolution of cyst was observed in 85% of women with recurrence in 15% of women. χ^2 test shows that age is an insignificant factor ($P = 0.12$) and size of the cyst (>10.1 cm) has a significant association ($P = 0.01$) with recurrence of cyst considering $P < 0.05$ as significant.

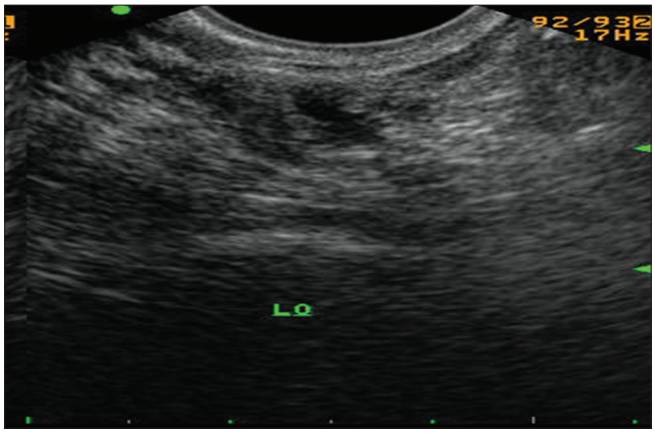

Figure 4: Transvaginal image shows resolution of left ovarian cyst at fifteen days follow-up

Table 1: Distribution of women according to outcome and age

Age group (years)	Number of women	Cyst resolution in percentage	Cyst recurrence in percentage
16-25	25	33	4.5
26-35	20	24	3
36-45	14	17	4.5
46-55	11	11	3
Total	70	85	15

Table 2: Distribution of women according to outcome and cyst size

Cyst size (cm)	Number of women	Cyst resolution in percentage	Cyst recurrence in percentage
5.5-7.0	8	11	0
7.1-8.5	22	28	3
8.6-10.0	20	26	3
10.1-11.5	12	13	4.5
11.6-13.0	8	7	4.5
Total	70	85	15

DISCUSSION

With the use of ultrasonography in recent years, there has been an increase in the detection of ovarian cysts majority of them being symptomless. However, treatment is required to avoid the potential complications. Surgery was the mainstay treatment until recent times, but ultrasound guided aspiration has proved to be a simple, effective, and rapidly effective treatment requiring no sedation in most cases.[10] Our study clearly indicates that management of ovarian cysts with aspiration and tetracycline injection is an effective method in its management. Complete resolution in 60 of 70 (85%) women on the first attempt and 10 of 10 women on the second attempt (100%). Many authors have used different sclerosing agents such as tetracycline, ethanol, and methotrexate. In this study, we used tetracycline due to its easy availability in our setting. No complication from tetracycline or from inadvertent spillage of tetracycline was noted. The cyst wall cells are responsible for the secretion of fluid and hence we employed tetracycline to cause fusion of the walls and prevent any recurrence.[11] There is a theoretical risk associated with aspiration of cysts which is seeding of the needle tract and the spread of malignant cells leading to dissemination.[12,13] To avoid this our inclusion criteria consisted of cysts which showed no features of malignancy on ultrasound. We also performed cytological examination of the aspirate to confirm the sonographic finding, and none of the cysts turned out to be malignant.

Fisch *et al.*,[14] reported complete resolution in 75% of women at follow-up examination and repeat aspiration of watery fluid was required in 25% of women and concluded that sclerotherapy with 5% tetracycline is a simple and effective alternative to surgical intervention. Kars *et al.,*[15] and Thummalakunta and Panditi[16] investigated the value of tetracycline sclerotherapy for management of recurrent or persisting non-neoplastic ovarian cysts in comparison to the aspiration without sclerotherapy and concluded that the use of a sclerosing agent leads to less recurrence. Abosrie and Abdelaziz[8] also showed that aspiration and sclerotherapy of ovarian cyst is a safe and effective treatment with a significantly low recurrence rate compared to simple aspiration only. In our study, the recurrence rate was 15% which we attributed to the cyst size. χ^2 test shows that age is an insignificant factor ($P = 0.12$) and size of the cyst (>10.1 cm) has a significant association ($P = 0.01$) with recurrence of cyst. Studies have shown parameters in predicting recurrence such as age, size of cyst and sidedness.[17]

CONCLUSION

In our study, we found that aspiration of simple ovarian cyst followed by tetracycline sclerotherapy is a safe, feasible and effective with minimal chances of recurrence and is a valid alternative to surgery.

REFERENCES

1. Levine D, Brown DL, Andreotti RF, Benacerraf B, Benson CB, Brewster WR, *et al.* Management of a symptomatic ovarian and other adnexal cysts imaged at US: Society of Radiologists in Ultrasound Consensus Conference Statement. Radiology 2010;256:943-54.
2. Eng-Lunt J, Appelbaum H, Avarello J. Pediatric and Adolescent Ovarian Torsion. ACEP News. December; 2011.
3. Duke D, Colville J, Keeling A, Broe D, Fotheringham T, Lee MJ. Transvaginal aspiration of ovarian cysts: Long-term follow-up. Cardiovasc Intervent Radiol 2006;29:401-5.
4. Brandt ML, Helmrath MA. Ovarian cysts in infants and children. Semin Pediatr Surg 2005;14:78-85.
5. Schwartz PE. The role of tumor markers in the preoperative diagnosis of ovarian cysts. Clin Obstet Gynecol 1993;36:384-94.
6. Balat O, Sarac K, Sonmez S. Ultrasound guided aspiration of benign ovarian cysts: An alternative to surgery? Eur J Radiol 1996;22:136-7.
7. Abosrie M, Abdelaziz AM. Effectiveness of aspiration and sclerotherapy of ovarian cyst: A comparative study of ethanol 95% or tetracycline solution versus simple aspiration. J Am Sci 2013;9:243-8.
8. Fabrizzi G, Lanza C, Bolli V, Pieroni G. Symptomatic hepatic cyst in a child: Treatment with single-shot injection of tetracycline hydrochloride. Pediatr Radiol 2009;39:1091-4.
9. Kilinc M, Tufan O, Guven S, Odev K, Gurbuz R. Percutaneous injection sclerotherapy with tetracycline hydrochloride in simple renal cysts. Int Urol Nephrol 2008;40:609-13.
10. Scanlan KA, Propeck PA, Lee FT Jr. Invasive procedures in the female pelvis: Value of transabdominal, endovaginal, and endorectal US guidance. Radiographics 2001;21:491-506.
11. Zanetta G, Lissoni A, Torri V, Dalla Valle C, Trio D, Rangoni G, *et al.* Role of puncture and aspiration in expectant management of simple ovarian cysts: A randomised study. BMJ 1996;313:1110-3.
12. Dordoni D, Zaglio S, Zucca S, Favalli G. The role of sonographically guided aspiration in the clinical management of ovarian cysts. J Ultrasound Med 1993;12:27-31.
13. de Crespigny LC, Robinson HP, Davoren RA, Fortune D. The 'simple' ovarian cyst: Aspirate or operate? Br J Obstet Gynaecol 1989;96:1035-9.
14. Fisch JD, Sher G. Sclerotherapy with 5% tetracycline is a simple alternative to potentially complex surgical treatment of ovarian endometriomas before *in vitro* fertilization. Fertil Steril 2004;82:437-41.
15. Kars B, Buyukbayrak EE, Karsidag AY, Pirimoglu M, Unal O, Turan C. Comparison of success rates of transvaginal aspiration and tetracycline sclerotherapy' versus 'only aspiration' in the management of non-neoplastic ovarian cysts. J Obstet Gynaecol Res 2012;38:65-9.
16. Thummalakunta PL, Panditi S. Comparison of success rates of 'transvaginal aspiration and tetracycline sclerotherapy' versus 'only aspiration' in the management of non-neoplastic ovarian cysts. J Obstet Gynaecol Res 2012;38:1342.
17. Weinraub Z, Avrech O, Fuchs C, Schneider D, Golan A, Bukovsky I, *et al.* Transvaginal aspiration of ovarian cysts: Prognosis based on outcome over a 12-month period. J Ultrasound Med 1994;13:275-9.

How to cite this article: Patre V, Singh A, Nagaria T, Gahine R, Netam SB, Patre V, Vatwani N. Management of Simple Ovarian Cyst with Ultrasonography Guided Aspiration and Sclerotherapy with Tetracycline. Int J Sci Stud 2015;3(8):24-27.

Source of Support: Nil, **Conflict of Interest:** None declared.