Original Article

DOI: 10.17354/ijss/2015/525

Cytological Evaluation of Thyroid Lesions and its Correlation with Histopathology: A Prospective Study

Sheela Chaudhari, Deepa Hatwal, Pawan Bhat, Neha Batra, Sachan Bhat

Associate Professor, Department of Pathology, Veer Chandra Sing Garhwali Government Medical Science & Research Institute, Pauri Garhwal, Uttarakhand, India

Abstract

Introduction: Fine-needle aspiration cytology (FNAC) has an important role in differentiating between neoplastic and non-neoplastic lesions of the thyroid. It is a quick outpatient department (OPD) procedure. It greatly affects the treatment decision. The current study was carried out to evaluate the role of FNAC as a diagnostic tool in thyroid lesions and establish a clinico-cytological, biochemical, and histological correlation.

Purpose: The purpose of this study is to establish a cytohistological correlation in thyroid lesion and to find out can FNA obviate the need for histopathological diagnosis in thyroid lesions.

Materials and Methods: It is a prospective study of thyroid lesions carried out at the Department of Pathology, Government Medical College, Srikot, Srinagar Pauri Garhwal Uttarakhand over a period of 2-year. A total of 136 patients with thyroid lesion were undertaken for FNAC. Their clinico-cytological, biochemical, and histological correlation was done. Their statistical analysis was done.

Results: Majority of the cases were non-neoplastic. The accuracy of cytodiagnosis was 94%.

Conclusion: FNAC of thyroid lesion has a high accuracy in differentiating between malignant and benign lesions. It is safe cost effective, minimally invasive, and OPD procedure. Using FNAC as the first line of investigation, the number of surgeries for thyroid lesion has reduced greatly.

Key words: Accuracy of fine-needle aspiration cytology, Histopathology, Sensitivity, Specificity

INTRODUCTION

Thyroid fine-needle aspiration cytology (FNAC) was introduced in 1950 and became popular worldwide in 1980.[1] Today, it is a well-established technique for pre-operative diagnosis of thyroid pathologies. Thyroid lesions may cause sign and symptoms of hypothyroidism or hyperthyroidism and also have malignant potential.[2] Therefore, accurate evaluation of thyroid lesions is difficult.

Access this article online

www.ijss-sn.com

Month of Submission : 09-2015
Month of Peer Review : 10-2015
Month of Acceptance : 11-2015
Month of Publishing : 11-2015

Various non-invasive methods used for diagnosis of thyroid lesions do not make a definitive diagnosis of malignant lesions. FNA has now replaced most other tests used for pre-operative diagnosis of thyroid lesions. Now-a-day, most clinicians rely solely on FNA for making a diagnosis of benign lesions. As a result the incidence of malignancy in thyroidectomy patients has increased from 10% to 30-50% in recent years.[3] In spite of the first choice of investigation in thyroid lesions, it also has some limitations. The reported pitfalls are mostly related to sampling techniques, the skill of doctor performing the aspiration, sample adequacy, the experience of pathologist interpreting the aspirate, and overlapping cytological features between benign and malignant follicular neoplasm.[4,5]

FNAC is safe relatively simple and cost effective for evaluation of thyroid patients. This procedure provides

Corresponding author: Dr. Sheela Chaudhari, Department of Pathology, Veer Chandra Sing Garhwali Government Medical Science & Research Institute, Srinagar - 246 174, Pauri Garhwal, Uttarakhand, India. E-mail: drcnsuk@yahoo.com

a tool for detecting thyroid malignancies in an early stage, resulting in a better outcome of patients. In this study effectiveness of FNAC is evaluated in the clinical management of thyroid disease and also to reduce the rate of surgery in benign cases.

MATERIALS AND METHODS

This is a prospective study of thyroid lesions carried out at Department of Pathology, Government Medical College, Srikot, Srinagar, Pauri Garhwal, Uttarakhand over a period of 2-year (June 2013 to May 2015). Patients from ENT outpatient department (OPD) and from medicine OPD were taken for FNA. 136 FNACs were done during this period. Patients of all ages and both the sexes were included in the study. Out of 136 patient, histological confirmation was available in 52 cases. A sample of histopathology was collected from our own surgical department as well as from the surgeries done outside. Methods used in this study included a clinical presentation, thyroid function test, FNAC, and histopathology. Sign and symptoms related to thyroid gland were a solitary nodule, multinodular, and diffuse goiter. Sign of compression, hoarseness of voice, cough, pain, dysphagia, and symptoms related with hypo functioning or hyper functioning of thyroid gland. Thyroid function test was used to determine the level of free T3, T4 and free T4, and thyroid stimulating hormone.

All FNA was done by the pathologist as the outpatient procedure; no ultrasound guided FNA was done. Air-dried smears were stained with May–Grunwald–Giemsa, and wet smears were stained with papanicolaou and hematoxylin and eosin stain. The results of FNAC were compared with histopathology in 52 cases. The cytological results were also correlated with clinical features and thyroid function test. The statistical analysis included sensitivity, specificity, accuracy, false positive rate, and false negative rate.

RESULTS

FNAC performed in 136 patients of which 82% were female, and 18% were male. Most of the patients were in the age group of 20-40 (Table 1). Most common presenting symptom was painless solitary nodule (Table 2). Among 136 patients, 81.6% were non-neoplastic, and 18.4% were reported as neoplastic on cytology (Table 3, Figures 1,2)). Cytohisto-correlation was done in 52 cases. 49/52 cases were confirmed on histology (Figures 3 and4), one was false positive and two were false negative (Table 4). The sensitivity of FNAC was 90%, specifitive was 96% (Table 5).

Table 1: Age distribution of thyroid patients

Age group in years	Number of patients
0-20	14
21-40	70
41-60	40
61-80	12
Total	136

Table 2: Clinical sign and symptoms

Clinical sign and symptoms	Number of patients
Goitre	136
Solitary nodule	111
Multinodular	17
Diffuse	08
Pain	10
Dysphagia	08
Hoarseness	12
Cough	03
Sign and symptoms of increased hormonal concentration	10
Sign and symptoms of decreased hormonal concentration	12

Table 3: FNAC of thyroid nodule (*n*=136)

Non-neoplastic lesions	*n*=111
Nodular goiter	62
Benign cyst	24
Thyroiditis	25
Neoplastic lesions	*n*=25
Follicular neoplasm	14
Papillary neoplasm	06
Hurthle cell neoplasm	04
Anaplastic	01
Total	136

FNAC: Fine-needle aspiration cytology

Table 4: Cytohistological correlation (*n*=52)

FNAC	Histology		Total
	Neoplastic	Non-neoplastic	
Neoplastic	19	1	20
Non-neoplastic	2	30	32
Total	21	31	52

FNAC: Fine-needle aspiration cytology

Table 5: Statistical analysis (%)

Sensitivity	90
Specificity	96
False positive rate	3.1
False negative rate	9.1
Accuracy	94

DISCUSSION

Thyroid enlargement is the most common occurrence in the sub-Himalayan region of the India. Our hospital

is located in Garhwal region. This hospital gets patients exclusively from this region. These regions are iodine deficient areas. The incidence of goiter is much higher in these regions. Thyroid enlargement whether nodular or diffuse needs thorough investigation, mainly to rule out malignancy or thyroiditis. Thyroid malignancy accounts for 1% of all malignancy. Early diagnosis of thyroid cancer provides higher life expectancy due to low malignant potential and slow progressing nature of thyroid cancer.

FNAC has excellent patient acceptance and no morbidity. It is easy and low-cost effective test used in the diagnosis of the thyroid nodule.[4,6,7] FNAC of thyroid nodule has decreased the rate of thyroid surgery while increasing the percentage of malignancy in thyroidectomy patients.[8]

The value of any test depends on its ability to detect the presence of disease (sensitivity) and to verify the absence of disease when it is not presence (specificity). The sensitivity of thyroid FNAC ranges from 74% to 92% and specificity ranges from 74% to 100%.[9,10] In our study, sensitivity was 90%, and specificity was 96%, which correlates with other studies.[11,13-18] This shows that FNAC is more specific than sensitive. The reason for the wide range of sensitivity and specificity is the difference in the way of categorization of lesions by a different cytopathologist.

Factors that reduce the efficacy of FNAC of thyroid include inadequate sampling, the inexperience of cytopathologist, and difficulty in differentiating between benign and malignant follicular lesions. Inadequate sampling may result from sclerotic, calcified nodule, or nodule with cystic degeneration in large areas.

The solitary thyroid nodule is less likely to be malignant. In our study, of 111 patients of solitary nodule, only six were reported as neoplastic on FNAC. Which correlates with others studies.[12,13]

Most common age group in our study was the 3rd and 4th decade of life, which is accordance to the study of

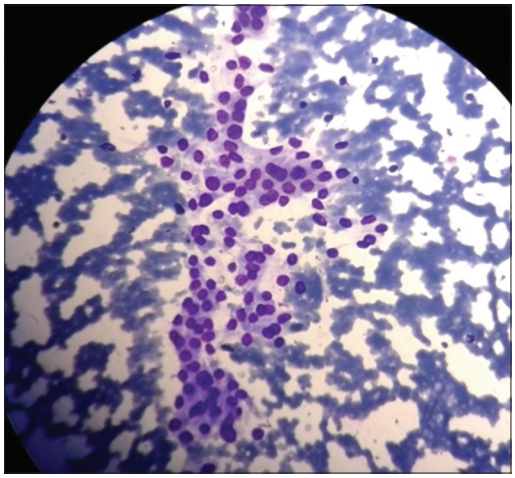

Figure 1: Papillary structure in papillary carcinoma on fine-needle aspiration cytology (×10)

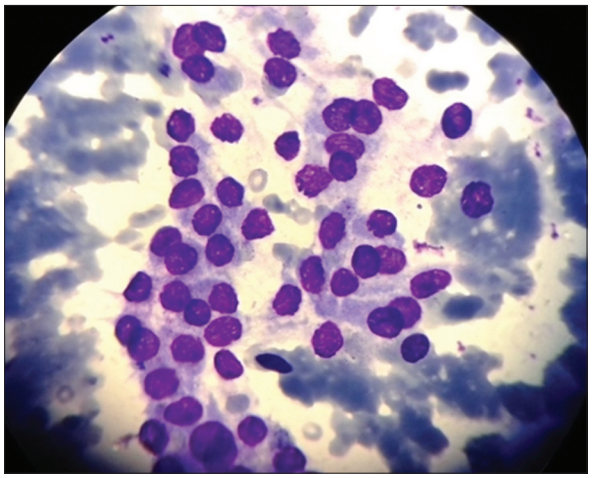

Figure 2: Anisonucleosis and nuclear grooveing in papillary carcinoma on fine-needle aspiration cytology (×40)

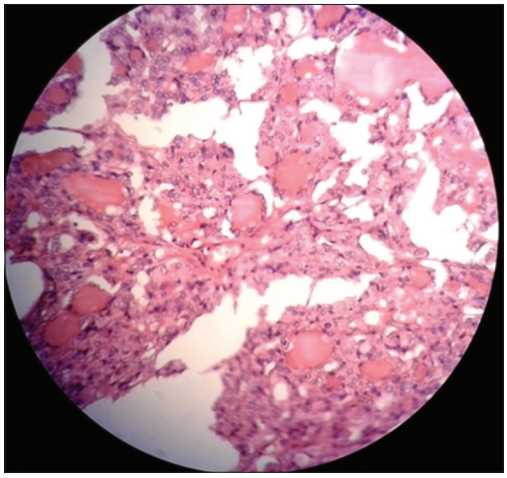

Figure 3: Papillary carcinoma on histology (×10)

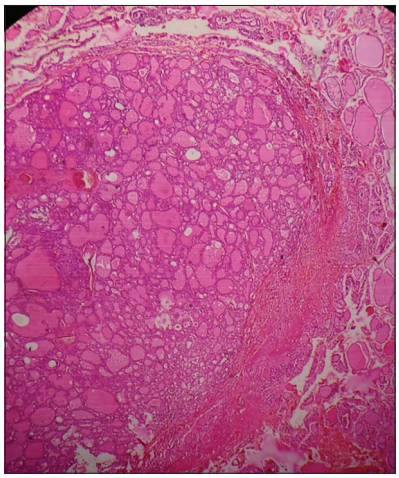

Figure 4: Capsular invasion in follicular carcinoma (×40)

Bukhari *et al.* and Khanzada *et al.* Most of the malignant patients presents after 5th decade of life. Anaplastic carcinoma which is usually seen in late ages, in this study, the age of anaplastic carcinoma was 39 years.

In our study, there was 106 female and 30 male, with a male to female ratio of 1:3.5 which correlates with the study of Sharma.[19] In this study, rate of false negative was 9.7% and false positive rate was 3.1% which was accordance with the study of Sharma.[19] In previous studies, false negative rate were reported between 1% and 7% and false positive rate 1-11%.[4,7,9] Wide range of false negative and false positive may be due to sampling error and cytological interpretation. False negative FNAC occurred in two cases. Both cases were diagnosed as adenomatoid goiter on histopathological examination both were confirmed as follicular carcinoma. False positive was only one case which was diagnosed as Hurthle cell neoplasm on cytology, but on histology it was confirmed as Hurthle cell change in hyperplastic goiter.

CONCLUSION

FNAC is rapid, simple, cost-effective, and minimally invasive diagnostic tool for making pre-operative assessment of patient with the thyroid nodule. By adopting this method, unnecessary thyroid surgeries for benign lesions can be avoided.

REFERENCES

1. Tabaqchali MA, Hanson JM, Johnson SJ, Wadehra V, Lennard TW, Proud G. Thyroid aspiration cytology in Newcastle: A six year cytology/histology correlation study. Ann R Coll Surg Engl 2000;82:149-55.
2. American Thyroid Association (ATA) Guidelines Taskforce on Thyroid Nodules and Differentiated Thyroid Cancer, Cooper DS, Doherty GM, Haugen BR, Kloos RT, Lee SL, *et al.* Revised American Thyroid Association management guidelines for patients with thyroid nodules and differentiated thyroid cancer. Thyroid 2009;19:1167-214.
3. Ridgway EC. Clinical review 30: Clinician's evaluation of a solitary thyroid nodule. J Clin Endocrinol Metab 1992;74:231-5.
4. Pandey P, Dixit A, Mahajan NC. Fine-needle aspiration of the thyroid: A cytohistologic correlation with critical evaluation of discordant cases. Thyroid Res Pract 2012;9:32-9.
5. Caraway NP, Sneige N, Samaan NA. Diagnostic pitfalls in thyroid fine-needle aspiration: A review of 394 cases. Diagn Cytopathol 1993;9:345-50.
6. Cibas ES, Ali SZ; NCI Thyroid FNA State of the Science Conference. The Bethesda system for reporting thyroid cytopathology. Am J Clin Pathol 2009;132:658-65.
7. Bagga PK, Mahajan NC. Fine needle aspiration cytology of thyroid swellings: How useful and accurate is it? Indian J Cancer 2010;47:437-42.
8. Yassa L, Cibas ES, Benson CB, Frates MC, Doubilet PM, Gawande AA, *et al.* Long-term assessment of a multidisciplinary approach to thyroid nodule diagnostic evaluation. Cancer 2007;111:508-16.
9. Haberal AN, Toru S, Ozen O, Arat Z, Bilezikçi B. Diagnostic pitfalls in the evaluation of fine needle aspiration cytology of the thyroid: Correlation with histopathology in 260 cases. Cytopathology 2009;20:103-8.
10. Amrikachi M, Ramzy I, Rubenfeld S, Wheeler TM. Accuracy of fine-needle aspiration of thyroid. Arch Pathol Lab Med 2001;125:484-8.
11. Gharib H, Goellner JR. Fine-needle aspiration biopsy of the thyroid: An appraisal. Ann Intern Med 1993;118:282-9.
12. Hegedüs L. Clinical practice. The thyroid nodule. N Engl J Med 2004;351:1764-71.
13. Ko HM, Jhu IK, Yang SH, Lee JH, Nam JH, Juhng SW, *et al.* Clinicopathologic analysis of fine needle aspiration cytology of the thyroid. A review of 1,613 cases and correlation with histopathologic diagnoses. Acta Cytol 2003;47:727-32.
14. Ravetto C, Colombo L, Dottorini ME. Usefulness of fine-needle aspiration in the diagnosis of thyroid carcinoma: A retrospective study in 37,895 patients. Cancer 2000;90:357-63.
15. Cáp J, Ryska A, Rehorková P, Hovorková E, Kerekes Z, Pohnetalová D. Sensitivity and specificity of the fine needle aspiration biopsy of the thyroid: Clinical point of view. Clin Endocrinol (Oxf) 1999;51:509-15.
16. Bista M, KC T, Regmi D, Maharjan M, Kafle P, Shrestha S. Diagnostic accuracy of fine needle aspiration cytology in thyroid swellings. J Nepal Health Res Counc 2011;9:14-6.
17. Guhamallick M, Sengupta S, Bhattacharya NK. Cytodiagnosis of thyroid lesions-usefulness and pitfalls: A study of 288 cases. J Cytol 2008;25:6-9.
18. Jogai S, Al-Jassar A, Temmim L, Dey P, Adesina AO, Amanguno HG. Fine needle aspiration cytology of the thyroid: A cytohistologic study with evaluation of discordant cases. Acta Cytol 2005;49:483-8.
19. Sharma C. Diagnostic accuracy of fine needle aspiration cytology of thyroid and evaluation of discordant cases. J Egypt Natl Canc Inst 2015;27:147-53.

How to cite this article: Chaudhari S, Hatwal D, Bhat P, Batra N, Bhat S. Cytological Evaluation of Thyroid Lesions and its Correlation with Histopathology: A Prospective Study. Int J Sci Stud 2015;3(8):132-135.

Source of Support: Nil, **Conflict of Interest:** None declared.