Print ISSN: 2321-6379
Online ISSN: 2321-595X

Original Article

Evaluation of Maxillary Central Incisor and Canine Exposures in Resting Position of the Maxillary Lip for Determining the Anterior Level of Occlusal Plane

Shivkumar A. Mule[1], Shankar P. Dange[2], Arun N. Khalikar[3], Smita P. Vaidya[4], Shubhendra S. Khandewale[5], Babita Suryawanshi[6], Nazish Baig[6]

[1]Associate Professor, Department of Prosthodontics, Chhatrapati Shahu Maharaj Shikshan Sanstha, Aurangabad, Maharashtra, India, [2]Dean and Professor, Department of Prosthodontics, Government Dental Hospital and College, Aurangabad, Maharashtra, India, [3]Professor, Department of Prosthodontics, Government Dental College and Hospital, Nagpur, Maharashtra, India, [4]Associate Professor, Department of Prosthodontics, Government Dental Hospital and College, Aurangabad, Maharashtra, India, [5]Assistant Professor, Department of Pedodontics, Chhatrapati Shahu Maharaj Shikshan Sanstha, Aurangabad, Maharashtra, India, [6]Professor, Department of Prosthodontics, Chhatrapati Shahu Maharaj Shikshan Sanstha, Aurangabad, Maharashtra, India

Abstract

Introduction: The exposure of the maxillary anterior teeth affects the anterior level of occlusal plane, esthetics, and speech. Previous data suggests approximately 2 mm of exposure of the maxillary central incisors in the resting position of the maxillary lip.

Aim: This study aimed to evaluate the relationship between the vertical position of the maxillary central incisors and canines and the maxillary lip in Indian dentulous subjects according to age, sex, and lip length.

Material and method: A total of 540 (272 male and 268 female) Indian adults between 21 and 60 years of age were included in the study. The exposures of the maxillary central incisors and canines were measured using a ruler with the maxillary lip in the rest position. Additionally, the maxillary lip length of each subject was also measured.

Result: Data were analyzed using analysis of variance and Student's t-test. The tooth exposure was inversely proportional to lip length. Statistically significant differences in the exposures of the maxillary central incisors and canines were observed between the age groups 20-30 years and 30-40 years and 40-50 years for maxillary central incisors. However, no significant differences were observed between the age groups 50-60 years for maxillary central incisors and between 40-50 years and 50-60 years for maxillary canines.

Conclusion: Maxillary central incisor exposure is highly variable while maxillary canine exposure showed lesser variations with age, sex, and lip length.

Key words: Canine exposure, Incisor exposure, Lip length, Occlusal plane

INTRODUCTION

An esthetic and appealing smile is the requirement of most patients. Hence, anterior teeth have become the focus of attention for both patients and dentists. The anterior teeth play a key role in speech, incision of food, and definitely, esthetics. Replacement of one or two missing maxillary anterior teeth using adjacent teeth as abutments is not difficult. However, when the maxillary anterior teeth, all maxillary teeth, or all teeth are missing, the determination of the relative positions of the anterior teeth becomes a subjective decision.

Landa laid specific guidelines for the vertical positioning of the maxillary central incisors and clarified that 0 mm–2 mm of the incisal edge should be visible below the maxillary

Access this article online

www.ijss-sn.com

Month of Submission : 08-2019
Month of Peer Review : 09-2019
Month of Acceptance : 10-2019
Month of Publishing : 10-2019

Corresponding Author: Shivkumar A. Mule, Department of Prosthodontics, Chhatrapati Shahu Maharaj Shikshan Sanstha, Aurangabad, Maharashtra, India.

lip.[1] Sharry instructed that "for a patient with an average length of the upper lip, 1–2 mm of the occlusion rim should be seen when the lip is at rest. For a patient with a short upper lip, perhaps, 5–6 mm of the occlusion rim would be seen."[2] Ellinger *et al*. suggested that for a normal lip, the occlusion rim should extend just below the resting lip position and proposed variations in guidelines for short or long lips.[3] Boucher and Payne used phonetics to determine the position of the maxillary anterior teeth.[4,5] Heartwell recommended that the vertical length of the maxillary occlusion rim in the anterior region should extend approximately 2 mm below the relaxed lip.[6]

Vig and Brundo found a gradual decrease in the amount of maxillary central incisor exposure with an increase in age, accompanied by a gradual increase in the exposure of mandibular anterior teeth.[7] Ahmed described that a decreasing amount of maxillary teeth exposure and increasing amount of mandibular teeth exposure can be seen from Caucasians to Asians to Blacks.[8] Misch performed a pilot study on Caucasian dentulous patients and concluded that the range of maxillary central incisor exposure was wide, and the use of an average dimension as a guide may not be accurate in clinical practice.[9]

Therefore, the purpose of the study was to investigate the effect of lip length, age, and sex on the exposure of maxillary central incisors and canines in the resting position of the maxillary lip in the Indian population.

MATERIALS AND METHODS

This clinical observational study was planned with 540 Indian adults (272 were male and 268 were female) aged between 21 and 60 years. The participants were recruited from patients visiting the department of prosthodontics of a dental college. All subjects had Angle's Class I occlusion, without crowding or spacing between the anterior or posterior teeth. Patients were excluded if they had a history of trauma or plastic surgery associated with the lips, undergone orthodontic treatment, prostheses in the anterior region, mobile or extruded anterior teeth, and/or moderate-to-severe wear of the maxillary anterior teeth.

Table 1: The overall mean exposures of the maxillary central incisors and canines

	Maxillary central incisors		Maxillary canines	
Sex	Mean (mm)	Range (mm)	Mean (mm)	Range (mm)
Male	2.27	–2 to 7	–0.22	–3 to 2
Female	3.00	–2 to 8	0.07	–3 to 2

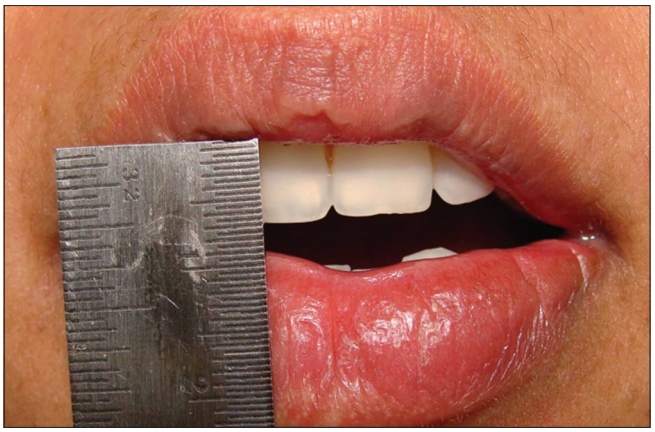

Figure 1: Measurement of maxillary central incisor exposure

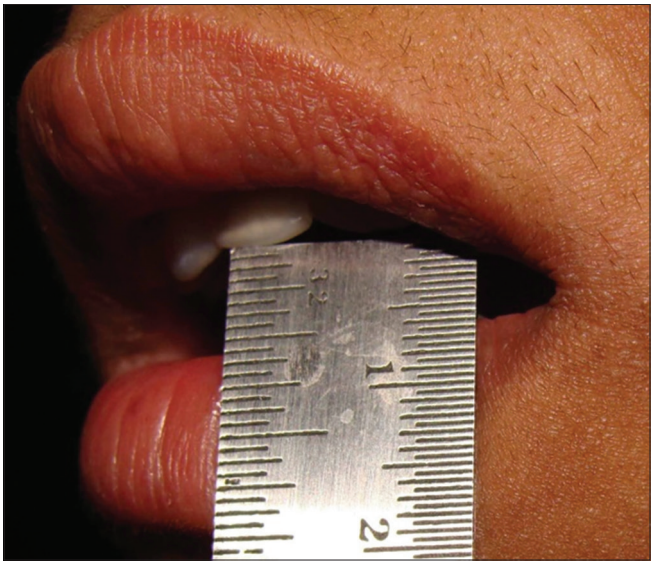

Figure 2: Measurement of maxillary canine exposure

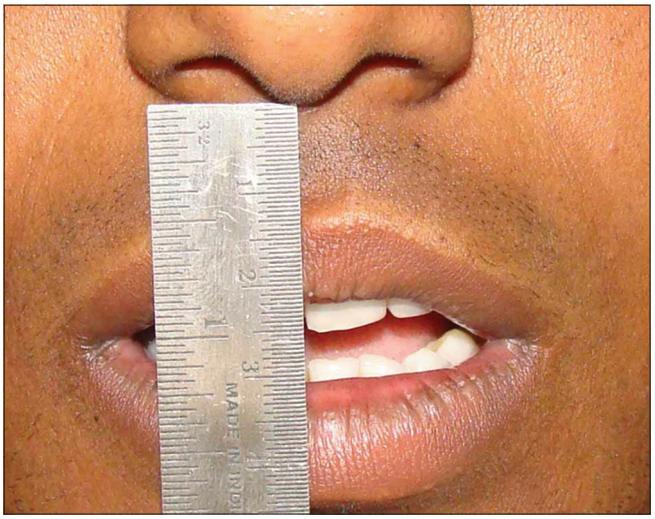

Figure 3: Measurement of maxillary lip length

Each subject was asked to sit upright in a chair with the head unsupported. Measurements were made by an examiner

Table 2: The exposures of the maxillary central incisors and canines according to lip length in male and female subjects

Lip length (mm)	Number of observations	Maxillary central incisors			Maxillary canines		
		Mean (mm)	Standard deviation	Range (mm)	Mean (mm)	Standard deviation	Range (mm)
Male							
10–15 (short)	30	5.06	1.21	2.5 to 7	0.86	1.19	–1 to 2
16–20 (medium)	178	2.38	1.69	–2 to 5	–0.20	1.07	–3 to 2
21–25 (medium)	66	1.01	1.37	–2 to 4	–0.74	0.94	–3 to 1
Female							
10–15 (short)	38	5.34	1.64	0 to 8	1.26	0.72	–1 to 2
16–20 (medium)	160	3.07	1.06	0 to 5	0.21	0.88	–2 to 2
21–25 (medium)	70	1.68	1.93	–2 to 4	–0.72	1.15	–3 to 1

using a handheld millimeter ruler. Each subject was asked to say "emma" so that the mandible and lips attained their respective rest positions. The lower lip was parted and using the millimeter ruler, the vertical distance from the inferior margin of the vermilion border of the maxillary lip in repose to the incisal edge of the right maxillary central incisor was measured [Figure 1].

Thereafter, the vertical distance from the inferior margin of the vermilion border of the maxillary lip in repose to the tip of the right maxillary canine was measured [Figure 2].Similarly, the exposures of the left maxillary central incisor and canine were recorded. When the incisal edge/canine tip was above the inferior border of the maxillary lip, the exposure was recorded as a negative value. The maxillary lip length of each subject was also measured from the base of the columella to the lower margin of the vermilion border of the maxillary lip [Figure 3].

The exposures of the maxillary central incisors and canines on both sides of the arch were averaged, and the mean values of maxillary central incisor and canine exposures for each subject were used for further analysis. The obtained data were categorized for male and female subjects according to age groups as follows: 21–30, 31–40, 41–50, and 51–60 years. The obtained data for maxillary lip length were categorized according to the lip lengths as follows: Short, medium, and medium lip lengths for lip lengths of 10–15 mm, 16–20 mm, and 21–25 mm, respectively.

The exposures of the maxillary central incisors and canines in different age groups and in patients with different lip lengths were compared between male and female subjects using the analysis of variance (ANOVA). $P < 0.05$ was considered statistically significant.

RESULTS

The overall mean exposure and range of exposure of the maxillary central incisors and canines in the rest position of the maxillary lip in both male and female subjects are shown in Table 1. The overall mean exposures of the maxillary central incisors and canines in male subjects were 2.27 mm and –0.22 mm, respectively. The mean exposures of the maxillary central incisors and canines in female subjects were 3.00 mm and 0.07 mm, respectively.

Table 3: Results of one-way ANOVA for lip length groups

P-value	Maxillary central incisors	Maxillary canines
Male	<0.000	<0.000
Female	<0.000	<0.000

ANOVA: Analysis of variance

The mean exposure, standard deviation, and range of exposure of the maxillary central incisors and canines in the rest position of the maxillary lip in male and female subjects according to their lip length are shown in Table 2. With the increase in lip length, the exposures of the central incisors and canines decreased in both male and female subjects. The exposures of the maxillary central incisors and canines [Table 3] showed statistically significant difference between the age groups in male and female subjects.

The mean exposure, standard deviation, and range of exposure of the maxillary central incisors and canines in the rest position of the maxillary lip in male and female subjects according to their age groups are shown in Table 4. The mean exposures of both maxillary central incisors and canines in male and female subjects decreased with increasing age from 20 to 60 years.

In this study, the overall mean exposures of the maxillary central incisors and canines were greater in female subjects than that in male subjects. The mean exposures of the maxillary central incisors and canines decreased from 5.06 mm to 1.01 mm and 0.86 mm to –0.74 mm, respectively, as the lip length increased from 10 mm to 25 mm in male subjects. The mean exposures of the maxillary central incisors and canines decreased from 5.34 mm to

Table 4: The exposures of the maxillary central incisors and canines according to age groups in male and female subjects

Age groups (Years)	Number of observations	Maxillary central incisors			Maxillary canines		
		Mean exposure (mm)	Standard deviation	Range of exposure (mm)	Mean exposure (mm)	Standard deviation	Range of exposure (mm)
Male							
21–30	76	3.10	1.98	–2 to 7	0.02	1.01	–2 to 3
31–40	68	2.63	1.75	–1 to 6	–0.19	1.14	–3 to 2
41–50	68	2.00	1.93	–2 to 5	–0.33	1.22	–3 to 2
51–60	62	1.38	1.68	–2 to 5	–0.40	1.14	–3 to 2
Female							
21–30	74	3.95	1.62	–1 to 8	0.58	1.09	–2 to 2
31–40	64	3.34	1.25	0 to 7	0.20	0.89	–2 to 2
41–50	70	2.80	1.63	–1–5	–0.01	1.08	–3–1
51–60	60	1.93	1.97	–2 to 4	–0.46	1.21	–3 to 1

Table 5: Comparison between male and female groups for the exposures of maxillary central incisors and canines

Age groups	*P*-value	Inference
Maxillary central incisors		
20–30 years	0.004	Significant difference
30–40 years	0.038	Significant difference
40–50 years	0.010	Significant difference
51–60 years	0.100	Non-significant difference
Maxillary canines		
20–30 years	0.002	Significant difference
30–40 years	0.029	Significant difference
40–50 years	0.102	Non-significant difference
51–60 years	0.767	Non-significant difference

1.68 mm and 1.26 mm to –0.72 mm, respectively, as the lip length increased from 10 mm to 25 mm in female subjects.

The results [Table 5] demonstrated that there was a statistically significant difference in the maxillary central incisor and canine exposures between the age groups 20–30 years and 30–40 years and in the maxillary central incisor exposure between 40 and 50 years. However, no significant differences were observed between the age groups 50 and 60 years for maxillary central incisor exposure and 40–50 years and 50–60 years for canine exposure.

DISCUSSION

The anterior level of the occlusal plane should be accurately determined. Limited studies have provided the average values for the accurate determination of the anterior level of occlusal plane in both male and female patients of all age groups according to the maxillary lip length and race of the patient.[1-6] Hence, this study was conducted to investigate the effect of lip length, age, and sex on the exposure of maxillary central incisors and canines in the resting position of the maxillary lip in the Indian population. The rest position of the lip is determined when the lips are slightly parted and the teeth are out of occlusion with the perioral muscles relatively relaxed. In the static position, the following four factors influence the tooth exposure: Lip length, age, race, and sex.[7]

The results suggest that exposure of the maxillary central incisor is similar between male and female subjects after 50 years of age while exposure of the maxillary canine is similar between male and female subjects after 40 years of age in the studied population.

The tooth display was inversely proportional to lip length. This result suggests that the exposure of both maxillary central incisors and canines should be altered according to the lip length in both male and female patients.

From Tables 4 and 5, it can be proposed that the exposures of maxillary central incisors in male and female subjects decrease with age, and clinically negligible change occurs after the age of 50 years. In contrast, the exposures of canines in male and female subjects decrease faster with age, and clinically negligible change occurs after the age of 40 years.

The results of this study suggest that the exposure of maxillary central incisors shows greater variation according to age and lip length, in both male and female subjects, compared to the exposure of maxillary canines. Hence, the use of the maxillary central incisors as a guide for positioning the anterior level of occlusal plane may not be predictable. In addition, limited changes in canine exposure occur according to age and lip length, in both male and female subjects. Hence, the anterior level of occlusal plane can be established in a more predictable manner using canine exposure as guide. However, further long-term prospective studies are required to validate the results of this study.

This study is not without limitations. Subjects included in the study were from a single relatively small area to be representative of the entire Indian population. The limited sample size and manual method of measurements restrict the generalization of the study results. Further studies, targeting a larger population, or large multicenter studies should be performed for providing insights into this vast topic.

CONCLUSION

This study showed that the mean exposures of maxillary central incisors and canines were greater in female subjects than that in male subjects. The exposures of the maxillary central incisors and canines decreased as the lip length increased from 10 mm to 25 mm in male and female subjects. Maxillary canine exposure decreases till 40 years of age and shows few changes till the age of 60 years while the maxillary central incisor exposure decreases till 50 years of age and limited changes occur till the age of 60 years. As reported, the maxillary central incisor exposure in the resting position of the maxillary lip is highly variable, while the maxillary canine exposure tended to show lesser variations with age, sex, or lip length.

ACKNOWLEDGMENT

Dr. Trupti Agrawal-Khandewale for help in editing this article.

REFERENCES

1. Landa SL. Anterior tooth selection and guidelines for complete denture esthetics. In: Winkler S, editor. Essentials of Complete Denture Prosthodontics. Philadelphia, PA: Saunders; 1979. p. 282-300.
2. Sharry JJ. Anterior tooth selection. In: Sharry JJ, editor. Complete Denture Prosthodontics. New York: McGraw-Hill; 1974. p. 234.
3. Ellinger CW, Rayson JH, Terry JM, Rahn AO. Arrangement of anterior teeth. In: Ellinger CW, editor. Synopsis of Complete Dentures. Philadelphia, PA: Lea and Febiger; 1975. p. 163.
4. Boucher CO. Arrangement of teeth. In: Boucher CO, editor. Swenson's Complete Dentures. St. Louis, MO: Mosby; 1970. p. 155-210.
5. Payne SH. Contouring and positioning. In: Moss SJ, editor. Esthetics. New York: 1973. p. 50-4.
6. Heartwell CM. Tooth arrangement. In: Heartwell CM, editor. Syllabus of Complete Dentures. Philadelphia, PA: Lea and Febiger; 1968. p. 261-76.
7. Vig RG, Brundo GC. The kinetics of anterior tooth display. J Prosthet Dent 1978;39:502-4.
8. Ahmad I. Anterior dental aesthetics: Dentofacial perspective. Br Dent J 2005;199:81-8.
9. Misch CE. Guidelines for maxillary incisal edge position-a pilot study: The key is the canine. J Prosthdont 2008;17:130-4.

How to cite this article: Mule SA, Dange SP, Khalikar AN, Vaidya SP, Khandewale SS, Suryawanshi B, Baig N. Evaluation of Maxillary Central Incisor and Canine Exposures in Resting Position of the Maxillary Lip for Determining the Anterior Level of Occlusal Plane. Int J Sci Stud 2019;7(7):103-107.

Source of Support: Nil, **Conflict of Interest:** None declared.