

# A Unique Bilateral Squamous Papilloma of Nasal Vestibule

**M K Rajasekar<sup>1</sup>,  
M Vivek<sup>2</sup>,  
V Narendrakumar<sup>2</sup>**

<sup>1</sup>Professor, Department of ENT, Upgrade Institute of Otorhinolaryngology, Madras Medical College, Chennai, Tamil Nadu, India, <sup>2</sup>Formerly Post-graduate Student, Department of ENT, Upgrade Institute of Otorhinolaryngology, Madras Medical College, Chennai, Tamil Nadu, India

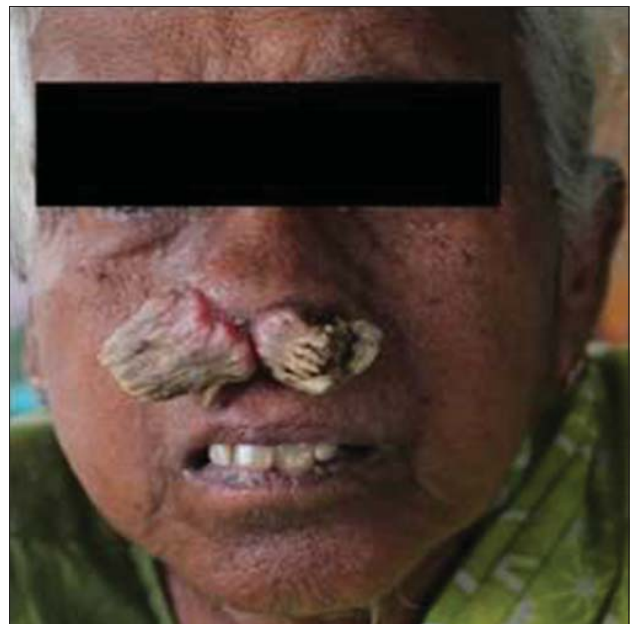**Corresponding Author:** Dr. M K Rajasekar, Department of ENT, Upgrade Institute of Otorhinolaryngology, Madras Medical College, Chennai, Tamil Nadu, India. E-mail: drmkrent@gmail.com

The nasal vestibule is lined with keratinizing squamous epithelium and contains different components from the nasal cavity proper. Pathologic lesions occurring in the nasal vestibule are different from those in the nasal cavity proper, partially due to histologic differences.<sup>1</sup>

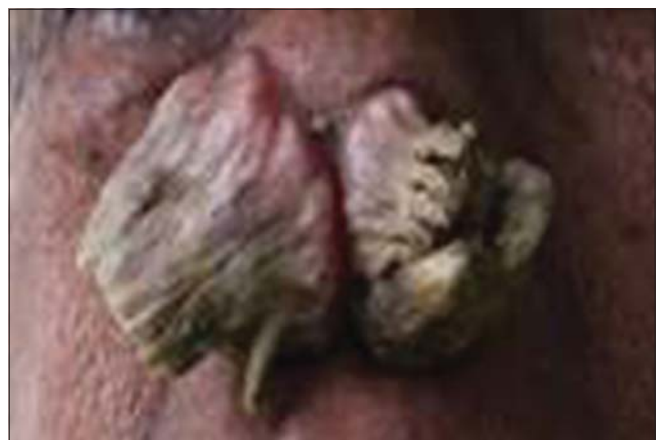The papilloma are classified into exophytic squamous, inverted and cylindrical. Squamous papilloma is unilateral, most common in males and in younger age groups.<sup>2</sup>

A 75-years-old female presented with the complaints of exophytic, warty growth arising from the both nasal cavities for the past 8 months. The growth had started as a wisp of cotton arising from the nasal septum, and she used to pull it manually off. It progressed gradually in the span of 8 years to attain a size of around 3 cm × 2 cm on each side, pinkish proximally, greyish and nail-like distally (Figures 1 and 2). The tumour completely obstructed both nares, as a result of which anterior rhinoscopy could not be performed. The patient also complained of pain of pricking and dragging type possibly due to super-added infection which also explains the foul-smell that exuded on examination. There was no lymph node enlargement. The patient was also a known diabetic Type II for past 8 years and a hypertensive for past 5 years in addition to her personal history of snuff application from the age of 25-65 years. Computed tomography scan was taken to locate the extent of the lesion (Figure 3) and surgery was done to excise the lesion and sent for histopathological examination which is suggestive of a squamous papilloma (Figure 4). The integrity of the nasal vestibule, both functionally and cosmetically improved post-operatively (Figure 5).

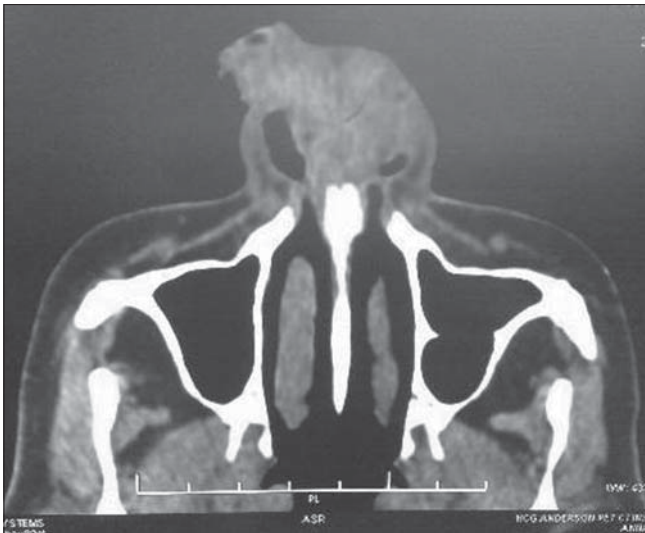A squamous papilloma is characterized by the epithelial proliferation growing an exophytic manner with the



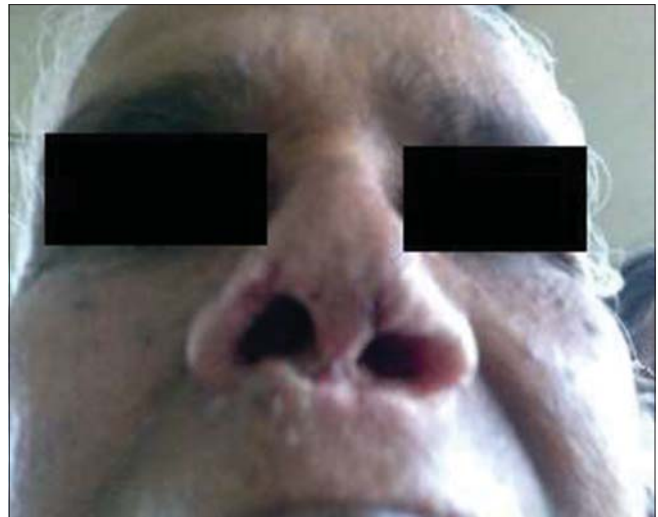**Figure 1: Pre-operative picture of the patient**



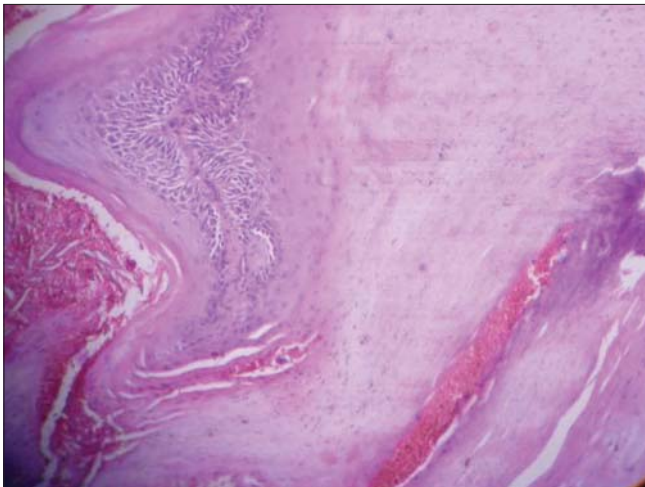
**Figure 2: View of the lesion, obstructing both the nares**



**Figure 3: Computed tomography showing the growth being localized to the nasal vestibule**



**Figure 5: Post-operative picture of the patient**



**Figure 4: Section of the excised tissue showing squamous hyperplasia with a prominent fibrovascular core**

formation of multiple papillary fronds and uncommon mitosis.<sup>3</sup>

#### Points to Ponder

- 1) Squamous papilloma is unilateral, most common in males and in younger age groups.<sup>2</sup>
- 2) In our case, unique about the squamous papilloma is, it occurs in 75-years-old female presenting bilaterally and synchronously.

#### REFERENCES

1. Kim SJ, Byun SW, Lee SS. Various tumors in the nasal vestibule. *Int J Clin Exp Pathol* 2013;6:2713-8.
2. Michaels L, Hellquist HB. *Ear, nose and throat histopathology*. 2<sup>nd</sup> ed. London: Springer; 2001.
3. Kumagai M, Endo S, Matsunaga E, Kida A, Sakata H, Yamamoto M. Squamous papillomatosis of the bilateral nasal cavities. *Tohoku J Exp Med* 2005;206:267-70.

**How to cite this article:** Rajasekar MK, Vivek M, Narendrakumar V. A Unique Bilateral Squamous Papilloma of Nasal Vestibule. *Int J Sci Stud* 2014;2(7):262-263.

**Source of Support:** Nil, **Conflict of Interest:** None declared.