

Comparative Study between Interrupted and Continuous Suture Techniques in Ventricular Septal Defect Patch Closure: A Retrospective Study

T Muthuvijayan, A. Kumaravel

Assistant professor, Department of Cardiothoracic Surgery, Madurai Medical College, Madurai, Tamil Nadu, India

Abstract

Introduction: Ventricular septal defect (VSD) is the most common congenital cardiac anomaly that may occur as an isolated anomaly or as a part of complex of anomaly such as tetralogy of Fallot. Small defects may close spontaneously and may cause no significant disability in lifetime.

Materials and Methods: This is a comparison study of interrupted and continuous suture technique for closure of VSDs done with the objective to study the experience regarding the effectiveness, post-operative complication rates, and the total outcome done in the Department of Cardiothoracic Surgery, Government Rajaji Hospital from October 2012 to December 2015.

Results: A total of 43 total s were recruited for the study. Of these, 18 had VSD repair using glutaraldehyde-treated autologous pericardial patch and 25 had VSD repair using Gore-Tex patch. The majority of patients were in the age group of 6-10 years comprising 44% of the total study. Children under 5 years of age comprised <10% of the study group. The most common associated anomaly was congenital mitral valve abnormality, mainly cleft mitral valve and chordal prolapsed leading to significant mitral regurgitation requiring mitral valve repair. Right ventricular outflow tract obstruction was due to hypertrophied RV muscle bundle which required the division of the muscle bundle to relieve the obstruction. Two patients had significant aortic regurgitation due to aortic valve prolapse.

Conclusion: Continuous and interrupted suture techniques are equally effective in closure of VSD. Even though residual shunt is common with continuous suture technique VSD closure, 7% cases of residual shunt occurred in interrupted suture techniques in our institutions which is statistically insignificant.

Key words: Continuous suturing technique, Gore-Tex, Interrupted suturing technique, Pericardial patch closure, Polypropylene sutures, Ventricular septal defect

INTRODUCTION

Ventricular septal defect (VSD) is the most common congenital cardiac anomaly that may occur as an isolated anomaly or as a part of complex of anomaly such as tetralogy of Fallot.¹⁻⁴ Small defects may close spontaneously and may cause no significant disability in lifetime. Patients with cardiomegaly and large left to right shunts

are unquestionable candidates for the operation.⁵⁻⁹ By operating electively, the tendency to develop pulmonary hypertension, valvulitis, and bacterial endocarditis is virtually eliminated.^{10,11}

MATERIALS AND METHODS

All the patients for VSD closure were done by a single experienced surgeon. All patients undergoing repair for VSD in the Department of Cardiothoracic Surgery, Government Rajaji Hospital during October 2012-December 2015 were included in the study. Patients with VSD associated with complex anomalies and muscular typeth atiwere excluded from this study. One group used continuous suture for VSD closure and the other group used interrupted techniques for VSD closure.

Access this article online



www.ijss-sn.com

Month of Submission : 08-2016
Month of Peer Review : 08-2016
Month of Acceptance : 09-2016
Month of Publishing : 10-2016

Corresponding Author: Kumaravel, Madurai Medical College, Madurai, Tamil Nadu, India. E-mail: drkums89@gmail.com

After median sternotomy, the thymus was dissected from the pericardium. Pericardium harvested as a free graft taking care to avoid injury to the phrenic nerves. It was treated with 0.6% glutaraldehyde solution for 20 min and rinsed 3 times in 0.9% saline solution for 5 min.

Cardiopulmonary bypass was started after aorta, superior vena cava, inferior vena cava cannulation. Under moderate hypothermia, cross clamp applied, antegrade cold blood cardioplegia given. Heart arrested in diastole right atrium was opened, and the VSD was inspected. The pericardial/Gore-Tex patch was trimmed to match the size of the VSD. The defect was closed with the pericardial patch using 4/0 or 5/0 polypropylene continuous suture, starting from the inferior margin and proceeding toward the anterosuperior margin and superiorly toward the aortic valve, avoiding injury to the aortic cusps. With the second arm of the suture, the postero-inferior margin was closed up to the septal leaflet of the tricuspid valve.

The tricuspid margin of the defect was closed with a reinforcing strip of pericardium. When using interrupted sutures pledget supported interrupted mattress sutures are placed around all margins of the defect and then passed through an appropriately tailored patch, which is lowered down and tied in.

Patients with an uneventful recovery were discharged after ten days. Echocardiography was done before discharge and documented.

Data Collection

The information collected regarding all the selected cases were recorded on a master chart. Data analysis was done with the help of computer using epidemiological information package developed by center for disease control, Atlanta.

Using this software range, frequencies, percentages, mean standard deviations, Chi-square, and “*P*” values were calculated. Kruskal-Wallis Chi-square test was used to test the significance of the difference between quantitative variables. A $P < 0.05$ is taken to denote significant relationship.

RESULTS

A total of 43 patients were recruited for the study. Of these, 18 had VSD repair using glutaraldehyde-treated autologous pericardial patch and 25 had VSD repair using Gore-Tex patch.

The majority of patients were in the age group of 6-10 years comprising 44% of the total study. Children

under 5 years of age comprised <10% of the study group (Tables 1-3).

Most of the VSD operated were restrictive physiology. The nonrestrictive type included the VSD of outlet type (Table 4).

The most common associated anomaly was congenital mitral valve abnormality, mainly cleft mitral valve, and chordal prolapsed leading to significant mitral regurgitation requiring mitral valve repair. Right ventricular outflow tract (RVOT) obstruction was due to hypertrophied RV muscle bundle which required the division of the muscle bundle to relieve the obstruction. Two patients had significant aortic regurgitation due to aortic valve prolapse (Tables 5-10 and Graph 1).

Table 1: Age distribution

Age (in years)	Cases n (%)
Up to 5	3 (6.9)
6-10	19 (44.2)
11-15	14 (32.6)
16-20	6 (13.9)
>20	1 (2.4)
Total	43 (100)
Range	5-29 years
Mean	11.3 years
SD	5.21 years

SD: Standard deviation

Table 2: Sex distribution

Sex	Cases n (%)
Male	20 (46.4)
Female	23 (53.6)
Total	43 (100)

Table 3: Type of VSD

Diagnosis	Cases n (%)
Subpulmonic	8 (18.6)
Subaortic	14 (32.6)
Perimembranous	20 (46.5)
Inlet	1 (2.3)
Total	43 (100)

VSD: Ventricular septal defect

Table 4: Hemodynamics

Type of hemodynamics	Cases n (%)
Restrictive VSD	37 (86.1)
Nonrestrictive VSD	6 (13.9)
Total	43 (100)

VSD: Ventricular septal defect

Table 5: Associated anomalies

Associated anomalies	Cases n (%)
Present	13 (30.2)
Absent	30 (69.8)
Total	43 (100)

Table 6: Suturing technique

Suturing technique	Cases n (%)
Continuous	17 (39.5)
Interrupted	26 (60.5)
Total	43 (100)

Table 7: Patch material used

Patch material used	Cases n (%)
Pericardium	18 (42)
Gore-Tex	25 (58)
Total	43 (100)

Table 8: Complications

Complication	Cases n (%)
Block	1 (2.3)
Stroke	2 (4.7)
IE	2 (4.7)
Renal failure	1 (2.3)
Residual shunt	3 (7)
Other complications	14 (32.5)
Death	3 (6.9)
Total cases with complications	24 (55.8)
Total cases without complications	19 (44.2)
Total	43 (100)

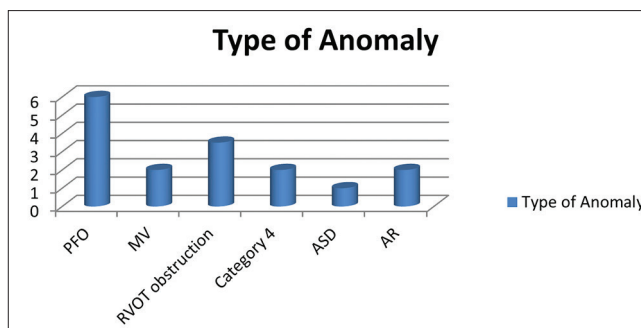
IE: Infective endocarditis

Two patients had infective endocarditis (IE) in Gore-Tex patch group. The residual shunt was present in three patients, none of them were significant enough to warrant re-exploration and closure. One patient had nodal rhythm in Gore-Tex patch group and received temporary pacing, recovered after 1 week (Graphs 2 and 3, Tables 11-21).

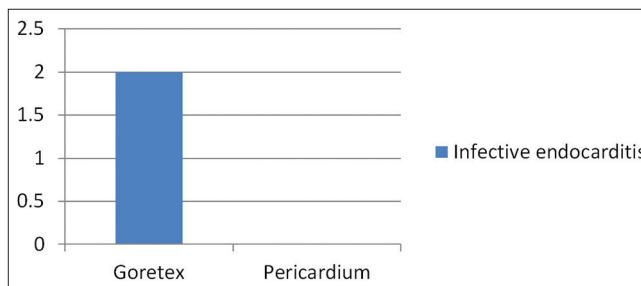
DISCUSSION

A total of 43 patients were recruited for the study, out of these, 17 had VSD repair using continuous and 26 had repair using interrupted suture techniques.

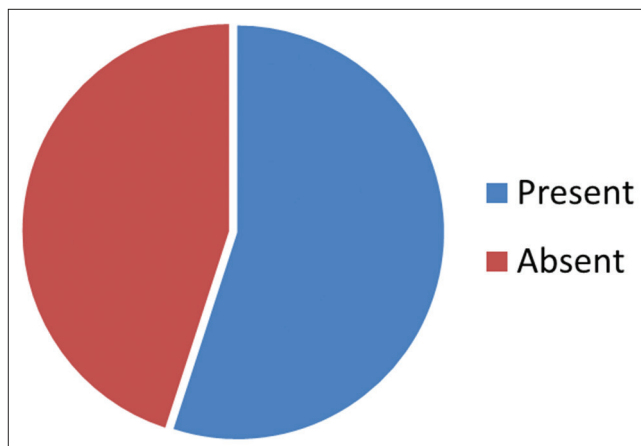
Continuous suture technique was employed in 40% of the study group. For most of the patients in this group, pericardial patch was applied. The glutaraldehyde-treated



Graph 1: Associated anomalies



Graph 2: Infective endocarditis



Graph 3: Complications

patch was more flexible and had better handling properties when compared to Gore-Tex patch, for ease of surgery. For the remaining patients, interrupted suture technique was used and most of them were from Gore-Tex group. They were mainly operated on by me during the study.

25 patients had VSD using Gore-Tex patch and 18 patch had VSD using Goreoperatglutaraldehyde-treated autologous pericardial patch.

Congenital mitral valve abnormalities were the most common associated anomaly, mainly chordal prolapsed and cleft mitral valve with significant mitral regurgitation requiring repair. AML cleft was closed with 5-0 prolene sutures, and chordal shortening was done.¹²⁻¹⁷

Table 9: Residual shunt

Residual shunt	Cases n (%)
Yes	3 (7)
No	40 (93)
Total	43 (100)

Table 10: Outcome

Outcome	Cases n (%)
Recovered	40 (93)
Death	3 (7)
Total	43 (100)

Table 11: Age and outcome

Age group (years)	Outcome, n (%)	
	Recovered	Death
Up to 5 (3)	2 (67)	1 (33)
6-10 (19)	18 (94.7)	1 (5.3)
11-15 (14)	13 (92.9)	1 (7.1)
16-20 (6)	6 (100)	-
>20 (1)	1 (100)	-
Mean age	11.48	9.0
SD	5.29	4.0
"P"	0.434	
	Not significant	

SD: Standard deviation

Table 12: Sex and outcome

Sex	Outcome, n (%)	
	Recovered	Death
Male (20)	19 (95.0)	1 (5.0)
Female (23)	21 (91.3)	2 (8.7)
"P"	0.897	
	Not significant	

Table 13: Diagnosis and outcome

Diagnosis	Outcome, n (%)	
	Recovered	Death
Subpulmonic (8)	7 (87.5)	1 (12.5)
Subaortic (14)	13 (92.9)	1 (7.1)
PM (20)	19 (95)	1 (5)
Inlet	1 (40)	-
Total	100	3

The most common VSD was outlet type which comprises 51% of the study population. Perimembranous type comprises 49% in the study population.

The transarterial approach was used for most of the patients. Two patients requiring aortic valve repair were

Table 14: Other variables and outcome

Variable	Outcome	
	Recovered n (%)	Death n (%)
Type of VSD		
Outlet (22)	20 (91)	2 (9)
PM (21)	20 (95)	1 (5)
Patch material used		
Pericardium (18)	17 (94.4)	1 (5.6)
Gore-Tex (25)	23 (92)	2 (8)

VSD: Ventricular septal defect

Table 15: Outcomes and other variables

Variable	Outcome		"P"
	Recovered	Death	
	n (%)	n (%)	
Type of hemodynamics			
Restrictive VSD (37)	35 (94.6)	2 (5.4)	0.898
Nonrestrictive VSD (6)	5 (83.3)	1 (16.7)	Not significant
Anomalies			
Present (13)	12 (92.3)	1 (7.7)	0.829
Absent (30)	28 (93.3)	2 (6.7)	Not significant
Suturing technique			
Continuous (17)	16 (94.1)	1 (5.9)	0.856
Interrupted (26)	24 (92.3)	2 (7.7)	Not significant
Residual shunt			
Yes (3)	3 (100)	-	0.989
No (40)	37 (92.5)	3 (7.5)	Not significant

VSD: Ventricular septal defect

Table 16: Complications and other variables

Variable	Complications				"P"
	Present		Absent		
	Yes	No	Yes	No	
Type of hemodynamics					
Restrictive VSD (37)	20	54.1	17	45.9	0.756
Nonrestrictive VSD (6)	5	83.3	1	16.7	Not significant
Anomalies					
Present (13)	10	76.9	3	23.1	0.499
Absent (30)	14	46.7	16	53.3	Not significant
Suturing technique					
Continuous (17)	6	35.3	11	64.7	0.351
Interrupted (26)	18	69.2	8	30.8	Not significant

VSD: Ventricular septal defect

approached through aortic exposure; mitral valve repair was done through interatrial septal approach.^{5,7,18-20}

One patient had nodal rhythm in Gore-Tex patch group with interrupted suture technique and temporary pacing was done but recovered after 6 days. Residual shunt was present in 3 patients, but none of them were significant for reexploration.

Table 17: Complications and other variables

Variables	Complications	
	Present	Absent
	n (%)	n (%)
Type of VSD		
Outlet (22)	12 (54.5)	10 (45.5)
PM (21)	12 (57.1)	9 (42.9)
Patch material		
Pericardium (18)	10 (46.7)	8 (44.4)
Gore-Tex (25)	14 (56)	11 (44)

VSD: Ventricular septal defect

Table 18: Patch material and residual shunt

Patch material used	Residual shunt	
	Yes	No
	n (%)	n (%)
Pericardium (18)	1 (5.6)	17 (94.4)
Gore-Tex (25)	2 (8)	23 (92)
Total	3	40

Table 19: Type of VSD and residual shunt

Type of VSD	Residual shunt	
	Yes	No
	n (%)	n (%)
Outlet (22)	2 (9)	20 (91)
PM (21)	1 (4.8)	20 (95.2)

VSD: Ventricular septal defect

Table 20: Type of hemodynamic and residual shunt

Type of hemodynamics	Residual shunt	
	Yes	No
	n (%)	n (%)
Restrictive (37)	1 (2.7)	36 (97.3)
Nonrestrictive (6)	2 (33.3)	4 (66.7)
<i>P</i>	0.747	
	Not significant	

Table 21: Patch material and suture techniques

Patch material used	Suture techniques	
	Continuous	Interrupted
	n (%)	n (%)
Pericardium (18)	10 (55.6)	8 (44.4)
Gore-Tex (25)	7 (28)	18 (72)

IE was noticed in 2 patients in Gore-Tex patch group with interrupted sutures.

Aortic valve prolapsed with aortic regurgitation was noted in 2 patients. Through transaortic route, they were approached

and modified Trussler's repair was done to correct the prolapsed right coronary cusp. RVO'T obstruction was commonly due to RV muscle bundle hypertrophy; the obstruction was relieved by dividing the muscle bundle. Two patients had anomalous muscle bundle in RV which was excised. Patent foramen ovale was closed.^{5,21,22}

One patient suffered neurological deficit in the immediate post-operative period. Definite areas of infarct were noted in the computed tomography scan of the brain, but the patient recovered successfully. The patient regained full functional recovery after a period of 2-month.

Two patients had prerenal failure in the post-operative period and conservatively managed. In the 3-day period, his renal parameters returned to normal baseline.

Two patients from the interrupted suture technique group with Gore-Tex patch had IE were successfully treated for 3 week with antibiotics based on culture reports.

Three patients died in the immediate post-operative period, of which two died of post-operative cardiac failure, and one died due to pulmonary hypertensive crisis.

Residual shunt was noted in three patients. No patients warranted reexploration. Two patients were from the continuous suture technique group with Gore-Tex patch, irrespective of the type of VSD.

Limitations

This study is limited by its nonrandomized nature and the inherent limitations of the nonrandomized studies. Only those patients who were referred for surgery and underwent surgical repair were reviewed. Indications for surgery were based on the retrospective review of the referring cardiologist clinical notes and the surgical pre-operative notes. Although the study did not address long-term follow-up of these patients, long-term survival and clinical outcomes for patients after surgical closure of isolated VSD or consistently excellent, and we would anticipate the same for this study population. In addition, we intentionally excluded patients with multiple VSDs. We recognized that patients with multiple VSDs can be a challenging group for surgical repair. However, the focus of the study was patient with isolated, single VSD.

CONCLUSION

Continuous and interrupted suture techniques are equally effective in closure of VSD. Even though residual shunt is common with continuous suture techniques VSD closure, 7% cases of residual shunt occurred in interrupted

suture techniques in our institutions, which is statistically insignificant.

Incidence of IE is slightly higher in interrupted when compared to continuous suture techniques in our institution, could be explained by more number of pledgets used in interrupted technique which is also statistically insignificant.

Because of small number of groups included in our study, we are unable to come to conclusion and suggesting large randomized controlled study to ascertain this.

REFERENCES

- Brickner ME, Hillis LD, Lange RA. Congenital heart disease in adults. Second of two parts. *N Engl J Med* 2000;342:334-42.
- Presbitero P, Prever SB, Contrafatto I, Morea M. As originally published in 1988: Results of total correction of tetralogy of Fallot performed in adults. Updated in 1996. *Ann Thorac Surg* 1996;61:1870-3.
- Hussain A, Malik A, Jalal A, Rehman M. Abnormalities of conduction after total correction of tetralogy of Fallot. *J Pak Med Assoc* 2002;52:77-82.
- Murphy JG, Gersh BJ, Mair DD, Fuster V, McGoon MD, Ilstrup DM, *et al.* Long-term outcome in patients undergoing surgical repair of tetralogy of Fallot. *N Engl J Med* 1993;329:593-9.
- Touati GD, Vouhé PR, Amodeo A, Pouard P, Mauriat P, Leca F, *et al.* Primary repair of tetralogy of Fallot in infancy. *J Thorac Cardiovasc Surg* 1990;99:396-402.
- Webb GD. Care of adults with congenital heart disease – a challenge for the new millennium. *Thorac Cardiovasc Surg* 2001;49:30-4.
- Horowitz LN, Vetter VL, Harken AH, Josephson ME. Electrophysiologic characteristics of sustained ventricular tachycardia occurring after repair of tetralogy of Fallot. *Am J Cardiol* 1980;46:446-52.
- Norgård G, Gatzoulis MA, Moraes F, Lincoln C, Shore DF, Shinebourne EA, *et al.* Relationship between type of outflow tract repair and postoperative right ventricular diastolic physiology in tetralogy of Fallot. Implications for long-term outcome. *Circulation* 1996;94:3276-80.
- Zaman H, Jalal A, Cheema MA. The effect of residual ventricular septal defects on early clinical outcome: Initial experience. *J Coll Physicians Surg Pak* 2000;10:325-8.
- Niwa K, Siu SC, Webb GD, Gatzoulis MA. Progressive aortic root dilatation in adults late after repair of tetralogy of Fallot. *Circulation* 2002;106:1374-8.
- Teoh KH, Mickle DA, Weisel RD, Li RK, Tumiati LC, Coles JG, *et al.* Effect of oxygen tension and cardiovascular operations on the myocardial antioxidant enzyme activities in patients with TOF and aorta-coronary bypass. *J Thorac Cardiovasc Surg* 1992;104:159-64.
- Li RK, Mickle DA, Weisel RD, Tumiati LC, Jackowski G, Wu TW, *et al.* Effect of oxygen tension on the anti-oxidant enzyme activities of tetralogy of Fallot ventricular myocytes. *J Mol Cell Cardiol* 1989;21:567-75.
- Van Arsdell GS, Maharaj GS, Tom J, Rao VK, Coles JG, Freedom RM, *et al.* What is the optimal age for repair of tetralogy of Fallot? *Circulation* 2000;102 19 Suppl 3:III123-9.
- Hennein HA, Mosca RS, Ureclay G, Crowley DC, Bove EL. Intermediate results following complete repair of TOF in neonates. *J Thorac Cardiovasc Surg* 1995;109:332-44.
- Lukács L, Kassai I, Arvay A. Total correction of tetralogy of Fallot in adolescents and adults. *Thorac Cardiovasc Surg* 1992;40:261-5.
- Patel CR, Agamanolis DP, Stewart JW. Prenatal diagnosis of tetralogy of Fallot with obstructed supracardiac totally anomalous pulmonary venous connection. *Cardiol Young* 2005;15:656-9.
- Dietl CA, Cazzaniga ME, Dubner SJ, Pérez-Balño NA, Torres AR, Favaloro RG. Life-threatening arrhythmias and RV dysfunction after surgical repair of tetralogy of Fallot. Comparison between transventricular and transatrial approaches. *Circulation* 1994;90:117-12.
- Martin R, Khaghani A, Radley-Smith R, Yac-Oub M. Patient status 10 or more years after primary total correction of TOF under age of two years. *Br Heart J* 1985;53:666-7.
- Chandar JS, Wolff GS, Garson A Jr, Bell TJ, Beder SD, Bink-Boelkens M, *et al.* Ventricular arrhythmias in postoperative tetralogy of Fallot. *Am J Cardiol* 1990;65:655-61.
- Sugita T, Ueda Y, Matsumoto M, Ogino H, Sakakibara Y, Matsuyama K. Repeated procedure after radical surgery for tetralogy of Fallot. *Circulation* 2000;70:1507-10.
- Kaiser LR, Kron IL, Spray TL. Tetralogy of Fallot. In: Jaquiss RD, editor. *Mastery of Cardiothoracic Surgery*. 2nd ed. Philadelphia, PA Lippincott Williams & Wilkins; 2007. p. 907.
- Nicholas T, Kouchoukos EH, Blackstone A, Donald B, Doty FL, Hanley C. Ventricular septal defect with pulmonary stenosis or atresia. In: Kirklin JW, Barratt-Boyes BG, editors. *Cardiac Surgery*. 3rd ed. New York: Churchill-Livingstone; 2003. p. 948.

How to cite this article: Muthuvijayan T, Kumaravel. Comparative Study between Interrupted and Continuous Suture Techniques in Ventricular Septal Defect Patch Closure: A Retrospective Study. *Int J Sci Stud* 2016;4(7):65-70.

Source of Support: Nil, **Conflict of Interest:** None declared.