Original Article

DOI: 10.17354/ijss/2015/458

Outcomes of Percutaneous Medial-Lateral Cross Pinning of the Pediatric Supracondylar Fractures of the Humerus

M Julfiqar[1], Ajay Pant[2], Najmul Huda[3], Mohammed Aslam[1]

[1]Assistant Professor, Department of Orthopaedics, Teerthanker Mahaveer Medical College and Research Centre, Teerthanker Mahaveer University, Moradabad, Uttar Pradesh, India, [2]Professor and Head, Department of Orthopaedics, Teerthanker Mahaveer Medical College and Research Centre, Teerthanker Mahaveer University, Moradabad, Uttar Pradesh, India, [3]Professor, Department of Orthopaedics, Teerthanker Mahaveer Medical College and Research Centre, Teerthanker Mahaveer University, Moradabad, Uttar Pradesh, India

Abstract

Introduction: Supracondylar fracture of distal humerus is the commonest pediatric fractures around the elbow. Treatment options range from non-operative to the closed or open reduction of the fracture and percutaneous Kirchner-wire (K-wire) fixation depending upon fracture and patient variables and expertise available. There are various patterns of percutaneous K-wire fixations described by different authors. The rate of traumatic and iatrogenic ulnar nerve injuries following pediatric supracondylar fractures of the humerus ranges from 12% to 20% and 2% to 6% respectively. The present study is aimed at determining the various outcomes in patients with pediatric supracondylar fractures of the humerus treated by close reduction and a medial-lateral percutaneous K-wire fixation.

Materials and Methods: Thirty five children with Gartland Type II and III supracondylar fracture of humerus were treated between February 2009 and December 2014 by closed reduction and percutaneous medial-lateral cross K-wire fixation. There were 22 male and 13 female children. Mean age of the children was 6.9 years (range 3-15 years) Extra care was taken to identify and secure the ulnar nerve while inserting the medial pin. All the patients were followed for a mean period of 9.4 months (range 6-13 months).

Results: Union was seen in all patients (100%) at a mean interval of 4.5 weeks (range 3-5 weeks). One patient (2.9%) had varus union. Superficial pin tract infection was seen in 5 (14.2%) patients. None of the patients has a pre-operative ulnar nerve injury, while 1 (2.9%) patient had iatrogenic ulnar nerve neurapraxia. Based on Flynn's criteria 85.6% patients had good to excellent results, 8.6% patients had fair results while 5.8% had poor results.

Conclusion: Pediatric supracondylar fractures can be satisfactorily treated by close reduction and percutaneous medial-lateral cross K-wire fixation without any undue risk of ulnar nerve injury.

Key words: Child, Closed reduction, Fracture fixation, Humerus, Ulnar nerve

INTRODUCTION

Supracondylar fracture of the humerus is the second most common pediatric fracture and account for 16% of all pediatric fractures. Pediatric supracondylar fractures of the humerus with an incidence rate of 65.4% constitute the most common pediatric elbow fractures.[1] The peak age of the fracture is at 5-7 years of age.[2] During this age there is intense remodeling taking place at the distal end of humerus making it thinner and more prone to fracture in the supracondylar area.[3] The usual mode and mechanism of injury involve a high velocity injury in the form of a road traffic accident or a fall from a height with hyperextension or flexion at elbow and supination or pronation at the radioulnar joint.[4,5] Extension type of supracondylar fracture is most common with an incidence of 95%, followed by less common flexion type of supracondylar fracture. Gartland classified the pediatric supracondylar fractures

Access this article online

www.ijss-sn.com

Month of Submission : 09-2015
Month of Peer Review : 10-2015
Month of Acceptance : 10-2015
Month of Publishing : 10-2015

Corresponding Author: Dr. Julfiqar, Department of Orthopaedics, Teerthanker Mahaveer Medical College and Research Centre, Teerthanker Mahaveer University, Moradabad - 244 001, Uttar Pradesh, India. Phone: +91-9756640470. E-mail: drzulfiqar1983@rediffmail.com

of the humerus into three types based on the degree of displacement, which was letter modified by Wilkins.[4,6] The available treatment options range from conservative to closed and or open reduction and percutaneous Kirchner-wire (K-wire) fixation depending upon the age of the patient, displacement, and duration of fracture and the expertise available.[4] Percutaneous K-wire fixation can be inserted either in a medial-lateral fashion or thorough a lateral entry only with each method having its own merits and demerits.[7,8] Failure to execute a timely and appropriate treatment plan for these fractures may lead to various complication including, varus malunion, elbow stiffness, Volkmann ischemic syndrome/contracture, neurovascular injury, myositis ossificans, etc.[9-12]

MATERIALS AND METHODS

This was retrospective study that included the pediatric patients with acute supracondylar fracture of humerus operated between February 2009 and December 2014 at a tertiary care institute. There were 22 male and 13 female patients. Mean age of the patients was 6.9 years (range 3-15 years). Inclusion criteria were fresh (≤7 days), traumatic, extension type, supracondylar fractures in children <15 years of age. Exclusion criteria were neglected (≥7 days), fractures complicated by open wounds or neurovascular injury, irreducible fracture by the closed method and patients having age of more than 15 years. The study was started after approval by the Institutional Ethical Committee. An informed written consent was obtained from all the study participants. A thorough clinical history and detailed examination with particular emphasis on neurovascular component was done for all the patients, followed by plain radiological examination of the injured elbow including anteroposterior (AP) and lateral views (Figure 1).

Surgical Technique

All the patients were operated in a supine position on a plain operation table either under regional or general anesthesia depending upon anesthetist's choice. No tourniquet was used. Pre-operatively all the patients were given a single shot of broad spectrum antibiotic through intravenous route. With the patient in the supine position (Figure 2), Fracture was reduced by applying the traction on the forearm and the assistant holding the humerus with elbow being in mild flexion. Reduction of the fracture was confirmed under image intensifier. After a satisfactory reduction a 1.5 mm wire was passed percutaneously through lateral epicondyle across the fracture and taking hold into the opposite cortex of the proximal fragment under image intensifier. Before inserting the medial wire through medial epicondyle following precautions were observed to minimize the risk of iatrogenic ulnar nerve injury:

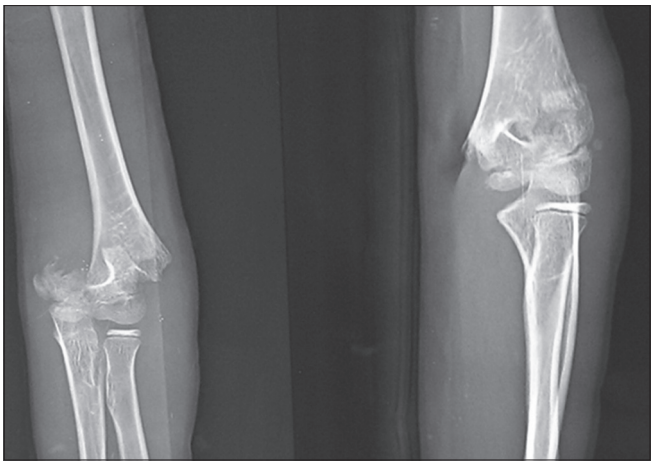

Figure 1: Pre-operative radiograph of the injured extremity (anteroposterior and lateral views) showing a Gartland Type III supracondylar fracture of the distal humerus

Figure 2: Patient positioning to reduce the extension type of supracondylar fracture of the humerus

1. Elbow flexion was reduced to minimum desirable position
2. Small stab incision was given just behind the medial epicondyle to identify and secure ulnar nerve in few selected cases
3. Skin over the medial epicondyle was stretched posteriorly with the help of overlying fingers
4. The final position of fracture reduction and K-wires was verified under image intensifier. The extra length of K-wires was cut and tip of the remaining wires was bent (Figure 3) outside the skin. After K-wire fixation a posterior plaster of Paris (POP) splint was applied for 3 weeks in all the patients followed by a check X-ray immediately after the surgery (Figure 4).

Post-operative Protocol

Intravenous analgesic and antibiotics were administered for the first 24 h after the surgery. A routine check radiograph including AP and lateral views of the operated elbow were done on the next morning in all the patients. On the next

day all the patients were switched to oral analgesics and antibiotics. Patients were routinely discharges on the second post-operative day.

Follow-up and Outcome Assessment

All the patients were called for routine follow-up in the outdoor department for clinico-radiological assessment of union and for any possible complication. Clinical union of the fracture was defined as the absence of tenderness at the fracture site and painless elbow motion. Radiological union was defined as the presence of bridging callus at the fracture site in both AP and lateral radiographs (Figure 5). After 3 weeks POP splint was removed in all the patients and elbow range motion were started. Removal of K-wires was done after confirmation of clinico-radiological union at the fracture site. Final assessment of the results was done according to Flynn's criteria (Table 1).

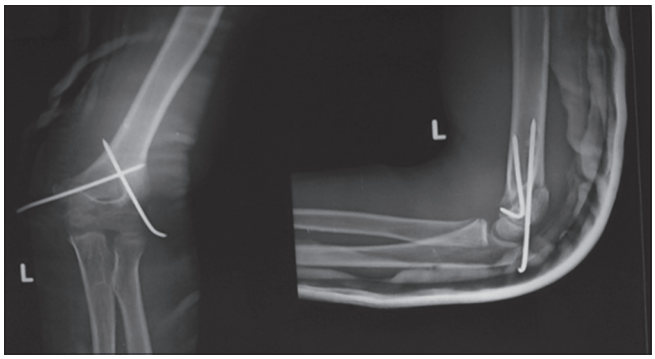

Figure 4: Immediate post-operative radiographs (anteroposterior and lateral views) of the child showing anatomical reduction of the supracondylar fracture fixed with two cross Kirchner-wires

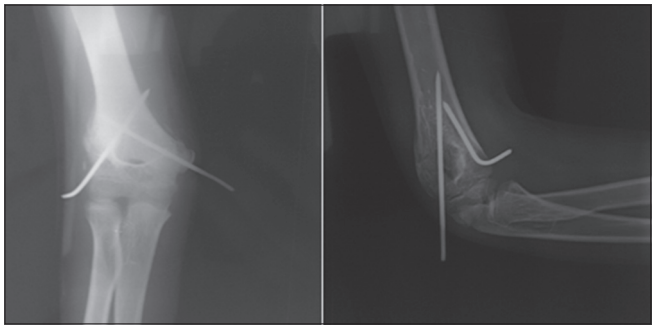

Figure 5: Four weeks follow-up radiograph (anteroposterior and lateral views) of the same patient showing union at the fracture site

Figure 3: Percutaneously inserted Kirchner-wires left outside the skin and bent at the ends

RESULTS

There were 35 patients including 22 male and 13 female children. The mean age of the patient was 6.9 years (range 3-15 years). Union was observed in all the patients at a mean interval of 4.5 weeks (range 3-5 weeks). The peak incidence of the supracondylar fracture was found in children around the age of 7 years (Table 2).

Most (80%) of the injuries were the result of high velocity trauma including road traffic accidents and fall from

Table 1: Flynn's criteria

Result	Rating	Functional outcome motion loss (°)	Cosmetic factor loss of carrying angle (°)
Satisfactory	Excellent	0-5	0-5
	Good	5-10	5-10
Unsatisfactory	Fair	10-15	10-15
	Poor	>15	>15

Table 2: Age distribution of patient

Age of patient (years)	Number of patients	Percentage
3-6	17	48.6
7-9	8	22.8
10-12	6	17.2
13-15	4	11.4
Total	35	100

Table 3: Mode of injury

Mode/mechanism of injury	Number of patient	Percentage
Road traffic accident	12	34.2
Fall from height/tree	16	45.8
Fall on the ground	7	20
Total	35	100

Table 4: Fracture displacement

Fracture displacement	Number of patients	Percentage
Gartland Type II	14	40
Gartland Type III	21	60
Total	35	100

height (Table 3). The majority (60%) of the fractures were Gartland Type III supracondylar fracture (Table 4).

Most common peripheral nerve injury observed was median nerve injury seen in 5 patients (Table 5), the next most common nerve involved was radial nerve seen in three patients. All these nerve injuries recovered following successful reduction and fixation of the fracture in a mean period of 10 weeks (range 6-14 weeks). One patient had presented with an established compartment syndrome following fracture (Table 5). This patient ultimately developed severe Volkmann ischemic contracture on subsequent follow-up.

One patient presented with a supracondylar fracture with gross posteromedial displacement, with well perfused but without a palpable radial artery in the injured upper extremity. This patient presented 24 h after sustaining the injury, an urgent reduction and fixation of the fracture was followed by the return of the peripheral pulses but, postoperatively this patient had mild ischemic contracture of the right forearm muscles. Three patients had an associated fracture of the distal end radius and ulna (Table 5).

The most common post-operative complication observed was a superficial pin tract infection seen in 5 (14.3%) patients (Table 6), this infection healed well following removal of infected pins and daily cleaning and dressing of the infected pin tracts supplemented by culture based oral antibiotics. None of the patient required hospitalization or intravenous antibiotics for pin tract infection. One patient had an iatrogenic ulnar nerve injury. Elbow stiffness was observed in 4 (11.4%) patients. Cubitus varus was seen in 1 patient, and implant loosening was seen in another 1 patient.

Overall based upon the Flynn's criteria 24 patients (68.6%) had excellent results, 6 (17.0%) patients had good, 3 (8.6%) had fair and 2 (5.8%) patients had poor functional results (Table 7).

Table 5: Pre-operative complications see in patients

Complication	Number of patients	Percentage
Established compartment syndrome	1	2.9
Pink pulse less hand	1	2.9
Radial nerve injury	3	8.6
Ulnar nerve injury	0	0.0
Median nerve injury	5	14.3
Open fracture	0	0.0
Associated fractures	3	8.6

Table 6: Post-operative complications

Complications	Number of patients	Percentage
Iatrogenic ulnar nerve injury	1	2.9
Iatrogenic median nerve injury	0	0.0
Pin tract infection	5	14.3
Loosening of K-wires	1	2.9
Malunion (varus)	1	2.9
Volk ischemic contracture	2	5.7
Elbow stiffness	4	11.4

K-wires: Kirchner-wires

Table 7: Functional results based on Flynn's criteria

Criteria	Number of patients	Percentage
Excellent	24	68.6
Good	6	17.0
Fair	3	8.6
Poor	2	5.8
Total	35	100

DISCUSSION

The most common pediatric fracture around the elbow in children <7 years of age is supracondylar fracture distal end humerus and with a male predominance. There are no controversies in the management of these fractures as far as the undisplaced fractures are concerned; such fractures can be successfully treated by immobilization alone with excellent results. The major controversy lies in the management of Gartland Type II and III displaced supracondylar fracture of the humerus. A variety of treatment options have been described for managing displaced supracondylar fractures ranging from conservative treatment on traction to close or open reduction and internal fixation using different configuration of pins/K-wires with each method having its own merits and demerits.[13-18]

Two most common configurations of the K-wires for fixation of the pediatric supracondylar fracture of humerus are cross K-wire configuration and lateral K-wire configuration in parallel or divergent fashion with its advantages and disadvantages. The major disadvantage of cross K-wire configuration is the risk of iatrogenic ulnar nerve injury however, it said to biomechanically the strongest construct. The major advantage of lateral K-wire placement is that it is free from the risk of an iatrogenic ulnar nerve injury. In our study only 1 (2.9%) patient had an iatrogenic ulnar nerve injury. Some authors have advocated the use of ultrasound to minimize the risk of ulnar nerve injury during insertion of medial pin; however, it is technically demanding, and the expertise may not be available easily.[19] Although the risk of iatrogenic peripheral nerve injuries following supracondylar fracture of the humerus has been reported ranging from 2% to

6% in various in various studies, in our study we observed this complication in only 2.9% patients, and this injury recovered at 6 months follow-up.[20,21]

The other poor indicator of treatment of supracondylar fracture of the humerus is the cubitus varus deformity due to residual medial tilt and rotation of the distal fragment. In present study one (2.9%) patient had cubitus varus deformity. The other major complication observed in the present study was superficial pin tract infection seen in 5 (14.3%) patients. This infection was managed successfully in all the patients without the need of patient readmission or parentral antibiotics. Elbow stiffness was encountered in 4 (11.4%) patients in the present study; two of these patients had only fair results based on Flynn's criteria. Pin loosening was seen in one patient following accidental removal of POP splint during follow-up visit of the patient.

Two patients with vascular complications had poor results based on Flynn's criteria. In one patient who presented with a full blown compartment syndrome of the forearm, even after urgent management of the fracture the patient developed Volkmann ischemic contracture. Another patient who presented with grossly displaced supracondylar fracture with an absent radial artery pulsation, an urgent reduction and fixation of the fracture lead to return of peripheral arterial pulsations in the injured extremity, but on subsequent follow-ups the patient showed signs of mild muscle ischemia. Based on Flynn's criteria 85.6% patients in our study had God to excellent results, 8.6% patients had fair results and only 5.8% patients had poor results.

CONCLUSION

Closed reduction and medial-lateral percutaneous K-wire fixation is the treatment of choice for displaced pediatric supracondylar fractures of the humerus with an acceptably low risk of iatrogenic ulnar nerve injury.

REFERENCES

1. Cheng JC, Shen WY. Limb fracture pattern in different pediatric age groups: A study of 3,350 children. J Orthop Trauma 1993;7:15-22.
2. Kasser JR, Beaty JH, editors. Supracondylar fractures of the distal humerus. In: Rockwood and Wilkins Fractures in Children. 6th ed., Ch. 14. Philadelphia: Lippincott Williams and Wilkins; 2006. p. 543-89.
3. Brubacher JW, Dodds SD. Pediatric supracondylar fractures of the distal humerus. Curr Rev Musculoskelet Med 2008;1:190-6.
4. Wilkins KE. Fractures and dislocations of the elbow region. In: Rockwood CA, Wilkins KE, King RE, editors. Fractures in Children. Vol. 3. Philadelphia: JB Lippincott Co.; 1984. p. 363-575.
5. Farnsworth CL, Silva PD, Mubarak SJ. Etiology of supracondylar humerus fractures. J Pediatr Orthop 1998;18:38-42.
6. Gartland JJ. Management of supracondylar fractures of the humerus in children. Surg Gynecol Obstet 1959;109:145-54.
7. O'Hara LJ, Barlow JW, Clarke NM. Displaced supracondylar fractures of the humerus in children. Audit changes practice. J Bone Joint Surg Br 2000;82:204-10.
8. Green DW, Widmann RF, Frank JS, Gardner MJ. Low incidence of ulnar nerve injury with crossed pin placement for pediatric supracondylar humerus fractures using a mini-open technique. J Orthop Trauma 2005;19:158-63.
9. Smith L. Deformity following supracondylar fractures of the humerus. Bone Joint Surg (Am) 1960;42-A:235-52.
10. Weiland AJ, Meyer S, Tolo VT, Berg HL, Mueller J. Surgical treatment of displaced supracondylar fractures of the humerus in children. Analysis of fifty-two cases followed for five to fifteen years. J Bone Joint Surg Am 1978;60:657-61.
11. Srivastava S. The results of open reduction and pin fixation in displaced supracondylar fractures of the humerus in children. Med J Malaysia 2000;55:44-8.
12. Henrikson B. Supracondylar fracture of the humerus in children. A late review of end-results with special reference to the cause of deformity, disability and complications. Acta Chir Scand Suppl 1966;369:1-72.
13. Kumar R, Kiran EK, Malhotra R, Bhan S. Surgical management of the severely displaced supracondylar fracture of the humerus in children. Injury 2002;33:517-22.
14. Skaggs DL, Hale JM, Bassett J, Kaminsky C, Kay RM, Tolo VT. Operative treatment of supracondylar fractures of the humerus in children. The consequences of pin placement. J Bone Joint Surg Am 2001;83-A:735-40.
15. Ucar BY, Demirtas A, Ucar DE. Treatment approaches and outcomes in childhood supracondylar humerus fractures. Eur Rev Med Pharmacol Sci 2012;16:936-41.
16. Pirone AM, Graham HK, Krajbich JI. Management of displaced extension-type supracondylar fractures of the humerus in children. J Bone Joint Surg Am 1988;70:641-50.
17. Dodge HS. Displaced supracondylar fractures of the humerus in children - Treatment by Dunlop's traction. J Bone Joint Surg (Am) 1972;54:1408-18.
18. Piggot J, Graham HK, McCoy GF. Supracondylar fractures of the humerus in children - Treatment by straight lateral traction. J Bone Joint Surg (Am) 1986;68:577-83.
19. Soldado F, Knorr J, Haddad S, Diaz-Gallardo P, Palau-Gonzalez J, Mascarenhas VV, *et al*. Ultrasound-guided percutaneous medial pinning of pediatric supracondylar humeral fractures to avoid ulnar nerve injury. Arch Bone Joint Surg 2015;3:169-72.
20. Rasool MN. Ulnar nerve injury after K-wire fixation of supracondylar humerus fractures in children. J Pediatr Orthop 1998;18:686-90.
21. Birch R, Achan P. Peripheral nerve repairs and their results in children. Hand Clin 2000;16:579-95.

How to cite this article: Julfiqar, Pant A, Huda N, Aslam M. Outcomes of Percutaneous Medial-Lateral Cross Pinning of the Pediatric Supracondylar Fractures of the Humerus. Int J Sci Stud 2015;3(7):112-116.

Source of Support: Nil, **Conflict of Interest:** None declared.