DOI: 10.17354/ijss/2015/436

# Fundus Macular Hypoplasia in a Case of Oculocutaneous Albinism

**Sumit Grover[1], Shalini Gupta[2], Manisha Kataria[3], Bhawna P Khurana[4]**

[1]Resident, Department of Ophthalmology, Dr. Baba Saheb Ambedkar Medical College and Hospital, Rohini, Delhi, India, [2]Assistant Professor, Department of Ophthalmology, Dr. Baba Saheb Ambedkar Medical College and Hospital, Rohini, Delhi, India, [3]Senior Resident, Department of Ophthalmology, Dr. Baba Saheb Ambedkar Medical College and Hospital, Rohini, Delhi, India, [4]Fellow, Narayana Nethralaya, Bangaluru, Karnataka, India

Albinism comprises a heterogenous group of inherited disorders characterized by the reduction or total absence of melanin pigment biosynthesis from the eye, hair, and skin.

All the current known types of albinism are inherited as autosomal recessive fashion with the exception of ocular albinism, which is X-linked recessive.

Albinism has been classified as to type by the degree and the distribution of hypopigmentation as total versus partial, ocular versus oculocutaneous.

The prevalence of all types of albinism varies considerably worldwide and has been estimated at approximately 1/7000, suggesting that about 1 in 70 people carry gene for oculocutaneous albinism (OCA).

The clinical spectrum of OCA ranges with OCA1 being the most severe type with a complete lack of melanin production throughout life, while the milder forms OCA1B, OCA2, OCA3, and OCA4 shows some pigment accumulation over time.

The ocular consequences of pigmentary dilution are identical in all types of albinism:

- Nystagmus may be detected in first few months of life
- VA ranges from 20/80 to 20/400 but may be as good as 20/40 in some patients of OCA-2
- Patients are generally photophobic, and there is a high incidence of strabismus and astigmatic errors of refraction. Color vision is generally normal. The amplitudes of the scotopic electroretinographic response may be more than normal, and a high electrooculographic Arden ratio may be recorded. Abnormal decussation of optic nerve fibers at the chiasma is seen with misrouting of the optic nerve fibers.

Anterior segment findings: A pink reflex is sometimes seen through the undilated iris (Figure 1). Retroillumination

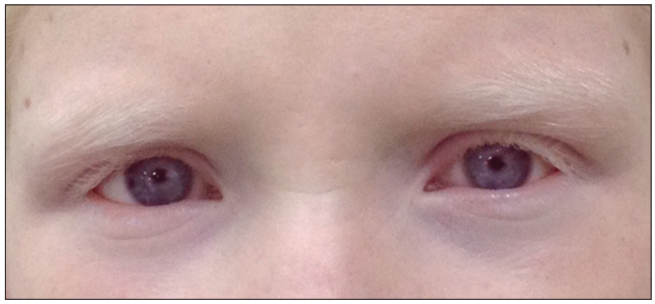

**Figure 1: Clinical picture showing undilated hypopigmented iris**

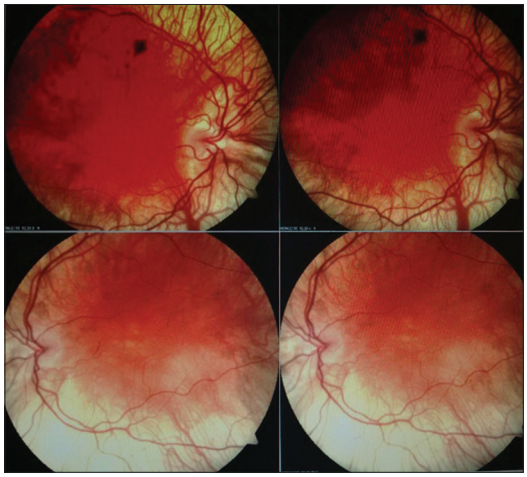

**Figure 2: Fundus pictures shows prominence of the choroidal vasculature because of the lack or paucity of pigment in the overlying RPE and surrounding choroidal stroma**

**Access this article online**

www.ijss-sn.com

**Month of Submission** : 07-2015
**Month of Peer Review** : 08-2015
**Month of Acceptance** : 08-2015
**Month of Publishing** : 09-2015

**Corresponding Author:** Dr. Sumit Grover, House No-1134, Sector-21, Gurgaon, Haryana, India. Phone: +91-9871264596.
E-mail: dr.sumitgrover@gmail.com

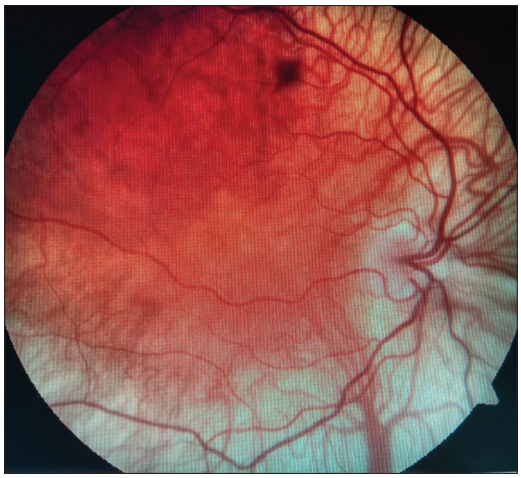

**Figure 3: Fundus picture shows hypoplastic macula with the absent foveal pit. The retinal vessels fail to wreath the fovea**

shows transillumination through the iris and the globe. The outline of the lens can be seen.

Fundus findings: There is prominence of the choroidal vasculature because of the lack or paucity of pigment in the overlying RPE and surrounding choroidal stroma (Figure 2).

The macula is always hypoplastic and foveal pit is absent. Many post-mortem histopathological studies[1-3] shows no foveal pit or umbo but thick central ganglion and nuclear cell layers.

The retinal vessels fail to wreath the fovea (Figure 3). Some pigment may be present in the presumed macular area, obscuring a view of the submacular choroidal vasculature. FFA findings in few studies showed multiple window defects in the RPE with normal foveal avascular zone.[4] Patients with tyrosine positive OCA were more likely to demonstrate foveation than those with tyrosinase negative disease.

### Points to Ponder

- The etiology of macular hypoplasia which is the most important factor causing visual impairment is not fully understood but may be related to reduced amount of melanin in the RPE. Hypoplastic macula may also be seen in aniridia and retinopathy of Prematurity.
- Differential Diagnosis includes entities that can present with cutaneous and ocular hypopigmentation namely waardenburg syndrome, vitiligo, congenital nystagmus, achromatopsia.

## REFERENCES


1. Fulton AB, Albert DM, Craft JL. Human albinism. Light and electron microscopy study. Arch Ophthalmol 1978;96:305-10.
2. Mietz H, Green WR, Wolff SM, Abundo GP. Foveal hypoplasia in complete oculocutaneous albinism. A histopathologic study. Retina 1992;12:254-60.
3. Naumann GO, Lerche W, Schroeder W. Foveolar aplasia in tyrosinase-positive oculocutaneous albinisim (author's transl). Albrecht Von Graefes Arch Klin Exp Ophthalmol 1976;200:39-50.
4. Gregor Z. The perifoveal vasculature in albinism. Br J Ophthalmol 1978;62:554-7.


**How to cite this article:** Grover S, Gupta S, Kataria M, Khurana BP. Fundus Macular Hypoplasia in a Case of Oculocutaneous Albinism. Int J Sci Stud 2015;3(6):251-252.

**Source of Support:** Nil, **Conflict of Interest:** None declared.