

A Cross-Sectional Study on Pupillary Mydriasis among Patients with Pseudoexfoliation in a Tertiary Care Center

G Archana¹, Hemalatha Krishnamurthy², Ravali Yenepalli¹

¹Post Graduate, Department of Ophthalmology, Karpagam Faculty of Medical Sciences and Research, Coimbatore, Tamil Nadu, India,

²Professor and Head, Department of Ophthalmology, Karpagam Faculty of Medical Sciences and Research, Coimbatore, Tamil Nadu, India

Abstract

Objective: This study aims to assess the pupillary mydriasis in Pseudoexfoliation (PXF) patients and their complications during cataract surgery.

Materials and Methods: One hundred subjects with PXF amounting to 171 eyes with exfoliative material were involved in the study and were examined for pupillary mydriasis. The intra and post-operative complications were assessed in 60 eyes which were operated by manual small incision cataract surgery.

Results: 41.6% of the operated cases had complications. The majority of them had poor mydriasis and floppy iris during the intraoperative period.

Conclusion: A notable correlation was observed between the size of pupil dilatation and intraoperative complications.

Key words: Cataract surgery, Complication, Pseudoexfoliation, Pupillary mydriasis, Sics

INTRODUCTION

The description of pseudoexfoliation (PXF) was first done by John G. Lindberg earlier in the twentieth century. PXF syndrome is an age-associated systemic disorder characterized by abnormal synthesis and turnover of the extracellular matrix. It results in the progressive deposition of extracellular, fibrillary, white, flaky deposits in different tissues and organs of the body.^[1] In the eyes, the pseudoexfoliative material appears as white-colored deposits on the anterior capsule of the crystalline lenticular surface. It can also be found dusted over the pupillary region of the iris.^[2] The chemical composition of exfoliation material is not clearly known till date. It is made up of a central protein core which in turn is surrounded by glycoconjugates. The

protein core has a non-collagenous substance similar to that found in the basement membrane. It also has fibers that resemble elastic microfibrils.^[3] Recent genetic studies show a strong association between seven genetic loci (LOXL1, CACNA1A, FLT1-POMP, TMEM136-ARHGEF12, AGPAT1, RBMS3, and SEMA6A) and increased risk of PXF syndrome.^[4] PXF syndrome has been reported to have a Universal prevalence, but the rate of prevalence of this condition was variable across different regions.

In South India, specifically as reported by Krishnadas *et al.* in 2003, the prevalence of PXF syndrome was reported to be 6%.^[5]

Pupillary Mydriasis in PXF Syndrome

Poor dilation of the pupil was noted in the eyes which are affected by PXF, even in cases where drugs such as miotics have never been administered before. This phenomenon may be due to the structural and functional changes in the iris associated with PXF, such as fibrosis and atrophy of the iris sphincter muscle.^[6]

Secondary open-angle glaucoma can occur also as a result of PXF syndrome. It was found that higher

Access this article online



www.ijss-sn.com

Month of Submission : 02-2025
Month of Peer Review : 03-2025
Month of Acceptance : 03-2025
Month of Publishing : 04-2025

Corresponding Author: Dr. G Archana, Post Graduate, Department of Ophthalmology, Karpagam Faculty of Medical Sciences and Research, Coimbatore - 641032, Tamil Nadu, India.

mean intraocular pressure (IOP), secondary open-angle glaucoma, and mature and nuclear cataracts are seen in association with PXF. PXF syndrome is associated with an increased risk of complications such as posterior capsule rupture, vitreous loss, aphakia, poor pupillary mydriasis, nucleus drop, and zonular dehiscence. Poor pupillary dilatation causes difficulty in nucleus delivery.

Need for the Study

This study aims to investigate the clinical significance of pupillary mydriasis in patients with PXF syndrome at a tertiary care center. Assessing pupillary mydriasis in PXF patients can help in taking precautions while during cataract surgery to reduce the risk of complications due to poor dilation.

Objectives

- 1) To assess about the pupillary dilatation in the eyes of pseudoexfoliation patients
- 2) To study about the surgical complications of manual sics in eyes with pseudoexfoliation.

MATERIALS AND METHODS

Study Design

This hospital-based observational study was conducted at the ophthalmology department of a tertiary care center, enrolling 100 patients diagnosed with PXF syndrome for a study period of 1 year from September 2022. The study was approved by the institutional ethics committee, and informed consent was obtained from all participants.

Inclusion Criteria

- Adults aged above 40 years of age
- Diagnosed with PXF syndrome in one or both eyes based on clinical examination and slit-lamp evaluation
- Ability to participate in the study and provide informed consent.

Exclusion Criteria

- History of ocular trauma or surgery that could affect the pupil response
- Patients below 40 years of age
- Presence of other ocular conditions such as acute uveitis, retinal diseases, or neuro-ophthalmic disorders that might confound pupillary assessment
- Patients are unable or unwilling to comply with study protocols.

Clinical Examination

A comprehensive ocular examination was performed for each patient, which included:

- Slit-lamp examination: To assess the characteristic features of PXF, including the presence of fibrillary

material on the lens capsule, iris, and other anterior segment structures

- Fundoscopy: Fundus examination was done using a 90D lens to assess the optic nerve for signs of glaucomatous damage, including cupping and disc hemorrhages
- IOP measurement: Using a Goldman applanation tonometer to measure IOP
- Pupillary examination: Pupillary size and response to light were evaluated under standard lighting conditions. The pupil was dilated using 0.8% tropicamide and 5% phenylephrine eye drops. After dilation, patients were again examined under a slit lamp, and pupillary diameter was noted in millimeters. The lens opacities classification system is used for grading the lens cataractous changes.

Data Collection

Demographic information (age, gender) and clinical features (disease duration, IOP) were recorded for each patient. Pupillary size and mydriasis severity were documented using direct observation and slit-lamp biomicroscope. For patients undergoing cataract surgery, A-scan ultrasound biometry for axial length and keratometry for corneal curvature was done. Intraocular lens power was calculated using SRK formulae. Any intraoperative complications such as Aphakia, posterior rent, vitreous loss, nucleus drop, and poor mydriasis were noted for patients undergoing cataract surgery.

Statistical Analysis

Data analysis was performed using a statistical package for the social sciences software version 26. Descriptive statistics were used to summarize demographic characteristics, whereas the prevalence of pupillary mydriasis and the relationship between mydriasis and complications were expressed in percentage.

RESULTS

The study included 100 patients diagnosed with PXF syndrome. The majority percentage of study subjects fall in the 61–70 years of age category which is approximately contributing to 40% of the total study population. Among them, 57% of them were females and the remaining 43% were males. 71% of them had a bilateral distribution of exfoliative material whereas the remaining 29% had a unilateral presentation. Hence, a total of 171 eyes with PXF were included in the study.

Among the males, 22.8% had a unilateral occurrence and 77.2% had a bilateral occurrence. In our study, the females had 62.8% bilateral distribution and 37.2% unilateral

occurrence as shown in Figure 1. There was a unilateral distribution of 37.9% in the 71–80 years age category whereas there was 43.7% of them who had bilateral PXF were in the 61–70 years age category.

As far as systemic association is concerned, 32% of the study population had hypertension followed by 21% with diabetes mellitus as depicted in Figure 2. On examination with a slit lamp biomicroscope, 19.3% of the study subjects had PXF on the iris surface, 58.5% had poor pupil dilatation, and 61.4% had PXF on the pupil. In the lens component, 61.4% had PXF on the anterior lens capsule. The anterior chamber was found to be open in almost all cases. Nearly, 66.6% of the study subjects presented with nuclear sclerosis.

As far as intra-ocular pressure was concerned, the pre-operative IOP in eyes with PXF was <20 in 95.3% of the study population. Most of them had normal IOP.

Only 28 eyes out of 171 eyes which we examined had a pupillary mydriasis of 8 mm as shown in Table 1. Among 60 eyes were operated and out of which 25 had some complications during the intra- and post-operative period. Among the intraoperative complications, 76% had poor mydriasis, 48% of them had floppy iris and 28% of them had difficulty in nucleus delivery as shown in Figure 3. Corneal edema was noted in the post-operative period in 16% of the study population which resolved in the subsequent days and almost 96% of the cases had regained a good vision of more than 6/12. The association of complications with pupil dilatation is described in Table 2.

DISCUSSION

This study involved 100 patients diagnosed with PXF who visited the ophthalmology department at a tertiary hospital during the study period. Table 3 illustrates the distribution of study subjects across different age groups. Among them, 1% were reported to be in their fourth-decade age group. Twenty percent of them were reported to be belonging to the fifth decade whereas 40% were in their sixth decade of age. 27% were reported to be in their seventh decade of age whereas 9% were of age of more than 81 years. The average age of patients' presentation was calculated to be 68.71 years. While the majority of them (76 out of 100) were over 60 years old. This observation coincides with numerous studies indicating that the PXF syndrome is basically a condition associated with normal aging, while its prevalence increases gradually as individuals grow older.

About 84% of subjects had presented with exfoliative material dusted over the pupillary area of the iris in a study

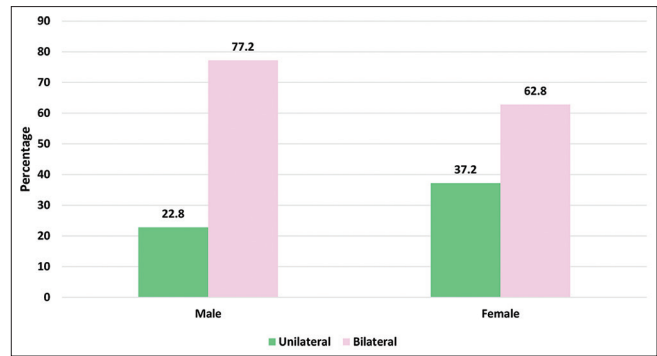


Figure 1: Laterality-sex incidence

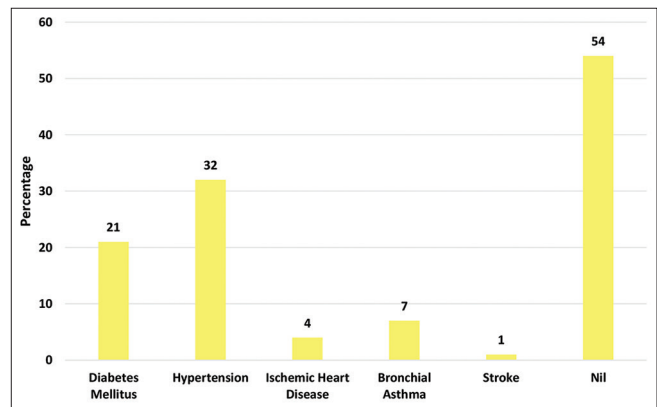


Figure 2: Systemic association

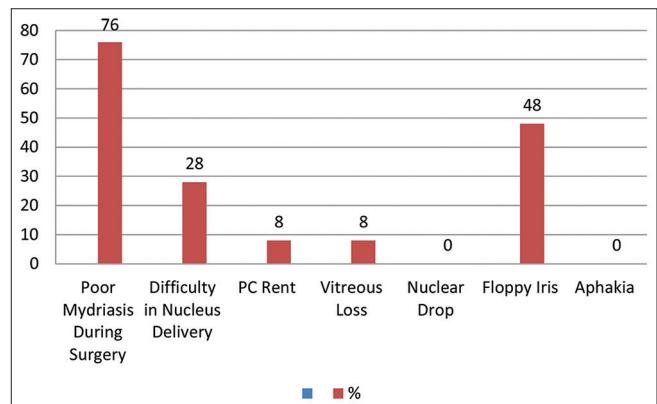


Figure 3: Intraoperative complications

Table 1: Pupil size after dilatation in eyes with PXF

Pupil size after dilatation	Frequency (n)	Percentage
≤5 mm	37	21.6
6 mm	63	36.8
7 mm	43	25.1
≥8 mm	28	16.5

PXF: Pseudoexfoliation

done by Naumann *et al.*^[7] In concordance with this study, 61.4% of our study subjects which accounts for nearly 105 presented with exfoliative particles over their pupillary zone. Similar to our study population, nuclear sclerosis or

Table 2: Association of surgical complications with pupillary dilatation (n=25)

Complications	Frequency (n)	Pupil size after dilatation			
		≤6 mm		>6 mm	
		Frequency (n)	%	Frequency (n)	%
Poor mydriasis during surgery	19	15	78.9	4	21.1
Difficulty in nucleus delivery	7	5	71.4	2	28.6
PC rent	1	1	100	0	0
Vitreous loss	0	0	0	0	0
Nuclear drop	0	0	0	0	0
Floppy iris	12	6	50	6	50
Aphakia	0	0	0	0	0

Table 3: Distribution of age among participants (n=100)

Age (in years)	Frequency (n)	Percentage
41–50 years	1	1
51–60 years	23	23
61–70 years	40	40
71–80 years	27	27
Above 81	9	9

hard cataract was demonstrated to be the most frequently encountered variant of cataract in PXF patients in a study by Hietanen *et al.*^[8]

In a study by Freyler, 19 Patients had very minimal pupillary mydriasis during cataract surgery.^[9] A research work by Asano and his colleagues brought to light that in addition to degenerative changes affecting the sphincter fibers of the pupil in eyes with exfoliation, there are also changes involving the dilator fibers of the pupil.^[10] In our current study, among the 60 study patients who underwent cataract surgery, poor mydriasis during the procedure was observed in 19 patients.

The study by Lumme and Lattikaanen revealed 10 times the raised possibility of breaching the posterior lenticular capsule whereas operating on eyes with exfoliative particles. He also postulated that this increased susceptibility to the presence of suspensory ligament instability in 15% of his study members.^[11]

In concordance with the above study, a similar ten-fold rise in on-table complications was revealed in a study by Ritch a pioneer in this field.^[2]

A study conducted at the end of the twentieth century by Laatikainen revealed that there is a significantly higher risk of vitreous loss nearly 4 times than that of the control group observed in the group with exfoliation syndrome.^[11]

A study by Avramides *et al.* revealed that 7.14% of people had vitreous loss similar to our research work.^[12] Similarly,

vitreous loss was encountered in a relatively significant percentage in our study accounting for 8%. A similar outcome was found in the research work of Zenkel *et al.* where the presence of vitreous loss was almost 7% during surgical procedures.^[13] A research work by Naseem *et al.* revealed nearly 50% of the people involved in his study developed haziness of cornea due to edema in the post-operative period.^[14] In contrary to this, only 16.6% of people had edema of the cornea in our study after surgical removal of the cataract.

CONCLUSION

Poor pupillary mydriasis is a prevalent and significant finding in patients with PXF syndrome. This study underscores the importance of evaluating pupillary function in PXF patients as part of comprehensive ocular management as poor response of pupils to dilating agents during pre-operative assessment triggers warning signals for increased probability of complications during cataract surgery. Further research is required to understand the underlying mechanisms of pupillary changes in PXF. Our study had the following limitations such as the lack of a control group to compare our outcomes. There is also difficulty in post-operative follow-up to look for any setbacks due to the reason that a huge chunk of our patients were from villages in remote places. All these factors made us concentrate solely on earlier onset complications during the stay of patients in our hospital. Our study had fewer participants and non-analytical study. To extrapolate the study findings to the general population, there is a need for larger-scale research.

REFERENCES

1. Mastronikolis S, Pagkalou M, Plotas P, Kagkellaris K, Georgakopoulos CD. Emerging roles of oxidative stress in the pathogenesis of pseudoexfoliation syndrome (review). *Exp Ther Med* 2022;24:602.
2. Ritch R. Ocular and systemic manifestations of exfoliation syndrome. *J Glaucoma* 2014;23:S1-8.
3. Ritch R, Schlötzer-Schrehardt U, Konstas AG. Why is glaucoma associated

- with exfoliation syndrome? Prog Retin Eye Res 2003;22:253-75.
4. Aung T, Chan AS, Khor CC. Genetics of exfoliation syndrome. J Glaucoma 2018;27 Suppl 1:S12-4.
 5. Krishnadas R, Nirmalan PK, Ramakrishnan R, Thulasiraj RD, Katz J, Tielsch JM, *et al.* Pseudoexfoliation in a rural population of Southern India: The Aravind comprehensive eye survey. Am J Ophthalmol 2003;135:830-7.
 6. Repo LP, Naucharinen A, Paljärvi L, Teräsvirta ME. Pseudoexfoliation syndrome with poorly dilating pupil: A light and electron microscopic study of the sphincter area. Graefes Arch Clin Exp Ophthalmol 1996;234:171-6.
 7. Naumann GO, Schlotzer-Schrehardt U, Kuchle M. Pseudoexfoliation syndrome for the comprehensive ophthalmologist. Intraocular and systemic manifestations. Ophthalmology 1998;105:951-68.
 8. Hietanen J, Kivela T, Vesti E, Tarkkanen A. Exfoliation syndrome in patients scheduled for cataract surgery. Acta Ophthalmol (Copenh) 1992;70:440-6.
 9. Freyler H, Radax U. Pseudoexfoliation syndrome--a risk factor in modern cataract surgery? Klin Monbl Augenheilkd 1994;205:275-9.
 10. Asano N, Schlotze-Scherhardt U, Naumann GO. A histopathologic study of iris changes in pseudoexfoliation syndrome. Ophthalmology 1996;102:1279-90.
 11. Lumme P, Lattikainen L. Exfoliation syndrome and cataract extraction. Am J Ophthalmol 1993;116:51-5.
 12. Avramides S, Traianidis P, Sakkias G. Cataract surgery and lens implantation in eyes with exfoliation syndrome. J Cataract Refract Surg 1997;23:583-7.
 13. Zenkel M, Kruse FE, Junemann AG, Naumann GO, Schlotzer-Schrehardt U. Clusterin deficiency in eyes with pseudoexfoliation syndrome may be implicated in the aggregation and deposition of pseudoexfoliative material. Invest Ophthalmol Vis Sci 2006;47:1982-90.
 14. Naseem A, Khan S, Khan MN, Muhammad S. Cataract surgery in patients with pseudoexfoliation. Pak J Ophthalmol 2007;23:155-60.

How to cite this article: Archana G, Krishnamurthy H, Yenepalli R. A Cross-Sectional Study on Pupillary Mydriasis among Patients with Pseudoexfoliation in a Tertiary Care Center. Int J Sci Stud 2025;13(1):1-5.

Source of Support: Nil, **Conflicts of Interest:** None declared.