

Intracerebral Hemorrhage as Isolated Complication in Coronavirus Disease 2019 Patient: A Case Report

Jipsa Anand¹, Gurjinder Singh², Janender Pal Singh³, Ambreen Jyot Sidhu⁴, Anuj Uttam⁵, Monica Chhabra⁶

¹Consultant Radiologist, Department of Radiology, Bijendra Multispeciality Hospital, Ropar, Punjab, India, ²Attending Consultant, Department of Radiology, Max Super Speciality Hospital, Mohali, Punjab, India, ³Director and Head of Department, Department of Radiology, Max Super Speciality Hospital, Mohali, Punjab, India, ⁴Consultant, Department of Radiology, Max Super Speciality Hospital, Mohali, Punjab, India, ⁵Principle Consultant, Department of Radiology, Max Super Speciality Hospital, Mohali, Punjab, India, ⁶Associate Director, Department of Radiology, Max Super Speciality Hospital, Mohali, Punjab, India

Abstract

Human coronaviruses have neuroinvasive capacities and may be neurovirulent by two main mechanisms: Viral replication into neuronal or glial cells of the brain or autoimmune reaction with a misdirected host immune response. In the present study, we present clinical presentation and imaging finding in a coronavirus disease 2019 (COVID-19) patient who presented as a rare isolated complication of severe intracranial hemorrhage to our institution, which has not been reported till date, in our knowledge. A 64-year-old patient presented with the complaints of headache and altered mental status. CT brain reflected multiple cerebral, left thalamic, and medullary hemorrhages. Antiphospholipid antibodies, IgM beta2 glycoprotein antibodies, and COVID antibodies came out to be positive. Contrast enhanced magnetic resonance (CEMR) was performed to rule out the other complications of COVID. CEMRI depicted multiple cerebral hemorrhages, involving the left thalamus, cerebellar hemispheres, and medulla. Hence, the patient got infected with COVID-19 at some point of time but remained asymptomatic and now presented with late complication of COVID as multiple cerebral and cerebellar hemorrhages.

Key words: Case report, COVID-19, Intracerebral hemorrhage, Neurovirulent

BACKGROUND

Due to the unprecedented times, the world witnessed the pandemic with the surge of coronavirus disease 2019 (COVID-19). Recent reports have highlighted the relationship between COVID-19 and cerebrovascular disease (CVD). Although, ischemic CVD has been validated to be a hypercoagulable state characterized by micro- and macrovascular thrombotic angiopathy,^[1,2] is more common and is described in literature,^[3-6] reports on hemorrhagic CVD in these patients are limited and occasional.^[7-10] The paper presents the clinical presentation and imaging finding in a COVID-19 patient who presented as a rare isolated complication of severe intracranial hemorrhage (ICH) to our institution, which has not been reported till date, in our knowledge.

Human coronaviruses have neuroinvasive capacities and may be neurovirulent by two main mechanisms^[11-13] Viral replication into neuronal or glial cells of the brain or autoimmune reaction with a misdirected host immune response.^[14]

CASE PRESENTATION

On put date, the neurology department of our hospital reported a 64-year-old patient with the complaints of headache and altered mental status. Classic Framingham risk factors such as advanced age, being male, and pre-existing illnesses of diabetes mellitus, which are well-established risk factors for vascular degenerative changes, were present. The patient was not on any form of anticoagulation therapy. There was no history of recent or remote head trauma.

On physical examination, the following observations were made:-spontaneous response to eye opening (E4), no response to painful stimulus (M1), and no verbal response (V1), that is, glasgow coma scale of 6 and a fever of 100.3 F.

Access this article online



www.ijss-sn.com

Month of Submission : 01-2022
Month of Peer Review : 01-2022
Month of Acceptance : 02-2022
Month of Publishing : 03-2022

Corresponding Author: Dr. Jipsa Anand, Department of Radiology, Bijendra Multispeciality Hospital, Ropar, Punjab, India.

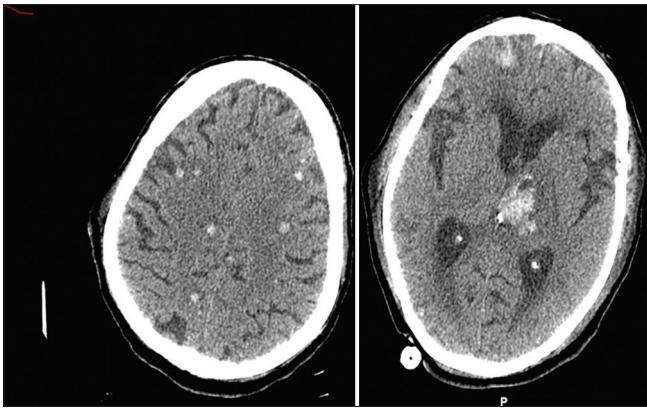


Figure 1: Non contrast computed tomography head shows multiple foci of cerebral hemorrhages, also involving the left thalamus

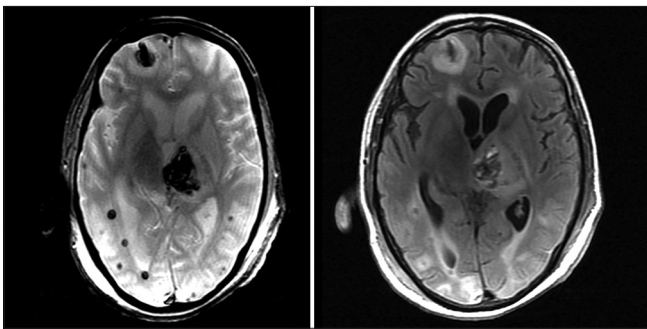


Figure 2: GRE and FLAIR images of the brain taken at the level of basal ganglia shows multiple cerebral hemorrhages

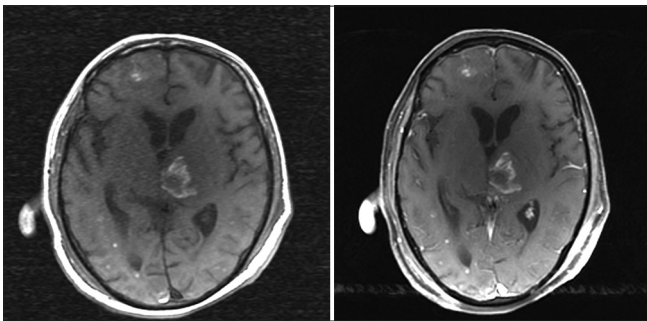


Figure 3: Pre- and post-contrast T1W images shows multiple foci of intracerebral hemorrhages with no post-contrast enhancement

Furthermore, laboratory investigation of complete blood count and COVID antigen was sent, and also head non contrast computed tomography (NCCT) was conducted.

The complete blood work showed thrombocytopenia and deranged coagulation profile. NCCT brain reflected multiple cerebral, left thalamic and medullary hemorrhages. The COVID antigens were negative.

In view of deranged coagulation profile, vasculitis workup, antiphospholipid antibodies (APLA), and IgM beta2 glycoprotein antibodies were ordered, and the result

came out to be positive. Because of ongoing COVID-19 pandemic and positive APLA, COVID antibodies and NCCT chest were performed. CT chest came out to be normal while antibodies were positive. Hence, the conclusion drawn was as follows:- The patient got infected with COVID-19 at some point of time but remained asymptomatic and now presented with late complication of COVID as multiple cerebral and cerebellar hemorrhages as observed on NCCT [Figure 1].

Contrast enhanced magnetic resonance imaging (CEMRI) was performed to rule out the other complications of COVID. CEMR depicted multiple cerebral hemorrhages, involving the left thalamus, cerebellar hemispheres, and medulla [Figures 2 and 3]. No abnormal meningeal/parenchymal enhancement on post-contrast scans was found.

DISCUSSION

The common imaging findings across all the articles is acute infarction that is prognostic marker of a poor result in COVID-19^[15] hospitalized patients seconded by diffuse white matter abnormality, consistent with leukoencephalopathy, with parenchymal microhemorrhages. Isolated ICH was noted in the above case reported by us with no associated infarction, white matter changes, and abnormal parenchymal enhancement.

COVID-19 can have association with a type of leukoencephalopathy which is particularly characterized by the presence (existence) of microhemorrhages. This might be a consequence of severe acute respiratory syndrome coronavirus 2 (SARS-CoV-2) CNS infection or a secondary effect of a generalized COVID-19 (such as hypercoagulability).^[16]

As observed and speculated by Nicholson *et al.*,^[17] multifocal, predominantly petechial hemorrhages in patients with COVID-19 may have resulted from diffuse thrombotic microangiopathy, which has previously been reported to cause similar abnormalities^[18] and can also lead to PRES.^[19]

Relatively, high percentage of neurologic involvement can be accounted by neurotropism of coronavirus.^[20,21] In addition, other explanations shouldn't be secluded: Wide expression of the angiotensin-converting enzyme 2 (ACE2) receptor on endothelial cells in the brain.^[22,23] This has been showed by few studies available and can activate a cytokine storm that recruits macrophages and causes inflammatory reactions similarly as vasculitis. Moreover, there is possibility that ICH may be linked with arterial hypertension catalyzed by binding of ACE2 receptors with SARS-CoV-2 and thrombocytopenia.^[24,25]

From the recent study conducted by Cheruiyot,^[26] hemorrhage involving multiple cranial compartments was reported in 14 cases (9.5%). Single compartments were involved in the rest, with intraparenchymal hemorrhage being the most common variety (62.6%), followed by sub-arachnoid hemorrhage (15.0%), subdural hemorrhage (11.6%), and intraventricular hemorrhage (1.4%).

CONCLUSION

Although neurological complications such as acute infarction and diffuse white matter abnormality are relatively common among COVID-19 patients, case of isolated ICH is rare. Early identification of patients at risk of developing ICH, particularly with comorbid conditions, may be important to improve outcomes.

AUTHORS CONTRIBUTIONS

JA conceived the study, participated in its design and coordination, drafted the manuscript, and carried out the radiological results. GS participated in the study design and helped in drafting the manuscript and radiological results. JPS participated in the study design and helped in drafting the manuscript and radiological results. AJS participated in the study design and helped in drafting the manuscript and radiological results. AU participated in the study design and helped in drafting the manuscript and radiological results. MC participated in the study design and helped in drafting the manuscript and radiological results.

REFERENCES

- Magro C, Mulvey JJ, Berlin D, Nuovo G, Salvatore S, Harp J, *et al.* Complement associated microvascular injury and thrombosis in the pathogenesis of severe COVID-19 infection: A report of five cases. *Transl Res* 2020;220:1-13.
- Panigada M, Bottino N, Tagliabue P, Grasselli G, Novembrino C, Chantarangkul V, *et al.* Hypercoagulability of COVID-19 patients in intensive care unit: A report of thromboelastography findings and other parameters of hemostasis. *J Thromb Haemost* 2020;18:1738-42.
- Klok FA, Kruip MJ, van der Meer NJ, Arbous MS, Gommers D, Kant KM, *et al.* Confirmation of the high cumulative incidence of thrombotic complications in critically ill ICU patients with COVID-19: An updated analysis. *Thromb Res* 2020;191:148-50.
- Lodigiani C, Iapichino G, Carenzi L, Cecconi M, Ferrazzi P, Sebastian T, *et al.* Venous and arterial thromboembolic complications in COVID-19 patients admitted to an academic hospital in Milan, Italy. *Thromb Res* 2020;191:9-14.
- Thomas W, Varley J, Johnston A, Symington E, Robinson M, Sheares K, *et al.* Thrombotic complications of patients admitted to intensive care with COVID-19 at a teaching hospital in the United Kingdom. *Thromb Res* 2020;191:76-7.
- Viguier A, Delamarre L, Duplantier J, Olivot JM, Bonneville F. Acute ischemic stroke complicating common carotid artery thrombosis during a severe COVID-19 infection. *J Neuroradiol* 2020;47:393-4.
- Altschul DJ, Unda SR, de La Garza RR, Zampolin R, Benton J, Holland R, *et al.* Hemorrhagic presentations of COVID-19: risk factors for mortality. *Clin Neurol Neurosurg* 2020;198:106112.
- Morassi M, Bagatto D, Cobelli M, D'Agostini S, Gigli GL, Bnà C, *et al.* Stroke in patients with SARS-CoV-2 infection: Case series. *J Neuro* 2020;267:2185-92.
- Reddy ST, Reddy ST, Garg T, Shah C, Nascimento FA, Imran R, *et al.* Cerebrovascular disease in patients with COVID-19: A review of the literature and case series. *Case Rep Neurol* 2020;77030:199-209.
- Romero-Sánchez CM, Díaz-Maroto I, Fernández-Díaz E, Sánchez-Larsen Á, Layos-Romero A, García-García J, *et al.* Neurologic manifestations in hospitalized patients with COVID-19: the ALBACOV registry. *Neurology* 2020;95:e1060-70.
- Bohmwald K, Gálvez NMS, Ríos M, Kalergis AM. Neurologic alterations due to respiratory virus infections. *Front Cell Neurosci* 2018;12:386.
- Desforges M, Le Coupanec A, Stodola JK, Meessen-Pinard M, Talbot PJ. Human coronaviruses: Viral and cellular factors involved in neuroinvasiveness and neuro-pathogenesis. *Virus Res* 2014;194:145-58.
- Desforges M, Le Coupanec A, Dubeau P, Bourgouin A, Lajoie L, Dubé M, *et al.* Human coronaviruses and other respiratory viruses: Underestimated opportunistic pathogens of the central nervous system. *Viruses* 2019;12:E14.
- Li Y, Li H, Fan R, Wen B, Zhang J, Cao X, *et al.* Coronavirus infections in the central nervous system and respiratory tract show distinct features in hospitalized children. *Intervirology* 2016;59:163-9.
- Jain R, Young M, Dogra S, Kennedy H, Nguyen V, Jones S, *et al.* COVID-19 related neuroimaging findings: A signal of thromboembolic complications and a strong prognostic marker of poor patient outcome. *J Neuro Sci* 2020;414:116923.
- Radmanesh A, Derman A, Lui YW, Hagiwara M, Borija MJ, Zan E, Fatterpekar GM. COVID-19-associated diffuse leukoencephalopathy and microhemorrhages. *Radiology* 2020;297:202040.
- Nicholson P, Alshafai L, Krings T. Neuroimaging findings in patients with COVID-19. *AJNR Am J Neuroradiol* 2020;41:1380-3.
- Ellechuk TN, Shah LM, Hewlett RH, Osborn AG. Suspicious neuroimaging pattern of thrombotic microangiopathy. *AJNR Am J Neuroradiol* 2011;32:734-8.
- Hawley JS, Ney JP, Swanberg MM. Thrombotic thrombocytopenic purpura-induced posterior leukoencephalopathy in a patient without significant renal or hypertensive complications. *J Postgrad Med* 2004;50:197-9.
- Morfopoulou S, Brown JR, Davies EG, Anderson G, Virasami A, Qasim W, *et al.* Human coronavirus OC43 associated with fatal encephalitis. *N Engl J Med* 2016;375:497-8.
- Tsai LK, Hsieh ST, Chang YC. Neurological manifestations in severe acute respiratory syndrome. *Acta Neurol Taiwan* 2005;14:113-9.
- Varga Z, Flammer AJ, Steiger P, Haberecker M, Andermatt R, Zinkernagel AS, *et al.* Endothelial cell infection and endotheliitis in COVID-19. *Lancet* 2020;395:1417-8.
- Hamming I, Timens W, Bulthuis ML, Lely AT, Navis GJ, van Goor H. Tissue distribution of ACE2 protein, the functional receptor for SARS coronavirus. A first step in understanding SARS pathogenesis. *J Pathol* 2004;203:631-7.
- Guan W, Ni Z, Hu Y, Liang W, Ou C, He J, *et al.* Clinical characteristics of coronavirus disease 2019 in China. *N Engl J Med* 2020;382:1708-20.
- Oudit GY, Kassiri Z, Jiang C, Liu PP, Poutanen SM, Penninger JM, *et al.* SARS-coronavirus modulation of myocardial ACE2 expression and inflammation in patients with SARS. *Eur J Clin Invest* 2009;39:618-25.
- Cheruiyot I, Sehmi P, Ominde B, Bundi P, Misilani M, Ngure B, *et al.* Intracranial hemorrhage in coronavirus disease 2019 (COVID-19) patients. *Neuro Sci* 2021;42:25-33.

How to cite this article: Anand J, Singh G, Singh JP, Sidhu AJ, Uttam A, Chhabra M. Intracerebral Hemorrhage as Isolated Complication in Coronavirus Disease 2019 Patient: A Case Report. *Int J Sci Stud* 2022;9(12):1-3.

Source of Support: Nil, **Conflicts of Interest:** None declared.