

Localized Lesion of Plasma Cell Gingivitis Mimicking Pyogenic Granuloma: A Case Report

Shikha Gupta¹, Priya Kumar², Shruti Tandon³, Sunita Gupta⁴

¹Senior Resident, Department of Oral Medicine and Radiology, Maulana Azad Institute of Dental Sciences, New Delhi, ²Associate Professor, Department of Oral Pathology and Microbiology, Maulana Azad Institute of Dental Sciences, New Delhi, India, ³Associate Professor, Department of Periodontics and Oral Implantology, Maulana Azad Institute of Dental Sciences, New Delhi, India, ⁴Professor and HOD, Department of Oral Medicine and Radiology, Maulana Azad Institute of Dental Sciences, New Delhi, India

Abstract

Plasma cell gingivitis is a rare benign condition of unknown etiology postulated to be an immunologic reaction to allergens such as flavoring agents, mouthwash, dentifrices, cinnamon, and chewing gum. The diagnosis is usually made after histopathological examination which reveals inflammatory infiltrate in connective tissue composed predominantly of plasma cells. We present here a case of plasma cell gingivitis in a 22-year-old female which was diagnosed on basis of characteristic histopathological findings and was managed by conventional periodontal treatment. Plasma cell gingivitis usually affects gingiva in a more generalized manner, but this case reports an atypical presentation in form of a localized lesion similar to pyogenic granuloma. Through this case, we highlight the importance of proper history taking and histopathology to institute proper treatment for lesions which are refractory to conventional procedures alone.

Key words: Cartwheel, Gingivitis, Plasma, Pyogenic

INTRODUCTION

Plasma cell gingivitis (PCG) is a condition characterized by diffuse and massive infiltration of plasma cells into the subepithelial gingival tissue.^[1,2] Exact etiology of PCG is still not known but according to many authors, due to the presence of plasma cells, it is considered to be an immunological reaction to allergen such as mint candy, herbal toothpastes, red pepper, cinnamon clove, khat leaves, and food flavoring agents.^[2,3] Because of its allergic nature, it is also known as atypical gingivitis, plasma cell gingivostomatitis, allergic gingivostomatitis, and stomatitis venenata.

Clinically, it is characterized by macular lesions that are bright red, velvety, sharply circumscribed, and flat to slightly elevated.^[4] In most cases, these lesions are asymptomatic, but some patients may complain of burning, pain, or pruritus.

Histologically, it is defined by a dense, band-like plasmacytic infiltrate in the upper dermis.^[4] Usually, PCG is not associated with loss of attachment. Here, we present a case of plasma cell gingivitis with loss of attachment and alveolar bone loss, but without any identifiable source of allergy.

CASE REPORT

A 22-year-old female patient reported to the department of oral medicine and radiology with the chief complaint of swelling of gum in maxillary right quadrant for 6 months. According to the history, it was insidious in onset and bleed occasionally on brushing. There was no associated pain and burning. Medical history including drug history was non-contributory.

Extraoral examination was unremarkable. On intraoral examination, there was bright red, elevated lesion in relation to marginal and attached labial gingiva of maxillary right lateral incisor, measuring approximately 5 × 5 mm in size [Figure 1a and b]. It was edematous, soft, and friable in consistency. There was bleeding on probing with exudate through gingival sulcus. The probing depth was found to be 7 mm with no associated mobility of teeth. The probing depth and erythema were disproportionate with

Access this article online



www.ijss-sn.com

Month of Submission : 08-2020
Month of Peer Review : 09-2020
Month of Acceptance : 09-2020
Month of Publishing : 10-2020

Corresponding Author: Dr. Shikha Gupta, Senior Resident, Department of Oral Medicine and Radiology, Maulana Azad Institute of Dental Sciences, New Delhi - 110 002, India.

the amount of local factors present as evidenced by oral hygiene index with total score of 2.1. Based on clinical findings, a provisional diagnosis of periodontal abscess was made with pyogenic granuloma as the differential diagnosis.

The patient was advised routine blood investigations and intraoral periapical radiograph (IOPA) in relation to 12. Results of routine blood investigations revealed lowered hemoglobin levels with increased mean corpuscular volume and mean corpuscular hemoglobin. IOPA radiograph was suggestive of alveolar interdental bone loss [Figure 1c]. The lesion was excised and sent for histopathological examination.

On histopathological examination, sections showed parakeratinized stratified squamous epithelium with moderate hyperplasia overlying a cellular connective tissue stroma. Underlying stromal tissue showed numerous plasma cells with eccentric nuclei having cartwheel pattern of chromatin arrangement [Figure 2a], arranged in sheets and large nests. Numerous budding capillaries surrounded by plump endothelial cells were noted throughout the lesion. Bands of fibrous collagen were seen in between the plasma cells. Immunohistochemistry for kappa and lambda bodies was positive suggesting polyclonal nature of the lesion [Figure 2b and c]. Overall findings were suggestive of plasma cell gingivitis.

Based on histopathology, diagnosis of plasma cell gingivitis was made. To find out the possible allergen, the patient was

enquired about habitual use of chewing gum, mouthwash, and herbal toothpaste but no definite etiology could be found. However, there was recurrence of lesion 10 days after complete excision [Figure 3a and b]. The patient was referred to the department of periodontology for further management. The lesion was completely excised and thorough curettage was done followed by a periodontal pack. Complete healing was evident in 7 days and no recurrence was noted after 1 month of follow-up [Figure 3c and d].

DISCUSSION

Plasma cell gingivitis is a benign inflammatory condition that is uncommon and of unclear etiology. Clinical appearance of PCG is striking; it mostly affects maxillary labial gingiva and presents as fiery red erythematous lesion involving the attached gingiva extending to mucogingival junction.^[5,6] In the present case also, lesion is present on maxillary labial gingiva as bright red lesion. Although the precise cause of it is not known, is thought to be caused because of exposure to an allergen. Diagnosis is formed by selective exclusion through hematological screening, histopathological examination, and identification of allergen.

Gorgillo and Timms *et al.*^[3,7] divided plasma cell gingivitis into three types:

1. Caused by an allergen
2. Neoplastic
3. Unknown origin

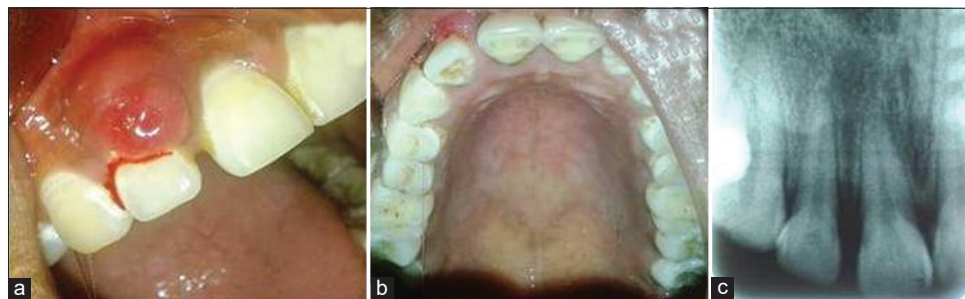


Figure 1: Clinical intraoral photograph of the patient showing well-circumscribed lesion on maxillary labial gingiva i.r.t 12 (a and b) and intraoral periapical radiograph of the patient showing interdental bone loss between 11 and 12 (c)

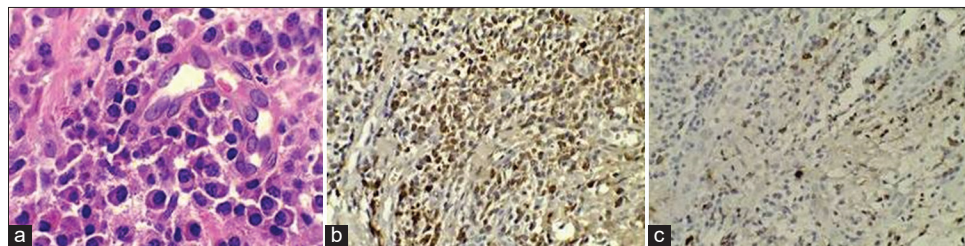


Figure 2: Photomicrograph (x40) showing plasma cells with cartwheel arrangement of chromatin (a), positive immunohistochemical expression of kappa antibody with brown staining plasma cells (b), and positive immunohistochemical expression of lambda antibody with brown staining plasma cells (c)

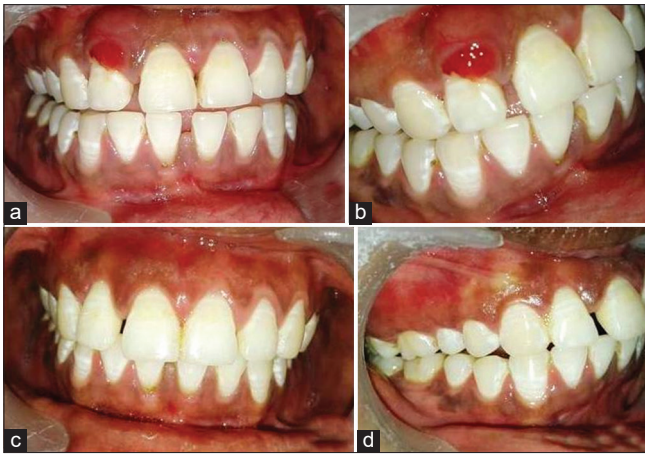

Figure 3: Clinical photograph of the patient with recurrence of lesion 10 days after complete excision (a and b) and follow-up photograph of the patient 1 month after periodontal treatment (c and d)

The present case belongs to type 3 as no known allergen was identified. PCG mimics lesions related to discoid lupus, lichen planus, cicatricial pemphigoid, and leukemia. However, in the present case, the lesion was slightly elevated clinically giving the appearance of periodontal abscess and pyogenic granuloma. Therefore, in addition to clinical and histopathological examination, the diagnosis requires hematological screening.

As already mentioned, from a histopathologic viewpoint, the intensely inflammatory infiltrate in the dermis and dermoepidermal border with infiltrate consisting mainly of plasma cells is considered characteristic of this lesion. Plasma cells are identified by eccentric nuclei with a cartwheel appearance.^[8] However, the histopathological changes with predominance of plasma cells mimic conditions such as multiple myeloma, plasmacytoma, and plasma cell granuloma. Hence, to rule out plasmacytoma, immunohistochemistry with kappa and lambda antibody is often diagnostic.^[9] In the present case, there was positivity for both kappa and lambda antibody, thereby eliminating plasmacytoma.

Since PCG is a benign lesion, for complete remission of the condition, it is essential to detect and eliminate any exposure to the etiologic agent.^[2] The patient must, therefore, be advised to record complete dietary history, including food, dentifrice, mouthwash, alcohol, chewing gum, candy, and medication.

In this case, the patient's thorough history was taken but no possible allergen was identified. All the relevant hematological investigations were performed to rule out other probable lesions. Comprehensive history taking, clinical examination, and appropriate diagnostic tests form the key to diagnosis of PCG. Histopathological examination forms the basis for differentiating plasma cell gingivitis from other mimicking lesions. Hence, the present case highlights the importance of comprehensive history to arrive at a definitive diagnosis as well as appropriate management of lesions which are refractory to conventional therapy alone.

REFERENCES

1. Kandwal A, Jindal R. Plasma cell gingivitis associated with inflammatory cheilitis: A report on a rare case. *Ethiop J Health Sci* 2013;23:183-7.
2. Makkar A, Tewari S, Kishor K, Kataria S. An unusual clinical presentation of plasma cell gingivitis related to "Acacia" containing herbal toothpaste. *J Indian Soc Periodontol* 2013;17:527-30.
3. Marker P, Kroghdal A. Plasma cell gingivitis apparently related to the use of khat: Report of a case. *Br Dent J* 2002;192:311-3.
4. Curto CR, Chaves MY, Moran AG, Asensio PG, Lopez G. Plasma cell gingivitis. *Cutis* 2002;69:41-5.
5. Agarwal S, Ajmera N, Chatterjee A, Hemlata M. An unusual plasma cell gingivitis case related to use of herbal toothpowder. *Clin Adv Periodontics* 2012;2:107-12.
6. Palmer RM, Eveson JW. Plasma-cell gingivitis. *Oral Surg Oral Med Oral Pathol* 1981;51:187-9.
7. Elavarasu S, Thangakumaran S, Karthik SJ, Arthie T. Plasma cell gingivitis of unknown origin. *J Indian Acad Dent Spec* 2010;1:34-8.
8. Vaidya P, Gupta U. Plasma cell gingivitis-a case report. *Indian J Dent Sci* 2010;2:23-5.
9. Newcomb GM, Seymour GJ, Adkins SF. An unusual form of chronic gingivitis: An ultrastructural, histochemical and immunological investigation. *Oral Surg Oral Med Oral Pathol* 1982;53:488-95.

How to cite this article: Gupta S, Kumar P, Tandon S, Gupta S. Localized Lesion of Plasma Cell Gingivitis Mimicking Pyogenic Granuloma: A Case Report. *Int J Sci Stud* 2020;8(7):1-3.

Source of Support: Nil, **Conflicts of Interest:** None declared.