

A Multidisciplinary Outlook in Prosthodontics

V Chakradhar¹, B Lakshmana Rao², Satyanarayana S V Tammineedi³, Y S S Sruthi¹, P S H L Parvathi¹

¹Postgraduate Student, Department of Prosthodontics, Lenora Institute of Dental Sciences, Rajahmundry, Andhra Pradesh, India, ²Professor and Head, Department of Prosthodontics, Lenora Institute of Dental Sciences, Rajahmundry, Andhra Pradesh, India, ³Reader, Department of Prosthodontics, Lenora Institute of Dental Sciences, Rajahmundry, Andhra Pradesh, India

Abstract

Prosthodontic research needs to cover all aspects that can contribute to the clinical outcomes. Without a strong interdisciplinary relationship between other disciplines of dentistry and prosthodontics, the esthetic, functional, and/or biological outcome may be compromised and necessitate extensive and expensive retreatment. Through this paper, we would like to review the outline of the areas that overlap between prosthodontics and other branches of modern dentistry that dictates the interdisciplinary treatment.

Key words: Multidisciplinary prosthodontics, Oral radiology, Oral surgery, Orthodontics, Pedodontics, Periodontics

INTRODUCTION

“Multidisciplinarity” signifies the juxtaposition of disciplines. Interdisciplinary research has been gaining prominence across all domains of science, engineering, and social sciences. In the contemporary advanced period of dentistry, there is a need for the multidisciplinary approach to achieve biologically acceptable, esthetic, functional, and patient satisfactory treatment outcomes. For a patient overall rehabilitation process, there is a need of involving various specialties either for removing the pathologically active tissues or modifying the anatomically defective sites before the start of the prosthetic part of treatment.^[1]

Prosthodontics is a branch of modern dentistry that deals mainly to restore the lost form, function, and the esthetics of the patients. Rehabilitation of the orofacial defects in accordance with the surrounding anatomical, physiological, and biological tissues requires the intervention of various disciplines starting from the diagnosis to better treatment outcomes such as oral radiology, periodontics, endodontics, orthodontics, and pedodontics. This article aims to outline the areas of overlap between prosthodontics and

other branches of modern dentistry that dictates the interdisciplinary treatment.

WHAT'S MULTIDISCIPLINARY APPROACH?

Multidisciplinary dentistry refers to dental treatment that uses more than 1 type of dental strategy. This type of multilevel care occurs where there are various complex steps in treatment planning. The key is to build a team of likeminded, dedicated professionals who share a common goal of providing ideal oral health care to patients [Figure 1].

BENEFITS

For Clinician [Figure 2]

Improved patient care and outcome through the development of an agreed treatment plan, improved coordination of care, streamlined treatment pathways, and reduction in duplication of services.

For Patient

Gets the most appropriate treatment decision made by a team of experts and improved satisfaction with treatment and care.

ORAL RADIOLOGY

In the era of modern medicine and dentistry, the diagnostic pathway leads to the treatment planning phase

Access this article online



www.ijss-sn.com

Month of Submission : 06-2020
Month of Peer Review : 06-2020
Month of Acceptance : 07-2020
Month of Publishing : 07-2020

Corresponding Author: Dr. V Chakradhar, Department of Prosthodontics, Lenora Institute of Dental Sciences, Rajahmundry - 533 294, Andhra Pradesh, India.

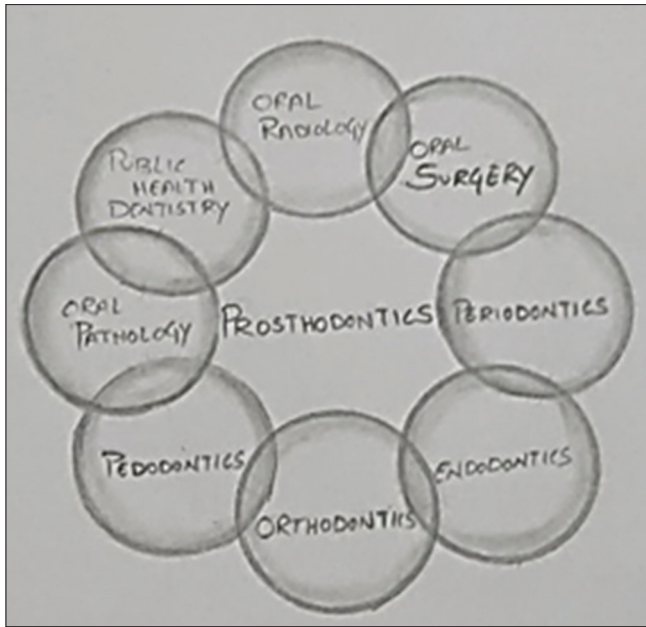

Figure 1: Multidisciplinary prosthodontics

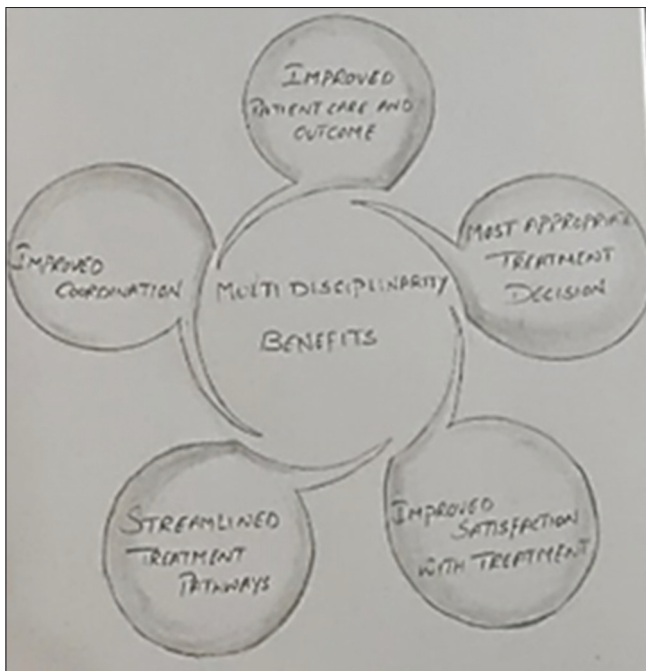

Figure 2: Multidisciplinary prosthodontics benefit

and successful outcomes. Oral radiology is vital for the assessment of structures such as jaws, jaw relationships, denture foundation, the position of anatomical landmarks, bone height-width, tooth condition, and their position in the arch. Radiology is of two types, intraoral radiography and extraoral radiography.

Intraoral Radiography

It includes periapical, bitewing, and occlusal projections.

The intraoral radiology has a limited role in defining:^[1]

1. Abnormalities in the oral structures
2. Examining the tuberosities
3. Evaluating the submucosal conditions under denture bearing areas
4. Evaluating the periodontium and bone level at the abutment and pontic levels in fixed partial dentures (FPDs).
5. Pre-operative, operative, and post-operative imaging for implant therapy helps in the accurate positioning of the implants.
6. Post-operative imaging after 3–5 years and beyond can be used to assess the bone-implant interface and
7. Marginal peri-implant bone height.

Extraoral Radiography

These extraoral radiographs in complete denture can provide a survey of the patient's denture foundation and surrounding structures and evaluate the status of impacted teeth, trauma, and temporomandibular (TM) joint area.^[2]

Panoramic Radiography

It is evaluated for the presence of retained root fragments, impacted teeth, radiolucency's, radiopacities and foreign bodies, location of mental foramina at or near the crest of the residual alveolar ridge, and maxillary sinus proximity to the crest of the residual alveolar ridge on a single film.^[3]

Computed Tomography

It has become popular in implant and TM joint diagnosis at an acceptable radiation dose risk.^[4] Cone-beam computed tomography provides cross-sectional images of the alveolar bone height, width, and angulations and accurately depicts vital structures such as the inferior alveolar dental nerve canal in the mandible or the sinus in the maxilla and also a reliable tool in ridge mapping technique.

Magnetic Resonance Imaging (MRI)

MRI techniques are currently being used in dentistry for diagnosis of TM joint diseases and inflammatory conditions of the facial skeleton.^[5]

Specialized radiographic techniques arthrography of the TM joint is basically a method that will supply information on soft-tissue state of the TM joint.^[2] In addition, radiotherapy protective devices/stents can be fabricated and used to shield/position tissues or to assist in the efficient administration of the radiation to a specific structure, thus reducing the post-operative morbidity of tissues.

Al Faleh *et al.* highlighted the necessity of routine radiographic examination of the jaws for all edentulous patients before constructing complete dentures.^[1]

Jamil *et al.* reviewed on the different radiographic techniques used in the prosthodontics and concluded that there is crucial role of radiographs in prosthodontics and in their successful treatment outcomes.^[5]

Thus, the different oral radiology techniques provide valuable information to the prosthodontist about the comprehensive oral scenario and play as a deciding factor in the treatment planning.

PERIODONTICS

The periodontium is a complex structure that consists of the periodontal ligament, gingiva, cementum, and alveolar bone.^[6] Of all disciplines within modern dentistry, periodontics and prosthodontics have the strongest and the most intimate connections.^[7]

The principal purpose of the periodontal aspect is to create a sound foundation where the final prosthesis is placed.

Its objectives are as follows:^[8,9]

- Removal of local and environmental etiologic factors (preventive periodontal procedure like scaling)
- Plaque control and oral hygiene maintenance during the course of therapy
- Removal of pockets
- Restoring osseous and gingival contours (treatment of recession by grafting procedures)
- Removal of furcal invasions by combined periodontal, endodontic, and prosthetic procedures.
- Cosmetic gingival procedures (like gingivectomy/crown lengthening)
- Periodic recall and maintenance program.

The prosthodontic-perio relation starts from the impression phase of the treatment:^[10]

The use of retraction cord yields minimal gingival recession and also sulcular tissue preservation. If it is used with negligence in areas of insufficient attached gingiva or gingival fiber, injury occurs which leads to inaccurate impressions and impression material infuse into the gingival connective tissue and bone which, in turn, foreign body reaction.

The Provisional Restoration

In-accurate interim restorations with poor adaptation at the margins being under or over contoured with porous or rough surfaces result in inflammation, overgrowth, or recession of gingival tissues.

Marginal Fit

There should ideally be no gap at the interface for a restored tooth. Studies suggested that the 50 μ m gap is clinically acceptable.

The Contour of the Crown

Properly designed contours provide hygienic access, have the completeness to create the desired gingival shape and a pleasant visual tooth contour in esthetic areas.^[10]

Smoothness of the Contacts and Contours

The fineness of the restorative margins and in the contacts and contours and on the gingival portion of the restoration is critical, porous or rough surface, over or under contoured restoration leads to gingival irritation, inflammation, and overgrowth, which progress toward bone loss and finally failure of the prosthesis.

Biologic Width and Margin Placement

Biological width (BW) has a tendency of self-restoration and adapts dynamically.^[11] The conservation of periodontal health is dependent on the biologic width. The violation of BW has been widely discussed as a contributing factor that jeopardizes periodontal health.

The result of BW breach includes attachment loss, pain, gingival inflammation, localized gingival hyperplasia, pocket formation, and loss of periodontal structure finally early implant bone loss.^[12]

BW and Implants

BW is very important in implant success. During the initial phase of implant healing, peri-implant bone remodeling is from the process of BW reformation to allow a stable soft-tissue barrier. In addition, the locations of microgaps and smooth/rough surface interfaces may be associated with the length of peri-implant BW. Platform switching is using abutments with a reduced diameter than the drilled implant diameter which limits the crestal resorption by maintaining the BW and preserving the interdental papilla.

According to Berglundh *et al.*, the strategies to prevent early implant-bone resorption were control of biologic width and microgap.^[13]

As per Hsu *et al.*, robust supporting periodontal/peri-implant tissues, proper contacts, and occlusal scheme provide solid foundations for predictable prosthetic therapy.^[7]

ORTHODONTICS

Orthodontics is a clinical branch of dentistry that will correct poor alignment, positioning of teeth, jaws, and face structure.^[14] Pre-prosthetic orthodontics is necessary for some clinical scenarios mainly such as correction of anterior deep vertical overlap, orthodontics treatment with multiple missing teeth, tilted teeth, intrusion/extrusion of teeth, retainers/night guards, and space maintainers/regainers.^[15]

Excessive Vertical Overbite

It can be treated either intrusion of anterior teeth, extrusion of posterior teeth, or a combination of both. A segmented intrusion of the anterior teeth is preferable in adult patients.^[16]

Uprighting of Tilted Molars

Uprighting is necessary in directing the forces long axis to the tooth. A slight modification of tooth reduction will be sufficient when preparing the tooth for a FPD and use of a locked attachment or telescopic crown.^[17]

Orthodontics Extrusion for Crown Lengthening Purpose

The advantages of orthodontic extrusion over surgical crown lengthening are – orthodontic extrusion provides a more favorable crown to root ratio, eliminates the risk of compromising the alveolar bone support of the adjacent teeth, and will not compromise the esthetic of the tooth that requires crown lengthening.^[18]

Becker *et al.* stated that alignment of the tilted tooth through orthodontic treatment has the advantage of the elimination of the intrabony defect on the mesial side of the tilted tooth, simplify the preparation of the tilted abutment tooth to receive a FPD, aid in aligning the occlusal plane, and aid in the transmission of occlusal forces through the long axes of the tooth.^[19] Alfallaz felt that the importance of diagnostic wax-up is a critical tool in nearly all situations to visualize and assess the treatment outcomes. Thus, orthodontics has a profound influence on the prosthodontic treatment planning.

ENDODONTICS

Endodontics is the branch of dentistry related to dental pulp and tissues surrounding the roots of a tooth. Endodontists has paid a great foundation for the creation and maintenance of successful prostheses.^[20] The effect of endodontics is predominant on the overdenture and fixed type prostheses before the prosthesis fabrication on the teeth.^[21]

In Fixed Prosthodontics

The amount of suprabony tooth structure is the most critical factor determining the restorative prognosis for a tooth and superstructure. Studies suggested that endodontically treated teeth are somehow more “brittle” than vital teeth.^[22] The band of extracoronal material (usually metal or metal-ceramic) that encircles this tooth structure is termed as the ferrule and is usually provided by the crown, is very important in preventing the vertical fracture of the tooth.

In Tooth-supported Overdenture

Providing good apical seal and preserving the tooth are the key factors for the success.

Lakshmi *et al.*, from their study, concluded that for the endodontically treated tooth that requires a post, the minimum length of the solid tooth remaining would be the – biologic width (2.5 mm) + ferrule length (2 mm) + apical seal (4 mm) + post length (equal to crown length), (i.e., 8.5 mm + post length beyond crown margin). For those teeth not requiring a post, the requirements are for biologic width + ferrule length (i.e., 4.5 mm of the suprabony solid tooth; this assumes adequate bone support to provide a clinically acceptable level of mobility).^[21] Barkhordar *et al.*^[23] in 1989 compared restored teeth that were prepared with and without a ferrule and showed that the ferrule reduced vertical root fracture by one-third.

ORAL SURGERY

It is a branch of dentistry dealing with the surgical treatment or repair of any problematic or pathological condition of the mouth or jaws. The main aim of the pre-prosthetic surgeries is to provide an ideal denture bearing area or the foundation area on/in which the prosthesis gains retention, stability, and harmony with the surrounding structures. The pre-prosthetic surgeries are done under the reference/consultation of the prosthodontist.

There are two main categories of pre-prosthetic surgery procedure [Figure 3]:

1. Soft-tissue procedures
2. Hard tissue procedures.

Soft-tissue Procedures

It includes – excision of the hyperplastic ridge, prominent labial frenum, epulis fissuratum papillary hyperplasia, and mental nerve repositioning.

Hard Tissue Procedures

It includes – alveoplasty, maxillary tuberosity reduction, mylohyoid ridge reduction, excision of a maxillary or mandibular torus, reduction of genial tubercles, ridge extension procedures restoration of grossly deficient denture bearing areas (bone grafting).^[24]

PEDODONTICS [FIGURE 4]

In the cases such as cleft lip and palate conditions, the multidisciplinary approach by a surgeon, orthodontist, speech therapist, pedodontist, and prosthodontist is very crucial. Providing of feeding bulb apparatus and the obturators that help in the suckling without gagging or struggling is the duty of the prosthodontist in many techniques including the pre-surgical nasoalveolar molding (PNAM). PNAM is an evolving technique which acts as a form of custom tissue expansion while correcting the

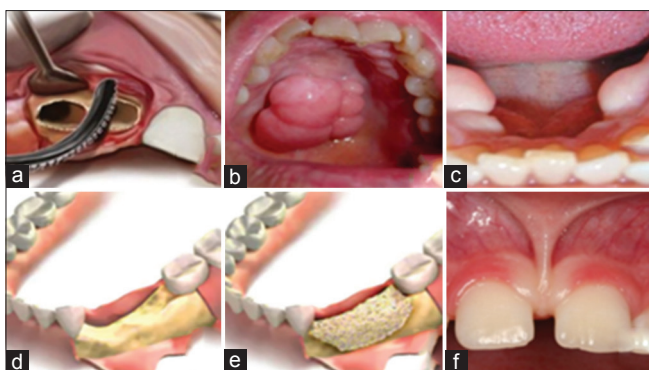


Figure 3: (a) Alveoplasty, (b) palatal exostosis, (c) mandibular tori, (d and e) ridge augmentation, (f) high frenal attachment

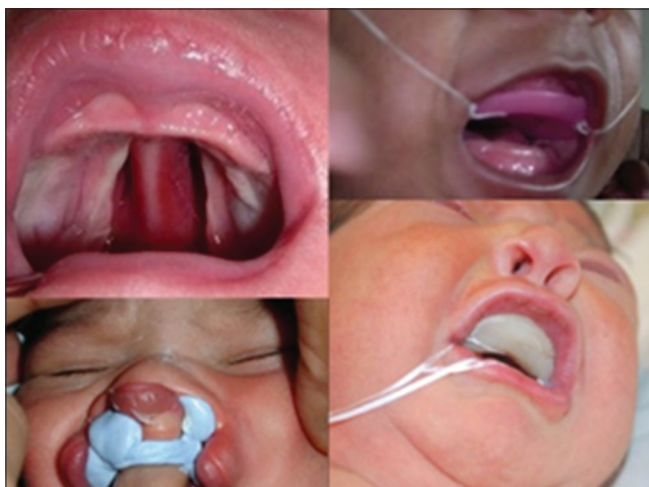

Figure 4: Prosthetic management of cleft conditions

nasal deformity non-surgically and addressing the shortness of columellar length deficiency and alveolar segment malposition with minimal surgery. Frequent surgical intervention to achieve the desired esthetic results can be avoided by PNAM.^[25]

PUBLIC HEALTH DENTISTRY

Community dentistry helps in doing the survey among the population and analyzes the results and to draw the conclusion on the knowledge, awareness of the population toward prosthetic treatment, percentage of edentulism, and the prevalence of edentulous sites pertaining to the classification systems, and the age group commonly effected by edentulism, the percentage satisfaction of the patient's toward prosthetic treatment, etc.

ORAL PATHOLOGY

Pathology has an indirect relation to the prosthodontics in analyzing the quality of the saliva, determining the oral

lesions, biopsies, and in obtaining the complete blood picture regarding the systemic condition of the patient.

CONCLUSION

- By working collaboratively, we can hope to answer questions never addressed before, including those with substantial influence on society. Clinical and research aspects of prosthodontics have become more multidisciplinary.
- Therefore, prosthodontists need to understand various technical procedures as well as the underlying physiological, anatomical, and biological principles.

REFERENCES

1. Al-Faleh W, Mansour S, Ibrahim ME. The value of pre-operative radiographic examination of edentulous patients prior to denture construction: The risk versus the benefit. *Egypt Dent J* 2005;51:1853-7.
2. Karjodkar FR. *Textbook of Dental and Maxillofacial Radiology*. 2nd ed. New Delhi: Jaypee Brothers Medical Publishers; 2009.
3. Venkata CI, Krishnan MD. Survey of panoramic radiographic examination of edentulous jaws prior to denture construction. *IOSR J Dent Med Sci* 2013;5:11-7.
4. Tyndall DA, Price JB, Tetradis S, Ganz SD, Hildebolt C, Scarfe WC, et al. Position statement of the American academy of oral and maxillofacial radiology on selection criteria for the use of radiology in dental implantology with emphasis on cone beam computed tomography. *Oral Surg Oral Med Oral Pathol Oral Radiol* 2012;113:817-26.
5. Jamil I, Mahajan T, Solanki S, Kapoor A, Roy CK. Radiographs in prosthodontics-a review. *Rama Univ J Dent Sci* 2017;4:20-2.
6. Abduo J, Lyons KM. Interdisciplinary interface between fixed prosthodontics and periodontics. *Periodontol* 2000 2017;74:40-62.
7. Hsu YT, Huang NC, Wang HL. Relationship between periodontics and prosthodontics: The two-way street. *J Prosthodont Implantol* 2015;4:4-11.
8. Meyers HE, Baraff LS. A restorative approach to periodontally treated mouth. *Dent Clin North Am* 1965;9:13.
9. Rosenberg MM. Management of osseous defects, furcation involvement and periodontal pulpal lesions. In: Clark JW, editor. *Clinical Dentistry*. Vol. 3, Ch. 10. Hagerstown, MD: Harper and Row; 1979.
10. Nithisha B, Kumar CR, Rao DC, Sujesh M, Sreenivasulu D. An insight into the periodontal restorative interrelationship. *Indian J Dent Adv* 2018;10:41-6.
11. Gargiulo AW, Wentz FM, Orban B. Dimensions and relations of the dentogingival junction in humans. *J Periodontol* 1961;32:261-7.
12. Tal H, Soldinger M, Dreiangel A, Pitaru S. Periodontal response to long-term abuse of the gingival attachment by supracrestal amalgam restorations. *J Clin Periodontol* 1989;16:654-9.
13. Berglundh T, Lindhe J. Dimension of the periimplant mucosa. Biological width revisited. *J Clin Periodontol* 1996;23:971-3.
14. Shrivastava N. Interdisciplinary orthodontics: A review. *IOSR J Dent Med Sci* 2018;17:34-40.
15. Teresa P, Manuel N, Celia A. Multidisciplinary management including periodontics, orthodontics, implants, and prosthetics for an adult. *Am J Orthod Dentofacial Orthop* 2012;142:235-45.
16. Dahl BL, Krogstad O, Karlsen K. An alternative treatment in cases with advanced localized attrition. *J Oral Rehabil* 1975;2:209-14.
17. Torbjørner A, Fransson B. Biomechanical aspects of prosthetic treatment of structurally compromised teeth. *Int J Prosthodont* 2004;17:135-41.
18. Potashnick SR, Rosenberg ES. Forced eruption: Principles in periodontics and restorative dentistry. *J Prosthet Dent* 1982;48:141-8.
19. Becker A, Zalkind M, Stern N. The tilted posterior tooth. Part II: Biomechanical therapy. *J Prosthet Dent* 1982;48:149-55.
20. Goodacre CJ, Spolnik KJ. The prosthodontic management of endodontically

- treated teeth: A literature review. Part II. Maintaining the apical seal. J Prosthodont 1995;4:51-3.
21. Lakshmi S, Krishna VG, Sivagami S. Prosthodontic considerations of endodontically managed teeth. J Conserv Dent 2006;9:104-9.
 22. Ray HA, Trope M. Periapical status of endodontically treated teeth in relation to the technical quality of the root filling and the coronal restoration. Int Endod J 1995;28:12-8.
 23. Barkhordar RA, Radke R, Abbasi J. Effect of metal collars on resistance of endodontically treated teeth to root fracture. J Prosthet Dent 1989;61:676-8.
 24. Chari H, Shaik KV. Preprosthetic surgery: Review of literature. IJSS 2016;3:10.
 25. Kamble VD, Parkhedkar RD, Sarin SP, Patil PG, Kothari B. Simplifying cleft surgery by presurgical nasoalveolar molding (PNAM) for infant born with unilateral cleft lip, alveolus, and palate: A clinical report. J Prosthodont Res 2013;57:224-31.

How to cite this article: Chakradhar V, Rao BL, Tammineedi SS, Sruthi YS, Parvathi PS. A Multidisciplinary Outlook in Prosthodontics. Int J Sci Stud 2020;8(4):9-14.

Source of Support: Nil, **Conflicts of Interest:** None declared.