Print ISSN: 2321-6379
Online ISSN: 2321-595X

Case Report

Multiple Myeloma Presenting as a Maxillary Gingival Mass in Elderly Female

Khushboo Singh[1], Sunita Gupta[2], Shikha Gupta[3], Sujoy Ghosh[4], Aadithya B Urs[5], Prerna Arora[6], Sunita Aggarwal[7], Anjali Prakash[8], Ridam Sharma[9]

[1]Senior Research Associate, Department of Oral Medicine and Radiology, Maulana Azad Institute of Dental Sciences, New Delhi, India, [2]Director-Professor and Head, Department of Oral Medicine and Radiology, Maulana Azad Institute of Dental Sciences, New Delhi, India, [3]Senior Resident, Department of Oral Medicine and Radiology, Maulana Azad Institute of Dental Sciences, New Delhi, India, [4]Associate Professor, Department of Oral Medicine and Radiology, Maulana Azad Institute of Dental Sciences, New Delhi, India, [5]Professor and Head, Department of Oral Pathology and Microbiology, Maulana Azad Institute of Dental Sciences, New Delhi, India, [6]Associate Professor, Department of Pathology, Maulana Azad Institute of Dental Sciences, New Delhi, India, [7]Director Professor, Department of Medicine, MAMC and Lok Nayak Hospital, New Delhi, India, [8]Director Professor, Department of Radiodiagnosis, MAMC and Lok Nayak Hospital, New Delhi, India, [9]Postgraduate Student, Department of Oral Medicine and Radiology, Maulana Azad Institute of Dental Sciences, New Delhi, India

Abstract

We report a case of multiple myeloma in elderly female, wherein diagnosis was arrived at after careful history taking and examination with series of investigations. This case is of significance since oral manifestations are uncommon as first manifestation of the disease and even rarer to occur in maxilla.

Key words: Bence Jones protein, Jaw, Myeloma, Oral

INTRODUCTION

Multiple myeloma (MM) is a malignant, multifocal malignancy of plasma cell origin which comprises 1% of all malignancies and 10–15% of hematologic malignancies.[1-3] It is characterized by abnormal clonal proliferation of plasma cells in bone marrow. It occurs between the 4th and 7th decades of life and is more seen in males as compared to females.[3] The clinical manifestations commonly seen are bone pain, anemia, fatigue, and affected areas involve skull, spine, pelvis, vertebrae, and hip.[4,5] Maxillofacial lesions are although not rare but are seldom seen as primary manifestation or early sign of disease. These lesions are seen in posterior segments of jaw being more common in mandible than maxilla. Patients with maxillofacial lesions present as ulceration, unhealed socket, paresthesia, tooth mobility, or gingival bleeding.

Access this article online

www.ijss-sn.com

Month of Submission : 11-2020
Month of Peer Review : 11-2020
Month of Acceptance : 12-2020
Month of Publishing : 01-2021

Here, we present a case of MM in a 60-year-old female with oral manifestations as the primary manifestation of the disease and affecting maxilla which is a rare site of involvement. Through this case report, we would like to highlight the role of careful history taking, examination, and sequential investigations, leading up to timely diagnosis and management.

CASE REPORT

A 60-year-old female reported to the Department of Oral Medicine and Radiology with chief complaint of swelling in the right upper back tooth region for the past 2 months. She also complained of difficulty in swallowing and feeling of heaviness over the upper lip and right side of face. On eliciting history, the patient told that she had mobility of teeth in upper right quadrant posteriorly and underwent sequential extraction 5 months back of tooth no. 14, 15, 16, and 17. The patient started noticing a swelling at the extraction site for the past 2 months which was initially of a size of pea and progressed to the present size accompanied with pain in the region. The pain was dull, constant, localized in nature and was relived on taking anti-inflammatory drugs.

Medical history was positive for Type 2 diabetes mellitus for which she was on medications and active tuberculosis

Corresponding Author: Dr. Shikha Gupta, Department of Oral Medicine and Radiology, Maulana Azad Institute of Dental Sciences, New Delhi, India.

for which she was on antitubercular treatment for the past 4 months. No other family member was having any positive history. Personal history revealed the habit of paan chewing 2–3 times a day for 2 years and she had quit the habit 1 year back. General physical examination revealed an otherwise healthy female with moderate built, normal gait.

Extraoral examination showed no evidence of swelling; however, tenderness was present on palpation in the right zygomaticomaxillary region with overlying skin being normal in color, texture, and temperature. The right submandibular lymph node was palpable, 1 × 1 cm in size, firm in consistency, mobile, and tender on palpation. Intraorally, a soft-tissue growth of size 4 × 5 cm was present which was anteroposteriorly extending form distal end of 13 to the right maxillary tuberosity region and laterally obliterating the right maxillary buccal vestibule to medially approximately 0.5 cm away from midline of palate [Figure 1a]. It was soft to firm in consistency, sessile, non-pulsatile, slightly compressible, and ulcerated overlying mucosal surface with yellowish-white pseudomembranous slough due to impingement of opposing attrited tooth 46 [Figure 1b]. In the same region, teeth missing were 14, 15, 16, and 17 with Grade II mobility of 13 and an ill-fitting fixed prosthesis in relation to 12, 11, 21, and 22. Ill-fitting prosthesis was removed and tooth 13 was extracted. Subsequently, our differential diagnosis comprised secondary tuberculosis of oral cavity, malignant ameloblastoma, maxillary sinus malignancy, intraosseous carcinoma, osteosarcoma, and metastatic tumor. As the patient was on anti-tubercular therapy, hence, secondary tuberculosis involving oral cavity was considered as the first differential diagnosis.

A series of investigations were undertaken to arrive at a definite diagnosis keeping the above differential diagnosis in mind.

1) Maxillary occlusal view: It showed an ill-defined radiolucency involving the right hard palate not crossing the midline with severe bone loss mesial and distal to 13 [Figure 2a]. The panoramic radiograph revealed ill-defined radiolucency in the right maxillary region in relation to 13, 14, and 15 extending upward in maxillary sinus region [Figure 2b].
2) Contrast-enhanced computerized tomography (CECT): Spiral axial scans of the maxilla-mandibular region were obtained on multidetector computed tomography scanner followed by multiplanar reformats. It revealed the evidence of heterogeneously enhancing soft-tissue mass lesion of 5 × 5 × 4.5 cm in size involving the right hard palate and alveolar process of maxilla with bony destruction. The lesion was seen to extend into the right maxillary sinus, nasal cavity, superiorly the lesion was causing erosion of floor of the right orbit abutting the right inferior rectus muscle, infratemporal fossae causing thinning of pterygoid plates [Figures 2c-e]. Few subcentimetric bilateral level Ib, II lymph nodes were seen. Considering a short duration of history, maxillary location, soft consistency, numbness in same region, and destructive osteolytic lesion on radiographs suggested malignant neoplasm of different origin.
3) Hematological examination: Hemoglobin – 10.2 g/dl, total leukocyte count – 8700 mm^{-3}, differential leukocyte count – (neutrophils: 55.9%, lymphocytes: 33.3%, monocytes: 8.3%, and eosinophils: 2.4%), platelet count – 327,000 mm^{-3}, erythrocyte sedimentation rate – 40 mm/h.
4) Incisional biopsy of oral lesion: An incisional biopsy was performed and a 1.2 × 0.6 × 1 cm mass was incised from intraoral lesion under local anesthesia and was sent for histopathological examination. Lesional tissue revealed sheets of closely packed abundant mature plasma cells with few immature large cells. These cells showed round, ovoid, and angulated appearance of nuclei with the presence of chromatin clumping in a checkerboard and cartwheel pattern. The connective tissue stroma surrounding lesional tissue was loosely textured to collagenous in nature. The overall features were suggestive of plasmacytoma [Figures 3a and b]. Immunohistochemistry showed immunoreactivity for light chain lambda tumor marker suggestive of monoclonality [Figures 3c and d].
5) Bone marrow aspiration: Bone marrow aspirate and imprint smears were diluted with peripheral blood, occasional cellular marrow fragments entrapped in blood clot were seen. Myeloid-to-erythroid ratio was 3.5:1. Erythroid reaction was normoblastic with occasional micronormoblasts. Myeloid maturation series revealed mild increase in eosinophilic precursors as 8%. Megakaryocytes were adequate and functional. Plasma cells constituted 8% of marrow nucleated cells [Figures 4a-d]. Overall impression was suggestive of plasmacytoma.

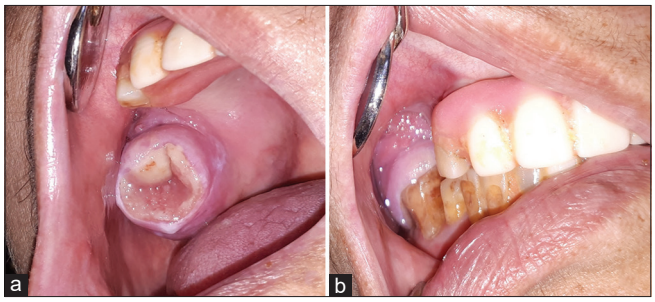

Figure 1: (a) Intraoral photograph showing soft-tissue growth of size 4 × 5 cm extending form distal end of 13 to the right maxillary tuberosity region, (b) intraoral photograph showing opposing tooth 46 impinging on the occlusal surface of the soft-tissue growth in maxillary region

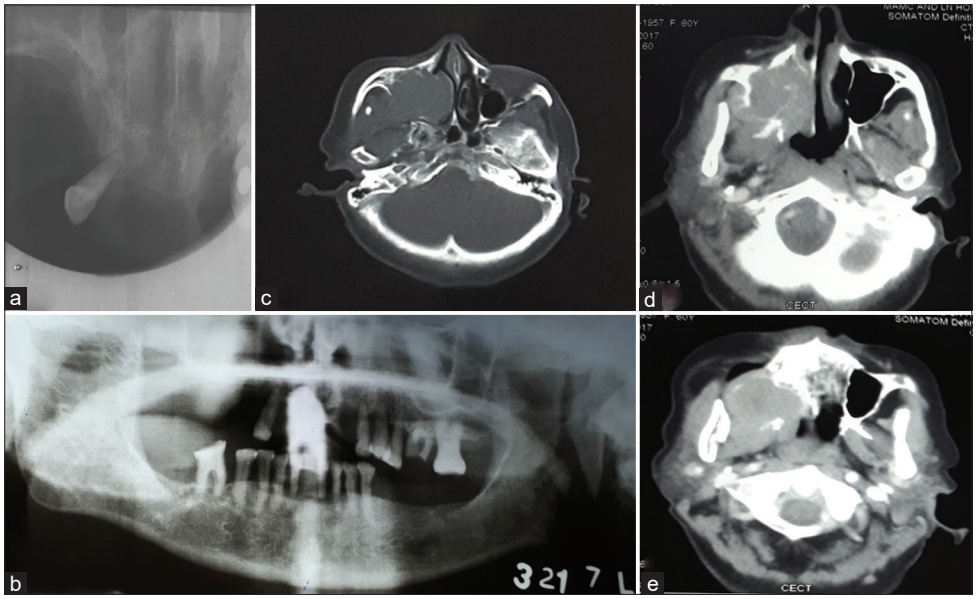

Figure 2: (a) Maxillary occlusal radiograph showing ill-defined radiolucency with soft-tissue density involving the right hard palate with severe bone loss mesial and distal to 13, (b) panoramic radiograph showing ill-defined radiolucency in the right maxillary region extending upwards in maxillary sinus region, (c-e) axial contrast-enhanced computerized tomography sections showing heterogeneously enhancing soft-tissue mass lesion of 5 × 5 × 4.5 cm involving right hard palate and alveolar process of maxilla extending into the right maxillary sinus, nasal cavity, and infratemporal fossae causing thinning of pterygoid plates

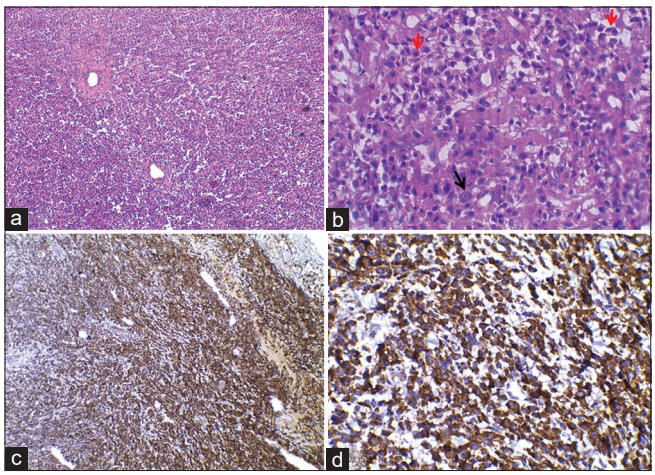

Figure 3: (a) Histological microphotograph (at 200×) of oral lesion showing sheets of closely packed abundant plasma cells, (b) histological microphotograph (at 400×) of oral lesion showing mature plasma cells (shown by red arrows) and immature plasma cell (shown by black arrow), (c and d) immunohistochemical microphotograph (at 200× and 400×) of oral lesion showing immunoreactivity for light chain lambda tumor marker

6) Bone marrow biopsy: H and E stained bone marrow biopsy showed many bony trabeculae with intratrabecular spaces enclosing hypocellular marrow. It revealed hematopoietic cells of all lineages with focal interstitial and mild increase in plasma cells which were <10% [Figure 5a]. Erythroid series showed normoblastic erythroid reaction. Myeloid series showed normal maturation with mild increase in eosinophils. Megakaryocytes were seen and adequate in number. There were CD38 positive plasma cells on immunohistochemical staining [Figure 5b].
7) Skeletal survey: Anteroposterior (AP) and lateral skull radiograph showed multiple, well-defined punched out lytic lesions in bony calvaria [Figure 6a]. Posteroanterior (PA) chest radiograph showed a lytic lesion in medial end of the right clavicle and fibrotic opacities in bilateral upper zone of lungs [Figure 6b]. Lateral radiographic view of cervical spine revealed straightening of cervical spine with marginal osteophytes at multiple levels [Figure 6c]. AP and lateral radiographic views of dorsolumbar and lumbosacral spine showed diffuse osteopenia [Figures 5e and 6d]. Radiograph of bilateral hip and pelvis was normal. CECT chest revealed well-defined soft-tissue lesion in the left upper lobe with few nodules having irregular margins in the right upper lobe, left upper, and lower lobe [Figure 6f], a lytic lesion with associated soft tissue in the right 4th rib and spinous process of D2 vertebra with epidural extension [Figure 6g].
8) Serological and immunological examination: Serum electrophoresis was negative for M spike. Urinary Bence Jones proteins were negative. Liver function and kidney function tests were within normal limits. Serum β_2 microglobulin level was 3524 ng/ml which was significantly raised (normal limit: 609–2366 ng/ml). Serum kappa free light chain and lambda free light chain were significantly increased, that is, 30.60 mg/l (normal limit: 3.30–19.40 mg/l) and 995 mg/l (normal limit: 5.71–26.30 mg/l), respectively.

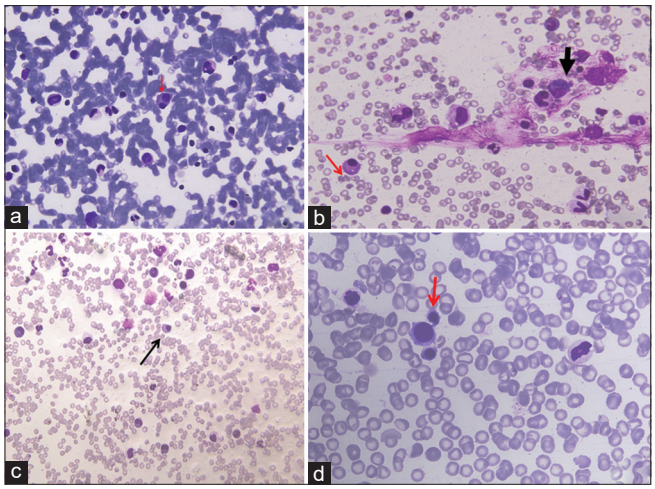

Figure 4: (a) Histological microphotograph (at 400×) of bone marrow aspirate showing binucleated plasma cell (shown by an arrow), (b) histological microphotograph (at 400×) of bone marrow aspirate showing plasma cell (shown by an arrow), (c) histological microphotograph (at 600×) of bone marrow aspirate showing plasma cell (shown by red arrow) and eosinophilic precursor (shown by black arrow), (d) histological microphotograph of bone marrow aspirate showing macronormoblastic erythroid precursor (shown by an arrow)

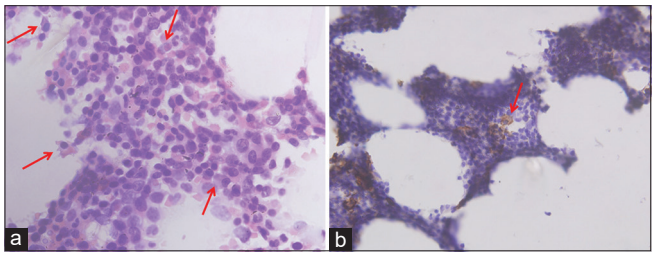

Figure 5: (a) Histological microphotograph (at 400×) of bone marrow biopsy showing plasma cells (shown by arrows), (b) microphotograph (at 400×) of bone marrow biopsy showing immunohistochemical expression of CD 38-positive plasma cells (shown by an arrow)

Based on all investigations and criteria for diagnosis of plasma cell disorders, a final diagnosis of MM was made. The uniqueness of the present case highlights that how a maxillary swelling with no other systemic symptoms turned out to be MM on subjecting to a series of investigations.

Based on the diagnosis of MM and considering the age of patient, (RVD) chemotherapy regimen was started which included tablet lenalidomide 25 mg (once a day from day 1 to day 21), injection bortezomib 1.3 mg/m^2 (2 mg intravenously over 2 min at day 1, day 4, day 8, and day 11), and tablet dexamethasone 40 mg (once a day at day1, day 8, and day 18). The patient underwent 6 cycles at an interval of 4 weeks and responded well with no complications. The patient has shown considerable improvement with almost complete resolution [Figure 7].

DISCUSSION

MM is the prototype of malignant monoclonal gammopathies with the cell of origin being the B-cell in late stage of development process occurring primarily in the bone marrow. MM is characterized by chronic, progressive, clonal neoplastic proliferation of abnormal plasma cells which secretes monoclonal immunoglobulins in the serum, often known as "M" or myeloma proteins.[1,2] It accounts for 1% of all the cancers and approximately 10% of all hematologic malignancies.[3,4] It involves a complex, multistep process, wherein healthy plasma cells transform into malignant myeloma cell resulting in production of abnormal immunoglobulins or M proteins. In normal condition, development of B-cell involves a sequence of conformational changes in DNA leading to the formation of plasmablasts (immature plasma cells) and eventually specific immunoglobulins secreting plasma cells. However, in MM, there is neoplastic transformation of B-cell in late stages of development leading to clonal proliferation of abnormal plasma cells which in most of the cases is characterized by pathological chromosomal translocation involving immunoglobulin heavy chain switch region.[5] Emerging researches have also proposed that dysregulated cyclins are responsible for uncontrolled proliferation of abnormal cells.[6]

The common age group to be affected range from 50 to 80 years with means age being 60 years with male predominance.[7] The most common skeletal sites to be involved are pelvis, skull, spine, ribs, and femoral and humeral shafts.[5] In case of jaw bones, mandible is more commonly involved than maxilla and the attributed reason for this is due to lower content of marrow space in mandible although the present case showed maxillary involvement. Bruce and Royer[8] and Miller *et al.*[9] had found the involvement of jaws in 20–30% of the cases only. Literature has shown that maxillary involvement is even rarer than mandible. Lambertenghi-Deliliers *et al.*[10] said that out of 193 cases, none of the case showed maxillary involvement, Pisano *et al.*[11] concluded saying that 4 out of 13 cases had maxillary involvement and Lae *et al.*[12] reported the involvement of maxilla in 7 out of 33 cases. The clinical manifestations are due to the expansion of abnormal plasma cells in bone marrow which secretes monoclonal light chain or heavy chain immunoglobulin, Bence-Jones proteins, and osteoclast activating factors. The most common clinical manifestations include renal failure, bone pain, fatigue, anemia, hypercalcemia, and infectious diseases, however, no such signs and symptoms were present in the present case except anemia.[13,14] The initial sign of MM in the form of oral and maxillofacial manifestations is a very rare presentation with an incidence of 2–70%.[15,16] The oral manifestations of MM resembles the features of that of malignancy such as pain, paresthesia,

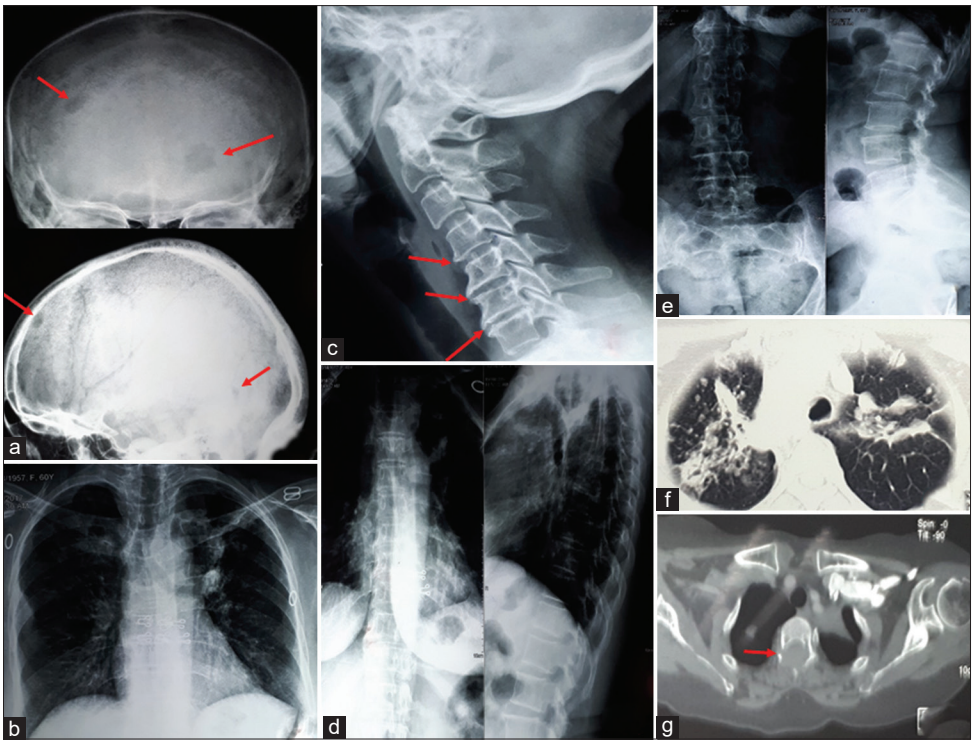

Figure 6: (a) Anteroposterior (AP) and lateral view of skull radiograph showing multiple, well-defined punched out lytic lesions in bony calvaria (shown by arrows), (b) posteroanterior chest radiograph showing a lytic lesion in medial end of the right clavicle and fibrotic opacities in bilateral upper zone of lungs, (c) lateral view of cervical spine radiograph straightening of cervical spine with marginal osteophytes at multiple levels (shown by arrows), (d and e) AP and lateral radiographic views of dorsolumbar and lumbosacral spine showing diffuse osteopenia, (f) axial section of contrast-enhanced computerized tomography (CECT) chest showing well-defined soft-tissue lesion in the left upper lobe with few nodules having irregular margins in the right upper lobe, left upper, and lower lobe, (g) CECT axial section showing a lytic lesion with associated soft tissue in the right 4th rib and spinous process of D2 vertebra with epidural extension (shown by an arrow)

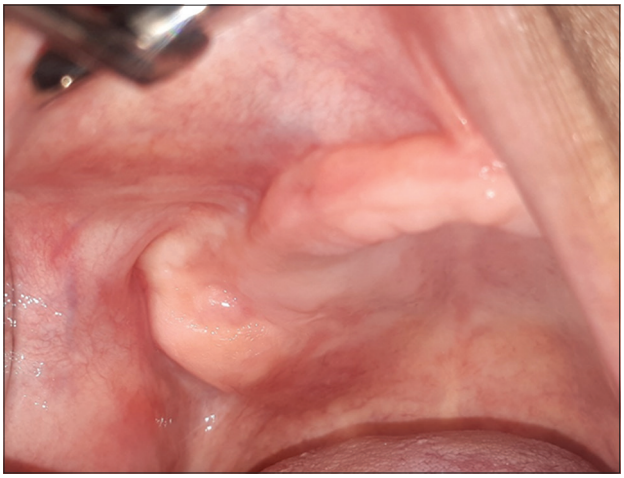

Figure 7: Intraoral photograph showing almost complete resolution of the maxillary lesion after 6 cycles of chemotherapy at an interval of 4 weeks

mucosal ulcerations, swelling, soft-tissue mass, tooth mobility and migration, and pathological fractures.[5]

The series of investigations are required to arrive at definitive diagnosis of MM which involves workup including histopathological confirmation of proliferation of malignant plasma cells, hematological examination, biochemical and immunological examination, urine analysis, bone marrow aspirate, and skeletal survey.[17] When MM is suspected, it is necessary to evaluate the patient for the presence of M proteins using a combination of tests that should include a serum protein electrophoresis, serum immunofixation, and the serum free light chain (FLC) assay.[18] Approximately 2% of patients with MM have true non-secretory disease and have no evidence of an M protein on any of the above studies.[18] The revised International Myeloma Working Group criteria for the diagnosis of MM are ≥10% clonal bone marrow plasma cells or a biopsy-proven plasmacytoma plus evidence of one or more MM defining events: CRAB (hypercalcemia, renal failure, anemia, or lytic bone lesions) features felt related to the plasma cell disorder, bone marrow clonal plasmacytosis ≥60%, serum involved/uninvolved FLC ratio ≥100 (provided involved FLC is ≥100 mg/L), or >1 focal lesion on magnetic resonance imaging.[18] As per the above-mentioned criteria for the diagnosis of MM, the present case fulfilled the biopsy-proven plasmacytoma, anemia, lytic bone lesions, and increased FLC.

Radiographic presentation of MM is commonly osteolytic lesions with irregular, non-corticated margins, and multiple

punched out radiolucencies which could be attributed to infiltration of bone by malignant plasma cells secreting various bone resorbing factors. The four different radiological appearances of bony destruction caused by malignant plasma cells are as follows: Type 1: Solitary type (similar to bone cyst); Type 2: Multiple osteolytic lesions without marginal sclerosis (a) central type and (b) peripheral type; Type 3: Diffuse osteoporosis with generalized involvement; and Type 4: Diffuse osteosclerosis.[19] In the presence case, skull, clavicle, rib, and D2 vertebra showed Type 2 variety, and dorsolumbar and lumbosacral spine showed Type 3 form. Although skeletal conventional plain radiographs have vital contribution toward the assessment of bony involvement, low-dose whole-body CECT, PET/CT, and MRI imaging are more sensitive and should be advised when no changes are observed on routine radiographs, dilemma about the true extent of the disease as well as to assess treatment response and monitoring.

Treatment of MM involves mainly radiation therapy, chemotherapy, and autologous stem cell transplantation. The treatment plan and prognosis is determined by risk stratification through Revised International Staging System which defines three stages on the basis of serum albumin, serum β_2 microglobulin, and high-risk cytogenetics and serum lactate dehydrogenase.[20] Overall survival rate in MM has improved significantly with the emergence of thalidomide, bortezomib, and lenalidomide, and more recently, carfilzomib, pomalidomide, panobinostat, ixazomib, elotuzumab, and daratumumab have been approved by the Food and Drug Administration (FDA) for the treatment of relapsed MM, and promise to improve outcomes further and several combinations of these drugs have been used in the management of MM successfully.[18]

CONCLUSION

A case of MM has been reported wherein primary manifestation in the form of soft-tissue mass in maxilla was present which is a very unusual and rare presentation and no other systemic symptoms were reported. However, we arrived at the conclusive diagnosis of MM after following proper diagnostic protocol through series of investigations along with ruling out other disorders and therefore able to deliver the apt treatment. Hence, it is suggested with reinforcing the role of clinicians in the appropriate workup, early diagnosis, and timely management of such systemic conditions and thus reducing mortality and morbidity in such cases.

REFERENCES

1. Kyle RA, Rajkumar SV. Multiple myeloma. N Engl J Med 2004;351:1860-73.
2. International Myeloma Working Group. Criteria for the classification of monoclonal gammopathies, multiple myeloma and related disorders: A report of the international myeloma working group. Br J Haematol 2003;121:749-57.
3. Rajkumar SV, Dimopoulos MA, Palumbo A, Blade J, Merlini G, Mateos MV, *et al*. International myeloma working group updated criteria for the diagnosis of multiple myeloma. Lancet Oncol 2014;15:e538-48.
4. Rajkumar SV. Multiple myeloma: 2014 Update on diagnosis, risk-stratification, and management. Am J Hematol 2014;89:998-1009.
5. Ghosh S, Wadhwa P, Kumar A, Pai KM, Seshadri S, Manohar C. Abnormal radiological features in a multiple myeloma patient: A case report and radiological review of myelomas. Dentomaxillofac Radiol 2011;40:513-8.
6. Stoopler ET, Vogl DT, Stadtmauer EA. Medical management update: Multiple myeloma. Oral Surg Oral Med Oral Pathol Oral Radiol Endod 2007;103:599-609.
7. Kyle RA, Gertz MA, Witzig TE, Lust JA, Lacy MQ, Dispenzieri A, *et al*. Review of 1027 patients with newly diagnosed multiple myeloma. Mayo Clin Proc 2003;78:21-33.
8. Bruce KW, Royer RQ. Multiple myeloma occurring in the jaws: A study of 17 cases. Oral Surg Oral Med Oral Pathol 1953;6:729-44.
9. Miller CD, Goltry RR, Shenasky JH. Multiple myeloma involving the mandible. Report of a case. Oral Surg Oral Med Oral Pathol 1969;28:603-9.
10. Lambertenghi-Deliliers G, Bruno E, Cortelezzi A, Fumagalli L, Morosini A. Incidence of jaw lesions in 193 patients with multiple myeloma. Oral Surg Oral Med Oral Pathol 1988;65:533-7.
11. Pisano JJ, Coupland R, Chen S, Miller AS. Plasmacytoma of the oral cavity and jaws: A clinicopathologic study of 13 cases. Oral Surg Oral Med Oral Pathol Oral Radiol Endod 1997;83:265-71.
12. Lae ME, Vencio EF, Inwards CY, Unni KK, Nascimento AG. Myeloma of the jaw bones: A clinicopathologic study of 33 cases. Head Neck 2003;25:373-81.
13. Lee SH, Huang JJ, Pan WL, Chan CP. Gingival mass as the primary manifestation of multiple myeloma: Report of two cases. Oral Surg Oral Med Oral Pathol Oral Radiol Endod 1996;82:75-9.
14. Bird JM, Owen RG, D'Sa S, Snowden JA, Pratt G, Ashcroft J, *et al*. Guidelines for the diagnosis and management of multiple myeloma. Br J Haematol 2011;154:32-75.
15. Sharma V, Sharma A. Punched-out lesions in skull. Multiple myeloma. N Z Med J 2010;123:81-2.
16. Mozaffari E, Mupparapu M, Otis L. Undiagnosed multiple myeloma causing extensive dental bleeding: Report of a case and review. Oral Surg Oral Med Oral Pathol Oral Radiol Endod 2002;94:448-53.
17. Pinto LS, Campagnoli EB, Leon JE, Lopes MA, Jorge J. Maxillary lesion presenting as a first sign of multiple myeloma: Case report. Med Oral Patol Oral Cir Bucal 2007;12:E344-7.
18. Rajkumar SV. Multiple myeloma: 2016 update on diagnosis, risk-stratification, and management. Am J Hematol 2016;91:719-34.
19. Witt C, Borges AC, Klein K, Neumann HJ. Radiographic manifestations of multiple myeloma in the mandible: A retrospective study of 77 patients. J Oral Maxillofac Surg 1997;55:450-3.
20. Palumbo A, Avet-Loiseau H, Oliva S, Lokhorst HM, Goldschmidt H, Rosinol L, *et al*. Revised international staging system for multiple myeloma: A report from international myeloma working group. J Clin Oncol 2015;33:2863-9.

How to cite this article: Singh K, Gupta S, Gupta S, Ghosh S, Urs AB, Arora P, Aggarwal S, Prakash A, Sharma R. Multiple Myeloma Presenting as a Maxillary Gingival Mass in Elderly Female. Int J Sci Stud 2020;8(10):10-15.

Source of Support: Nil, **Conflicts of Interest:** None declared.