Original Article

DOI: 10.17354/ijss/2015/383

Sexual Dimorphism of Human Hip Bone with Respect to Chilotic Index in North Karnataka Region

Mohammad Muzammil Ahmed[1], Mohammed Jeelani[2], Syeda Arshiya Tarnum[3]

[1]Assistant Professor, Department of Anatomy, Navodaya Medical College, Raichur, Karnataka, India; [2]Tutor, Department of Physiology, Employees State Insurance Corporation Medical College, Gulbarga, Karnataka, India, [3]Junior Resident, Department of Pediatrics, Employees State Insurance Corporation Medical College, Gulbarga, Karnataka, India

Abstract

Introduction: The hip bone is an ideal bone for sex determination because it reflects the general differences between the two sexes and it also shows a special adaptation of female hip bone for childbearing. For sexing of human skeleton opinion of the experts regards the hip bone as providing the highest accuracy levels. Traditional non-metric methods such as visual examination of bone morphology for determination of sex, depends entirely on the ability and experience of an expert. It is almost impossible to assign sex with 100% certainty in all cases unless the whole skeleton is available.

The purpose of Study: The present study is done to determine the sexual dimorphism of human hip bone with respect to chilotic line and chilotic index (CI).

Materials and Methods: In the present study about 50 dry adult human hip bones of unknown sex are studied, the sex of the bones were determined by some non-metrical parameters, about 31 were classified as male and 19 were classified as females. From these two groups, the bones were further studied for metrical parameters which involved measurement of the pelvic segment and the sacral segment of the chilotic line, and the CI was also calculated.

Results: From the present study, it is revealed that the pelvic segment of the chilotic line is greater in females than in male hip bones and vice versa. The mean value of CI in males is found to be 117.86 and that in female hip bones is found to be 79.88. From the present study, it is also seen that the bones having CI <85 are classified as female hip bones and bones having CI >105 are classified as male hip bones.

Conclusion: From this study, it is concluded that the total chilotic line in males is longer than in females.

Key words: Chilotic index, Chilotic line, Pelvic segment, Sacral segment

INTRODUCTION

Hip bone, also known as the innominate is large, irregular in shape, centrally constricted bone which is expanded above and below. The lateral surface of hip bone has a deep, cup-shaped acetabulum, articulating with the femoral head, antero-inferior to which there is the large obturator foramen, which is oval or triangular in shape. In front bone articulates with its other side fellow to form the pelvic girdle. Each bone has three parts named as ilium, ischium, and pubis which are connected by cartilage and are united as one bone in adults. The ilium includes the upper acetabulum and expanded area above it; the ischium includes the lower acetabulum and bone posteroinferior to it; the pubis forms the anterior acetabulum, separating the ilium from ischium, and the anterior median region where the pubes meet. Determining the sex of the skeletal remains is very important part in any forensic examination or anthropological studies. Therefore, the study of sexual dimorphism of a bone in the group of population is a matter of interest not only for an anatomist but for a forensic expert and an anthropologist. The hip bone is an ideal bone for sex determination because it reflects the general differences between the two sexes providing high accuracy levels of sex determination and it also shows a special adaptation of female hip bone for childbearing.[1] An awareness of the average dimensions of the hip bone in a given population also helps in early detection of

Access this article online

www.ijss-sn.com

Month of Submission : 07-2015
Month of Peer Review : 08-2015
Month of Acceptance : 08-2015
Month of Publishing : 09-2015

Corresponding Author: Dr. Mohammed Jeelani, H.No. 6-30, C1, Near Masjid E Salahin, Mominpura, Gulbarga - 585 104, Karnataka, India. Phone: +91-9538190365. E-mail: drjeelani24@gmail.com

disputed sex by forensic the forensic experts. For sexing of human skeleton opinion of the experts regards the hip bone as providing the highest accuracy levels.[2] Traditional non-metric methods such as visual examination of bone morphology for determination of sex, depends entirely on the ability and experience of expert. It is almost impossible to assign sex with 100% certainty in all cases unless the whole skeleton is available.[3] The introduction of metric method has provided the simplicity and accuracy to determine the sex of skeletal remains. Techniques requiring the measurements of diameters, circumferences or cross sectional areas of tubular bones may provide the needed means for sexing fragmentary remains.[4] Several studies of metrical characteristics in various pelvic regions have been made, leading to the production of various indices. The ilium has received particular attention, e.g. one index compares the pelvic and sacroiliac parts of the bone. A line is extended back from the iliopectineal eminence to the nearest point on the anterior auricular margin and thence to the iliac crest. The auricular point divides this chilotic line into anterior (pelvic) and posterior (sacral) segments, each expressed as a percentage of the other. Chilotic indices display reciprocal values in the sexes: The pelvic part of the chilotic line is predominant in females, and the sacral part in males.

Morphometric measurements done on the right and left sided hip bone indicates that there is bilateral asymmetry of hip bone.[5-7] Racial differences in Chinese, Thais, and Nigerians and other populations have been compared.[8,9] Various metrical parameters for hip bone have also been evolved. In spite of this not much work has been done in the Indian population. Therefore, the need for the present study to be carried out was felt. The present study will hence provide valuable parameters in the hip bones of the Indian population which would help the forensic experts, orthopedicians and anthropologists. The main objective of the present study is to do the morphometry of 50 adult dry human hip bones (25 right and 25 left) in the Indian population to evaluate various parameters of the hip bone.

MATERIALS AND METHODS

A total of 50 adult human hip bones were collected. The samples for the study were collected randomly independent of the sex. The hip bones were collected from the bone bank of Department of Anatomy, Navodaya Medical College, Raichur.

After collection of the hip bones (25 right and 25 left sided) samples randomly, sex of the hip bones is determined based on the non-metrical parameters,[10] as seen in Figure 1 and Figure 2 these bones were further assessed with the metrical parameter. The metric parameter taken under the study is chilotic index (CI), which is calculated with the help of chilotic line as seen in Figure 3, the chilotic line is the line extending from iliopectineal eminence to the nearest point in the anterior auricular margin forming the pelvic segment, and from the previous point to the iliac crest, forming the sacral segment of the chilotic line. The non-metrical parameters taken were:

1. Pre-auricular surface: Para-acetabular groove (AG), Pre-auricular groove (PAG), and Piriform tubercle (PT)
2. Composite arch (CA)



Figure 1: Male hip bone showing non-metrical parameters

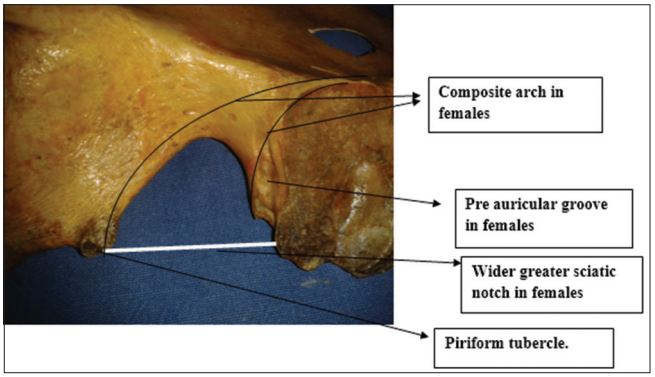

Figure 2: Female hip bone showing non-metrical parameters

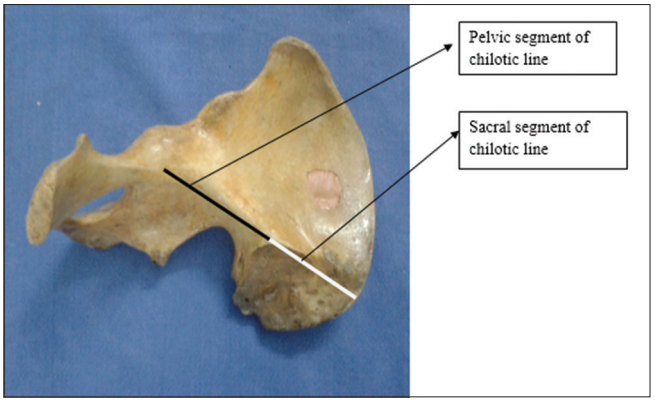

Figure 3: Chilotic line

3. Inferior pelvis: Margo inferior ossis coxae (MOC), phallic ridge (PR), and Ischio-pubic ramus (IPR) aspect.

According to the above mentioned non-metrical parameters sex of the hip bone can be determined by the presence or absence of these characters, hip bones were classified as female bones due to the presence of PAG, the trait only found in female hip bones. The following characteristic were found with the increasing order of their presence in the hip bone to classify male or female hip bone, (1) MOC, (2) PR, (3) IPR aspect, (4) PT, (5) para AG, (6) CA, and (7) PAG. Accordingly 31 bones were classified as male hip bones and 19 hip bones were classified as female hip bones. Only fully ossified adult hip bones were included in the present study. Hip bones showing wear and tear, any fracture, or pathology were excluded.

The metrical parameter taken under study is CI.

Using vernier callipers, the chilotic line was measured (Figures 3-5). The CI is calculated as follows:

$$CI = \frac{\text{Sacral segment}}{\text{Pelvic segment}} \times 100$$

Figure 4: Measuring pelvic segment of chilotic line

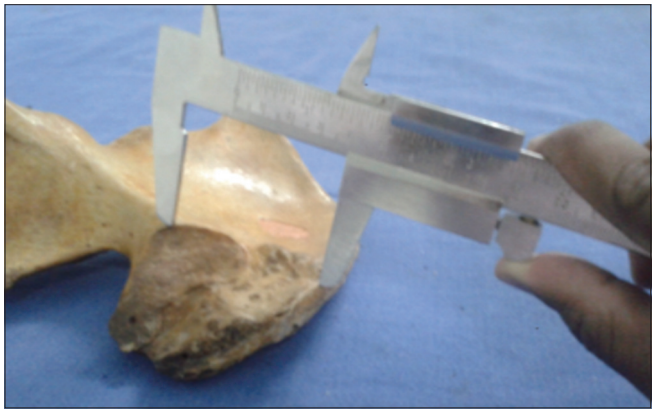

Figure 5: Measuring sacral segment of chilotic line

RESULTS

All the 50 adult hip bones were measured for chilotic line. After all the measurements, the observations were statistically analyzed by using the unpaired *t*-test.

As shown in Table 1, the pelvic segment of the male hip bones falls in the range of 41.3-65.5 mm, with the mean value of 54.14 mm, whereas the pelvic segment of the chilotic line for females lie in the range of 53.4-77.5 mm, with the men value of 63.31 mm. While *P* and *t* values were 0.0001 and 5.8177, respectively.

As shown in Table 2, the sacral segment of male hip bones falls in the range of 56.1-73.5 mm, with the mean value of 62.98 mm, whereas the sacral segment of the chilotic line for females lie in the range of 42.7-56.4 mm, with the mean value of 49.45 mm. While *P* and *t* values were 0.0001 and 10.8844, respectively.

As shown in Table 3, the CI for male lies in the range of 85.648-172.397, with the mean value of 117.865 and for females the CI lies in the range of 55.096-100.177, with the mean value of 79.887. While *P* and *t* values were found to be 0.0001 and 7.8437, respectively.

Table 1: Pelvic segment of chilotic line

Group	Males	Females
Number of bones	31	19
Range	41.3-65.5 mm	54.4-77.5 mm
Mean	54.14 mm	63.31 mm
SD	4.942	5.934
P<0.0001		
t=5.8177		

SD: Standard deviation

Table 2: Sacral segment of chilotic line

Group	Males	Females
Number of bones	31	19
Range	56.1-73.5 mm	42.7-56.4 mm
Mean	62.98 mm	49.45 mm
SD	4.313	4.183
P<0.0001		
t=10.8844		

SD: Standard deviation

Table 3: Interpretation of CI

Group	Males	Females
Number of bones	31	19
Range	85.6-172.39 mm	55.09-100.17 mm
Mean	117.86	79.88
SD	4.313	4.183
P<0.0001		
t=7.8437		

SD: Standard deviation, CI: Chilotic index

In the present study for interpretation of CI, it is seen that higher frequency of male bones, about 26% were in the class interval of 116-125, followed by 23% in the class interval of 106-115, followed by 16% in the class interval of 96-105, followed by 13% in the class interval of 85-95, followed by 10% in the class interval of 126-135, followed by 6% in the class interval of 146-155, followed by 3% in class interval of 136-145, and another 3% in class interval of 146-155.

For interpretation of CI in females, the highest frequency of females bones lie in the class interval of 86-95, about 32%. 26% were in the class interval of 66-75, 21% were in 76-85, 16% were in 55-65, and 5% were in the class interval of 96-105.

In this study, it is seen that the CI differentiates sex except in the range of 85-105 where overlapping values is seen in both sexes, therefore the probability of the bone belonging to male is higher if the CI is more than 105 and to females if the CI is <85.

DISCUSSION

The mean pelvic and the sacral segment of the present study along with the mean of CI in both males and females are compared with other studies as shown in Table 4. In the present study, the mean value of pelvic segment and sacral segment along with the mean value of CI of males is found to be 54.14 mm, 62.98 mm, and 117.86, respectively and in females the mentioned parameters are found to be 63.31 mm, 49.45 mm, and 79.88, respectively. In the study done by Derry,[11] the mean values of pelvic segment, sacral segment and chilotic line in males are found to be 54.5 mm, 59.9 mm, and 124.4, respectively, and in females the mean values of the mentioned parameters were found to be 59.1 mm, 60.8 mm, and 120.5, respectively.

Table 4: Comparison of mean values of pelvic segment and sacral segment of the chilotic line and also CI with other studies

Investigator	Pelvic segment (mm)		Sacral segment (mm)		CI	
	Males	Females	Males	Females	Males	Females
Derry[11]	54.5	59.1	59.9	60.8	124.4	120.5
Davivongs[12]	49.88	58.23	60.01	56.74	113.88	114.97
Charnalia[13]	47.14	59.90	65.72	56.74	112.86	115.64
Sarangee *et al.*[14]	54.3	60.0	62.0	50.35	116.30	110.5
Present study	54.14	63.31	62.98	49.45	117.86	79.88

CI: Chilotic index

The comparison with other authors is shown in Table 4.

CONCLUSION

From this study, it is concluded that the total chilotic line in males is longer than in females. The value of mean CI in males is found to be 117.86 and in females it is found to be 79.88, there from this study it is seen that average values of CI is more in males then in females. From the present study, it is also seen that few hip bones about 12% in females and 23% in males have overlapping values of CI lying in the range of 85-105, therefore from the present study of CI about 77% of hip bones were accurately classified as male hip bones and about 88% of hip bones were classified as female hip bones, from the present study, it is also concluded that the bones having the values of CI <85 belongs to females and the hip bones having the values of CI above 105 belongs to males.

REFERENCES

1. Shah S, Zalawadia A, Ruparelia S, Patel S, Rathod SP, Patel SV. Morphometric study of greater sciatic notch of dry human hip bone in Gujarat region. NJIRM 2011;2:27-30.
2. Phenice TW. A newly developed visual method of sexing the os pubis. Am J Phys Anthropol 1969;30:297-301.
3. Singh G, Singh S, Singh SP. Identification of sex from tibia. J. Anat Soc India 1975;24:20-4.
4. Black TK 3rd. A new method for assessing the sex of fragmentary skeletal remains: Femoral shaft circumference. Am J Phys Anthropol 1978;48:227-31.
5. Chhibber SR, Singh I. Asymmetry in muscle weight and one-sided dominance in the human lower limbs. J Anat 1970;106:553-6.
6. Singh I. Functional asymmetry in the lower limbs. Acta Anat (Basel) 1970;77:131-8.
7. Dogra SK, Singh I. Asymmetry in bone weight in the human lower limbs. Anat Anz 1971;128:278-80.
8. Varodompun N, Thinley T, Visutipol B, Ketmalasiri B, Pattarabunjerd N. Correlation between the acetabular diameter and thickness in Thais. J Orthop Surg (Hong Kong) 2002;10:41-4.
9. Msamati BC, Igbigbi PS, Lavy CB. Geometric measurements of the acetabulum in adult Malawians: Radiographic study. East Afr Med J 2003;80:546-9.
10. Chaudhary AK, Jain SK. Osteoscopic assessment of sexual dimorphism in hip bone. Acta Med Int 2014;1:22-5.
11. Derry DE. On the sexual and racial characters of the human ilium. J Anat 1923;58:71-83.
12. Davivongs V. The pelvic girdle of the Australian aborigine; sex differences and sex determination. Am J Phys Anthropol 1963;21:443-55.
13. Charnalia VM. Sex difference and determination in human sacra in south India. J Anat Soc India 1967;16:33.
14. Sarangee MP, Maharana PC, Rao KS, Das S. A study on sexual dimorphism of the human hip bones in respect of chilotic line and chilotic index in the population of Orissa. Indian Anthropol 1992;22:13-23.

How to cite this article: Ahmed MM, Jeelani M, Tarnum SA. Sexual Dimorphism of Human Hip Bone with Respect to Chilotic Index in North Karnataka Region. Int J Sci Stud 2015;3(6):14-17.

Source of Support: Nil, **Conflict of Interest:** None declared.