

Treatment of Distal End Radius Fractures - By Various Modalities

Rajiv Sakhuja¹, Antony R Benn², Gaurav Sharma³, Swaroop Solunke⁴

¹Assistant Professor, Department of Orthopaedics, CIMS Medical College and Hospital, Bilaspur, Chhattisgarh, India, ²Professor, Department of Orthopaedics, CIMS Medical College and Hospital, Bilaspur, Chhattisgarh, India, ³Assistant Professor, Department of Orthopaedics, MGM Medical College, Navi Mumbai, Maharashtra, India, ⁴Assistant Professor, Department of Orthopaedics, D. Y. Patil Medical College, Pimpri, Pune, India

Abstract

Introduction: Fractures of the distal end radius represent approximately 16% of all fractures treated by orthopedic surgeons. Our study is intended to find both conceptual and practical guidance for precision treatment with an expectant favorable result.

Materials and Methods: A total of 50 patients of distal end radius fractures were treated with cast immobilization, percutaneous pinning, external fixation, and volar locking plate fixation. Fernandez classification was used. Functional outcomes were assessed using Demerit Point System of Gartland and Werley (modified). The anatomical evaluation was done by Lindstrom criteria (modified).

Results: Functional outcomes depend on patient's age, fracture anatomy, displacement, reducibility, stability, and articular incongruity of fractures. They are related more to the anatomical reduction than to the method of immobilization. Volar locking plate is a safe and effective treatment for unstable and metaphyseal comminuted fractures.

Conclusion: According to Fernandez classification, Type I fractures were the most common. The volar locking compression plate fixation gives excellent functional and anatomical results than other modalities of treatment. Hence, we recommend volar locking plate fixation is the best modality of treatment among others.

Key words: Fernandez classification, Fracture distal end radius, Volar plating

INTRODUCTION

Fractures of the distal radius are a common clinical problem affecting skeletally mature people. The young sustain this injury as a result of significant local trauma. The elderly have predisposing risks of disuse or postmenopausal osteoporosis.^[1]

The overall male to female ratio is about one to five. However, before the age of 40 the incidence is equal in both sexes. In males, the incidence rises only slightly from the age of 40 to 80 but in the females it is 8–10 times from 40 to 60 after which it remains constant. This correlates with an increased incidence of osteoporosis after menopause in females.^[2,3]

These fractures are generally closed and usually involve displacement of fracture fragments. They may be either extra-articular or intra-articular. In particular, “Colles’ fracture” is still the terminology used for a fracture in which there is an obvious and typical clinical deformity.^[4]

Two centuries have passed since the first description of Colles’ fracture, still there is no unanimity about its best management. Different authors have claimed varied results with various treatment modalities.

The final choice of treatment method will be influenced by many considerations including the nature of the fracture, bone stock and fragility, the presence of local complications (compound injury and nerve injury) or other injuries, the patient's general medical condition, the expected functional loading (activity demands), and patient motivation.^[3]

In our study, we have included closed reduction with plaster cast; percutaneous pinning; external fixation with external fixator using the principle of ligamentotaxis; and internal

Access this article online



www.ijss-sn.com

Month of Submission : 09-2019
Month of Peer Review : 10-2019
Month of Acceptance : 11-2019
Month of Publishing : 11-2019

Corresponding Author: Dr. Rajiv Sakhuja, Assistant Professor, Department of Orthopedics, CIMS Medical College and Hospital, Bilaspur, 495001, Chhattisgarh, India.

fixation with plates, pins, and screws, depending on the type of fracture and patients general condition.

Aims

The aims are as follows:

1. To study the outcomes different treatment modalities of fractures of distal end of radius
2. To compare the anatomical results between various treatment modalities
3. To compare the functional outcomes between various treatment modalities
4. To study the complications of different treatment modalities.

Inclusion Criteria

All isolated fractures of the distal end of radius between the age group of 18 and 80 years among males and females were included in the study.

Exclusion Criteria

The following criteria were excluded from the study:

1. All compound fractures of distal end radius
2. Pathological fractures
3. Distal radius fractures with other injuries around the wrist joint.

Radiographic Assessment

Radiographic imaging is important in diagnosis, classification, treatment, and follow-up assessment of these fractures.

Guidelines for acceptable closed reduction as given by Nana *et al.* (2005)^[5] include:

1. Radial inclination: Greater than or equal to 15 degrees on the posteroanterior view
2. Radial length: Less than or equal to 5 mm shortening on posteroanterior view
3. Radial Tilt: Less than 15 degrees dorsal or 20 degrees volar tilt on the lateral view
4. Articular incongruity: Less than 2 mm of step off.

Radiographic signs that alert the surgeon that the fracture is probably unstable and closed reduction alone will be insufficient include the following:^[6-8]

- a. Dorsal comminution >50% of the width in lateral view
- b. Palmar metaphyseal comminution
- c. Initial dorsal tilt >20 degrees
- d. Initial displacement (fragment translation) >1 cm
- e. Initial radial shortening more than 5 mm
- f. Intra-articular disruption
- g. Associated ulna fracture
- h. Severe osteoporosis

Classification

We have used Fernandez classification – According to the mechanism of injury^[9] in our study:

Table 1: Demerit Point System used to evaluate end results of healed colles fractures

Result	Points
Residual deformity	
Prominent ulnar styloid	1
Residual dorsal tilt	2
Radial deviation of hand	2–3
Point range	0–3
Subjective evaluation	
Excellent: No pain, disability or limitation of motion	0
Good: Occasional pain, slight limitation of motion, no disability	2
Fair: Occasional pain, some limitation of motion, feeling of weakness in wrist, no particular disability if careful, activities slightly restricted	4
Poor: Pain, limitation of motion, disability, activities more or less markedly restricted	6
Point range	0–6
Objective evaluation of range of motion	
Loss of dorsiflexion	5
Loss of ulnar deviation	3
Loss of supination	2
Loss of palmar flexion	1
Loss of radial deviation	1
Loss of circumduction	1
Loss of pronation	2
Pain in distal radioulnar joint	1
Grip strength – 60% or less of opposite side	1
Point range	0–5
Complications arthritic change	
Minimum	1
Minimum with pain	3
Moderate	2
Moderate with pain	4
Severe	3
Severe with pain	5
Nerve complications (median)	1–3
Poor finger functions due to cast	1–2
Point range	0–5
End result point ranges	
Excellent	0–2
Good	3–8
Fair	9–20
Poor	21 and above

Table 2: Age and sex distribution

Age in years	Male No. of cases (%)	Female No. of cases (%)	Total No. of cases (%)
<20	1 (3.57)	0	1 (2)
21–30	10 (35.71)	2 (9.09)	12 (24)
31–40	6 (21.43)	3 (13.63)	9 (18)
41–50	2 (7.14)	2 (9.09)	4 (8)
51–60	6 (21.43)	6 (27.27)	12 (24)
61–70	2 (7.14)	5 (22.73)	7 (14)
>70	1 (3.57)	4 (18.19)	5 (10)
Total	28 (56)	22 (44)	50 (100)
Mean±SD	39.70±8.87	54.40±11.02	46.15±9.88

- Type I: Fractures are extra-articular metaphyseal bending fractures, such as Colles' (dorsal angulation) or Smith (volar angulation) fractures. One cortex fails in tension, and the opposite cortex is comminuted and impacted

- Type II: Fractures are intra-articular and are produced by shearing. These include volar Barton, dorsal Barton, and radial styloid fractures
- Type III: Fractures result from compression injuries that cause intra-articular fractures and impaction of metaphyseal bone. These include complex articular fractures and radial pilon fractures
- Type IV: Fractures are avulsion fractures of ligament attachments that occur with radiocarpal fracture-dislocations
- Type V: Combined injuries with significant soft tissue involvement due to the high-energy nature of these fractures.

Treatment Modalities

Closed reduction and plaster cast method

From 1925 plaster immobilization was used for Colles’ fracture. Most frequently used cast or splint is a below the elbow. It relies on the principle of ligamentotaxis to reduce fracture fragments. No control can be expected for depressed articular fragments that lack ligament attachment.^[2,10,11] For disimpaction of fragment traction was given for 2–5 min followed by additional manual pressure on the distal fragment to achieve reduction. This is commonly used method.^[11,12] According to Bohler, the wrist should be positioned between volar and dorsal flexion, with moderate ulnar deviation.^[13] Weber documented that collapse of the fracture is unavoidable because the compressive forces generated by the tendons of flexor and the extensor muscles

crossing the wrist cannot be counteracted by the supporting plaster.^[14]

Several factors have been associated with re-displacement following closed manipulation of a distal radius fracture:

1. The initial displacement of the fracture
2. The age of the patient
3. The extent of metaphyseal comminution (the metaphyseal defect)
4. Displacement following closed treatment is a predictor of instability.

We used below-elbow cast with forearm in pronation and above elbow cast in cases of comminution and associated ulna styloid fracture.

Percutaneous pin fixation

Percutaneous pinning techniques are an attempt to bridge the therapeutic gap between external fixation. Indications for percutaneous pin fixation are as follows:^[15]

- Extra-articular undisplaced Colles’ fracture
- Extra-articular displaced Colles’ fracture
- Intra-articular fracture with two fragments where the radial styloid fragment is larger
- Intra-articular fracture with radio-ulnar joint involvement
- Subluxation of the distal radio-ulnar joint.

The method we used first achieved the reduction by traction and counter traction followed by insertion of smooth Kirschner wires through the radial styloid and through the ulnar end of the radius. After this, they immobilized the extremity in a plaster cast; wrist in ulnar deviation and 15-degree flexion and elbow flexion for above-elbow cast.^[15]

Fractures with volar comminution, fractures with any articular displacement and fractures with more

Table 3: Mode of trauma (overall cases)

Mode of trauma	No. of cases (%)
Fall	33 (66)
RTA	17 (34)
Total	50

RTA: Road traffic accident

Table 4: Modality of treatment and type of fracture (Fernandez classification)

Fernandez classification	Modality of treatment (%)				Total
	CMRC	External fixator	PL	Percutaneous pinning	
I	10 (55.55)	2	1 (5.55)	5 (27.78)	18 (36)
II	0	2	8 (57.15)	4 (28.57)	14 (28)
III	4 (26.67)	7	2 (13.033)	1 (6.67)	14 (28)
IV	0	0	0	0	0
V	0	4	0	0	4 (8)
Total	14 (28)	15 (30)	11 (22)	10 (20)	50

Value of $\chi^2=29.12$, $df=12$, significant, $P<0.05$. CMRC: Closed manual reduction with cast, PL: Plating

Table 5: Mean follow-up of patients (weeks)

Duration of follow-up (weeks)	Treatment modality				Mean total
	Plaster cast	External fixator	Plating	Percutaneous pinning	
Mean±SD	20.285±3.62	22.60±1.80	21.82±2.13	20.50±2.83	21.30±2.14

Mean follow-up of all patients in our study was 21.3 weeks

Table 6: Mean values of the range of movements of various treatment modalities (in degrees)

Range of motion	CMRC	Percutaneous pinning	External fixator	PL
Dorsiflexion	49.28	72	63.33	75.45
Palmar flexion	46.42	64	53	70.90
Radial deviation	12.14	12.5	12.0	18.63
Ulnar deviation	16.78	21.5	20	27.27
Pronation	48.92	68	62.66	77.27
Supination	51.07	71	63.33	76.36

CMRC: Closed manual reduction with cast, PL: Plating

than “minimal articular involvement” are reported contraindications for this technique.^[16]

The early loss of reduction and the late collapse after Colle’s fracture were blamed for poor functional outcome. Need for intact volar buttress and dorsal tension by traction or external fixator was stressed to prevent them.^[17]

External fixation

It was indicated when there was failure to maintain adequate closed reduction using plaster, unstable fractures which on radiography had dorsal angulations of more than 20 degree, fractures involving the joint, radial shortening of more than 10 mm, and severe dorsal comminution.^[18]

For Frykman’s Type VII or Type VIII fractures, external fixation is the treatment of choice. The importance of reduction of Sheck’s dorsomedial “Die-punch fragment” was also emphasized.^[19,20] The fixator should be retained for 8 weeks to reduce the risk of loss of position and it gives good or excellent anatomical results on radiological assessment after removal of fixator; the functional results were good or excellent in 80% in these complicated fractures.^[21]

The principles of the application of external fixator for distal radius fractures are as follows:^[22]

1. The distance between the skin and fixator should be as small as possible
2. The fixator should be fixed as close as possible to the fracture
3. The diameter of the pins should be as great as possible
4. If more than 2 pins per plane are used, the pins should be wide apart
5. If only two pins per plane are used the bending force on each pin is high
6. If more than two parallel pins per plane are used the axial forces on each pin are high
7. The pins should be placed at the right angle to the fractured bone.

External fixators could be combined with percutaneous pin manipulation of key fragments, percutaneous screw

fixation of larger fragments, or open reduction, and internal fixation.^[23]

Open reduction and internal fixation by plates

Surgical treatment (plating in particular) ensures more consistent correction of displacement and maintenance of reduction. The choice of surgical technique for reduction and fixation depends on fracture displacement, joint surface involvement, patient age, bone quality, occupation, and avocation. Surgeon experience and preference also dictate the treatment method.

With the advent of new fixed-angle screw plate designs, volar fixation should be the standard approach for distal radius fractures. When the comminution involves both the palmar and the dorsal cortices, the use of palmer locking plate is preferred. Volar plating is also ideally used in unstable bending fractures of the radial metaphysis due to the ability to control and maintain physiologic palmer tilt, prevent collapse with external fixation and avoid bridging the radio-carpal joint. The emphasis on optimal management of articular shear fractures is on anatomical reduction of the articular surface and compression across the fracture site, which is achieved with a volar buttress plate.^[24]

Volar plates fall into four functional categories: Buttress plates (with or without distal screws), tiny or blade plates, fixed-angled locking plates, and polyaxial locking plates.

Martineau *et al.* documented that the locking nature of the screw-plate construct produces fixation even in bone defects and osteopenic bone and permits early range of motion exercises. In contrast to external fixation and percutaneous pinning, no tethering of muscle, tendon, or capsule occurs with plate fixation and therefore motion of the wrist and fingers is uninhibited. These advantages would permit earlier and more aggressive rehabilitation and more rapid regain of function.

MATERIALS AND METHODS

This study is carried out on the patients with fractures of the distal end radius, admitted and treated in CIMS Medical College and Hospital, Bilaspur, C.G. from 2016 to 2018. Fifty patients with fractures of the distal radius were included in the study.

On arrival of patient, detail history regarding age, sex, mode of injury, days since injury, associated injuries were noted carefully. The patients were assessed clinically and radiologically. The fracture pattern was noted and the fractures were classified according to Fernandez (1993) classification system. Radiological assessment was done

in terms residual dorsal tilt, radial shortening and loss of radial inclination and the results were graded according to Sarmiento’s modification of Lindstrom criteria^[2,25] which is:

Results	Deformity	Residual dorsal tilt	Radial shortening	Loss of radial inclination
Excellent	No or insignificant	0°	<3 mm	<5°
Good	Slight	1°–10°	3–6 mm	5°–9°
Fair	Moderate	11°–14°	7–11 mm	10°–14°
Poor	Severe	≥15°	≥12 mm	>14°

Functional evaluation of the patients was done at last follow-up according to the demerit point system of Gartland and Werley with Sarmiento *et al.*'s modification.^[25]

Follow-up

The follow-up was on 10th day, and 6, 12, and 24 weeks, respectively. They were assessed for any wound dehiscence, radiological assessment for fracture healing, swelling secondary to tightness of cast, compartment syndrome, pin tract infection, redisplacement of fracture in cast, and in percutaneous pinning category patients, pin loosening, and re-alignment of distracter accordingly.

All the patients were motivated for physiotherapy and range of motion exercises in every follow-up.

OBSERVATIONS AND RESULTS

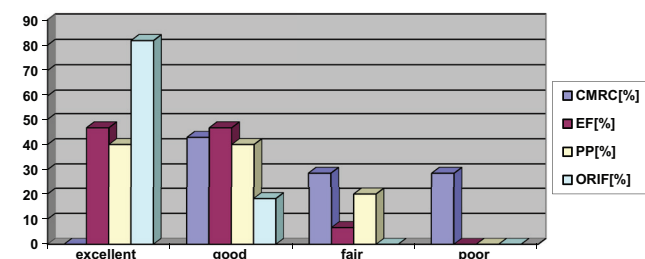
In our study of 50 patients, 28 were males and 22 were females. The fractures were most common among 21–30 and 51–60 years of age group. The youngest patient was 18 years old and the eldest was 80 years old.

By applying the Chi-square test, there is a significant association between the modality of treatment and type of fracture (Fernandez classification) ($P < 0.05$).

The most common fracture in our study, according to Fernandez classification, was Type I followed by Types II, III, and V.

Anatomical Evaluation

Anatomical evaluation results according to Sarmiento’s modification of Lindstrom criteria were obtained.



In our study, anatomically excellent results according to Sarmiento’s modification of Lindstrom criteria were obtained in open reduction and plate fixation (81.81%) followed by ligamentotaxis by external fixator application (46.66%) and percutaneous pinning (40%).

Functional Evaluation

Functional evaluation of the patients was done at last follow-up according to Demerit Point System of Gartland and Werley with Sarmiento *et al.*'s modification.

For closed reduction and cast application group

Out of 14 patients, 57.14% had good results and 42.86% had fair to poor results.

For external fixator group

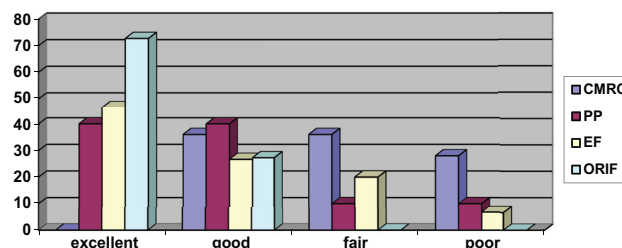
Out of 15 patients, 73% has given us excellent to good results, with the most common type of fracture being Type III and 27% has given fair to poor results with Type V fractures.

For percutaneous pinning group

Out of 10 patients treated with this modality, 90% gave excellent to good results and 10% gave poor results. The poor results were due to complexity of fracture.

For open reduction and plate fixation group

Out of 11 patients, 72.72% has given us excellent results and 27.27% has given us good results. There were no poor results in this group.



In our study, assessment of functional outcome by Demerit’s Point System of Gartland and Werley with Sarmiento *et al.* modification revealed excellent results with open reduction and plate fixation modality (72.72%), followed by ligamentotaxis by external fixator application (46.67%) and percutaneous pinning modality.

Complications

The most common complications encountered in our series were stiffness and pain in the wrist joint after removal of cast or external fixator because of lack of wrist movements for prolonged time. We observed Plaster sores in two patients, pin tract infections in three patients, which were superficial and got treated by oral antibiotics, pin loosening in two patients treated by external fixator due

to osteoporotic bone. Three patients developed minimal arthritic changes at 24 weeks of follow-up. The presence of deformity in six patients, which was mostly prominence of ulna styloid and residual dorsal tilt, which is seen in patients treated nonoperatively [Tables 1-6].

CONCLUSION

We have concluded:

1. Fracture of distal end of radius is one of the most common fractures occurring in all age groups. The youngest patient in our study was 18 years of age while the eldest was 80 years, with the mean age being 49 years
2. This fracture is more common in males (56%) than females (44%)
3. Fall is still the common mode of injury than road traffic accidents. Among which females were more common in sustaining this type of fracture, due to domestic fall and post menopausal osteoporosis, while road traffic accident was common in males
4. From Fernandez classification we have concluded, that bending type of injury is most common
5. Closed manual reduction and cast application modality gives good functional results in undisplaced, extra-articular distal radius fractures, but at a later stage. It has given poor results in displaced extra-articular, and in intra-articular fractures
6. Among the operative treatment, percutaneous pinning has given us excellent results in displaced extra-articular fractures and intra-articular fractures where the radial styloid is the major fragment
7. External fixator has given us good results by the principle of ligamentotaxis in complex fractures sustained by high-velocity injuries. Although anatomical results were good and functional results were delayed due to prolong immobilization of wrist in external fixator
8. Open reduction and internal fixation with plates and screws in our study have given excellent anatomical and functional results in displaced extra-articular, intra-articular, and complex fractures sustained by high-velocity trauma. With this treatment modality, the patient can start mobilization of wrist immediately after surgery and attain full range of motion in 6–8 weeks postoperatively, with no loss of grip strength.

Hence, to achieve good anatomical reduction and stable fixation and for early functional recovery with negligible complications, we recommend open reduction and volar

locking plate fixation treatment modality is best suited, among others.

REFERENCES

1. Colles A. On the fracture of the carpal extremity of the radius. *Edinb Med Surg J* 1814;10:182-6.
2. Lindstrom A. *Fractures of Distal end Healing*. Philadelphia, PA: W B Saunders Company; 1980.
3. Frykman G. Fracture of the distal radius including sequelae shoulder-hand-finger syndrome, disturbance in the distal radio-ulnar joint and impairment of nerve function. A clinical and experimental study. *Acta Orthop Scand* 1967;Suppl 108:7-153.
4. Handoll HH, Madhok R. Conservative interventions for treating distal radial fractures in adults. *Cochrane Collaboration* 2008;4:4-21.
5. Nana AD, Joshi A, Lichtman DM. Plating of the distal radius. *J Am Acad Orthop Surg* 2005;13:159-71.
6. Mann FA, Wilson AJ, Gilula LA. Radiographic evaluation of the wrist: What does the hand surgeon want to know? *Radiology* 1992;184:15-24.
7. Rubinovich RM, Rennie WR. Colles' fracture: End results in relation to radiologic parameters. *Can J Surg* 1983;26:361-3.
8. Metz VM, Gilula LA. Imaging techniques for distal radius fractures and related injuries. *Orthop Clin North Am* 1993;24:217-28.
9. Fernández DL. Fractures of the distal radius: Operative treatment. *Instr Course Lect* 1993;42:73-88.
10. Gartland JJ Jr., Werley CW. Evaluation of healed Colles' fractures. *J Bone Joint Surg Am* 1951;33-A:895-907.
11. Blichert-Toft M, Jensen HK. Colles' fracture treated with modified Böhler technique. *Acta Orthop Scand* 1971;42:45-57.
12. Friberg S, Lundström B. Radiographic measurements of the radio-carpal joint in normal adults. *Acta Radiol Diagn (Stockh)* 1976;17:249-56.
13. Bohler L. (Ed.). *The Treatment of Fractures*. Vienna, Austria: W Maudrich; 1929.
14. Weber ER. A rational approach for the recognition and treatment of Colles' fracture. *Hand Clin* 1987;3:13-21.
15. Stein AH Jr., Katz SF. Stabilization of comminuted fractures of the distal inch of the radius: Percutaneous pinning. *Clin Orthop Relat Res* 1975;108:174-81.
16. Kapandji A. Internal fixation by double intrafocal plate. Functional treatment of non articular fractures of the lower end of the radius (author's transl). *Ann Chir* 1976;30:903-8.
17. Cooney WP 3rd, Linscheid RL, Dobyns JH. External pin fixation for unstable Colles' fractures. *J Bone Joint Surg Am* 1979;61:840-5.
18. Vaughan PA, Lui SM, Harrington JJ, Maistrelli GL. Treatment of unstable fractures of the distal radius by external fixation. *J Bone Joint Surg Br* 1985;67:385-9.
19. Knirk JL, Jupiter JB. Intra-articular fractures of the distal end of the radius in young adults. *J Bone Joint Surg Am* 1986;68:647-59.
20. Clyburn TA. Dynamic external fixation for comminuted intra-articular fractures of the distal end of the radius. *J Bone Joint Surg Am* 1987;69:248-54.
21. Prince H, Worlock P. The small AO external fixator in the treatment of unstable distal forearm fractures. *J Hand Surg Br* 1988;13:294-7.
22. Herzberg W, Overbeck E, Herzberg R, Deckelmann G. Comparative theoretical study of various external fixation devices for the stabilization of distal radius fractures. *Unfallchirurg* 1990;93:257-62.
23. Agee JM. External fixation. Technical advances based upon multiplanar ligamentotaxis. *Orthop Clin North Am* 1993;24:265-74.
24. Charles AR Jr., Green DP. *Fractures in Adults*. 6th ed., Vol. 1. 2006. p. 910-63.
25. Sarmiento A, Pratt GW, Berry NC, Sinclair WF. Colles' fractures. Functional bracing in supination. *J Bone Joint Surg Am* 1975;57:311-7.

How to cite this article: Sakhuja R, Benn AR, Sharma G, Solunke S, Thorat R. Treatment of Distal End Radius Fractures – By Various Modalities. *Int J Sci Stud* 2019;7(8):31-36.

Source of Support: Nil, **Conflict of Interest:** None declared.