Print ISSN: 2321-6379
Online ISSN: 2321-595X

Original Article

Cytological Evaluation of Cervical PAP Smears in a Tertiary Care Center

Mallepogu Anil Kumar[1], Palakomma Vijetha[2], Gudikona Madhu[3], Mandla Janaki[4]

[1]Associate Professor, Department of Pathology, Santhiram Medical College and General Hospital, Nandyal, Andhra Pradesh, India, [2]Assistant Professor, Department of Anaesthesia, Santhiram Medical College and General Hospital, Nandyal, Andhra Pradesh, India, [3]Assistant Professor, Department of Pathology, Santhiram Medical College and General Hospital, Nandyal, Andhra Pradesh, India, [4]Professor and Head, Department of Pathology, Santhiram Medical College and General Hospital, Nandyal, Andhra Pradesh, India

Abstract

Background: Cervical carcinoma is the leading cause of death among women. Infections are the common gynecological problems and are curable. Screening tests are used for the detection of an infection, precancerous, and cancerous lesions. Conventional Papanicolaou (PAP) test is commonly used for early diagnosis and follow-up.

Aims and Objectives: The objectives of the study are as follows: (1) To study the cervical cytology in all age groups. (2) To evaluate the PAP smear according to Bethesda system

Materials and Methods: The prospective study was conducted and total of 815 PAP smears were evaluated in the department of pathology, Santhiram Medical College and General Hospital, Nandyal, Andhra Pradesh, during the period of 6 months from January 2022 to June 2022.

Results: Out of 815 cases, 795 (97.5%) cases were satisfactory and 20 cases (2.5%) were non satisfactory. Among 795 cases, 256 (32.2%) cases with negative for intraepithelial lesions or malignancy, 462 (58.1%) cases with inflammatory lesions, 33 (4.2%) cases with atypical squamous cells with undetermined significance, 20 (2.5%) cases with low-grade squamous intraepithelial lesion, and 12 (1.5%) cases with high-grade squamous intraepithelial lesion. 4 (0.5%) cases with atypical glandular cells of undetermined significance and 8 (1%) cases with squamous cell carcinoma.

Conclusion: Cervical cytological PAP test is used a screening test for detection of inflammatory, pre-cancerous, and cancerous lesions.

Key words: High-grade squamous intraepithelial lesion, Low-grade squamous intraepithelial lesion, Papanicolaou test, Squamous cell carcinoma

INTRODUCTION

Carcinoma cervix is the fourth leading cause of morbidity and mortality in developing countries. Cervical carcinoma is preventable and curable cancer as the precancerous cells are found in early stage of disease.[1]

The strategy of WHO is to reduce the incidence of cervical cancer by increasing the awareness of Papanicolaou (PAP) screening tests. PAP test is very specific, simple, rapid, and cost-effective. PAP smear test is ideal for mass screening programs and useful to evaluate the various cellular alterations of cervical abnormalities.

The present study was done to study the cervical PAP smears to classify the smears as inflammatory, pre-malignant, and malignant lesions.

Access this article online

www.ijss-sn.com

Month of Submission : 12-2022
Month of Peer Review : 01-2023
Month of Acceptance : 01-2023
Month of Publishing : 02-2023

MATERIALS AND METHODS

The prospective study was conducted in the Department of Pathology at Santhiram Medical College and General Hospital, Nandyal, from January 2022 to June 2022. Samples were collected from all women of 20–70 years. The

Corresponding Author: Dr. Mandla Janaki, Department of Pathology, Santhiram Medical College and General Hospital, Nandyal, Andhra Pradesh, India.

study was conducted for a period of 6 months. PAP smears are received from the OBG and gynecology department. Smears are stained with PAP staining. Patients details were obtained from requisition and case sheets.

Inclusion Criteria

Women in the age group of 20–70 years with history of leucorrhea, foul smelling discharge, and unhealthy cervix were included in the study.

Exclusion Criteria

Women with theprevious surgical procedures on the cervix, unmarried females, pregnant women, and known case of carcinoma cervix are excluded from the study. Ethical approval was taken from the Institutional Ethical Committee.

Cervical PAP smears reporting were done according to Bethesda system (2014).

Bethesda System for Reporting PAP Smears

Specimen adequacy

1. Satisfactory for evaluation
2. Unsatisfactory for evaluation (Hemorrhage, severe inflammation).

General categorization

1. Negative for intraepithelial lesion or malignancy (NILM)
2. Epithelial cell abnormalities
3. Others.

Non-neoplastic results, organisms

1. *Trichomonas vaginalis*
2. Fungal organisms morphologically consistent with *Candida* species
3. Shift in flora suggestive of Bacterial vaginosis
4. Bacteria morphologically consistent with actinomyces species
5. Cellular changes consistent with herpes simplex virus infection.

Other neoplastic findings

1. Reactive cellular changes due to infection
2. Reactive cellular changes due to radiation
3. Reactive cellular changes due to intrauterine device
4. Benign glandular cells after hysterectomy
5. Atrophy.

Epithelial cell abnormalities

1. Squamous cell abnormalities
   a. Atypical squamous cell undetermined significance (ASC-US)
   b. ASC cannot exclude (ASC-H) high grade squamous intraepithelial lesion (HSIL).
2. Low-grade squamous intraepithelial lesion (LSIL)
3. HSIL
4. Squamous cell carcinoma (SCC).

Glandular cell abnormalities

1. Atypical glandular cells (specify endocervical, endometrial, or not otherwise specified)
2. Atypical glandular cells favor neoplastic (specify endocervical or not otherwise specified)
3. Endocervical adenocarcinoma *in situ*
4. Adenocarcinoma (specify endocervical, endometrial, extrauterine, or not otherwise specified).

RESULTS

In this study, out of 815 cases, the age range of the patient was 21–70 years. Maximum number of cases 304 (38.2%) were in the age group of 41–50 years. Second highest 256 cases (32.2%) were seen in between 31 and 40 years and least number of cases 64 (5.6%) were seen in 60–70 years [Table 1].

In the present study, 20 (2.5%) smears were unsatisfactory and 795 (97.5%) smears were satisfactory and analyzed according to Bethesda system [Table 2].

Two hundred and fifty-six (32.2%) cases were in the category of NILM and inflammatory were 462 (58%) cases. In this study, the epithelial cell abnormalities were 77 (9.6%) among these, ASCUS 33 (4.2%), LSIL 20 (2.5%), SCC 8 cases (1%), HSIL 12 (1.5%), and AGUS 4 (0.5%) in the age group of 41–50 years. Out of eight cases of SCC, 4 cases (0.5%) were seen in the age group of 41–50 years and two cases(0.2%) were seen between 31 and 40 years [Tables 3-5 and Figures 1-4]. For all cases of SCC, cervical biopsies were histologically evaluated.

The clinical presentation was PV discharge in 613 (75.2%) patients, 408 patients had lower abdominal pain (50.1%),

Table 1: Age distribution

Age distribution	No of patients	Percentage
21–30	112	14.1
31–40	256	32.2
41–50	304	38.2
51–60	79	9.9
61–70		5.6
Total	795	100

Table 2: PAP smear sample adequacy

PAP smear	No of cases	Percentage
Satisfactory for evaluation	795	97.5
Unsatisfactory	20	2.5
Total	815	100

PAP: Papanicolaou

117 patients had genital itching (14.4%), 105 patients with irregular bleeding (12.9%), five patients had post coital bleeding (0.6%), and 102 patients with utero vaginal prolapse (12.5%) [Table 6]. Most of the patients had multiple symptoms and 150 (18.4%) patients had routine screening without any symptoms.

DISCUSSION

Carcinoma of cervix is the leading cause of death in Indian women.[2] PAP smear test is an effective mass screening program for early detection of precancerous conditions to reduce the morbidity and mortality rate.

During the study period, 815 smear were evaluated. Among 815 smear 20 (2.5%) were unsatisfactory. Our study differed with Bamanikar *et al.*[3] (5.7%) Ranabhat *et al.*[4] (3.12%), Sarma *et al.*[5] (6.6%) Alta *et al.*[6] (6.3%), Laxmi *et al.*[7] (4.36%) Vaghela *et al.*[8] (4.36%) and Renuka *et al.* (3.38%).[9] Our study correlated with Ramu *et al.* (2.01%).[10]

In our study, out of 795 cases (97.5%), 256 cases (32.2%) were negative for intraepithelial malignancy with normal PAP smear. The present study differed with Renuka *et al.* (97.4%),[9] Ranabhat *et al.* (98.25%),[4] Laxmi *et al.* (95.53%),[7] and Tailor *et al.* (98.10%).[11] Our study correlated with the studies done by Ramu *et al.* (35.88%).[10]

In our study, 462 cases (58.1%) were inflammatory smears such as non-specific 166 (21%), Bacterial vaginosis 185 (23.3%), *Candida vaginalis* 57 (7.2%), and *T. vaginalis* 54 (6.8%) [Table 7 and 8]. Bacterial vaginosis was most common cervical vaginal infection in the age group of 21–50 years and lowest was 50–70 years. Zubair *et al.* reported 307 cases (55.3%).[12] Our study differed with Zubair *et al.* Adad *et al.*[13] and Zubair *et al.* documented the frequency of *Candida* and *Trichomonas* as 22.5% and 3.4%, 2.9% and 2.3%, respectively our study differed with above author studies.

In the present study, the bacterial vaginosis (23.3%) was the most common cervical-vaginal infection. Our study differed with Renuka *et al.* (12.30%),[9] Ranabhat *et al.*,[4] Vaghela *et al.*,[8] Ramu *et al.*,[10] Saha *et al.*,[14] Verma *et al.*,[15] and Zubair *et al.*[12] as 7.6%, 1.6%, 0.72%, 7.1%, 8.8%, and 2.9%.

In the present study, the *Candida* infection was 7.2% and the study differed with Renuka *et al.* (1.86%),[9] Ranabhat *et al.* (1%),[4] Ramu *et al.*[10] 3.71%, and Tailor *et al.*[11] 0.45%.

Renuka *et al.*[9] 0.22% cases of *T. vaginalis* and other studies were 0.36%, 0.77%, 3.2%, and 0.6% cases. Our study differed with above author studies.

In the present study, 256 (32.2%) cases were NILM with normal PAP smears. Our study differed with study done by Ranabhat *et al.*,[4] Laxmi *et al.*,[7] and Tailor *et al.*[11] found as 98.29%,95.53%, and 98.10%. Vaghela *et al.*,[8] Ramu *et al.*,[10] and Saha *et al.*[14] as 47%, 35.88%, and 50.6%.

In the present study, ASCUS 33 (4.2%) was most common epithelial abnormality. Mulay *et al.*[16] and Patel *et al.*[17] documented the similar findings. Hence, our study correlated with above author studies. Tailor *et al.*[11] documented high incidence of ASCUS 40.7%. Our study revealed low incidence hence differed with above author study. Lahari and Bharathi 22 (4.4%)[18] and Zubair *et al.*[12] 18 (3.2%) documented the ASCUS cases. Our study correlated with above author studies.

Our study revealed the epithelial abnormalities as LSIL and HSIL in the age group of 20–70 years. Similar findings were documented by Ranabhat *et al.*,[4] Alta *et al.*,[6] and Patel *et al.*[17] In our study, LSIL and HSIL was 2.5% and 1.5%.

Table 3: PAP smear findings

PAP smear report	No of cases	Percentage
NILM	256	32.2
Inflammatory	462	58.1
Epithelial cell abnormality	77	9.7
Total	795	100

PAP: Papanicolaou, NILM: Negative for intraepithelial lesion or malignancy

Table 4: Case wise and age wise distribution of PAP smears

Cytological diagnosis	21–30	31–40	41–50	51–60	61–70	No of cases	Percentage
NILM	26	104	101	11	14	256	32.2
Inflammatory	84	141	171	46	20	462	58.1
ASCUS	1	3	13	12	4	33	4.2
LSIL	1	2	8	6	3	20	2.5
HSIL	0	4	5	2	1	12	1.5
AGUS	0	0	2	1	1	04	1
SCC	0	2	4	1	1	08	0.5
Total	112	256	304	79	44	795	100

LSIL: Low-grade squamous intraepithelial lesion, HSIL: High-grade squamous intraepithelial lesion, ASCUS: Atypical squamous cell undetermined significance, SCC: Squamous cell carcinoma

Table 5: Distribution of cases with epithelial cell abnormalities

Cytological diagnosis	No of cases (*n*=77)	Percentage	Over all percentage (*n*=795)
ASCUS	33	42.9	4.2
LSIL	20	26	2.5
HSIL	12	15.6	1.5
AGUS	04	5.2	0.5
SCC	08	10.3	1
Total	77	100	9.6

LSIL: Low-grade squamous intraepithelial lesion, HSIL: High-grade squamous intraepithelial lesion, SCC: Squamous cell carcinoma

Table 6: Distribution of symptoms

Chief complaints	No of cases	Percentage
PV discharge	613	75.2
Lower abdominal pain	408	50.1
Genital itching	117	14.4
Abnormal irregular PV bleeding	105	12.9
Post-coital bleeding	05	0.6
Uterovaginal prolapse	102	12.5

Table 7: Distribution of inflammatory lesions

Inflammatory lesions	No of cases (*n*=462)	Percentage	Over all percentage (*n*=795)
Non specific	166	35.9	20.9
Specific	296	64.1	37.2
Total	462	100	58.1

Table 8: Distribution of specific inflammatory lesions

Specific inflammatory lesion	No of cases (*n*=296)	Percentage	Overall percentage (*n*=795)
Bacterial vaginosis	185	62.5	23.2
Candida	57	19.3	7.2
Trichomonas vaginalis	54	18.2	6.8
Total	296	100	37.2

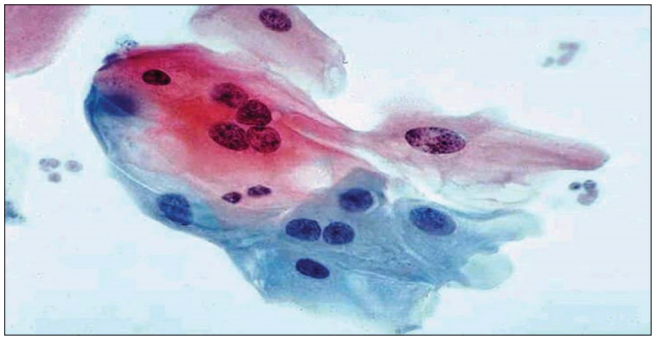

Figure 1: Ascus (400X) – atypical squamous cells of undetermined significance

Low incidence documented by Renuka *et al.*[9] and high incidence by Joshi and Thakur[19] (17% and 12%).Our study

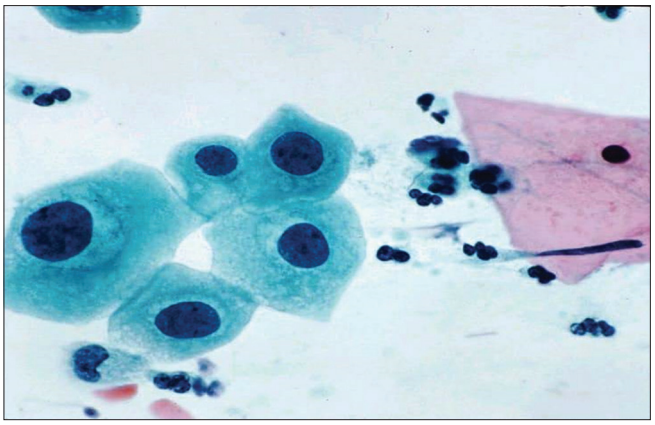

Figure 2: Lsil (400X) - low grade squamous intraepithelial lesion

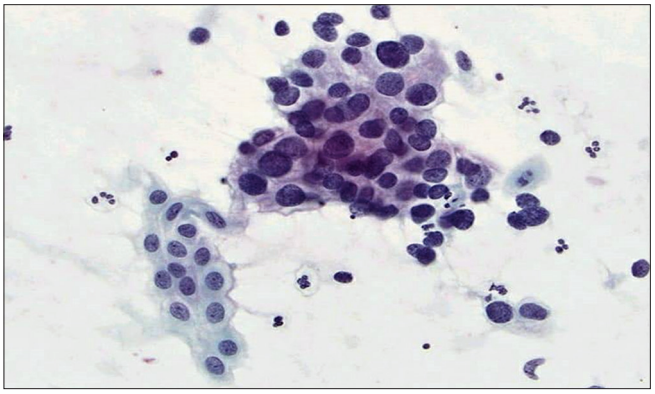

Figure 3: Hsil (400X0– high grade squamous intraepithelial lesion

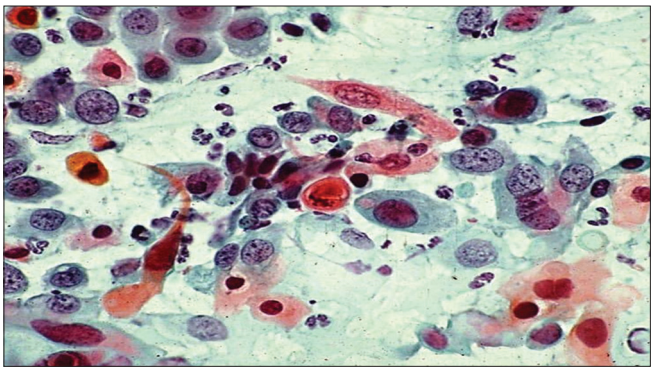

Figure 4: Squamous cell carcinoma (400X)

correlated with Renuka *et al.* and Joshi and Thakur. In the present study, LSIL and HSIL was 2.5% and 1.5%. Hence, our study correlated with Laxmi *et al.*[7] and Zubair *et al.*[12]

In our study, 8 cases (1%) of SCC was noted. Aruna and Lahari and Bharathi[18] documented 2 cases (0.4%), Zubair *et al.* (0.2%),[12] Bal *et al.* (1%),[20] Bukhari *et al.*[21] (1.4%), and Nandwani *et al.*[22] (3.5%). The present study correlated with Bal *et al.* and differed with Bukhari *et al.* and Nandwani *et al.*

In the present study, 4 cases (0.5%) of AGUS was noted in 40–70 years. Lahari and Bharathi documented 3 cases

of AGUS (0.6%) in 31–60 years. Our study differed with Lahari and Bharathi.[18] Bukhari *et al.*[21] (2012), Nandwani *et al.*[22] (2016), and Zubair *et al.*[12] (2019) documented the AGUS as 0.4%, 0.4%, and 0.9%. The study correlated with Bukhari *et al.* and Nandwani *et al.*

Lahari and Bharathi[18] documented 386 cases(77.2%) Zubair *et al.*[12] 504 cases (90.8%) of NILM. The present study (32.2%) differed with the above author studies.

Verma *et al.*[23] (2022) reported ASCUS 2 cases (1%). In the present study, 33 (4.2%) cases were documented. Our study differed with Verma *et al.*

Verma *et al.*[23] documented 11 cases of LSIL (5.5%) and 5 cases of HSIL (2.5%). In the present study, 20/2.5% and HSIL 12/1.5%. The present study correlated with the study of Verma *et al.* in HSIL cases.

CONCLUSION

Our study highlights the conventional PAP smears (with Bethesda system 2014) evaluation to identify specific infections, non-neoplastic and epithelial abnormalities. PAP smears screening test is recommended as regular test in various age group to prevent morbidity and mortality. PAP smear test maybe used in screening the inflammatory lesions to rule out the bacterial vaginosis (to eliminate the need of further vaginal sampling collection) to prevent pelvic inflammatory diseases.

REFERENCES

1. Vijaya LP, SreeGouri SR. Study and analysis of two hundred cervical PAP smears in our hospital. Int J Contemporary Med Res 2016;3:2787-9.
2. Patel MM, Pandya AN, Modi J. Cervical pap smear study and its utility in cancer screening to specify the strategy for cervical cancer control. Nat J Community Med 2011;2:49-51.
3. Bamanikar SA, Chandanwale SS, Baravkar DS, Dapkekar P. Study of cervical pap smears in a tertiary hospital. Indian Med Gaz 2014;148:250-4.
4. Ranabhat SK, Shrestha R, Tiwari M. Analysis of abnormal epithelial lesions in cervical pap smears in Mid-Western Nepal. J Pathol Nepal 2011;1:30-3.
5. Sarma U, Mahanta J, Talukdar K. Pattern of abnormal cervical cytology in women attending tertiary hospital. Int J Sci Res Pub 2012;29:1-4.
6. Alta BL, Prasad U, Shamili MS, Kumar S. Cytological patterns of cervical pap smears with histopathological correlation. Int J Res Med Sci 2015;3:1911-61.
7. Laxmi RC, Shrestha P, Pradhan B. Analysis of cervical cancer screening at Patan hospital Nepal. J Chitwan Med Coll 2018;8:1-4.
8. Vaghela BK, Vaghela VK, Santawani PM. Analysis of abnormal cervical cytology in papanicolaou smears at tertiary care center a retrospective study. Int J Biomed Adv Res 2014;5:47.
9. Tamrakar R, Ranabhat S, Shrestha M, Poudel S, Shrestha S, Khanal B, *et al*. Clinico-pathological analysis of cervical pap smear in patients attending gynecology OPD of a medical college. Eur J Med Sci 2021;3:12-7.
10. Ramu S, Bindu BJ, Murthy N. Pap smear as early diagnostic tool for cervical cancer-a life saviour. Trop J Pathol Microbiol 2018;4:22-6.
11. Tailor HJ, Patel RD, Patel PR, Bhagat VM. Study of cervical pap smear in a tertiary care hospital of South Gujarat, India. Int J Res Med Sci 2016;4:286-8.
12. Zubair AA, Kulkarni S, Preethi M. Cytomorphological patterns of cervical papanicolaou smear abnormalities based on 2014 Bethesda system in North Karnataka region. Trop J Pathol Microbiol 2019;5:251-9.
13. Adad SJ, De Lima RV, Sawan ZT, Silva ML, De Souza MA, Saldanha JC, *et al*. Frequency of *Trichomonas vaginalis*, *Candida* sp and *Gardnerella vaginalis* in cervical-vaginal smears in four different decades. Sao Paulo Med J 2001;119:200-5.
14. Saha K, Sengupta M, Mistry CJ. Cytological findings of conventional cervical papanicolaou smear in a tertiary care hospital. Glob Res Anal 2013;2:149-51.
15. Verma I, Jain V, Kaur T. Application of Bethesda system for cervical cytology in unhealthy cervix. J Clin Diagn Res 2014;8:OC26-30.
16. Mulay K, Swain M, Patra S, Gowrishankar S. A comparative study of cervical smears in an Urban hospital in India and a population-based screening program in Mauritius. Indian J Pathol Microbiol 2009;52:34-7.
17. Patel CB, Shah PC, Bhagat VM. A Role of cervical pap smear as a screening tool in diagnosis of lesions of cervix-a one-year study. Int J Med Sci Public Health 2016;5:1841-5.
18. Lahari NA, Bharathi M. Application of Bethesda system to study cytological pattern of cervical papaincolaou smear in 500 cases at a tertiary care centre. Indian Pathol Oncol 2020;7:58-62.
19. Joshi C, Kujur P, Thakur N. Correlation of Pap smear and colposcopy in relation to histopathological findings in detection of premalignant lesions of cervix in a tertiary care centre. Int J Sci Stud 2015;3:55-60.
20. Bal MS, Goyal R, Suri AK, Mohi MK. Detection of abnormal cervical cytology in papanicolaou smears. J Cytol 2012;29:45-7.
21. Bukhari MH, Saba K, Qamar S Majeed MM, Niazi S, Naeem S. Clinicopathological importance of papanicolaou smears for the diagnosis of premalignant and malignant lesions of the cervix. J Cytol 2012;29:20-5.
22. Nandwani RR, Totade S, Krishnan MG. Cytomorphological evaluation of squamous cell abnormalities observed on cervical smears in government medical college, Jabalpur, India : A five year study. Int J Res Med Sci 2016;4:794-9.
23. Verma A, Verma S, Vashist S, Attri S, Singhal A. A study on cervical cancer screening in symptomatic women using Pap smear in a tertiary care hospital in rural area of Himachal Pradesh, India Middle East Fertil Soc J 2017;22:39-42.

How to cite this article: Kumar MA, Vijetha P, Madhu G, Janaki M. Cytological Evaluation of Cervical PAP Smears in a Tertiary Care Center. Int J Sci Stud 2023;10(11):36-40.

Source of Support: Nil, **Conflicts of Interest:** None declared.