

# Laparoscopic Congenital Inguinal Hernia Repair: A Minimal Invasive Approach

Rahul Amin<sup>1</sup>, Divyang Dave<sup>2</sup>, Hardik Astik<sup>3</sup>, Tejas Patel<sup>4</sup>

<sup>1</sup>Assistant Professor, Department of General Surgery, Government Medical College, Surat, Gujarat, India, <sup>2</sup>Additional Professor, Department of General Surgery, Government Medical College, Surat, Gujarat, India, <sup>3</sup>Associate Professor, Department of General Surgery, Government Medical College, Surat, Gujarat, India, <sup>4</sup>3<sup>rd</sup> Year Resident, Department of General Surgery, Government Medical College, Surat, Gujarat, India

## Abstract

**Introduction:** Inguinal hernias in children are found in 10–50/1000 live births. Congenital inguinal hernias are due to the persistent processus vaginalis and its repair is necessary because if repair is not done, then it associated with complication such as strangulation and obstruction. So for, better management it deal with laparoscopic repair is done to avoid complication such as injury to vas deferens, post-operative pain, hematoma, wound infection, and recurrence occur with conventional open repair.

**Methods:** This present study scheduled for 50 patients for laparoscopic repair 43 males and 7 females, between age of 1 and 14 year. Both sexes are included, unilateral and bilateral as well as. One 5-mm and two 3-mm instruments were used to access the peritoneal cavity. Peritoneal incision was made. The internal inguinal ring was closed with a non-absorbable suture. Moreover, intraoperative time, post-operative pain, total hospital stay, wound infection, and testicular atrophy noted.

**Results:** The maximum number of cases were in the age group year 7–8 (20%) and the minimum number as in the 13–14 age group year (8%). The operating time from skin-to-skin ranged from 25 to 30 min (mean 28.44 min) for unilateral hernia and 35–40 min (mean 39.33 min) for bilateral hernia without conversion and no wound infection with only three cases have post op swelling and less post-operative pain without evident of recurrence.

**Conclusion:** Laparoscopic herniotomy is feasible and safe in congenital inguinal hernia. There is clear visualization of structures and vas hence less chance to injury. The recurrence rate is less in comparable to that of the traditional open approach with no wound infection, less chance of post-operative swelling, and testicular atrophy with a good cosmetic result.

**Key words:** Laparoscopy, Congenital hernia, Minimal Invasive approach

## INTRODUCTION

Congenital hernia is one of the most common surgical problems in pediatric age group. Patent processus vaginalis is the common etiological factor for congenital hernia. Inguinal hernias in children are found in 10–50/1000 live births.<sup>[1]</sup> It is higher in premature and low birth weight infants (17–30%). Inguinal hernia is common in boys (M: F = 8:1).<sup>[2]</sup> Congenital inguinal hernia requires operation, since they have risk for obstruction and incarceration. Under 1 year of age, the incarceration rate is

up to 30% which drops to 15% by 18 months age.<sup>[3]</sup> During recent years, the trend toward laparoscopic approach for hernia repair in children has been increasingly justified. The ability to detect and repair the contralateral opening of internal rings simultaneously, along with safe high ligation of the hernia sac without injury of the vas deference or the spermatic vessels, make laparoscopic approach a reliable alternative to the conventional open technique.<sup>[4]</sup> Nowadays, laparoscopic hernia repair has obvious advantages, excellent visual exposure including cosmetically better outcomes and identification of the contralateral side.<sup>[5]</sup> Suturing and closing the internal inguinal ring are the key procedures for laparoscopic hernia repair. The procedure has many variations described in the literature.<sup>[6]</sup> Intracorporeal techniques refer to the use of laparoscopic instruments to suture the internal ring and tie the knot while avoiding the injury of the vas deferens and vessels.<sup>[7]</sup> The internal ring is intracorporeally stitched using various methods such as the

Access this article online



www.ijss-sn.com

Month of Submission : 12-2022  
Month of Peer Review : 01-2023  
Month of Acceptance : 01-2023  
Month of Publishing : 02-2023

**Corresponding Author:** Dr. Rahul Amin, Assistant Professor, Department of Surgery, Government Medical College, Surat - 395 001, Gujarat, India.

purse-string, Z-type, W-type, or flip-flap suture technique<sup>[8]</sup> The aim of the study is to focus on the appeal and success of laparoscopic approaches compared to open techniques and to survey which method is likely to survive as the gold standard in the future.

## METHODS

The patients attending the department of surgery and also patients referred from other departments of combined tertiary care hospital of south Gujarat, presenting with symptoms and signs of congenital hernia are subjects for our study. Conveniently, selected 50 patients diagnosed to have congenital inguinal hernia between age of 1 and 14 year and scheduled for laparoscopic repair and both sexes are included, unilateral, and bilateral as well as with due consent from the parents. Exclusion criteria included were prematurity, age <1 year, recurrent hernia, and irreducible hernia. Intraoperative findings, post-operative complication such as pain, swelling, wound infection, recurrence, testicular atrophy, and post-operative hospital stay were observed. The patients were placed in a supine position. The operation done under general anesthesia with endotracheal intubation. An infraumbilical incision was made and creating pneumoperitoneum with CO<sub>2</sub> at 10 mmHg using a Veress needle AND then 5 mm telescope was inserted through the 5 mm umbilical port and contralateral site is also observed. Another incision was made in midclavicular line at the level of umbilicus and 3-mm working instruments were introduced. The head of the table was lowered in Trendelenburg's position in some case bowel which was seen to be passing through the ring, which was reduced with non-traumatic bowel grasper. The peritoneum was incised circumferentially at the neck of the sac. The sac was dissected away from spermatic vessels and vas deferens with take care of cord structure and avoids injury to the cord structures and the landmarks identified included the arching of fascia transversalis, iliopubic tract (IPT), and peritoneal reflection and cord structure. The IPT was approximated to the transversus arch using non-absorbable 2-0 interrupted suture to narrow the internal ring (Lytle's repair) as shown in Figure 1. Too tight approximation was avoided. Patients were routinely discharged on the first sos 2<sup>nd</sup> post-operative day. All patients were evaluated after 7 days, 1 month, 6 months, and 1 year, and then annually, when possible on out-patient basis.

## RESULTS

Total 50 patients were included in this study. The age of the patients ranged from 1 year to 14 year. They were divided into seven groups. The maximum number of cases

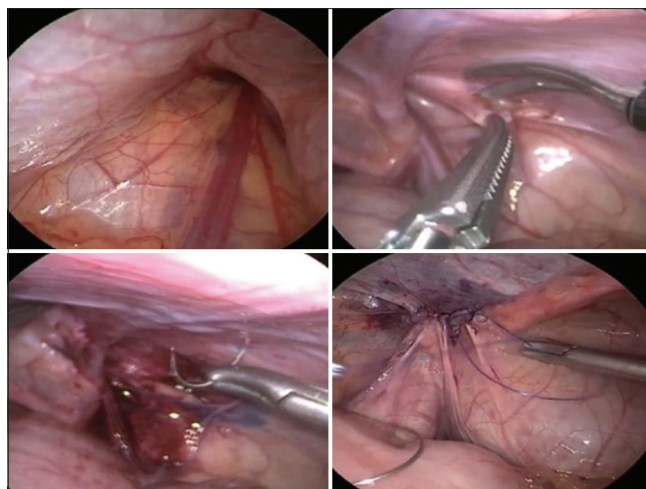


Figure 1: Laparoscopic view of Lytle's repair

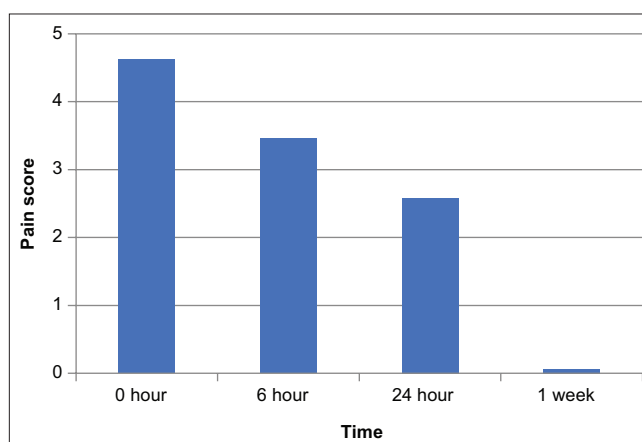


Figure 2: Distribution of post-operative mean pain score with time

were in the age group year 7–8 (20%) and the minimum number was in the 13–14 age group year (8%). The mean age is 6.6 year (SD 3.66) as shown in Table 1. In this study, of 50 children were 43 males (86%) and were seven females (14%), the male-to-female ratio being 6.1:1. Now for the Regarding the site distribution right-sided inguinal hernia found in 30 children, left-sided inguinal hernia in 17 children, and bilateral in 3 children. The operative time ranged from 25 to 38 min (mean 28.44 min) for unilateral and 36–42 min (mean 39.33 min) for bilateral hernia as shown in Table 2. Operative time is calculated from skin incision to skin closure. With experience, this time has gradually decreased. All cases were done laparoscopically without conversion and no intraoperative complications occurred like bleeding, injury of the vas, or vessels or bowel. Scrotal swelling developed in three cases (6%). It resolved by conservative treatment after 2–3 days. All patients were discharged the morning of the next day of operation except in the three cases were stay in hospital for 2 days (6%). On evaluating pain on immediate post-operative, the mean pain

**Table 1: Pre-operative evaluation**

<b>Total no of cases</b>	<b>50</b>
Sex distribution	Male=43 (86%), Female=7 (14%)
Mean age	6.6 years (SD±3.66)
Side of hernia	Right=30 (60%), Left=17 (34%), bilateral=3 (6%)

**Table 2: Intraoperative evaluation**

Parameter	Observation
Mean operative duration for	
Unilateral hernia	25–38 min (mean 28.44 min)
Bilateral hernia	36–42 min (mean 39.33 min)
Conversion	No

**Table 3: Post-operative evaluation for pain**

Pain score	Mean range	SD
0 h	4.62	±0.60
6 h	3.46	±0.50
24 h	2.58	±0.49
1 week	0.06	±0.31

**Table 4: Post-operative evaluation**

Parameter	Observation
Post-operative swelling	3 cases (6% cases)
Post-operative hospital stay	1 day (94% cases) 2 days (6% cases)
Recurrence	No

score was 4.64 and after 6 h, the mean pain score was 3.46 and it decrease with time after 24 h as shown in Figure 2 and Table 3. On follow-up the pain and scrotal swelling was present only in 1 patient after the 1 week. No wound complications occurred No testicular atrophy was noted.

## DISCUSSION

Inguinal hernia repair remains the most common operation performed by pediatric surgeons. It occurs in 0.8–4.4% of all children with higher incidence (up to 30%) in premature babies.<sup>[9]</sup> All hernias in children are likely to be due to failure of the processus vaginalis to close completely during fetal and new born development. Inguinal hernia will not close spontaneously, and due to the high risk of incarceration, surgical closure is always indicated. Most surgeons recommend repair soon after diagnosis. Conventional herniotomy is considered the gold standard treatment method for PIH.<sup>[10]</sup> In the past 2 decades, the advances of minimally invasive surgery have completely changed the management of pediatric inguinal hernias.<sup>[6,11]</sup> In 1975, the first laparoscopic surgery was done in pediatric patient to treat intestinal obstruction and it

laid milestone in development of pediatric laparoscopic surgery.<sup>[12]</sup> In 1997, the first laparoscopic repair of inguinal hernia in pediatric patient was described by El-Gohary.<sup>[13]</sup> Monteput and Esposito were first to use laparoscopy in the repair of inguinal hernia in male pediatric patient using intracorporeal purse string suture to close the ring.<sup>[14]</sup>

In 2003, Chan and Tam added intracorporeal hydrodissector to avoid vas and vessel damage.<sup>[15]</sup> Laparoscopic surgery has been acknowledged for shorter duration of hospital stay and early return to work. Small incision site, less post-operative pain, and early mobilization have made laparoscopic surgery popular among both the patients and the surgeons. In our study, we were able to discharge the patient in 1<sup>st</sup> post-operative day with full activity and controlled pain. Less post-operative pain is an advantage of laparoscopic surgery. Size of the incision is less than the open herniotomy in congenital inguinal hernia and laparoscopic repair has better cosmesis. Our study was a prospective study that included 50 patients of congenital inguinal hernia. All cases disconnection of the hernia sac was done with closure of peritoneum over internal ring with using non-absorbable 2–0 interrupted suture. The age of the patients varied from 1 year to 14 year. The maximum number of cases were in the age group of 7–8 year (20%) and the minimum number of cases were in the age group of 13–14 year (8%). There were 43 males and were seven females, the male: female ratio being 6.1:1. Among these 50 cases, 30 cases (60%) were on the right side, 17 cases (34%) on the left side, and 3 (6%) cases were bilateral. Mean operative time is 28.44 min in unilateral hernia repair and 39.33 min in bilateral hernia repair.

About 94% of the patient were discharge on the next day, and 6% required 2 days of hospital stay.

## CONCLUSION

Laparoscopic inguinal hernia repair in children can be offered, as it is safe, excellent cosmetic results, and reproducible technically easy for experienced laparoscopic surgeons.

## REFERENCES

1. Ferguson AH. Oblique inguinal hernia: Typical operation for its radical cure. *JAMA* 1889;33:6.
2. Boocock GR, Todd PJ. Inguinal hernias are common in pre-term infants. *Arch Dis Child* 1985;60:669-70.
3. Grosfeld JL. Hernias in children. In: Spitz L, Coran AG, editors. *Rob and Smith's Operative Surgery: Pediatric Surgery*. London: Chapman and Hall; 1995. p. 222-38.
4. Bharathi RS. Comparative Study of Laparoscopic Versus Conventional Surgery for Congenital Inguinal Hernia in Children [M.S. Thesis]. University of Pune; 2008.

5. Abd-Alrazek M, Alsherbiny H, Mahfouz M, Alsamahy O, Shalaby R, Shams A, *et al.* Laparoscopic pediatric inguinal hernia repair: A controlled randomized study. *J Pediatr Surg* 2017;52:1539-44.
6. Ostlie DJ, Ponsky TA. Technical options of the laparoscopic pediatric inguinal hernia repair. *J Laparoendosc Adv Surg Tech A* 2014;24:194-8.
7. Lee DY, Baik YH, Kwak BS, Oh MG, Choi WY. A purse-string suture at the level of internal inguinal ring, taking only the peritoneum leaving the distal sac: Is it enough for inguinal hernia in pediatric patients? *Hernia* 2015;19:607-10.
8. Schier F. Laparoscopic herniorrhaphy in girls. *J Pediatr Surg* 1998;33:1495-7.
9. Kumar A, Ramakrishnan T. Single port laparoscopic repair of paediatric inguinal hernias: Our experience at a secondary care centre. *J. Min Access Surg* 2013;9:7-12.
10. Schier F, Danzer E, Bondartschuk M. Incidence of contralateral patent processus vaginalis in children with inguinal hernia. *J Pediatr Surg* 2001;36:1561-3.
11. Esposito C, Escolino M, Farina A, Settini A. Two history of decade of laparoscopic pediatric inguinal hernia repair. *J Laparoendosc Adv Surg Tech A* 2014;24:669-70.
12. Becmeur F. Videosurgery-the second generation. *J Pediatr Surg* 2011;46:275-9.
13. El Gohary MA. Laparoscopic ligation of inguinal hernia in girls. *Pediatr Endosurg Innov Technol* 1997;1:185-8.
14. Montupet P, Esposito C. Laparoscopic treatment of congenital inguinal hernia in children. *J Pediatr Surg* 1999;34:420-3.
15. Chan KL, Tam PKH. A safe laparoscopic technique for the repair of inguinal hernia in boys. *J Am Coll Surg* 2003;196:987-89.

**How to cite this article:** Amin R, Dave D, Astik H, Patel T. Laparoscopic Congenital Inguinal Hernia Repair: A Minimal Invasive Approach. *Int J Sci Stud* 2023;10(11):46-49.

**Source of Support:** Nil, **Conflicts of Interest:** None declared.