Print ISSN: 2321-6379
Online ISSN: 2321-595X

Original Article

Worth of Laparoscopy in Undiagnosed Chronic Abdominal Pain: A Tertiary Care Center Study

Vibhuti Bhushan[1], Deepak Pankaj[2], Nitesh Kumar[2], Sweta Muni[3], Bipin Kumar[4], Nitesh[5], Priyanka Chaubey[5], Abhay Kumar[5]

[1]Additional Professor, Department of General Surgery, Indira Gandhi Institute of Medical Sciences, Patna, Bihar, India, [2]Assistant Professor, Department of General Surgery, Indira Gandhi Institute of Medical Sciences, Patna, Bihar, India, [3]Assistant Professor, Department of Microbiology, Indira Gandhi Institute of Medical Sciences, Patna, Bihar, India, [4]Professor, Department of Pathology, Indira Gandhi Institute of Medical Sciences, Patna, Bihar, India, [5]Senior Resident, Department of General Surgery, Indira Gandhi Institute of Medical Sciences, Patna, Bihar, India

Abstract

Introduction: Chronic abdominal pain which is difficult to diagnose initially not only encumbers the patient but it also affects their daily routine, leading to physical and psychological disability, here comes the role of diagnostic laparoscopy which proves to be beneficial aiding in diagnosing most of these cases. Hence, the aim was to evaluate the diagnostic value of laparoscopy in cases with chronic abdominal pain.

Materials and Methods: This study was done in the Department of General Surgery at Indira Gandhi Institute of Medical sciences, Patna, Bihar, from July 2019 to March 2020 in 40 patients. Prior Institutional Ethical Committee approval was also obtained for this study.

Results: Out of 40 patients included in this study, maximum number of patients were females. Male-to-female ratio was 1:1.4. The maximum number of patients were in the age group of 21–40 years (60%). Maximum patients 45% (n = 18) had complaint of pain in the right lower quadrant of abdomen. The most common finding during diagnostic laparoscopy was found to be pathology in the appendix accounting for 27.5% of cases (11/40).

Conclusion: Diagnostic laparoscopy is a safe and effective tool to establish the etiology of chronic abdominal pain and allows for appropriate interventions. It can serve as a time saving and cost-effective implement for these patients.

Key words: Abdominal pain, Appendicitis, Laparoscopy, Uncertain diagnosis

INTRODUCTION

Abdominal pain of chronic type is one of the most common disorders, which comes to the surgeon and physician in routine practice. The concern for patient is to have an etiology with chronic abdominal pain even after all the work up and diagnostic tests have been performed leading to their condition.[1] These patients are in good numbers with an estimate in the range of 30–40% as per various studies.[2] The pain in these people can be so engrossing and obsessive that it begins to impact the quality of life socially, physically, mentally, and economically becoming the main center of their life. These types of patients with pain in abdomen have been also referred to as undiagnosed chronic abdominal pain and their evaluation remains a daunting task.[3] These undiagnosed chronic abdominal pain imitate variety of abdominal conditions associated with pain and possess a conundrum to the operating surgeon for an intervention and possibility of diagnostic laparoscopy and proceed further. Since its emergence to the present days, laparoscopy has a comprehensive spectrum, it not only assists in diagnosis but also in contemporary surgical practice and the procedure has taken over for most of the interventions. It helps in avoiding unwarranted laparotomy and provides diagnosis to any planned surgery.[4,5] Although laparoscopy has gained popularity but has its own merits and demerits, so the role of laparoscopy is not free of controversies in patient with ill-defined abdominal pain. Most of the patients of pelvic pain have been treated with

Access this article online

www.ijss-sn.com

Month of Submission : 04-2020
Month of Peer Review : 05-2020
Month of Acceptance : 05-2020
Month of Publishing : 06-2020

Corresponding Author: Dr. Deepak Pankaj, Shanti Niwas, Amba Vihar Colony, Ambedkar Path, Near Mahima Mandir, Rukanpura, Patna - 800 014, Bihar, India.

diagnostic laparoscopy followed by adhesiolysis which has gained acceptance in gynecological practice but not very well practiced in mainstream surgical literature and practice remains slow.[6,7] The burden of abdominal pain is shared by young females in reproductive age group who possess variety of conditions leading to lower abdominal and pelvic pain and inconsistent features of appendicitis where the worth of diagnostic laparoscopy comes into picture. Diagnosing with laparoscopy not only provides a better assessment for pain in these group of patients but also prevents negative appendicectomy.[8] Cases of abdominal tuberculosis (TB) present with very vague symptoms and are nightmare for the surgeon in clinical practice even after an extensive work-up with a series of tests. This results in starting most patients with empirical treatment even without proper evidence of the disease. Diagnostic laparoscopy in these cases can detect nodules in the peritoneal cavity and biopsy can be taken from various areas which would confirm the diagnosis. The result would avoid unnecessary overusage of anti-Koch's drugs and subsequent resistance and drug-related side effects faced by patients.[9] Variety of abdominal conditions can be diagnosed with laparoscopy as stated by other authors and therapeutic interventions can be planned accordingly.[10] Besides diagnosis, sometimes, the underlying etiology can itself be treated in the same sitting also known as therapeutic laparoscopy.[11] A simple dictum is that diagnosis should precede treatment whenever possible, so this way laparoscopic diagnosis will not only be time saving and cost effective but will serve as an important tool in avoiding unnecessary surgeries for most cases.

Aims and Objectives of the Study

The objectives of the study were as follows:

1. To evaluate whether diagnostic value of laparoscopy is worth in cases with new onset and chronic abdominal pain
2. Providing a much safe, time saving, and effectual accompaniment to non-surgical diagnostic modalities for establishing a conclusive diagnosis
3. As an adjunct in patients where conventional methods of investigations have failed to elicit a certain cause.

MATERIALS AND METHODS

This prospective observational study was carried out in the Department of General Surgery at Indira Gandhi Institute of Medical Sciences, Patna, from July 2019 to March 2020 in 40 patients. Approval from the Institute's Ethical Committee was duly obtained.

Inclusion Criteria

All patients of either sex or age, who will present with vague abdominal pain with new onset or chronic, admitted through emergency or outpatient department in whom history, clinical examination and routine diagnostic investigations fail to make a definite diagnosis, were included in the study.

Exclusion Criteria

The following criteria were excluded from the study:

1. Severe/decompensated cardiopulmonary failure
2. Acute myocardial infarction
3. Severe peritonitis
4. Infection of abdominal wall
5. Severe coagulopathy
6. Patient unfit for general anesthesia.

All patients in this study were subjected to complete preoperative evaluation in the form of medical history and clinical examination and investigations. The patients were be placed in supine position and operated under general anesthesia. In cases of previous upper midline incision or suspected massive intra-abdominal adhesions, the Veress needle was introduced through the abdominal wall in an area with no scars, most often in the left upper quadrant of the abdomen. After creating pneumoperitoneum, a standard three trocar techniques was used (10-mm through umbilical trocar and two 5 mm lateral trocars). A fourth 5 mm trocar was inserted in a few cases. The whole abdominal cavity was inspected carefully starting from the liver, gallbladder, anterior surface of the stomach, and spleen. Fine smooth graspers were used to safely touch the structures and elevating them for further inspection. The small bowel was examined by atraumatic graspers from the ligament of Treitz to the ileocecal valve. The colon including the appendix was inspected in same way as the small bowel. In females, the uterus, adnexa, and pouch of Douglas were inspected and the amount of fluid, color, and its site was noted. Specimen was sent for histopathological diagnosis and therapeutic intervention if needed was done. Post-operative hospital stay was recorded and the patient was followed postoperatively at regular intervals.

RESULTS

Out of 40 patients included in this study, maximum number of patients were female who accounted for 57.5% (23/40) of cases and the rest were male accounting for 27.5% (17/40) of cases. Male-to-female ratio was 1:1.4. The studied patients were in the age group ranging from 20 to 65 years, with a mean age of 32 years. The maximum number of patients were in the age group of 21–40 years (60%). The least number of patients were in the age group of 60 years and above with 12.5% of cases. Maximum patients 45% (n = 18) had complaint of pain in the right lower quadrant of abdomen followed by pain in the left lower quadrant

22.5% ($n = 9$). Other sites of pain were right upper quadrant, left upper quadrant, and periumbilical area. Some patients 5% ($n = 2$) had diffuse pain all over the abdomen [Table 1].

Seven patients in this study 17.5% (7/40) had a history of previous surgeries with three patients having a history of hysterectomy and two patients having a history of cholecystectomy and appendectomy each.

The most common finding during diagnostic laparoscopy was found to be pathology in the appendix 27.5% ($n = 11$), in which 10 patients had appendicitis while one patient had sealed appendicular perforation. The second most common finding was bands and adhesions in 20% of cases ($n = 8$). No diagnosis was established in 7.5% of cases ($n = 3$). Least common findings in present study were endometriosis and mesenteric lymphadenitis in 5% of cases [Table 2]. Some of the findings seen during laparoscopic procedure that could be depicted in the picture were omental node being taken for biopsy [Figure 1], ascitic fluid with peritoneal tubercles [Figure 2] and small bowel adhesions. [Figure 3].

DISCUSSION

Chronic abdominal pain is a frequent symptom and if not diagnosed after a series of investigations, possesses a challenge to the treating doctor, here comes the role of laparoscopy which can diagnose more than 90% of these patients in clinical practice.[12] In the present study also, diagnosis was done in 92.5% of cases (37/40). Early diagnosis is the key to any access toward the treatment of the disease, laparoscopy not only aims this but also reduces hospital stays, further readmissions providing mental and financial benefit to the patient.[13] Pathology

Table 1: Characteristics of studied patients

Characters	Value (%)
Age (years) mean (range)	32 (20–65)
Male	17 (42.5)
Female	23 (57.5)
Duration of pain (months) mean (range)	6 (3–10)
Site of pain	
Right lower quadrant	18 (45)
Right upper quadrant	2 (5)
Left lower quadrant	9 (22.5)
Left upper quadrant	5 (12.5)
Diffuse	2 (5)
Periumbilical	4 (10)

Table 2: Laparoscopic findings

Findings	Number of patients (n=40)	Percentage
Appendicular pathology	11	27.5
Bands/adhesions	8	20
Salpingitis with free fluid in pouch of Douglas	6	15
Koch's abdomen	5	12.5
Peritoneal omental deposits (disseminated carcinomatosis)	3	7.5
Inconclusive (no diagnosis)	3	7.5
Endometriosis	2	5
Mesenteric lymphadenitis (inflammatory)	2	5

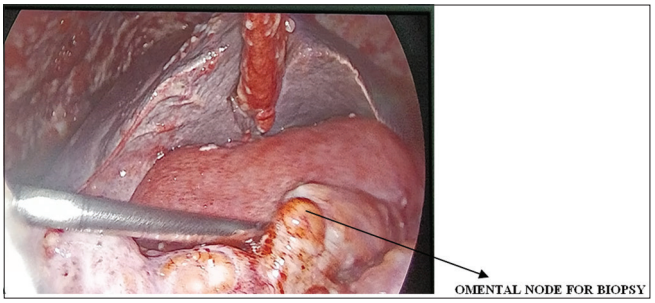

Figure 1: Omental node being taken for biopsy

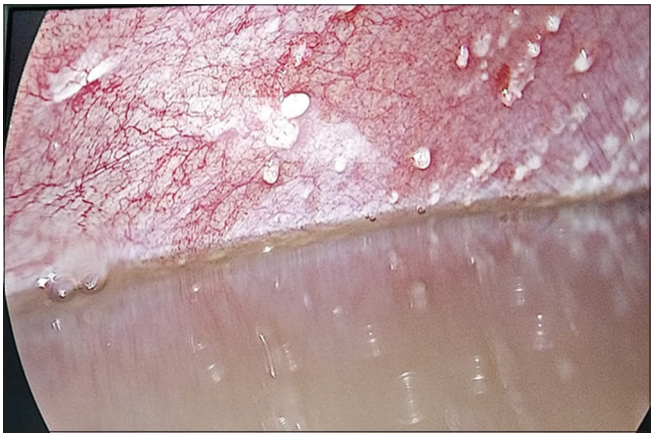

Figure 2: Laparoscopic image showing parietal peritoneum studded with tubercles and ascitic fluid

Figure 3: Laparoscopic image showing small bowel adhesions

of the appendix was one of the most common findings in our study. This is also in accordance with other studies where the sensitivity and specificity of laparoscopic appendectomy in patients who were posted for diagnosis were higher than of computed tomography scan (98% vs. 94%). This states the value of laparoscopy in achieving early and correct diagnosis of appendicitis and thus reducing the incidence of perforated appendicitis.[14] Abdominal TB is another condition which is known for its varied and confusing symptoms and can mimic between both inflammatory and carcinomatous pathology, and there is hardly any investigation that can be completely 100% correct for abdominal TB.[15,16] Laparoscopic examination of abdomen and examination of suspected nodules, deposits, and ascitic fluid for TB bacilli can be of great help in these cases. Although the cases of TB are high in a developing country like India, the incidence of abdominal TB is comparatively low in the present study. This may be due to the fact that many patients are treated empirically with antitubercular drug with no proper evidence of the disease. Laparoscopic diagnosis would avoid unnecessary overusage of anti-Koch's drugs and subsequent resistance and drug-related side effects regularly faced by patients. Many researchers in their studies done in the past have found out abdominal adhesions and appendicitis as the key diagnosis in laparoscopic procedures which is quite synonymous with the present study.[10] The pain in these adhesions may due to restricted mobility and distension of the organ particularly bowel.[17] Sometimes, conversion may be required to open procedures in these types of cases due to extensive bowel adhesions not amendable to laparoscopy. Diagnostic laparoscopy bears great significance in gynecological practice with main indications being infertility and chronic pelvic pain.[18] Cases of pelvic inflammatory diseases and endometriosis, relatively difficult to diagnose in ultrasound, were the main finding in some cases. Laparoscopy should be the main modality of diagnosing cases of chronic abdominal pain in females. The additional worth of doing laparoscopy can be in the fact that any therapeutic or definitive procedure can be done in the same sitting thus saving time.

CONCLUSION

Diagnostic laparoscopy can identify abnormal findings and improve the outcome in patients with chronic abdominal pain. However, it should be considered only after a complete diagnostic evaluation has been carried out. It allows the effective surgical treatment of many conditions encountered at the time of diagnostic laparoscopy.

Limitations

All the patients underwent anesthesia in this study, thus leading to unintentional associated risks. Of all the patients in this study, diagnosis with laparoscopy was not established in three patients. Various pathologies present in the retroperitoneum causing pain in abdomen are relatively difficult to diagnose with diagnostic laparoscopy.

REFERENCES

1. El-Labban GM, Hokkam EM. The efficacy of laparoscopy in the diagnosis and management of chronic abdominal pain. J Minim Access Surg 2010;6:95-9.
2. Ahmad MM, Dar HM, Waseem M, Wani H, Irfan N, Jeelani A. Role of laparoscopy in nonspecific abdominal pain. Saudi Surg J 2014;2:71-4.
3. Anbarasu S, Ponnusamy S, Kannan I. Diagnostic and therapeutic role of laparoscopy in chronic abdominal pain: A retrospective study in a rural tertiary care teaching hospital. Int J Res Med Sci 2018;6:2256-9.
4. Berci G. Elective and emergent laparoscopy. World J Surg 1993;17:8-15.
5. Easter DW, Cuschieri A, Nathanson LK, Lavelle-Jones M. The utility of diagnostic laparoscopy for abdominal disorders. Audit of 120 patients. Arch Surg 1992;127:379-83.
6. Klingensmith ME, Soybel DI, Brooks DC. Laparoscopy for chronic abdominal pain. Surg Endosc 1996;10:1085-7.
7. Schietroma M, Carlei F, Altilia F, Carloni A, Mattucci S, Agnifili A, *et al*. The role of laparoscopic adhesiolysis in chronic abdominal pain. Minerva Chir 2001;56:461-5.
8. Lippert V, Zaage J, Pilz F. Diagnostic laparoscopy and laparoscopic appendectomy in the diagnosis and therapy concept of abdominal pain of unknown origin. Zentralbl Chir 1998;123 Suppl 4:46-9.
9. Arya PK, Gaur KJ. Laparoscopy: A tool in diagnosis of lower abdominal pain. Indian J Surg 2004;66:216-20.
10. Rathod A, Agrawal A, Mehera B. Role of laparoscopy in chronic and recurrent abdominal pain-rural area experience. Indian J Surg 2015;77:S1018-22.
11. Parray MY, Malik AA, Hassan Y, Wani IA, Wani MA, Bashir WS. The role of diagnostic laparoscopy in the era of modern imaging techniques: A study from a single center. Int Surg J 2019;6:1578-83.
12. Amandeep SN, Ashvind B, Amit M. Role of diagnostic laparoscopy in chronic abdominal conditions with uncertain diagnosis. Niger J Surg 2014;20:75-8.
13. Nehar UC, Shreya NC, Satish DD, Rajiv KS, Amol ML, Ankita AL. Role of diagnostic laparoscopy in nonspecific abdominal pain (NSAP). Int J Anat Radiol Surg 2019;8:5-8.
14. Bachar I, Perry ZH, Dukhno L, Mizrahi S, Kirshtein B. Diagnostic value of laparoscopy, abdominal computed tomography, and ultrasonography in acute appendicitis. J Laparoendosc Adv Surg Tech A 2013;23:982-9.
15. Jadvar H, Mindelzun RE, Olcott EW, Levitt DB. Still the great mimicker: Abdominal tuberculosis. Am J Roentgenol 1997;168:1455-60.
16. Navaneethan U, Cherian JV, Prabhu R, Venkataraman J. Distinguishing tuberculosis and Crohn's disease in developing countries: How certain can you be of the diagnosis? Saudi J Gastroenterol 2009;15:142-4.
17. Swank DJ, Van Erp WF, Repelaer Van Driel OJ, Hop WC, Bonjer HJ, Jeekel H. A prospective analysis of predictive factors on the results of laparoscopic adhesiolysis in patients with chronic abdominal pain. Surg Laparosc Endosc 2003;13:88-94.
18. Raquel T, Cristina LB, Daniela AY. The role of diagnostic laparoscopy in gynecology. Sao Paulo Med J 2016;134:70-3.

How to cite this article: Bhushan V, Pankaj D, Kumar N, Muni S, Kumar B, Nitesh, Chaubey P, Kumar A. Worth of Laparoscopy in Undiagnosed Chronic Abdominal Pain: A Tertiary Care Center Study. Int J Sci Stud 2020;8(3):48-51.

Source of Support: Nil, **Conflicts of Interest:** None declared.