Print ISSN: 2321-6379
Online ISSN: 2321-595X

Original Article

Limb Reconstruction Using Masquelet Technique in the Treatment of Post-traumatic Compound Tibial Fractures with Bone Loss

P Kingsly[1], Gowtham Ram[2], Hari Hara Subramanian[2]

[1]Assitant Professor, Department of Orthopaedics, Institute of Orthopaedics and Traumatology, Madras Medical College, Rajiv Gandhi Government General Hospital, Chennai, Tamil Nadu, India, [2]Post Graduate, Department of Orthopaedics, Institute of Orthopaedics and Traumatology, Madras Medical College, Rajiv Gandhi Government General Hospital, Chennai, Tamil Nadu, India

Abstract

Introduction: Traumatic segmental bone defects of leg are difficult problem to manage with significant long-term morbidity. Historically, due to difficulty in managing segmental bone defects, amputation was the preferred treatment. Later over the last half-century, limb salvage was done using various techniques such as vascularized fibular grafts, acute limb shortening, external fixator application, and filling the defect with autograft or allograft. More recently, Masquelet described the use of cement spacer application within this defect and staged bone grafting within the induced biomembrane formed around the spacer as a potential treatment strategy to manage these bone defects.

Method: This study describes the clinical, radiological, and functional outcome in 20 patients with traumatic bone loss of up to 5 cm managed using Masquelet technique.

Results: The outcome was analyzed using Association for the study and application of methods of ilizarov (ASAMI) score which showed excellent results in 10 patients, good in 5 patients, fair in 2 patients, and poor in 3 patients.

Conclusion: We conclude that the induced membrane technique can be a valuable addition to the armamentarium of limb reconstruction procedures in patients with small bone defects with or without soft tissue injury.

Key words: Antibiotic cement spacer, Bone grafting, External fixator, Induced biomembrane, Limb salvage, Masquelet technique, Soft tissue reconstruction, Traumatic segmental bone defects

INTRODUCTION

Reconstruction of traumatic segmental bone loss that occurs after compound tibial fractures is a major challenge in orthopedic practice due to the risk of infection, prolonged healing time, and no guarantee of a satisfactory clinical outcome with physical and psychological stress to the patient.[1] Historically in the early 20th century, due to these problems involved in limb salvage surgery and also lack of technically demanding procedures involving other specialties, these patients were treated by amputation. Modern techniques of fracture stabilization and soft tissue reconstruction in more severely injured limb with bone loss can now be salvaged in majority of the patients. The French technique of bone grafting within the induced membrane, otherwise known as Masquelet technique, offers a viable alternative for limb reconstruction with minimal complications.[2,3] Our study was intended to review the clinical, radiological, and functional outcome in the reconstruction of compound traumatic tibial bone defects managed by Masquelet technique.

Access this article online

www.ijss-sn.com

Month of Submission : 10-2019
Month of Peer Review : 10-2019
Month of Acceptance : 10-2019
Month of Publishing : 11-2019

MATERIALS AND METHODS

Patients with compound traumatic tibial bone defects were treated by the induced membrane technique in our Institute of Orthopaedics and Traumatology, Rajiv Gandhi Government General Hospital between August 2016 and

Corresponding Author: Dr. P Kingsly, Institute of Orthopaedics and Traumatology, Rajiv Gandhi Government General Hospital, No 3, EVR Periyar Salai, Park Town, Chennai - 600 003, Tamil Nadu, India.

August 2019. The patients included in our study were between 18 and 60 years of age with traumatic compound tibial fractures with bone defects in the diaphysis or metaphysis of size <5 cm with or without soft tissue defect. The exclusion criteria included diaphyseal or metaphyseal defects size more than 5 cm, articular defects, patients with bone defects of etiology other than trauma, patients with persistent infection even after cement spacer application, patients with neurovascular injury, and patients with unreconstructable limb. This study was performed after obtaining Institute's ethical committee approval and patients informed consent before the surgery.

Procedure

Patients with reconstructable limb were evaluated for injury type, size of the soft tissue, and bone defect. In patients with compound fractures, opinion was obtained from plastic and vascular surgeons in the emergency department. Poor prognostic signs for limb salvage were major soft tissue injury, an ischemic time in excess of 6 h, the presence of significant neurological deficit, especially of the tibial nerve, and other major organ injuries. Salvageable and reconstructable limbs were treated in the emergency theatre by surgical debridement to ensure complete removal of contaminated soft tissue and devitalized bone if necessary. An intravenous broad-spectrum antibiotic was given to all patients in the emergency room. Skeletal stabilization was achieved by using external fixator. All compound fractures with bone defects after debridement were filled with antibiotic impregnated cemented spacer [Figure 1]. We preferred to use 2 g vancomycin or gentamicin per 40 g of cement. The cement spacer was kept for a period of 6–8 weeks. Cultures were taken for all patients at the time of debridements and postoperatively if there was any discharge. Antibiotics were given according to the culture and sensitivity report.

The second stage of bone grafting was performed 4–8 weeks after the first surgery. This allowed the formation of biomembrane. The defect was approached through the previous incision down to the encapsulating cement spacer. Once exposed, the cement spacer was removed and the defect was filled with cancellous bone graft harvested from the iliac crest [Figure 2]. An intravenous antibiotic for 2 weeks according to the previous culture and sensitivity report and oral antibiotics for another 3 weeks or until culture report was negative. Patients were followed up clinically and radiologically for graft integration every 6 weeks. Non-weight bearing walking was allowed until radiological signs of union. Partial weight-bearing with the external fixator insitu was continued until radiological consolidation of the graft. Once solid union was achieved and external fixator was removed after dynamization. Functional assessment was measured using ASAMI scoring system.

RESULTS

A total of 20 patients were identified within the time period. All 20 patients were males with average age of 35.5 years (range 18–55 years). In our study, the mode of injury was road traffic accident in sixteen patients and fall from height in four patients. The bone defect size varied from 2 cm to 5 cm (bone defect <3 cm in 13 patients and 3–5 cm bone defect in 7 patients). Grade IIIa compound fracture in 8 patients and Grade IIIb in 12 patients, among them in 4 patients defect was in the proximal tibia, middle third in 11 patients and distal third in 5 patients. The average time between injury to Stage I procedure was 30 days (range 10–90 days) and time duration between Stage I and Stage II was 43.8 days (range 32–56 days). The soft tissue injuries were managed with primary closure of the skin in 2 patients, split skin grafting in 6 patients, and fasciocutaneous flap in 12 patients. The average complete bony union time was 8 months (range 6–12 months). The external fixator was removed after dynamization in all patients except in two patients, the fixator was removed earlier. There was persistent infection in 1 case, non-union in 2 cases, malalignment in 4 cases, and limb shortening of 1 cm in 5 cases. The outcome was analyzed using ASAMI score which showed excellent results in 10 patients, good in 5 patients, fair in 2 patients, and poor in 3 patients.

DISCUSSION

Management of bone defects has received great attention recently by scientific and clinical communities. There are various techniques available in the treatment of compound tibial fractures with bone loss such as circular ring fixators and limb reconstruction systems using the distraction

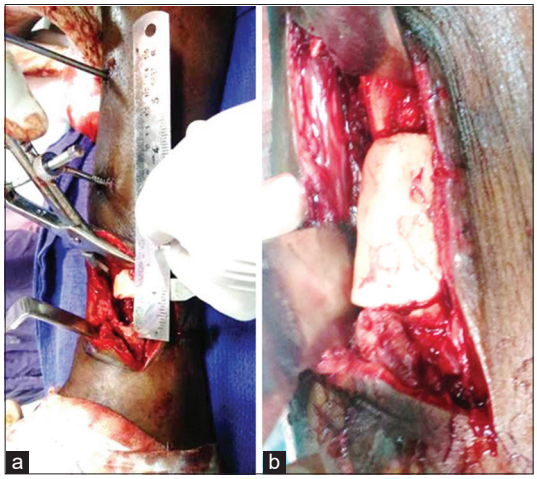

Figure 1: (a) Demonstrating defect size measurement after excising all infected and necrotic bone. (b) Intraoperative photograph showing cement spacer application between the bone defect

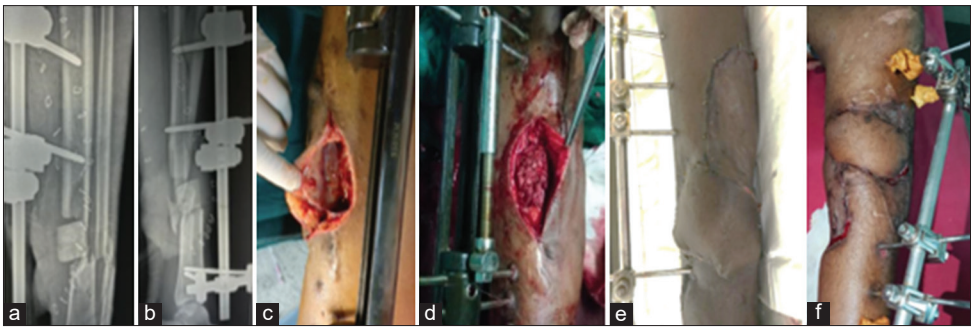

Figure 2: (a and b) X-ray showing antibiotic spacer, (c) intraoperative photograph demonstrating the mature biomembrane of 1 mm thickness, (d) intraoperative photograph showing Stage II surgery – filling the defect with morselized iliac crest autografts, (e) shows inferomedially based transposition fasciocutaneous flap done for soft tissue defect in lower leg, (f) shows superiorly based transposition flap done for middle third soft tissue defect in leg

osteogenesis principle described by Ilizarov and Ledyaev,[4] but this requires specialized training. In some series, the authors have used vascularized fibula graft for large bone defects with varying results, it is limited by pedicle length and it involves microsurgical anastomosis.[5] Recently, the induced membrane is a relatively newer method described by Pelissier *et al.*,[2,3] which is a two-staged technique for reconstruction of bone defect. It is a simple and straight forward procedure with good results. Only few studies have used this technique in the treatment of posttraumatic bone defects until now.[6-8]

Recent literature has shown that this biomembrane can be 0.5–1 mm thick.[3] Pelissier *et al.* concluded that these membranes (pseudo-periosteum) possessed a rich capillary network and enriched with growth factors (vascular endothelial growth factor and transforming growth factor beta-1) and osteoinductive factors (bone morphogenetic protein-2). Immunohistochemical studies on induced membranes in a sheep model by Viateau *et al.*[9] established the presence of cells expressing transcription factor core-binding factor alpha 1 and type-1 collagen-rich extracellular matrix. With the above characteristics, the membrane prevents resorption of bone graft, acts as a barrier to outward diffusion of growth and osteoinductive factors, and it provides a source of osteoprogenitor cells and vascular cells supporting revascularization and osseous consolidation.[2]

Originally, the bone cement used by many authors was without antibiotic impregnation. In traumatic wounds, antibiotic impregnated cement beads or spacers are often used for local antibiotic administration to the soft tissue bed in high concentration without systemic side effects. In addition, the advantages of inserting such a spacer include maintaining a well-defined void to allow for later placement of bone graft, providing structural support, offloading the implant, inducing the formation of biomembranes, and increased concentration of antibiotics locally.[10] We used antibiotic impregnated cement as previously done by Wong *et al.* in his study patients.

It was found that the 1-month-old membrane has higher osteogenesis-improving capabilities compared to the 2-month-old membrane. Hence, the study concluded that optimal time for performing second-stage surgery may be within a month after implantation of foreign material (cement spacer).[11]

In all our patients, the presence of induced membrane was visualized at the fracture gap on removal of the cement spacer as described by Woon *et al.*[12] We think that at the time of trauma some residual native periosteum is left uninjured so that periosteum along with the biomembrane helps in regeneration of this new bone.

There was persistent infection in 1 case, non-union in 2 cases, malalignment in 4 cases, and limb shortening of 1 cm in 5 patients. One patient underwent amputation for persistent infection in the distal bone defect site and the soft tissue coverage using flap also failed. The 2 patients with nonunion were subjected for ilizarov frames and limb shortening was managed with heel rise.

The outcomes were analyzed using ASAMI score which showed excellent results in 10 patients, good in 5 patients, fair in 2 patients, and poor in 3 patients. The results in our study were comparable with the study done by Karger *et al.*[6] He reported his experience with the Masquelet technique in the treatment of chronic posttraumatic diaphyseal long bone defect with 90% success rate.

CONCLUSION

The induced membrane technique can be a valuable addition to the armamentarium of limb reconstruction procedures in patients with medium size bone defects with or without soft tissue loss. However, this method of treatment requires long consolidation time and prolonged non-weight-bearing compared to other treatment options. This technique does not require specialized equipment

and can be performed easily in lower trauma centers by surgeons with varying experience and capabilities. We also think that at the time of trauma some residual native periosteum is left uninjured so that periosteum along with the biomembrane helps in regeneration of this new bone.

ACKNOWLEDGMENT

The authors declare that they have no conflict of interests, any grant, or financial profit related to this clinical study.

REFERENCES

1. Papakostidis C, Kanakaris NK, Pretel J, Faour O, Morell DJ, Giannoudis PV, *et al.* Prevalence of complications of open tibial shaft fractures stratified as per the gustilo-anderson classification. Injury 2011;42:1408-15.
2. Pelissier P, Martin D, Baudet J, Lepreux S, Masquelet AC. Behaviour of cancellous bone graft placed in induced membranes. Br J Plast Surg 2002;55:596-8.
3. Pelissier P, Masquelet AC, Bareille R, Pelissier SM, Amedee J. Induced membranes secrete growth factors including vascular and osteoinductive factors and could stimulate bone regeneration. J Orthop Res 2004;22:73-9.
4. Ilizarov GA, Ledyaev VI. The replacement of long tubular bone defects by lengthening distraction osteotomy of one of the fragments 1969. Clin Orthop Relat Res 1992;280:7-10.
5. Pederson WC, Person DW. Long bone reconstruction with vascularized bone grafts. Orthop Clin North Am 2007;38:23-35.
6. Karger C, Kishi T, Schneider L, Fitoussi F, Masquelet AC, French Society of Orthopaedic Surgery and Traumatology (SoFCOT). *et al.* Treatment of posttraumatic bone defects by the induced membrane technique. Orthop Traumatol Surg Res 2012;98:97-102.
7. Gupta G, Ahmad S, Zahid M, Khan AH, Sherwani MK, Khan AQ, *et al.* Management of traumatic tibial diaphyseal bone defect by "induced-membrane technique". Indian J Orthop 2016;50:290-6.
8. El-Alfy BS, Ali AM. Management of segmental skeletal defects by the induced membrane technique. Indian J Orthop 2015;49:643-8.
9. Viateau V, Guillemin G, Calando Y, Logeart D, Oudina K, Sedel L, *et al.* Induction of a barrier membrane to facilitate reconstruction of massive segmental diaphyseal bone defects: An ovine model. Vet Surg 2006;35:445-52.
10. Wong TM, Lau TW, Li X, Fang C, Yeung K, Leung F. Masquelet technique for treatment of posttraumatic bone defects. Sci world J 2014;2014:1-5.
11. Aho OM, Lehenkari P, Ristiniemi J, Lehtonen S, Risteli J, Leskelä HV, *et al.* The mechanism of action of induced membranes in bone repair. J Bone Joint Surg Am 2013;95:597-604.
12. Woon CY, Chong KW, Wong MK. Induced membranes a staged technique of bone-grafting for segmental bone loss: A report of two cases and a literature review. J Bone Joint Surg Am 2010;92:196-201.

How to cite this article: Kingsly P, Ram G, Subramanian HH. Limb Reconstruction Using Masquelet Technique in the Treatment of Post-traumatic Compound Tibial Fractures with Bone Loss. Int J Sci Stud 2019;7(8):72-76.

Source of Support: Nil, **Conflict of Interest:** None declared.

CASE ILLUSTRATION

A 19-year-old male with the diagnosis of Grade IIIb compound fracture both bones right leg and bone defect size 3 cm

PRE-OPERATIVE

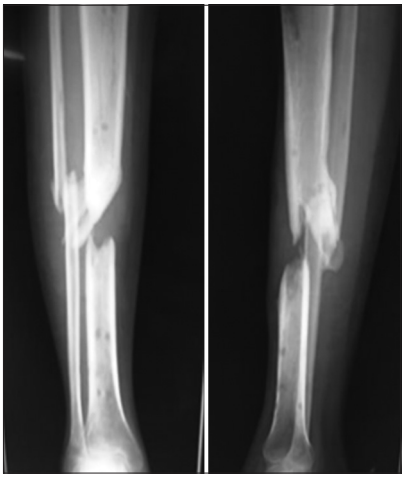

POST-OPEARTIVE

Post-stage I

Post-stage I

12 weeks post-operative

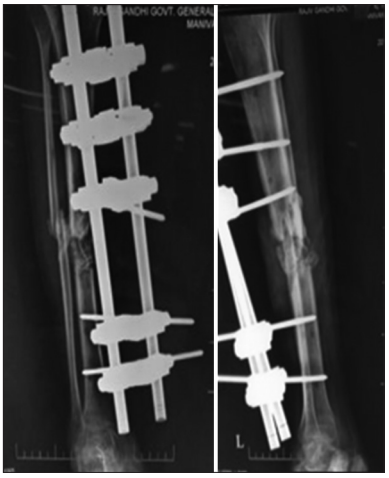

1 year and 8 months post-operative