Print ISSN: 2321-6379
Online ISSN: 2321-595X

Original Article

Our Experience with Different Skin Closure Techniques in Meningomyeloceles

Sura Anitha[1], Mahender Erugurala[2], J P Varnika[3], Subodh Kumar Arige[4], Baliram Chikte[5], B K Lakshmi[3]

[1]Assistant Professor, [2]Associate Professor, [3]MCh PG, [4]Professor, [5]Associate Professor, Department of Plastic Surgery, Gandhi Medical College and Hospital, Secunderabad, Telangana, India

Abstract

Introduction: Myelomeningocele is a spinal dysraphism containing a placode of neural tissue attached to the surrounding skin. Although common and a serious malformation of the Central nervous system, it is compatible with life. Neurologic impairment corresponds to size and location of the malformation Closure of the defect is challenging as the tissue available is less, with high chances of wound dehiscence. Therefore, multispecialty treatment to close both the neural tube and provides a stable skin cover over the defect and avoid complications is necessary.

Aim of the Study: To study various reconstructive skin closure techniques for the defects of meningomyeloceles and their outcomes.

Material and Methods: Prospective study of 2 years between 2017 and 2019 included 27 children who were operated for meningomyelocele where there was a skin defect after closure of it. Different closure techniques were analyzed.

Results: Eighteen were male children and nine were female. Common location was lumbosacral region (17 of 27). The defect size varied from 10–40 cm^2. Common technique was primary closure at 40.7%. Various other flaps like bipedicled and transposition flaps were used in another 60%. Complications amounted to 24%. The mean hospital stay was 12 days.

Discussion and Conclusions: Although musculocutaneous flaps are around, we preferred fasciocutaneous flaps for their reliability, ease of dissection less operative time, and minimal blood loss. The disadvantage with these flaps is their random pattern of blood supply, and so careful planning and wide base are required.

Key words: Bipedicle flap, Cerebrospinal fluid, Closure, Defect, Fasciocutaneous flap, Limberg flap, Meningomyelocele, Musculocutaneous flap, Primary, Rotation flap, Transposition flap

INTRODUCTION

Myelomeningocele (MMC) is a form of spinal dysraphism. The etiology of neural tube defects may include genetics, geography, low socioeconomic status, and folic acid deficiency.[1] At four weeks of gestation, the lateral edges of the neural plates elevate toward each other and fuse to form a tube known as the neural tube. Failure of this process results in a neural tube defect and represents a localized failure of primary neurulation. When the failure involves a posterior closure, it is called spinal dysraphism.[1]

Access this article online

www.ijss-sn.com

Month of Submission : 07-2020
Month of Peer Review : 08-2020
Month of Acceptance : 08-2020
Month of Publishing : 09-2020

The resultant malformation contains a placode of neural tissue attached peripherally to the surrounding skin. The underlying cerebrospinal fluid (CSF) elevates the placode on a dome or sac. If the thin tissue on the dome tears, the CSF is allowed to escape and the malformation is flat. Whether domed or flat, there will always be a placode on the skin surface and, MMCs are, therefore, open malformations.[1] An MMC is the most common of the dysraphic malformations and is also the most serious CNS malformation compatible with life. Neurologic impairment and sensorimotor paralysis corresponds to size and location of the malformation.[1]

Global prevalence of MMCs ranges from 0.8 to 1.0 in 1000 live births.[2] MMCs cause chronic disability. Closure of such defects is a challenging task, as the amount of tissue available in an infant is less, and there are high chances of wound dehiscence. Therefore, treatment with multidisciplinary care involving both neurosurgeons and

Corresponding Author: Dr. Mahender Erugurala, Mahender Erugurala, H No 6-1-134, Flat No 207, Giridhari Kamalanarayan Apartments, Street No 10, Padmaraonagar, Telangana, 500020, Hyderabad, India.

plastic surgeons to close the neural tube and provides a stable cover over the defect and avoid complications is necessary to improve the quality of life, and survival.

The aim of the study is to analyze the size of MMC defects, and various reconstructive skin closure techniques for those defects and the outcome of such closures.

MATERIALS AND METHODS

This is a prospective study done over a period of 2 years from September 2017 to October 2019 at a tertiary care hospital. A total of 27 children were included in the study. They underwent surgery of closure for meningomyelocele and it was followed by plastic surgical intervention for closure of the skin defect. They were followed up. The data such as demography, site of the defect, site of the defect, closure technique, and post-operative complications were analyzed, results and conclusions drawn.

After explaining the complexity of the disease, all aspects of treatment, complications, and long-term problems associated with this disease, to the parents, the informed consent was taken, and the patients were operated.

Surgical Techniques

The newborn is placed in mild Trendelenburg prone position on firm chest rolls to allow thoracic expansion and avoid CSF escape.

Although different methods are described, closure of large meningomyelocele defects remains a challenging problem. Several authors prefer musculocutaneous flaps for managing large Meningomyelocele defects, but it is recognized that musculocutaneous flap coverage of large lumbosacral MMC defects is associated with high complication rates.[3,4]

To avoid this some authors prefer using skin flaps such as advancement flaps, bipedicled flaps, local transposition flaps, bilobed flaps, double Z-plasty, rotation flaps, and Limberg flaps, which can be used successfully in the closure of large MMC defects.[5-8]

Large defects of more than half of the width of the child's back cannot be closed reliably by simple skin undermining. In addition to defect size, location and shape, the general status, associated kyphosis, and the condition of the surrounding tissues are other important parameters that can influence the technique of the reconstruction.

A perfect approximation of suture edges may be possible in cases of well-epithelized MMC with redundant skin. This may not be the case with large flat myeloceles with deficient cutaneous layers that will require a more complex plastic surgery reconstruction.

At our center, we managed to close the defects either through primary closure, or bipedicled flaps with primary closure of donor defect, bipedicled flap with skin grafting of the donor defect, transposition flap, triple rotation flap, and Limberg flap.

Although the correction of MMC should be performed as soon as possible, preferentially within the first 72 h of life, in some of the patients the correction was made at two years of age. Closure of MMC defect increases intracranial pressure, leading to CSF flow through the recently repaired dura, resulting in subcutaneous fluid collection, increase in tension on the fragile wound edges. A ventriculoperitoneal shunt for hydrocephalus was placed in 22 (81.05%) patients either preoperatively (19), intraoperatively (1), or postoperatively (2), and it reduced the risk of CNS infection.

The goals of closure are to preserve the function of the neural tissue, provide a stable skin cover over the repaired neural tissue in the form of flap and to prevent secondary infection.

Primary Closure with Advancement

MMC defects with sizes ranging from 10 cm^2 to 40 cm^2 underwent excision of the MMC sac and water tight dural closure, followed by immediate reconstruction of any residual skin defect. Ideal solution for covering the skin defect in MMC surgery is still lacking. There is no decision-making guide in the literature on whether to use a flap or primary closure for the reconstruction of all types of these skin defects. We did tension free primary closure in few cases after undermining up to posterior axillary lines where there was laxity of the skin.

Bipedicled Flaps

In cases, where there was tension over the suture line, we adopted standard planning techniques for bipedicled flaps in our institution. Most of the defects were addressed with bipedicled flaps usually two, one from either side of the defect and in a few, other flaps also were used. The planning of the flaps was done for the defect after the excision of the MMC sac and dural closure. The defect size was measured in length "Y" and width "X." Both "X" and "Y" were divided into equal halves and the flaps were planned on both sides of the defect. The horizontal dimension of the flap is marked at 1.5"X" from the margin of the defect limiting at the posterior axillary line on either side. The vertical height of the flap was marked at 2"Y" both above and below the defect. These markings are joined on either side to draw

bipedicled flaps on both sides from the defect margin [Clinical picture 1].

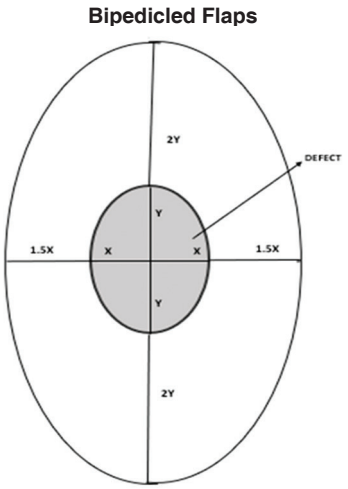

Transposition Flap

In one case, a classical transposition flap was used. In the planning of the local transposition flap, the defect was triangulated first. The transposition flap was designed as a rectangle in a ratio of not more than 2:1 immediately adjoining the defect and was moved to cover the defect. The base of the flap was alongside the apex of the triangle [Clinical picture 2]

Limberg Flap

In one case, Limberg flap was planned keeping the angles at 60 and 120°. The margin of the defect was then trimmed into a parallelogram to act as the Limberg flap. A vertical line equal to the length of one side of the rhomboidal defect was determined, followed by a second line parallel to one side of the rhombus.

Triple Rotation Flap

In one more case, a triple rotation flap was used [Clinical picture 3].

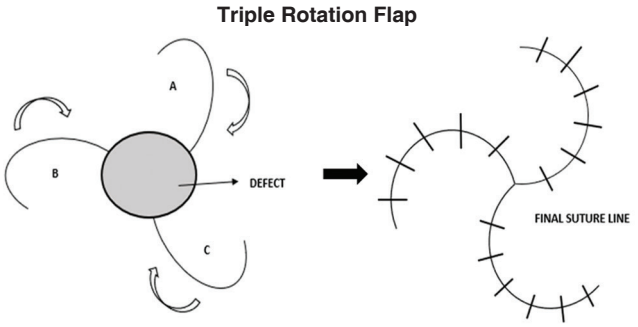

The first step of MMC repair is the development of the subcutaneous layer and flap elevation by digital dissection in the fascial plane all around the spinal defect. Excessive coagulation of perforator vessels to the skin that may compromise the blood supply of the cutaneous coverings is avoided. The subcutaneous layer is usually minimal at the border of the malformation. Suturing at the margins is done without excessive tension with absorbable 3-0 Rapid Vicryl in two layers. Care is taken to interpose adequate subcutaneous layer beneath the superficial skin layers to

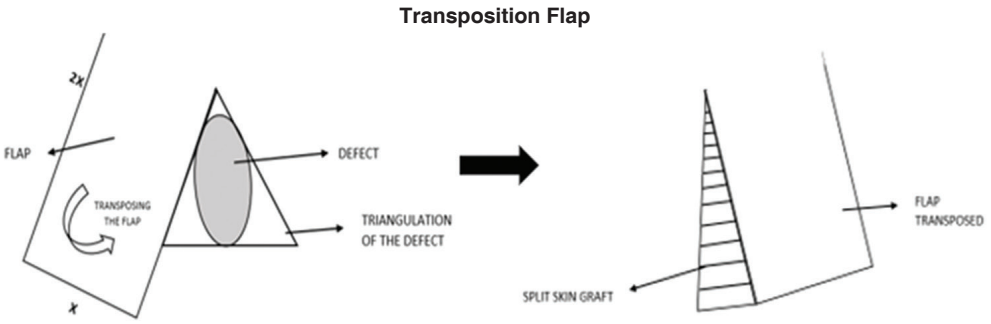

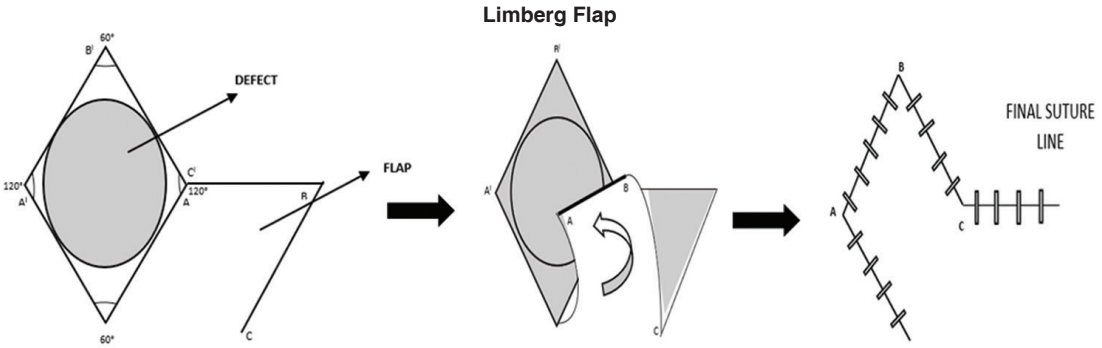

reduce the incidence of retracting scars. Initially, following closure, the skin may be blanched as a sign of tension due to edema. This usually improves as the edema subsides and wound dehiscence rarely occurs.

Post-operative Care

After completing skin closure, the wound is cleaned and covered with sterile gauze. The perineal area and anus are kept separated from the wound dressing by a separate adhesive plastic drape to limit the contact of the wound with urine or fecal matter. The newborn is kept in the neonatal ICU for 1–2 post-operative days, for any signs of apnea or of brainstem dysfunction. The child is maintained prone with the lower back slightly elevated above the level of the head to reduce the risk of CSF leak from the wound.

Intravenous antibiotics are given for 5 days or more if there is significant risk of infection. The wound dressing is changed every 48 hrs, or anytime if soiled. As we used absorbable sutures, there was no need of suture removal.

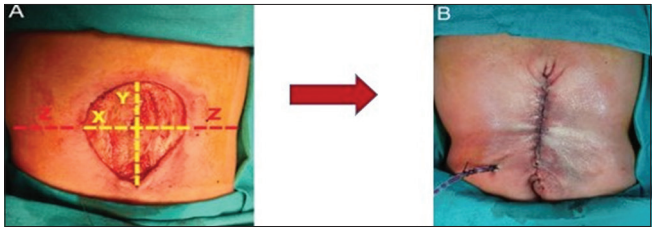

Clinical picture 1: Left Picture showing planning of bipedicle flap. X and Y measured. Posterior axillary lines marked. Flap is planned as 1.5X (Z) in horizontal dimension from defect margin and 2Y in vertical dimension from defect margin. Markings joined to form bipedicle flap on both sides. The right picture showing final closure of the defect with bipedicle flap

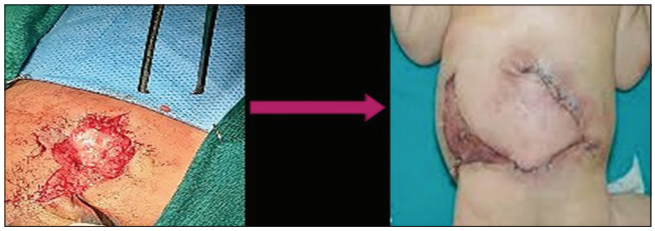

Clinical picture 2: The left picture showing defect and its reconstruction with transposition flap in right picture

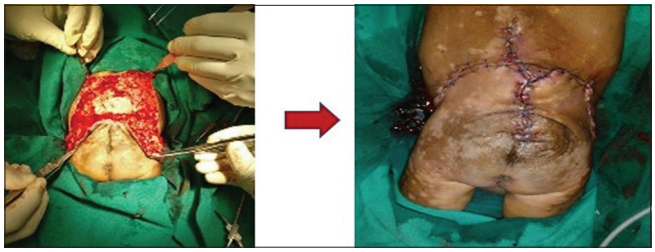

Clinical picture 3: The left picture shows triple rotation flaps elevated and final closure in right picture

Complications and their management are described in the section below.

RESULTS

A total of 27 patients were included in the study.

Demography

About 18 (66.67%) were male children and nine (33.33%) were female [Figure 1]. 44.5% (12) were of age < 72 h. About 22.1% (6) were between 4 to 7 days old. About 25.9% (7) were of age from one week to 30 days. About 3.7% one patient was 10 months age. Another patient 3.7% was of 18 months age [Table 1].

Location

The most common location of the MMC in this study was the lumbosacral region with 17 cases (62.9%). In 1.5% of the cases, it was in the lumbar region. There were three (11.1%) patients with thoracolumbar MMC. There were no cases of cervical MMC. And two (2.74%) patients presented with sacrococcygeal MMC [Figure 2].

Size

The defect sizes varied from 10 to 40 cm^2. In 7.4% (2) cases, defect was about 10 cm^2, in 48.14 % (8) cases it was

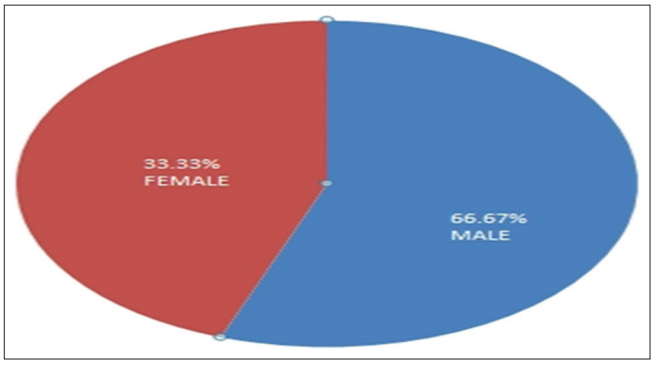

Figure 1: Gender distribution (*n*=27)

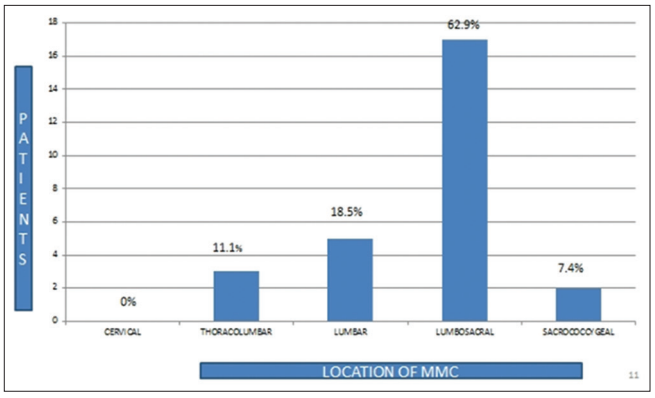

Figure 2: Location of MMC and number of patients (*n*=27)

10–20 cm², in 11.1% (3) cases it was 20–30 cm², and in one case (3.7%), the largest of the defect was 40 cm² [Table 2].

Closure Technique

In most of the cases, 11 of 27 (40.7%) a tension free primary closure could be done with undermining of the surrounding skin in the subcutaneous plane. In 7 of 27 cases (25.9%), defect was closed using bipedicled flaps after giving relaxing incisions in the posterior axillary lines. These relaxing incisions were also closed with primary suturing. In four cases (14.8%), after the bipedicled flap was sutured, the relaxing incisions could not be approximated so skin grafting was done at the donor site. We used rotation flap in two cases (7.4%). Limberg flap in one case (3.7%), classic transposition flap in one case (3.7%), and triple rotation flap in one case (3.7%) [Figure 3].

Relation of Defect Size to the Flap Planned

For primary closure of defect, the average size of the defect was 10.5 cm², the mean size of the defect for bipedicled flap and primary closure was 32.3 cm². While bipedicled flaps requiring closure and skin grafting, the size was around 36.4 cm². In case of the Limberg flap, the size was 39.4 cm². The size of defect for closure with classical transposition flap was 26.9 cm². The defect size was an average of 38.3 cm² for closure with rotation flaps. Moreover, the single triple rotation flap had a defect size of 40.1 cm² [Table 3].

Complications (*n*=6)

We encountered complications in the form of wound infection in one cases (4%), wound dehiscence in four cases (16%), three cases of primary closure where the defect size was 16 cm², 18 cm², and 20 cm², one case of bipedicled flap. Marginal flap necrosis in one patient where triple rotation flap was done (4%) [Figure 4].

Table 1: Relationship of age to number of patients (*n*=27)

Age	Number of patients	Percentage
48–72 h	12	44.5
4–7 days	6	22.1
<30 days	7	25.9
1 month–1 year	1	3.7
1–2 years	1	3.7

Table 2: The dimensions of defect (*n*=27)

Defect size in cm²	Number of patients	Percentage
<10	2	7.4
10–20	13	48.14
20–30	8	29.6
30–40	3	11.1
>40	1	3.7

Wound infection was managed by altering the antibiotics as per culture sensitivity of wound swab and daily dressings. Other complications were managed by secondary procedures.

Wound Dimensions Where Complications were Encountered

Wound dehiscence was noted in cases of primary closure of defect size 16 cm², 18 cm², and 20 cm², and in another case of bipedicle flap with dimension of 15 cm² [Table 4].

Secondary Procedures (*n* = 6)

In four of six cases, (67%) wound complication was managed by debriding the skin margins and closure with flap advancement. In another two of the six (33%) cases, the complication was addressed by debridement of skin margins and skin grafting. luckily, the graft take was good even on exposed closed neural tube defect [Figure 5].

Hospital Stay

In patients, where rotation and transposition flaps were used, the mean hospital stay was 8 days. In cases, where the defect was addressed with bipedicled flap and primary closure, the mean hospital stay was 10 days. In patients with bipedicled flap and skin grafting, the stay was for 12 days. Patients with

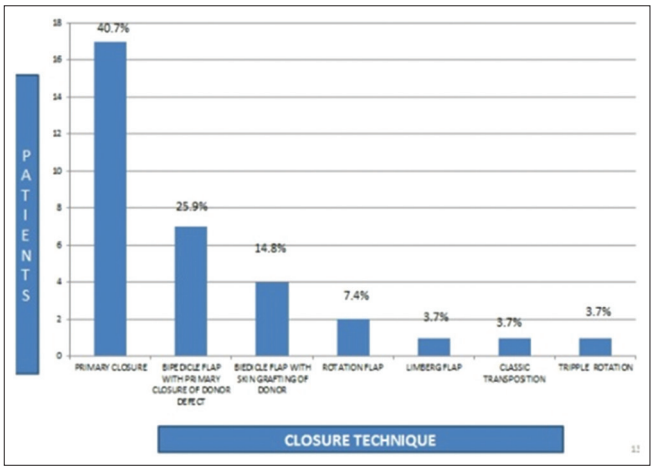

Figure 3: Different closure techniques (*n*=27)

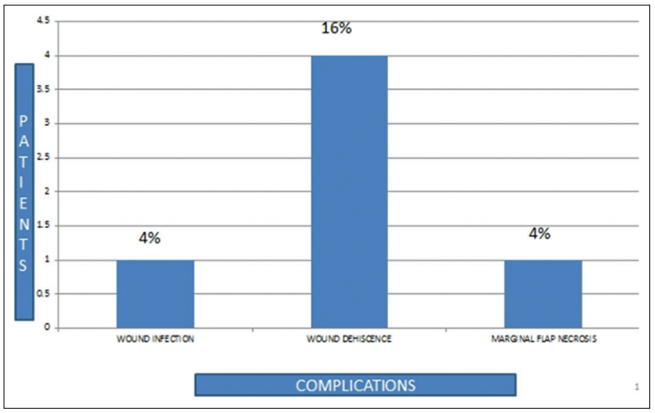

Figure 4: Complications (*n*=6)

Table 3: Different closure techniques for various size of defects (*n*=27)

Closure technique	Number of patients	Average defect size
Primary closure	17	10.5 cm^2
Bipedicle flap with primary closure of donor defect	7	32.3 cm^2
Bipedicle flap with skin grafting of donor	4	36.4 cm^2
Rotation flap	2	38.3 cm^2
Limberg flap	1	49.4 cm^2
Classic transposition	1	26.9 cm^2
Triple roration	1	40.1 cm^2

Table 4: Complications for techniques and defect size

Technique of closure	Size of defect
Primary closure	16 cm^2
Primary closure	18 cm^2
Primary closure	20 cm^2
Bipedicle flap with primary closure of donor defect	15 cm^2

primary closure after undermining the flaps, the mean stay was for 18 days due to complications encountered during healing. In one case where a triple rotation flap was used, the stay was for long period of 22 days as there was wound infection which healed slowly [Figure 6].

Deaths

There were two deaths (7.4%). One baby operated within 48–72 h of birth died two days later to surgery. Another baby operated at one week of birth died five days after surgery. In both the cases, the cause of death was due to CSF leak and CNS infection.

Follow-up

All the patients were followed up till the flaps healed well for a period of three months.

DISCUSSION

There are many techniques available in the armamentarium of the plastic surgeon that can be useful for the closure of MMC defects. Regardless of the technique used, it should be tension free closure with good soft-tissue padding of the neural tube, prevent CSF leakage, and facilitate proper wound healing, especially for large defects. The techniques should lead to minimal morbidity. To achieve successful outcomes, reconstruction and planning should be done specifically for each patient.

Closure of the larger defects especially in children is always challenging. There is a range of options as per

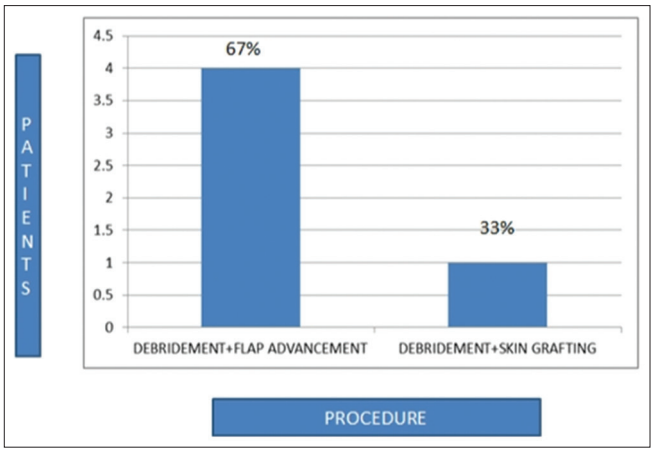

Figure 5: Secondary procedures (*n*=5)

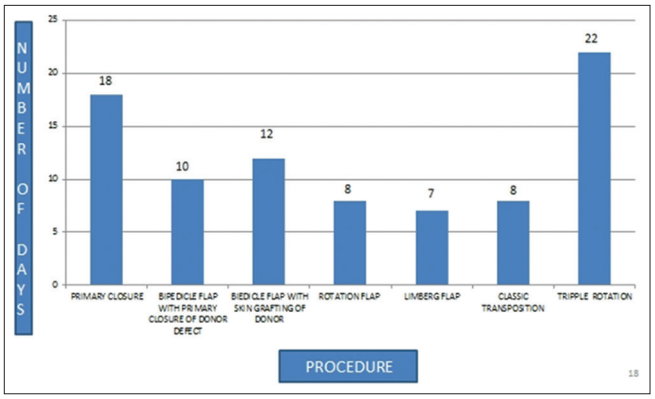

Figure 6: Hospital stay (*n*=25)

reconstructive ladder from a simple skin graft to the local flaps to various regional flaps, musculocutaneous flaps, and even the perforator flaps. Musculocutaneous flaps as an option for wide MMC defects was described by Mustarde in 1968. McCraw *et al.* in 1978 used bilateral latissimus dorsi musculocutaneous flaps for the closure of MMC. McDevitt *et al.* in 1982 had used bilateral latissimus dorsi musculocutaneous flaps with extended gluteal fasciocutaneous flaps for the closure of thoracic and lumbar defects. Use of these flaps was extended to sacral defects by Ramirez *et al.* in 1987. These musculocutaneous flaps did not gain much popularity due to extensive flap dissection, increased blood loss, and prolonged operative time, thereby limiting their use.

Perforator flaps were effectively used by El-Sabbagh in 2011[9] and Duffy *et al.* in 2004. The limitation of these perforator flaps is that these flaps require expertise with microsurgical instrumentation and the microscope.

More recently, in 2012, Patel *et al.*[10] had described the local turnover fascial flaps and the midline linear skin closure as methods of repair for the extradural MMC defects. Some

surgeons relied on single flap for MMC defects. Patterson[11] used only rotation flaps. Cemal Alper Kemaloğlu *et al.*[12] proposed some decision-making guidelines for closure of MMC defects. A similar type of guidelines was used in this study for planning bipedicled local flaps. Length and width are marked as "Y" and "X" from the centre of the defect on either side. Width of 1.5 times X on either side from centre point, and length of 2Y on each side for each of the bipedicled flaps are marked. This planning has enabled our bipedicled flaps to settle well without any major complications.

In this study, we also used other flaps such as advancement flaps, local transposition flaps, triple rotation flaps, and Limberg flaps, which were used successfully in various studies.[2,13,14] The dissection of local skin flaps is much easier to perform, requires less operative time, and results in less blood loss. Primary closure with advancement is possible by undermining of the wound margins in almost 40% of cases. However, in the remaining 60% of patients, we planned for flaps as our aim was to achieve a tension free closure and avoid wound dehiscence. The drawback of these commonly used techniques is the vascular compromise and seroma formation which can lead to wound dehiscence. The use of fasciocutaneous flaps has been described in plastic surgery literature. Flaps with primary midline closure heal well with a cosmetically pleasing scar as there is good vascular supply to both skin and fascial edges.

In the previous studies, approximately 75% of MMC defects were closed by direct repair, while the remaining 25% required other reconstructive options.[11] While in this study, 40% were primary closures and 60% of cases needed flaps.

The most frequent location of MMCs in this study (62.9%) was lumbosacral region which is also, a finding in study done by others.[2,14-16] Although this may be the reason for satisfactory post-operative ambulation in these patients, we had limited time to assess the follow-up because of the prevailing COVID situation. Patients with MMC at high level can also achieve community ambulation when they receive good care, as reported by Charney *et al.*[12]

Male to female ratio in this study is 1.25 almost similar to the findings as other studies[2,11,17] where there is preponderance of males over females. Complication rate is 24% of which wound dehiscence was noted in four (16%) patients, and one was a triple rotation flap and the same was seen in other studies.[2,15] Wound dehiscence arising more in primary closure cases than where flaps are planned states that wherever possible, closure with well planned and executed flaps gives better outcomes. This was the reason for relatively long hospital stay in cases of primary closure where discharge could have been planned early.

Types of flaps planned for the defect size in this study is correlating to those planned by Mukesh Kumar sharma.[2]

CONCLUSIONS

In spite of many options for closure of MMC defects, flaps are more reliable in giving a good closure and support to the underlying cord structures. Although there are many flaps described in various studies, there is a lack of a standard road map to guide the young plastic surgeons. Fasciocutaneous flaps rather than musculocutaneous flaps are easy to practice and reliable as there is no muscle dissection which may compromise the physical quality of life later.

Furthermore, fasciocutaneous flaps take less operative time in a child already under general anesthesia and critical life. There is minimal intraoperative blood loss in case of fasciocutaneous flaps. Bipedicled flaps planned in the manner described with 1.5 X and 2Y had satisfactory results.

The disadvantage with these flaps is because of the random pattern of blood supply, careful planning and wide base are required.

REFERENCES

1. Dias M, Partington M, Section on Neurologic Surgery. Congenital brain and spinal cord malformations and their associated cutaneous markers. Pediatrics 2015;136:e1105-19.
2. Sharma MK, Kumar N, Jha MK, Umesh N, Srivastava RK, Bhattacharya S. Experience with various reconstructive techniques for meningomyelocele defect closure in India. JPRAS Open 2019;21:75-85.
3. Brau RH, Rodríguez R, Ramírez MV, González R, Martínez V. Experience in the management of myelomeningocele in Puerto Rico. J Neurosurg 1990;72:726-31.
4. McCraw JB, Penix JO, Baker JW. Repair of major defects of the chest wall and spine with the latissimus dorsi myocutaneous flap. Plast Reconstr Surg 1978;62:197-206.
5. Akan IM, Ulusoy MG, Bilen BT, Kapucu MR. Modified bilateral advancement flap: The slide-in flap. Ann Plast Surg 1999;42:545-8.
6. Bajaj PS, Welsh F, Shadid EA. Versatility of lumbar transposition flaps in the closure of meningomyelocele skin defects. Ann Plast Surg 1979;2:103-8.
7. Cruz NI, Ariyan S, Duncan CC, Cuono CB. Repair of lumbosacral myelomeningoceles with double Z-rhomboid flaps. Technical note. J Neurosurg 1983;59:714-7.
8. Ohtsuka H, Shioya N, Yada K. Modified Limberg flap for lumbosacral meningomyelocele defects. Ann Plast Surg 1979;3:114-7.
9. El-Sabbagh AH, Zidan AS. Closure of large myelomeningocele by lumbar artery perforator flaps. J Reconstr Microsurg 2011;27:287-94.
10. Patel KB, Taghinia AH, Proctor MR. Extradural myelomeningocele reconstruction using local turnover fascial flaps and midline linear skin closure. J Plast Reconstr Aesthet Surg 2012;65:1569-72.
11. Patterson TJ. The use of rotation flaps following excision of lumbar myelo-meningoceles: An aid to the closure of large defects. Br J Surg 1959;46:606-8.
12. Kemaloğlu CA, Özyazgan İ, Ünverdi ÖF. A decision-making guide for the closure of myelomeningocele skin defects with or without primary repair. J

Neurosurg Pediatr 2016;18:187-91.
13. Shim JH, Hwang NH, Yoon ES, Dhong ES, Kim DW, Kim SD. Closure of myelomeningocele defects using a Limberg flap or direct repair. Arch Plast Surg 2016;43:26-31.
14. Ulsenheimer MM, Antoniuk SA, Santos LH, Ceccatto MP, Silveira AE, Ruiz AP, *et al*. Myelomeningocele: A Brazilian University hospital experience Arq Neuropsiquiatr 2004;62:963-8.
15. Jabaiti S, Al-Zaben KR, Saleh Q, Abou Alrob M, Al-Shudifat AR. Fasciocutaneous flap reconstruction after repair of meningomyelocele: Technique and outcome. Pediatr Neurosurg 2015;50:344-9.
16. Lapid O, Rosenberg L, Cohen A. Meningomyelocele reconstruction with bilobed flaps. Br J Plast Surg 2001;54:570-2.
17. Nejat F, Baradaran N, EI Khashab M. Large myelomeningocele repair. Indian J Plast Surg 2011;44:87-90.

How to cite this article: Anitha S, Erugurala M, Varnika JP, Arige SK, Chikte B. Our Experience with Different Skin Closure Techniques in Meningomyeloceles. Int J Sci Stud 2020;8(6):63-70.

Source of Support: Nil, **Conflicts of Interest:** None declared.