Print ISSN: 2321-6379
Online ISSN: 2321-595X

Original Article

Assessment of the Outcome of Transarterial Chemoembolization and Sorafenib in the Treatment of Advanced Stage of Hepatocellular Carcinoma: An Observational Study

Chandra Dev Sahu[1], Vinay Goel[2]

[1]Assistant Professor, Department of Radiodiagnosis, Pt. Jawahar Lal Nehru Memorial Medical College, Raipur, Chhattisgarh, India, [2]Junior Resident, Department of Radiodiagnosis, Pt. Jawahar Lal Nehru Memorial Medical College, Raipur, Chhattisgarh, India

Abstract

Aim: This study aims to assess the outcome of transarterial chemoembolization (TACE) and sorafenib in the treatment of advanced stage of hepatocellular carcinoma (HCC).

Materials and Methods: The longitudinal analysis of the data was approved by the institutional ethical committee and proper informed consent was taken from the study population. Advanced-stage HCC was defined according to Barcelona clinic liver cancer staging classification (Child-Pugh Class A or B, Eastern Cooperative Oncology Group performance status of 1–2, and/or macrovascular invasion or extrahepatic metastasis). A total number of 22 patients of advanced-stage HCC were treated with TACE (n = 11) and sorafenib (n = 11) between the period of July 2017 and September 2018. Modified response evaluation criteria in solid tumors (mRECIST) were used to evaluate the outcome in all patients.

Results: There was no significant difference between the tumor characteristics (size and number of the lesion, portal vein invasion, and metastases) in the study groups. Both sorafenib and TACE would result in stable response in majority of the patients using mRECIST with no significant difference in the overall survival period between these two treatment modalities.

Conclusion: TACE is similar to sorafenib in terms of outcome in advanced-stage HCC using mRECIST. Thus, TACE can be considered as an effective treatment modality in advanced-stage HCC; however, further studies are required to firmly establish this clause.

Key words: Hepatocellular carcinoma (HCC), TACE, Sorafenib, mRECIST

INTRODUCTION

Hepatocellular carcinoma (HCC) is the most common primary malignancy of the liver.[1] According to GLOBOCAN 2018[2] data, there are approximately 8.5 lacs new cases of HCC registered, among which the majority (72.5%) is seen in Asia. HCC is the third most common cause of death in cancer patients (8.2%) preceded by lung and colorectal cancer. There is inadequate information of HCC prevalence in India as data are available from tertiary centers in selected areas only. The age-adjusted incidence rate for HCC in India for men ranged from 0.9 to 7.5 and for women it ranged from 0.2 to 2.2/100,000 population.[3] With an M:F of 4:1 and the median age ranging from 40 to 70, the frequency of liver cancers seems to be higher with increasing age.[4] Cirrhosis is the most common and important risk factor for HCC. Hepatitis B and C are also considered important in etiology of HCC. Other risk factors include alcohol, aflatoxin, obesity, and diabetes.

Barcelona clinic liver cancer (BCLC) staging system[5] is being followed in our institution for the treatment of HCC. Accordingly, curative options such as transplantation, resection of tumor, and radiofrequency ablation can be employed only in the early stage of HCC. Since >50% of patients present with advanced-stage HCC, there is continuous need of the

Access this article online

www.ijss-sn.com

Month of Submission : 02-2019
Month of Peer Review : 03-2019
Month of Acceptance : 03-2019
Month of Publishing : 04-2019

Corresponding Author: Dr.Vinay Goel, Department of Radiodiagnosis, Pt. Jawahar Lal Nehru Memorial Medical College, Raipur, Chhattisgarh, India.

development of palliative treatment modalities. BCLC has defined advanced stage of HCC as HCC with extrahepatic metastases or microvascular invasion and/or an Eastern Cooperative Oncology Group (ECOG) performance status of 1–2. According to BCLC staging system, sorafenib is the treatment of choice in advanced stage of HCC.

It has been seen that the intrahepatic spread of the disease is more common cause of death in advanced-stage HCC rather than the extrahepatic spread of the disease,[6] thus transarterial chemoembolization (TACE) can be considered as an effective modality for such patients which targets the intrahepatic lesion.

As Dr. Bhim Rao Ambedkar Memorial Hospital is a tertiary facility with regional cancer unit, there is high prevalence of HCC in our hospital with both TACE and sorafenib being provided to the patients. Therefore, we hypothesized that TACE may achieve a comparable survival outcome to sorafenib in patients with advanced-stage HCC. Therefore, we observed the outcome of TACE and sorafenib in patients with advanced-stage HCC.

Aims and Objectives

The objectives of this study were as follows:

- To assess the outcome of sorafenib in advanced-stage HCC.
- To assess the outcome of TACE in advanced-stage HCC.

MATERIALS AND METHODS

Study Design

This was a longitudinal descriptive tertiary hospital-based study.

Study Area

The present study was conducted in the Department of Radiodiagnosis, Pt. Jawahar Lal Nehru Memorial Medical College and associated Dr. Bhim Rao Ambedkar Memorial Hospital, Raipur, Chhattisgarh. The study period was from July 2017 to September 2018.

Sampling Methods

Simple random sampling procedure was used. The study population includes patients aged between 18 and 75 years referred to the radiology department from regional cancer unit and receiving any prior treatment (sorafenib/TACE).

Sample Size

The sample size was 22 patients in the study.

Selection Criteria

Inclusion criteria

The study includes:

- Any patient of the age group of 18–75 years old.
- Patient who has given informed consent.
- Diagnosed cases of HCC who have received any prior treatment (sorafenib/TACE).

Exclusion criteria

The following criteria were excluded from the study:

- Any previous history of liver failure.
- Active variceal bleeding or other signs of hepatic decompensation.
- Patient not willing to participate in the study.

Instrumentation

Triple-phase computed tomography (CT) performed on 128-slice Siemens SOMATOM definition AS machine.

Triple-phase magnetic resonance imaging (MRI) performed on Siemens Magnetom SKYRA 3T MRI.

Method of collection of data

A thorough clinical history of all patients diagnosed with advanced stage of HCC was taken. They were asked regarding the duration of treatment and any adverse effects related to it. General physical and abdominal examination of all patients was done. Then, a meticulous record of all the available laboratory investigations including HepB, HCV, HIV status, serum alpha-fetoprotein (AFP), liver function test, prothrombin time/international normalized ratio, and routine blood investigations was kept.

All subjects were enrolled with detailed oral and written consent. This study was approved by ethical and scientific committee of our institute.

Triple-phase contrast-enhanced CT/MRI was done in all the cases taken in the study.

Treatment procedures

TACE and sorafenib treatment were given to the patients by the multidisciplinary regional cancer center of our institute. Conventional TACE was performed in 11 patients using cisplatin (65 mg/m^2 of body surface area) mixed with lipiodol with or without using polyvinyl alcohol particles (300–500 μm).

Sorafenib was given to 11 patients at a dose of 400 mg twice a day.

Patients were followed for 1 month, and subsequently, CT/MRI was done to evaluate the tumor using modified response evaluation criteria in solid tumors (mRECIST).

Statistical Methods

- Data were expressed as percentage and mean ± S.D.
- Student's *t*-test correlation analysis was used to check

the difference between two parameters in parametric data.

- Fischer's exact test or Chi-square test was used to analyze the significance of difference between frequency distribution of the data.
- Correlation analysis was performed using Pearson's correlation.
- Wilcoxon signed-rank test was used to compare pre- and post-treatment analysis.
- $P < 0.05$ was considered as statistically significant.
- Survival period for sorafenib and TACE was defined as time from start of sorafenib/TACE treatment till the date of death/last follow-up (which was in our case up to September 2018)
- SPSS© for Windows™ Version 17, IBM™ Corp NY and Microsoft Excel™ 2007, and Microsoft® Inc. USA were used to perform the statistical analysis.

RESULTS

A total of 22 patients of advanced-stage HCC who got treated with TACE (n = 11) and sorafenib (n = 11) were included in this study. Demographic data of the study population are discussed in Table 1.

The mean age in sorafenib group was 50.3 years and in TACE group was 54.4 years. The male:female ratio in both study groups was 1.7:1.

The major risk factors were alcohol intake (63.3%) followed by hepatitis B (40.9%) and hepatitis C (9%).

Most of the patients in both groups had preserved liver function at the time of presentation as Child-Pugh Class A/B were seen in 90.9% of the patients and only few patients (9.1%) had poor hepatic reserve as they fall into Child-Pugh Class C category.

The number of lesions in both the groups was predominantly <4 (72.7%) and 27.3% of the patients had >4 lesions. The size of the target lesion was <7 cm in majority of the patients (63.6%) in both the groups, whereas 36.4% of the patients had size >7 cm.

Portal vein invasion was seen in 63.6% of patients of the sorafenib study group and 72.7% of patients in TACE study group. Metastases were seen in 63.6% of the cases of sorafenib study group and 54.5% of cases in TACE study group.

There was significant association between the Child-Pugh class and outcome using mRECIST. Stable disease (100%) was seen in patients with Child-Pugh Class A/B.

There was no significant difference between the outcome of lesions less and more than 7 cm using mRECIST.

Table 1: Demographics in total and by treatment

Characteristics	Overall		Sorafenib		Tace		*P*-value
	n	%	n	%	n	%	
Total	22	100	11	50	11	50	
Sex							0.67
Male	14	63.6	7	63.6	7	63.6	
Female	8	36.4	4	36.4	4	36.4	
Age							
<50 years	10	45.45	5	45.45	5	45.45	0.392
>50 years	12	54.55	6	54.55	6	54.55	
Etiology							
Alcohol	14	56	6	54.5	8	72.7	0.33
Hepatitis b	9	36	4	36.4	5	45.5	0.5
Hepatitis c	2	8	2	18.2	0	0	0.238
Bilirubin (mg/dl)							
Total <2	13	59	6	54.55	7	63.63	0.41
>2	9	41	5	45.45	4	36.37	
Direct <1.5	16	72.72	8	72.73	8	72.73	0.44
>1.5	6	27.27	3	27.27	3	27.27	
SGOT (IU)							0.918
<100	11	50	5	45.45	6	54.55	
>100	11	50	6	54.55	5	45.45	
SGPT (IU)							0.043
<100	12	45.45	5	45.45	7	63.64	
>100	10	54.55	6	54.55	4	36.36	
Albumin (g/dl)							0.59
<3.5	11	50	5	45.45	6	54.55	
>3.5	11	50	6	54.55	5	45.45	
Creatinine (mg/dl)							0.74
<1.2	11	50	8	72.73	8	72.73	
>1.2	11	50	3	27.27	3	27.27	
Prothrombin time (Sec)							0.28
<14	10	45.45	3	27.27	7	63.64	
>14	12	54.55	8	72.73	4	36.36	
INR							0.80
<1.3	13	59.1	7	63.64	6	54.55	
>1.3	9	40.9	4	36.36	5	45.45	
Ascites							0.70
Absent	10	45.5	4	36.4	6	54.5	
Mild	4	18.2	2	18.2	2	18.2	
Moderate	4	18.2	2	18.2	2	18.2	
Severe	4	18.2	3	27.3	1	9.1	
Encephalopathy							1.0
Absent	11	50	8	72.73	8	72.73	
Present	11	50	3	27.27	3	27.27	
Child pugh score							1.0
A	6	63.6	2	18.2	4	36.4	
B	14	27.2	8	72.7	6	54.5	
C	2	18.2	1	9.1	1	9.1	
Size of target lesion (cm)							0.67
<7	14	63.6	7	63.6	7	63.6	
>7	8	36.4	4	36.4	4	36.4	
Number of lesions							0.5
</= 4	16	72.7	7	63.6	9	81.8	
>4	6	27.3	4	36.4	2	18.2	
Portal vein invasion							0.5
Yes	15	46.66	7	63.6	8	72.7	
No	7	53.34	4	36.4	3	27.3	
Metastases							0.5
Yes	9	69.23	4	36.4	5	45.45	
No	13	30.77	7	63.6	6	54.55	
Outcome using mrecist							0.62
CR	1	9.1	0	0	1	9.1	
PR	2	18.2	1	9.1	1	9.1	

(Contd...)

Table 1: *Continued*

Characteristics	Overall		Sorafenib		Tace		*P*-value
	n	%	n	%	n	%	
SD	10	45.5	5	45.4	5	54.5	
PD	4	18.2	3	27.3	1	9.1	
Died/no follow up	5	22.7	2	18.2	3	27.3	
AFP(μg/L)							0.25
<1000	9	40.9	4	36.4	5	45.5	
>1000	13	59.1	7	63.6	6	54.5	

TACE: Trans-arterial chemoembolization SGOT: Asparatate transaminase; SGPT: alanine transaminase; mRECIST: modified response evaluation criteria in solid tumors ; CR: complete response ;PR: partial response ; PD: Progressive disease ; SD: Stable disease ; AFP: alfa-fetoprotein

Stable disease was seen in 100% of cases with number of lesions <4.

Sorafenib had a mean survival period of 3.9 months and TACE had a mean survival period of 3.8 months.

There was no significant difference in serum AFP level before and after (1 month) of sorafenib and TACE treatment.

CASE ILLUSTRATIONS

Case -1

History:

A 40 years old Hepatitis B positive male patient presented with complaints of vague abdominal pain with mild distension of abdomen since 15 days.

On Contrast enhanced computed tomography (CECT), there was a large relatively defined mass lesion in left lobe of liver with portal vein thrombus which was subsequently confirmed as hepatocellular carcinoma on biopsy.

Patient undergone Trans-arterial chemoembolisation(TACE) with cisplatin and was followed after one month and evaluated using mRECIST criteria.

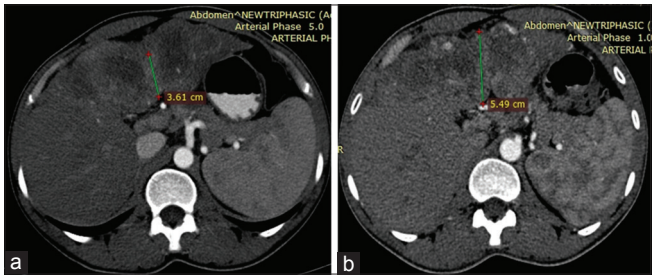

Figure 1: (a) CECT shows an ill-defined heterogeneously enhancing mass lesion noted in left lobe of liver (longest diameter of viable part of the lesion is 3.6cm), (b) After 1 month of TACE, there is significant increase in the size of the lesion (longest diameter of viable part of the tumor is 5.49 cm)

According to mRECIST criteria, it was a progressive disease.

Case -2

History:

A 65 years old Hepatitis-C positive female patient came with complaint of abdominal distension since 2 months.

On CECT, multiple variable sized mass lesion noted in right lobe of liver with secondaries in lung.

Patient was started on sorafenib 400mg twice a day and was followed after one month.

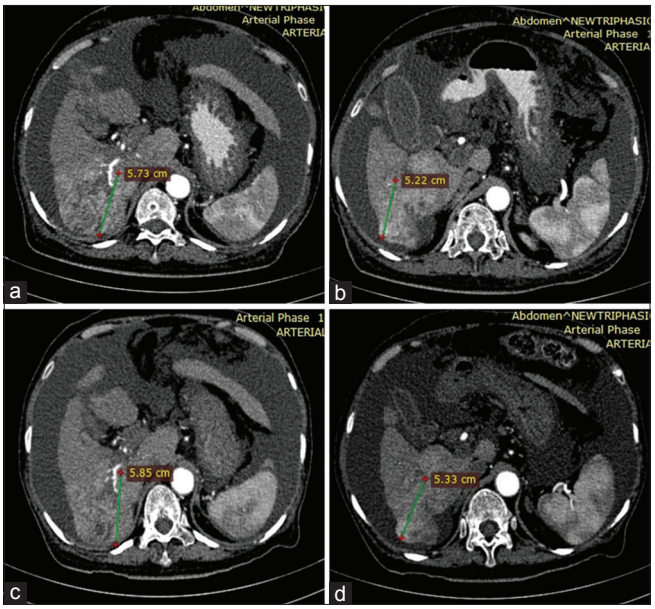

Figure 2: (a and b) Pre-Sorafenib CECT arterial phase showing longest dimension of viable part of two target lesions in right lobe of liver. (Sum of the two diameters is 10.95cm) (c and d) Post sorafenib CECT arterial phase (after 1 month) showing no significant increase in the viable part of tumor. (Sum of the two diamters is 11.18cm)

Therefore, by using mRECIST criteria, this is a stable response to sorafenib treatment.

Case-3

A 58 years old chronic alcoholic male patient came with complaint of yellowing of eyes and pain in abdomen since 10 days.

On CECT, there were multple lesion(three in number) noted in right lobe of liver with portal vein invasion.

Patient undergone TACE with Cisplatin and was followed after 1 month .

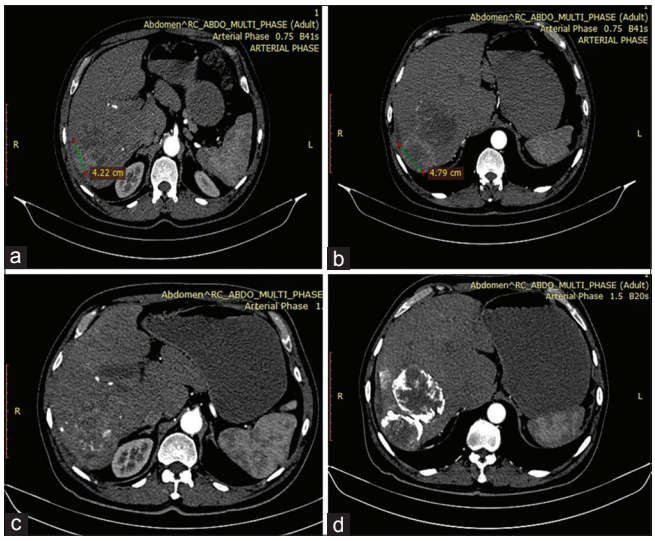

Figure 3: (a and b) CECT abdomen (pre chemoembolisation) showing longest diameter of viable part of two target lesion (sum of two diamteres is 9.01cm), (c and d) CECT abdomen (post chemoemblisation) showing no obvious enhancement in the target lesions

Thus, according to mRECIST criteria, there is complete response in this patient.

Case-4

A 50 years old male patient came with complaints of abdominal pain and distension since 1.5 months.

MRI contrast revealed a large heterogeneous mass lesion noted in left lober of liver with portal vein invasion.

Patient was treated with trans-arterial chemoembolisation and followed up after one month.

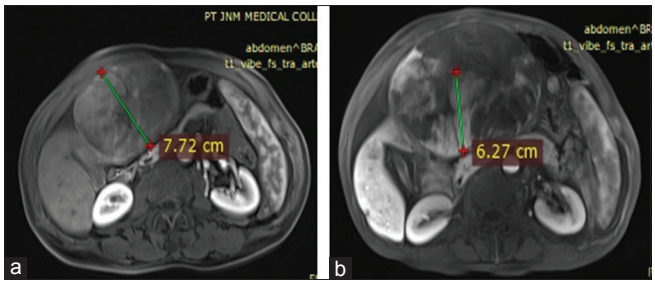

Figure 4: (a) Gd enhanced MRI arterial phase showing a large peripherally enhancing heterogeneous mass lesion in left lobe of liver (longest diameter of the viable part of the lesion measures 7.72cm), (b) after 1 month of TACE, there is signifcant necrosis noted in the lesion. (longest diameter of the viable part of the lesion measures 6.27cm)

According to mRECIST criteria,a stable disease was seen in this case.

Case-5

A 42 years old chronic alcoholic man came with complaints of blood in vomitus with distension of abdomen since 5 days.

CECT showed a well-defined peripherally enhancing lesion in segment V of liver with multiple large lymph nodal metastases.

Patient was prescribed sorafenib 400mg twice a day and was followed after 1 month.

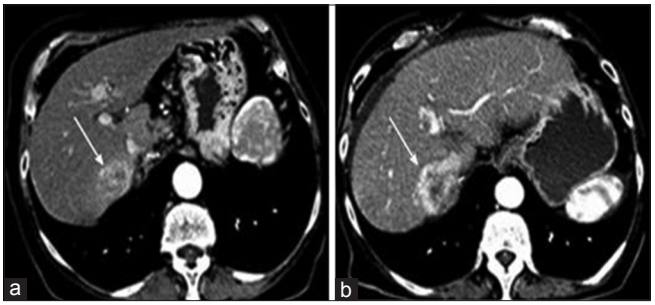

Figure 5: (a) CECT arterial phase showing a well-defined peripherally enhancing lesion in segment V of the liver (longest viable diameter of the lesion came out to be 3.24 cm) and (b) After 1 month of sorafenib treatment ,there is significant increase in the size of the lesion (longest viable diameter of the lesion now increased to 5.12 cm)

Thus, by applying mRECIST criteria, it is a progressive disease.

Case-6

A 45 years old hepatitis B postitive woman came with complaints of abdomen pain since 6 months.

On CECT, there is a large relatively defined heterogenosuly enhancing mass lesion noted in right lobe of liver with portal vein invasion.

Patient was given sorafenib 400mf twice a day and subsquently followed up after 1 month.

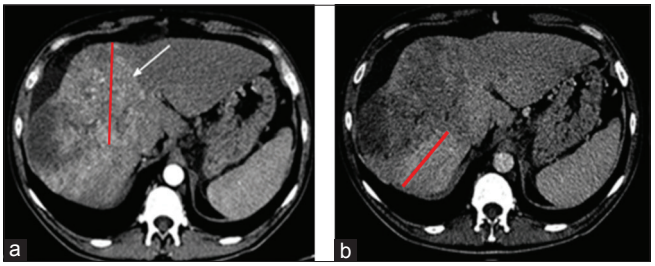

Figure 6: (a) CECT shows a heterogeneously enhancing lesion (white arrow) involving segment VII and VIII of liver.(longest viable diameter of the lesion is 8.65cm[red line]) and (b) After 1 month of sorafenib therapy, there is decrease in the viable part of the tumor(longest diameter of viable part of the tumour is now 5.73cm)

Thus applying mRECIST criteria, it is a partial response in this case.

DISCUSSION

An observational longitudinal study of the assessment of the outcome of TACE and sorafenib in advanced-stage

HCC in the age group of 18–75 years was conducted in the Department of Radiodiagnosis, Pt. Jawahar Lal Nehru Memorial Medical College and associated Dr. B. R. Ambedkar Memorial Hospital, Raipur, from July 2017 to September 2018 on 22 advanced-stage HCC patients.

Advanced HCC (i.e., BCLC Stage C) is characterized by an ECOG performance status of 1–2 and/or the presence of microvascular invasion or extrahepatic metastasis. Sorafenib is currently the only treatment that substantially prolongs survival in patients with BCLC Stage C HCC, making sorafenib the standard treatment for advanced-stage HCC.

Sorafenib predominantly inhibits tumor cell proliferation which results in delayed tumor progression, whereas occlusion of the tumor-feeding vessels with transarterial chemoembolization results in variable degree of hypoxia, which leads to tumor necrosis.

The mean age in sorafenib group was 50.3 years and in TACE group was 54.4 years. Pinter *et al.* showed a mean age of >65 years in both the age groups. Males were more frequently affected with HCC than females (1.7:1) which correlates well with studies conducted by Pinter *et al.* and Kirstein *et al.* The major risk factors were alcohol intake (63.3%) followed by hepatitis B (40.9%) and hepatitis C (9%) which correlates well with studies conducted by Pinter *et al.*

Poor prognosis has been consistently reported in patients with advanced-stage HCC. Many natural history studies and one meta-analysis of 30 randomized controlled trials of HCC revealed a median survival period of <7 months and emphasized the need for optimized therapeutic approaches.[7-9] Since 2008, sorafenib has been available for patients with advanced-stage disease and has improved median survival period to 10 months. Its efficacy in such patients has been investigated in several pro- and retrospective studies. In our study, a mean survival period of 3.9 months was noted in sorafenib group. Kirstein *et al.* also showed a survival period of 7 months in sorafenib-treated patients. This difference could be explained by the shorter duration of our study and less sample size. Moreover, patients in these previous studies[7-9] have lesions <3, whereas most of our patients have >3 lesions. The extrahepatic burden was less in the previous studies as compared to our studies. In line with our findings, lung metastases were also the most common extrahepatic metastatic site within comparable studies.[7-9]

The role of locoregional tumor therapy is not established in the setting of advanced-stage HCC. Following the recommendation of the BCLC, locoregional therapies are not recommended for patients with advanced-stage HCC (it was included in original BCLC). However, natural history studies of HCC suggest that it is the intrahepatic tumor burden which significantly contributes to death in such patients and not extrahepatic spread. A retrospective study including 240 patients with HCC and extrahepatic metastases, who were treated with locoregional and/or systemic treatment between 2004 and 2009, revealed progressive intrahepatic tumor as the leading cause of death[10] providing a rationale to consider locoregional therapy even in the presence of portal vein invasion/metastases. By now, several studies have been performed that have investigated TACE in patients with advanced-stage HCC and have reported efficacy in this specific subgroup of patients. Accordingly, following the recommendation of the German practice guideline, TACE may be considered for patients with limited epizootic hemorrhagic disease (EHD).[11] Median survival period times ranging from 8 to 13 months have been reported for patients with advanced-stage HCC treated with TACE. Median survival period was 11.9 months within one large, retrospective study including 508 patients with advanced-stage disease treated with TACE, among which 84 patients were diagnosed with EHD.[12] Another small retrospective study compared TACE in patients with and without extrahepatic spread of HCC and revealed a considerable median survival period of 13 months for patients with EHD (n = 39).[13] The patients included in this study, however, had an excellent hepatic function with no liver cirrhosis in 22.7% of the patients and with only 2.2% of patients classified as Child-Pugh Class B, whereas the remaining patients were classified as Class A.

In our study, survival period of 3.8 months was observed in TACE group which was lower as compared to other studies.[13,14] It is important to mention that patient with preserved hepatic function (Child-Pugh Class A/B) has a survival period of 6 months in our study. Finally, the broad range of survival period found in literature may also be explained by the lack of standardization in procedures, repetitions, and intervals of TACE treatments.

So far, there are only few studies comparing outcome of patients with advanced HCC treated with TACE or sorafenib.[13,15] Within a retrospective study including patients with any advanced disease – either with or without extrahepatic disease – 55 patients were treated with TACE and 56 were treated with sorafenib. Median overall survival (OS) was 6.6 months in the TACE group and 9.2 months in the sorafenib group.[15] Another retrospective analysis included 97 patients with advanced disease stage with or without extrahepatic spread. The median OS was 9.2 months for patients treated with TACE and 7.4 months for those treated with sorafenib. This difference was

non-significant.[13] However, in contrast to our analysis, these studies have not particularly included patients with metastases.

We have found no survival difference between sorafenib and TACE treatment in patients with advanced-stage HCC. Therefore, it can be said that TACE is an effective modality in advanced-stage HCC.

CONCLUSION

We observed the outcome of TACE and sorafenib in advanced-stage HCC (with metastases/portal vein invasion). Both the modalities result in similar response; however, TACE did result in complete response in one patient; this was not significant. Thus, TACE has similar efficacy as compared to sorafenib in advanced-stage HCC. Intrahepatic tumor burden significantly results in mortality in such patients; therefore, locoregional therapy is useful in these cases. TACE might be considered in those patients who are intolerant to sorafenib. However, further studies are required to firmly establish this clause.

Limitations of Our Study

- The sample size of the study conducted was relatively small. The study conducted over larger population and longer period provides more information regarding outcome of sorafenib and TACE in advanced-stage HCC.
- Long-term follow-up of these patients not available due to shorter duration of our study which resulted in shorter survival period.
- There is lack of standardization in procedures, repetitions, and intervals in TACE treatments.
- Few of the patients refused for follow-up which resulted in decreased significance of this study.
- The outcome was evaluated using mRECIST which requires radiological images; hence, there can be intra- and inter-observer variation in the findings.

REFERENCES

1. Stuver S, Trichopoulos D. Cancer of the liver and biliary tract. In: Adami HO, Hunter D, Trichopoulos D, editors. Textbook of Cancer Epidemiology. 2nd ed. New York: Oxford University Press; 2008.
2. Bray F, Ferlay J, Soerjomataram I, Siegel RL, Torre LA, Jemal A, et al. Global cancer statistics 2018: GLOBOCAN estimates of incidence and mortality worldwide for 36 cancers in 185 countries. CA Cancer J Clin 2018;68:394-424.
3. Acharya SK. Epidemiology of hepatocellular carcinoma in India. J Clin Exp Hepatol 2014;4:S27-33.
4. Acharya SK. Epidemiology of hepatocellular carcinoma in India. J Clin Exp Hepatol 2014;4:S27-33.
5. Forner A, Reig ME, de Lope CR, Bruix J. Current strategy for staging and treatment: The BCLC update and future prospects. Semin Liver Dis 2010;30:61-74.
6. Uka K, Aikata H, Takaki S, Shirakawa H, Jeong SC, Yamashina K, *et al.* Clinical features and prognosis of patients with extrahepatic metastases from hepatocellular carcinoma. World J Gastroenterol 2007;13:414-20.
7. Nakano M, Tanaka M, Kuromatsu R, Nagamatsu H, Tajiri N, Satani M, *et al.* Sorafenib for the treatment of advanced hepatocellular carcinoma with extrahepatic metastasis: A prospective multicenter cohort study. Cancer Med 2015;4:1836-43.
8. Kawaoka T, Aikata H, Kan H, Fujino H, Fukuhara T, Kobayashi T, *et al.* Clinical outcome and prognostic factors of patients with hepatocellular carcinoma and extrahepatic metastasis treated with sorafenib. Hepatol Res 2014;44:1320-8.
9. Sohn W, Paik YH, Cho JY, Lim HY, Ahn JM, Sinn DH, *et al.* Sorafenib therapy for hepatocellular carcinoma with extrahepatic spread: Treatment outcome and prognostic factors. J Hepatol 2015;62:1112-21.
10. Jung SM, Jang JW, You CR, Yoo SH, Kwon JH, Bae SH, *et al.* Role of intrahepatic tumor control in the prognosis of patients with hepatocellular carcinoma and extrahepatic metastases. J Gastroenterol Hepatol 2012;27:684-9.
11. Malek NP, Schmidt S, Huber P, Manns MP, Greten TF. The diagnosis and treatment of hepatocellular carcinoma. Dtsch Arztebl Int 2014;111:101-6.
12. Zhao Y, Duran R, Chapiro J, Sohn JH, Sahu S, Fleckenstein F, *et al.* Transarterial chemoembolization for the treatment of advanced-stage hepatocellular carcinoma. J Gastrointest Surg 2016;20:2002-9.
13. Pinter M, Hucke F, Graziadei I, Vogel W, Maieron A, Königsberg R, *et al.* Advanced-stage hepatocellular carcinoma: Transarterial chemoembolization versus sorafenib. Radiology 2012;263:590-9.
14. Kirstein MM, Voigtländer T, Schweitzer N, Hinrichs JB, Marquardt J, Wörns MA, *et al.* Transarterial chemoembolization versus sorafenib in patients with hepatocellular carcinoma and extrahepatic disease. United European Gastroenterol J 2018;6:238-46.
15. Nishikawa H, Osaki Y, Iguchi E, Takeda H, Nakajima J, Matsuda F, *et al.* Comparison of the efficacy of transcatheter arterial chemoembolization and sorafenib for advanced hepatocellular carcinoma. Exp Ther Med 2012;4:381-6.

How to cite this article: Sahu CD, Goel V. Assessment of the Outcome of Transarterial Chemoembolization and Sorafenib in Treatment of Advanced Stage of Hepatocellular Carcinoma: An Observational Study. Int J Sci Stud 2019;7(1):61-67.

Source of Support: Nil, **Conflict of Interest:** None declared.